

A research paper for submission to Prosthetics and Orthotics International

The use of targeted muscle reinnervation for improved myoelectric prosthesis control in a bilateral shoulder disarticulation amputee.

T. A. Kuiken***, G. A. Dumanian***, R.D. Lipschutz*, L.A. Miller*
and K.A. Stubblefield*

Foot note (Affiliations and financial acknowledgements):

*Rehabilitation Institute of Chicago and the Dept. of PM&R at Feinberg School of
Medicine, Northwestern University, Chicago, Illinois, USA.

**The Electrical and Computer Engineering Dept. of Northwestern University,
Evanston, Illinois, USA.

***The Dept of Surgery, Division of Plastic Surgery, Feinberg School of Medicine,
Northwestern University, Chicago, Illinois, USA.

Corresponding Author:

Todd Kuiken, MD, PhD

Rehabilitation Institute of Chicago, Rm. 1124

345 E. Superior St.

Chicago, IL 60611

Tel: 312-238-8072

Fax: 312-238-1166

Email: tkuiken@rehabchicago.org

Key words- myoelectric, reinnervation, prosthesis, EMG

Abstract

A novel method for the control of a myoelectric upper limb prosthesis was achieved in a patient with bilateral amputations at the shoulder disarticulation level. Four independently controlled nerve-muscle units were created by surgically anastomosing residual brachial plexus nerves to dissected and divided aspects of the pectoralis major and minor muscles. The musculocutaneous nerve was anastomosed to the upper pectoralis major; the median nerve was transferred to the middle pectoralis major region; the radial nerve was anastomosed to the lower pectoralis major region; and the ulnar nerve was transferred to the pectoralis minor muscle which was moved out to the lateral chest wall. After five months, three nerve-muscle units were successful (the musculocutaneous, median and radial nerves) in that a contraction could be seen, felt and a surface electromyogram (EMG) could be recorded. Sensory reinnervation also occurred on the chest in an area where the subcutaneous fat was removed. The patient was fit with a new myoelectric prosthesis using the targeted muscle reinnervation. The patient could simultaneously control two degrees-of-freedom with the experimental prosthesis, the elbow and either the terminal device or wrist. Objective testing showed a doubling of blocks moved with a box and blocks test and a 26% increase in speed with a clothes pin moving test. Subjectively the patient clearly preferred the new prosthesis. He reported that it was easier and faster to use, and felt more natural.

Introduction

The control of shoulder disarticulation prostheses is very difficult. A number of functions need to be operated in the prosthesis including the terminal device, wrist, elbow and shoulder joint. Currently, only one function can be controlled at a time with body-power or myoelectric signals. This can be done manually by harnessing shoulder motion. In the case of externally-powered prostheses one function can be operated at a time with either shoulder-operated switches or myoelectric control of a single function using the pectoralis and back muscles. Operation of the terminal device, wrist, elbow and any shoulder locks generally needs to be done sequentially which makes for a very slow and cumbersome process.

Following amputation, the control information for the arm remains in the brachial plexus nerves. The potential exists to transfer these nerves to spare muscle regions on the chest and use these nerve-muscle units to control the prosthesis (Hoffer and Loeb, 1980; Kuiken et al, 2001). This muscle reinnervated with targeted neural inputs could then be used to provide simultaneous control of multiple degrees-of-freedom in the prosthesis. The control would hopefully have a natural feel since the nerves would be controlling the same function in the prosthesis that they controlled in the natural arm.

Research into this concept has been promising. After transection, nerves do not reinnervate their own muscles consistently, which may cause concern for the targeted muscle reinnervation procedure. However, when doing muscle reinnervation for myoelectric control, large nerves containing many motoneurons would be transferred on to a fairly small amount of muscle and would 'hyper-reinnervate' the muscle. Research on rat muscles has shown that hyper-reinnervation improves muscle recovery and with high levels of hyper-reinnervation full muscle recovery can be expected (Kuiken, 1989). Another issue is whether the myoelectric signals could be recorded independently after the recovery. If the cross-talk from multiple nerve-muscle units were large enough to prevent EMG signal isolation and control independence, this would be a hindrance to the success of the procedure. Finite element analyses have shown that the pick-up area of bipolar electrodes which limit EMG cross-talk from adjacent muscles to less than 5% is fairly small—a radius of approximately 10 mm when there is little or no subcutaneous fat (Lowery et al, 2003). Thus muscle reinnervation units need to be greater than 2 cm wide, which should not be problematic.

With this supportive research in hand, the targeted muscle reinnervation procedure was performed in a gentleman with bilateral shoulder disarticulation amputations. This is the first report of using nerve transfers to develop additional myoelectric control sites for improved prosthesis control.

Methods

The patient was a 54 year-old white man working as a high-power lineman, who suffered severe electrical burns in May, 2002. He required bilateral shoulder disarticulation amputations, and his wounds were closed with local viable skin. A split-thickness skin graft measuring about 6 cm by 8 cm closed small areas bilaterally in the upper-thorax along the anterior axillary line.

The patient presented to the Rehabilitation Institute of Chicago approximately 7 weeks after his injury. He was initially fit with a body-powered prosthesis on the right side and an externally-powered prosthesis on the left. The body-powered arm had a

voluntary opening split hook (Homer 5XA), modified four-function wrist unit, internal locking elbow and LTI-Collier manual locking shoulder joint. He had 3 mechanical chin switches mounted near the chin on the socket: one locked and unlocked the elbow; one locked and unlocked the rotation wrist unit and the last switch operated the shoulder lock. The cable, with an excursion amplifier, was utilized for terminal device opening, wrist flexion and supination, and elbow flexion. On the left side the patient was fit with a Griener terminal device; a powered wrist rotator; a Boston digital arm and an LTI-Collier manual locking shoulder joint operated by a single mechanical chin switch. The Boston digital arm was operated using four touch pads mounted in the apex of his socket. The two anterior pads controlled terminal device opening and closing. A superior pad controlled elbow flexion/extension. The posterior pad controlled wrist rotation. The patient received extensive training with his prostheses and did well operating the devices.

The split-thickness skin grafts on both sides became hyper-esthetic and caused the patient considerable pain. His local surgeon recommended surgical revision to remove these problematic skin grafts and resurfacing with local tissue. Since revision surgery was needed, the option of performing targeted muscle reinnervation with his residual brachial plexus nerves to his pectoralis muscles for improved prosthesis control was discussed. The left limb was chosen because that was the side of his externally-powered prosthesis and the choice was made by the patient and medical team not to change the operation of his right body-powered prosthesis which worked well for the patient.

This patient was deemed to be a good surgical candidate for multiple reasons. He had good shoulder motion, strong pectoralis muscle contraction and no sign of brachial plexopathy. The pectoralis muscle, though still under active control, was without function due to the loss of its insertion site on the disarticulated humerus. He had a severe disability and had the potential to gain significant improvement in the operation of his left prosthesis if the targeted muscle reinnervation worked. If the targeted muscle reinnervation failed, his pectoralis muscle would atrophy, but he would still be able to use his prosthesis with the touch pad control. The objective of revising his painful skin graft regions would still be accomplished. Therefore, with IRB approval, insurance approval and the informed consent of the patient, targeted muscle reinnervation was performed as part of his scar revision surgery.

Surgery

The goals of surgery were threefold: The elements of the brachial plexus needed to be safely identified, the muscles of the chest needed to be creatively divided into units based on the muscle innervation and vascularity; and the brachial plexus nerves needed to be mobilized down to the muscle segments. Prior to performing surgery on the patient, a cadaver dissection was performed. The median, musculocutaneous, radial and ulnar nerves were identified and found to form several centimeters proximal to the glenohumeral joint. The pectoralis nerves were delineated as they entered the pectoralis muscle and their branching pattern was established. Finally, the residual nerves were mobilized and routed down to the point where the pectoralis nerve branches inserted into the muscle. An MRI was also taken of the patient's shoulder region to evaluate his brachial plexus.

Under general anesthesia, the split thickness skin graft was excised and large skin flaps were elevated to expose the entire pectoralis major and minor muscles. Dissection between the pectoralis major and minor muscles was performed to identify and preserve the lateral and medial pectoral nerves. The groove between the clavicular and sternal heads of the pectoralis major was developed, and the nerve branches to the clavicular head were identified and tagged.

Next, working first in unscarred tissue cephalad to the amputation site and then working distally, the median, musculocutaneous, radial and ulnar nerves were dissected free and serially identified. The brachial artery and the location of the nerves in relation to this artery were critical in the identification process. After cutting the scarred nerve ends back to healthy appearing fascicles, the nerve ends were indeed long enough to reach the distal aspects of the pectoralis muscle. Functional length was gained, because the nerves were routed more directly towards their new muscle units, as opposed to travelling more laterally in the axilla.

With the knowledge that the nerves had the length to reach their putative targets, the pectoralis major was defined into 3 sections. The clavicular head has its own blood and nerve supply, and was separated bluntly from the larger body of the pectoralis major. The lateral pectoral nerve was noted to split into an upper and lower fascicle after it emerged from the pectoralis minor muscle. The branching served as the basis to further divide the sternal head of pectoralis major transversely into an upper and lower segment. These segments were supplied by vascularity arising from the internal mammary artery. Finally, the origin of the pectoralis minor was mobilized and moved laterally to the level of the mid-axillary line. This was done to prevent its EMG signal from interfering with the EMG signals of the other muscle reinnervation units. All nerve fascicles to these newly created muscle units were divided close to the site where the nerve entered the muscle. The proximal aspect of these nerves were tightly ligated and were mobilized away from these newly denervated pieces of muscle to prevent any spurious reinnervation.

The musculocutaneous nerve was sewn to the clavicular head of the pectoralis major, the median nerve was sewn to the upper segment of the sternal head of the pectoralis major, the radial nerve was sewn to the lower segment of the sternal head, and the ulnar nerve was sewn to the pectoralis minor. In each case, the residual plexus nerve was sewn both to the nerve fascicles leading to the muscle, and to the muscle itself (Fig 1).

Most of the subcutaneous fat was surgically removed over the pectoralis muscles so that the recording electrodes would be as close as possible to the muscle regions of interest with the strongest surface EMG signals possible and the least cross-talk. Finally, the skin was closed over drains.

Recovery

The patient recovered from surgery without complication. After approximately three weeks he was able to wear and use his conventional prostheses. As expected, the patient did not have any voluntary active pectoralis contractions after the surgery. To encourage nerve regeneration, the patient was instructed to try to open and close his left hand, flex and extend his left wrist, and flex and extend his left elbow on a daily basis. After approximately three months the patient noticed his first voluntary 'twitches' in his pectoralis muscle when he tried to bend his missing elbow. By five months he could

activate 3 different areas of his pectoralis major muscle. Trying to flex his phantom elbow would cause a strong contraction of the muscle area just beneath the clavicle. This was consistent with musculocutaneous nerve reinnervation. Closing his phantom hand caused a moderate contraction in the mid-region of the pectoralis major, consistent with median nerve reinnervation. Extending his elbow and hand caused a palpable contraction of the lower pectoralis muscle, consistent with radial nerve reinnervation. No contraction could ever be appreciated on the lateral chest wall indicating that the ulnar nerve to pectoralis minor anastomosis was unsuccessful.

Prosthetic fitting and training

Extensive EMG testing was done on the anterior chest wall. A large EMG signal could be recorded just under the clavicle when the patient tried to bend his elbow. This was expected from the musculocutaneous nerve-muscle unit. Surprisingly two separate EMG signals could be detected in the mid pectoral region where the median nerve-muscle reinnervation was performed. When the patient closed his hand a good EMG signal could be detected on the lateral pectoral region well below the clavicle. When the patient tried to open his hand an independent signal could be detected more medially. Since this was an unexpected result the patient was questioned at length as to what he felt like he was doing to open his hand. It seems that he was attempting some thumb abduction movement to generate this signal, but it felt to him like he was naturally trying to open his hand. In the inferior region of the pectoralis major muscle down near the nipple an EMG signal could be detected when the patient tried opening the hand and extending the wrist. This was an unfortunately small signal containing a significant electrocardiogram (ECG) and the signal was difficult to isolate from the other surface EMG signals.

The new experimental prostheses consisted of a body-powered prosthesis on the right side and the experimental myoelectric prosthesis on the left. The right-side body powered prosthesis was unchanged from the initial design with the exception of adding an electronic lock to the shoulder, which was operated by a single touch pad in the apex of the right socket. The left side prosthesis still consisted of a Griener terminal device; a powered wrist rotator; a Boston digital arm and a LTI-Collier shoulder joint. An electronic lock was also added to the left shoulder joint, operated with a single touch pad in the apex of the left socket. The decision was made to use the three most robust EMG signals to control the externally-powered prosthesis. The Liberating Technologies Inc. was very helpful in designing the new control programs that were needed. The musculocutaneous nerve-muscle unit EMG signal was used to provide proportional control of elbow as a "myoservo." With the "myoservo" control, the amount of elbow flexion is proportional to the magnitude of the EMG signal: a small contraction flexing the elbow slightly and a strong contraction flexing the elbow fully, relaxing the contraction would then extend the elbow. If the EMG signal was held constant for about 1-2 seconds the elbow would lock in place. A muscle contraction of higher magnitude than the level where the arm stopped would then release the lock. The two areas in the median nerve-muscle unit that provided hand opening and closing surface EMG signals were used to proportionally control the terminal device. For control of wrist rotation the patient had two choices. The initial intent was for him to activate touch pads in the posterior of the socket to control rotation of the wrist, as with his previous prostheses.

However, one software version allowed him to use his hand opening and closing EMG signals to sequentially control wrist pronation and supination. A strong co-contraction of the signals would switch operation from terminal device to wrist control. Once the wrist was positioned he would co-contrast to switch back to terminal device control. Since the patient liked this control paradigm he was provided with the option of using either the touch pad or the EMG co-contraction for mode selection of the terminal device and wrist. Another touch pad mounted superiorly in the apex of the socket was used to operate the shoulder lock.

Once again, a fairly extensive rehabilitation program was performed with close collaboration between the medical, prosthetic and occupational therapy teams. The patient lived in another state so he would come and stay in a nearby hotel for two week blocks of time while he was worked with daily. He was treated for the initial fitting then went home for a month to practice. He returned for another two weeks of practice with the device in a preparatory stage then went home to practice with the device for two more months. He returned for two more weeks to have the definitive device fit, to have some more therapy and finally to do some performance testing.

Testing

For objective testing, two tests were performed comparing the function of the touch pad prosthesis to the new myoelectric prosthesis. The only standardized and validated test that the team felt was applicable was the box and blocks test (Mathiowetz et al, 1985). In this test the subject moves one-inch square blocks from one box, over a short wall and into another box. The goal is to see how many blocks the subject can move in one minute. The test was modified slightly allowing the patient two minutes to move blocks. A clothes pin test was developed that required use of the terminal device, elbow and wrist rotator unit. In this test the patient picked up clothes pins off of a horizontal bar, rotated the pins and placed them on a higher vertical bar. The goal was to see how long it took the subject to move three clothes pins. For these tests the patient started with his original left touch pad controlled externally-powered prosthesis. The patient was allowed to practice each task for several minutes until he felt comfortable with the task. He then performed each task three times with rest breaks of several minutes in between. The patient then donned the experimental prostheses and used the left sided myoelectric prosthesis first to practice the task, then to perform each test three more times with rest breaks in between each trial. For each trial and each prosthesis, the patient began with the arm fully extended at his side.

Results

As noted above four targeted muscle reinnervation segments were performed. Three of the muscle reinnervations were successful in that a contraction could be palpated, seen visibly and an EMG signal could be recorded from the muscle segment. The three successful nerve-muscle units used the musculocutaneous nerve, the median nerve and the radial nerve. All three of these nerves were transferred to different regions of the pectoralis major muscle. One muscle reinnervation was unsuccessful; this was the ulnar nerve to pectoralis minor nerve anastomosis. No visible, palpable or electrical activity

could be detected in the area of the lateral chest wall where the pectoralis minor muscle was moved.

In addition to the motor reinnervation of the muscle, sensory cross-reinnervation occurred in the skin of the chest wall. When the chest wall was touched lightly in different places the patient had a sensation of a light touch to different parts of his hand and arm. This sensory reinnervation took place primarily over the region where the musculocutaneous and median nerves were anastomosed which consisted of the upper two-thirds of the pectoralis major muscle. This sensory cross-reinnervation is diagrammed in Figure 2.

Three independent EMG control signals could be reliably recorded on the surface of the patient's chest; one over the musculocutaneous nerve-muscle unit and two over the median nerve-muscle unit. These allowed myoelectric control of the patient's terminal device, wrist and elbow as noted above. It was also noted that the patient could simultaneously operate the two functions—the elbow and either the terminal device or the wrist rotator—at the same time. This allowed him to, for example, throw a ball. He could initiate the throw with his elbow flexing and then let go of the ball in mid swing with the terminal device.

Objective testing of the patient's prosthetic function was done with the standard box and blocks test and a clothes pin test. The results of the box and blocks test are shown in Table 1. The patient was able to move more than twice as many blocks with his experimental myoelectric prosthesis as he was with his touch pad controlled externally-powered prosthesis. The results of the clothes pin test are summarized in Table 2. The patient was able to remove the clothes pins an average of 26% faster with the experimental myoelectric prostheses than he could with his original touch pad controlled externally-powered prosthesis.

Just as important as the objective testing were the patient's subjective preferences and impressions. The patient reported that he strongly preferred the new myoelectric prosthesis to his previous devices—he felt that there was a “night and day” difference. He found that the myoelectric prosthesis was much easier to use and faster. Perhaps the most telling statement was “when I use the new prosthesis I just do things—I don't have to think about it.” There are also a number of tasks that the patient reports he could do better with his new prosthesis and some tasks that he can now do with his new myoelectric prosthesis that he could not do with his previous devices; these are listed in Table 3. There was one significant problem with the new prosthesis that the patient noted. When he got very sweaty the prosthesis did not work as well. He then needed to take off his prostheses, dry off and then don the devices again, which was a fair amount of work for this patient.

Discussion

This paper presents the first application of the targeted muscle reinnervation technique for improved myoelectric prosthesis control. The idea is fairly simple; muscle is being used as a biological amplifier of the nerve signal to obtain additional independent control signals for operation of a multifunction prosthesis. Fortunately the terminal nerve branches of the brachial plexus have discreetly different functions, thus independent functional controls can be recorded from each nerve-muscle unit. The signaling for the

prosthesis is obtained without the need for implantable wires and devices which run the lifetime risk of infection, dislodgement and breakage.

Three important anatomic principles were demonstrated in this case. First, the brachial plexus differentiates into the median, ulnar, musculocutaneous and radial nerves in the mid-clavicular region. This is essential to have the discreetly different functions of these nerves available for control signals. Second, the distal brachial plexus and the terminal nerve branches could be mobilized down onto the chest wall and reach the pectoralis major and pectoralis minor muscles without the need of an additional nerve-to-nerve grafts. The length of the residual nerves can be judged clinically by the presence of a “Tinel” sign, by a history taken from the amputation surgeon, and from radiologic studies such as MRI’s. Finally, the pectoralis major muscle was successfully divided into three parts to form three separate nerve-muscle units. Simply cutting the muscle formed an adequate barrier to the reinnervating nerves to contain the reinnervation process in the desired area. If there had been overlap of reinnervation into the three parts then the independence of the surface EMG signals would have been compromised.

Three of the four targeted muscle reinnervations were successful. The musculocutaneous nerve anastomosis to the subclavian pectoralis major muscle area yielded the most robust myoelectric signal. This may be in part due to the proximity of the clavicle since bone can act as an electrical insulator, containing the conduction currents of the EMG signal and causing a larger surface EMG (Lowery, 2002). This nerve-muscle unit allowed for single site control of the powered elbow in a myo-servo control paradigm.

The median nerve anastomosis to the mid pectoral muscle region gave perhaps the most surprising result. Two distinctly separate myoelectric signals could be recorded in this region; one generated by hand closing (as expected) and one generated by hand opening (a very unexpected result). With interviewing the patient it seemed that the hand-opening task he was attempting may have been a thumb abduction movement. Perhaps the portion of the median nerve that innervated the abductor pollicis brevis dominated an area of reinnervation that allowed us to record the independent surface EMG signal. In the future it may be possible to subdivide individual terminal nerve branches of the residual nerves into different fascicles and make multiple independent EMG signals for control of myoelectric prostheses. In this case it was just good fortune.

The radial nerve anastomosis to the lower pectoralis major muscle region was a disappointment. The nerve-muscle unit was clearly successful in that a visible and palpable contraction could be appreciated. However, a very strong EMG signal could not be obtained nor was the signal obtained very independent from the other EMG signals. Furthermore, the electrocardiogram (ECG) was considerably larger in this EMG. The small EMG amplitude for this site may be the result of insufficient removal of the subcutaneous fat in this region which attenuated the EMG. Perhaps if the subcutaneous fat had been removed the EMG signal would have been larger and the ECG proportionately smaller. Removing subcutaneous fat has been shown to increase surface EMG amplitude and signal independence (Kuiken, 2003). The case presented here emphasizes this result. With regard to EMG signal independence, the signal may have been contaminated by co-contraction and with enough practice the patient could have learned to activate it independently. Nevertheless, this site was not used for control of the prosthesis.

The one targeted muscle reinnervation that clearly failed was the ulnar nerve to pectoralis minor anastomosis. This result is consistent with the poor return of ulnar nerve motor function after surgical repairs often seen in hand surgery. The pectoralis muscle also had a slightly violaceous hue after mobilization, suggesting a mild congestion of its vascular supply. The blood supply to the pectoralis minor muscle may have been compromised when it was moved laterally out from under the pectoralis major.

Another unexpected and interesting result was that skin sensory reinnervation occurred. Touching the chest in different places produced a sensation in different areas in his phantom hand and arm. This sensory reinnervation only happened over the upper and middle pectoralis major regions where the subcutaneous fat was surgically excised. When the fat was removed the skin was denervated and the patient did have some numbness in the chest. The sensory elements of the nerve transfers then reinnervated this region producing the cross-sensory reinnervation. Of note, there was no cross-sensory reinnervation of the lower pectoral region where the subcutaneous fat was not removed.

In this patient three independent surface EMG control signals were obtained. Furthermore, this demonstrated, for the first time, simultaneous control of two degrees-of-freedom with only myoelectric control. The fact that the patient could throw a ball was clear evidence of the simultaneous control of the elbow and hand. Furthermore the patient could operate his device more quickly. This is due to the fact that he did not have to stop and change a control input and because he was using physiologically natural controls.

Evaluating the success of upper limb prosthetic function is a very difficult task—especially for such a severe disability as bilateral shoulder disarticulation amputations. For objective testing, the only standardized test that was felt to be applicable was the box and blocks test (Mathiowetz, 1985). This is a fairly simple test that is validated and widely used. The box and blocks test only required use of the terminal device and elbow. The clothes pin test was therefore developed. This test was also fairly simple, but it required use of the terminal device, elbow and wrist rotator unit so therefore added some value in determining whether the function of the patient improved in this experiment. In both of these tests the patient performed considerably better with the new myoelectric prostheses than he did with the touch pad controlled device. This demonstrated superior function with the targeted muscle reinnervation myoelectric control in this particular case. However, both of these tests are artificial and therefore somewhat unsatisfying—tests of a more practical nature would have been preferred, but were not possible with the level of disability in this patient.

Just as important as the objective testing was the subjective response of the patient. He clearly preferred the new targeted muscle reinnervation myoelectric control system to his original touch pad system. He found the device was easier to use, faster and more natural to control. There is likely some bias in these opinions because he would like to please the clinicians with whom he formed a strong bond. However the fact that he chooses to wear the new prostheses rather than the old and that he had a significant list of items he felt he could only do with the new devices is telling.

For the original set of prostheses the patient was fit with touch pad controls in his left externally-powered prosthesis. There were many other control systems possible. In particular a controller could have been developed using EMG signals from the pectoralis, trapezius, infraspinatus and/or latissimus dorsi muscles. It is possible that a better control

system could have been built for his first prosthesis and such a system might have compared better to the targeted muscle reinnervation control system. It is also possible that some back muscle EMGs could have been used in addition to the nerve-muscle unit signals and made an even better control system for his second prosthesis. However, when these options were first presented to the patient, he preferred the idea of the touch pads. Additionally, it was determined that this type of control would be less likely to interfere with operation of the right-side body-powered prosthesis.

This case demonstrates the need for more research. A larger clinical trial in shoulder disarticulation amputees with appropriate objective and subjective testing is warranted to see if these results can be repeated or even improved upon. Development of quantifiable tests would also assist in the objective comparison of different designs for higher level amputees. Controlling the elbow, wrist and terminal device of a prosthesis with targeted muscle reinnervation also frees up shoulder motion, thus shoulder motion could be used to control a powered artificial shoulder, rather than only the locking function, if such a device became available. Having control of both a shoulder and distal arm would be a great advancement for shoulder disarticulation amputees. The targeted muscle reinnervation procedure may also be applicable to other levels of amputation. For example in a transhumeral amputee the medial biceps could be denervated and the median nerve could be anastomosed onto it. Similarly the radial nerve could be transferred onto a denervated brachialis muscle. Once reinnervated, these muscles could allow for myoelectric control of a terminal device while the lateral biceps and triceps provide simultaneous control of the elbow. Finally, the targeted muscle reinnervation technique opens up possibilities of even better control with advanced signal processing systems (Lyman et al, 1974; Wirta et al, 1978; Alstrom et al, 1981; Graupe et al, 1985; Hudgin et al, 1993; Lee et al, 1996; Ferry et al, 1997; Gallant et al, 1998; Chan et al, 2000; Englehart et al, 2001). The targeted muscle reinnervation makes more information content available for use with such state-of-the-art systems.

Conclusions

By anastomosing the residual peripheral nerves to the pectoralis major muscle in a shoulder disarticulation patient additional independent myoelectric control signals were developed. These additional control signals allowed simultaneous control of two degrees-of-freedom using just the EMG signals. In this patient both objective testing and subjective impressions demonstrated improvement in the speed and ease of use of the prosthesis. Sensory reinnervation of the chest with the nerve transfers occurred in areas where the subcutaneous fat was removed.

Acknowledgements

We would like to thank Richard Weir, Craig Heckathorne and Bolu Ajiboye for their assistance with this project. We would also like to thank the Liberating Technologies Inc. for their assistance in developing appropriate prosthetic computer control system for this research project.

This work was supported by the National Institute of Child and Human Development (Grant #1K08HD01224-01A1) and the National Institute of Disability and Rehabilitation Research (Grant #H133G990074-00).

References

- Alstrom C, Herberts P, Korner L (1981). Experience with Swedish multifunctional prosthetic hands controlled by pattern recognition of multiple myoelectric signals. *Intl Orthopedics* **5**, 15-21.
- Chan FHY, Yang YS, Lam FK, Zhang YT, Parker PA (2000). Fuzzy EMG classification for prosthesis control. *IEEE Trans Rehab Eng* **8**, 305 – 311.
- Englehart K, Hudgins B, Parker PA (2001). A wavelet-based continuous classification scheme for multifunction myoelectric control. *IEEE Trans Biomed Eng* **48**, 302-311.
- Farry K, Fernandez J, Abramczyk R, Novy M, Atkins D (1997). Applying genetic programming to control of an artificial limb. *Issues in Upper Limb Prosthetics*, Institute of Biomedical Engineering, University of New Brunswick, 50-55.
- Gallant PJ, Morin EL, Peppard LE (1998). Feature-based classification of myoelectric signals using artificial neural networks. *Med & Biol Eng & Comp* **36**, 485-489.
- Graupe D, Salahi J, Zhang DS (1985). Stochastic analysis of myoelectric temporal signatures for multifunctional single-sit activation of prostheses and orthoses. *J Biomed Eng* **7**, 18-29.
- Hoffer JA, Loeb GE (1980). Implantable electrical and mechanical interfaces with nerve and muscle. *Ann of Biomed Eng* **8**, 351-360.
- Hudgins B, Parker P, Scott R (1993). A new strategy for multifunction myoelectric control. *IEEE Trans Biomed Eng* **40**, 82-94.
- Kuiken TA, Rymer WZ, Childress DS (1995). The hyper-reinnervation of rat skeletal muscle. *Brain Res* **676**, 113-123.
- Kuiken TA, Stoykov S, Popovic M, Lowery M and Taflove A (2001). Finite element modeling of electromagnetic signal propagation in a phantom arm. *IEEE Trans Neural Sys and Rehab Engr* **9**(4), 345-354.
- Kuiken TA, Lowery MM and Stoykov NS. The Effect of Subcutaneous Fat on Myoelectric Signal Amplitude and Cross-Talk. *Prosthetics and Orthotics International* **27**, pp 48-54, 2003.
- Lee SP, Park SH., Kim J, Kim I (1996). EMG pattern recognition based on evidence accumulation for prosthesis control. *Proc Ann Intl Conf IEEE Eng Med Biol* **4**, 1481-1483.
- Lowery MM, Stoykov NS, Taflove A and Kuiken TA. A Multi-Layer Finite Element Model of the Surface EMG Signal. *IEEE Transactions in Biomedical Engineering* **49**(5), pp. 446-54, 2002.
- Lowery MM, Stoykov NS and Kuiken TA (2003). Independence of myoelectric control signals examined using a surface EMG model. *IEEE Transactions on Biomedical Engineering*, **50**(6), 789-793.
- Lyman J, Freedy A, Solomonow M (1974). Studies toward a practical computer-aided arm prosthesis system. *Bulletin Prosth Res* **10**, 213-225.
- Mathiowetz V, Volland G, Kashman N and Weber K (1985). Adult norms for the box and blocks test of manual dexterity. *Am J of Occ Ther* **39**(6), 386-391.
- Wirta RW, Taylor DR, Finley FR (1978). Pattern recognition prostheses: a historical perspective—final report. *Bulletin Prosth Res* **10**, 8-35.

Tables

Table 1. Comparison of box and block test for touch pad controlled prosthesis and nerve-muscle graft controlled prosthesis.

	Touch pad control Number of blocks	Myoelectric control Number of blocks
Trial 1	5	10
Trial 2	5	14
Trial 3	7	18
Average	5.7	14

Table 2. Comparison of clothes pin test for touch pad controlled prosthesis and nerve-muscle graft controlled prosthesis.

	Touch pad control Time (sec)	Myoelectric control Time (sec)
Trial 1	153	83
Trial 2	137	122
Trial 3	121	99
Average	137	101

Table 3. Patient's self-report of improved function with nerve-muscle graft controlled prosthesis.

Things patient can do <u>better</u> with myoelectric prosthesis	<u>New things</u> patient can do with myoelectric prosthesis
Take out garbage	Feed himself
Carry groceries	Shave
Pick-up yard	Put on socks
Vacuum	Weed in garden
Dust mop	Water the yard
Pick up toys	Open small jar
Put on hat	Use pair of handicap scissors
Put on glasses	Throw a ball
Wash driveway	

Legend

Figure 1. Diagram of nerve-muscle graft procedure.

Figure 2. Diagram of sensory reinnervation of anterior chest wall indication where touching the patient produced sensation in his phantom arm.

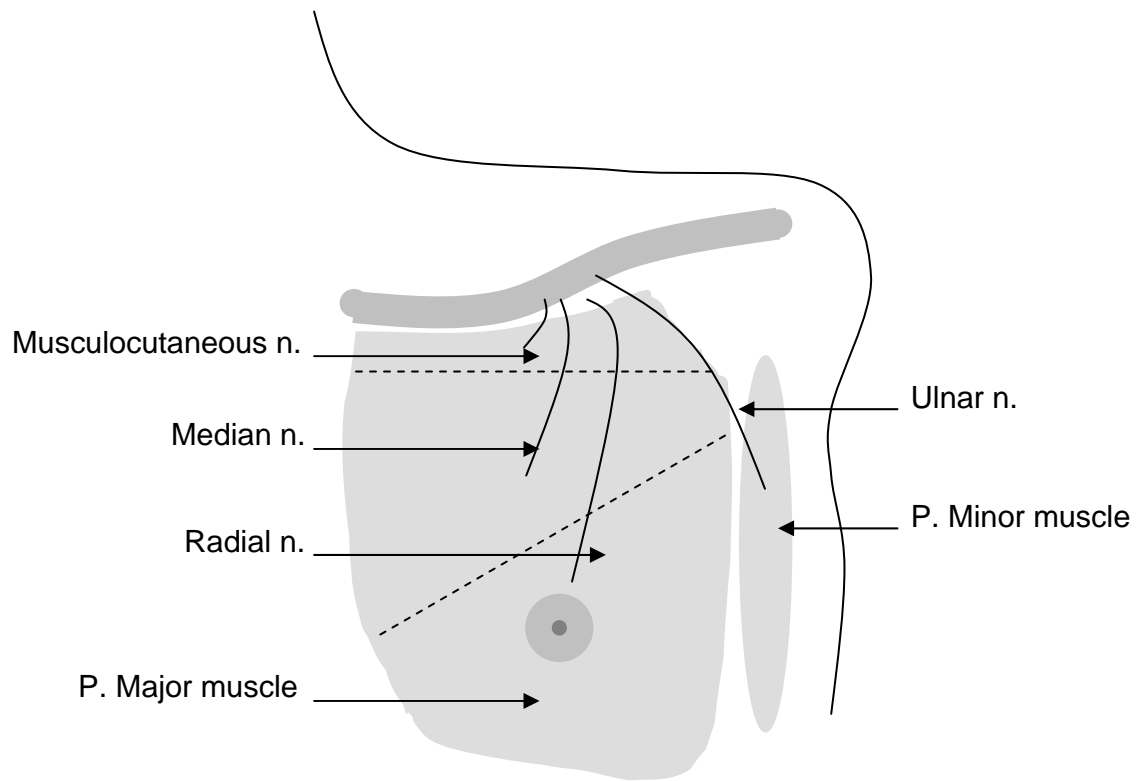


Figure 1.

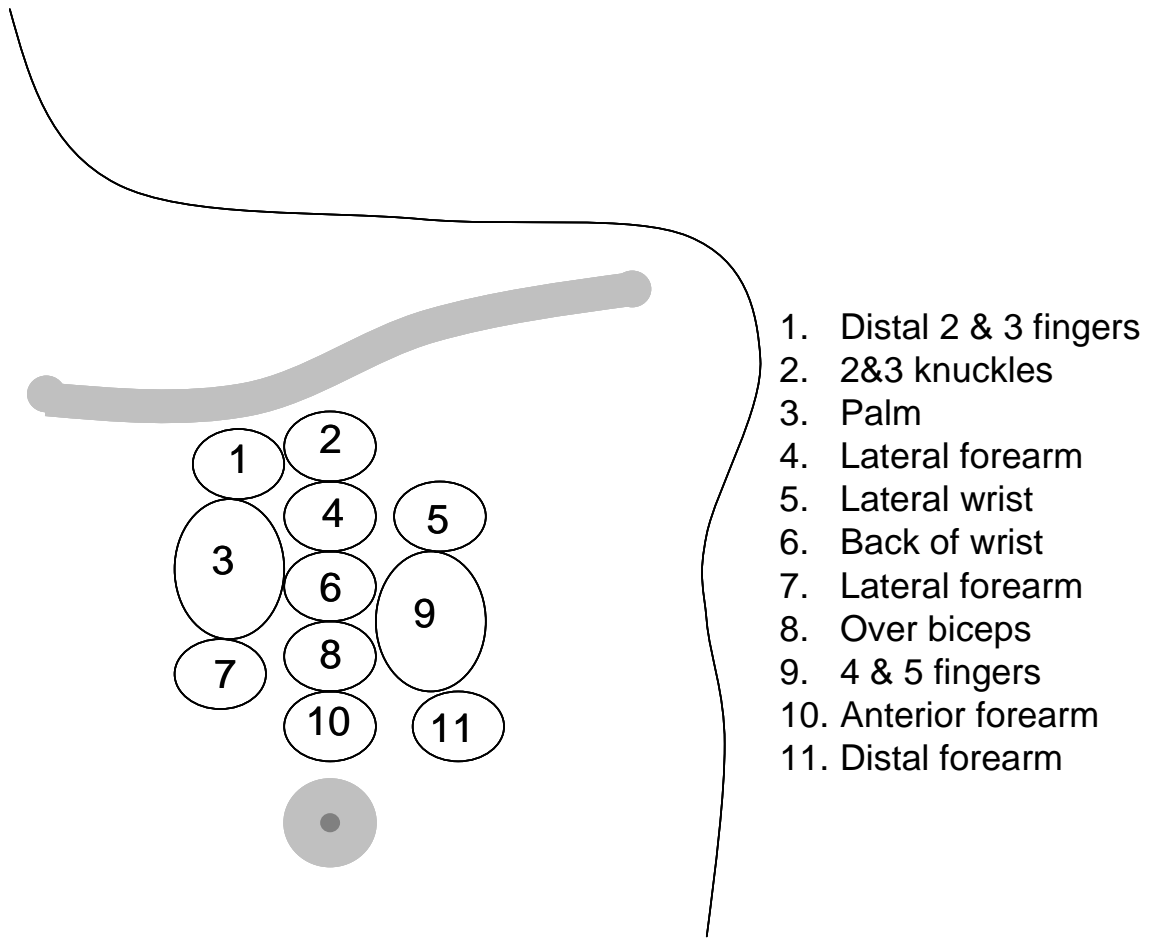


Figure 2.