

VASCULARIZED FIBULAR GRAFT TRANSPOSITION TO UPPER FEMUR AVOIDING MICROSURGERY

LUCIANO RUIZ TORRES¹, FERNANDA BOGDANOVICS PAGANOTTI¹, GUILHERME PELOSINI GAIARSA¹,
HSIANG WEI TENG¹, FRANCISCO PEREZ SORO NETO², DAN CARAI MAIA VIOLA²,
FABIANO INÁCIO DE SOUZA¹, CLÉCIO SEIJI YUHARA², RAMES MATTAR JÚNIOR¹, LEONARDO FRANCO PINHEIRO GAIA¹

ABSTRACT

Objective: The study describes a new and simple way to transpose a vascularized fibular graft from the fibula to the femur diaphysis without the need for microsurgery, demonstrates a successful clinical case with good results with regards to vascularization and osseous consolidation, and speculates about other applications of this flap procedure in reconstructive surgery. **Methods:** A stalked vascularized fibular bone graft was transferred without microsurgery. The bone reached the proximal diaphysis of the femur. Communication between the lateral gastrocnemius arterial system and fibular artery through a skin flap and its perforating

arteries allowed good vascularization to the graft. The concept of "perforating artery-to-perforating artery" was established with their vascular territories intersecting the skin island flap. **Results:** The patient operated on healed without infection. Bone scintigraphy showed periosteal bone vascularization. **Conclusion:** The Cutaneous Gastrocnemius–Fibular Flap is a new weapon for the reconstructive surgeon. It's practical and reliable, and its reduced surgery time and its principle of construction will be applicable to the creation of other flaps.

Keywords: Bone transplantation. Surgical flaps. Fibula/transplantation. Muscle, Skeletal.

Citation: Torres LR, Paganotti FB, Gaiarsa GP, Teng HW, Soro Neto FP, Viola DCM et al. Vascularized fibular graft transposition to upper femur avoiding microsurgery. *Acta Ortop Bras.* [online]. 2010; 18(4):212-7. Available from URL: <http://www.scielo.br/aob>

INTRODUCTION

Small posttraumatic bone defects can be treated by conventional bone grafting. However, the superiority of the consolidation potential of the vascularized bone graft when compared with the conventional autologous graft and bone substitutes, as well as its lower postoperative resorption, is firmly established in literature¹⁻³ and in our field.⁴⁻⁶

The resistance to unfavorable and previously infected environments of a vascularized live tissue is also superior to that which demands revascularization by the adjacent bed.^{1,7}

Since its first description by Taylor,⁸ the microsurgical transplantation procedure of the vascularized fibula has been considered of high technical demand, in our opinion comparable to Grade 4 of the classification of dissection of skin flaps.⁹

Fibular dissection involves opening of all the leg compartments. The pedicle of the fibular artery, in general, can only be elongated up to its origin in the tibiofibular trunk. Proceeding with its

elongation implies ligation of the posterior tibial artery and risk of devascularization or hypovascularization of the lower limb. The ideal positioning of the vascularized bone graft is also difficult, often requiring the use of vascular loops due to the bone depth and short extension of the fibular pedicle.*

Described previously¹⁰⁻¹⁴, transposition of the pediculated fibula, based on its proximal pedicle reaches at most the distal metaphyseal region of the femur. Its dissection is also laborious, resembling the dissection of the fibular skin flap (lateral flap of the leg).

Also in relation to vascularized bone grafts, other flaps allow their osteocutaneous form: lateral arm flap associated with the humerus, antebrachial (Chinese) flap with radial segment, ulnar artery flap with ulnar segment, parascapular flap with lateral edge of the scapula, serratus anterior flap with ribs, large dorsal flap with rib/scapula, trapezial flap with scapula, inguocrural flap with iliac crest, osteocutaneous medial femoral condyle flap, second metatarsal associated with dorsal flap of the foot. Almost

All the authors declare that there is no potential conflict of interest referring to this article.

1 – LIM 41 – Laboratory of Medical Investigation of the Musculoskeletal System of the Department of Orthopedics and Traumatology of HC/FMUSP
2 – Hospital Municipal Moysés Deutsch, São Paulo, SP

Study developed at the Institute of Orthopedics and Traumatology of HC-FMUSP – Trauma, Hand and Microsurgery Discipline / Hand and Microsurgery Group and at Hospital Municipal Moysés Deutsch
Mailing address: Rua Barata Ribeiro, 414, cj. 23, São Paulo, Bela Vista, SP- Brazil, CEP: 01308-000. E-mail: lucrut@terra.com.br

Article received on 5/07/09 and approved on 8/12/09

* Cavadas, personal communication at the International Symposium of SBMR - December/2008

all of these are performed in the microsurgical form for the thigh. The exception is the iliac crest flap that can be pediculated on the deep iliac circumflex artery in rotation for femoral head in the treatment of osteonecrosis, yet it does not reach the diaphyseal region of the femur.

As regards muscular flaps, Ger^{15,16} popularized the concept of covering a defect with transposition from a local muscle then grafting with partial skin. Orticochea¹⁷ first described the transplantation of skin adjacent to the muscle on the lower limb. McCraw et al.¹⁸ then McCraw and Dibbel¹⁹ demonstrated that the skin adjacent to the muscles receives its vascular supply from perforating branches of the vessels that irrigate the muscle. McCraw et al.²⁰ Morris,²¹ Mathes and Nahai,²² Salibian and Menick²³ and Cheng et al.²⁴ further expanded the limits for use of the musculocutaneous gastrocnemius flap for defects in the distal third of the leg and thigh.

The most refined study of the physiology of flaps based on perforating pedicle, in the last decade²⁵⁻²⁸, allowed the use of new local flaps in an island called propeller flaps. In these, the dissection of a perforating pedicle in an eccentric region of the flap allows its rotation, up to 180 degrees, reaching the targeted defect, with a large quantity of tissues perfused by a single perforating vessel.^{29,30} The idea that a cutaneous artery pierces the muscle and reaches the homogeneous vascular mesh of the skin, allowing the irrigation of large areas, became clearer. These perforating arteries can also be irrigated in a reverse manner, when there is the performance of ligation of the origin of a perforating pedicle that entered the skin of a flap already irrigated by another source. In this manner it is possible to add part of the muscle adjacent to this perforating artery at the skin island flap, generating chimeric flaps.³¹⁻³³

Nevertheless, different from muscular tissue, the application of the same principle to the use of vascularized bone tissue with considerable mobility of its pedicle and of this in relation to the skin/muscle portion taken is not described in the medical literature examined.

The aim of this study is to describe a new and simple way of transplanting the vascularized bone graft from the fibula to the femur diaphysis without the need for microsurgery and to speculate about other possible applications in reconstructive surgery.

MATERIAL AND METHOD

We conducted a prior anatomical study of the perforating vessels of the medial gastrocnemius muscle.³⁴ In the subsequent clinical experience, increasingly larger skin islands were lifted from the flap without presenting damage. Accordingly, the muscle becomes, for the most distant defects, a "carrier" of vascularized skin. Once familiarized with the irrigation power of a perforating vessel of the gastrocnemius muscle, we also begin to use the lateral head of this muscle. This muscle has smaller proportions than the medial head and leads to an even lower plantar flexion deficit, within the global structure of the triceps surae. It is, however, able to associate the same quantity of skin necessary for the defects, easily reaching the middle third and the transition from the middle to the proximal third on the lateral side of the thigh.

In a study of the perforating branches of the fibular artery, Yoshimura et al.³⁵ differentiated musculocutaneous and septomusculocutaneous perforating branches, travelling between soleus and fibular,

but emitting muscular branches and pure septocutaneous vessels, with a greater probability of finding septal vessels in the distal third of the leg and others in the proximal and middle third.

We then proposed the removal of the lateral head of the gastrocnemius muscle in a musculocutaneous manner where the skin island formed an intersection with the emergence of the distal fibular artery perforating branches. (Figure 1) The largest of these perforating branches is dissected unscathed up to the fibular pedicle and this is removed together with the fibular segment, with ligation of the fibular pedicle proximal and distal to the resected bone. (Figure 2) Thus the skin irrigated by perforating arteries of the lateral head of the gastrocnemius muscle reversely supplies the fibular pedicle that enters the fibula, reaching the femur diaphysis, with the possibility of rotation of this fibular perforating artery in relation to the skin. (Figure 3)

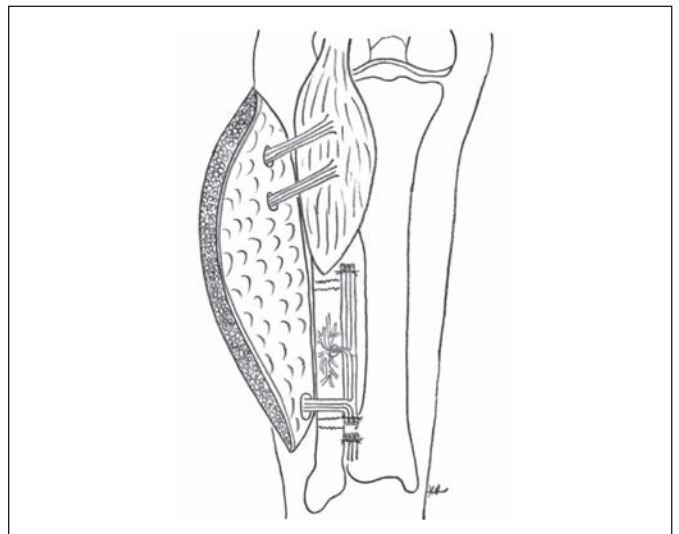


Figure 1 – Representation of the skin flap performing the communication of the perforating vessels of the lateral gastrocnemius system and of the fibular artery; in the detail a periosteal branch to the fibula emerging from the vascular pedicle.

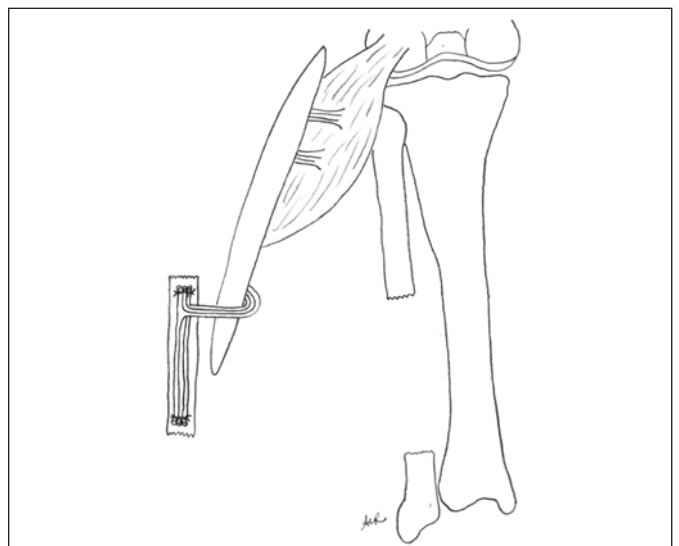


Figure 2 – Flap raised, ready for the transplantation.

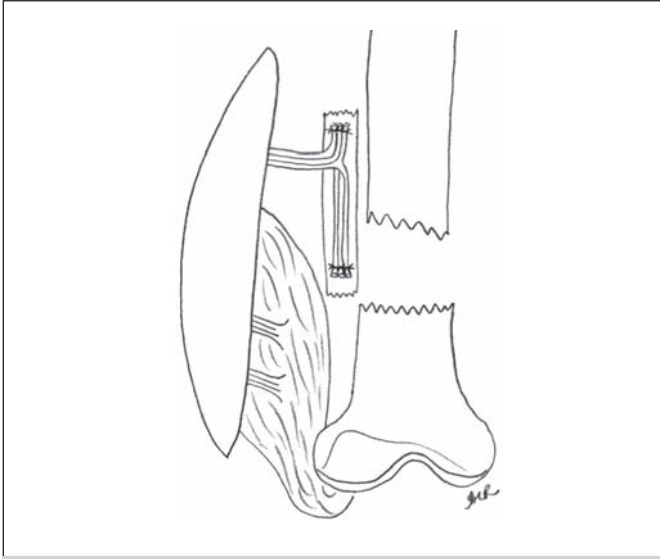


Figure 3 – Positioning of the vascularized bone graft in relation to the femur on the thigh after transposition.

CLINICAL CASE

The patient is a 23-year old male student, with infected pseudoarthrosis of the right femur after trauma. He previously underwent 14 surgical treatments without obtaining success in the cure of the infection and bone consolidation. (Figures 4 and 5)

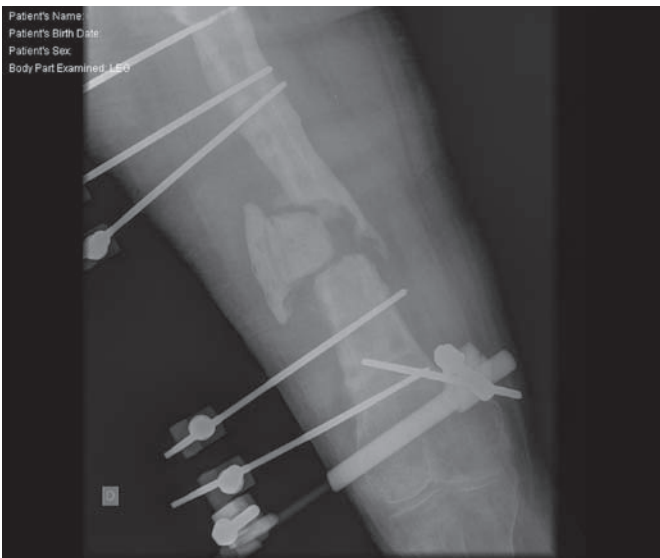

Figure 4 – Preoperative radiography demonstrating cement spacer, defective pseudoarthrosis of the femur and bone of poor quality.

The medical team performed aggressive debridement of all the devitalized tissue (Figure 6), installation of uniplanar external fixator and raising of the lateral gastrocnemius flap with extensive skin island involving the posterior and lateral sides of the leg and including fibular perforating artery of the distal 1/3 of the leg. This was dissected and removed with the bone graft of the fibula and segment of fibular vessels adjacent to the bone. (Figure 7) Flap positioning rotation was performed with a pro-

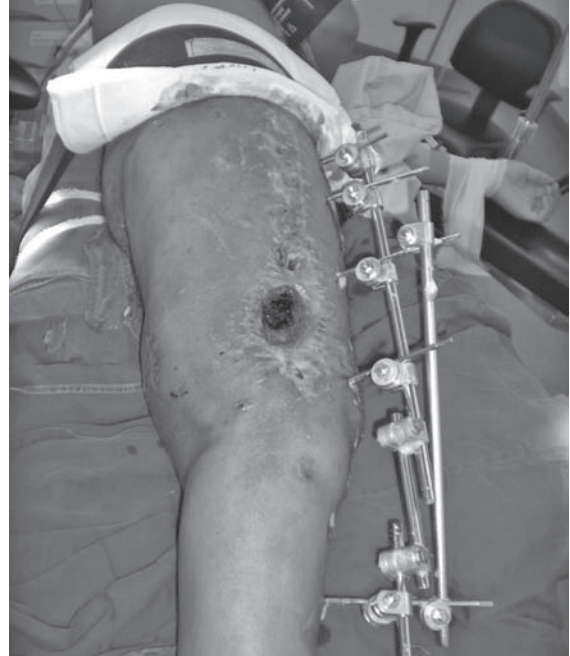

Figure 5 – Observe the infected wound and cicatricial cutaneous covering that does not provide protection to the bone.



Figure 6 – After extensive debridement of the surgical wound and of the devitalized bone tissue.

pellor on the fibular perforating vessel in order to position the largest portion of bone at the femoral pseudoarthrosis site, not involving any tension or difficulty. (Figure 8) For technical ease the bone was positioned at the pseudoarthrosis focus without osteosynthesis.

The patient received broad-spectrum antibiotics. The flap donor area received a partial skin graft removed from the same thigh with dermatome or Blair knife.

RESULTS

Effective success was achieved in overcoming the infection and integrating the skin flap to the coverage of the ulcer and of the unstable tegument. (Figure 9) The skin graft was integrated to the donor area of the flap on the leg.

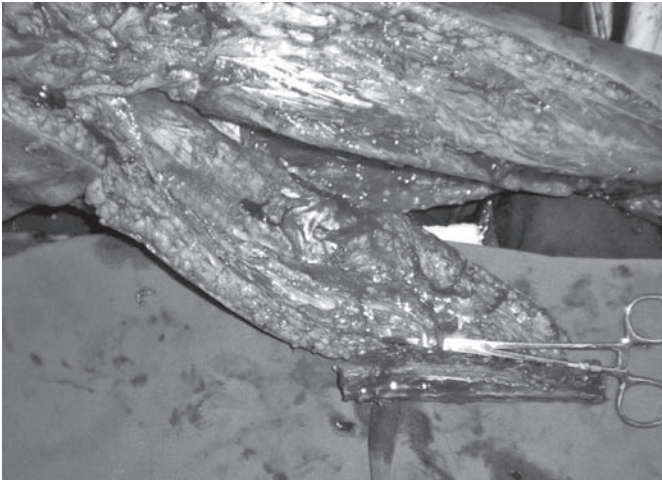


Figure 7 – Flap of the dissected lateral head of the gastrocnemius muscle (its medial side), its associated skin island and in the detail the perforating vessel that communicates the skin island with the vascular pedicle of the fibula, under the hemostatic forceps.

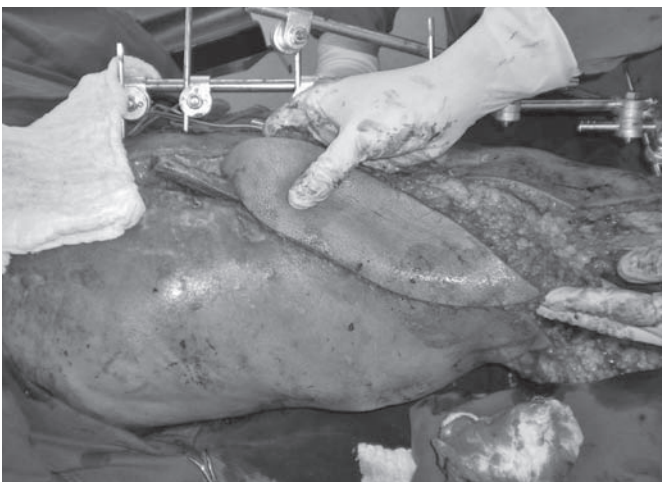

Figure 8 – Ease of vascularized bone to reach the proximal femur in the technique.

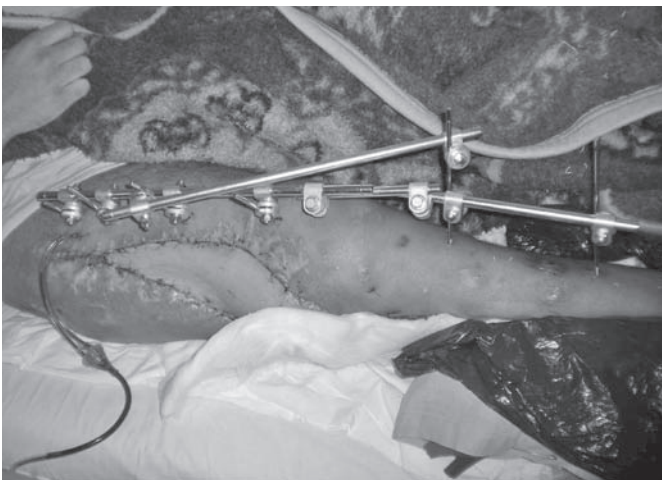

Figure 9 – Photograph in 1st postoperative week. Integration of flap and graft without infection.

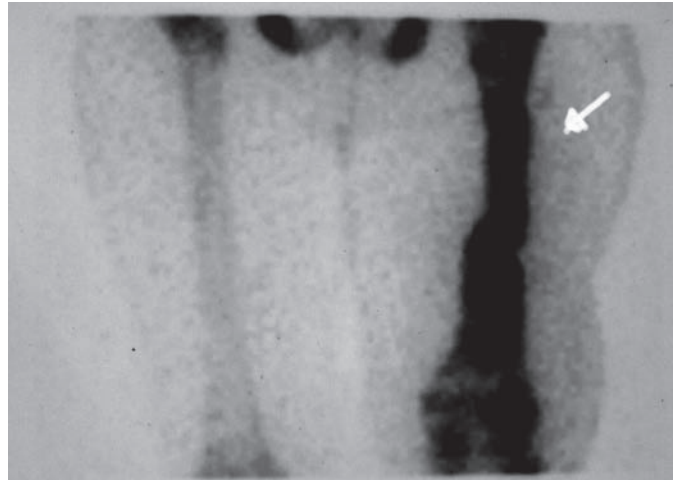


Figure 10 – Skeletal scintigraphy with Tc 99 demonstrating periosteal reception of the vascularized bone graft.

Early skeletal scintigraphy showed a tenuous area of hyperconcentration of the radiopharmaceutical sidelong to the femur that corresponds to periosteal uptake of the fibular graft. (Figure 10) This was corroborated by the intra-operative finding that showed clear filling of the fibular vessels and abundant periosteal bleeding from the fibula. Therefore, this should be the scintigraphic expression of a vascularized bone graft supplied only by a perforating vessel. Periosteal irrigation is prioritized to the detriment of the nutrient vessels according to the graft vascularization sources proposed by Harii³⁶. (Figure 11)

The evolution of this case demonstrated this adequate bone vascularization. The bone is consolidated and no additional osteosynthesis procedure was performed. (Figures 12 and 13) The levelling of length of the lower limbs will be performed at the expense of tibial lengthening with circular apparatus, accepting unlevelling of the knees.

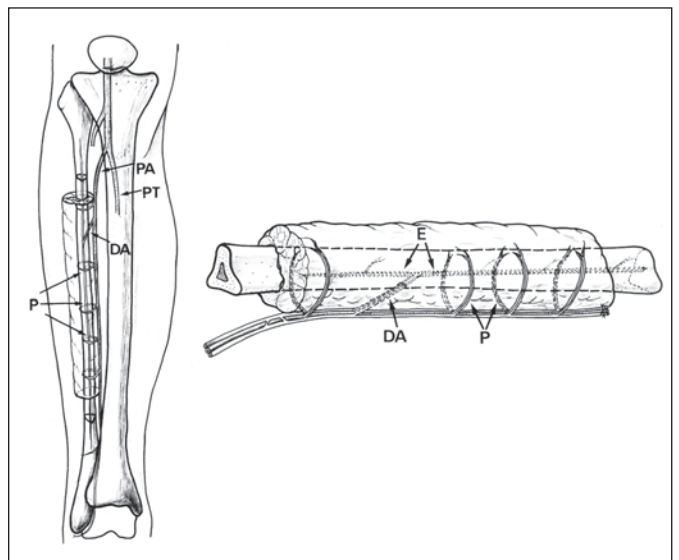


Figure 11 – Irrigation of the fibula according to Harii.⁽³⁶⁾ Representation of the fibular artery (PA), posterior tibial (PT), of the periosteal arteries (P), principal nutrient (DA), endosteal vessels (E). Reprinted with permission of the author.

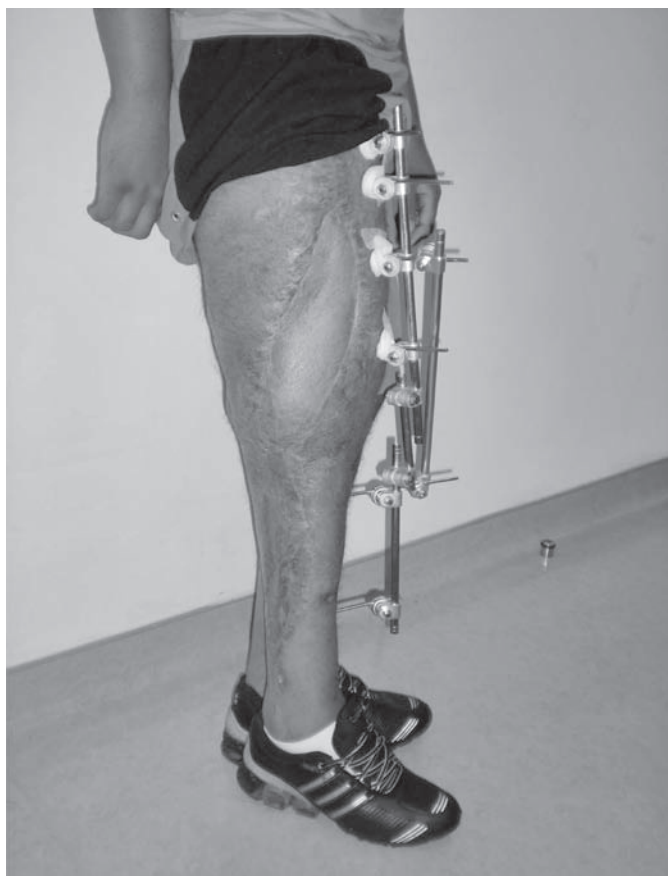

Figure 12 – Complete healing, good coverage and absence of local infection. Applying partial load with the external fixator.

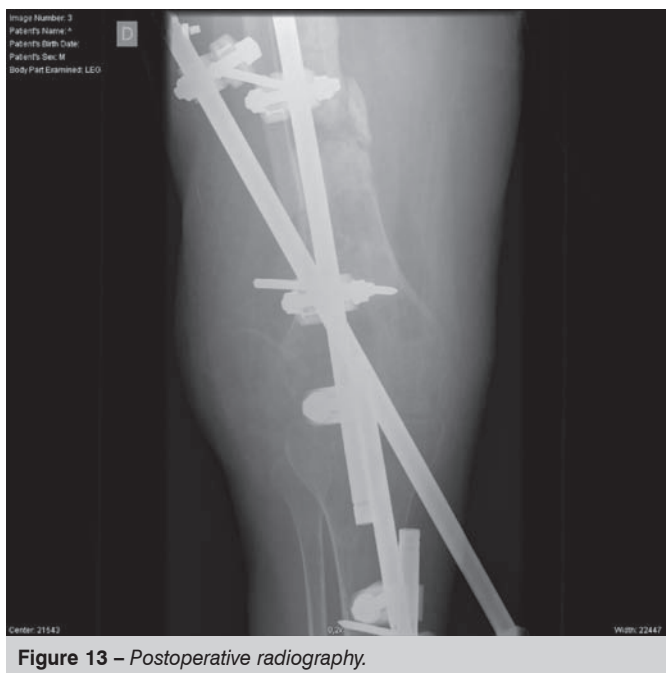

Figure 13 – Postoperative radiography.

DISCUSSION

Georgescu³⁷ described a microsurgical dissection flap concept, yet without vascular microsurgery. The new technique falls into this didactic category. Perfect understanding of the perforating anatomy and familiarization with microsurgical technique is certainly a prerequisite for its executor, yet its reproducibility at other centers and possibility of performance in institutions where costly microscope, forceps, microsurgical clips and fine threads are not available makes way for the treatment of infected osteomyelitis and pseudoarthrosis of the tibia and of the femur.

We were asked whether the vascularized bone graft could also be taken just in the perforating vessel without its communication with the segment of fibular vessels from where it originates, thus avoiding the ligation of an important leg vessel. In effect we do not believe that the perforating vessel contains direct nutritious branches to the bone or periosteum capable of irrigating it over a sufficient area. Actually we see the adjacent skin and the perforating vessel as a conduit that performs the nutrition and drainage of the fibular pedicle that emits the nutritious branches to the bone. Therefore the ligation and the raising of a segment of the fibular pedicle in this flap are essential.

Historically, Brazilian surgeons have been active and creative in the description of new flaps: Baudet et al.³⁸ dos Santos^{39,40}, Nassif et al.⁴¹ Masquelet and Rinaldi,⁴² Masquelet et al.⁴³ Recalde Rocha et al.^{44,45} Bertelli and Pagliei^{46,47}, Teng et al.^{48,49} and Ishida et al.⁵⁰ With this initial report the authors aim to hoist this category with the osteomiocutaneous flap that we call gastrocnemius-fibular skin flap. Its greatest damage is aesthetic, since its large skin island is taken from the leg, which may be a problem to female patients. Functionally, the damage is undetectable. The flap is safe and the rate of success for bone vascularization should be higher as it does not depend on micro-vascular anastomoses, which are hard to monitor when in the femur, due to depth, and subject to vascular thrombosis. Nevertheless, a subsequent comparative study with a large series of cases is necessary to demonstrate such efficacy. Its evident original application was as a rotation flap in the treatment of defective osteomyelitis. Another tissue that could be added in this actual flap is a portion of the soleus muscle or of the flexor hallucis longus at the fibula in the same fibular pedicle to obliterate any dead space. Moreover, its application is possible in the free form with anastomoses in the pedicle of the lateral sural and/or fibular artery. This would assist in "chimeric" reconstructions in a wide variety of body areas; including in reconstruction for head and neck surgery. It could also be applied as a functional muscular flap through microneuroraphy from the tibial branch to the lateral gastrocnemius muscle with motor branch of the receptor area, allowing simultaneous bone reconstruction of the humerus or of the forearm bones, functional muscle and cutaneous cover.

CONCLUSION

Due to its technical simplicity and reproducibility, we consider the gastrocnemius-fibular skin flap a promising alternative in the field of reconstructive surgery, and meriting further research for greater clinical experience.

REFERENCES

- Wood MB, Cooney WP. Vascularized bone segment transfers for management of chronic osteomyelitis. *Orthop Clin North Am.* 1984;15:461-72.
- Wood MB. Free vascularized bone transfers for nonunions, segmental gaps and following tumor resection. *Orthopedics.* 1986;9:810-6.
- De Boer HD, Wood MB. Bone changes in the vascularised fibular graft. *J Bone Joint Surg Br.* 1989;71:374-8.
- Zumiotti AV, Ferreira MC. Treatment of congenital pseudarthrosis of the tibia by microsurgical fibula transfer. *Microsurgery.* 1994;15:37-43.
- Mattar Junior R, Azze RJ, Rezende MR. Congenital Pseudarthrosis of the Forearm. In: Gupta A, Kay SPJ, Scheker LR, editors. *The growing hand - diagnosis and management of the upper extremity in children.* New York: Mosby; 2000. p.1035-40.
- Mattar Junior R, Azze RJ, Camargo OP, Oliveira NRB, Croci AT, Okane SY, Campos Filho R. Abordagem cirúrgica do tumor de células gigantes da extremidade distal do rádio. *Rev Hosp Clin Fac Med Sao Paulo.* 1994;49:95-9.
- Chang N, Mathes SJ. Comparison of the effect of bacterial inoculation in musculocutaneous and random-pattern flaps. *Plast Reconstr Surg.* 1982;70:1-9.
- Taylor GI, Miller GD, Ham FJ. **The free vascularised bone graft: a clinical extension of microvascular techniques.** *Plast Reconstr Surg.* 1975;55:533-44.
- Cariou JL. Dix ans de lambeaux cutanés. *Ann Chir Plast Esthet.* 1995;40:435-9.
- Chow SP, Chan KC, Tang SC, Billett DM. Reconstruction of the lateral tibial condyle by a pedicled vascularized fibular graft after en bloc resection of giant cell tumour. *Int Orthop.* 1986;10:239-43.
- Satoh K, Wong F, Shibui S, Suka T, Akizuki T. Effectiveness of the pedicled vascularized fibula graft to reconstruct tibial defects. *Europ J Plast Surg.* 1991;14:274-9.
- Molski M, Wielopolski A, Ozonек W. Distal femur reconstruction with vascularized fibular graft: indications and surgical technique. *Chir Narzadow Ruchu Ortop Pol.* 1998;63:347-52.
- Toh S, Tsubo K, Nishikawa S, Narita S, Kanno H, Harata S. Ipsilateral pedicle vascularized fibula grafts for reconstruction of tibial defects and non-unions. *J Reconstr Microsurg.* 2001;17:487-96.
- Zalavras CG, Femino D, Triche R, Zions L, Stevanovic M. Reconstruction of large skeletal defects due to osteomyelitis with the vascularized fibular graft in children. *J Bone Joint Surg Am.* 2007;89:2233-40.
- Ger R. The management of pretibial skin loss. *Surgery.* 1968;63:757.
- Ger R. The technique of muscle transposition in the operative treatment of traumatic and ulcerative lesions of the leg. *J Trauma.* 1971;11:502-10.
- Orticochea M. The musculo-cutaneous flap method: an immediate and heroic substitute for the method of delay. *Br J Plast Surg.* 1972;25:106-10.
- McCraw JB, Massey FM, Shanklin KD, Horton CE. Vaginal reconstruction with gracilis myocutaneous flaps. *Plast Reconstr Surg.* 1976;58:176-83.
- McCraw JB, Dibbel DG. Experimental definition of independent myocutaneous vascular territories. *Plast Reconstr Surg.* 1977;60:212-20.
- McCraw JB, Fishman JH, Sharzer LA. The versatile gastrocnemius myocutaneous flap. *Plast Reconstr Surg.* 1978;62:15-23.
- Morris A. A gastrocnemius musculocutaneous flap. *Br J Plast Surg.* 1978;31:216-9.
- Mathes SJ, Nahai F, editors. *Clinical atlas of muscle and musculocutaneous flaps.* St Louis: Mosby; 1979.
- Salibian AH, Menick FJ. Bipedicle gastrocnemius musculocutaneous flap for defects of the distal one-third of the leg. *Plast Reconstr Surg.* 1982;70:17-23.
- Cheng HH, Rong GW, Yin TC, Wang HY, Jiao YC. Coverage of wounds in the distal lower leg by advancement of an enlarged medial gastrocnemius skin flap. *Plast Reconstr Surg.* 1984;73:671-5.
- Koshima I, Soeda S. Inferior epigastric artery skin flaps without rectus abdominis muscle. *Br J Plast Surg.* 1989;42:645-8.
- Angrigiani C, Grilli D, Siebert J. Latissimus dorsi musculocutaneous flap without muscle. *Plast Reconstr Surg.* 1995;96:1608-14.
- Wei FC, Jain V, Celik N, Chen HC, Chuang DC, Lin CH. Have we found an ideal soft-tissue flap? An experience with 672 anterolateral thigh flaps. *Plast Reconstr Surg.* 2002;109:2219-26.
- Hallock GG. The medial sural gastrocnemius perforator local flap. *Ann Plast Surg.* 2004;53:501-5.
- Teo TC. Reconstrucción de la extremidad inferior con colgajos de perforantes locales. *Cir Plast Iberoamericana Madrid.* 2006;32:15-6.
- Cavadas PC, Landin L. Reconstruction of chronic Achilles tendon defects with posterior tibial perforator flap and soleus tendon graft: clinical series. *Plast Reconstr Surg.* 2006;117:266-71.
- Al-Qattan, MM. The Reverse sural artery fasciomusculocutaneous flap for small lower-limb defects: the use of the gastrocnemius muscle cuff as a plug for small bony defects following debridement of infected/necrotic bone. *Ann Plast Surg.* 2007;59:307-10.
- Koshima I, Yamamoto H, Hosoda M, Moriguchi T, Orita Y, Nagayama H. Free combined composite flaps using the lateral circumflex femoral system for repair of massive defects of head and neck regions: an introduction to the chimeric flap principle. *Plast Reconstr Surg.* 1993;9:411-20.
- Koshima I. A new classification of free combined or connected tissue transfers: introduction to the concept of bridge, siamese, chimeric, mosaic and chain-circle flaps. *Acta Med Okayama.* 2001;55:329-32.
- Torres LR, Teixeira WGJ, Setani EO, Teng HW, Zumiotti AV. Retalho cutâneo das artérias perforantes do músculo gastrocnêmio medial: estudo anatômico. *Acta Ortop Bras.* 2007;15:40-2.
- Yoshimura M, Shimada T, Hosokawa M. The vasculature of the peroneal tissue transfer. *Plast Reconstr Surg.* 1990;85:917-21.
- Harii K. *Microvascular Tissue transfer - fundamental techniques and clinical applications.* Tokyo: Igaku-Shoin; 1982.
- Georgescu AIV. Microsurgical non-microvascular flaps in upper limb reconstruction. In: Loda G, editor. *Proceedings of the III Congress of The World Society for Reconstructive Microsurgery - WSRM.* Buenos Aires: Medimond; 2005. p. 9-14.
- Baudet J, Guimberteau JC, Nascimento E. Successful clinical transfer of two free thoracodorsal axillary flaps. *Plast Reconstr Surg.* 1976;58:680-8.
- dos Santos LF. Retalho escapular: um novo retalho livre microcirúrgico. *Rev Bras Cir.* 1980;70:133-44.
- dos Santos LF. The vascular anatomy and dissection of the free scapular flap. *Plast Reconstr Surg.* 1984;73:599-604.
- Nassif TM, Vidal L, Bovet JL, Baudet J. The parascapular flap: a new cutaneous microsurgical free flap. *Plast Reconstr Surg.* 1982;69:591-600.
- Masquelet AC, Rinaldi S. Anatomical basis of the posterior brachial skin flap. *Anat Clin.* 1985;7:155-60.
- Masquelet AC, Rinaldi S, Mouchet A, Gilbert A. The posterior arm free flap. *Plast Reconstr Surg.* 1985;76:908-13.
- Recalde Rocha JF. Les branches cutanées de l'artère tibiale antérieure. *Communication de la Société Anatomique de Paris;* 1984.
- Recalde Rocha JF, Gilbert A, Masquelet A, Yousif NJ, Sanger JR, Matloub HS. The anterior tibial artery flap: anatomic study and clinical application. *Plast Reconstr Surg.* 1987;79:396-406.
- Bertelli JA, Pagliei A. Direct and reversed flow proximal phalangeal island flaps. *J Hand Surg Am.* 1994;19:671-80.
- Bertelli JA, Pagliei A. The neurocutaneous flap based on the dorsal branches of the ulnar artery and nerve: a new flap for extensive reconstruction of the hand. *Plast Reconstr Surg.* 1998;101:1537-43.
- Teng HW, Torres LR, Araújo MP, Gaiarsa GP, Sousa CT, Zumiotti AV. The superolateral leg flap: a new flap with a new pedicle (upper peroneal artery) - anatomical study and clinical applications. In: *8th International Course on Perforator Flaps.* Sao Paulo, September 5-7; 2004.
- Teng HW, Torres LR, Araújo MP, Gaiarsa GP, Sousa CT, Zumiotti AV. "The superolateral leg flap: a new flap with a new pedicle. anatomical study and clinical applications". In: Loda G, editor, *Proceedings of the III Congress of The World Society for Reconstructive Microsurgery - WSRM.* Buenos Aires: Medimond; 2005.
- Ishida LH, Munhoz AM, Montag E, Alves HR, Saito FL, Nakamoto HA, Ferreira MC. *Tensor fasciae latae perforator flap: minimizing donor-site morbidity in the treatment of trochanteric pressure sores.* *Plast Reconstr Surg.* 2005;116:1346-52.