

Brit. Heart J., 1967, 29, 282.

Cardiac Tamponade in Constrictive Pericarditis Following Cardiac Catheterization

FREDERIC JACKSON

From the Cardiovascular Department, Newcastle General Hospital, Newcastle upon Tyne 4

Fatal tamponade following cardiac catheterization in constrictive pericarditis is reported to demonstrate that this complication can occur, and because uncertainty on this point denied a patient surgical relief which would probably have been life-saving.

Case Report

A 62-year-old woman showed the signs of constrictive pericarditis. Increasing size of the abdomen for the past two or three years requiring paracentesis was her main complaint. She was in sinus rhythm, blood pressure 150/80 mm. Hg, and the electrocardiogram (Fig. 1A) showed normal P waves and flat or slightly upright T waves. On the radiograph the transverse diameter of the heart was within normal limits, there was a fine shell of calcification extending round both ventricles, and a right basal effusion (Fig. 2); on fluoroscopy the heart was almost pulseless.

Catheterization from a left arm vein produced characteristic pressure tracings in the right atrium and right ventricle; the cardiac output was calculated to be 4.1 litres per minute and the stroke volume 45 ml. The pulmonary artery could not be entered despite considerable manipulation of the catheter. Undue force was not exerted as far as is known, but the patient was turned onto both left and right sides while the catheter remained in the right ventricle, and in retrospect it is thought that this manoeuvre may have forced the catheter tip onto the anterior ventricular wall. At one stage the heart rate slowed to 50 a minute and the P waves on the electrocardiograph monitor were seen to be smaller. When questioned afterwards she admitted to feeling sick at about that time.

The patient returned to the ward in apparently good condition with the heart rate 84 a minute. During the next few hours she had no complaints, but routine observation showed a steadily rising pulse rate and falling blood pressure until, nine hours after catheterization, the heart rate was 140 a minute, the systolic pressure 70 mm. Hg, and the diastolic level not recordable. Pressor amines maintained a systolic pressure of 100-120 mm. Hg but without them the pressure fell, and a continuous infusion of 1-noradrenaline had to be given.

As might be expected a portable chest X ray showed no conclusive change in the size of the heart shadow. The electrocardiogram (Fig. 1B) showed a trifling elevation of the RT segment in leads II, III, and V₄ compared with the pre-catheter tracing, compatible with pericarditis.

The picture was that of cardiac tamponade and an immediate operation was considered. Two cardiac surgeons and four cardiologists saw the patient. In the face of a proven diagnosis of constrictive pericarditis tamponade was doubted, and myocardial weakness in a woman of 62 following a lengthy catheterization was

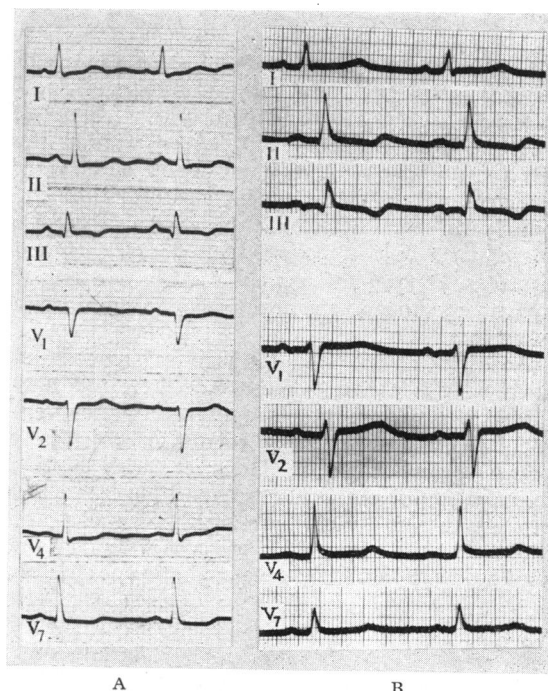


FIG. 1.—Electrocardiogram (A) before and (B) 24 hours after cardiac catheterization.

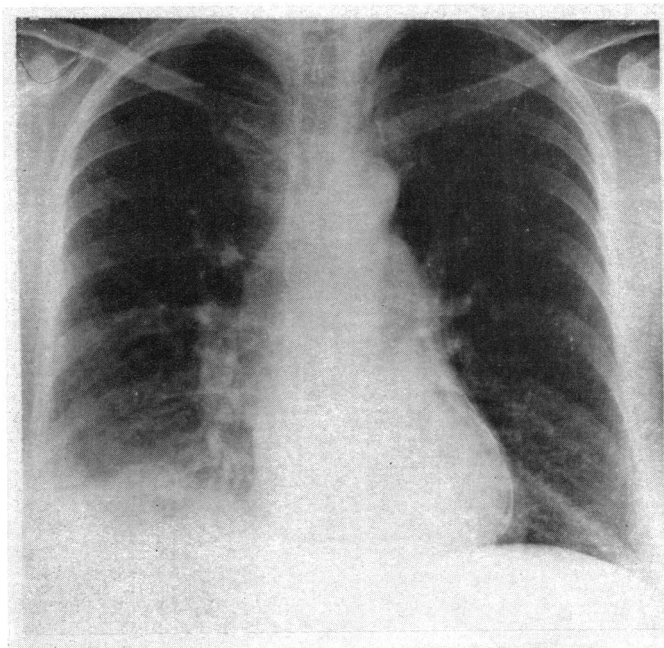


FIG. 2.—Chest radiograph showing a heart of normal size, a thin line of calcium round the ventricular border, and a right pleural effusion.

thought to be an alternative explanation of the peripheral circulatory failure. General anaesthesia and emergency surgery seemed too dangerous at that stage, and the response to pressor amines encouraged delay in the hope of further improvement. This hope proved illusory and the opportunity for surgery was lost. Her condition deteriorated and she died suddenly about 60 hours after the catheterization.

At necropsy the pericardium was thickened and extensively calcified, and was almost completely separated from both ventricles by a layer of fluid blood estimated to be between 100 and 150 ml. in volume. The epicardial surface of the right ventricle was extensively contused (Fig. 3). On the endocardium there were two small sub-intimal haemorrhages and an intimal tear 6 mm. long and 1 mm. deep. No track through the ventricular wall could be found, but blood from the floor of the tear had infiltrated widely between the muscle fibres through to the pericardial cavity.

Comment

It is clear that this patient died of cardiac tamponade. The presence of over 100 ml. of blood in a pericardial cavity with an indistensible wall is sufficient to prevent diastolic filling of the ventricles. Usually in constrictive pericarditis both layers of the pericardium are fused together, and often there is

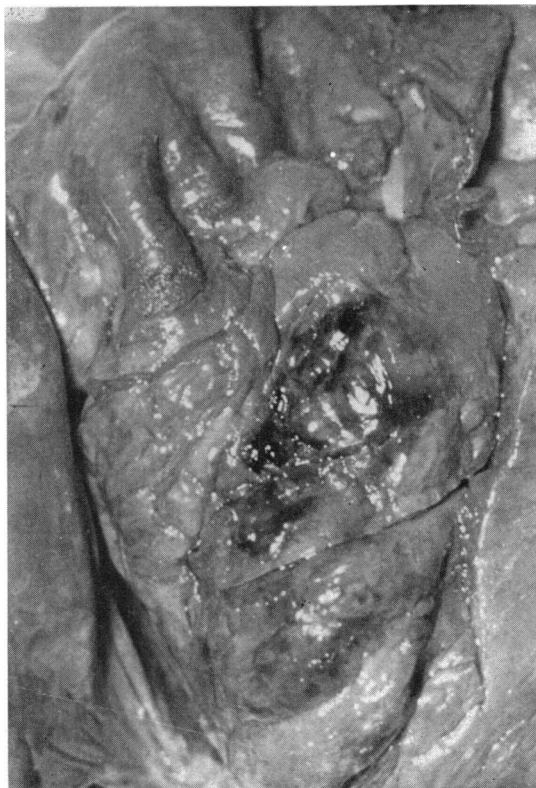


FIG. 3.—Pericardium reflected showing extensive contusion of the epicardial surface of the right ventricle.

considerable difficulty in separating the thickened fused pericardium from the myocardium to which it is attached by penetrating strands of fibrous tissue. In a minority of cases, however, the pericardium strips easily from the heart at operation. It was pointed out by Evans and Jackson (1952) that in these cases there was little or no inversion of the T waves in the electrocardiogram, and this prediction of light adherence of the pericardium to the heart muscle proved to be correct in 10 of their 11 cases showing this electrocardiographic feature. The electrocardiogram in this case also showed very

little alteration of the T waves. This fact combined with the development after catheterization of slight RT segment elevation consistent with acute pericarditis, ought, in retrospect, to have emboldened immediate operation.

I am indebted to Dr. B. E. Tomlinson for the necropsy data.

Reference

Evans, W., and Jackson, F. (1952). Constrictive pericarditis. *Brit. Heart J.*, **14**, 53.

Heart

Cardiac tamponade in constrictive pericarditis following cardiac catheterization.

F Jackson

Br Heart J 1967 29: 282-284
doi: 10.1136/hrt.29.2.282

Updated information and services can be found at:
<http://heart.bmj.com/content/29/2/282.citation>

These include:

Email alerting service

Receive free email alerts when new articles cite this article.
Sign up in the box at the top right corner of the online article.

Notes

To request permissions go to:
<http://group.bmj.com/group/rights-licensing/permissions>

To order reprints go to:
<http://journals.bmj.com/cgi/reprintform>

To subscribe to BMJ go to:
<http://group.bmj.com/subscribe/>