
Possible Role of Neurointerventional Techniques in the Diagnosis of Hemifacial Spasm

Kohsuke Yamashita, Masato Hojo, Shinichiro Okamoto, Choegon Kim, Shoji Nakatsu, and Hideaki Mishima

Summary: We used neurointerventional techniques to conduct a functional investigation of the artery responsible for hemifacial spasm in a 48-year-old woman. Insertion of a microcatheter into the posterior inferior cerebellar artery stopped the hemifacial spasm immediately and completely. The artery was verified intraoperatively as the vessel compressing the root exit zone of the facial nerve.

Index terms: Face, spasm; Interventional neuroradiology, provocative testing; Nerves, facial (VII)

Hemifacial spasm is a syndrome of unilateral facial nerve hyperactive dysfunction, characterized by the spontaneous onset of intermittent twitching in the orbicularis oculi muscle that gradually progresses in severity and frequency and spreads downward to include all the muscles of facial expression, including the platysma. Vascular compression of the facial nerve at the root exit zone, where the central myelin changes to peripheral myelin, is a widely accepted mechanism of hemifacial spasm (1–3), and microvascular decompression of the facial nerve at the root exit zone is the established method of treatment (1, 2).

Advancements in microcatheter technology and neurointerventional techniques have made it possible to access cerebral arteries of small caliber. Experience with therapeutic embolization (4, 5) has shown that manipulation of a microcatheter and guidewire within the cerebral arteries often cause positional and configurational changes, such as migration, unrolling, and straightening of the tortuous vessels. We reasoned that if these manipulations were applied to the causative vessels of hemifacial spasm, pulsatile compression at the root exit zone might be reversed and hence hemifacial spasm might be stopped. This case provided the opportunity to determine whether such a

neurointerventional technique could play a role in the treatment of hemifacial spasm.

Case Report

A 48-year-old woman was admitted for evaluation and treatment of frequent left-sided hemifacial spasm. She had no history of facial palsy. Seven years before admission, intermittent spasm had started around the left eye and gradually increased in severity and frequency. One year before admission, the spasm spread down the cheek and neck, and a clinical diagnosis of hemifacial spasm was made. The patient had been treated with carbamazepine, which did not successfully control the spasms.

On admission, mild left-sided facial weakness was noted, and grimacing was found to evoke a spasm. Computed tomography (CT) and magnetic resonance (MR) imaging failed to show any abnormalities in the brain stem or along the path of the left facial nerve.

After providing informed consent, the patient was given a local anesthetic, after which a 5F sheath was placed in the femoral artery by standard Seldinger technique. Diagnostic four-vessel angiograms were obtained, but no abnormalities were apparent. Since the left posterior inferior cerebellar artery (PICA) is near the root exit zone, which is located medial to the internal auditory meatus on the anteroposterior view and superoposterior to the external auditory canal on the lateral view (6), this artery was considered to be responsible for the symptoms. Systemic heparin was administered in a bolus injection of 100 U/kg. A 5F catheter was positioned in the left vertebral artery and through it a Fastracker-18 catheter and a Dasher-14 guidewire (Target Therapeutics, Fremont, Calif) were navigated into the PICA (Fig 1A and B). As the microcatheter was gradually advanced distally, the hemifacial spasm and facial weakness were evaluated. The spasms did not stop as long as the microcatheter stayed in the proximal segment of the PICA. But when the catheter reached the lateral medullary segment, the spasms stopped immediately and completely, and continued to be absent as long as the catheter remained in place.

Received September 25, 1995; accepted after revision April 8, 1996.

From the Department of Neurosurgery, Osaka Red Cross Hospital, 5-53 Fudegasaki-Cho, Tennoji-Ku, Osaka 543, Japan. Address reprint requests to Kohsuke Yamashita, MD.

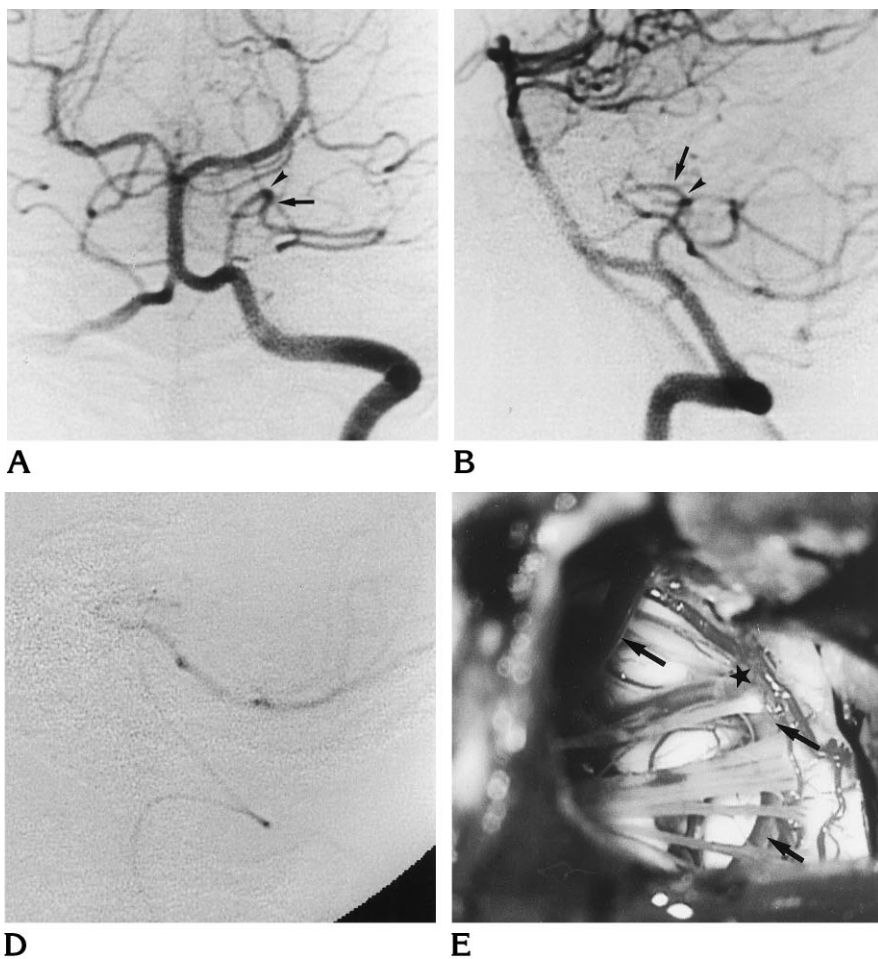
AJNR 18:287–290, Feb 1997 0195-6108/97/1802-0287 © American Society of Neuroradiology

Fig 1. A 48-year-old woman with frequent left-sided hemifacial spasm.

Left vertebral anteroposterior (A) and lateral (B) angiograms show the PICA as the possible causative artery of hemifacial spasm. Arrows indicate the eventual position of the tip of the microcatheter; arrowheads indicate the suspected position of the root exit zone of the facial nerve.

Superselective anteroposterior (C) and lateral (D) angiograms show the straightening and positional changes of the PICA, which still has a good distal run off.

Intraoperative photograph (E) shows the PICA (arrows) compressing the root exit zone (star) of the facial nerve from the brain stem.



Superselective angiography showed a straightening of the anterior medullary segment and a mild shift of the segment anteromedial to the original position (Fig 1C and D). The spasms recurred from the orbicularis oculi muscles 6 minutes after withdrawal of the catheter, and returned to their habitual state 15 minutes later. These phenomena were reproducible. Insertion of the microcatheter and/or guidewire into the basilar artery and the left superior cerebellar artery failed to stop the spasms.

The patient underwent microvascular decompression surgery (1, 2). During surgery, a loop of the anterior medullary segment of the PICA was found to compress the root exit zone of the facial nerve (Fig 1E), and was transposed with a piece of shredded Teflon felt. The patient had no spasms after surgery. Mild facial weakness, which had been present before surgery, has been improving.

Discussion

The definitive diagnosis of hemifacial spasm caused by neurovascular compression is difficult to make, since it stems from a variety of conditions, such as tumors, bone abnormalities,

and multiple sclerosis (7). Although clinical observation alone may distinguish hemifacial spasm from other abnormal facial movements (8) and electromyographic studies can provide pathognomonic signs of hemifacial spasm (9), neither can supply any information as to the pathogenesis of this disorder. The role of neuroradiologic studies in the diagnosis of hemifacial spasm is not only to exclude other causes but also to detect the vascular structures running adjacent to the root exit zone that might distort the facial nerve and compress the brain stem around the root exit zone (10–12). However, angiography may not be helpful in determining whether the observed intimate relationship between the nerve and the vessel is truly responsible for the spasms (13). In fact, the false-negative rate in MR studies has been reported to range from 0% to 68%, and the false-positive rate from 14% to 22% (10–12). The neurointerventional techniques described above

allowed a functional investigation of the suspected arteries and successfully provided information that the artery was indeed responsible for the hemifacial spasm in this patient.

It was surprising that the spasms stopped so abruptly after simple insertion of the microcatheter into the lateral medullary segment of the PICA. Probably, as indicated on selective angiograms, a little change in the position and configuration of the artery transposed the compressing loop away from the root exit zone. Another possibility is that the pulsatile action of the artery against the root exit zone might have been reduced during catheterization of the small-caliber artery. Although elimination of such pulsatile stress was suspected in a patient who had a giant aneurysm (14), such might not be the case in this patient, as the hemifacial spasm did not stop until the catheter passed the anterior medullary segment, and it did not recur immediately after the catheter was withdrawn. The possibility of transient ischemia of the facial nucleus and/or nerve, which may stop abnormal excitation and conduction of the facial nerve and thus hemifacial spasm, should also be considered, but this seems rather unlikely in this patient, because there was no aggravation of facial weakness or occlusive catheterization in the PICA during the procedure.

Catheterization of small arteries may carry an inherent risk to the vessels, such as vascular perforation and vasospasm (15). In one study, vascular perforations reportedly occurred in 1% of more than 1200 endovascular procedures to treat vascular disorders involving the central nervous system (16). Perforation of normal vessels seems to be a rare event, occurring in approximately 0.5% of procedures (16). Dissection may also occur; one dissection in 482 patients with cerebral arteriovenous malformations has been reported to be related to the use of intracerebral guidewires (17). Increased experience and careful manipulation are required to avoid such complications (15).

Although most cases of hemifacial spasm may be improved or cured by microvascular decompressive surgery (1, 2), a substantial number of patients have not been helped by the surgery, simply because there are no compressing vessels around the root exit zone of the facial nerve (18, 19). In that the present functional investigation seemed to simulate the microvascular decompression; this may also be used to predict the efficacy of decompressive

surgery and to eliminate poor surgical candidates.

The techniques described here may be useful for making a definitive diagnosis of other neurovascular compression syndromes, such as trigeminal neuralgia, glossopharyngeal neuralgia, and essential hypertension (2, 20), and, more important, may lead to the inclusion of hemifacial spasm and other neurovascular compression syndromes (2, 20) as candidates for endovascular treatment if methods are developed to keep the vessels transposed.

References

1. Jannetta PJ, Abbasy M, Maroon JC, Ramos FM, Albin MS. Etiology and definitive microsurgical treatment of hemifacial spasm: operative techniques and results in 47 patients. *J Neurosurg* 1977; 47:321-328
2. Jannetta PJ. Observations on the etiology of trigeminal neuralgia, hemifacial spasm, acoustic nerve dysfunction and glossopharyngeal neuralgia: definitive microsurgical treatment and results in 117 patients. *Neurochirurgia* 1977;20:145-154
3. Ruby JR, Jannetta PJ. Hemifacial spasm: ultrastructural changes in the facial nerve induced by neurovascular compression. *Surg Neurol* 1975;4:369-370
4. Taki W, Nishi S, Yamashita K, et al. Selection and combination of various endovascular techniques in the treatment of giant aneurysms. *J Neurosurg* 1992;77:37-42
5. Yamashita K, Taki W, Nishi S, et al. Transvenous embolization of dural carotidocavernous fistulae: technical considerations. *Neuroradiology* 1993;35:475-479
6. Okamura T, Aoki H, Tanai K, Abe T, Oh M. Roentgenographic positions of the cranial nerve root (V, VII-XI) proximal zones with reference to microvascular decompression. *Neurol Med Chir (Tokyo)* 1983;23:776-782
7. Digre K, Corbett JJ. Hemifacial spasm: differential diagnosis, mechanism, and treatment. *Adv Neurol* 1988;49:151-176
8. Blair RL, Berry H. Spontaneous facial movement. *J Otolaryngol* 1981;10:459-462
9. Hjorth RJ, Willison RG. The electromyogram in facial myokymia and hemifacial spasm. *J Neurol Sci* 1973;20:117-126
10. Tash R, DeMerritt J, Sze G, Leslie D. Hemifacial spasm: MR imaging features. *AJNR Am J Neuroradiol* 1991;12:839-842
11. Bernardi B, Zimmermann RA, Savino PJ, Adler C. Magnetic resonance tomographic angiography in the investigation of hemifacial spasm. *Neuroradiology* 1993;35:606-611
12. Hosoya T, Watanabe N, Yamaguchi K, Saito S, Nakai O. Three-dimensional-MRI of neurovascular compression in patients with hemifacial spasm. *Neuroradiology* 1995;37:350-352
13. Sunderland S. Neurovascular relationships and anomalies at the base of the brain. *J Neurol Neurosurg Psychiatry* 1948;11:243-247
14. Moore AP. Postural fluctuation of hemifacial spasm. *J Neurosurg* 1984;60:190-191

15. Berenstein A, Lasjaunias P. *Surgical Neuroangiography*. New York, NY: Springer-Verlag; 1992;4:252-266
16. Halbach VV, Higashida RT, Dowd CF, Barnwell SL, Hieshima GB. Management of vascular perforations that occur during neurointerventional procedures. *AJNR Am J Neuroradiol* 1991;12:319-327
17. Berenstein A, Lasjaunias P. *Surgical Neuroangiography*. New York, NY: Springer-Verlag; 1992;4:186-187
18. Adams CBT, Chir M. Microvascular compression: an alternative view and hypothesis. *J Neurosurg* 1989;57:1-12
19. Aoki N, Nagao T. Resolution of hemifacial spasm after posterior fossa exploration without vascular decompression. *Neurosurgery* 1986;18:478-479
20. Jannetta PJ. Neurovascular compression in cranial nerve and systemic disease. *Ann Surg* 1980;192:518-525