



ACADEMIC
PRESS

Available online at www.sciencedirect.com

SCIENCE @ DIRECT®

NeuroImage

NeuroImage 19 (2003) 1417–1426

www.elsevier.com/locate/ynimg

Functional anatomy of pitch memory—an fMRI study with sparse temporal sampling

Nadine Gaab,^a Christian Gaser,^b Tino Zaehle,^a Lutz Jancke,^c and Gottfried Schlaug^{a,*}

^a Department of Neurology, Music and Neuroimaging Laboratory, Beth Israel Deaconess Medical Center and Harvard Medical School, Boston, MA 02215 USA

^b Department of Psychiatry, University of Jena, Germany

^c Department of Neuropsychology, University of Zurich, Switzerland

Received 9 September 2002; revised 11 February 2003; accepted 15 April 2003

Abstract

Auditory functional magnetic resonance imaging tasks are challenging since the MR scanner noise can interfere with the auditory stimulation. To avoid this interference a sparse temporal sampling method with a long repetition time (TR = 17 s) was used to explore the functional anatomy of pitch memory. Eighteen right-handed subjects listened to a sequence of sine-wave tones (4.6 s total duration) and were asked to make a decision (depending on a visual prompt) whether the last or second to last tone was the same or different as the first tone. An alternating button press condition served as a control. Sets of 24 axial slices were acquired with a variable delay time (between 0 and 6 s) between the end of the auditory stimulation and the MR acquisition. Individual imaging time points were combined into three clusters (0–2, 3–4, and 5–6 s after the end of the auditory stimulation) for the analysis. The analysis showed a dynamic activation pattern over time which involved the superior temporal gyrus, supramarginal gyrus, posterior dorsolateral frontal regions, superior parietal regions, and dorsolateral cerebellar regions bilaterally as well as the left inferior frontal gyrus. By regressing the performance score in the pitch memory task with task-related MR signal changes, the supramarginal gyrus (left > right) and the dorsolateral cerebellum (lobules V and VI, left > right) were significantly correlated with good task performance. The SMG and the dorsolateral cerebellum may play a critical role in short-term storage of pitch information and the continuous pitch discrimination necessary for performing this pitch memory task.

© 2003 Elsevier Science (USA). All rights reserved.

Keywords: Pitch memory; Music; Temporal lobe; Supramarginal gyrus; Cerebellum; Performance

Introduction

Auditory tasks in the MR environment have been regarded as challenging because of the noise created by the gradient coil switches. This “scanner noise” can (1) interfere with the auditory stimulation (Bandettini et al., 1998; Shah et al., 1999, 2000; Hall et al., 2000), (2) lead to masking of the auditory cortical response depending on the frequency of the MR acquisition, (3) lead to activation of the auditory cortex itself depending on the effective repetition time (TR) for MR acquisitions (Bandettini et al., 1998; Scheich et al.,

1997; Ulmer et al., 1998), and (4) lead to differences in the attentional demands if frequency and intensity of the MR scanner noise differ between studies. A few imaging designs have been proposed to overcome this interference (Edmister et al., 1999; Hall et al., 1999, 2000). Hall et al. (1999) compared continuous scanning with a sparse temporal sampling method, using an effective TR of 14 s, and revealed a greater MR signal change for acquisitions with a long TR. In addition, it was found that recording scanner noise and playing it back to the subject could lead to a signal change of up to 1.5% in primary and secondary auditory cortex. Hall et al. 1999, 2000 showed further that the activation reached its maximum at 4–5 s after stimulus onset and decayed after an additional 5–8 s. Others have shown a decrease in the spatial spread and lower *z* scores of the activated auditory regions dependent upon the duration of

* Corresponding author. Department of Neurology, Beth Israel Deaconess Medical Center and Harvard Medical School, 330 Brookline Avenue, Boston, MA 02215. Fax: +1-617-632-8920.

E-mail address: gschlaug@bidmc.harvard.edu (G. Schlaug).

the MR scanner noise (Shah et al., 1999). Belin et al. (1999) used an effective TR of 10 s and varied the delay between a short auditory stimulus and the MR acquisition. Primary auditory cortex showed a maximum response about 3 s after stimulus onset and had a duration of 3 s.

We used a variation of Hall's (1999) and Belin's (1999) methods of sparse temporal sampling to examine MR signal changes related to a pitch memory task. The functional anatomy of pitch memory is still poorly explored and there are discrepancies comparing some of the experimental animal studies and the few neuroimaging studies in humans that have examined pitch memory. Deficits in tonal retention and auditory memory were seen after bilateral ablations of the superior temporal cortex in monkeys, whereas unilateral cortex lesions resulted only in minor auditory memory deficits (Stepien et al., 1960; Colombo et al., 1990, 1996) but usually no impairments in frequency discriminations. There is also a growing body of literature that extra-temporal brain regions within the dorsolateral and ventrolateral prefrontal cortex may play a role during the retention of an auditory stimulus (Gottlieb et al., 1989; Bodner et al., 1996; Romanski and Goldman-Rakic, 2002).

Human functional imaging studies assessing pitch processing or auditory short-term working memory have not revealed a consistent pattern of activation across these studies. In a positron emission tomography study, Zatorre et al. (1994) showed blood flow increases bilaterally in the superior temporal cortex (more on the right than on the left) when subjects listened to melodies. When subjects were asked to perform a pitch memory task in contrast to a passive listening task, a right inferior frontal region became activated, indicating an involvement of frontal regions in auditory working memory. Griffiths et al. (1999) found a more extensive right lateralized network including cerebellum, posterior temporal, and inferior frontal regions when subjects were asked to make a "same/different" judgement while comparing pitch sequences of 6 tones. More left hemispheric activation in the precuneus, superior temporal gyrus, and superior frontal gyrus were found in a study by Platel et al. (1997) in which subjects were asked to detect pitch changes in familiar tunes. Celsis and colleagues (1999) found rightward asymmetry of the primary and secondary auditory cortex for tones, but left more than right posterior temporal lobe activation when subjects were presented with deviances in the tonal sequences. It is most likely that frontal/prefrontal as well as parietal lobe regions play a common role in auditory working memory and in the online maintenance of tonal patterns (Chao and Knight, 1996; Celsis et al., 1999); recent experimental evidence even suggested that the prefrontal cortex has cells that respond to nonspatial auditory cues (Romanski and Goldman-Rakic, 2002). The role of the temporal lobe in auditory memory remains unclear. Several studies assessing the effects of lesions on melodic discriminations and pitch judgements found impairments mainly after right but not left temporal lesions or temporal lobectomies (Milner, 1962;

Zatorre, 1985; Zatorre and Halpern, 1993; Samson and Zatorre, 1988).

We undertook the current study to explore the functional anatomy of pitch memory in a group of subjects with minimal or no musical experience using a variation of a sparse temporal sampling technique to allow subjects to listen to the auditory stimulation without any scanner interference in order to examine the time course of cortical activation due to a pitch memory task.

Materials and methods

Subjects

Eighteen normal right-handed volunteers (age range: 18–40; 9 female and 9 male), participated in this study after giving written informed consent. Subjects were unselected for musical training; most of them had received some musical theory classes, usually as part of their elementary, high school, or college education, but none were professional musicians and none of our subjects actively played any instruments. They had no history of any neurological or hearing impairments. All subjects were strongly right-handed according to a standard handedness questionnaire (Annett, 1970). This study was approved by the institutional review board of the Beth Israel Deaconess Medical Center.

Experimental tasks

All subjects performed a pitch memory task which was contrasted with a motor control task. During the pitch memory task, subjects were instructed to listen to a sequence of individual sine-wave tones (either 6 or 7 tones) with a duration of 4.6 s for each sequence. Each tone was 300 ms long with an attack and decay rate of 50 ms and a pause of 300 ms separated tones from each other. Our target tones corresponded to the frequencies of semitones of the Western musical scale (based on A = 440 Hz). Target tones had a frequency range from 330 (E4) to 622 (D#5). Semitones within that range were used as target tones. The absolute frequency difference between the first and the last or second to last tone was between 41 and 64 Hz, if the tones were different. Microtones were used only as distractor tones. The frequency range from the lowest to the highest tone in all tone sequences was not more than 108 Hz. In the pitch memory task subjects had to compare either the last or the second to last tone (depending on the visual prompt "second to last" or "very last") to the first tone and we asked subjects to make a decision as to whether these tones were the same or different (Fig. 1). We chose to vary the total number of tones (6 or 7 tones per sequence) and the comparison to be made (second last tone with first tone or last tone with first tone) across sequences to reduce the possible inattention to intervening tones. The sequence length was kept constant for the 6- and 7-tone sequences by introducing a short pause

prior to the first tone for the 6-tone sequences. No analysis was planned to compare the 6-tone with the 7-tone conditions. Subjects were asked to keep their eyes open and fixate a cross in the middle of the screen that was only interrupted for the short visual prompt. The motor control task was a rest condition with eye fixation. Subjects were asked to press a button depending on a short visual prompt (“right” or “left”; Fig. 1). All subjects were made familiar with the pitch memory task for approximately 10 min prior to the actual MR session using samples of the stimulation material. All subjects performed above chance in the pre-functional magnetic resonance imaging (fMRI) training phase. The behavioral performance during the fMRI session was calculated as correct responses (in percentage). All subjects performed above chance in the pitch memory task. The mean of correct responses was 66.8% (SD 11.1; range: 54–100%).

fMRI scanning

fMRI was performed on a Siemens Vision (Siemens, Erlangen, Germany) 1.5 Tesla whole-body MRI scanner, equipped with echo planar imaging (EPI) capabilities using the standard head coil for radio-frequency transmission and signal reception. A gradient-echo EPI sequence with an effective repetition time (TR) of 17 s, an echo time of 50 ms, and a matrix of 64×64 was used. Using a midsagittal scout image, a total of 24 axial slices $4 \times 4 \times 6$ mm voxel size—parallel to the bicommissural plane—were acquired over 2.75 s each 17 s. Initiation of the first set of 24 slices was triggered by a TTL pulse from a PC and all subsequent MR acquisitions were synchronized with stimulus presentation. A high-resolution T1-weighted scan (1 mm³ voxel size) was acquired for each subject for anatomical co-registration.

We used a variation of a sparse temporal sampling technique acquiring one set of 24 axial slices every 17 s to circumvent the scanner noise interference. Although the TR was kept constant at 17 s, the MR acquisition actually varied with regard to the auditory stimulation by moving the auditory stimulation frame within the 17-s time frame, which varied the delay between the end of the stimulation and the onset of the next MR acquisition (see Fig. 1). There was a minimum delay of 0 s and a maximum delay of 6 s between the end of the auditory stimulation and the onset of the MR acquisition (see Fig. 1). We will refer to these imaging time points (ITP) as ITP0 through ITP6. Similarly, there was a minimum delay of 4 s and a maximum delay of 10 s between the end of the MR acquisition and the onset of the next auditory stimulation. We acquired four sets of axial images per acquisition time point during each run in a randomized order; we had two runs per subject. Thus, each acquisition time point was sampled eight times.

The initial exploratory analysis of each imaging time point indicated that the pattern of brain activation varied depending on the delay between MR acquisition and the end

of the auditory stimulation frame. However, the change between neighboring imaging time points was minimal, which led us to combine imaging time points into three combined clusters of time points to demonstrate the main activation changes over time; furthermore, this allowed us to have a higher number of acquisitions per combined time point for statistical reasons. MR acquisitions obtained at ITP 0–2 were combined into one block, MR acquisitions obtained at ITP 3–4 were combined into the second block, and MR acquisitions obtained at ITP 5–6 were combined into the third block.

fMRI data analysis

fMRI data were analyzed using the SPM99 software package (Institute of Neurology, London, UK). Each set of axial images for each subject was realigned to the first image, co-registered with the corresponding T1-weighted data set, spatially normalized to the SPM99 template using a nonlinear spatial transformation with $7 \times 8 \times 7$ basis functions, and smoothed with an isotropic Gaussian kernel (8 mm full-width at half-maximum). Condition and subject effects were estimated using a general linear model (Friston et al., 1995). The effect of global differences in scan intensity was removed by scaling each scan in proportion to its global intensity. We contrasted the pitch memory task with the motor control task for these three clusters of ITP and applied a threshold of $P < 0.05$, corrected for multiple comparisons (Worsley et al., 1996). In addition, we also contrasted these imaging clusters with each other using the contrast images to determine significant changes in the time course of the activation. Low-frequency drifts were removed using a temporal high-pass filter with a cutoff of 200 s. Because of the sparse temporal sampling design there is no temporal auto correlation between the images. Therefore, we did not convolve our data with the hemodynamic response function (HRF) and we did not apply a low-pass filter.

In order to describe the time course of activation, regions of interests were drawn on a spatially standardized, group-averaged anatomical dataset and superimposed on the SPM_T images representing the group contrasts “pitch memory vs motor control” for each single imaging time point. Anatomical regions were drawn on each hemisphere and included the first transverse gyrus of Heschl representing primary auditory cortex, the planum temporale (for definition see Steinmetz et al., 1991, and Schlaug et al., 1995) representing auditory association cortex, the supra-marginal gyrus, and lobules V and VI of the cerebellum (Schmahmann et al., 1999).

The relationship between performance (percentage correct responses) and task-related activations was examined by weighting the parameter estimates with the performance data of each subject which were normalized to the group mean performance.

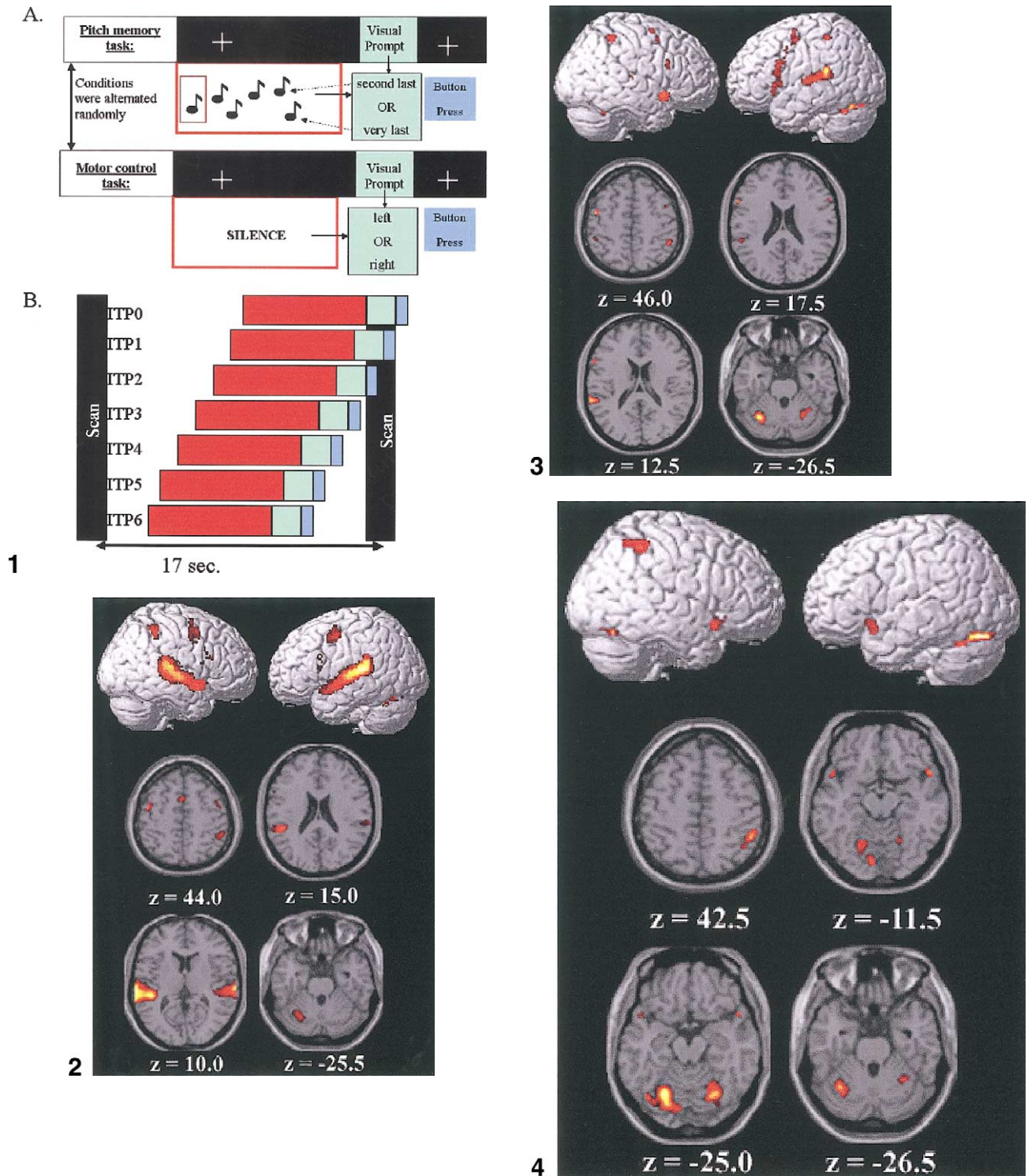


Fig. 1. This schematic drawing demonstrates the task design (A) and MR image acquisition procedure (B) using a modification of a sparse temporal sampling technique (ITP, imaging time point).

Fig. 2. Brain activation pattern ($P < 0.05$, corrected) during the initial ITP 0–2 (0–2 s after the end of the auditory stimulation).

Fig. 3. Brain activation pattern ($P < 0.05$, corrected) during the intermediate ITP 3–4 (3–4 s after the end of the auditory stimulation).

Fig. 4. Brain activation pattern ($P < 0.05$, corrected) during the late ITP 5–6 (5–6 s after the end of the auditory stimulation).

Results

Time course of activation pattern: comparing pitch memory with control condition for three combined imaging time points

The brain activation pattern during combined ITP 0–2 (0–2 s after end of stimulation) is dominated by strong and extensive—left more than right—activation of the superior temporal gyrus bilaterally including Heschl's gyrus (HG) and auditory association cortex; anterior, lateral, and posterior to HG including the planum temporale (PT); and the supramarginal gyrus (Fig. 2). Activations outside the perisylvian region included a left posterior dorsolateral frontal ($-43.0, -7.2, 43.2$) and right posterior dorsolateral frontal region ($43.2, 2.5, 41.9$), a superior parietal region on the right side ($44.9, -44.0, 43.1$), a left > right pre-SMA region ($-0.8, 4.4, 45.5$), and lobules V and VI of the cerebellum on the left side ($-23.6, -67.3, -24.9$) (Fig. 2).

The brain activation pattern at combined ITP 3 and 4 (3–4 s after end of stimulation) showed prominent activation of the left lateral superior temporal plane and of the right planum polare, but no longer any significant activation of HG. There was still strong activation of cerebellar lobules V and VI bilaterally (left more than right). There was some scattered activation involving a posterior dorsolateral frontal region (left hemisphere) and a superior parietal region (both hemispheres) which were seen in the initial time points as well. There was also activation of the left inferior frontal operculum, including Broca's region ($-51.8, 6.4, 24.5$), and an adjacent activation in the left lateral mid-dorsal prefrontal cortex ($-41.2, -7.2, 44.9$) (Fig. 3).

The brain activation pattern at combined ITP 5 and 6 (5–6 s after end of stimulation) showed prominent activation of cerebellar lobules V and VI on both sides, the anterior superior parietal region on the right, and the planum polare region bilaterally (Fig. 4).

Contrasting early with late activations

Contrasting the initial ITPs (0–2 s after the end of auditory stimulation) with the intermediate (3–4 s) and the late ITPs (5–6 s) revealed extended significant ($P < 0.05$, corrected) activations of the superior temporal gyrus bilaterally for both contrasts (Fig. 5). In addition, activation of the anterior frontomesial region ($-4.3, 4.4, 47.3$) was seen bilaterally in the contrast “initial time points vs late time points.” The differences in the superior temporal gyrus are consistent with results from our ROI analysis (Fig. 6), which showed higher t values for HG and PT in the first time point cluster and then a continuous decrease at later ITPs reaching negative values after ITP 4 (Fig. 6). Mean regional t values were overall greater for the left hemisphere for the first three imaging time points (Fig. 6). The planum temporale region, representing auditory association cortex, showed a slight rise in mean t values on the left, reaching

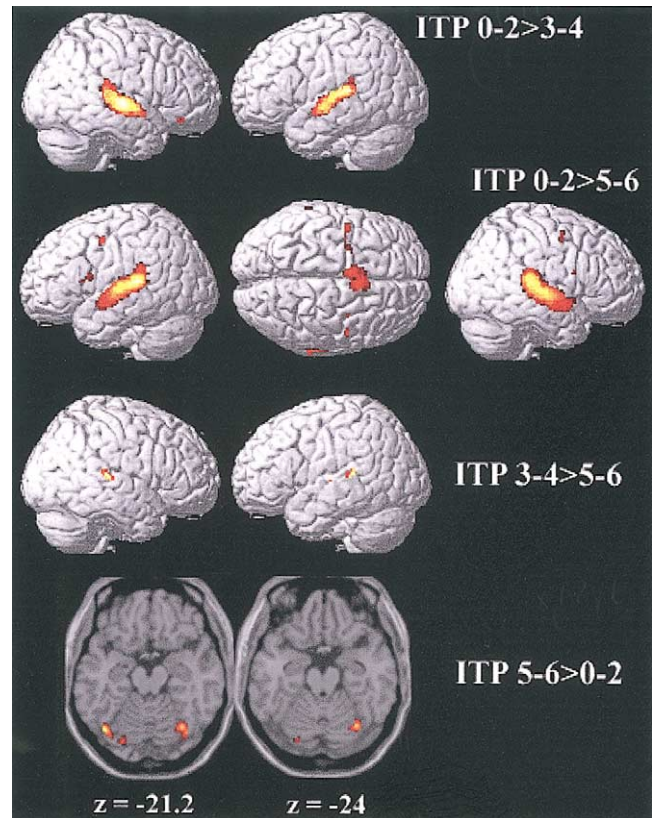


Fig. 5. Brain activation pattern ($P < 0.05$, corrected) comparing initial ITP with intermediate (ITP 0–2 > 3–4) and late ITP (ITP 0–2 > 5–6). Brain activation pattern comparing intermediate ITP with late (ITP 3–4 > 5–6) and late ITP with initial ITP (ITP 5–6 > 0–2). All other comparisons did not show any significant activations.

the highest t values at the second imaging time point for both hemispheres; again higher t values were seen for the left hemisphere region. Mean regional t values in the PT region decreased gradually, reaching negative t values at time point 4 for the right hemisphere and time point 5 for the left hemisphere. The regional analysis for the supramarginal gyrus (SMG) showed the highest mean t values at the second ITP (1 s after the end of the auditory stimulation) and a rapid decline over time in the right SMG while the left SMG showed positive t values up to ITP 6, indicating a longer involvement of the left supramarginal gyrus in the pitch memory task.

By contrasting the intermediate ITPs (3–4 s) with the late ITPs (5–6 s) a small cluster of significant voxels were seen in the right ($55.5, -31.5, 7.1$) and left superior temporal gyrus region ($-57.4, -36.8, 6.8$) (Fig. 5). The contrast of the intermediate time points (3–4 s) with the earlier ones (0–2 s) revealed no significant differences.

By contrasting the last time points (5–6 s) with the initial time points (0–2 s) bilateral activation of the dorsolateral cerebellum was seen (Fig. 5), further supporting the strong activation of the cerebellum throughout the task. Similar results were seen in the regional analysis (Fig. 6). The

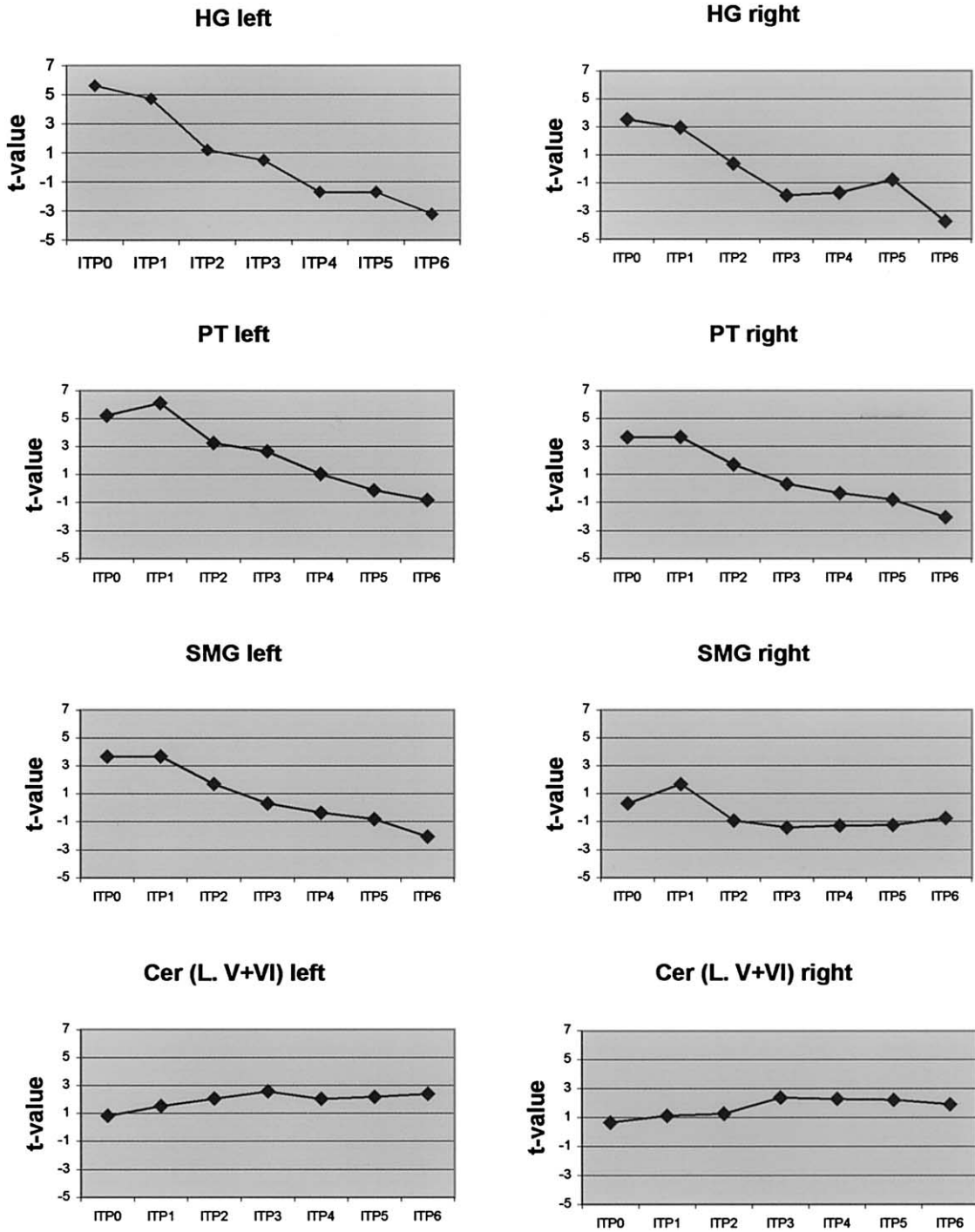


Fig. 6. Regional group mean *t* values for all ITP for selected regions of interest (HG, Heschl's gyrus; PT, planum temporale; SMG, supramarginal gyrus; Cer, cerebellum; L. V + VI, lobules V and VI).

contrast of the last ITP (5–6 s) with the intermediate ITP (3–4 s) showed no significant differences.

Correlating performance with brain activation pattern

By weighting the parameter estimates with the mean corrected performance data for each subject, activity in the

SMG emerged as positively correlated with higher accuracy in the pitch memory task (Figs. 7A and B). The left SMG (–44.8, 42.1, 20.3) was much more dominantly activated than the right SMG (55.5, –34.3, 13.6). The supramarginal gyrus on the left also stayed active during the intermediate ITP (3–4 s after the end of the auditory stimulation). At the last ITP (5–6 s after the end of the auditory stimulation),

there was prominent activation of the left cerebellum including the posterior part of lobule VI ($-16.6, -72.9, 23.9$; Figs. 7C and D).

A negative correlation between activity and performance in the pitch memory task was found in the right temporal–occipital junction ($53.7, -51.8, 0.5$) for the initial ITP and in the left superior parietal lobe ($-28.9, -57.6, 44.1$) for the last two ITPs (Figs. 7E and F).

Discussion

In refining a sparse temporal sampling technique as originally developed by Hall et al. (1999), we were able to discern the functional anatomy and the time course of cerebral activations of a pitch memory task. The use of a sparse temporal sampling technique enabled us to overcome some of the interference between scanner noise and auditory tasks (Hall et al., 1999; Belin et al., 1999; Edmister et al., 1999; Shah et al., 2000). The majority of previous studies using a sparse temporal sampling technique only examined responses in primary and secondary auditory areas, most typically using short stimuli such as single tones. Belin et al. (1999) assessed the time course of primary auditory cortex activation with an event-related method. Maximal signal change occurred 3 s after stimulus onset and lasted for 3 s. The earliest imaging data in our study were obtained at 4.6 s after the start of the auditory stimulation. No MR acquisitions were obtained before 4.6 s to minimize the possible interference between scanner noise and auditory task. This makes it likely that the maximal signal change in primary auditory cortex in our study could be earlier than 4.6 s after stimulus onset. It is also possible that the time course of the cerebrovascular response in primary and secondary auditory cortex to a single tone differs from that to a sequence of tones. Robson et al. (1998) showed that the fMRI response to sequences of 6 s and longer are linear but that shorter stimuli produce signals that are larger than might be expected from the results of the longer stimuli. The responses in HG in this study are in partial agreement with Hall et al. (2000), who reported maximal activity change in response to recorded MR scanner noise to occur between 4 and 5 s after stimulus onset and to decay 5–8 s later. The decay of significant activations occurred slightly faster in our study compared to Hall et al., (2000).

The planum temporale—a representative anatomical region for secondary auditory cortex—showed a maximal signal change between 5 and 6 s after the beginning of auditory stimulation and the signal decayed 3–4 s later. Similar activations of the PT have been seen in other studies using either single tones or musical sequences (Binder et al., 1996; Ohnishi et al., 2001). The SMG showed the highest t values between 5 and 6 s after the beginning of the auditory stimulation in both hemispheres. However, there was stronger activation on the left compared to the right SMG and the decay was different for the right and left hemispheres.

While activity in the right SMG decayed relatively fast, the left SMG remained active for a longer period of time.

The strong leftward activation pattern is somewhat different from other studies showing a more rightward activation pattern in pitch memory tasks (Zatorre et al., 1994; Griffiths et al., 1999). It is not very likely that our subjects were able to verbally encode the target tone, since none of them possessed absolute pitch and it would be very difficult for a subject without absolute pitch to develop a verbal labeling scheme during the course of this task. In similar experiments, Siegel (1974) and Zatorre and Beckett (1989) found that subjects without absolute pitch most likely use a sensory encoding strategy. This sensory encoding strategy may be visual, kinesthetic, or auditory. It is also unlikely that the visual prompt shown at the end of the auditory stimulation could have caused the left-sided activation, since the inherent cerebrovascular delay in response to a visually presented verbal command would have caused a left temporal lobe activation at our last ITP, but this was not seen. A more convincing explanation for the left more than right activation pattern is the possibility that a top-down processing stream could influence the activation pattern; a higher order brain region (e.g., SMG) could specify the area of processing at earlier ITPs during the perceptual phase of this task. This explanation has some support in our data, since the SMG on the left was more strongly activated than the SMG on the right and seemed to play a key role in those individuals performing well in the pitch memory task. The SMG could serve as a top-down modulator causing stronger involvement of the left than the right temporal regions. Several neurophysiological and lesion studies have revealed the importance of the SMG—particularly on the left—for short-term auditory–verbal memory processes and phonological storage (e.g., Salmon et al., 1996; Sakurai et al., 1998; Vallar et al., 1997; Caplan et al., 1995; Paulesu et al., 1993; Clarke et al., 2000). Our study and those of others indicate that the SMG may be involved in short-term memory processes for musical information as well. Celsis et al. (1999) showed left SMG activation in a task requiring memory judgements between tones of different pitch height or spectral content.

The dominant dorsal cerebellar activation in our pitch memory task was surprising, although in agreement with reports indicating that the cerebellum has non-motor functions (Bower, 1997; Jueptner et al., 1997; Parsons and Fox, 1997; Desmond et al., 1998; Penhune et al., 1998; Satoh et al., 2001; Schmahmann and Sherman, 1998). Several studies have shown now an involvement of the cerebellum in auditory tasks such as the planning of speech production (Silveri et al., 1998), auditory verbal memory function (Grasby et al., 1993), tone recognition tasks (Holcomb et al., 1998), and musical tasks such as musical tempo and duration discrimination (Parsons, 2001). Furthermore, patients with degeneration of the cerebellum were found to be impaired in pitch discrimination tasks (Parsons, 2001). In our study, the cerebellum may be involved in the ongoing ac-

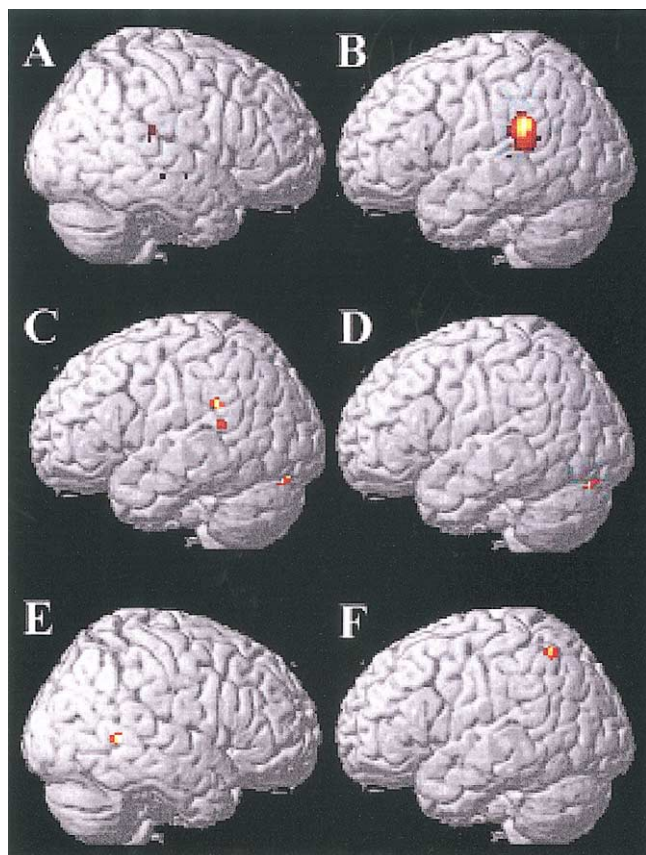


Fig. 7. Correlating performance and brain activity changes showed significant positive correlations in the supramarginal gyrus (mainly on the left) and the left dorsolateral cerebellum ($P < 0.05$, corrected). (A and B) The activation pattern for ITP 0–2; (C) ITP 3–4; (D) ITP 5–6. (E) Negative correlations for ITP 0–2; (F) negative correlations for ITP 5–6. No significant negative correlations were seen for ITP 3–4.

tivity of pitch discrimination while subjects perform the pitch memory task. This could explain the cerebellar activation in the initial time points as well as throughout the task (see Fig. 5). Furthermore, the strong correlation between activation and accuracy underlines the importance of the cerebellum for this pitch memory task.

The superior parietal lobule was activated more prominently during the initial ITPs. The superior parietal lobule may actually serve two functions in this task. Converging evidence from several studies has shown that the superior parietal lobule is an important nodal point for integrating multimodal sensory information and for providing guidance to motor operations through intense reciprocal connections with the premotor cortex (Friedman and Goldman-Rakic, 1994; Bushara et al., 1999). Thus, requiring a motor response to an auditory cue could involve the superior parietal lobule. Neuropsychological and functional imaging evidence also suggests that the parietal lobe, in particular the right parietal lobe, is a key part of a larger network involved in auditory spatial and attentional functions (Clarke et al., 2000; Bushara et al., 1999; Griffiths et al., 2000; Weeks et al., 1999). Satoh et al., (2001) compared a harmony listen-

ing condition with a more specific alto-part-listening condition and found bilateral increases in the superior parietal lobules among other changes using positron emission tomography. Their interpretation that the parietal lobules are involved in auditory selective attention and the analysis of pitch information on a mental score is supported by other work showing that selective auditory attention led to significant activation of the superior parietal lobe (Pugh et al., 1996). Of interest is that better performance in the pitch memory task was associated with less activation of the left superior parietal lobule and of a region in the temporo-occipital junction. This might indicate that subjects with an overall better task performance might rely more on short-term auditory memory storage (involving the SMG) rather than on multisensory integration of information (involving the superior parietal lobule).

The initial and intermediate ITP in this pitch memory task also showed strong activations of the inferior frontal gyrus on both sides. Although neuroimaging studies have shown the involvement of the inferior frontal lobes in auditory processing and auditory working memory (Chao and Knight, 1996; Griffiths, 2001; Zatorre et al., 1994), the role that these regions play in auditory processing remains largely unclear. Several physiological studies of the frontal lobe in nonhuman primates have focused on auditory spatial processing in the dorsolateral prefrontal cortex, although the ventrolateral prefrontal cortex might also play a role, since it receives afferents from auditory cortex, as has been shown in monkeys. Romanski and Goldman-Rakic (2002) recorded neuronal responses to auditory cues in awake monkeys from ventrolateral prefrontal cortex. The localization of auditory responses in the ventral prefrontal cortex in the macaque brain is suggestive of some functional similarity between this region and the inferior frontal gyrus of the human brain (including Broca's area), where mnemonic, semantic, and syntactic auditory processes have led to brain activation. Griffiths (2001) suggested that the features of individual notes are analyzed in the pathway up to and including the auditory cortices, while higher-order auditory patterns and information are analyzed by distributed networks in the temporal lobe and frontal lobes distinct from the auditory cortices. Zatorre and Belin (2001) suggested that processing of pitch patterns, such as occurs in melodies, requires higher-order cortical areas, and interactions with the frontal cortex. The latter are likely related to tonal working memory functions that are necessary for the online maintenance and encoding of tonal patterns.

In summary, our study showed that a distributed and dynamic brain network subserves pitch memory functions. The pitch memory task used in our experiment relied more on left than on right hemisphere regions. The supramarginal gyrus and the dorsolateral cerebellum seem to play a critical role, possibly as a short-term pitch information storage site (SMG) and as a pitch discrimination processor (cerebellum). Both processes are of critical importance for the successful performance in this pitch memory task.

Acknowledgments

This study was supported by a grant from the International Foundation for Music Research. Dr. Schlaug is partly supported by a Clinical Scientist Development Award from the Doris Duke Foundation. This research was also partly supported by a grant from the National Science Foundation. Further support from the Rubenstein Foundation and the Dana Foundation is acknowledged. Nadine Gaab is supported in part by a fellowship from the German Academic Exchange Program (DAAD) and by the German Merit Foundation (Deutsche Studienstiftung).

References

- Annett, M., 1970. A classification of hand preference by association analysis. *Br. J. Psychol.* 61, 303–321.
- Bandettini, P.A., Jesmanowicz, A., Van Kylen, J., Birn, R.M., Hyde, J.S., 1998. Functional MRI of brain activation induced by scanner acoustic noise. *Magn. Reson. Med.* 39, 410–416.
- Belin, P., Zatorre, R.J., Hoge, R., Evans, A.C., Pike, B., 1999. Event-related fMRI of the auditory cortex. *NeuroImage* 10, 417–429.
- Binder, J.R., Frost, J.A., Hammeke, T.A., Rao, S.M., Cox, R.W., 1996. Function of the left planum temporale in auditory and linguistic processing. *Brain* 119, 1239–1247.
- Bodner, M., Kroger, J., Fuster, J.M., 1996. Auditory memory cells in dorsolateral prefrontal cortex. *Neuroreport* 7, 1905–1908.
- Bower, J.M., 1997. In the cerebellum sensory for motor's sake, or motor for sensory's sake: the view from the whiskers of a rat? in: de Zeeuw, C.I., Strata, P., Voogd, J. (Eds.), *Progress in Brain Research*. Elsevier, New York, pp. 463–496.
- Bushara, K.O., Weeks, R.A., Ishii, K., Tian, B., Rauschecker, J.P., Hallett, M., 1999. Modality-specific frontal and parietal areas for auditory and visual spatial localization in humans. *Nature Neurosci.* 2, 759–766.
- Caplan, D., Gow, D., Makris, N., 1995. Analysis of lesions by MRI in stroke patients with acoustic-phonetic processing deficits. *Neurology* 45, 293–298.
- Celsis, P., Boulanouar, K., Doyon, B., Ranjeva, J.P., Berry, I., Nespoulous, J.L., Chollet, F., 1999. Differential fMRI responses in the left posterior superior temporal gyrus and left supramarginal gyrus to habituation and change detection in syllables and tones. *NeuroImage* 9, 135–144.
- Chao, L.L., Knight, R.T., 1996. Prefrontal and posterior cortical activation during auditory working memory. *Cogn. Brain Res.* 4, 27–37.
- Clarke, S., Bellmann, A., Meuli, R.A., Assal, G., Steck, A.J., 2000. Auditory agnosia and auditory spatial deficits following left hemispheric lesions: evidence for distinct processing pathways. *Neuropsychologia* 38, 797–807.
- Colombo, M.D., D'Amato, M.R., Rodman, H.R., Gross, C.G., 1990. Auditory association cortex impair auditory short-term memory in monkeys. *Science* 247, 336–338.
- Colombo, M., Rodman, H.R., Gross, C.G., 1996. The effects of superior temporal lesions on the processing and retention of auditory information in monkeys (*Cebus apella*). *J. Neurosci.* 16, 4501–4517.
- Desmond, J.E., Gabrieli, J.D., Glover, G.H., 1998. Dissociation of frontal and cerebellar activity in a cognitive task: evidence for a distinction between selection and search. *NeuroImage* 7, 368–376.
- Edmister, W.B., Talavage, T.M., Ledden, P.J., Weisskopf, R.M., 1999. Improved auditory cortex imaging using clustered volume acquisitions. *Hum. Brain Mapp.* 7, 89–97.
- Friedman, H.R., Goldman-Rakic, P.S., 1994. Coactivation of prefrontal cortex and inferior parietal cortex in working memory tasks revealed by 2DG functional mapping in the rhesus monkey. *J. Neurosci.* 14, 2775–2788.
- Friston, K.J., Holmes, A., Worsley, K.J., Poline, J.B., Frith, C.D., Frackowiak, R.S.J., 1995. Statistical parametric maps in functional imaging: a general linear approach. *Hum. Brain Mapp.* 2, 189–210.
- Gottlieb, Y., Vaadia, E., Abeles, M., 1989. Single unit activity in the auditory cortex of a monkey performing a short term memory task. *Exp. Brain Res.* 74, 139–148.
- Grasby, P.M., Frith, C.D., Friston, K.J., Bench, C., Frackowiak, R.S., Dolan, R.J., 1993. Functional mapping of brain areas implicated in auditory-verbal memory function. *Brain* 116, 1–20.
- Griffiths, T.D., 2001. The neural processing of complex sounds. *Ann. NY Acad. Sci.* 930, 179–192.
- Griffiths, T.D., Johnsrude, I., Dean, J.L., Green, G.G.R., 1999. A common neural substrate for the analysis of pitch and duration pattern in segmented sound? *Neuroreport* 10, 3825–3830.
- Griffiths, T.D., Green, G.G., Rees, A., Rees, G., 2000. Human brain areas involved in the analysis of auditory movement. *Hum. Brain Mapp.* 9, 72–80.
- Hall, D.A., Haggard, M.P., Akeroyd, M.A., Palmer, A.R., Summerfield, A.Q., Elliott, M.P., Gurney, E.M., Bowtell, R.W., 1999. "Sparse" temporal sampling in auditory fMRI. *Hum. Brain Mapp.* 7, 213–223.
- Hall, D.A., Summerfield, A.Q., Goncalves, M.S., Foster, J.R., Palmer, A.R., Bowtell, R.W., 2000. Time-course of the auditory BOLD response to scanner noise. *Magn. Res. Med.* 43, 601–606.
- Holcomb, H.H., Medoff, D.R., Caudill, P.J., Zhao, Z., Lahti, A.C., Danahs, R.F., Tamminga, C.A., 1998. Cerebral blood flow relationships associated with a difficult tone recognition task in trained normal volunteers. *Cereb. Cortex* 8, 534–542.
- Jueptner, M., Ottinger, S., Fellows, S.J., Adamschewski, J., Flerich, L., Muller, S.P., Diener, H.C., Thilmann, A.F., Weiler, C., 1997. The relevance of sensory input for the cerebellar control of movements. *NeuroImage* 5, 41–48.
- Milner, B., 1962. Laterality effects in audition, in: Mountcastle, V.B. (Ed.), *Interhemispheric Relations and Cerebral Dominance*. Johns Hopkins, Baltimore, pp. 177–195.
- Ohnishi, T., Matsuda, H., Asada, T., Aruga, M., Hirakata, M., Nishikawa, M., Kato, A., Imabayashi, E., 2001. Functional anatomy of musical perception in musicians. *Cereb. Cortex* 11, 754–760.
- Parsons, L.M., 2001. Exploring the functional neuroanatomy of music performance, perception, and comprehension. *Ann. NY Acad. Sci.* 930, 211–231.
- Parsons, L.M., Fox, P.T., 1997. Sensory and cognitive functions, in: Schmahmann, J.D. (Ed.), *The Cerebellum and Cognition*. Academic Press, New York, pp. 255–272.
- Paulesu, E., Frith, C.D., Frackowiak, R.S.J., 1993. The neural correlates of verbal component of working memory. *Nature* 362, 342–345.
- Penhune, V.B., Zatorre, R.J., Evans, A.C., 1998. Cerebellar contributions to motor timing: a PET study of auditory and visual rhythm reproduction. *J. Cogn. Neurosci.* 10, 752–765.
- Platel, H., Price, C., Baron, J.-C., Wise, R., Lambert, J., Frackowiak, R.S.J., Lechevalier, B., Eustache, F., 1997. The structural components of music perception a functional anatomical study. *Brain* 120, 229–243.
- Pugh, K.R., Offwitz, B.A., Shaywitz, S.E., Fulbright, R.K., Byrd, D., Skudlarski, P., Shankweiler, D.P., Katz, L., Constable, R.T., Fletcher, J., Lacadie, C., Marchione, K., Gore, J.C., 1996. Auditory selective attention: an fMRI investigation. *NeuroImage* 4, 159–173.
- Robson, M.D., Dorosz, J.L., Gore, J.C., 1998. Measurements of the temporal fMRI response of the human auditory cortex to trains of tones. *NeuroImage* 7, 185–198.
- Romanski, L.M., Goldman-Rakic, P.S., 2002. An auditory domain in primate prefrontal cortex. *Nature Neurosci.* 5, 15–16.
- Sakurai, Y., Takeuchi, S., Kojima, E., Yazawa, I., Murayama, S., Kaga, K., Momose, T., Nakase, H., Sakuta, M., Kanazawa, I., 1998. Mechanism of short-term memory and repetition in conduction aphasia and related cognitive disorders. A neuropsychological, audiological and neuroimaging study. *J. Neurol. Sci.* 154, 182–193.

- Salmon, E., Van der Linden, M., Colette, F., Delfiore, G., Maquet, P., Degueldre, C., Luxen, A., Franck, G., 1996. Regional brain activity during working memory tasks. *Brain* 119, 1617–1625.
- Samson, S., Zatorre, R.J., 1988. Melodic and harmonic discrimination following unilateral cerebral excision. *Brain Cogn.* 7, 348–360.
- Satoh, M., Takeda, K., Nagata, K., Hatazawa, J., Kuzuhara, S., 2001. Activated brain regions in musicians during an ensemble: a PET study. *Cogn. Brain Res.* 12, 101–108.
- Scheich, H., Baumgart, F., Gaschler, B., Tempelmann, C., Tegeler, C., Stiller, D., Heinze, H.J., 1997. Masking of acoustic stimuli produces fMRI activation in a particular human auditory cortex field, in: Abstracts of the Twentieth Midwinter Research Meeting of the Association for Research in Otolaryngology, p. 27.
- Schlaug, G., Jancke, L., Huang, Y., Steinmetz, H., 1995. In vivo evidence of structural brain asymmetry in musicians. *Science* 267, 699–701.
- Schmahmann, J.D., Sherman, J.C., 1998. The cerebellar cognitive affective syndrome. *Brain* 121, 561–79.
- Schmahmann, J.D., Doyon, J., McDonald, D., Homes, C., Lavoie, K., Hurwitz, A.S., Kabani, N., Toga, A., Evans, A., Petrides, M., 1999. Three-dimensional MRI atlas of the human cerebellum in proportional stereotaxic space. *NeuroImage* 10, 233–260.
- Shah, N.J., Jancke, L., Grosse-Ruyken, M.L., Muller-Gartner, H.W., 1999. Influence of acoustic masking noise in fMRI of the auditory cortex during phonetic discrimination. *J. Magn. Reson. Imaging* 9, 19–25.
- Shah, N.J., Steinhoff, S., Mirzazade, S., Zafiris, O., Grosse-Ruyken, M.L., Jancke, L., Zilles, K., 2000. The effect of sequence repeat time on auditory cortex stimulation during phonetic discrimination. *NeuroImage* 12, 100–108.
- Siegel, J.A., 1974. Sensory and verbal coding strategies in subjects with absolute pitch. *J. Exp. Psychol.* 103, 37–44.
- Silveri, M.C., Di Betta, A.M., Filippini, V., Leggio, M.G., Molinari, M., 1998. Verbal short-term store-rehearsal system and the cerebellum. Evidence from a patient with a right cerebellar lesion. *Brain* 121, 2175–2187.
- Steinmetz, H., Volkman, J., Jancke, L., Freund, H.J., 1991. Anatomical left–right asymmetry of language-related temporal cortex is different in left- and right-handers. *Ann. Neurol.* 29, 315–319.
- Stepien, L.S., Cordeau, J.P., Rasmussen, T., 1960. The effect of temporal lobe and hippocampal lesions on auditory and visual recent memory in monkeys. *Brain* 83, 470–489.
- Ulmer, J.L., Biswal, B.B., Yetkin, F.Z., Mark, L.P., Mathews, V.P., Probst, R.W., Estkowski, L.D., McAuliffe, T.L., Haughton, V.M., Daniels, D.L., 1998. Cortical activation response to acoustic echo planar scanner noise. *J. Comput. Assist. Tomogr.* 22, 111–119.
- Vallar, G., DiBetta, A.M., Silveri, M.C., 1997. The phonological short-term store-rehearsal system: patterns of impairment and neural correlates. *Neuropsychologia* 35, 795–812.
- Weeks, R.A., Aziz-Sultan, A., Bushara, K.O., Tian, B., Wessinger, C.M., Dang, N., Rauschecker, J.P., Hallett, M., 1999. A PET study of human auditory spatial processing. *Neurosci. Lett.* 262, 155–158.
- Worsley, K.J., Marrett, S., Neelin, P., Vandal, A.C., Friston, K.J., Evans, A.C., 1996. A unified statistical approach for determining significant voxels in images of cerebral activation. *Hum. Brain Mapp.* 4, 58–73.
- Zatorre, R.J., 1985. Discrimination and recognition of tonal melodies after unilateral cerebral excisions. *Neuropsychologia* 23, 31–41.
- Zatorre, R.J., Beckett, C., 1989. Multiple coding strategies in the retention of musical tones by possessors of absolute pitch. *Mem. Cogn.* 17, 582–589.
- Zatorre, R.J., Halpern, A.R., 1993. Effect of unilateral temporal-lobe excision on perception and imagery of songs. *Neuropsychologia* 31, 221–232.
- Zatorre, R.J., Evans, A.C., Meyer, E., 1994. Neural mechanism underlying melodic perception and memory for pitch. *J. Neurosci.* 14, 1908–1919.
- Zatorre, R.J., Belin, P., 2001. Spectral and temporal processing in human auditory cortex. *Cereb. Cortex* 11, 946–953.