

ACTAS Derma-Sifiliográficas

Full English text available at
www.elsevier.es/ad



ORIGINAL ARTICLE

Mohs Micrographic Surgery for the Treatment of Basal Cell Carcinoma

G. Galimberti,* A. Pontón Montaña, D. Ferrario, A. Kowalczuk, R. Galimberti

Servicio de Dermatología, Escuela de Medicina, Hospital Italiano de Buenos Aires, Buenos Aires, Argentina

Manuscript received January 19, 2010; accepted for publication June 16, 2010

KEYWORDS

Mohs micrographic surgery;
Basal cell carcinoma;
Treatment;
Skin cancer

Abstract

Introduction: Basal cell carcinoma accounts for 75% of all nonmelanoma skin cancer. Although various treatment modalities are available, the most frequently used option is surgical excision. Here, we evaluate the efficacy of Mohs micrographic surgery for the treatment of basal cell carcinoma.

Material and methods: A retrospective review of cases of basal cell carcinoma treated with Mohs micrographic surgery between October 2003 and June 2009 was performed using patient records from Hospital Italiano in Buenos Aires, Argentina.

Results: A total of 2412 basal cell carcinomas treated with Mohs micrographic surgery were identified; 50.5% were in women and 49.5% in men. The mean age of the patients was 70.7 years (range, 8-100 years). The histologic type of the tumor was solid in 65.3% of cases and in 89% of cases the tumor was located on the head or neck. Ten percent of the tumors were recurrent following previous treatment. A mean of 1.74 Mohs stages were used, with a mean of 3.81 sections. The mean size of the initial defect was 0.86 cm² and the mean final defect was 1.88 cm². The ratio of initial tumor size to final defect was estimated at 1.02. Over a mean follow-up of 32 months, there were 9 cases of tumor recurrence (0.37%).

Conclusions: In our experience, Mohs micrographic surgery is effective for the treatment of high-risk basal cell carcinoma.

© 2010 Elsevier España, S.L. and AEDV. All rights reserved.

PALABRAS CLAVE

Cirugía micrográfica de Mohs;
Carcinoma basocelular;

Cirugía micrográfica de Mohs en el tratamiento de carcinoma basocelular

Resumen

Introducción: El carcinoma basocelular constituye el 75% de todos los carcinomas cutáneos no melanoma. Para su tratamiento existen múltiples modalidades siendo la escisión quirúrgica la más frecuentemente usada. Se plantea evaluar la eficacia de la cirugía micrográfica de Mohs en el tratamiento del carcinoma basocelular.

*Corresponding author.

E-mail address: gaston.galimberti@gmail.com (G. Galimberti).

Tratamiento;
Cáncer de piel

Materiales y métodos: Revisión retrospectiva en la base de datos del Hospital Italiano de Buenos Aires de los casos de carcinoma basocelular tratados con cirugía micrográfica de Mohs entre octubre del 2003 y junio del 2009.

Resultados: Se encontraron 2.412 casos (85,3%); el 50,5% se presentaron en mujeres y el 49,5% en hombres. La media de edad fue de 70,7 años (rango entre 8 y 100 años). El 65,3% de los tumores eran del tipo histológico sólido y la ubicación más frecuente fue la cabeza y el cuello (89%). El 10% de los carcinomas basocelulares eran recidivas de tratamientos previos. El número medio de estadios fue de 1,74 con una media de 3,81 cortes. La media del defecto inicial fue de 0,86 cm² y del defecto final de 1,88 cm². La relación defecto final/defecto inicial se estimó en 1,02 cm². Nueve tumores presentaron recidiva (0,37%) con una media de seguimiento de 32 meses.

Conclusión: Consideramos que la cirugía micrográfica de Mohs es eficaz en el tratamiento del carcinoma basocelular de alto riesgo.

© 2010 Elsevier España, S.L. y AEDV. Todos los derechos reservados.

Introduction

Skin cancer accounts for a third of all malignant neoplasms in humans. Basal cell carcinoma is the most common form, accounting for 75% of all nonmelanoma skin cancers,¹ and the incidence of this type of skin cancer has increased by 20% in recent decades.

There are a range of therapeutic approaches for basal cell carcinoma, with radiotherapy, cryosurgery, photodynamic therapy, and surgical excision being the most widely used.² In view of the clinical characteristics (histologic subtype, poorly defined borders, tendency for recurrence) or site, some of these tumors are classified as high risk and are candidates for Mohs micrographic surgery (MMS).

MMS was first described in 1941 by Dr Frederic E Mohs, who coined the term “chemosurgery.”³ The original technique consisted of applying zinc chloride paste to the tumor in vivo; after 24 hours the tissue adhering to the paste was removed and sectioned. The sections were precisely mapped to determine where they each came from and their margins were then assessed histologically. In the event that residual tumor was detected, the procedure was repeated using the map to define the exact location until tissue that was free of tumor cells was obtained. Currently, an improved technique is used. It is performed under local anesthetic, with the tumor being fixed by freezing before excision. The piece is then mapped under a microscope according to the Mohs method.

In the United States, MMS is indicated in the treatment of approximately 30% of basal cell carcinomas.⁴ The technique is widely practiced throughout the world and its effectiveness in the treatment of nonmelanoma skin cancer has been demonstrated. In Argentina, there is no registry of the number of patients in whom this technique is used. Basal cell carcinoma is, however, a common presenting complaint in Argentinian dermatology departments. The aim of this study was to evaluate the efficacy of treatment of basal cell carcinoma by MMS in a retrospective analysis of all cases treated in the Dermatology Department of Hospital Italiano in Buenos Aires, Argentina in the last 5 years and to compare these data with those found in the literature.

Materials and Methods

A retrospective review was undertaken of all patients with basal cell carcinoma who underwent MMS in the Dermatology Department of Hospital Italiano, Buenos Aires, Argentina, between October 2003 and June 2009. The following inclusion criteria were considered for excision of the basal cell carcinoma: high-risk facial site (nose, eyelids, between the eyebrows, lips, outer ear, region in front of and behind the ear); size greater than 2 cm; presence of irregular and poorly defined borders; infiltrative histology (cicatrical, sclerosing, infiltrative micronodular, or metatypic); presence of perineural infiltration; recurrences; and basal cell carcinomas in immunosuppressed patients.

For the analysis, the age of the patient, tumor site, histologic type, prior treatments, size of the initial and final defect, difference between initial and final defect, number of stages and sections, type of closure, follow-up time, and recurrence were taken into account.

Surgical Technique

Local anesthetic was applied with 2% lidocaine and diluted epinephrine (Klein formula). Whenever possible, curettage of the lesion was performed or the visible lesion was excised; this process is known as cytoreduction. The tumor was excised with a margin of 1 to 2 mm, with a superficial cut at 45° and a cut parallel to the skin surface at greater depth. Subsequently, the piece was mapped, sectioned, and the reference margins of the piece were stained green, black, and yellow with dyes supplied by DELASCO. The tissue was placed on a mount and embedded in optimal-cutting-temperature compound. It was then frozen and cut into 5 µm sections with a HM 550 Carl Zeiss cryostat before staining with hematoxylin and eosin. A dermatopathologist and the Mohs surgeon examined all tissue margins. In cases where residual tumor was observed, the aforementioned procedure was repeated only in the positive area until no residual tumor could be detected. In most cases, repair of the defect was undertaken during the same surgical procedure. All patients entered a follow-up protocol with

visits after 1 month, 6 months, and then every year after surgery. Recurrence was defined as histologic confirmation of the presence of basal cell carcinoma within the borders of the healed wound.

Results

In 1957 patients, we identified 2412 basal cell carcinomas that were treated by MMS between October 2003 and June 2009. Men accounted for 49.5% and women for 50.5% of the sample. The mean age was 70.7 years (range, 8-100 years). In most cases, the lesion was a primary tumor (Table 1).

The most common histologic type was a solid tumor, followed by sclerosing tumors. In 20.2% of cases, the type corresponded to a more aggressive and less common tumor such as micronodular or adnexal basal cell carcinoma, keratoacanthoma transformed into basal cell carcinoma, or a nevus sebaceous of Jadassohn transformed into basal cell carcinoma in 1 patient aged 8 years (Table 1).

Eighty-nine percent of the tumors were located on the face and neck; the remaining 11% were located on the chest, arms, and legs (Table 2).

The mean initial defect size was 0.86 cm² (range, 0.02-19.4 cm²) and 5.4% measured more than 2 cm². The mean size of the final defect was 1.88 cm² (range, 0.06-42.37 cm²) and the mean difference between the initial and final defect size was 1.02 cm². The mean number of stages was 1.74 (range, 1-10) with a mean of 3.81 sections (range, 1-43) (Table 3).

Defect repair was performed by primary closure in 42% of the cases. For the rest, flaps, grafts, and second-intention healing were used. Support was required from other specialties in 1.7% of the patients (Figure).

The mean follow-up time was 32 months (range, 1-64 months) and the recurrence rate was 0.37% (9 cases) over a 5-year period.

Table 1 Characteristics of the Sample Studied

Total BCC	2412
Women	969
Men	988
Age	70.7 y
Primary	2206
Recurrences	206
Local excision	146
Cryosurgery	36
Electrocurettage	9
5-fluoracyl	6
Imiquimod	5
PDT	2
Radiotherapy	2
Histologic Type	
Solid	1577
Sclerosing	242
Superficial	110
Others	483

Abbreviations: BCC, basal cell carcinoma; PDT, photodynamic therapy.

Table 2 Site of Lesions

	Patients	%
Head and neck	2144	98
Forehead	200	18
Infraorbital	185	17
Nasal septum	158	14
Temples	148	13
Dorsum of the nose	126	11
Cheek	102	9
Ala nasi	101	9
In front of the ear	90	8
Others	268	11

With regard to the 9 cases with subsequent recurrence of the basal cell carcinoma, 3 corresponded to sclerosing forms, 1 was a metatypic basal cell form, and the rest were solid basal cell carcinomas. Two of the sclerosing forms were located on the nose (lateral nasal septum and ala nasi) and the third was located on the forehead. The metatypic basal cell carcinoma was located behind the ear. Two of the solid basal cell carcinomas were located on the eyelid (inner corner and lower lid), 2 on the nose, and 1 on the forehead. The mean tumor size after recurrence was 0.5 cm² and the mean final defect was 1.6 cm². In all cases, a further MMS procedure was undertaken and there have been no reports of additional recurrence to date.

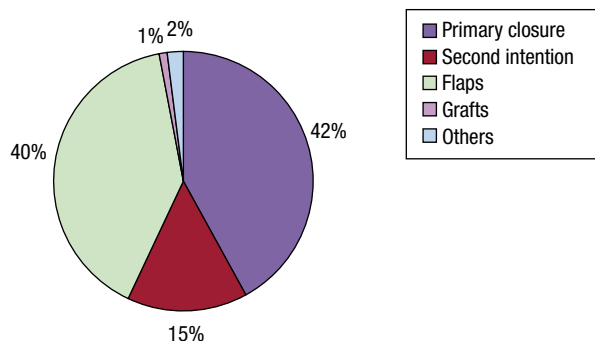
Discussion

It is important to highlight the increase in the number of cases of skin cancer in recent years, both in healthy individuals and patients with some degree of immunosuppression. The increase has been greater in countries where the number of patients who receive transplants is greater. In addition, the increased extent of exposure to sunlight as a result of lifestyle changes in modern society and the continued degradation of the ozone layer, as well as exposure to radiation from use and abuse of tanning devices such as sunbeds, are also factors responsible for the increase. Nonmelanoma skin tumors such as basal cell carcinoma are a frequent presenting complaint in dermatology departments, and dermatologists are responsible for diagnosis and treatment of this disease.

In our literature review, we found several studies that investigated MMS in the treatment of basal cell carcinoma. Few of these, however, reported 5-year recurrence rates and this information is required to draw truly valid conclusions. In most of the studies, recurrence rates between 1% and 7% were reported for MMS,⁵ with higher recurrence rates for other therapeutic alternatives. Thissen et al⁶ reported a recurrence rate of 5% for treatment with conventional surgery and 19% for tumors treated by curettage and radiotherapy. In the case of cryotherapy, studies have found recurrence rates of 4%, although the histologic type

Table 3 Outcomes of Treatment of Basal Cell Carcinoma With Mohs Micrographic Surgery

	Initial Defect cm ²	Final Defect cm ²	Final - Initial cm ²	Sections	Stages
Average over stages	0.82	1.88	1.02	1.74	3.8

**Figure 1** Techniques for Wound Closure After Mohs Micrographic Surgery.

of tumor was not specified.⁷ Photodynamic therapy had an efficacy of 90% in superficial basal cell carcinomas but histologic types such as sclerosing tumors had a recurrence rate of 19%⁸ and the nodular types and ulcerated nodular types had a response rate of 10% to 50%.⁹ It is also important to consider the tumor site given that the recurrence rate is greater when the tumor is located on the face. McGovern and Leffell¹⁰ reported a recurrence rate for MMS of 43% in the external canthus of the eye, 33% in the supraorbital region, 24% on the ear, and 19% on the nose but only a single recurrence among 187 patients with tumors located on sites other than the face. Nagore Enguidanos et al,¹¹ in a case-control study, included 35 patients with basal cell carcinomas of the internal canthus of the eye and 34 patients with basal cell carcinomas on the forehead and cheeks. They concluded that basal cell carcinomas of the internal canthus of the eye had a smaller tumor size, but as the tumors had infiltrated more deeply, more stages were required with more complex reconstructions during the surgical procedure and the recurrence rate was higher. These authors therefore recommended MMS as the first-choice treatment in this type of tumor. This is in line with our findings in that 2 basal cell carcinomas, located on the eyelid, recurred after MMS despite being of the solid form. The site with the highest rate of recurrence was the nose (4 cases), probably because 3 of these cases corresponded to sclerosing forms, which are considered much more aggressive. None of the tumors measured more than 2 cm. In a series of 105 tumors treated by MMS, 80% of which were basal cell carcinomas, Alonso et al¹² arrived at the conclusion that tumor size is the risk factor most strongly related to aggressiveness and subclinical extension of the tumor.

With regard to the time to recurrence, 75% of the tumors appear within 3 years of surgery,¹³ and so authors

recommend a follow-up time of up to 5 years after surgery for the primary tumor and 10 years for recurrences. We should also remember that patients who present with basal cell carcinoma have a 44% risk of presenting a second tumor.¹⁴ In these patients, a good follow-up strategy is to create skin oncology groups that perform an annual follow-up of patients and aim for early detection of new and recurrent tumors.

Many authors have attempted to explain why some patients present with recurrences even though MMS allows us to observe the entire margin.^{15,16} In 75% of the cases, this is due to an error in the technique. Hruza et al¹⁷ analyzed 77 cases of recurrence after MMS and found that the most common cause was that the dermis or epidermis were not sampled in the histologic preparations. Smeets et al¹⁸ indicated that there is a 2% error in the detection of basal cell carcinoma by hematoxylin-eosin staining, particularly for the sclerosing form. The possibility that basal cell carcinoma might not have continuous growth is also considered, although there are studies that do not support this hypothesis.¹⁹

MMS procedures that eradicate the tumor in no more than 2 stages incur the same cost as conventional surgery,²⁰ although only 71% of procedures actually require 2 stages or less.² In our study, the mean number of stages was less than 2. Therefore, when considering treatment of basal cell carcinoma with MMS, it is necessary to take into account not only the low recurrence rate but also weigh up other important factors such as histologic type, site, characteristics of the borders, tumor size, cosmetic outcomes for the patient, and whether immunosuppression is present.²²

Like many other authors, we believe that MMS is a valuable resource within the dermatologist's therapeutic options but it should be used consistently and only be practiced by experienced dermatologic surgeons whose know-how can ensure that the procedure is performed correctly.

Conclusion

Given the low recurrence rate of basal cell carcinoma in treatment with MMS in our study, in line with similar studies in the literature, we can conclude that basal cell carcinoma is an appropriate indication in lesions considered as high risk. The advantage of the technique lies in the methodology that allows all surgical margins, whether located on the surface or at depth, to be examined. This approach respects as far as possible healthy tissue and therefore optimizes subsequent reconstruction, while at the same time ensuring that the entire tumor has been excised.

Conflict of Interest

The authors declare that they have no conflicts of interest.

References

1. Gloster HM, Brodland DG. The epidemiology of skin cancer. *Dermatol Surg*. 1996;22:217-26.
2. Kuijper D, Thiessen M, Nuemann M. Basal cell carcinoma: treatment options and prognosis, a scientific approach to the common malignancy. *Am J Clin Dermatol*. 2002;3:247-59.
3. Mohs F. Chemosurgery, a microscopically controlled method of cancer excision. *Arch Surg*. 1941;42:279-95.
4. Gaston D, Naugle C, Clark D. Mohs micrographic surgery referral patterns: the University of Missouri experience. *Dermatol Surg*. 1999;25:862-6.
5. Wennberg A, Larko O, Stenquist B. Five-year of Moh's micrographic surgery for aggressive facial basal cell carcinoma in Sweden. *Acta Derm Venereol*. 1999;79:370-2.
6. Thissen M, Neumann M, Schouten L. A systemic review of treatment modalities for primary basal cell carcinoma. *Arch Dermatol*. 1999;135:1177-83.
7. Alonso Trujillo I, Castillo Oliva A, Rodríguez García M, Collazo Caballero S. Criocirugía en dermatología: Experiencia en el Hospital Clínico Quirúrgico Universitario "Hermanos Ameijeiras" *Dermatol*. Perú 2007;17:161-9.
8. Pennington D, Waner M, Knox A. Photodynamic therapy for multiple skin cancers. *Plast Reconstr Surg*. 1988;82:1067-71.
9. Reynolds T. Photodynamic therapy expands its horizons. *J Natl Cancer Inst*. 1997;89:112-4.
10. McGovern T, Leffell D. Mohs Surgery: The informed view. *Arch Dermatol*. 1999;135:1255-9.
11. Nagore Enguñados E, Llombart Cussac B, Compañ Quilis A, Sanmartín Jiménez O, Sevilla Llinares A, Botella Estrada R, et al. Cirugía micrográfica de Mohs del canto interno del ojo. Estudio de casos y controles. *Actas Dermosifiliogr*. 2002;93:406-12.
12. Alonso T, Sánchez P, González A, Ingelmo J, Ruiz I, Delgado S, et al. Cirugía de Mohs: nuestros primeros cien pacientes. *Actas Dermosifiliogr*. 2008;99:275-80.
13. Silverman MK, Kopf AW, Grin CM, Bart RS, Levenstein MJ. Recurrence rates of treated basal cell carcinomas. Part 1: Overview. *J Dermatol Surg Oncol*. 1991;17:713-8.
14. Marcil I, Stern R. Risk of developing a subsequent nonmelanoma skin cancer in patients with a history of nonmelanoma skin cancer: a critical review of the literature and meta-analysis. *Arch Dermatol*. 2000;136:1524-30.
15. Eliezri Y, Cohen P. Cancer recurrence following Mohs micrographic surgery: a mechanism of tumor persistence. *Plast Reconstr Surg*. 1992;90:121-5.
16. Dzubow L. False-negative tumor-free margins following Mohs surgery. *J Dermatol Surg Oncol*. 1988;14:600-6002.
17. Hruza G. Mohs micrographic surgery local recurrences. *J Dermatol Surg Oncol*. 1994;20:573-7.
18. Smeets NW, Stavast-Kooy AJ, Krekels GA, Daemen MJ, Newmann HA. Adjuvant cytokeratin staining in Mohs micrographic surgery for basal cell carcinoma. *Dermatol Surg*. 2003;29:375-7.
19. Lang P, McKelvey A, Nicholson J. Three-dimensional reconstruction of the superficial multicentric basal cell carcinoma using serial sections and a computer. *Am J Dermatopathol*. 1987;9:198-203.
20. Cook J, Zitelli J. Mohs micrographic surgery: a cost analysis. *J Am Acad Dermatol*. 1998;39:698-703.
21. Welch M, Anderson L, Grabski W. Evaluation and management of non melanoma skin cancer. The military perspective. *Dermatol Clin*. 1999;17:19-28.
22. Ríos-Buceta L, Picoto A. Cirugía de Mohs. *Actas Dermosifiliogr*. 2003;94:502-3.