

Teaching Point

(Section Editor: A Meyrier)

What is the risk that I will transmit nephrotic syndrome to my children, Doctor?

Geneviève Benoit^{1,2}, Vincent Morinière³, Marina Charbit⁴, Patrick Niaudet^{4,5} and Corinne Antignac^{1,3,5}

¹Inserm, U983, Hôpital Necker-Enfants Malades, Paris, France, ²Service de Néphrologie Pédiatrique, CHU Sainte-Justine, Université de Montréal, Canada, ³Assistance Publique-Hôpitaux de Paris (AP-HP), Département de Génétique, Hôpital Necker-Enfants Malades, Paris, France, ⁴Assistance Publique-Hôpitaux de Paris (AP-HP), Service de Néphrologie Pédiatrique, Hôpital Necker-Enfants Malades, Paris, France and ⁵Université Paris Descartes, Faculté de Médecine Paris Descartes, Paris, France

Correspondence and offprint requests to: Corinne Antignac; E-mail: corinne.antignac@inserm.fr

Keywords: hereditary glomerular disease; nephrotic syndrome; *NPHS2*

Introduction

Focal and segmental glomerulosclerosis (FSGS) is a histological entity commonly found in children and adults with steroid-resistant nephrotic syndrome (SRNS), with a 10-year renal survival rate in the 40–60% range [1–3]. FSGS has diverse aetiologies, among which genetic, infectious, toxic and inflammatory factors have been identified. In the last few years, significant advances have been made in the identification of genes involved in the development of familial forms of FSGS, thereby revealing molecules which play a central role in podocyte function. Determination of the appropriate genetic diagnosis is crucial, as it allows accurate counselling to be provided for the patients and their families, particularly on the risk of disease transmission.

Case

The proband is an 18-year-old boy from France who was diagnosed with non-syndromic SRNS at the age of 5. The kidney biopsy showed FSGS. The patient progressed to end-stage renal failure (ESRF) 15 months after the first clinical manifestations and was started on haemodialysis. He received a cadaveric renal allograft 10 months later, at the age of 8, without post-transplantation recurrence. His parents were first cousins. His father presented SRNS when he was 43 years old, and FSGS was also observed on a renal biopsy. On the last follow-up, at the age of 53, proteinuria was significantly reduced but still in the nephrotic range (3.5 g/24 h), and moderate chronic renal insufficiency (serum creatinine 160 µmol/L) was present. A pedigree is shown in Figure 1. The proband is seen in a genetic consultation and asks you: ‘What is the risk that I will transmit SRNS to my children, Doctor?’

Although a history of consanguinity is present, the analysis of disease segregation in this family may suggest an autosomal dominant disorder. However, the renal phenotype differs significantly between the proband and his father, from childhood-onset SRNS with ESRF to adult-onset SRNS with a slower deterioration of the renal function. Based on the clinical presentation of the proband, screening for mutations in the *NPHS2* gene was undertaken and revealed that this patient had a homozygous deletion of two nucleotides in exon 7 (c.855_856delAA, p.Arg286ThrfsX17). As expected, both his parents carried this mutation in the heterozygous state. However, this finding did not explain the occurrence of FSGS in the proband’s father. Search for the *NPHS2* p.R229Q polymorphism revealed this variant in the heterozygous state in the father but its absence in the mother and the proband. This confirmed that the proband’s father was compound heterozygous (*NPHS2*: p.[Arg286ThrfsX17] + [Arg229Gln]).

Discussion

In this family, both the proband and his father developed glomerular proteinuria with FSGS lesions on renal histology, strongly suggesting that a mutation in one of the genes involved in autosomal dominant FSGS may be the underlying cause. However, the presence of a significant difference in the severity of the clinical manifestations between the father and his son, the child presenting a very severe disease, oriented us towards the implication of the *NPHS2* gene and an autosomal recessive mode of inheritance.

Mutations in *ACTN4* and *TRPC6*, encoding α-actinin-4 and the transient receptor potential cation channel, subfamily C, member 6, respectively, have been shown to account for ~4% and 6% of the autosomal dominant juvenile or adult-onset FSGS [4,5]. In addition, *INF2*, which en-

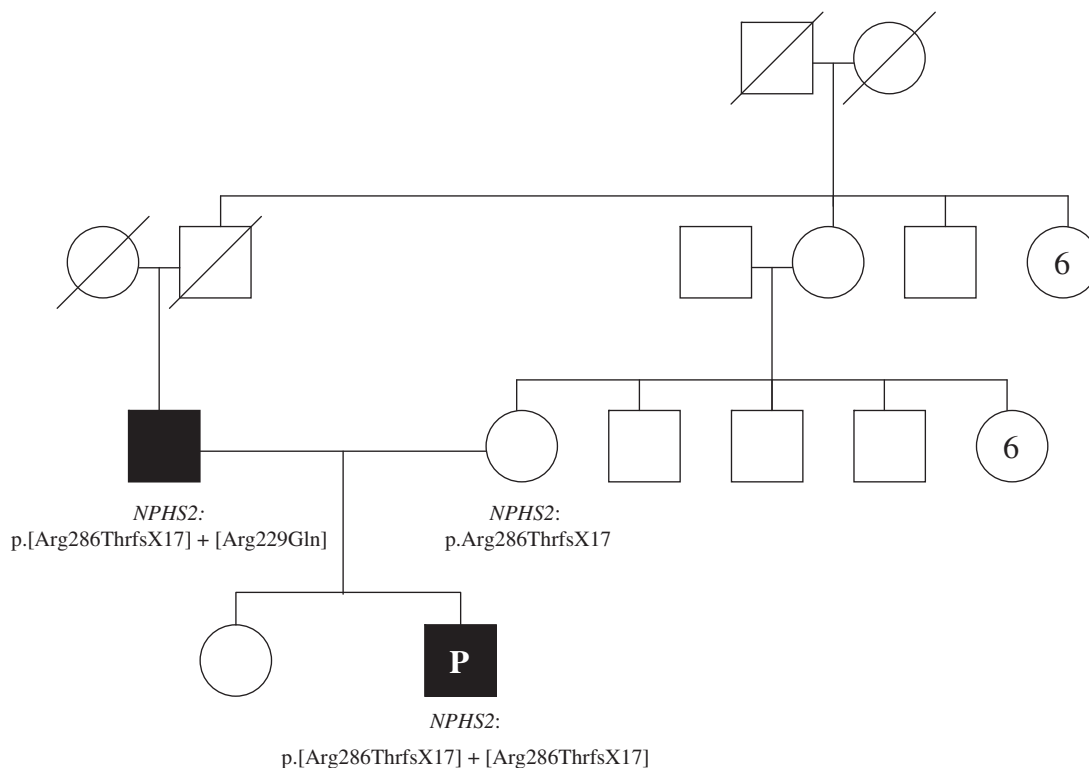


Fig. 1. Pedigree and *NPHS2* mutations identified in the family. The proband (P) was diagnosed with steroid-resistant nephrotic syndrome at the age of 5. He received a cadaveric renal allograft at the age of 8. His father presented proteinuria when he was 43 years old and developed moderate chronic renal insufficiency. FSGS was noted on renal histology of both patients.

codes a member of the formin family of actin-regulating proteins, has also been implicated very recently in families presenting a similar renal phenotype [6]. On the other hand, mutations in the *NPHS2* gene, encoding podocin, cause autosomal recessive FSGS and were initially described in early-onset SRNS [7]. Mutations in this gene occur in ~40% of familial SRNS cases [8,9]. Patients typically develop NS from birth to 6 years of age and reach ESRF before the end of the first decade. However, Tsukagushi *et al.* showed that *NPHS2* mutations may cause FSGS with a quite broad spectrum of severity and age of onset, as they identified mutations in this gene in ~30% of families with an adolescent or adult-onset recessive form of the disease [10]. Interestingly, in two-thirds of these families, the *NPHS2* p.R229Q variant was detected in association with one pathogenic mutation. Recently, in a large population-based US study, the allele frequency of the podocin p.R229Q variant was found to be 3.7% in white and 0.6% in black individuals [11], being the most frequently reported non-synonymous polymorphism in Caucasians. Several arguments point towards a pathogenic role of the p.R229Q allele in FSGS: (i) There is an evolutionary conservation of the arginine 229 residue in podocin orthologues. (ii) Arginine to glutamine is a non-conservative amino acid change. (iii) This variant alters functional properties of podocin *in vitro*, as a decreased nephrin binding to the p.R229Q podocin has been observed [10]. (iv) Further studies found epidemiological and clinical evidence confirming the role of this variant in the pathogenesis of SRNS. Indeed, Machuca *et al.* recently sequenced the complete coding region of

NPHS2 in 455 families with NS non-responsive to immunosuppressive therapy [12]. The median age at onset of NS in this cohort was 6 years (range 0–73). Six percent of the families (27 families; 14 from South America, 11 from Europe and 2 from North Africa) were compound heterozygous for the p.R229Q variant and one pathogenic mutation. These patients developed SRNS at a median age of 19 years (range 0–39) with a median age at ESRF of 27.9 years (range 9.3–43.5), clearly showing a correlation between genotype and age at disease presentation. Moreover, in the subset of patients with adult-onset NS, the frequency of *NPHS2* mutations was as high as 25% in those with a familial form of the disease. On the other hand, the presence of the p.R229Q variant in the homozygous state may rather act as a modifier, requiring an additional renal insult to lead to a clinically apparent disease. Indeed, although the proportion of homozygous individuals seems higher among affected cases than among controls [11–14], the incidence of FSGS is significantly less important than the expected frequency of p.R229Q homozygotes. Finally, it has been shown that single heterozygotes for p.R229Q or a pathogenic *NPHS2* mutation do not present a renal phenotype [12]. Some authors found an association between the p.R229Q variant and microalbuminuria [15], but this finding has not been confirmed in other studies [11].

In the family presented here, we detected a homozygous *NPHS2* mutation in the proband and compound heterozygous *NPHS2* mutations in his father, thereby proving that the podocin gene was responsible for the disease, with an autosomal recessive inheritance. In order to determine the

risk that the proband may transmit the disease to his children, genetic testing for the p.R229Q variant should be proposed to the spouse. If the variant is absent in the spouse, we can reassure the patient that the risk that his progeny will develop NS secondary to podocin mutations is minimal (in the absence of a consanguineous relationship), given the low prevalence of *NPHS2* mutations in a healthy population. However, if the p.R229Q variant is identified in the spouse, there is a 50% risk of disease (a juvenile or adult-onset form of SRNS) transmission to their progeny. Of note, this counselling should be modified if the parents are consanguineous, as there is an increased probability that the asymptomatic spouse carries the same pathogenic mutation (in the heterozygous state) as the patient. For example, if genetic counselling had been provided to the parents of the actual proband, they should have been informed that there was a 25% risk of transmitting early-onset SRNS (*NPHS2*: p.[Arg286ThrfsX17] + [Arg286ThrfsX17]) and a 25% risk of transmitting late-onset SRNS (*NPHS2*: p.[Arg286ThrfsX17] + [Arg229Gln]). Finally, the asymptomatic proband's sister may carry the p.Arg286ThrfsX17 mutation; therefore, she should be informed that she has a non-negligible risk of disease transmission to her children if the p.R229Q variant is detected in her spouse.

The identification of the pathogenic role of the p.R229Q variant raises particular concerns regarding living-related donor transplantation (usually from the mother or the father) in cases with inherited SRNS. Indeed, because the association of the p.R229Q variant and a pathogenic *NPHS2* mutation leads to a late-onset renal phenotype, a relative carrying this genotype could be fully asymptomatic at the time of pre-transplantation donor evaluation. This would have been the case if the father, who was free of proteinuria at the time his son reached ESRF, had considered kidney donation. Therefore, in a related potential donor of an SRNS patient with two documented pathogenic *NPHS2* mutations, exclusion of the p.R229Q variant seems advisable (in addition to screening for the specific *NPHS2* mutation involved in the family). This is particularly true considering that access to genetic testing is now easier than before and that mutational analysis of some specific *NPHS2* exons is relatively fast and inexpensive. The question whether a mother or father without the p.R229Q variant, who is however an obligatory healthy *NPHS2* heterozygous pathogenic mutation carrier, should be considered as a potential donor is another matter of debate. The long-term risk of developing renal disease after donor transplantation in a heterozygous carrier needs to be better evaluated before establishing clear guidelines on living-related donor transplantation in genetic forms of SRNS, although there is as of yet no evidence that this practice should be contraindicated.

Teaching points

- (1) Recessive *NPHS2* mutations typically lead to early-onset steroid-resistant nephrotic syndrome with a high risk of end-stage renal failure.

- (2) The *NPHS2* p.R229Q variant may cause late-onset FSGS if found in association with a pathogenic *NPHS2* mutation.
- (3) In SRNS patients with *NPHS2* mutations considering having children, genetic testing for the p.R229Q variant, which is found in high frequency in some populations, should be proposed to their asymptomatic spouses.
- (4) In SRNS patients with *NPHS2* mutations requiring a kidney transplant, exclusion of the p.R229Q variant in the related potential donor should be strongly considered (in addition to screening for the specific *NPHS2* mutation involved in the family).

Conflict of interest statement. None declared.

References

1. Beaufils H, Alphonse JC, Guedon J *et al.* Focal glomerulosclerosis: natural history and treatment. A report of 70 cases. *Nephron* 1978; 21: 75–85
2. Cattran DC, Rao P. Long-term outcome in children and adults with classic focal segmental glomerulosclerosis. *Am J Kidney Dis* 1998; 32: 72–79
3. El-Refaey AM, Bakr A, Hammad A *et al.* Primary focal segmental glomerulosclerosis in Egyptian children: a 10-year single-centre experience. *Pediatr Nephrol* 2010; Mar 2. [Epub ahead of print]
4. Weins A, Kenlan P, Herbert S *et al.* Mutational and biological analysis of alpha-actinin-4 in focal segmental glomerulosclerosis. *J Am Soc Nephrol* 2005; 16: 3694–3701
5. Santin S, Ars E, Rossetti S *et al.* TRPC6 mutational analysis in a large cohort of patients with focal segmental glomerulosclerosis. *Nephrol Dial Transplant* 2009; 24: 3089–3096
6. Brown EJ, Schlondorff JS, Becker DJ *et al.* Mutations in the formin gene *INF2* cause focal segmental glomerulosclerosis. *Nat Genet* 2009; 42: 72–76
7. Boute N, Gribouval O, Roselli S *et al.* *NPHS2*, encoding the glomerular protein podocin, is mutated in autosomal recessive steroid-resistant nephrotic syndrome. *Nat Genet* 2000; 24: 349–354
8. Hinkes B, Vlangos C, Heeringa S *et al.* Specific podocin mutations correlate with age of onset in steroid-resistant nephrotic syndrome. *J Am Soc Nephrol* 2008; 19: 365–371
9. Weber S, Gribouval O, Esquivel EL *et al.* *NPHS2* mutation analysis shows genetic heterogeneity of steroid-resistant nephrotic syndrome and low post-transplant recurrence. *Kidney Int* 2004; 66: 571–579
10. Tsukaguchi H, Sudhakar A, Le TC *et al.* *NPHS2* mutations in late-onset focal segmental glomerulosclerosis: R229Q is a common disease-associated allele. *J Clin Invest* 2002; 110: 1659–1666
11. Kottgen A, Hsu CC, Coresh J *et al.* The association of podocin R229Q polymorphism with increased albuminuria or reduced estimated GFR in a large population-based sample of US adults. *Am J Kidney Dis* 2008; 52: 868–875
12. Machuca E, Hummel A, Nevo F *et al.* Clinical and epidemiological assessment of steroid-resistant nephrotic syndrome associated with the *NPHS2* R229Q variant. *Kidney Int* 2009; 75: 727–735
13. Berdeli A, Mir S, Yavascan O *et al.* *NPHS2* (podocin) mutations in Turkish children with idiopathic nephrotic syndrome. *Pediatr Nephrol* 2007; 22: 2031–2040
14. McKenzie LM, Hendrickson SL, Briggs WA *et al.* *NPHS2* variation in sporadic focal segmental glomerulosclerosis. *J Am Soc Nephrol* 2007; 18: 2987–2995
15. Pereira AC, Pereira AB, Mota GF *et al.* *NPHS2* R229Q functional variant is associated with microalbuminuria in the general population. *Kidney Int* 2004; 65: 1026–1030

Received for publication: 29.4.10; Accepted in revised form: 6.5.10