

## Torsion of the Spleen with Incomplete Infarction: Case Report

O. Z. Lernau, J. Baron, and S. Nissan

*Hadassah University Hospital, Jerusalem, Israel and Ichilov Hospital, Tel Aviv, Israel*

***Torsion and infarction of a "wandering spleen" is a rare disease which is often confused with other acute abdominal crises. A correct preoperative diagnosis, when made, has usually been determined by arteriographic studies. A child is described in whom changes in the TcSC scan made a correct diagnosis possible by non-invasive methods.***

**J Nucl Med 18: 1208–1210, 1977**

Torsion and infarction of the spleen is a rare disease, especially in the young. Several recent reports have dealt with its roentgenographic and radionuclide manifestations. The case presented here illustrates a dynamic change in the radionuclide study which, together with the clinical picture, allowed for a correct preoperative diagnosis to be made.

### CASE REPORT

A 5-year-old girl was admitted to the hospital with a history of intermittent left abdominal pain of one year's duration. The pain had become progressively more severe over the 2 wk before admission and was accompanied by malaise and vomiting. Physical examination showed a tender mass in the lower abdomen; it was palpated with some difficulty because of voluntary muscle spasm. The right side of the abdomen was soft and non-tender, and the patient was afebrile.

Laboratory investigations included Hb of 7.8 g%,



**FIG. 1.** Tc-99m sulfur colloid scan on admission. No uptake in spleen.

white blood count of 16,000 mm<sup>3</sup> and normal urinalysis and liver-function tests.

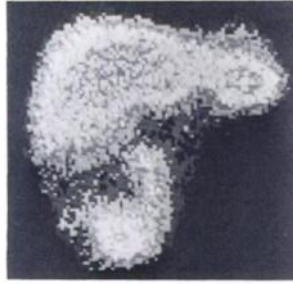A plain abdominal film showed a mass in the left lower abdomen displacing the descending colon laterally. It also showed obliteration of the borders of the left psoas muscle and of the lower pole of the left kidney. On the i.v. pyelogram, the left ureter was dilated down to the pelvic brim.

A Tc-99m sulfur colloid (TcSC) scan was carried out on admission (Fig. 1). It showed a normal liver but no spleen. The patient's general condition was stable and she was treated initially with nasogastric suction and i.v. fluids. During the next few hours the abdominal tenderness subsided and the palpated mass strongly suggested an enlarged spleen. A repeat TcSC scan showed uptake of colloid, other than in the liver, in two areas, one in the left upper abdomen, the other in the right lower abdomen (Fig. 2).

At laparotomy an enlarged spleen was found, completely devoid of its ligamentous attachments. It was reddish black in color and lay anterior to the abdominal organs, the upper pole in the left upper abdomen and the lower pole caudal to the right lobe of the liver. Its blood vessels formed an 18-cm-long, cord-like pedicle that was twisted 360° in a counter-clockwise direction; this compressed the descending colon. The splenic vein contained clotted blood.

Received Sept. 7, 1976; revision accepted June 29, 1977.

For reprints contact: O. Lernau, Dept. of Surgery, Hadassah Medical Ctr., Mt. Scopus, Jerusalem, Israel.



**FIG. 2.** Second TcSC scan. Note colloid uptake in left upper abdomen and right lower abdomen.

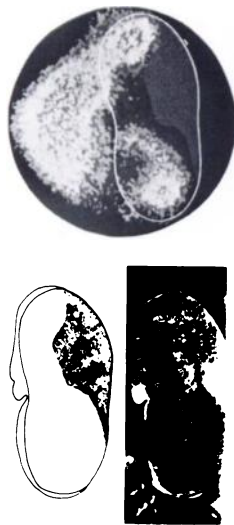Splenectomy was performed, followed by an uneventful recovery.

The spleen weighed 350 g. The cut surface showed evidence of partial infarction. The pattern of the non-infarcted areas corresponded to the areas of colloid uptake as demonstrated in the second scan (Fig. 3).

#### DISCUSSION

Torsion of a "wandering spleen" is a rare disease. It has been described mainly in females in the child-bearing years, where anomalous ligamentous attachments of the spleen become lax and elongated (1,2). There are only a few reports of torsion of the spleen in children (1,3,4,5).

In the case described, attention was drawn to splenic disease by the first TcSC study, which failed to show uptake of the colloid in the spleen. The



**FIG. 3.** Correlation between second scintigraphic examination, pathologic changes in the removed spleen, and operative findings. Lower right: cut surface of spleen shows infarcted area, as sketched at lower left. Above: line drawing is superimposed on scintigraphic image, showing position of spleen in abdomen. Note that only the lower and upper poles of the spleen have taken up the radionuclide.

second colloid study, however, demonstrated that there was some return of bloodflow to the spleen, since it now showed functional areas in the upper and lower poles. The above radionuclide picture can be consistent with either of two conditions:

1. A complete obstruction of the splenic artery caused by torsion, partially relieved by incomplete "detorsion" and reperfusion of segments of the splenic pulp through released arterial branches.

2. A partial infarction or a hematoma in a large and diseased spleen, causing an initial complete obstruction to blood flow by reflex vasoconstriction, with subsequent reopening of the vascular bed to the remaining non-infarcted spleen.

Non-visualization of the spleen with the TcSC scan in splenic torsion has been recently described by Broker et al. (6). Non-visualization may also be due to other conditions such as congenital absence of the spleen (7) or "functional asplenia" in sickle-cell anemia (8). Rosenthal et al. (9) described a chain of events somewhat like those in the present case: a twisted spleen that was not visualized initially but showed up faintly a few days later when Tc-99m macroaggregated albumin was injected directly into the celiac artery. However, no repeat scan was done by i.v. injection of TcSC, which presumably would have shown the return of splenic blood flow. The definite diagnosis in their case was obtained by arteriography, which has also been used by others (10). This examination carries a much higher risk, especially in a child. Thus, an acute abdominal episode with a palpable mass on the left side, in conjunction with non-visualization of the spleen in a TcSC study, should suggest torsion of the spleen and call for immediate exploration. Should the clinical course be benign, however, and the diagnosis obscure (3,9), a later repeat scan would be called for with a view to ascertaining whether there has been a return of splenic blood flow. This would confirm the diagnosis.

It would be interesting to find out whether partial infarction of a normally attached spleen could cause early and complete disappearance of its scintigraphic image by reflex vasoconstriction, as postulated above. If it does not, then "reappearance" of the spleen would indeed be pathognomonic for splenic torsion.

#### REFERENCES

1. ABELL I: Wandering spleen with torsion of the pedicle. *Ann Surg* 98: 722-735, 1933
2. WOODWARD DAK: Torsion of the spleen. *Amer J Surg* 114: 953-955, 1967
3. DEBARTOLO HM JR, VAN HEERDEN JA, LYNN HB, et al: Torsion of the spleen: A case Report. *Mayo Clin Proc* 48: 783-786, 1973

LERNAU, BARON, AND NISSAN

4. BELLMAINE SP: Splenoptosis in infancy: Two cases. *Med J Australia* 1: 236-237, 1956

5. HALL CL: Wandering spleen during first decade of life. *Brit Med J* 1: 957-958, 1952

6. BROKER FHL, KHETTRY J, FILLER RM, et al: Splenic torsion and accessory spleen: A scintigraphic demonstration. *J Ped Surg* 10: 913-915, 1975

7. MURPHY JW, MITCHELL WA: Congenital absence of spleen. *Pediatrics* 20: 253-256, 1957

8. PEARSON HA, SPENCER RP, CORNELLUS EA: Functional asplenia in sickle-cell anemia. *N Engl J Med* 281: 923-925, 1969

9. ROSENTHAL L, LISBONA R, BANERJEE K: A nucleographic and radioangiographic study of a patient with torsion of the spleen. *Radiology* 110: 427-428, 1974

10. BOSNIAK MA, BYCK W: Wandering spleen diagnosed preoperatively by intravenous aortography. *Am J Roentgenol* 84: 898-901, 1960

## **SNM ROCKY MOUNTAIN CHAPTER ANNUAL MEETING**

**April 6-8, 1977**

**Hilton Inn**

**Albuquerque, New Mexico**

### **CALL FOR ABSTRACTS**

The Annual Scientific Meeting of the Rocky Mountain Chapter of the Society of Nuclear Medicine will be held Thursday through Saturday, April 6-8, 1977 at the Hilton Inn, 1901 University Boulevard, N.E., Albuquerque, NM 87125.

The program will include: Clinical Radiopharmacy; Investigation of IND Drugs; Special Technologist Session; Regular Scientific Session; Commercial Exhibits; Business Meeting; Tour of Los Alamos Scientific Laboratories.

The Clinical Radiopharmacy program will include exploring this new topic in depth and will include presentations by several guest speakers, as well as panels and discussions by participants. This part of the program is cosponsored by the University of New Mexico, College of Pharmacy and Radiopharmacy. Program coordinator is Buck A. Rhodes.

### **GUIDELINES FOR SUBMITTING ABSTRACTS**

Abstracts accepted for the program will be published in the *Rocky Mountain Medical Journal* (except for those also accepted for publication in *JNM*). The deadline for submitting abstracts for the regular scientific session is:

**FEBRUARY 15, 1978**

Abstracts may be submitted simultaneously to both the Chapter and the National SNM offices. The original abstract and two copies (or three copies, if the original is submitted to national office) with supporting data attached to each should be sent to:

**W. MARION JORDAN, M.D.**  
**Department of Radiology**  
**Presbyterian Hospital Center**  
**Albuquerque, NM 87102**



The Journal of  
NUCLEAR MEDICINE

## Torsion of the Spleen with Incomplete Infarction: Case Report

O. Z. Lernau, J. Baron and S. Nissan

*J Nucl Med.* 1977;18:1208-1210.

---

This article and updated information are available at:  
<http://jnm.snmjournals.org/content/18/12/1208>


---

Information about reproducing figures, tables, or other portions of this article can be found online at:  
<http://jnm.snmjournals.org/site/misc/permission.xhtml>

Information about subscriptions to JNM can be found at:  
<http://jnm.snmjournals.org/site/subscriptions/online.xhtml>

*The Journal of Nuclear Medicine* is published monthly.  
SNMMI | Society of Nuclear Medicine and Molecular Imaging  
1850 Samuel Morse Drive, Reston, VA 20190.  
(Print ISSN: 0161-5505, Online ISSN: 2159-662X)

© Copyright 1977 SNMMI; all rights reserved.

 SOCIETY OF  
NUCLEAR MEDICINE  
AND MOLECULAR IMAGING