

Severe Hemorrhagic Meningoencephalitis Due to *Angiostrongylus cantonensis* Among Young Children in Sydney, Australia

Nikola J. Morton,¹ Philip Britton,² Pamela Palasanthiran,¹ Ann Bye,¹ Ella Sugo,¹ Alison Kesson,^{2,3} Simone Ardern-Holmes,² and Thomas L. Snelling^{1,4}

¹Randwick Campus, and ²Westmead Campus, The Sydney Children's Hospital Network, ³Discipline of Paediatrics and Child Health, Sydney Medical School, University of Sydney; and ⁴National Centre for Immunisation Research and Surveillance, Westmead, New South Wales, Australia

***Angiostrongylus cantonensis* is the most common cause of eosinophilic meningitis worldwide. We describe 2 cases among young children from Sydney, Australia, where locally acquired infection of children has not been reported previously. Both cases manifested as severe hemorrhagic meningoencephalitis, one resulting in death. Angiostrongyliasis must be considered in acute neurological presentations occurring among individuals who live in endemic areas.**

Keywords. *Angiostrongylus cantonensis*; eosinophilia; meningoencephalitis; children; susceptibility-weighted imaging.

Angiostrongylus cantonensis is endemic in many parts of the world and is the most common cause of eosinophilic meningitis worldwide. We report 2 cases of locally-acquired Angiostrongyliasis in young children from Sydney, Australia. These cases illustrate the clinical challenges of the diagnosis and management of *Angiostrongylus cantonensis* infection.

CASE ONE

A 10-month-old girl presented after 6 days of lethargy and irritability. She had been sleeping poorly but had no anorexia, fever, or vomiting. She lived in suburban Sydney and was previously

well and fully vaccinated. There had been no overseas travel, notable animal exposures, or history of mollusk ingestion.

She was irritable but alert and afebrile. Facial movements were subtly decreased and she was drooling but eye movements were complete. She had head lag and antigravity movements only in the upper limbs, and was unable to support her own weight. She was hypotonic and areflexic.

The blood leukocyte count was 9.7×10^9 cells/L (65% lymphocytes, 39% neutrophils, 3% eosinophils). Hemoglobin, platelet count, electrolytes, and liver function tests were normal. C-reactive protein and lactate dehydrogenase were not elevated. Cerebrospinal fluid (CSF) analysis revealed 17 leukocytes/cmm (80% monocytes; 20% neutrophils), protein level of 0.52 g/L, and normal glucose and lactate levels. Magnetic resonance imaging (MRI) of the brain and spine showed mild enhancement of lumbosacral nerve roots. Neurophysiological studies performed on day 1 of admission were consistent with a proximal polyradiculoneuropathy. A presumptive diagnosis of Guillain-Barre syndrome was made and intravenous immunoglobulin was given.

Over the next 14 days, she had ongoing irritability, low-grade fevers, mild diarrhea, and progressive weakness. Intravenous immunoglobulin was repeated on day 15 but in the days that followed, ocular and facial movements were lost, followed by an acute deterioration in consciousness. Repeat MRI brain showed reduced parenchymal volume and moderate leptomeningeal enhancement. Susceptibility-weighted imaging (SWI) showed numerous hypointense foci within the parenchyma.

Repeat lumbar puncture showed marked eosinophilic pleocytosis (1125×10^6 /L leukocytes; 55% eosinophils), low glucose level (<0.2 mmol/L), and elevated lactate level (8.1 mmol/L). CSF India ink staining, cryptococcal antigen, and polymerase chain reaction (PCR) tests for herpes simplex virus (HSV), cytomegalovirus, Epstein-Barr virus, enterovirus, and mycobacteria were negative. Serology for HIV, viral hepatitis, varicella, rabies, rickettsia, Lyme disease, human herpesviruses 6 and 8, toxocara, and *Angiostrongylus cantonensis* were all negative. Findings of echocardiography, abdominal ultrasound, funduscopy, bone marrow aspiration, and flow cytometry were unremarkable. Further neurophysiological studies demonstrated severe sensorimotor axonal neuropathy and marked denervation.

High-dose corticosteroids were commenced on day 20. A brain biopsy performed 24 hours later demonstrated hemorrhagic leptomeningitis with a predominant plasma cell infiltrate and moderate reactive gliosis. There was infiltration of medium-sized vessels by inflammatory cells including eosinophils without

Received 27 March 2013; accepted 24 June 2013; electronically published 9 July 2013.

Correspondence: Thomas L. Snelling, MBBS, FRACP, PhD, c/o Telethon Institute for Child Health Research, Subiaco, Western Australia (tsnelling@ichr.uwa.edu.au).

Clinical Infectious Diseases 2013;57(8):1158–61

© The Author 2013. Published by Oxford University Press on behalf of the Infectious Diseases Society of America. All rights reserved. For Permissions, please e-mail: journals.permissions@oup.com.

DOI: 10.1093/cid/cit444

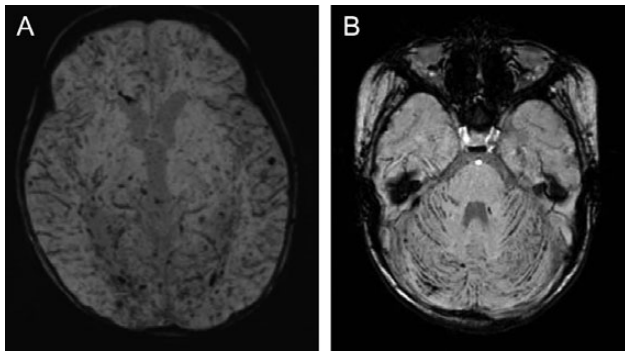


Figure 1. Brain magnetic resonance imaging (susceptibility-weighted imaging sequence) for 2 children with *Angiostrongylus* meningoenkephalitis, on day 23 of admission for case 1 (A) and on day 18 of admission for case 2 (B).

definite evidence of necrotizing vasculitis. Albendazole and imatinib were commenced, followed by a reduction in the eosinophilia but ongoing clinical deterioration. Repeat brain MRI showed further hypointense foci on SWI and evolving cerebral edema and white matter changes (Figure 1A). The child remained unresponsive with generalized weakness, and electroencephalography was consistent with global encephalopathy. After discussion with the family, active treatment was withdrawn and the patient died on day 27 of admission.

At autopsy, numerous 10 – to 12-mm threadlike organisms were visible macroscopically in the lumbar subdural space and over the cerebral surface and brainstem (Figure 2). Microscopically, both degenerate and viable organisms were seen in the subarachnoid space and central nervous system (CNS) parenchyma accompanied by patchy hemorrhagic meningitis in the brain and spinal cord. In the gray and white matter there were innumerable linear tracts of tissue destruction containing foamy macrophages, blood, and helminths (Figure 3). Degenerate helminths were also detected within the pulmonary

vasculature surrounded by inflammatory cells with a small pulmonary infarct. Helminths were identified as *A. cantonensis*, based on size, body shape, and long copulatory spicules in the male nematodes.

CASE 2

Two weeks after presentation of the child in case 1, a 14-month-old girl presented with 10 days of fever, irritability, early-morning vomiting, and dysconjugate eye movements. She was born in Sydney and resided within several kilometers of the first child. There had been no overseas travel or notable animal exposures.

She was irritable and lethargic with a bulging fontanelle. Upper limb movements were inexact with an intention tremor bilaterally. CSF demonstrated leukocytosis of $210 \times 10^6/L$ (45% eosinophils), protein level of 0.62 g/L, and glucose level of 0.6 mmol/L; the blood eosinophil count was $0.8 \times 10^9/L$. MRI demonstrated multiple hyperintensities scattered throughout both cerebral and cerebellar hemispheres on T2 and fluid-attenuated inversion recovery sequences, and hypointensities in the cerebellar sulci on SWI. CSF cultures, cytology, India ink stain, cryptococcal antigen, and PCR for HSV, enterovirus, and meningococcus were negative. A presumptive diagnosis of *A. cantonensis* meningoenkephalitis was made. Corticosteroids and albendazole were commenced, but albendazole was ceased after 10 days because of transaminitis.

Over the first week the child's condition worsened, with evolution of hydrocephalus requiring extraventricular drainage. Repeat MRI showed further focal hypointensities on SWI, particularly in the cerebellum (Figure 1B). Serial serum *Angiostrongylus* antibody testing was equivocal (0.39 IU and 0.32 IU) on days 5 and 21, and positive (0.74 IU) on day 24 of admission. A 10-week course of corticosteroids was titrated to her symptoms and eosinophil count, during which time her

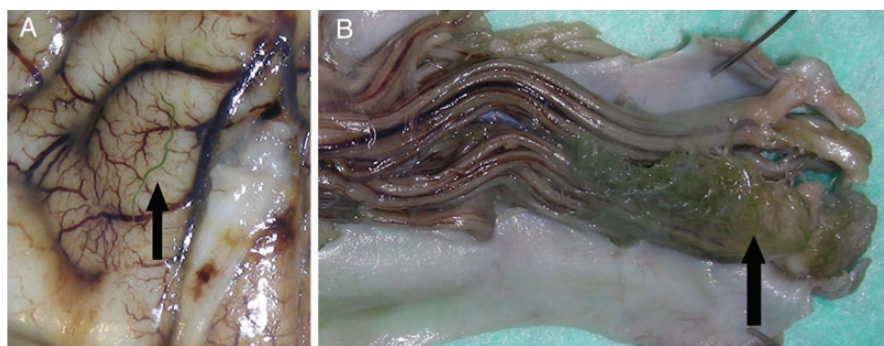


Figure 2. Autopsy photographs of case 1 showing macroscopically visible green-colored larvae of *Angiostrongylus cantonensis* (arrows) on the surface of the cerebrum (A) and forming a mass around the cauda equina in the lumbar subdural space (B). Note patchy brown discoloration of leptomeninges by hemosiderin, indicative of previous hemorrhage (B).

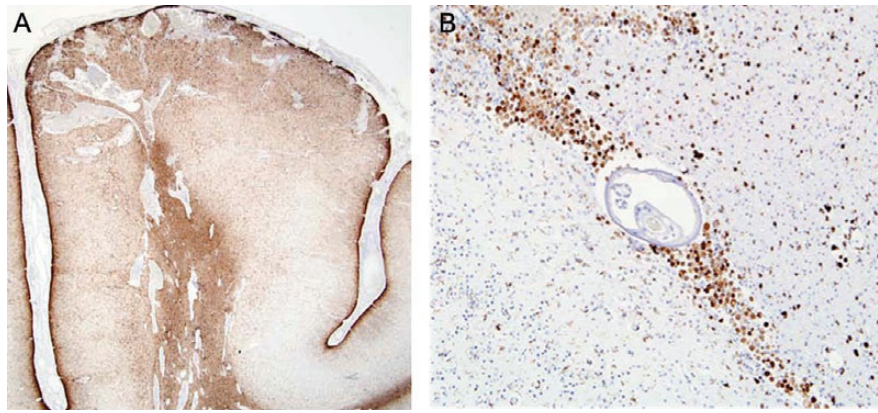


Figure 3. Histopathological sections from the autopsy of the child in case 1. Cerebral cortex and white matter showing numerous linear tracks of destruction with surrounding gliosis (A, glial fibrillary acid protein immunohistochemical stain, $\times 40$): high-power view of track in white matter filled with CD68⁺ macrophages and including cross-section of *Angiostrongylus cantonensis* (B, CD68 immunohistochemical stain, $\times 400$).

coordination improved. Three months after presentation, headaches and vomiting recurred due to progressive communicating hydrocephalus, requiring recommencement of steroids and acetazolamide, and insertion of a Rickham reservoir. Six months later she had recurrent symptoms of raised intracranial pressure after weaning of corticosteroids; CSF showed improved but persistent pleocytosis.

An attempt was made by public health officials to identify infected rats near the residences of each case, but none were caught. No common food or environmental source exposures could be identified.

DISCUSSION

Angiostrongylus cantonensis, the most common cause of eosinophilic meningoencephalitis worldwide, is endemic in the Caribbean, in East and Southeast Asia, and throughout the Pacific basin including Hawaii [1] and parts of Australia [2, 3]. Locally acquired human cases have also been reported from Brazil [4], Africa [5], and the United States [6]. The first reported human infection in Australia was in 1971 [7]; although infection is well documented in animals [8], only occasional autochthonous human cases have been reported since then [7–9]. To our knowledge these cases—which occurred within days of each other—are the first autochthonous cases among young children in the greater Sydney area.

In Australia, the definitive hosts are nonnative rats in whose pulmonary arteries and cardiac cavities adult worms lay their eggs [3, 10, 11]. These hatch in the lung capillaries and larvae pass from the alveoli up the trachea, and are then swallowed [3, 10, 12]. Larvae passed in the rat's feces are ingested by snails or other mollusks [3, 10]. Humans are infected by ingesting mollusks or possibly food contaminated with larvae, such as

improperly cooked crustaceans or unwashed vegetables. Larvae penetrate the intestinal wall, entering the circulatory system before migrating to the CNS [3, 10]. Unable to complete their life cycle, the larvae die, leading to intense CNS inflammation. The finding of larvae in the pulmonary vasculature at autopsy of the first child has been reported in only a small number of cases previously [12–15], and suggests that some larvae successfully migrate beyond the CNS.

Among adults, infection most commonly results in self-limiting meningitis and deaths are rarely reported [16]. Among children, nonspecific features (ie, fever, somnolence, weakness, nausea, and vomiting) occur more frequently [3, 17] and death or severe disability from overwhelming encephal meningitis appears to be most commonly reported among infants and toddlers [12, 13, 17, 18]. The initial clinical and neurophysiological features of the first child may reflect compression of nerve roots by larvae in the subdural space with ensuing distal Wallerian degeneration. The resultant flaccid paralysis masqueraded as Guillain-Barre syndrome, a pattern observed in young children previously [12].

The present cases illustrate some of the clinical challenges posed by *A. cantonensis* infection, with respect to both diagnosis and management. A history of witnessed mollusk ingestion is often absent in cases among young children [19], leading to uncertainty about the exact mechanism of infection. Blood or CSF eosinophilia may not be present at presentation [19], and CSF eosinophils might not be distinguished from neutrophils without the use of dedicated stains [9]. Furthermore, seroconversion may be delayed or, as in the first child, might not occur [12].

The MRI features of the present cases were distinctive. Generalized leptomeningeal enhancement [12, 20] and enhancing nodules on gadolinium-enhanced T1-images [13, 18, 20, 21] have been reported previously, as have normal MRI appearances [20].

The novel finding in both children of multiple hypointense foci on SWI sequences, known to accentuate paramagnetic properties of blood products [19], appears to correspond to the many blood-filled tracts seen on histopathology (Figure 3). The use of SWI might be an effective aid to diagnosis.

Management is controversial [3]. Anthelmintics have been used to treat angiostrongyliasis in children [17], but their role in the management of severe cases remains uncertain. Although they appear to reduce the duration of headache in typical cases [22], accelerating the death of migrating larvae might paradoxically worsen symptoms by enhancing the immune response [23]. Corticosteroids, alone or in combination with anthelmintics, appear to be beneficial [24]. Although educating parents about the dangers of handling mollusks seems a sensible precaution, it is not clear that this will prevent those cases where ingestion is not observed.

We have described concurrent cases of severe hemorrhagic *Angiostrongylus* meningoencephalitis. Neither patient had a history of witnessed mollusk ingestion or travel outside Australia. Where available, SWI sequence on MRI may be an adjunctive tool for diagnosis. Clinicians should be aware of the geographic distribution of this worm and its potential to cause death and severe disability. Work is needed to better define the treatment of severe cases and to establish effective preventive strategies.

Note

Potential conflicts of interest. All authors: No reported conflicts.

All authors have submitted the ICMJE Form for Disclosure of Potential Conflicts of Interest. Conflicts that the editors consider relevant to the content of the manuscript have been disclosed.

References

- Hochberg NS, Park SY, Blackburn BG, et al. Distribution of eosinophilic meningitis cases attributable to *Angiostrongylus cantonensis*, Hawaii. *Emerg Infect Dis* **2007**; 13:1675–80.
- Hughes AJ, Biggs BA. Parasitic worms of the central nervous system: an Australian perspective. *Intern Med* **2002**; 32:541–53.
- Wang QP, Lai DH, Zhu XQ, Chen XG, Lun ZR. Human angiostrongyliasis. *Lancet Infect Dis* **2008**; 8:621–30.
- Simoes RO, Monteiro FA, Sanchez E, et al. Endemic angiostrongyliasis, Rio de Janeiro Brazil. *Emerg Infect Dis* **2011**; 17:1331–3.
- Archer CE, Appleton CC, Mukaratirwa S, Hope KJ. The rat lung-worm *Angiostrongylus cantonensis*: a first report in South Africa. *S Afr Med J* **2011**; 101:174–5.
- New D, Little MD, Cross J. *Angiostrongylus cantonensis* infection from eating raw snails. *N Engl J Med* **1995**; 332:1105–6.
- Prociw P, Spratt DM, Carlisle MS. Neuro-angiostrongyliasis: unresolved issues. *Int J Parasitol* **2000**; 30:1295–303.
- Prociw P, Carlisle MS. The spread of *Angiostrongylus cantonensis* in Australia. *Southeast Asian J Trop Med Public Health* **2001**; 32(suppl 2):126–8.
- Senanayake SN, Pryor DS, Walker J, Konecny P. First report of human angiostrongyliasis acquired in Sydney. *Med J Aust* **2003**; 179:430–1.
- Graeff-Teixeira C, da Silva AC, Yoshimura K. Update on eosinophilic meningoencephalitis and its clinical relevance. *Clin Microbiol Rev* **2009**; 22:322–48.
- Spratt DM. Neuroangiostrongyliasis: disease in wildlife and humans. *Microbiol Aust* **2005**; 26:53–4.
- Lindo JF, Escoffery CT, Reid B, Codrington G, Cunningham-Myrie C, Eberhard ML. Fatal autochthonous eosinophilic meningitis in a Jamaican child caused by *Angiostrongylus cantonensis*. *Am J Trop Med Hyg* **2004**; 70:425–8.
- Cooke-Yarborough CM, Kornberg AJ, Hogg GG, Spratt DM, Forsyth JR. A fatal case of angiostrongyliasis in an 11-month-old infant. *Med J Aust* **1999**; 170:541–3.
- Yii CY, Chen CY, Fresh JW, Chen J, Cross JH. Human angiostrongyliasis involving the lungs. *Chin J Microbiol* **1968**; 1:148–50.
- Sonakul D. Pathological findings in four cases of human angiostrongyliasis. *Southeast Asian J Trop Med Public Health* **1978**; 9:220–7.
- Tangchai P, Nye SW, Beaver PC. Eosinophilic meningoencephalitis caused by angiostrongyliasis in Thailand. Autopsy report. *Am J Trop Med Hyg* **1967**; 16:454–61.
- Hwang KP, Chen ER. Clinical studies on angiostrongyliasis cantonensis among children in Taiwan. *Southeast Asian J Trop Med Public Health* **1991**; 22(suppl):194–9.
- Graber D, Hebert JC, Jaffar-Bandjee MC, Alessandri JL, Combes JC. Severe forms of eosinophilic meningitis in infants of Mayotte. Apropos of 3 cases. *Bull Soc Pathol Exot* **1999**; 92:164–6.
- Tseng YT, Tsai HC, Sy CL, Lee SS, Wann SR, Wang YH. Clinical manifestations of eosinophilic meningitis caused by *Angiostrongylus cantonensis*: 18 years' experience in a medical center in southern Taiwan. *J Microbiol Immunol Infect* **2011**; 44:382–9.
- Jin EH, Qiang MA, Da-qing MA, Wen HE, Ai-ping JI, Cheng-hong YIN. Magnetic resonance imaging of eosinophilic meningoencephalitis caused by *Angiostrongylus cantonensis* following eating freshwater snails. *Chin Med J* **2008**; 121:67–72.
- Tsai HC, Tseng YT, Yen CM, et al. Brain magnetic resonance imaging abnormalities in eosinophilic meningitis caused by *Angiostrongylus cantonensis* infection. *Vector Borne Zoonotic Dis* **2012**; 12:161–6.
- Jitpimolmard S, Sawanyawisuth K, Morakote N, Vejajiva A, Puntumetakul M, Sanchaisuriya K. Albendazole therapy for eosinophilic meningitis caused by *Angiostrongylus cantonensis*. *Parasitol Res* **2007**; 100:1293–6.
- Wang LC, Jung SM, Chen CC, Wong HF, Wan DP, Wan YL. Pathological changes in the brains of rabbits experimentally infected with *Angiostrongylus cantonensis* after albendazole treatment: histopathological and magnetic resonance imaging studies. *J Antimicrob Chemother* **2006**; 57:294–300.
- Chotmongkol V, Sawanyawisuth K, Thavornpitak Y. Corticosteroid treatment of eosinophilic meningitis. *Clin Infect Dis* **2000**; 31:660–2.