

A Rare Case of Acute Abdomen: Garegeot Hernia

V. Ardeleanu^{1,2}, S. Chicos¹, D. Tutunaru^{1,3}, C. Georgescu²

¹First Surgery Department, Emergency Clinical Hospital „Sfantul Apostol Andrei”, Galați, Romania

²“Lower Danube” University, Faculty of Medicine and Pharmacy, Galați, Romania

³Emergency Clinical Hospital „Sfantul Apostol Andrei”, Galați, Romania

Rezumat

Un caz rar de abdomen acut: hernie Garegeot

Asocierea apendicitei acute cu hernia femurală strangulată sau încarcerată, reprezintă o patologie rar întâlnită, dar bine documentată în literatura de specialitate medicală, așa numita hernie a lui Garegeot. Dezvoltarea unei apendicite acute în sacul de hernie femurală, devine o urgență chirurgicală de abdomen acut. Diagnosticul este întotdeauna confundat cu cel de hernie încarcerată sau strangulată, diagnosticul de certitudine fiind stabilit intraoperator, ocazie cu care la deschiderea sacului herniar se constată prezența apendicelui cecal, aflat în diferite stadii morfologice ale inflamației, care pot merge până la gangrena și perforația acestuia. În această lucrare, am raportat cazul unei femei de 76 de ani, care se prezintă pentru prezența unei formațiuni tumorale femurale, încarcerate, dureroase, care a fost inițial considerată ca hernie femurală încarcerată, diagnosticul final fiind stabilit intraoperator. Tratamentul acestor “hernii” este în general simplu, atunci când nu există complicații ale apendicitei acute, precum prezența de puroi în sacul de hernie, și constă în apendicectomie și herniorafie. Absența unei simptomatologii specifice apendicitei acute, face ca de cele mai multe ori intervenția chirurgicală să fie temporizată ceea ce duce la apariția frecventă a complicațiilor și la creșterea morbidității.

Cuvinte cheie: hernie femurală, încarcerare, apendicită

Abstract

The association of acute appendicitis with femoral hernia, strangulated or incarcerated, represents a rare but well documented pathology in the specialized medical literature, also known as Garegeot hernia. The development of an acute appendicitis in the femoral hernia sac becomes a surgical emergency of acute abdomen. The diagnosis is always mistaken for the one of incarcerated or strangled hernia, the correct diagnosis being established intraoperatively, occasion which exposes the cecal appendix by opening the herniary bag, found in different morphological stages of inflammation that can go as far as gangrene or even perforation. In this paper, we have reported the case of a 76 year-old female that presented with femoral tumours, incarcerated, painful and initially considered as an incarcerated femoral hernia, the final diagnosis being made intraoperatively. The treatment for these “hernias” is generally simple, when there are no complications of acute appendicitis as the presence of pus in the hernia sac, and consists in appendectomy and herniorrhaphy. The absence of symptoms for an acute appendicitis often delays the surgery which leads to frequent complications and increased rate of morbidity.

Key words: femoral hernia, incarcerated, appendicitis

Corresponding author:

Dana Tutunaru, MD
Roșiori Street, no 39, bloc PIN 2, sc.1
ap. 10, Galați, Romania
E-mail: dana_tutunaru_cmgl@yahoo.com

Introduction

The migrations of the cecal appendix in a hernia sac are a rare situation in most cases, the migration taking place right there in the inguinal hernia (hernia of Amyand) and very rarely in the right femoral hernia sac (herniation of Garengeot) which is an incarcerated hernia in the presence of cecal appendix in the hernia sac. The incidence of these types of acute appendicitis is estimated according to statistics from 0.13 to 1% of all cases of acute appendicitis (1,2).

In 1731, French surgeon Garengeot reported the first case of acute appendicitis in the right femoral hernia, and 5 years later Claudius Amyand reported the first case of acute appendicitis in a right inguinal hernia sac (3,4). In 1969, Wakeley, in a series of 655 cases of femoral hernias operated, reported an incidence of 1% herniated Garengeot (5), and Ryan, in 1937 reported 11 cases of acute appendicitis in the femoral hernia sac, from a total of 8692 appendicectomies (0.13%) (6).

In 1962, Kia-Nouri, in a review of reported cases of DeGarengeot hernia, collected a total of 233 such cases, but added that some of them showed signs of acute appendicitis, although the cecal appendix was in the right femoral hernia (7). De Garengeot hernias were thus statistically occupying an estimated 0.5 to 3.3% of the total femoral hernias (8). Cases of acute appendicitis in a hernia sac were reported as external and umbilical hernias (9), obturator hernias (10) or incisional hernias (11).

Case report

We present the case of a patient aged 76 years, from the rural area, which presented to the Surgery Ward Emergency Room for pain in the right femoral inguinal area, which had started about 24 hours before and had increased progressively. Clinical examination revealed the presence of a pseudo-tumour formation, round, about 7-8 cm in diameter, under the crural arch painful to palpation and irreducible by taxis.

Intestinal transit was slowed for bowel gas and faeces. The abdomen was normal, presenting respiratory movements, without signs of peritoneal irritation and painless on palpation. All signs and symptoms of the patient direct us towards the diagnosis of incarcerated right femoral hernia, which is the admission diagnosis. Plain abdominal radiography revealed no air-water levels. After considering the possibilities, emergency surgery herniorraphy was decided for as a course of treatment. An inguinal-femoral approach was chosen, by cutting length of 2-3 cm of the femoral arch. The presence of a femoral hernia sac was detected, which was opened after thorough dissection and hemostasis at which point we found the presence of the cecal appendix in the hernia sac (Fig. 1, 2).

This presented signs of acute inflammation. Retrograde appendectomy was performed, followed by tension free herniorraphy and mesoplasty, by Hartman-Quenu procedure. We administered adjuvant broad spectrum antibiotics (Ceftamril - 3 g / day) for 3 days postoperatively. The result of the histopathological exam was highly suggestive for the diagnosis of acute appendicitis. Postoperative evolution was favorable

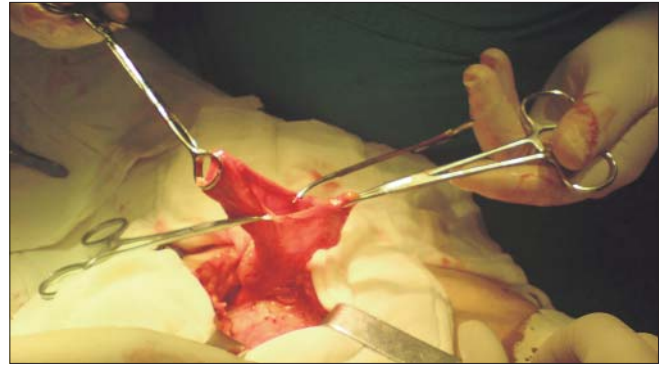


Figure 1. Observe the hernia sac under the crural arch

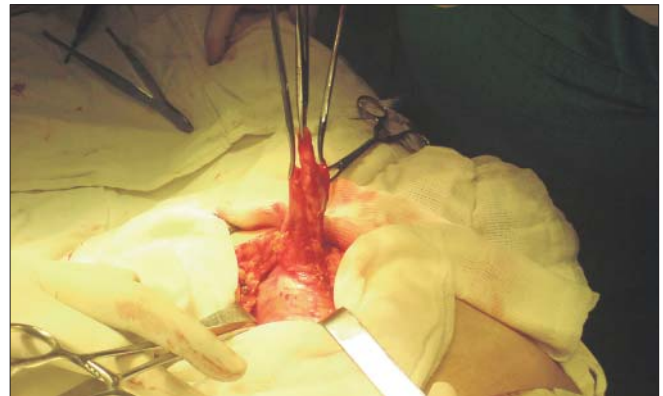


Figure 2. We notice the presence of the cecal appendix in the femoral hernia sac

with no complications, and the patient was discharged 7 days after surgery.

Discussion

The presence of femoral hernia is more common in post-menopausal women (12,13), while in the case of males inguinal hernias predominate, aged 6 weeks to 88 years (14,15). The diagnosis is always confirmed intraoperatively, one author reporting however a case diagnosed prior to surgical exploration (16). Radiological and laboratory findings are usually non-specific.

In terms of pathophysiology, the primary factor is not known yet. Whether inflammation occurs first and then the cecal appendix migrates in the hernia sac, or migration of the cecal appendix in a hernia sac occurs first and afterwards it swells in time is unknown. The second option seems more plausible however, and in order for it to migrate into the hernia sac the appendix must fulfil some anatomical conditions (cecal sac located below the mesoappendix, long appendix etc.) (2,12,17).

The De Garengeot hernia cases reported over time show that these hernias are usually incarcerated and present presenting signs of localized peritonitis. The advantage of these hernias is that due to strangulation of the hernia sac, the formation is not allowed to extend into the peritoneal cavity,

and the peritonitis remains localized mostly in the hernia sac (1,18).

Zuckerkindl first described another variety of this pathology in 1981, namely the presence of pus in the hernia sac, without a vermiform appendix bag being present and then observing that the pus came from the cecal appendix (19). In 2007, Suppiah described for the first time the presence of a femoral hernia sac of villous adenoma of the appendix (20), which is an extremely rare tumours of the gastrointestinal tract. In terms of the inflammatory process that triggers the appendicitis, over time many etiologies have been reported, the rarest of them being actinomycotic infections, *Salmonella enterica* or *Schistosomiasis* (21,22,23). The diagnosis can be suspected based on intense pain of a hernia sac, and can be associated with leucocytosis, fever or vomiting. Differential diagnosis in these cases is conducted with incarcerated epiplocele and Richter hernia, based on the characteristics of the pain. Exploratory laparoscopy can be a good technique for the diagnosis of these cases, but due to difficulties in preoperative diagnosis and often a false diagnosis of incarcerated or strangled femoral hernia, it is unlikely that this method be used in such cases. Furthermore, some authors argue that the use of these techniques can lead to extension of the peritonitis from the Garengot hernia sac to the entire peritoneal cavity (24).

We have to take into account that some cases of acute appendicitis occur in other diseases, mostly due to weaker immunity, diseases such as Henoch-Schonlein purpura, lymphangiomas, some forms of leukaemia, intestinal tuberculosis, the presence of tubular carcinosis or endometriosis in women, after injury, and again after the colonoscopic application of clips or celioscopic surgery (25,26,27,28,29, 30, 31,32,33). All of these pathologies are possible trigger an acute appendicitis or hernia sac, making careful examination necessary in any patient, as the surgeon is not to be misled by the "mirage of the first injury".

In recent years, the progress of medical imaging has led to the possibility of using CT scan for determining the diagnosis, it being practically the only imaging possibility in these cases. Some authors reported in the literature cases of herniated De Garengot explored through abdominal CT in which there was presence of air bubbles in the hernia sac, indicating involvement of intestinal loops, but no obstruction or dilatation of the small intestine (34,35,36,37).

Although there were few cases in which CT could provide certainty preoperative diagnosis, it remains however the best way to distinguish between Amyand and De Garengot hernias and other incarcerated hernias, the presence of air in the hernia sac being the defining sign in these cases. There is indication for major abdominal CT scan when attached femoral hernia is present and signs of peritoneal or abdominal irritation (38). We have not used this method of diagnosis, although it was available, because we were convinced of the preoperative diagnosis.

It is the first case of this type of acute appendicitis encountered in our clinic in the last 20 years, given that the average number per year of appendectomies lies around 600-

700. This is one more reason to point out the usefulness of abdominal CT scan in these cases. The treatment usually consists of appendectomy in the hernia sac. In complicated cases, especially those with signs of generalized peritonitis, median laparotomy is required, followed by appendectomy and surgical cure of the abdominal hernia. Laparoscopic approach for De Garengot hernia and other incarcerated hernias is still controversial. In these cases, multiple cavity drainage is necessary. Antibiotic therapy is necessary in all cases where there is evidence of peritoneal irritation, either localized or generalized, the presence of fluid or pus freely modified, and may be optional in cases of acute appendicitis diffusion. In uncomplicated cases, drainage is not required (2,39,40). Where sepsis and old age are associated the mortality rate was reported as 15-30% (41). Some authors reject the idea of using synthetic mesh in cases presenting with signs of acute appendicitis (39). Recent studies support the consensus that: if there are no signs of perforation or abscess for the appendicitis, the use of synthetic mesh is free of any risks (13,40), Nguyen and Komenaka stressing that the main factor contributing to the increased incidence of infection is a delay in diagnosis (39). Thus, many authors consider that the ideal solution is therapeutic appendectomy followed by herniorrhaphy (42).

Conclusions

The combination of strangled or imprisoned femoral hernia and acute appendicitis is a rare pathology, especially in older women, discovered intraoperatively. It supports intraoperative diagnosis, but CT can be a diagnostic method, if used in these cases. Treatment includes appendectomy and herniorrhaphy, the use of synthetic mesh remaining however controversial. If the patient presents on time to the doctor and is submitted to surgery immediately, treatment is simple and the prognosis favourable. If surgery is delayed for various reasons, septic complications appear in these cases and 30% lead to morbidity. And last but not least, we must consider that every acute appendicitis may be the echo of another disease, therefore patients should be carefully explored, even during surgery.

References

1. Voitek AJ, McFarlane JK, Estrada RL. Ruptured appendicitis in femoral hernias: report of two cases and review of the literature. *Ann Surg*. 1974;179(1):24-6.
2. Kiyoko E, Shintaro Y, Yuki K, Mitsuhiro K, Katsumi K, Seigo Y, et al. Acute Appendicitis in an Incarcerated Femoral Hernia: A Case of De Garengot Hernia. *Case Rep Gastroenterol*. 2009; 3(3):313-317.
3. Garland EA. Femoral appendicitis. *J Indiana State Med Assoc*. 1955;48(11):1292-4.
4. Suliman E, Popa D, Palade R, Simion G. Amyand's hernia - case presentation and a discussion about diagnosis problems and surgical treatment. *Chirurgia (Bucur)*. 2012;107(3):393-6.
5. Wakeley CPG. Hernia of the vermiform appendix. In: Maingot R, ed. *Abdominal operations*. New York: Appleton-Century-Crofts; 1969. pag. 1288.
6. Ryan WJ. Hernia of the vermiform appendix. *Ann Surg* 1937;

- 106:135-9.
7. Kia-Nouri M. Isolated incarcerated appendix in a femoral hernia. Review of the literature and report of a case. *J Albert Einstein Med Cent (Phila)*. 1962;10:38-9.
8. Tanner N. Strangulated femoral hernia appendix with perforated sigmoid diverticulitis. *Proc R Soc Med*. 1963;56:1105-6.
9. Doig CM. Appendicitis in umbilical hernial sac. *Br Med J* 1970;(ii):113-114.
10. Camerlinck M, Vanhoenacker F, De Vuyst D, Quanten I. Appendicitis in an obturator hernia. *Abdom Imaging*. 2011;36(2):170-3.
11. Carey LC. Acute appendicitis occurring in hernias: a report of 10 cases. *Surgery*. 1967;61(2):236-8.
12. Rebai W, Hentati H, Makni A, Ksontini R, Chebbi F, Ftiriche F, et al. Appendicitis in strangulated femoral hernia: a case report. *Tunis Med*. 2010;88(3):193-5.
13. Khatib CM. Strangulated femoral hernia containing acute gangrenous appendicitis: case report and review of the literature. *Can J Surg* 1987;30(1):50.
14. Burger TO, Torbert NC. The diagnosis of acute hernial appendicitis. *Am J Surg* 1938; 42:429-32.
15. Thomas WE, Vowles KD, Williamson RC. Appendicitis in external herniae. *Ann R Coll Surg Engl*. 1982;64(2):121-2.
16. Powell HDW. Gangrenous appendix in femoral hernial sac. *Lancet*. 1954;267(6850):1211-2.
17. Akopian G, Alexander M. De Garengot hernia: appendicitis within a femoral hernia. *Am Surg*. 2005;71(6):526-7.
18. Wiszniewski M, Faflik M, Grabowski M. Femoral hernia with acute appendicitis in a male patient. *Wiad Lek*. 2008;61(1-3):85-7.
19. Zuckerkandl M. Hernia inflammata in Folge Typhilitis des Wormfortsatzes in einem Leistebruche. *Wiener Klinische Wochenschrift* 1981; 4:305.
20. Suppiah A, Barandiaran J, Morgan R, Perry EP. First case of villous adenoma of the appendix leading to acute appendicitis presenting as strangulated femoral hernia: changes in management owing to concurrent adenoma. *Hernia*. 2008;12(1):95-8.
21. Oztürk A, Kaya C, Faruk Akinci O, Uçmaklı E. A rare but important cause for appendicitis: actinomyces. *Am Surg* 2010; 76(7):88-90.
22. Bartoli F, Guerra A, Dolina M, Bianchetti MG. Salmonella enterica serovar Israel causing perforating appendicitis. *Int J Infect Dis*. 2010;14(6):e538.
23. Señuque Artini M, López De Cenarruzabeitia I, Rodríguez Conde N, Landolfi S, Armengol Carrasco M. Schistosomiasis as a cause of acute appendicitis. *Cir Esp*. 2009;85(6):387-9. Spanish
24. Comman A, Gaetschmann P, Hanner T, Behrend M. De Garengot hernia: transabdominal preperitoneal hernia repair and appendectomy. *JSLs*. 2007;11(4):496-501.
25. Jasić M, Subat-Dezulović M, Nikolić H, Jonjić N, Manestar K, Dezulović M. Henoch-Schönlein purpura complicated by appendicitis, intussusception and ureteritis. *Coll Antropol* 2011;35(1):197-201.
26. Karaca G, Koçak E, Pekici R, Güler O, Köklü SA. A rare cause of acute appendicitis: cystic lymphangioma. *Am Surg*. 2010;76(9):E150-1.
27. Bercu TE, Rubin ZA, Agopian VG. Tuberculous appendicitis. *Am J Med* 2011;124(2):9-10.
28. Papageorgiou SG, Foukas P, Economopoulou C, Tsirigotis P, Sakorafas G, Georgakopoulos N, et al. Acute appendicitis in patient with acute promyelocytic leukemia. *Leuk Res* 2011; 35(1):4-5.
29. Salati SA, Raza AA. Endometriosis: a rare cause of appendicitis. *J Coll Physicians Surg Pak* 2011;21(5):304-5.
30. Atalla MA, Carangan M, Rozen WM. Acute traumatic appendicitis following blunt abdominal trauma. *ANZ J Surg*. 2010; 80(7-8):572-3.
31. Moorman ML, Miller JP, Khanduja KS, Price PD. Postcolonoscopy appendicitis. *Am Surg* 2010;76(8):892-895.
32. Hoshino I, Sugamoto Y, Fukunaga T, Imanishi S, Isozaki Y, Kimura M, et al. Appendicitis caused by an endoluminal clip. *Am J Gastroenterol* 2010;105(7):1677-8.
33. Hwang J, Telem DA, Nguyen SQ, Suarez YN, Warner RR, Divino CM. Tubular carcinoid tumor: a rare cause of appendicitis. *Am Surg*. 2009;75(6):518-519.
34. D'ambrosio N, Katz D, Hines J. Perforated appendix within a femoral hernia. *AJR Am J Roentgenol* 2006;186:906-7.
35. Ash L, Hatem S, Ramirez GA, Veniero J. Amyand's hernia: a case report of prospective CT diagnosis in the emergency department. *Emerg Radiol*. 2005;11(4):231-2.
36. Zissin R, Brautbar O, Shapiro-Feinberg M. CT diagnosis of acute appendicitis in a femoral hernia. *Br J Radiol*. 2000; 73(873):1013-4.
37. Luchs JS, Halpern D, Katz DS. Amyand's hernia: prospective CT diagnosis. *J Comput Assist Tomogr*. 2000;24(6):884-6.
38. Hsiao TF, Chou YH. Appendiceal pus in a hernia sac simulating strangulated femoral hernia: a case report. *Int J Gen Med*. 2011; 4:235-7.
39. Nguyen ET, Komenaka IK. Strangulated femoral hernia containing a perforated appendix. *Can J Surg*. 2004;47(1):68-9.
40. Nicolau AE. Laparoscopic appendectomy. *Chirurgia (Bucur)*. 2011;106(4):495-503. Romanian
41. Gray HT. Lesions of the isolated appendix vermiformis in the hernial sac. *Br Med J* 1910;(ii):1142-1145.
42. Armstrong O. Appendix strangulated in a femoral hernia. *Hernia*. 2010;14(2):225-226.