

VENTRICULAR ARRHYTHMIA OR SUPRAVENTRICULAR ARRHYTHMIA WITH ABERRANT CONDUCTION? AN ELECTROCARDIOGRAPHIC STUDY IN HALOTHANE-ANAESTHETIZED CHILDREN UNDERGOING ADENOIDECTOMY

G. H. SIGURDSSON, O. WERNER AND T. FAHRÆUS

SUMMARY

The electrocardiograph (ECG) was recorded continuously in 20 children undergoing adenoidectomy during halothane anaesthesia. Five surface ECG leads and an oesophageal lead were used. In 11 children, there were QRS complexes which had a shape distinctly different from that of the ordinary sinus-evoked beats. Except in one child, these anomalous QRS complexes first made their appearance during surgery, although the arrhythmia continued until 0–1 min after adenoidectomy in some children. The severity ranged from that of occasional anomalous QRS complexes with uniform shape to that of a fast irregular rhythm with a variety of QRS shapes. Although the anomalous QRS complexes were premature, P waves and P–P intervals were unchanged. In some children, there appeared to be ventricular capture beats and fusion beats. Because of this, and in view of evidence gathered from studies in animals, by other authors, we considered it likely that the anomalous beats were ventricular in origin.

Anomalous QRS complexes appear commonly during oral surgery (Kaufman, 1966; Ryder, 1971) particularly in association with halothane anaesthesia. Several authors have suggested that such complexes are usually aberrantly conducted supra-ventricular impulses (Alexander, 1971; Alexander, Bekheit and Fletcher, 1972; Alexander and Murtagh, 1979; Lindgren, 1981).

It has been shown in several animal studies (Hashimoto and Hashimoto, 1972a, b; Zink, Sasyniuk and Dresel, 1975) that halothane sensitizes the heart to the effects of catecholamines, so that the occurrence of ventricular arrhythmia increases. These findings are consistent with the observation by Lindgren (1981) that anomalous QRS complexes are more common during surgery than during undisturbed anaesthesia. However, the animal studies are difficult to reconcile with the notion that anomalous QRS complexes occurring in patients anaesthetized with halothane are usually aberrantly conducted supra-ventricular beats, rather than manifestations of ventricular excitability.

Although we have shown previously (Sigurdsson et al., 1983) that anomalous QRS complexes are common, and occur in 41% of children undergoing

adenoidectomy during halothane anaesthesia, only one surface ECG lead was used in that study. This made the definitive interpretation of the arrhythmia uncertain, since the differentiation between supra-ventricular and ventricular arrhythmia often rests on an accurate identification of atrial electric activity. To gather further information regarding the nature of arrhythmias arising during halothane anaesthesia, we have recorded continuously five surface ECG leads and one oesophageal lead in children undergoing adenoidectomy.

PATIENTS AND METHODS

Patients

Twenty children were studied. They underwent adenoidectomy on a day-stay basis, were not treated with sympathomimetic drugs and were in good general and cardiac health. Otherwise, no selection of the children was made. They were premedicated 20–30 min before anaesthesia with diazepam 5 mg rectally and atropine 0.3–0.4 mg sublingually.

Anaesthesia

Anaesthesia was induced with 75% nitrous oxide in oxygen via a Mapleson D circuit (fresh gas flow 300 ml kg⁻¹ min⁻¹). The nitrous oxide concentration was decreased to 50% and halothane added when the child became drowsy. Five surface ECG leads (V₁,

GISLI H. SIGURDSSON, M.D.; OLOF WERNER, M.D., Department of Anaesthesia, University Hospital, S-221 85 Lund, Sweden. THOMAS FAHRÆUS, M.D., Department of Cardiology, University Hospital, S-581 85 Linköping, Sweden.

V₃, V₆, aVL, aVF) were placed once the child no longer reacted to touch and the ECG was recorded continuously (Mingograph 81 (Siemens-Eléma)). The inspired halothane concentration was maintained at 2.5–3% for 3–5 min, with the child breathing spontaneously via a face-mask, after which an oesophageal unipolar electrode was inserted with the help of a Macintosh laryngoscope. The electrode consisted of a 60-cm isolated cable, diameter 1.5 mm, and a cylindrical silver tip coated with silver chloride, 3 mm long and 2 mm in diameter. The tip was placed so that the P wave was maximal. The child continued to breathe 2.5–3% halothane in nitrous oxide and oxygen until the depth of anaesthesia was judged adequate for adenoidectomy. The head was then tilted downwards, a mouth gag inserted and adenoidectomy performed with the child breathing air. At the end of surgery, the mouth gag was removed and 100% oxygen supplied by mask. The ECG recording was discontinued about 2 min after the end of surgery.

Terminology

The terms *anomalous QRS complexes* or *anomalous beats* (Bellet, 1972) are used to describe beats where the QRS complex was widened and its shape distinct from that of normally conducted sinus beats. *A–V dissociation* is an independent action of atria and ventricles, each beating in response to its own pacemaker. The P waves and the QRS complexes have no relation to each other. This condition may arise, for example, during A–V nodal or ventricular tachycardia. *Aberrant conduction* is used here to describe a functional bundle branch block, where one or more of the bundle branches were refractory when a supraventricular impulse arrived. The shape of the QRS complex became widened and often resembled that of a ventricular ectopic beat. *Ventricular fusion beat* describes a simultaneous stimulation of the ventricles by a supraventricular impulse and an ectopic ventricular impulse. The shape of the QRS complex will be an intermediate between the shape of a normal QRS complex and that of an ectopic ventricular impulse. This constitutes one of the best diagnostic criteria for the establishment of ventricular ectopic origin (Schamroth, 1980). *Ventricular capture beat*: in the presence of A–V dissociation, for example during ventricular tachycardia, an atrial impulse which occurs during the non-refractory period of both the A–V node and the bundle branches results in a normally conducted QRS complex (the atrial impulse “captures” the

ventricles). However, during A–V nodal tachycardia with aberrant conduction, a capturing impulse will also be conducted with aberration, since it is even more premature than the impulses of the basic A–V nodal tachycardia. Thus, a normally conducted capture beat constitutes strong evidence for ventricular rhythm.

Sinus tachycardia and sinus bradycardia were not considered as arrhythmias in this study.

Statistics

The two-sided *t* test for paired data was used.

RESULTS

Mean age was 6.3 yr (range 3–12 yr). The ECG was recorded from 7 ± 4 min (mean \pm 1 SD) before the mouth gag was inserted. This was held in place for 3 ± 1 min, after which the ECG recording continued for another 2.1 ± 0.7 min.

Eighteen children had a normal sinus rhythm during undisturbed anaesthesia, immediately after connecting the surface ECG leads. The heart rate was 102 ± 19 beat min^{-1} . The other two had an A–V nodal rhythm (also called A–V junctional by many authors), as diagnosed by normally shaped QRS complexes and P waves which were either absent, or else abnormally shaped and occurring close to or after the QRS complex. Seven other children developed A–V nodal rhythm at a later stage, either before (six) or during adenoidectomy (one). The heart rate at the onset of A–V nodal rhythm was 96 ± 17 beat min^{-1} . One child had an arrhythmia with variable P waves but normal P–R intervals before surgery. This was interpreted as an ectopic atrial rhythm. Five of the children with A–V nodal rhythm also had episodes with anomalously shaped QRS complexes during surgery, but the two types of arrhythmia were never seen in immediate temporal relation to one another.

In six children, QRS complexes with an anomalous but uniform shape were seen. In three of these children there were only single anomalous QRS complexes, while they occurred both singly and in pairs in one, and both singly and in bigeminy, alternating with sinus beats, in two children. A common observation in all six children was that the P–P intervals and the shape of the P waves were unchanged. The anomalous QRS complexes were preceded by shortened P–R intervals, sometimes to the extent that the QRS complex and the P wave coalesced (fig. 1).

In two children, anomalous QRS complexes of

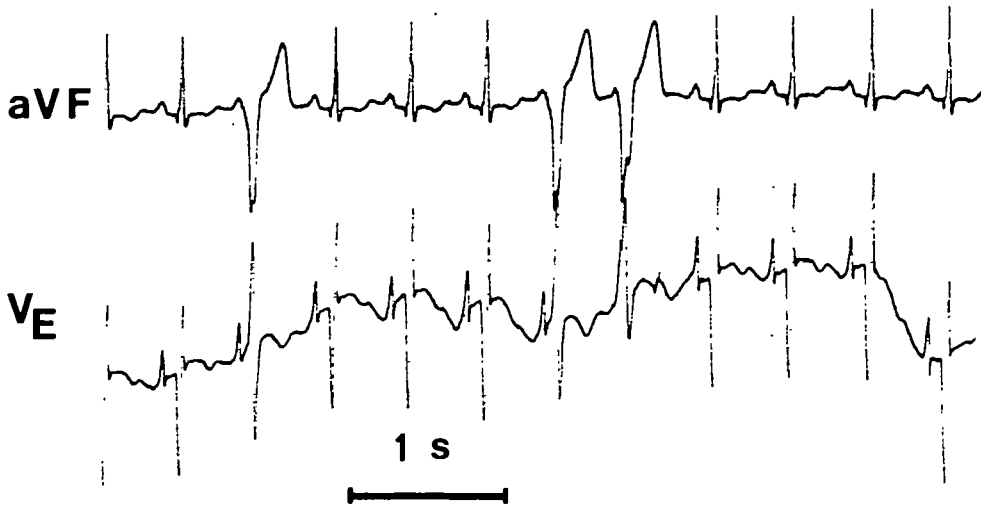


FIG. 1. Boy, 5 yr. Recording during surgery. V_E is the oesophageal lead.

more than one shape were observed, both single and in bigeminy. The shape of, and intervals between, the P waves were apparently unchanged (fig. 2). In another child, sequences of up to four consecutive anomalously shaped QRS complexes were seen during adenoidectomy. The oesophageal lead was displaced in this child. Therefore, it was difficult to locate the P waves.

In one child, a very irregular rhythm with linked multiform QRS complexes and varying R-R intervals at a rate of 160–170 beat min^{-1} was observed. The arrhythmia started 20 s after insertion of the mouth gag, continued throughout surgery (3 min),

but was replaced by sinus rhythm 30 s after removal of the mouth gag. While a variety of QRS shapes were seen, P waves and P-P intervals appeared unaffected (fig. 3). Several QRS complexes had the appearance of capture beats, that is beats with a normal QRS configuration interrupting the sequence of anomalous beats, or ventricular fusion beats. A similar arrhythmia started 3 min after insertion of the mouth gag in another child and continued for 90 s, until about 60 s after removal of the mouth gag (fig. 4). Sinus rhythm at a rate of 140 beat min^{-1} was present just before the onset of the arrhythmia.

Anomalously shaped QRS complexes were thus

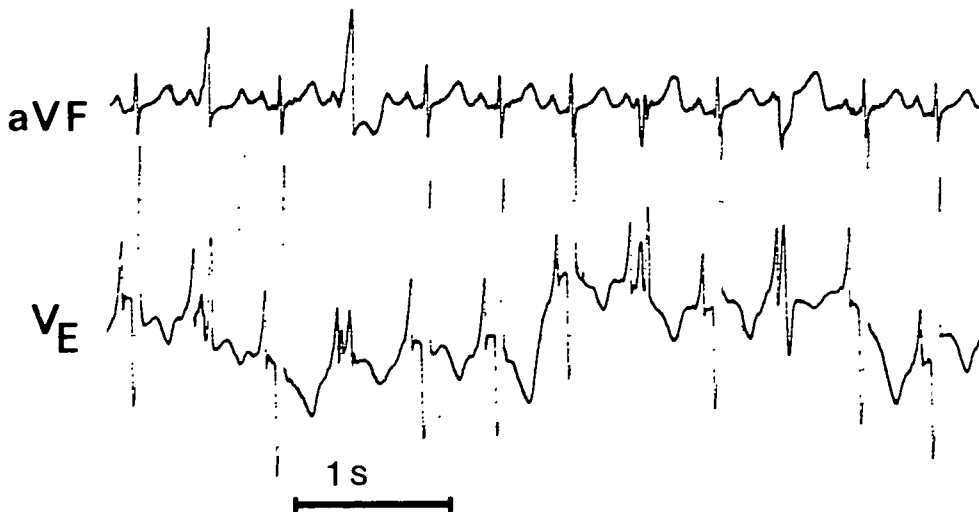


FIG. 2. Boy, 6 yr. Recording during surgery.

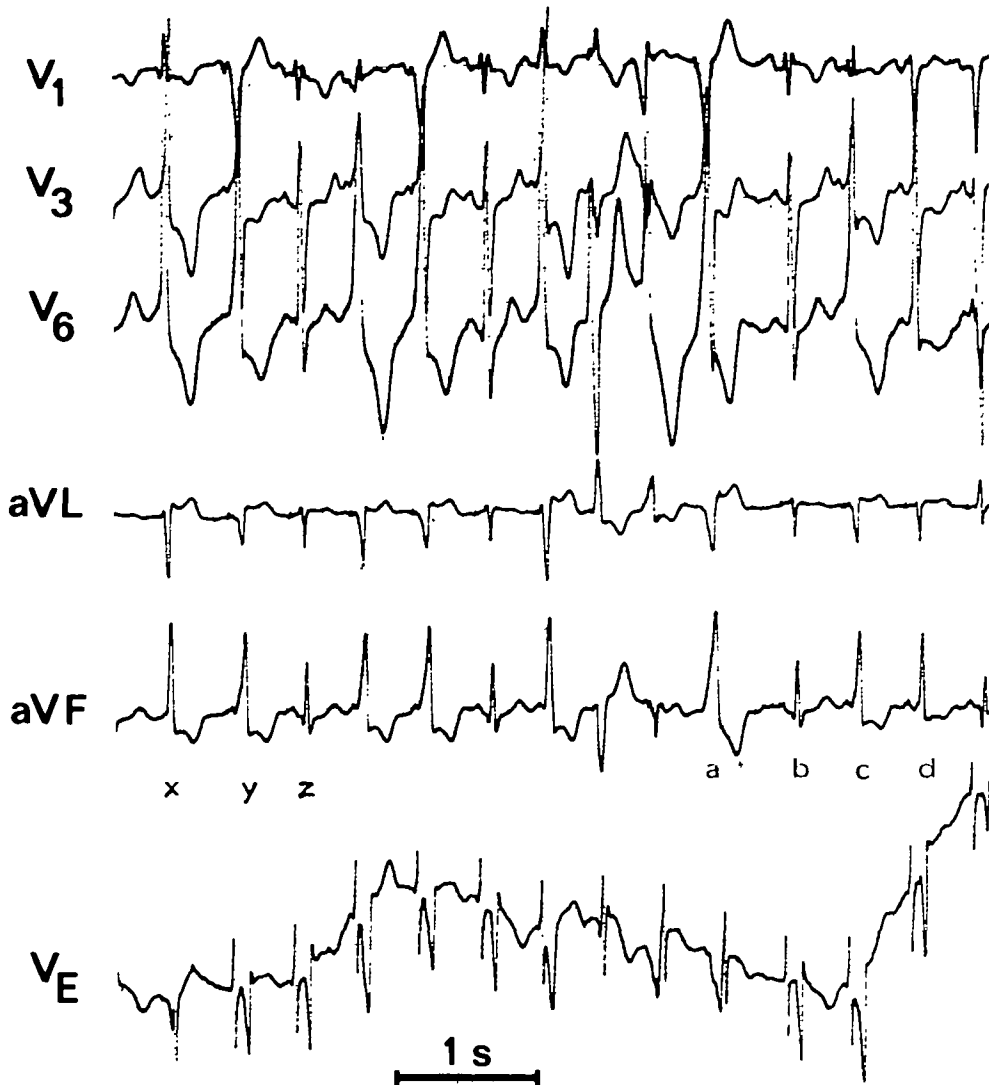


FIG. 3. Girl, 7 yr. Recording during surgery. A number of beats have been indicated by letters. b was regarded as a sinus-evoked beat with normal intraventricular conduction. d and c may be fusion beats. The P wave falls inside the QRS complex of beat a, which has a shape quite different from that of beat b. Beat a is thus probably a ventricular ectopic beat. Beat z has a normal QRS configuration (like beat b), while beats x and y are anomalously shaped. The distance between y and z is shorter than that between x and y. This makes it improbable that y is a supraventricular beat with aberrant conduction. In that case the impulse resulting in beat z would also have been aberrantly conducted, since the impulse would enter a conducting system, which had had even less time to recover from the preceding beat. Thus z must be a ventricular capture beat, the presence of which constitutes strong evidence that an arrhythmia is ventricular (Schamroth, 1980).

seen in 11 children (table I). The heart rate was 133 ± 17 beat min^{-1} when the anomalous beats first occurred, compared with 102 ± 16 beat min^{-1} at the start of the ECG recording in these children ($P < 0.001$). In one child, anomalous QRS complexes had appeared by the time the oesophageal elec-

trode was introduced. They reappeared during surgery. In the remaining 10 children, the mouth gag was in place at the onset of arrhythmia, although it sometimes ended only after the mouth gag was removed.

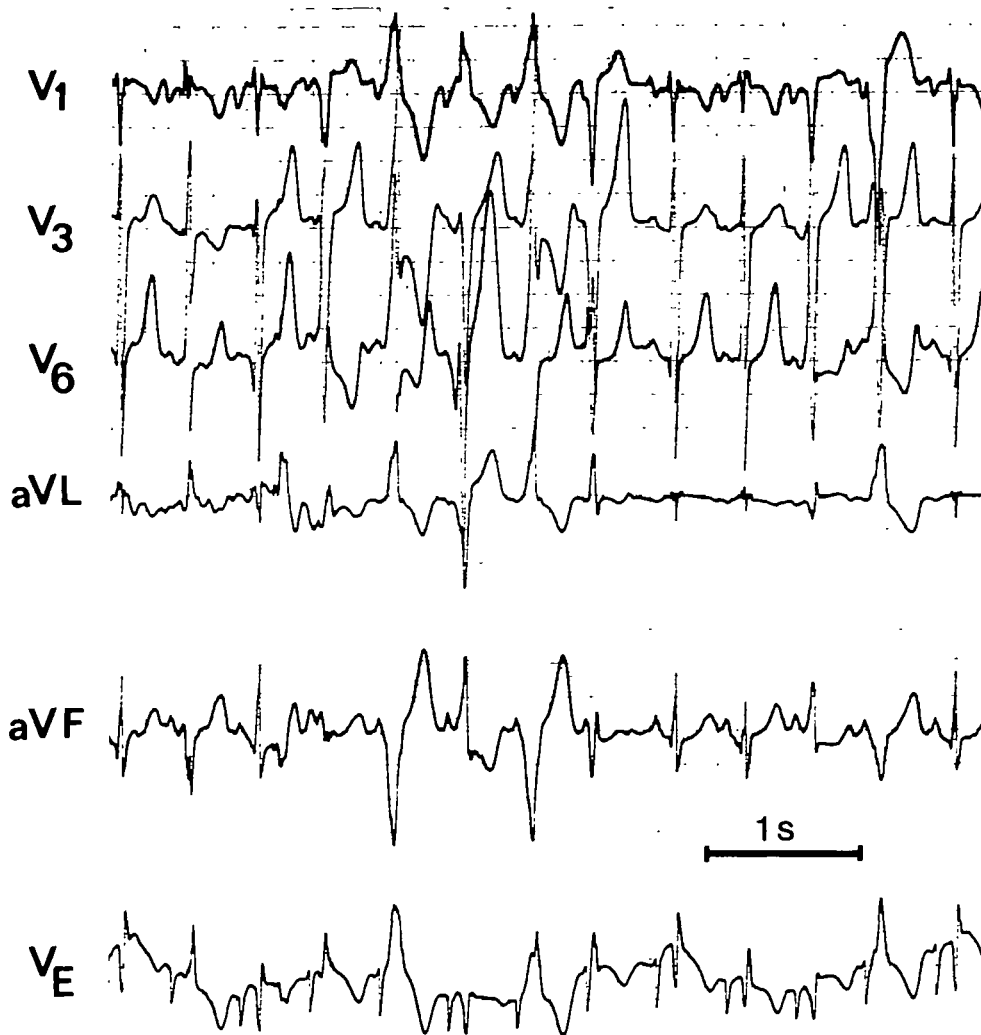


FIG. 4. Boy, 9 yr. Recording during surgery.

DISCUSSION

In our ECG recordings, P waves and P-P intervals remained unchanged when the regular sequence of QRS complexes was disturbed by the appearance of anomalous beats. Also, anomalous QRS complexes occurring, in isolation, in pairs, or in bigeminy were invariably premature, so that the P-R interval was shortened or the P wave even merged with the QRS. In the two children who developed a very irregular rhythm with runs of multiform QRS complexes, the arrhythmia started with a premature anomalous QRS complex. Therefore, it is improbable that there was an atrial focus for the anomalous beats in any of the patients.

One possible explanation for the present findings is that the anomalous beats were caused by aberrant conduction of impulses arising in the A-V junction, as proposed by Alexander and Murtagh (1979). However, as the shape of the P waves was unchanged, such an interpretation would require the additional assumption that retrograde A-V conduction to the atria was always blocked. In the two children with a very irregular rhythm (figs 3 and 4) there appeared to be occasional complete ventricular capture beats. Also, there seemed to be several fusion beats (fig. 3). These findings are difficult to reconcile with the hypothesis that the arrhythmia originated in the A-V junction. Furthermore, the

TABLE I. *Electrocardiographic findings in 20 children undergoing adenoidectomy. *Onset before surgery, except in one child. Five of these children also had ventricular arrhythmia during surgery. **Onset during surgery, except in one child. Most severe arrhythmia in each patient stated*

Observation	Number
Sinus rhythm throughout	4
Normal QRS configuration	
Ectopic atrial rhythm	1
A-V nodal rhythm	9
Total	10*
Anomalous QRS configuration	
Isolated, uniform	3
Uniform, in bigeminy	2
Uniform, in pairs	1
Varying shape in bigeminy	2
Up to four consecutive anomalous beats with a varying shape	1
Very irregular rhythm	2
Total	11**

hypothesis would not be consistent with experiments in halothane-anaesthetized dogs by Zink, Sasyniuk and Dresel (1975). They induced premature anomalous QRS complexes in bigeminy, by infusing adrenaline i.v. while pacing the atria electrically at a rate of 150–170 beat min^{-1} . The anomalous QRS complexes disappeared in most dogs when the atria were paced at very rapid rates. This would hardly have happened if the anomalous beats had an atrial or A-V junctional focus conducted with aberration. Smith and Dresel (1982) used a similar technique for provoking anomalous beats during halothane anaesthesia in dogs. By the use of intracardiac electrodes they concluded that the anomalous beats arose in the interventricular septum. In view of these findings, we believe that the arrhythmias with anomalous beats in our patients were also ventricular. One mechanism behind the ventricular arrhythmias may be re-entry, as proposed by Zink, Sasyniuk and Dresel (1975). The fact that halothane slows conduction in Purkinje fibres (Atlee and Alexander, 1977) may contribute to a re-entry phenomenon.

There is a certain parallelism between the results of Zink, Sasyniuk and Dresel (1975) and the findings in the present study. First, the anomalous QRS complexes usually appeared for the first time during surgery. The increased sympathetic discharge at

this stage may have cardiac effects, similar to those of an infusion of adrenaline. Second, sinus tachycardia was present when the arrhythmia started, while Zink and co-authors (1975) could make premature anomalous beats appear by inducing a moderately increased heart rate through electric pacing of the atria. Alexander and Murtagh (1979) and Lindgren (1981) also found that anomalous beats were more common during surgery than during undisturbed anaesthesia, although these authors concluded that the anomalous beats were usually caused by impulses arising supraventricularly but with aberrant intraventricular conduction. However, Lindgren (1981) only studied one ECG lead, and this may have precluded the precise interpretation of the arrhythmias. Therefore, ECG recordings which she suggests show aberrant intraventricular conduction (for example figures 3 and 4 of her study) might also be interpreted as ventricular arrhythmia. Alexander and Murtagh (1979) used three surface ECG leads. Although they concluded that many of their patients had supraventricular arrhythmia with bundle branch block, the recordings which they reproduced do not exclude the possibility of ventricular arrhythmia. These comments should not be taken to imply that a firm diagnosis of intermittent bundle branch block during anaesthesia cannot be made from surface ECG leads only. One example to the contrary is given by Edelman and Hurlbert (1980). Another instance, where anomalous QRS complexes might have been caused by aberrant conduction, is provided by figure 2 in the paper by Alexander, Bekheit and Fletcher (1972). However, an alternative diagnosis of ventricular tachycardia with retrograde A-V conduction cannot be ruled out in this particular case.

We conclude that the anomalous beats of the present study (table I) were most probably manifestations of ventricular arrhythmia. The frequent occurrence of these beats is consistent with previous electrocardiographic findings in 46 additional children undergoing adenoidectomy, with the same anaesthetic technique (Sigurdsson et al., 1983). In our hospital this used to be the most common method of anaesthesia for adenoidectomy. Although all our patients have had an uneventful recovery, we find the frequent occurrence of ventricular arrhythmias disturbing. Since it has been shown recently that the occurrence of arrhythmia is much less frequent in children after tracheal intubation (Sigurdsson and Lindahl, 1983), we prefer to intubate the trachea during adenoidectomy.

ACKNOWLEDGEMENTS

The study was supported by grants from the Medical Faculty, University of Lund. We thank Gert-Inge Jönsson, mechanical engineer, for making the oesophageal electrode.

REFERENCES

- Alexander, J. P. (1971). Dysrhythmia and oral surgery. *Br. J. Anaesth.*, **43**, 773.
- Bekheit, S., and Fletcher, E. (1972). Dysrhythmia and oral surgery. II: Junctional rhythms. *Br. J. Anaesth.*, **44**, 1179.
- Murtagh, J. G. (1979). Arrhythmia during oral surgery: fascicular blocks in the cardiac conducting system. *Br. J. Anaesth.*, **51**, 149.
- Atlee, J. L., and Alexander, S. C. (1977). Halothane effects on conductivity of the AV node and His-Purkinje system in the dog. *Anesth. Analg.*, **56**, 378.
- Bellet, S. (1972). *Essentials of Cardiac Arrhythmias. Diagnosis and Management*. Philadelphia, London, Toronto: W. B. Saunders Company.
- Edelman, J. D., and Hurlbert, B. J. (1980). Intermittent left bundle branch block during anesthesia. *Anesth. Analg.*, **59**, 628.
- Hashimoto, K., and Hashimoto, K. (1972a). Cardiac irregularities induced by intracoronary injection of epinephrine and acetylcholine into various portions of the canine ventricle. *Am. Heart J.*, **83**, 197.
- (1972b). The mechanism of sensitization of the ventricle to epinephrine by halothane. *Am. Heart J.*, **83**, 652.
- Kaufman, L. (1966). Unforeseen complications encountered during dental anaesthesia: cardiac arrhythmias during dental anaesthesia. *Proc. R. Soc. Med.*, **59**, 731.
- Lindgren, L. (1981). ECG changes during halothane and enflurane anaesthesia for ENT surgery in children. *Br. J. Anaesth.*, **53**, 653.
- Ryder, W. (1971). Cardiac rhythm during dental anaesthesia. *Proc. R. Soc. Med.*, **64**, 82.
- Schamroth, L. (1980). *The Disorders of Cardiac Rhythm*. Oxford: Blackwell Scientific Publications.
- Sigurdsson, G. H., Carlsson, C., Lindahl, S., and Werner, O. (1983). Cardiac arrhythmias in non-intubated children during adenoïdectomy. A comparison between enflurane and halothane anaesthesia. *Acta Anaesthesiol. Scand.*, **27**, 75.
- Lindahl, S. (1983). Cardiac arrhythmias in intubated children during adenoïdectomy. A comparison between enflurane and halothane anaesthesia. *Acta Anaesthesiol. Scand.*, (in press).
- Smith, E. R., and Dresel, P. E. (1982). Site of origin of halothane-epinephrine arrhythmia determined by direct and echocardiographic recordings. *Anesthesiology*, **57**, 98.
- Zink, J., Sasyniuk, B. I., and Dresel, P. E. (1975). Halothane-epinephrine-induced cardiac arrhythmias and the role of heart rate. *Anesthesiology*, **43**, 548.

ARYTHMIE VENTRICULAIRE OU ARYTHMIE
SUPRAVENTRICULAIRE AVEC CONDUCTION
ABERRANTE? UNE ETUDE
ELECTROCARDIOGRAPHIQUE CHEZ DES
ENFANTS ENDORMIS A L'HALOTHANE
POUR UNE ADENOÏDECTOMIE

RESUME

Un électrocardiogramme (ECG) a été enregistré en continu chez 20 enfants subissant une adenoïdectomie sous anesthésie à l'halothane. Cinq électrodes ECG de surface et une électrode oesophagienne ont été utilisées. Chez 11 enfants, certains complexes QRS avaient une forme nettement différente de celle observée sur les complexes provoqués normalement par le noeud sinusal. Chez tous ces enfants sauf un, ces complexes QRS anormaux ont fait leur première apparition au cours de la chirurgie, bien que l'arythmie se soit poursuivie jusqu'à 10 min après l'adenoïdectomie chez certains enfants. Leur gravité allait de quelques complexes QRS anormaux occasionnels et uniformes à une tachyarythmie à complexes QRS polymorphes. Bien que les complexes QRS anormaux soient prématurés, les ondes P et les intervalles P-P n'étaient pas modifiés. Chez quelques enfants, il semblait y avoir des battements de capture ventriculaire et des battements fusionnels. A cause de cela, et au vu des données recueillies à partir d'études chez l'animal par d'autres auteurs, nous avons considéré que les extra-systoles étaient d'origine ventriculaire.

VENTRIKULÄRE ARRHYTHMIE ODER
SUPRAVENTRIKULÄRE ARRHYTHMIE MIT
ABERRIERENDER FORTLEITUNG?
EINE ELEKTROKARDIOGRAPHISCHE
STUDIE BEI KINDERN MIT
HALOTHANNARKOSE ZUR ADENOÏDEKTOMIE

ZUSAMMENFASSUNG

Bei 20 Kindern wurde während Halothannarkose zur Adenoïdektomie ein kontinuierliches EKG aufgezeichnet, wobei fünf oberflächliche und eine ösophageale Ableitung benutzt wurden. Bei 11 Kindern kam es zu QRS-Komplexen mit deutlich anderer Form als normale sinus-evozierte Herzschläge. Bei all diesen außer einem Kind erschienen diese anomalen QRS-Komplexe erst während der Operation, bei einigen dauerten sie noch bis zu einer Minute nach der Adenoïdektomie an. Der Schweregrad reichte von gelegentlichen anomalen QRS-Komplexen mit einheitlicher Form bis zu schnellen Arrhythmien mit verschiedenartig geformten QRS-Komplexen. Obwohl die anomalen QRS-Komplexe vorzeitig einfielen, waren die P-Wellen und die Abstände zwischen zwei P-Wellen unverändert. Bei einigen Kindern schienen es ventricular capture beats und fusion beats zu sein. Aus diesem Grund und in Hinblick auf Beweise aus Tierstudien anderer Autoren hielten wir es für wahrscheinlich, daß die anomalen Schläge ventrikulären Ursprungs waren.

¿ARRITMIA VENTRICULAR O ARRITMIA
SUPRAVENTRICULAR CON CONDUCCION
ABERRANTE? UN ESTUDIO
ELECTROCARDIOGRAFICO EN NIÑOS
ANESTESIADOS CON HALOTANO Y
SOMETIDOS A ADENOIDECTOMIA

SUMARIO

Se registraron de forma continua los electrocardiogramas (ECG) de 20 niños sometidos a adenoidectomía durante la anestesia con halotano. Se utilizaron cinco hilos de superficie para ECG y uno para el esófago. En 11 de los niños se obtuvieron complejos QRS que tenían una configuración diferente de la de los pulsos sinusoidales. Con excepción de uno de los niños, estos complejos de QRS anómalos aparecieron por primera vez durante la intervención quirúrgica, aunque la arritmia continuó hasta después de transcurridos de 0 a 1 minutos de la adenoidectomía en algunos de los niños. Los casos más pronunciados oscilaron entre aquellos que aparecían ocasionalmente con una configuración uniforme y los correspondientes a un rápido ritmo irregular con una diversidad de formas. Aunque los complejos de QRS anómalos fueron prematuros, las ondas P y los intervalos P-P no cambiaron. En algunos de los niños parece que tuvieron lugar impulsos de captura ventricular e impulsos de fusión. Por estas razones y en vista de la evidencia obtenida de los estudios realizados en animales, por parte de otros autores, llegamos a la conclusión que los impulsos anómalos eran de origen ventricular.