

# Arthroscopic Autogenous Osteochondral Transplantation for Treating Knee Cartilage Defects: A 2- to 5-Year Follow-up Study

James C. Y. Chow, M.D., Michael E. Hantes, M.D., Jean Benoit Houle, M.D.,  
and Charalampos G. Zalavras, M.D.

---

**Purpose:** The purpose of this retrospective analysis was to evaluate the medium-term results of arthroscopic treatment of chondral and osteochondral lesions of the knee with autogenous osteochondral transplantation (AOT). **Type of Study:** Case series. **Methods:** Thirty-three skeletally mature patients with symptomatic, full-thickness cartilage lesions of the femoral condyles, between 1 and 2.5 cm in diameter, were treated with arthroscopic AOT. Grafts were harvested from the superior and lateral intercondylar notch and press-fit into holes drilled into the defect. All patients were evaluated both preoperatively and postoperatively with the Lysholm knee score, International Knee Documentation Committee (IKDC) Standard Evaluation Form, and knee joint radiographs. **Results:** Thirty patients of a mean age of 44.6 years were followed-up for a mean time of 45.1 months. Symptom duration ranged from 1 month to 15 years (median, 9.5 months). The mean Lysholm score significantly improved from 43.6 preoperatively to 87.5 postoperatively ( $P < .001$ ). Excellent or good outcome was accomplished in 25 of the patients (83%). Using the IKDC assessment, 26 of the patients (87%) reported their knee as being normal or nearly normal. Repeat arthroscopy with needle biopsy of the graft was performed in 9 patients. Seven of these had complete healing and 2 partial healing. The histologic examination revealed viable chondrocytes and normal hyaline cartilage in the completely healed cases. Congruency of the articular surface was restored in 11 of 12 patients (92%) who underwent magnetic resonance imaging examination. Abnormal marrow signal in the subchondral bone beneath the region of cartilage repair was present in 9 of 12 patients (75%), even 4 years after the procedure. **Conclusions:** Arthroscopic AOT is an effective and safe method of treating symptomatic full-thickness chondral defects of the femoral condyles in appropriately selected cases. However, further studies with long-term follow-up are needed to determine if the grafted area will maintain structural and functional integrity over time. **Level of Evidence:** Level IV, therapeutic, case series (no, or historical, control group). **Key Words:** Arthroscopy—Knee—Osteochondral transplantation—Cartilage defect.

---

Articular cartilage lesions constitute a common problem. Curl et al.<sup>1</sup> found that 63% of arthroscopically examined knees had cartilage lesions. In the same study,

5% of arthroscopies in patients younger than 40 years had a full-thickness cartilage defect. Treatment of chondral lesions is challenging because articular cartilage has limited capacity for regeneration and the difficulties are magnified in the case of full-thickness cartilage defects.

Nevertheless, a variety of open and arthroscopic techniques has been developed to treat chondral lesions. Techniques for regeneration stimulation, such as abrasion arthroplasty,<sup>2,3</sup> drilling,<sup>4,5</sup> and microfracture,<sup>6</sup> produce fibrocartilage instead of normal hyaline cartilage.<sup>7,8</sup> Thus, interest has focused on transplantation and grafting techniques, including osteochondral allografts,<sup>9-11</sup> autologous chondrocyte transplantation,<sup>12-14</sup> and osteochondral autografts.<sup>15-18</sup>

---

*From the Orthopaedic Center of Southern Illinois (J.C.Y.C., J.B.H.), Mt. Vernon, Illinois; the Department of Orthopaedic Surgery, Keck School of Medicine, University of Southern California (C.G.Z.), Los Angeles, California, U.S.A.; and the Department of Orthopaedic Surgery, University Hospital of Larissa (M.E.H.), Larissa, Greece.*

*Address correspondence and reprint requests to James C. Y. Chow, M.D., Orthopaedic Center of Southern Illinois, PO Box 2064, 4121 Veterans Memorial Dr, Mt. Vernon, IL 62864, U.S.A. E-mail: ocsijc@charter.net*

© 2004 by the Arthroscopy Association of North America  
0749-8063/04/2007-3569\$30.00/0  
doi:10.1016/j.arthro.2004.06.005

Autogenous osteochondral transplantation (AOT), or mosaicplasty, is a recently developed technique, in which multiple cylindrical osteochondral grafts are harvested from a weight-bearing area of lesser importance in the knee joint, and are then inserted into drilled holes at the site of the chondral defect.<sup>15-18</sup> This is a 1-stage, low-cost procedure that can be performed either arthroscopically or by open technique.

Satisfactory results have been reported from animal<sup>19</sup> and clinical studies<sup>15-18</sup> showing that the transplanted cartilage retains its hyaline characteristics. However, the experience with AOT is limited, especially for the arthroscopic technique.

We designed this study with the purpose of prospectively evaluating the efficacy and safety of arthroscopic AOT for the treatment of full-thickness cartilage defects of the femoral condyles. The present report details the medium-term results of this technique.

## METHODS

### Study Design

This study was initiated in March 1996 and the preliminary results have been previously reported.<sup>18</sup> Thirty-three knees in 33 consecutive patients with an arthroscopically established diagnosis of a full-thickness cartilage defect of the femoral condyles were eligible for inclusion in the study and were all treated with arthroscopic AOT from March 1996 to June 1999 by the senior author (J.C.Y.C.).

The inclusion criteria were (1) full-thickness chondral and osteochondral defects demonstrated by arthroscopy, (2) defect location at the medial or lateral femoral condyle, (3) dimensions ranging from 1 to 2.5 cm of defect diameter, and (4) radiographic evidence of physeal closure of the distal femur and the proximal tibia.

The exclusion criteria included (1) associated tibial or patellar articular cartilage defects, (2) generalized osteoarthritic changes of the knee joint, (3) osteophyte formation in the intercondylar notch area, (4) mechanical axis malalignment with abnormal orientation of the knee joint, (5) presence of a collagen disease, and (6) skeletal immaturity. Neither meniscal tears nor anterior cruciate ligament (ACL) disruptions were contraindications for the procedure. All patients underwent arthroscopic AOT to treat their chondral defects. Perioperative complications were recorded.

### Operative Technique

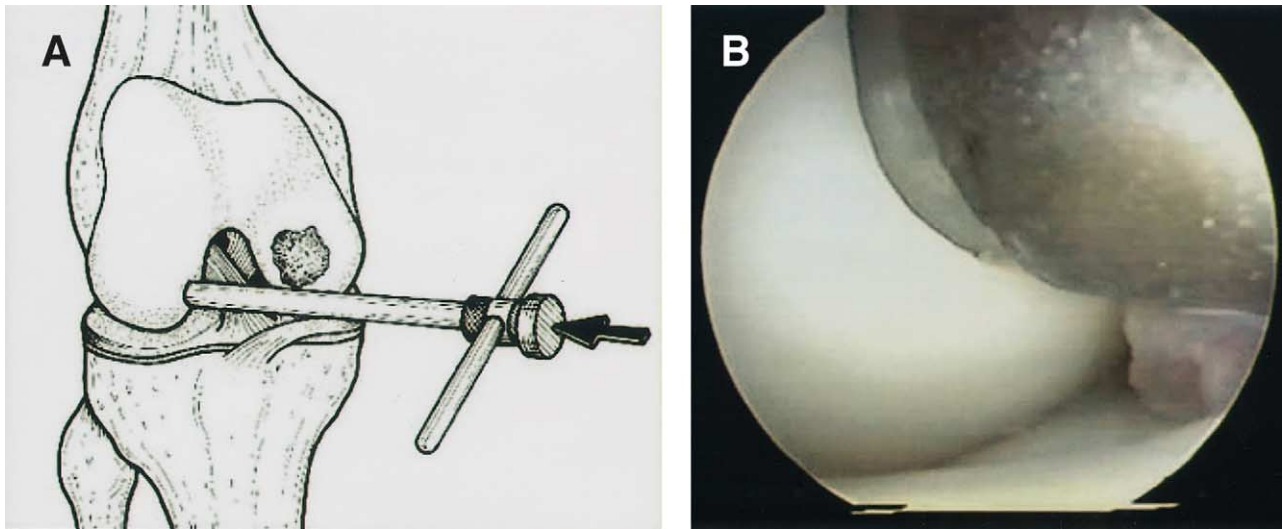
The COR-System (Mitek Products, Westwood, MA) was used in this study. The standard COR-System includes an osteochondral graft harvester, drill bit, delivery guide, and a plunger for the purposes of harvesting and implantation of the osteochondral autografts. The diameter of the graft harvester is 6 mm with a depth stop at 8 mm. Thus, grafts of standard diameter (6 mm) and length (8 mm) can be achieved. An open technique may be used if arthroscopic access to the defect is difficult.

The surgical technique has been previously described in detail.<sup>20</sup> After confirmation of a full-thickness cartilage defect by arthroscopic examination, selection of the working portal is carried out with the aid of a spinal needle. The spinal needle is placed perpendicular to both the harvest and defect sites to achieve optimal graft congruity, which is a critical factor for success of the procedure.

The size of the lesion and the necessary number of grafts can be determined by using the harvester as a guide. The harvester (T-handled instrument) is then positioned perpendicular to the donor site. The superior and lateral aspects of the intercondylar notch are used as donor sites, as access to this area is very easy arthroscopically (Fig 1). With a mallet, the harvester is driven into the bone to a depth of 8 mm until it is fully seated at the cutter's depth stop. The harvester containing the graft is then removed by rotating the T-handle clockwise a minimum of two complete revolutions (Fig 2). If additional grafts are required, another harvester can be used and the process repeated until the appropriate number of grafts has been taken.

Attention is then turned to the recipient site. Loose fragments are removed from the defect site with a shaver or a curette until the margins of the defect are well defined. The drill bit is then introduced into the joint and is placed at a 90° angle to the recipient site. Drilling is performed to the subchondral bone up to a depth of 8 mm. All holes may be drilled at once, maintaining a 1- to 2-mm bone bridge between recipient sites to achieve a tight press-fit. Alternatively, osteochondral grafts may be implanted after each hole is drilled.

For graft implantation, the clear delivery guide is screwed into the harvester. The graft is advanced to the distal tip of the delivery guide by tapping the plunger, which has been inserted into the proximal end of the harvester. The clear delivery guide may be rotated to align the graft's cartilage contour to fit the adjacent cartilage surface topography. Next, the graft



**FIGURE 1.** (A) The harvester is placed perpendicular to the superior-lateral intercondylar notch area for osteochondral graft harvesting. (Reprinted with permission.<sup>20</sup>) (B) Arthroscopic view of the graft harvester in the intercondylar notch area.

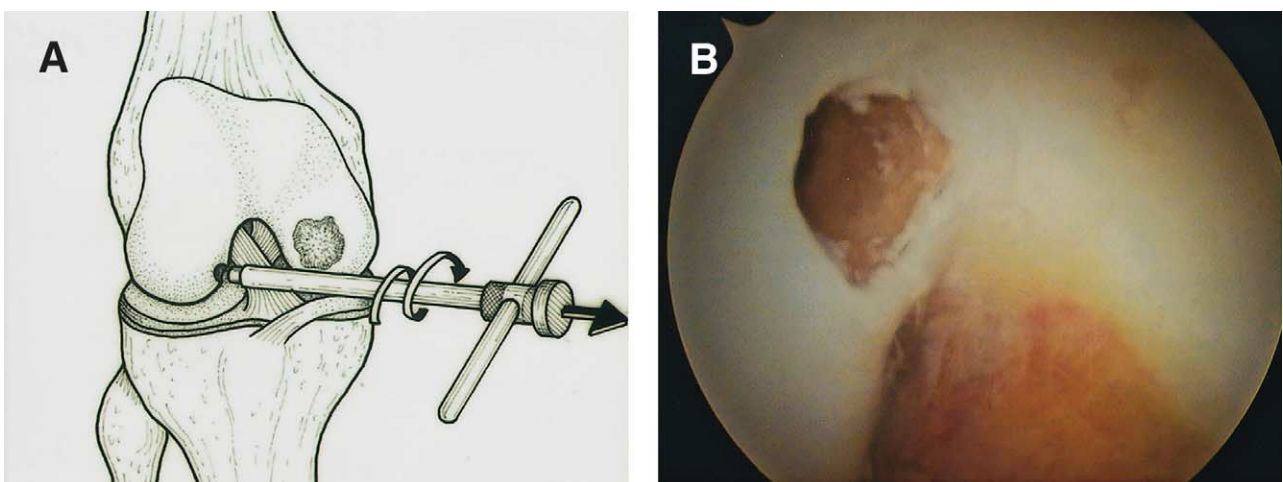
is positioned over the drill hole. By gently tapping the plunger, the plug is pressed into the hole until it is flush with the surrounding bone (Fig 3). If the level of the graft is higher than the surrounding bone, a tamp is inserted into the joint over the graft core. By tapping the tamp lightly, final seating of the graft is achieved. The procedure is repeated for each graft to be transplanted (Fig 4).

After completion of the procedure, surface congruity is confirmed under arthroscopic control. The knee is put through full range of motion to ensure graft stability. A postoperative drain is not necessary.


Postoperatively, patients remain non-weight-bearing for 3 weeks, while active knee motion is encouraged. During the next 3 to 6 weeks, the patient is allowed partial weight bearing. Light running is permitted when the patient regains full range of motion and shows no signs of effusion, usually at 12 weeks.

#### Evaluation Protocol

Preoperative as well as postoperative evaluation of patients was performed using the Lysholm knee score,<sup>21</sup> the International Knee Documentation Com-



**FIGURE 2.** (A) Removal of the graft is achieved by gentle twisting of the T-handle of the harvester while withdrawing it from the joint. (Reprinted with permission.<sup>20</sup>) (B) Arthroscopic view of the donor site after graft harvesting.



**FIGURE 3.** For graft insertion the plunger is tapped to press the plug into the drilled hole until it is flush with the surrounding host cartilage. (Reprinted with permission.<sup>20</sup>)

mittee (IKDC) Standard Evaluation Form,<sup>22</sup> and weight-bearing anteroposterior and lateral radiographs, at a minimum period of 24 months.

The number of points according to the Lysholm score (0-100 points) was graded as excellent (>94

points), good (84-94 points), fair (60-83 points), and poor (<60 points).

According to the IKDC Standard Evaluation Form, knees are graded as normal (A), near normal (B), abnormal (C), or severely abnormal (D). The categories that were evaluated to determine the final grade were subjective assessment, symptoms (pain, giving way, and swelling), range of motion, and ligament examination. The lowest grade in any category was used as the final outcome.

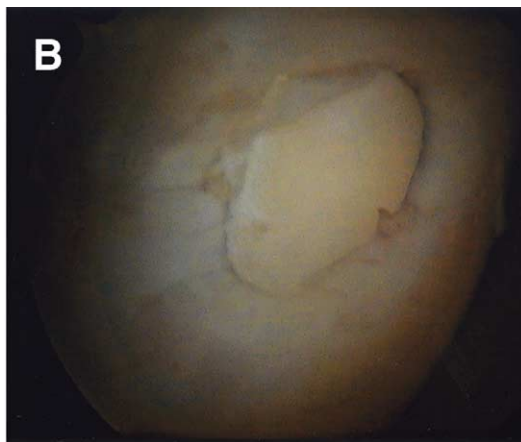
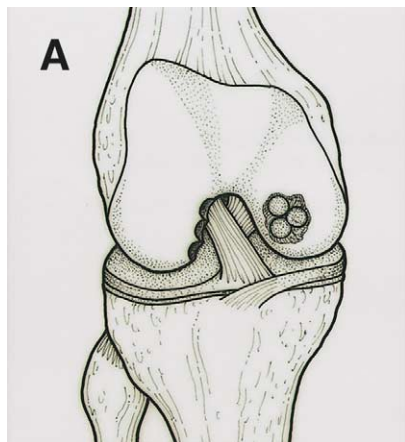
Radiographs were evaluated using Fairbank's criteria.<sup>23</sup> These include ridge and osteophyte formation, flattening or squaring of the femoral condyle, and joint space narrowing.

In addition, second-look arthroscopy and needle biopsy of the graft were offered to all patients independently of their symptoms to evaluate the status of graft healing and provide guidelines for activity level, including participation in sports.

Magnetic resonance imaging (MRI) evaluation to obtain additional information regarding the imaging characteristics of the osteochondral autografts was not part of this prospective study. However, MRI examination was ordered at the last follow-up visit for patients who did not object to the additional cost.

### Statistics

The paired *t* test was used for comparison of the preoperative and postoperative Lysholm score, and the Wilcoxon signed-rank test for comparison of the preoperative and postoperative IKDC classification in our patient group. Comparisons between subgroups of patients were performed using the unpaired *t* test for parametric data, the Mann-Whitney *U* test for non-parametric data, and the  $\chi$ -square and Fisher exact test



**FIGURE 4.** (A) Osteochondral grafts in place in the medial femoral condyle after completion of the procedure. (Reprinted with permission.<sup>20</sup>) (B) Arthroscopic view of a single osteochondral graft in place in the medial femoral condyle.



for proportions. All tests were 2-tailed and significance was set at  $P < .05$ .

## RESULTS

Three of 33 patients (9.1%) were lost to follow-up and were excluded from the study. Thus, 30 patients (30 knees) with a minimum follow-up of 2 years constitute the subjects of this report.

There were 13 male and 17 female patients with a mean age of 44.6 years (range, 19 to 66 years). The age distribution of our patients was as follows: 19 to 34 years, 9 patients; 35 to 44 years, 5 patients; 45 to 54 years, 11 patients; and 55 to 66 years, 5 patients. The procedure was performed in 18 right knees and 12 left knees. The etiology of the cartilage defect was trauma in 17 patients, osteochondritis dissecans (OCD) in 4 cases, and unknown in the remaining 9 cases. Twenty-eight of the 30 (93.3%) chondral defects were located on the medial femoral condyle and in the remaining 2 cases (6.7%) the lateral femoral condyle was affected.

Preoperatively, all patients complained of aching pain exacerbated by activity. Fourteen patients (46.6%) had repeated swelling in their knees and 4 patients (13.3%) reported a locking sensation. The median duration of symptoms before surgery was 9.5 months (range, 1 month to 15 years).

The mean preoperative Lysholm score was 43.6 (range, 18-61), and according to the IKDC evaluation form, 19 knees (63.3%) were characterized as severely abnormal (D) and 11 knees (36.7%) as abnormal (C). The OCD lesions, which all involved the medial femoral condyle, were revealed by preoperative radiographic evaluation in all 4 cases. Minor degenerative changes (such as a ridge formation) according to Fairbank's criteria were observed in only 1 of the remaining patients.

Ten patients had undergone surgery in their knees prior to AOT. The procedures performed comprised 1 lateral and 4 medial partial meniscectomies, 2 chondroplasties (drilling and abrasion arthroplasty), 1 OCD fixation, and 2 diagnostic arthroscopies.

During the procedure, 5 irreparable meniscal ruptures (4 medial and 1 lateral) were identified in 5 patients. Two of these patients also had an ACL tear. In all these cases, partial meniscectomy and ACL reconstruction were carried out in the same procedure immediately after AOT. Loose body removal was performed in 8 cases.

On average, 2.2 osteochondral autografts (range, 1 to 4) were used for reconstruction of the defect. All proce-

dures were performed arthroscopically. Tourniquet time ranged from 37 to 94 minutes with a mean of 65 minutes.

No intraoperative complications occurred. Postoperatively, 2 patients developed a painful hematoma and aspiration of the knee joint was performed. After this, the postoperative course was uneventful for both patients. No other complications occurred.

Mean follow-up time was 45.1 months (range, 24 to 63 months). Postoperative evaluation showed significant clinical improvement. The Lysholm score increased to a mean value of 87.5 (range, 57-100), which was statistically significant compared with the preoperative mean value of 43.6 (range, 18-61), ( $P < .001$ , paired  $t$  test). However, in 5 patients with associated pathology who were treated at the same time as the AOT, we cannot determine whether the improvement in symptoms was due to the AOT or the associated procedure. Twenty-five patients (83.3%) had an excellent or good outcome. Three patients (10%) had a fair result and the remaining 2 (6.7%) had a poor result. The last 2 patients underwent a total knee replacement 39 and 47 months after the AOT.

According to the IKDC Evaluation Form, 8 knees (26.7%) were classified as normal (A), 18 knees (60%) as near normal (B), 2 knees (6.7%) as abnormal (C), and 2 knees (6.7%) were classified as severely abnormal (D). The median IKDC classification significantly improved from (D) preoperatively to (B) at the latest follow-up evaluation ( $P < .001$ , Wilcoxon signed-rank test).

In an effort to identify factors associated with the end result, we compared patients with excellent outcome to those with fair or poor outcome (Table 1). Despite the small sample sizes, the fair/poor outcome subgroup had a significantly increased duration of preoperative symptoms (median duration, 31 v 7.5 months) and an increased prevalence of knee swelling (4 of 5 patients compared with 1 of 10 patients in the excellent outcome subgroup). Interestingly, the 2 subgroups did not differ in age.

We further compared patients younger than 45 years with patients 45 years and older with regard to the final outcome. No significant difference was identified in the final Lysholm score (87.9 in the younger subgroup v 87.1 in the older subgroup) and in the proportion of patients with a good or excellent outcome (11 of 14 patients [78.6%] in the younger subgroup v 14 of 16 [87.5%] in the older subgroup).

Two patients were found to have 2 or more Fairbank changes and eventually underwent total knee replacement. One patient had mild degenerative changes (small osteophyte formation). All OCD le-

**TABLE 1.** Comparison of the Excellent Outcome Subgroup With the Fair/Poor Outcome Subgroup

Parameters	Excellent Outcome (n = 10)	Fair/Poor Outcome (n = 5)	Statistical Results
Age	44.1 (10.5) yr	42.4 (13.1) yr	NS
Symptom duration	7.5 (1-38) mo*	31 (10-67) mo*	$P = .02$ , Mann-Whitney $U$ test
Preoperative swelling	10%	80%	$P = .01$ , Fisher exact test
No. of plugs	2.3 (0.9)	2.2 (0.8)	NS
Preoperative Lysholm score	45.1 (14.1)	32 (15.2)	NS
Follow-up	50.5 (11.4) mo	42.4 (9.4) mo	NS

NOTE. Parametric data are presented as mean (standard deviation) and nonparametric data as \*median (range).  
Abbreviation: NS, nonsignificant.

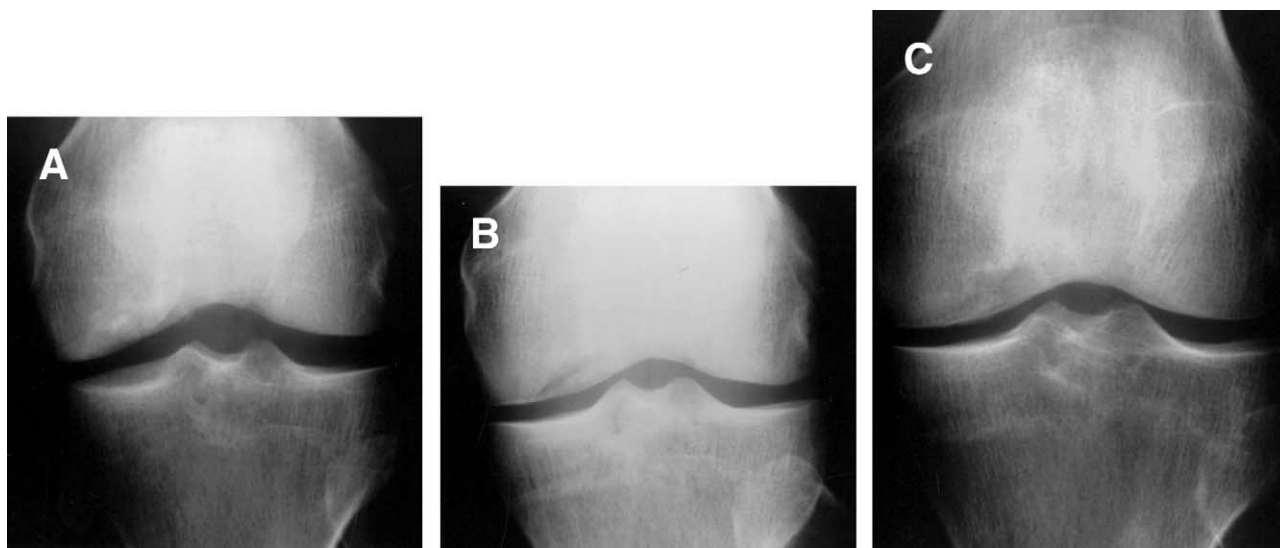
sions had completely healed without evidence of any degenerative changes (Fig 5).

Second-look arthroscopy was performed at various intervals between 6 and 15 months (mean time, 8.8 months) in 9 (30%) of our patients. Seven (77.8%) of these 9 patients had complete graft healing. The grafts were firm, with the same elasticity and color of the adjacent host cartilage, while the recipient surface remained congruent (Fig 6). These patients had an excellent or good outcome, according to the Lysholm score. In the remaining 2 cases, fibrillation of the grafted cartilage was observed and fibrocartilage-like tissue was present between the grafts and the adjacent host cartilage; this tissue was debrided. One patient had a good result and the other a fair result, according to Lysholm score. The donor sites in the superior and

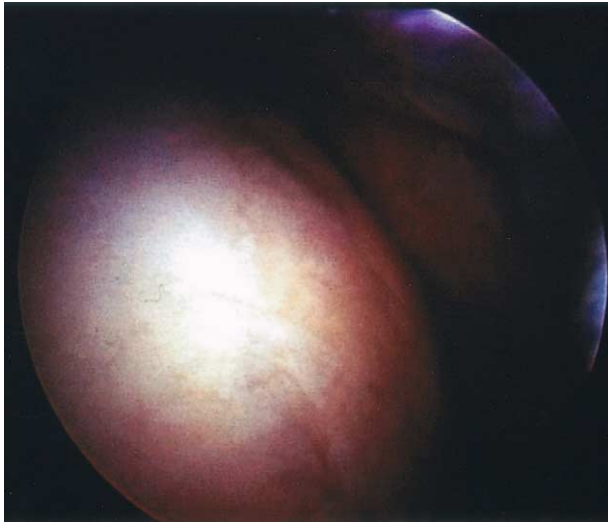lateral intercondylar notch were covered with fibrocartilaginous scar in all cases.

Graft biopsies were performed in all patients undergoing second-look arthroscopy. Histologic examination of the autogenous osteochondral plugs revealed normal hyaline cartilage in 7 of 9 patients and degenerative cartilage in 2.

To evaluate if patients who underwent second-look arthroscopy comprised a representative sample of our study population, we compared them with the ones who did not elect to have the procedure with regard to the outcome (Table 2). The second-look arthroscopy subgroup was followed up for a longer period of time and attained a similar Lysholm score and a proportion of excellent or good outcome compared with the subgroup that did not have the procedure. Thus, we be-



**FIGURE 5.** Anteroposterior radiographs of the knee joint in a 28-year-old man. (A) Preoperative radiograph showing OCD of the medial femoral condyle. (B) Two months after AOT, the congruency of the condyle has been restored but healing is not complete. (C) Five years postoperatively the OCD has completely healed while the joint maintains its congruity.



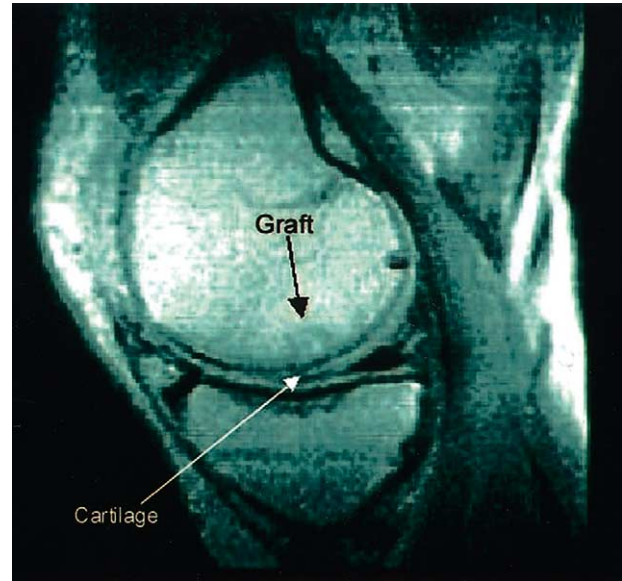
**FIGURE 6.** Arthroscopic view of the recipient site in the medial femoral condyle 8 months postoperatively.

lieve that no bias existed in selecting patients with successful outcome for the second-look arthroscopy.

Twelve patients underwent an MRI examination. Congruency of the articular surface was restored in 11 patients (91.7%) without signs of fissuring or delamination (Fig 7). A common finding, present in 9 of 12 MRI examinations (75%), was the abnormal marrow signal in the subchondral bone beneath the region of cartilage repair, even 4 years after the procedure.

## DISCUSSION

Full-thickness chondral and osteochondral defects of the knee can cause numerous problems to the patient, such as pain, swelling, and locking, and may lead to early development of osteoarthritis. The goals of treatment are to alleviate pain and improve func-



**FIGURE 7.** Sagittal T2-weighted MRI of the repair site in the medial femoral condyle of a 36-year-old man 43 months after AOT. The osteochondral plug has been completely incorporated (black arrow). The signal intensity of the graft is homogenous with the surrounding subchondral bone and the filling of the chondral defect is excellent with the transplanted cartilage (white arrow).

tion, and furthermore to prevent or delay prosthetic replacement of the joint.

A cascade of alternative methods is available to treat chondral lesions but many limitations exist. Techniques for repair stimulation, such as abrasion arthroplasty,<sup>2,3</sup> drilling,<sup>4,5</sup> and microfracture,<sup>6</sup> are technically easy procedures without the need for special equipment. However, the usual result of these penetrating techniques is coverage of the chondral defect with fibrocartilage, which has poor biomechanical characteristics, and the clinical results deteriorate over time.<sup>7,8</sup>

**TABLE 2.** Comparison of the Second-Look Arthroscopy Subgroup With the Subgroup of Patients Who Did Not Elect to Undergo the Procedure

Parameters	Second-Look Arthroscopy (n = 9)	No Procedure (n = 21)	Statistical Results
Age	40.3 (11.1) yr	46.4 (11.9) yr	NS
Symptom duration	13 (1-180) mo*	9 (2-67) mo*	NS
Preoperative Lysholm score	38.2 (14.5)	45.9 (11.1)	NS
Final Lysholm score	86.6 (14.1)	87.9 (15.2)	NS
Excellent/good outcome	77.8%	85.7%	NS
Follow-up	53 (6.4) mo	41.8 (10.5) mo	P = .006

NOTE. Parametric data are presented as mean (standard deviation) and nonparametric data as \*median (range). Abbreviation: NS, nonsignificant.

Transplantation of osteochondral allografts is another treatment option. Although, this method offers the ability to reconstruct large defects without any morbidity related to graft harvesting, concerns regarding disease transmission, the adverse effect of preservation techniques on chondrocyte viability, cost, and tissue availability limit the use of this technique.<sup>9-11</sup>

Autologous chondrocyte transplantation is an exciting clinical concept.<sup>12-14</sup> Peterson et al.<sup>24</sup> evaluated 94 patients with a minimum follow-up time of 2 years and observed good or excellent results in 92% of patients with isolated femoral condyle defects. However, autologous chondrocyte transplantation is a 2-stage, laboratory-dependent, and high-cost procedure, which necessitates an arthrotomy. Hypertrophic periosteal healing with resultant pain and catching complicates 10% to 15% of cases.<sup>25</sup> Moreover, skepticism was expressed by Breinan et al.,<sup>26</sup> who found no statistically significant differences at 12 and 18 months between cartilage defects that were treated with autologous chondrocyte transplantation under a periosteal flap, a periosteal flap, and a nontreated control group in an animal model.

AOT (mosaicplasty) was popularized by Hangody and associates. Their work began in the early 1990s and included initial animal trials<sup>19</sup> and subsequent clinical applications.<sup>16,17,27</sup> However, the published experience with AOT is limited, especially for the arthroscopic technique. We thus believe that the present study contributes to delineating the medium-term outcome of arthroscopic AOT.

In our experience, arthroscopic AOT is an effective and safe technique for restoration of chondral or osteochondral defects of the femoral condyles in skeletally mature patients. Arthroscopic AOT significantly improved knee pain and function in our patients, without associated complications or donor-site morbidity. At a mean follow-up time of almost 4 years, 83.3% of our patients had an excellent or good outcome, and 86.7% of knees were characterized as normal or near normal.

Our results are in accordance with other series. Hangody et al.,<sup>27</sup> using a modification of the Hospital for Special Surgery scoring system, reported 91% excellent and good results in a group of 57 patients with more than 3 year follow-up. Kish et al.<sup>17</sup> evaluated 52 competitive athletes who underwent the procedure. At a minimum follow-up time of 12 months, 63% had returned to full sport participation. Bradley,<sup>28</sup> in a multicenter study with 145 patients and 18 months of follow-up, reported a success rate of 86%. Similarly, Davidson and Rivenburgh<sup>29</sup> found 87% ex-

cellent or good results in their series at a mean follow-up time of 20 months.

The satisfactory outcome of this procedure is based on the viability of the grafted articular cartilage, which retains its hyaline characteristics. The process of graft healing begins in the cancellous bone. Subsequently, upward in-growth of fibrocartilage occurs and finally matrix integration of the cartilage takes place.<sup>17</sup> The presence of normal hyaline cartilage, with type II collagen appropriately oriented in the various zones, restores the biomechanical properties of the cartilage, and constitutes the major advantage of this method.

Autogenous osteochondral grafting does not depend on chondrocyte proliferation, matrix implantation, or mesenchymal cell differentiation for the restoration of articular cartilage. Instead, hyaline cartilage is harvested in the form of osteochondral grafts during the index procedure. Thus, the method is not laboratory dependent, is of low cost, involves only a 1-stage procedure, and carries no risk of disease transmission or immunologically mediated damage to the graft.

Another advantage of this method is its minimally invasive nature because it can be performed through a small incision or even arthroscopically. This makes AOT ideal for focal chondral defects of the knee associated with ACL tears, a common problem in the ACL-deficient knee.<sup>15,30,31</sup> Two patients in our series underwent an ACL reconstruction in conjunction with AOT in a 1-stage procedure and achieved a satisfactory outcome.

Thus, arthroscopic AOT appears to constitute a viable and promising option. However, limitations exist in the studies evaluating the technique, as well as in our study. Our follow-up is not enough to assess the effect of the procedure, if any, in modifying the development of knee joint osteoarthritis. Although the length of follow-up was 45.1 months, the rate of Fairbank changes was very low in our study. Furthermore, no comparison of the AOT technique was made with alternative methods.

Our study does, however, have the advantage of a consecutive series of patients operated on by a single surgeon using the same arthroscopic technique. Follow-up was accomplished in a prospective fashion, approached a period of almost 4 years, and involved the vast majority of patients.

We agree with other authors<sup>16,32</sup> that the ideal indication for this technique is a relatively small, less than 25 mm in diameter, full-thickness chondral defect with stable surrounding cartilage. It should be noted that the natural history of small chondral defects is unknown. Shelbourne<sup>33</sup> reported that there was no



harm in patients with small asymptomatic chondral defects who received no treatment in a 12-year follow-up study. However, in our series, all patients with isolated chondral defects were symptomatic, although the lesion was relatively small. We believe that these are different conditions and require different treatment.

Defect dimensions constitute a limitation of the procedure due to the limited availability of the donor site. Nevertheless, Jerosch et al.<sup>34</sup> proposed the proximal tibiofibular joint as an alternative donor site, able to provide additional cartilage surface.

Improved outcome was reported by Kish et al.<sup>17</sup> in patients of younger age. However, we consider that patient age is not a limiting factor for the procedure. According to our results, older patients, with an isolated chondral defect and a stable knee joint without osteoarthritic changes, appear to benefit from the procedure. However, we observed that patients with fair or poor outcome had a very low preoperative Lysholm score and a prolonged duration of knee symptoms that frequently included swelling.

The press-fit fixation of the graft avoids the use of screws or pins, which can cause further damage to the articular cartilage and compromise assessment of cartilage repair with MRI. Duchow et al.<sup>35</sup> showed that the fixation strength of press-fit implanted osteochondral grafts increases when larger grafts (in length and diameter) are used. However, the values necessary for secure graft fixation have not been determined yet, as mentioned by the same authors.<sup>36</sup>

The recreation of joint congruity with the mosaicplasty technique is a technically demanding procedure. However, with attention to detail, the restoration of articular surface congruency can be achieved. Graft harvesting and insertion should be perpendicular to the articular surface. A wrong angle will compromise the end result.<sup>32</sup> Grafts also should be delivered flush with the joint surface to avoid graft micromotion and allow rapid incorporation.<sup>37</sup>

Migration of a donor plug to create a loose body and damage to the weight-bearing area during graft harvest are potential complications. Nevertheless, the only complications we had in our series were 2 hematomas, similar to other reports.<sup>16</sup>

Donor-site morbidity is another concern generated by autologous osteochondral transplantation, because of iatrogenic damage of weight-bearing surfaces. Potential donor sites are the periphery of the lateral<sup>32</sup> or medial femoral condyle<sup>16,17</sup> and the superior and lateral aspects of the intercondylar

notch.<sup>31</sup> Simonian et al.<sup>38</sup> showed that, although non-weight-bearing articular cartilage does not exist in the knee joint, the lateral and superior aspect of the lateral femoral condyle and medial and superior aspect of the intercondylar notch showed significantly less contact pressure. In our series, we harvested the osteochondral autografts from the intercondylar notch because this area is easily accessible arthroscopically and experience with ACL reconstruction has not revealed problems after removal of this area during notchplasty. Furthermore, the relatively small length (8 mm) of the osteochondral grafts ensures that no other areas of subchondral bone will be violated during the procedure. In accordance with others,<sup>16,17,31</sup> we did not observe any problems arising from the donor site area by clinical examination and second-look arthroscopy.

It is interesting that an abnormal marrow signal was present in 75% of patients who underwent MRI in our series. Perhaps, this marrow signal abnormality is presumed to represent the granulation tissue of bony repair as the graft becomes incorporated.<sup>39</sup> However, long-term follow-up studies are necessary to determine the significance of this finding, although the congruency of the articular surface was restored.

Second-look arthroscopy with graft biopsy is the most helpful and reliable method for cartilage repair assessment. However, with very few asymptomatic patients willing to undergo second-look arthroscopy, a clear correlation between clinical result and graft healing is difficult to establish. In our study, only 8 patients without symptoms underwent a second-look arthroscopy. We noted that 7 of 8 grafts (87.5%) had healed. Based on this information, we believe that there is correlation between the clinical result and second-look arthroscopy.

In conclusion, our results suggest that arthroscopic AOT is an acceptable and reliable option for treating full-thickness chondral defects in appropriately selected cases. The arthroscopic technique is a minimally invasive, 1-stage procedure, with a low rate of complications, and low cost. Meticulous technique and accurate restoration of the articular surface are essential factors for a good result. However, further prospective studies with long-term follow-up are needed to investigate whether these promising results of the technique will stand the test of time.

## REFERENCES

1. Curl WW, Krome J, Gordon S, Rushing J, Paterson-Smith B, Poehling GG. Cartilage injuries: A review of 31,516 knee arthroscopies. *Arthroscopy* 1997;13:456-460.
2. Kim HW, Morgan ME, Salter RS. The potential for regeneration of articular cartilage in defects created by chondral shaving and subchondral abrasion. An experimental investigation in rabbits. *J Bone Joint Surg Am* 1997;73:1301-1315.
3. Bert JM. Abrasion arthroplasty. *Oper Tech Orthop* 1997;4:294-299.
4. Pirdie AH. The method of resurfacing osteoarthritic knee joints. *J Bone Joint Surg Br* 1959;41:613-618.
5. Mitchell N, Shepard N. Resurfacing of adult rabbit articular cartilage by multiple perforations of the subchondral bone. *J Bone Joint Surg Am* 1976;58:230-233.
6. Steadman JR, Rodkey WG, Singleton SB, Briggs KK. Microfracture technique for full thickness chondral defects. *Oper Tech Orthop* 1997;7:300-307.
7. Mankin HJ, Mow VC, Buckwalter JA, Iannotti J, Ratcliffe A. *Form and function of articular cartilage*. Rosemont, IL: AAOS Orthopaedic Basic Science, 1994;3-41.
8. Newman AP. Articular cartilage repair. Current concepts. *Am J Sports Med* 1998;26:309-324.
9. Garrett JC. Osteochondral allografts for reconstruction of articular defects of the knee. *Inst Course Lect* 1998;47:517-522.
10. Czitrom AA, Keating S, Gross AE. The viability of articular cartilage in fresh osteochondral allografts after clinical transplantation. *J Bone Joint Surg Am* 1990;72:574-581.
11. Friedlander GE. Immune responses to osteochondral allografts. Current knowledge and future directions. *Clin Orthop* 1983;174:58-68.
12. Brittberg M, Lindahl A, Nilsson A, Ohlsson C, Isaksson O, Peterson L. Treatment of deep cartilage defects in the knee with autologous chondrocyte transplantation. *N Engl J Med* 1994;331:889-895.
13. Brittberg M, Nilsson A, Lindahl A. Rabbit articular cartilage defects treated by autologous cultured chondrocytes. *Clin Orthop* 1996;326:270-283.
14. Minas T. The role of cartilage repair techniques, including chondrocyte transplantation, in focal chondral knee damage. *Inst Course Lect* 1999;48:629-643.
15. Bobic V. Arthroscopic osteochondral autograft transplantation in anterior cruciate ligament reconstruction: A preliminary clinical study. *Knee Surg Sports Traumatol Arthrosc* 1996;3:262-264.
16. Hangody L, Kish G, Karpati Z, Szerb I, Udvarhelyi I. Arthroscopic autogenous osteochondral mosaicplasty for the treatment of femoral condylar articular defects. A preliminary report. *Knee Surg Sports Traumatol Arthrosc* 1997;5:262-267.
17. Kish G, Modis L, Hangody L. Osteochondral mosaicplasty for the treatment of focal chondral and osteochondral lesions of the knee and talus in the athlete. *Clin Sports Med* 1999;18:45-66.
18. Chow J, Barber A. Osteochondral transplantation: Preliminary results and technique analysis. Presented at the 17th Annual Meeting of Proceedings of the Arthroscopy Association of North America, Orlando, FL, April 1998.
19. Hangody L, Kish G, Karpati Z, Szerb I. Autogenous osteochondral graft technique for replacing knee cartilage defects in dogs. *Ortop Tod Int* 1997;5:175-181.
20. Barber AF, Chow JYC, Chow JC. Osteochondral transplantation: Preliminary results and technique analysis. In: Chow JC, ed. *Advanced arthroscopy*. New York: Springer-Verlag, 2001; 573-579.
21. Tegner Y, Lysholm J. Rating system in the evaluation of knee ligament injuries. *Clin Orthop* 1985;198:43-49.
22. Anderson AF. Rating scales. In: Fu FH, Harner CD, Vince KG, eds. *Knee surgery*. Baltimore: Williams & Wilkins, 1994; 275-296.
23. Fairbank TJ. Knee joint changes after meniscectomy. *J Bone Joint Surg Br* 1948;30:664-670.
24. Peterson L, Minas T, Brittberg M, Nilsson A, Sjogren-Jansson E, Lindahl A. Two to 9 year outcome after autologous chondrocyte transplantation of the knee. *Clin Orthop* 2000;374:212-234.
25. Minas T, Peterson L. Advanced techniques in autologous chondrocyte transplantation. *Clin Sports Med* 1999;18:13-44.
26. Breinan HA, Minas T, Hsu HP, Nehrer S, Sledge CB, Spector M. Effect of cultured autologous chondrocytes on repair of chondral defects in a canine model. *J Bone Joint Surg Am* 1997;79:1439-1451.
27. Hangody L, Kish G, Karpati Z, Udvarhelyi I, Szigeti I, Bely M. Mosaicplasty for the treatment of articular cartilage defects. Application in clinical practice. *Orthopedics* 1998;21:751-756.
28. Bradley JP. Osteochondral autograft transplantation clinical outcome study. Proceedings of the Metcalf Memorial Meeting, Sun Valley, ID, January 1999.
29. Davidson PA, Rivenburgh DW. Osteochondral autogenous transfer for the treatment of full thickness articular surface defects. Presented at the 19th Annual Meeting of Proceedings of the Arthroscopy Association of North America, Miami, FL, April, 2000.
30. Matsue Y, Yamamuro T, Hama H. Case report. Arthroscopic multiple osteochondral transplantation to the chondral defect in the knee associated with anterior cruciate ligament disruption. *Arthroscopy* 1993;9:318-321.
31. Bittan ES. Arthroscopic osteochondral grafting of articular cartilage defects in ACL deficient knees. Presented at the 19th Annual Meeting of Proceedings of the Arthroscopy Association of North America, Miami, FL, April 2000.
32. Bobic V, Morgan C, Carter T. Osteochondral autologous graft transfer. *Oper Tech Sports Med* 2000;8:168-178.
33. Shelbourne KD. Outcome of the untreated traumatic articular cartilage defects of the knee—A 12-year natural history study. Presented at the Fourth Symposium of the International Cartilage Repair Society, Toronto, Canada, June 2002.
34. Jerosch J, Filler T, Peuker E. Is there an option for harvesting autologous osteochondral grafts without damaging weight-bearing areas in the knee joint? *Knee Surg Sports Traumatol Arthrosc* 2000;8:237-240.
35. Duchow J, Hess T, Kohn D. Primary stability of press-fit-implanted osteochondral grafts. Influence of graft size, repeated insertion and harvesting technique. *Am J Sports Med* 2000;28:24-27.
36. Duchow J, Hess T, Kohn D. Primary press-fit stability of different systems for osteochondral grafting: A biomechanical study. Presented at the 19th Annual Meeting of Proceedings of the Arthroscopy Association of North America, Miami, FL, April 2000.
37. Pearce SG, Hurtig MB, Clarnette R, Karla M, Cowan B, Miniaci A. An investigation of 2 techniques for optimizing joint surface congruency using multiple cylindrical osteochondral autografts. *Arthroscopy* 2001;17:50-55.
38. Simonian PT, Sussmann PS, Wickiewicz TL, Paletta GA, Warren RF. Contact pressures at osteochondral donor sites in the knee. *Am J Sports Med* 1998;26:491-494.
39. Winalski CS, Minas T. Evaluation of chondral injuries by magnetic resonance imaging: repair assessments. *Oper Tech Sports Med* 2000;8:108-119.