

Immunohistochemical detection of angiotensin receptors AT1 and AT2 in adrenal tumors

Marek Pawlikowski, Katarzyna Winczyk, Beata Śledź

Department of Neuroendocrinology, Chair of Endocrinology, Medical University of Łódź, Poland

Abstract: Angiotensin II is well known to affect the adrenal cell growth and function. Angiotensin receptors AT1 and AT2 were found to be present in the normal adrenal gland. However, the data on the expression of the angiotensin receptors in the adrenal tumors are very scarce. To overcome this gap, the paraffin sections of the adrenal cortical tumors and of pheochromocytomas from the archival material were immunostained with antibodies raised against AT1 (sc-1173) and AT2 (sc-9040) receptor proteins. In hyperplasia of the adrenal cortex and in benign adrenocortical adenomas, both functioning and non-functioning, the AT1 immunostaining was present mainly in the cell membranes. A positive immunoreaction was also found in the subpopulation of cell nuclei and within the cytoplasm. In the adrenal cancer, as well as in pheochromocytomas, neither cell membranes nor cell nuclei were immunostained with anti-AT1 antibody. However, a weak AT1 immunostaining was present within the cytoplasm of tumoral cells. With anti-AT2 antibody, in all tumors investigated, the tumoral cells were immunonegative but moderate to strong AT2 immunostaining was observed in the walls of intratumoral blood vessels and in the interstitial tissue. Our data indicates that the expression of AT1 receptors is altered in adrenal cancer and in pheochromocytomas. The expression of AT2 receptors, in turn, may be connected with the process of tumoral neo-angiogenesis.

Key words: Angiotensin receptors - AT1 - AT2 - Adrenal gland - Adrenal tumors - Immunohistochemistry

Introduction

The adrenal gland is well known to be a target for angiotensin II (Ang II). Ang II is the main regulator of aldosterone secretion and exerts the stimulatory effect on the adrenal cell growth [1-3]. Although the adrenal gland is affected by circulating Ang II, the peptide can be also generated within the gland by a local renin-angiotensin system [4,5]. Both main subtypes of Ang II receptors, AT1 and AT2 were identified in rodent and human adrenal cortex and medulla [6-8]. In adrenal cortex, AT1 subtype is prevalent, whereas in adrenal medulla the AT2 subtype dominates [6]. Despite the important roles of Ang II and its receptors in the adrenal physiology, the data on angiotensin receptors in the adrenal tumors are rather scarce and partly controversial [9-14]. These investigations were performed by means of radioligand binding or by means of molecular biology techniques, mainly polymerase chain reaction (PCR). On the other hand, the study performed by

means of immunohistochemistry is lacking. The present paper reports, for the first time, the expression of angiotensin receptors AT1 and AT2 in human adrenal tumors as revealed by immunohistochemistry.

Materials and methods

Tumor material. The archival material of 26 surgically excised adrenal tumors in years 2001-2006, stored in paraffin blocks was studied. The material included 3 hyperplasias, 8 non-functioning cortical adenomas, 3 cortical adenomas manifesting themselves as primary hyperaldosteronism (Conn's syndrome), 4 cortisol-secreting adrenocortical adenomas, causing the Cushing's syndrome, 3 hormonally non-functioning adrenal cancers and 5 pheochromocytomas. In addition, 6 non-tumoral adrenal glands were studied. Five of them were removed from patients suffering from renal cancers during the surgical excision of the affected kidney, and one was excised together with pheochromocytoma.

Immunohistochemistry. The paraffin sections were immunostained with antibodies raised against AT1 and AT2 receptor proteins. AT1 immunostaining was performed using the anti-AT1 polyclonal antibody (sc-1173), raised against the N-terminal extracellular domain of AT1 receptor and recognizes human, rat and mouse receptor protein. AT2 receptors were revealed using the sc-9040 polyclonal antibody raised against the 221-303 fragment of the human AT2 receptor protein. The antibody detects human, rat and mouse AT2 receptors. Both antibodies were pur-

Correspondence: M. Pawlikowski, Chair of Endocrinology, Medical University of Łódź, Sterlinga Str. 3, 91-425 Łódź, Poland; tel./fax.: (+4842) 6365427, e-mail: pawlikowski.m@wp.pl

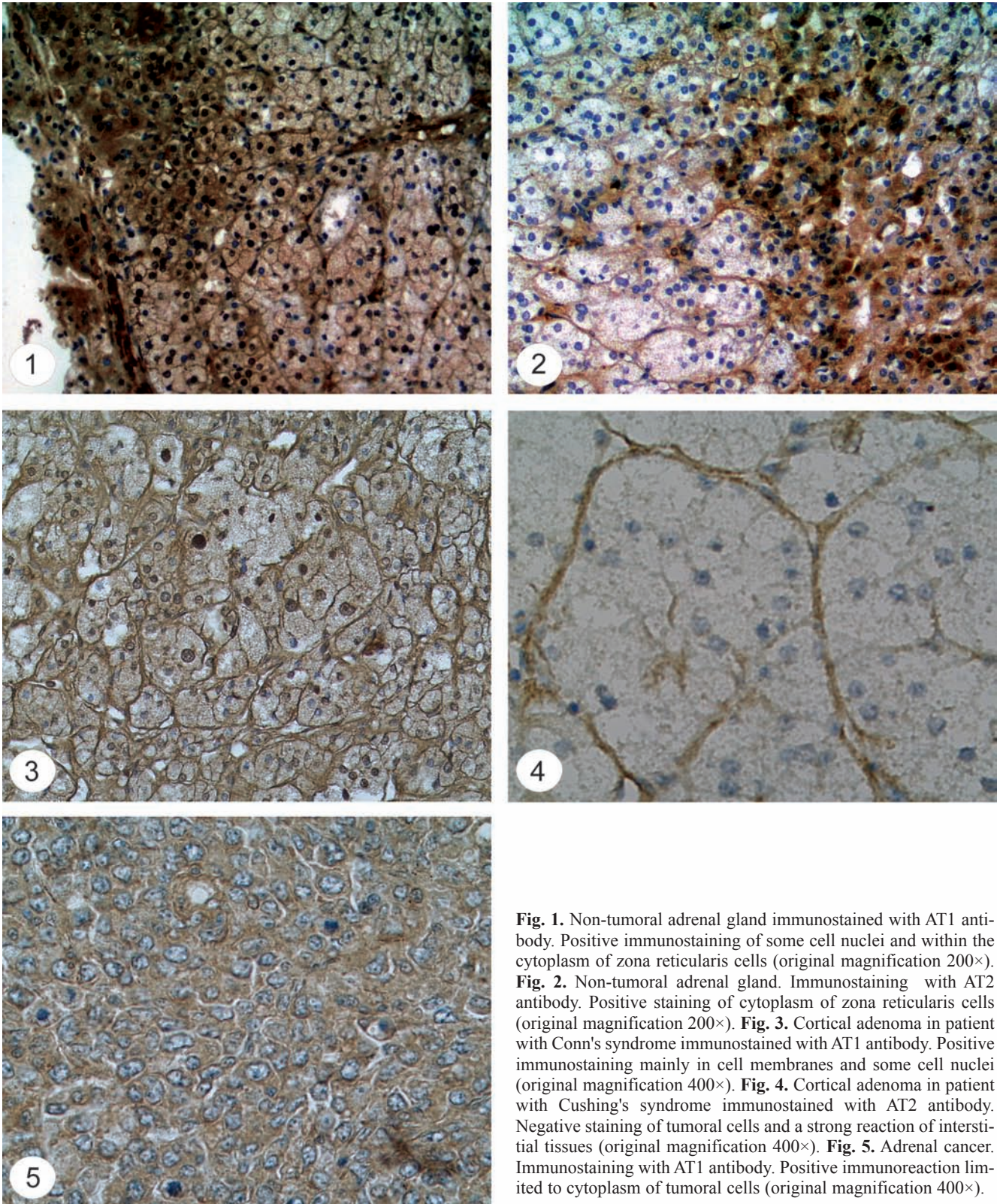


Fig. 1. Non-tumoral adrenal gland immunostained with AT1 antibody. Positive immunostaining of some cell nuclei and within the cytoplasm of zona reticularis cells (original magnification 200×). **Fig. 2.** Non-tumoral adrenal gland. Immunostaining with AT2 antibody. Positive staining of cytoplasm of zona reticularis cells (original magnification 200×). **Fig. 3.** Cortical adenoma in patient with Conn's syndrome immunostained with AT1 antibody. Positive immunostaining mainly in cell membranes and some cell nuclei (original magnification 400×). **Fig. 4.** Cortical adenoma in patient with Cushing's syndrome immunostained with AT2 antibody. Negative staining of tumoral cells and a strong reaction of interstitial tissues (original magnification 400×). **Fig. 5.** Adrenal cancer. Immunostaining with AT1 antibody. Positive immunoreaction limited to cytoplasm of tumoral cells (original magnification 400×).

chased from Santa Cruz Biotechnology, CA, USA. The anti-AT1 and anti-AT2 antibodies were applied in working dilution 1:100. The visualization of primary antibodies was done using the StreptABComplex/HRP Duet (Dako Cytomation) following the procedure recommended by the producer. In brief, the biotinylated

goat antibody against rabbit and mouse immunoglobulin was applied as the secondary antibody, followed by streptavidin-biotinylated horseradish peroxidase complex and 3,3'-diaminobenzidine as chromogen. The slides stained without the primary antibody served as controls.

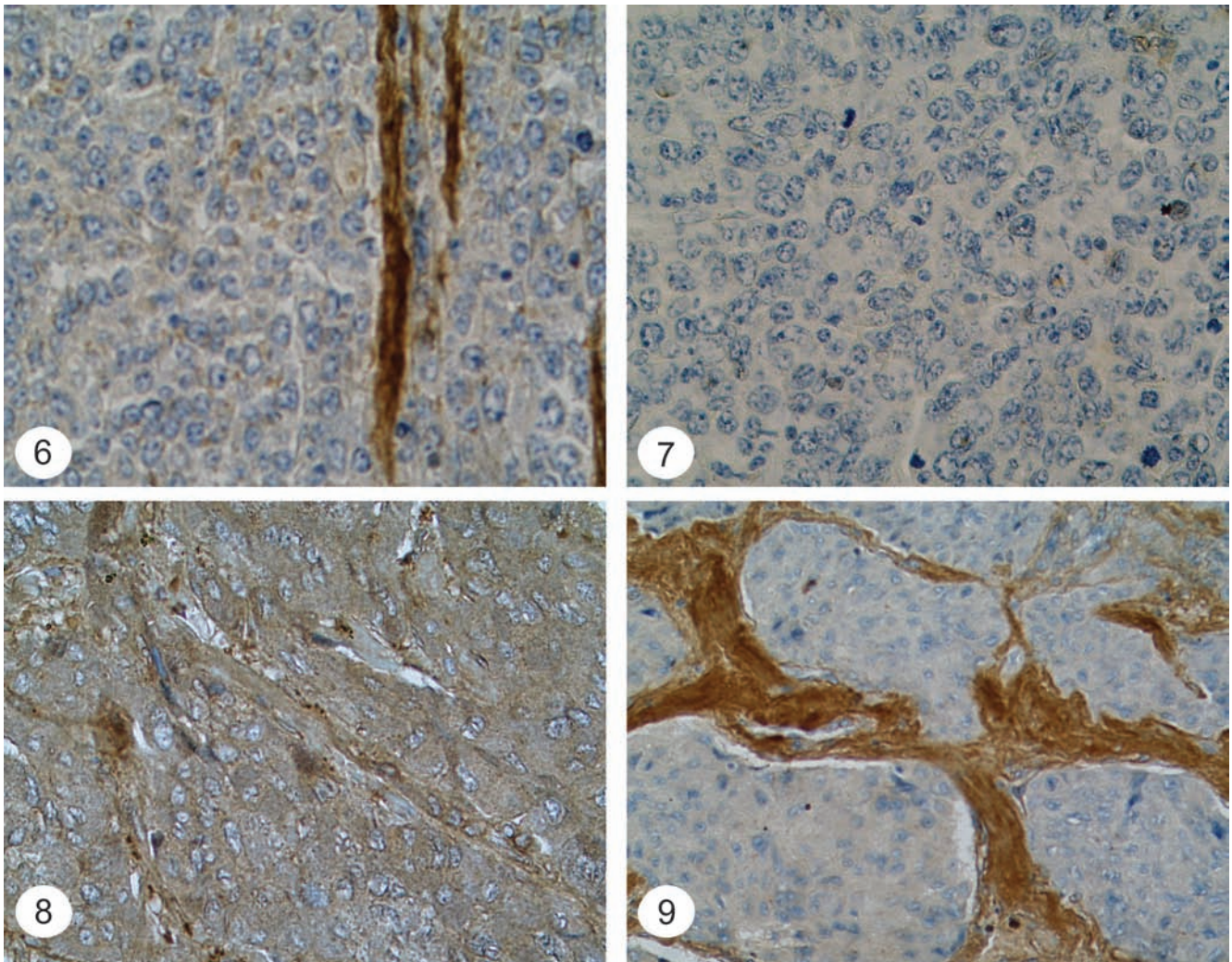


Fig. 6. Adrenal cancer immunostained with AT2 antibody. Negative staining of tumoral cells and strong positive reaction of blood vessels walls (original magnification 400×). **Fig. 7.** Adrenal cancer stained without primary antibodies (negative control - original magnification 400×). **Fig. 8.** Pheochromocytoma immunostained with AT1 antibody. Weak immunostaining of cytoplasm of the tumoral cells (original magnification 400×). **Fig. 9.** Pheochromocytoma immunostained with AT2 antibody. Negative staining of tumoral cells and strong immunostaining of interstitial tissue (original magnification 400×).

Results

The non-tumoral adrenal gland

The investigated fragments were limited to the adrenal cortex. The positive immunostaining with anti-AT1 antibody was found mainly in cell membranes. In the cytoplasm, a moderate staining was detectable in zona reticularis cells. In 3 from 6 examined glands, the subpopulation of the glandular cell nuclei (1%-31%) also immunostained with anti-AT1 antibody (Fig. 1). With anti-AT2 antibody, in all specimens the cell membranes and cell nuclei were negative. A weak or moderate reaction was observed within the cytoplasm of zona reticularis cells in 3 from 6 glands (Fig. 2). A weak reaction was also observable in capsule and interstitial connective tissue, and, in one case, also in the intra-glandular blood vessels.

Adrenocortical hyperplasia

In all the samples diagnosed as adrenocortical hyperplasia the reaction with anti-AT1 antibody was moderate to strong in cell membranes and weak to strong in cytoplasm. In all the cases a percentage of AT-1 positive cell nuclei was >15% (15%, 30% and 50%, respectively). On the other hand, there were no reactions with AT-2 antibody either in cell nuclei or in cytoplasm. The cell membranes were also immunonegative. In one case a weak reaction was also noticed in the interstitial tissue and blood vessels.

Non-functioning cortical adenomas

The localization of AT1 receptors was roughly similar to that in normal adrenal cortex and adrenocortical hyperplasia. The cell membrane-located immunostain-

ing was weak or strong, cytoplasmic immunostaining was weak except one case where the reaction was strong. The AT1-positive subpopulation of glandular cell nuclei was present in all but one tumor; its percentage varied from 2% to 50% of the nuclei. In all but one adenoma the reaction with anti-AT2 antibody was negative in cell membranes, cytoplasm and cell nuclei. In the remaining one case a strong AT2 immunopositivity in cell membranes was observed. In 4 from 8 adenomas, the variable AT2 immunopositivity was also found in blood vessels and the interstitial compartment.

Aldosterone- and cortisol-secreting adenomas

The adenomas removed from patients with Conn's syndrome presented moderate (in one case) or strong (2 cases) immunostaining of cell membranes with anti-AT1 antibody (Fig. 3). The subpopulation of AT1-positive cell nuclei included 4%, 5% and 50%, respectively. The variable immunostaining was noticed within the glandular cell cytoplasm (weak, moderate or strong). In contrast, the glandular cells were negative with anti-AT2 antibody.

In the tumors from patients with Cushing's syndrome the variable cell membrane immunostaining was found: strong in 2 cases, weak in another 2 cases and negative in one case. A subpopulation of cell nuclei was AT1-positive in 3 cases (5%, 6% and 15% of nuclei, respectively). In the remaining two cases, sporadic (<1%) cell nuclei were also immunostained with AT1 antibody. With AT2 antibody, both aldosterone- and cortisol-secreting adenomas were immunonegative except for blood vessel and interstitial tissues in some cases (Fig. 4).

Adrenal cancers

In adrenals cancers, neither cell membranes nor cell nuclei were immunostained with anti-AT1 antibody. However, the weak to moderate AT1 immunostaining was present within cytoplasm of the tumoral cells (Fig. 5). With anti-AT2 antibody the tumoral cells were immunonegative, but in one case moderate to strong AT2 immunostaining was observed in the walls of intratumoral blood vessels and in the interstitial tissue (Fig. 6).

Pheochromocytomas

In pheochromocytomas, neither cell membranes nor cell nuclei were immunostained with anti-AT1 antibody. The weak to moderate AT1 immunostaining was present within cytoplasm of the tumoral cells (Fig. 7). With anti-AT2 antibody the tumoral cells in majority of cases were immunonegative. In one case the small

population of cell nuclei (approx. 3%) was AT2-positive. In one case, a weak AT2 immunopositivity was also noticed within the cytoplasm. In majority of cases, a variable immunopositivity was also observed in the interstitial tissue and/or blood vessels walls (Fig. 8).

Discussion

The data presented above confirm the earlier findings that AT1 receptors are present and prevalent over AT2 receptors in the normal human adrenal cortex. AT1 receptors are also expressed in benign adrenal tumors both non-functioning and hormone-secreting. This observation is compatible with some data from earlier papers. Tanabe *et al.* [8] and Kitamura *et al.* [12] reported on the expression of AT1 mRNAs in both aldosterone- and cortisol-secreting adenomas. Opocher *et al.* [11] studied the binding of labeled Ang II in presence or absence of specific receptor blockers concluded that Ang II receptors are present in both aldosterone-secreting and cortisol-secreting adenomas, but in the latter the receptor density is lower than in the normal adrenal tissue. In turn, Schubert *et al.* [14] showed the elevated expression of AT1 mRNA in functioning adrenal adenomas, higher than in the normal adrenal cortex, but a very low signal in non-functioning tumors. The latter observation stays in opposition to our finding that the functioning and non-functioning adrenal adenomas do not differ markedly in the AT1 immunostaining. In adrenal cancers, our main finding was the altered localization of AT1 immunoreactivity: disappearance of the membrane-linked and nuclear AT1 staining and slightly increased AT1 immunostaining within the cytoplasm. Such alterations, obviously, cannot be detected by means of PCR technique, which reflects only the global content of receptor mRNA. Moreover, the earlier findings concerning the adrenal cancers, obtained with PCR technique, were discordant: very low or undetectable signal in one study [11] and no significant changes according to the other [14].

The nuclear AT1 immunostaining, observed sometimes in the normal adrenal cortex and in benign, but not in malignant adrenal lesions, is surprising. However, it is concordant with earlier observations indicating the presence of a nuclear binding site for Ang II and its AT1-like properties [15]. Although the role of this site is still unclear, its involvement in growth-promoting Ang II effects has been suggested [16].

In pheochromocytomas AT1 immunostaining was detectable in tumoral cells but confined only to cytoplasm. In the earlier studies AT1 mRNA expression in pheochromocytoma was very low or undetectable [11]. In contrast to AT1 receptor protein, the AT2 immunostaining of tumoral cells is undetectable in almost all adrenocortical tumors and pheochromocytomas. The loss of AT2 immunoreactivity in pheochro-

mocytomas may be of particular interest, since this subtype of angiotensin receptor is prevalent in the normal adrenal medulla.

Moreover, AT2 receptors were suggested to mediate the Ang II - induced inhibition of cell growth [17]. The strong reaction with AT2 antibody was found in some cases in the blood vessel walls and in the interstitial tissue. The reaction was absent in the control slides stained without primary antibody. However, the specificity of immunostaining in the interstitial tissue needs further investigations. If the discussed immunopositivity is specific, the earlier reports showing the expression of AT2 receptor mRNA in pheochromocytomas may be, at least in part, false positive. In turn, the strong expression of AT2 receptors in the walls of intratumoral vessels, as observed in some cases, was also reported by one of us in pituitary adenomas [18]. Interestingly, the AT2 block has been recently shown to inhibit retinal angiogenesis via suppression of the crucial factor involved in this process - vascular endothelial growth factor (VEGF) [19]. It suggests that the vascular over-expression of AT2 may have a role in tumoral neo-angiogenesis in both pituitary and adrenal tumors.

To conclude, AT1 and AT2 receptors are expressed in benign adrenocortical tumors roughly similarly to the non-tumoral adrenal cortex. It means that Ang II may affect their function and growth and be involved in adrenal tumorigenesis. In contrast, in malignant adrenocortical tumors and in pheochromocytomas (which are often potentially malignant neoplasms) the expression of Ang II receptors is altered. This alteration may reflect the process of dedifferentiation linked with malignancy but may also have some pathophysiological consequences.

Acknowledgements: This study was supported by the Medical University of Lodz. The skillful technical assistance of Mrs Maria Jaranowska, Mrs Małgorzata Jędrzejewska and Mrs Anna Opląowska is greatly appreciated.

References

- [1] McEwen PE, Lindop GB, Kenyon CJ. Control of cell proliferation in the rat adrenal gland in vivo by the renin-angiotensin system. *Am J Physiol.* 1996;271:E192-E198.
- [2] Tanabe A, Naruse M, Arai K, Naruse K, Yoshimoto T, Seki T, Imaki T, Kobayashi M, Miyazaki H, Demura H. Angiotensin II stimulates both aldosterone secretion and DNA synthesis via type 1 but not type 2 receptors in bovine adrenocortical cells. *J Endocrinol Invest.* 1998;21:668-672.
- [3] Pawlikowski M, Gruszka A, Mucha S, Melen-Mucha G. Angiotensins II and IV stimulate the rat adrenocortical cell proliferation acting via different receptors. *Endocrine Regul.* 2001;35:139-142.
- [4] Fallo F, Postorello M, Pedini F, D'Agostino D, Mantero F, Boscaro M. In vitro evidence for local generation of renin and angiotensin II/III immunoreactivity by the human adrenal gland. *Acta Endocrinol.* 1991;125:319-330.
- [5] Oda N, Takeda Y, Zhu A, Usukara M, Yoneda T, Takata H, Mabuchi H. Pathophysiological role s of the adrenal renin-angiotensin system in patients with primary aldosteronism. *Hypertens Res.* 2006;29:9-14.
- [6] Lu XY, KL Cove, Zhang W, Speth RC. Pharmacological characterization of angiotensin II AT2 receptor subtypee heterogeneity in the rat adrenal cortex and medulla. *Endocrine.* 1995; 3:255-261.
- [7] Naruse M, Tanabe A, Sugaya T, Naruse K, Yoshimoto T, Seki T, Imaki T, Demura R, Murakami K, Demura H. Differential role of angiotensin receptor subtypes in adrenocortical function in mice. *Life Sci.* 1998;63:1593-1598.
- [8] Tanabe A, Naruse M, Arai K, Naruse K, Yoshimoto T, Seki T, Imaki T, Miyazaki H, Zeng ZP, Demura R, Demura H. Gene expression and roles of angiotensin II type 1 and type 2 receptors in human adrenals. *Horm Metab Res.* 1998;30:490-495.
- [9] Cook MD, Philips MI, Cook VI, kimura B, Wilcox CSA. Angiotensin II receptor subtypes on adrenal adenoma in primary hyperaldosteronism. *J Am Soc Nephrol.* 1993;4:111-116.
- [10] Sarzani R, Opocher G, Dessi-Fulgheri P, Paci V, Cola G, Rocco S, Vianello B, Mantero F, Rappelli A. Expression of type 1 angiotensin II receptors in human aldosteronomas. *Endocr Res.* 1995;21:189-195.
- [11] Opocher G, Rocco S, Cimolato M, Vianello B, Arnaldi G, Mantero F. Angiotensin II receptors in cortical and medullary adrenal tumors. *J Clin Endocrinol Metab.* 1997;82:865-869.
- [12] Kitamura Y, Sasamura H, Maruyama T, Nakaya H, Amemiya T, Hayashi M, Saruta T. Adrenal angiotensin type 1 and type 2 receptors in Cushing's and Conn's syndrome. *Mol Cell Endocrinol.* 1998;144:37-45.
- [13] Chen YM, Wu KD, Hu-Tsai MI, Chu JS, Lai MK, Hsieh BS. Differential expression of type 1 angiotensin receptor mRNA and aldosterone responsiveness to angiotensin in aldosterone-producing adenoma. *Mol Cell Endocrinol.* 1999;25,152:47-55.
- [14] Schubert B, Fassnacht M, Beuschlein F, Zenkert S, Allolio B, Reincke M. Angiotensin II type1 receptor and ACTH receptor expression in human adrenocortical neoplasms. *Clinical Endocrinology.* 2001;54:627-632.
- [15] Tang SS, Rogg H, Schumacher R, Dzau VJ. Characterization of nuclear angiotensin II-binding sites in rat liver and comparison with plasma membrane receptors. *Endocrinology.* 1992;131:374-380.
- [16] Cook JL, Zhang Z, Re RN. In vitro evidence for an intracellular site of angiotensin action. *Circulation Res.* 2001;89: 1138-1146.
- [17] Wolf G, Harendza S, Schroeder R, Wenzel U, Zahner G, Butzmann U, Freeman RS, Stahl RA. Angiotensin II's antiproliferative effects mediated through AT2 receptors depend on down-regulation of SM-20. *J Lab Invest.* 2002;82: 1305-1317.
- [18] Pawlikowski M. Immunohistochemical detection of angiotensin receptors AT1 and AT2 in normal rat pituitary gland, estrogen-induced rat pituitary tumor and human pituitary adenomas. *Folia Histochem Cytobiol.* 2006;44:175-177.
- [19] Zhang N, Lassila M, Cooper ME, Cao Z. Retinal expression of vascular endothelial growth factor is mediated by angiotensin type 1 and type 2 receptors. *Hypertension.* 2004; 43:276-281.

Submitted: 28 August 2007

Accepted after reviews: 24 October 2007