

Reduction of Conjunctival Fibrosis After Trabeculectomy Using Topical α -Lipoic Acid in Rabbit Eyes

Metin Ekinci, MD,* Halil Hüseyin Çagatay, MD,† Erdiñç Ceylan, MD,‡
Sadullah Keles, MD,§ Yaran Koban, MD,† Gökçen Gokce, MD,||
Urfettin Huseyinoglu, MD,¶ Ece Ozcan, MD,# and Mehmet E. Oba, MD†

Purpose: To evaluate the efficacy of α -lipoic acid (ALA) in reducing scarring after trabeculectomy.

Materials and Methods: Eighteen adult New Zealand white rabbits underwent trabeculectomy. During trabeculectomy, thin sponges were placed between the sclera and Tenon's capsule for 3 minutes, saline solution, mitomycin-C (MMC) and ALA was applied to the control group (CG) (n = 6 eyes), MMC group (MMCG) (n = 6 eyes), and ALA group (ALAG) (n = 6 eyes), respectively. After surgery, topical saline and ALA was applied for 28 days to the control and ALAGs, respectively. Filtrating bleb patency was evaluated by using 0.1% trepan blue. Hematoxylin and eosin and Masson trichrome staining for toxicity, total cellularity, and collagen organization; α -smooth muscle actin immunohistochemistry staining performed for myofibroblast phenotype identification.

Results: Clinical evaluation showed that all 6 blebs (100%) of the CG had failed, whereas there were only 2 failures (33%) in the ALAG and no failures in the MMCG on day 28. Histologic evaluation showed significantly lower inflammatory cell infiltration in the ALAGs and CGs than the MMCG. Toxicity change was more significant in the MMCG than the control and ALAGs. Collagen was better organized in the ALAG than control and MMCGs. In immunohistochemistry evaluation, ALA significantly reduced the population of cells expressing α -smooth muscle action.

Conclusions: ALA prevents and/or reduces fibrosis by inhibition of inflammation pathways, revascularization, and accumulation of extracellular matrix. It can be used as an agent for delaying tissue regeneration and for providing a more functional-permanent fistula.

Key Words: α -lipoic acid, mitomycin-C, conjunctival fibrosis, trabeculectomy, scar formation

(*J Glaucoma* 2014;23:372–379)

Since its introduction by Cairns in 1968, trabeculectomy, with its relatively high success rate, has established itself

as the gold-standard technique among the surgical alternatives available for open-angle glaucoma.¹ The main cause of failure with this procedure has been attributed to excessive postoperative conjunctival scarring at the site of the filtering bleb.^{2–4} To reduce the wound-healing process and to inhibit the formation of unwanted scar tissue in challenging cases, antimetabolic agents such as mitomycin-C (MMC) and 5-fluorouracil may be used during trabeculectomy surgery. These agents are believed to improve the success rate of surgery by modulating fibroblast migration and/or proliferation,⁵ but their use is associated with a well-known high-complication rate.

α -lipoic acid (ALA) is an organosulfur compound with antioxidant, anti-inflammatory, antifibrotic properties, and has been used successfully in a wide range of nonocular pathologies.⁶ It is a key contributor to hepatoprotection by improving liver circulation.^{7,8} Its favorable effects on the treatment of diabetic neuropathy, on the prevention of atherosclerosis, and on cardiovascular diseases have been demonstrated.^{9–11} It has also been shown to reduce tissue inflammation and oxidation processes.^{12,13}

The aim of this study was to evaluate the histologic effects of postoperatively applied ALA on the conjunctival inflammation, scar tissue formation, and filtering bleb patency of rabbit eyes which underwent trabeculectomy, and to compare these results with those obtained with MMC.

MATERIALS AND METHODS

Eighteen eyes from 18 healthy New Zealand white albino male rabbits obtained from the Laboratory Animal Resource Center, Kafkas University (Kars, Turkey); aged 10 to 12 months and weighting between 3 and 3.5 kg were used in the study. The study was carried out in accordance with the Animal Ethical Guidelines for Investigations in Laboratory Animals and was approved by the Medical Experimental Research Ethics Committee of Kafkas University (KAÜ-HADYEK/2012-002). The rabbits were kept under standard conditions (20 ± 1°C, 12-h light/12-h dark cycles) and received humane care as outlined in the *Guide for the Care and Use of Laboratory Animals*.¹⁴

The animals were randomly divided into 3 groups: a control group (CG), an α -lipoic acid group (ALAG), and a mitomycin-C group (MMCG). Each group included the same number of eyes (n = 6). Limbus-based conjunctival incision was performed, and Tenon's capsule was dissected. After Tenon's capsule dissection; the MMCG received an antimetabolism drug administered with small (2 × 4 mm) lint impregnated with 0.25 mg/mL mitomycin (Mitomycin-C, Kyowa Hakko Kogyo, Japan), ALAG and CG received ALA and saline solution on the sclera and the Tenon's

Received for publication September 17, 2013; accepted March 4, 2014. From the *Kafkas University Medical School, Merkez, Departments of †Ophthalmology; ‡Anesthesiology; #Pathology, University of Kafkas; ||Sarıkamış Military Hospital Ophthalmology Clinic, Kars; ‡Erzurum Training and Research Hospital, Ophthalmology Clinic; and §Ophthalmology, University Of Atatürk, Erzurum, Turkey.

Disclosure: The authors declare no conflict of interest.

Reprints: Metin Ekinci, MD, Kafkas University Medical School, Merkez, Kars 36100, Turkey (e-mail: drmetinekinci@gmail.com).

This is an open-access article distributed under the terms of the Creative Commons Attribution-NonCommercial-NoDerivatives 3.0 License, where it is permissible to download and share the work provided it is properly cited. The work cannot be changed in any way or used commercially.

Copyright © 2014 by Lippincott Williams & Wilkins
DOI: 10.1097/IJG.0000000000000052

capsule for 3 minutes, respectively. The sponges were then removed and the surgical field was irrigated with copious amounts of balanced salt solution. Trapezoidal scleral flap was created and 3×1 mm trabeculectomy and peripheral iridectomy was performed. The ALAG received 1% ALA (Thioctacid 600t; MEDA, Hamburg, Germany) and CG received saline eye drops 5 times/d for 28 days. Twenty-eight days after trabeculectomy, the animals were killed, the trabecular region was removed, and the histopathologic and immunohistochemical analyses were performed by scoring the tissue changes and then comparing them among the 3 groups.

Samples were analyzed on the 28th day, because Miller and colleagues showed that in rabbits, 94% of blebs were closed on the 17th day, whereas in a study by Zhong and colleagues, their control group blebs were closed on day 12.8 ± 2.2 , and MMC group blebs were closed on day 19.0 ± 2.0 . In similar studies, Tina and colleagues reported that blebs were closed on the 16th day in the control group and on the 51.3rd day in the MMC group. Corderio and colleagues showed that in their control group, all blebs were closed by the 14th day. Tissues were taken from the rabbits on 28th day to account for the "bleb closure time" mentioned in the literature.^{15–18}

Anesthesia Procedure

Food was withheld from the animals for 12 hours before the operation. General anesthesia was performed intramuscularly with a combination of xylazine HCl (Rampun, 2%, Bayer; 5 mg/kg body weight) and ketamine HCl (Ketalar, 50 mg/mL, Pfizer; 50 mg/kg body weight). Before the surgical procedure, proparacaine HCl 0.5% (Alcaine, Alcon) was also applied as a topical anesthetic eye drop to produce a more analgesic effect. At the 28th post-operative day the rabbits were euthanized using an intracardiac injection of 1 mL Pentobarbital Sodium (Nembutal, Abbott, Turkey).

Surgical Procedure

Trabeculectomies were performed based on a standard study protocol: A 6 mm limbus-based conjunctival incision was produced 5 mm from the limbus. The underlying Tenon's capsule was opened and dissection was continued to the limbal area. Each rabbit underwent a limbus-based trabeculectomy. A half thickness trapezoidal scleral flap (3×2 mm) was created, starting 2 mm behind the limbus and continuing until the blade was just visible in the anterior corneal stroma. The anterior chamber was entered using a 45-degree blade. A piece of tissue containing the inner sclera, trabeculum, and peripheral cornea measuring approximately 3×1 mm was excised. Peripheral iridectomy was performed. The anterior chamber was filled and formed with ophthalmic viscosurgical device (1.8% Na Hyaluronate, Protectalon; VSY, Turkey). The scleral flap was closed with 10-0 nylon sutures (Ethicon; Johnson & Johnson; New Jersey, NJ). At the end of surgery, the conjunctiva was closed with 8/0 Vicryl sutures (Ethicon, Johnson & Johnson). All glaucoma filtration surgeries were performed by a single surgeon with experience in using the rabbit model (ME). Topical antibiotic drops [Tobramycin (Tobradex; Bilim İlaç, Istanbul, Turkey)] and antibiotic ointment (Tobradex; Bilim İlaç) was applied to all eyes for 14 days postoperatively. We did not prefer to use steroid and/or nonsteroid anti-inflammatory agents in order to assess the primary effectiveness of ALA.

Clinical Evaluation

After the surgery, macroscopic assessment and bleb function were controlled. Intraocular pressure was not collected as an endpoint as our specific metric of interest involved bleb function and histologic differences between groups. Macroscopic assessment was performed by Penlight to evaluate the presence of infection. To evaluate the filtering bleb patency, we injected 0.1 mL 0.1% trepan blue dye into the anterior chamber and observed its passage into the subconjunctival space. The dye applied into the anterior chamber by the same surgeon. Injections were applied without allowing excessive deepening of the anterior chamber and sudden increase in intraocular pressure.

In studies performed with in vitro human Tenon's capsular fibroblasts, it has been shown that trepan blue dye does not affect the antimetabolic effect of MMC. It has also been reported that during cataract surgery, trepan blue dye can be useful to evaluate filtering bleb patency and Baerveldt tube function by observing trepan blue passage into the subconjunctival space after injection of the dye into the anterior chamber.^{19–22}

Histologic Assessment

A large amount of tissue including the trabeculectomy site was removed using a lancet. The architecture of the superior fornix and conjunctival tissues around the drainage site was preserved. The tissues were fixed in 10% buffered formal saline for 24 hours, stored in 70% alcohol, and fixed in paraffin wax. Sequential 5- μ m sections of the operative wound site were prepared, and histologic staining was performed to demonstrate cellularity and extracellular matrix (ECM) deposition including: hematoxylin and eosin (for total cellularity), Masson trichrome frozen sections of 4- to 5- μ m thickness (for collagen organization) α -smooth muscle actin (α -SMA) immunohistochemistry (monoclonal mouse anti-human smooth muscle actin antibody, Clone 1A4; Dako, High Wycombe, UK) (for myofibroblast phenotype identification). The stained samples were observed under a Leica DM6000B photomicroscope and the parameters were graded randomly by 2 masked observers.

For evaluating cellularity, the polymorphonuclear leukocyte, plasmocyte, lymphocyte, and lymphoid aggregate and vascular structures were calculated in 1 magnification area ($40 \times$: magnifications).

For evaluating toxicity, analysis of the conjunctiva and the ciliary body were made and the findings were evaluated by scoring according to the grading systems published by Polak et al²³ and Aptel et al,²⁴ with slight modifications. The scale used for conjunctival changes was: 0 = no histologic change: no inflammation; 1 = minimal histologic change/conjunctiva epithelium preserved, thickening of conjunctiva; 2 = mild histologic change/conjunctiva epithelium preserved, thickening of conjunctiva, and mild inflammatory cell infiltration; 3 = moderate histologic change/score 2 with loss of collagen fibril organization; and 4 = severe histologic change: loss of conjunctival epithelium, total disorganization, and necrosis of the underlying scleral stroma. The scale used for ciliary body changes was: 0 = no histologic change; 1 = minimal histologic change/ciliary epithelium height normal, demonstrating minimal fibroblast proliferation, congestion, and edema, no fibrin; 2 = mild histologic change/ciliary epithelium height decreased, demonstrating moderate fibroblast proliferation with fibrin, moderate congestion and edema; 3 = moderate histologic change/score 2 with

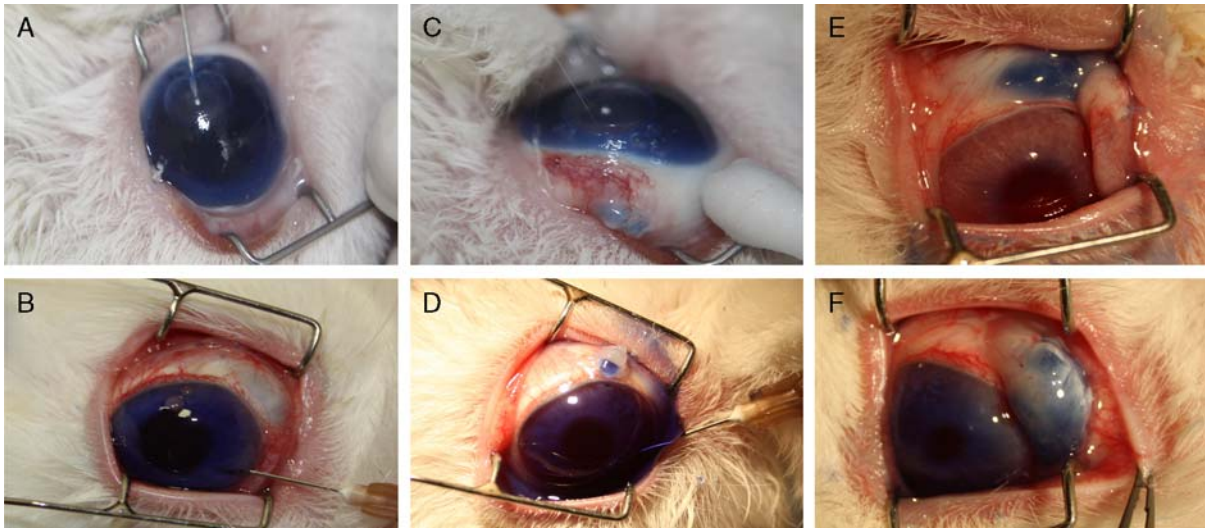


FIGURE 1. Evaluation of the filtering bleb patency by using 0.1% trepan blue dye. A and B, Failed blebs from the control group, (C and D) α -lipoic acid (ALA) group and (E and F) mitomycin-C (MMC) group filtering bleb patency and trepan blue dye passage into the subconjunctival space can be seen.

inflammatory cell infiltration; 4 = severe histologic change/desquamation of ciliary epithelium, total disorganization, and necrosis of ciliary body.

To evaluate the collagen organization we used a modified scoring system (which was based on that described by Janin-Manificat et al²⁵). The scale used for collagen organization was: 0 = no collagen disorganization/parallel mature collagen fibers; 1 = weak collagen disorganization/long, discrete collagen fibers; 2 = moderate collagen disorganization/shortened, focal perpendicular sequence of collagen fibers; and 3 = strong collagen disorganization/collagen fibers shortened and pointing in all directions.

For evaluating immunohistochemistry, the percentage of stained cells and the grade of staining were employed as criteria and a semiquantitative method was used: 0 = no

staining; 1 = weak staining; 2 = moderate staining; and 3 = strong staining. For sections, an immunohistochemistry score was calculated using “H-SCORE” (H-SCORE = I × PC; I, the grade of staining; and PC, the percentage of stained cells).²⁶

Statistical Analysis

All data were expressed as mean grade ± SD (mean ± SD). The histologic data were compared using Kruskal-Wallis nonparametric tests. Post hoc tests were performed with the Mann-Whitney *U* test. Values of *P* < 0.05 were regarded as significant. Calculations were performed using the Statistical Package for the Social Sciences (SPSS) version 18.0 system for personal computers (SPSS Inc., Chicago, IL).

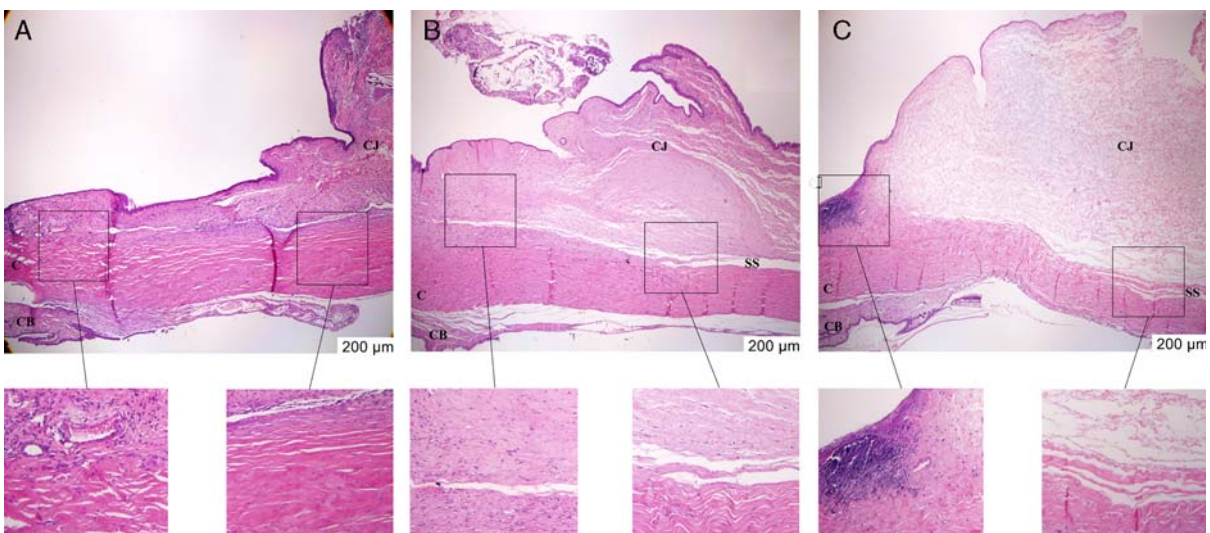


FIGURE 2. Histologic characteristics of the filtration site stained with hematoxylin and eosin on day 28. Tissues shown in (A) are from the control group, (B) is the ALA group, and (C) is the MMC group. Control group tissues show moderate inflammatory cells and closed sclerostomy. In the ALA group few inflammatory cells and fistula tract and in the MMC group severe inflammatory cells and fistula tract can be seen. ALA indicates α -lipoic acid; C, cornea; CB, ciliary body; CJ, conjunctiva; MMC, mitomycin-C; SS: sclerostomy site.

RESULTS

Experimental Details and Clinical Findings

Of the 18 rabbits observed for the duration of the 28-day experimental period, all completed the experimental protocol. No intraocular infection or cataract was observed. The tolerability of ALA drops was found very well and no side effect (conjunctival redness, chemosis, or discharge) was detected. When the filtering bleb patency was evaluated using 0.1% trepan blue dye, it was observed that all 6 blebs (100%) of control group had failed, whereas only 2 (33%) from the ALAG and none from the MMCG had failed on the 28th postsurgical day (Fig. 1). There was a statistically significant difference between CG and MMCG ($P = 0.002$), whereas the difference between CG and ALAG did not reach statistical significance ($P > 0.05$).

Histopathologic Features

Histologic analysis of the specimens was performed at the center of the sclerotomy site, as indicated by the location of the iridectomy.

Inflammatory cell infiltration was obviously lower in the ALA and control groups compared with the MMCG (Fig. 2). With respect to lymphocyte scores, there was a statistically significant difference between the MMC and ALA groups and between the MMC and control groups ($P < 0.05$). There was no statistically significant difference between ALA and control group scores ($P > 0.05$). There were no statistically significant differences among all groups when plasmocyte and lymphoid aggregate scores were evaluated. With respect to polymorphonuclear leukocyte scores, there was a statistically significant difference between the ALA and MMC groups and the ALA and control group scores ($P < 0.05$); there was no statistically significant difference between the MMC and control group scores ($P > 0.05$). With respect to vascular structure scores, there was statistically significant difference between the control and ALA groups, and the control and MMC groups ($P < 0.05$); there was no statistically significant difference between the ALA and MMC group scores ($P > 0.05$) (Table 1).

In the control group, mild histologic changes due to surgical trauma were observed in the conjunctiva and in the ciliary body. The conjunctival epithelium was preserved with mild inflammatory reaction, cell infiltration, and minimal thickening. The height of the epithelium of the ciliary body was normal. There was minimal fibroblast proliferation, congestion, and edema in the ciliary body. In the ALA group, minimal histologic changes were observed in the conjunctiva. The height of the conjunctival epithelium was normal, with minimal fibroblast proliferation, congestion, and edema. In the ciliary body, the height of the epithelium was normal, with minimal fibroblast proliferation, congestion, and edema. In the MMC group, the histologic changes observed in the conjunctiva were a decrease in the collagen density of the conjunctival epithelium, the loss of organization in the collagen fibrils, the slowing of mature collagen formation, epithelial cell loss, and increased inflammatory cell infiltration. The histologic changes observed in the ciliary body were a decrease in the height of pigmented and nonpigmented epithelium, the change of the cuboidal epithelium into a columnar epithelium, the accumulation of fibrin, and the disorganization of collagen fibers, with congestion and edema. When conjunctival and ciliary body toxicity scores were evaluated,

TABLE 1. Histopathologic Findings of Study Groups

Groups	Lymphocyte	Plasmocyte	Polymorphonuclear Leukocyte	Lymphoid Aggregate	Vascular Structures	Masson Trichrome Staining	α -SMA	Conjunctival Toxicity	Ciliary Body Toxicity
Control	8.67 ± 4.08	13.50 ± 13.28	13.67 ± 2.88	1.00 ± 0.89	8.33 ± 2.07	1.68 ± 0.52	170.83 ± 21.31	2.17 ± 0.41	1.50 ± 0.55
ALA	5.67 ± 1.21	5.00 ± 1.67	3.83 ± 2.04	0.83 ± 0.75	4.17 ± 1.17	0.33 ± 0.82	126.33 ± 28.12	0.83 ± 0.41	0.50 ± 0.55
MMC	18.67 ± 3.33	5.67 ± 0.82	16.67 ± 6.86	1.33 ± 1.03	5.17 ± 0.75	2.50 ± 0.55	70.83 ± 25.49	3.33 ± 0.52	2.83 ± 0.41
<i>P</i>	$\chi^2_{KW} = 11.974$ $P = 0.003$	$\chi^2_{KW} = 1.242$ $P = 0.537$	$\chi^2_{KW} = 11.366$ $P = 0.003$	$\chi^2_{KW} = 0.756$ $P = 0.685$	$\chi^2_{KW} = 11.871$ $P = 0.003$	$\chi^2_{KW} = 11.508$ $P = 0.003$	$\chi^2_{KW} = 12.785$ $P = 0.002$	$\chi^2_{KW} = 15.327$ $P = 0.000$	$\chi^2_{KW} = 13.798$ $P = 0.001$

ALA indicates α -lipoic acid; MMC, mitomycin-C; SMA, smooth muscle actin.

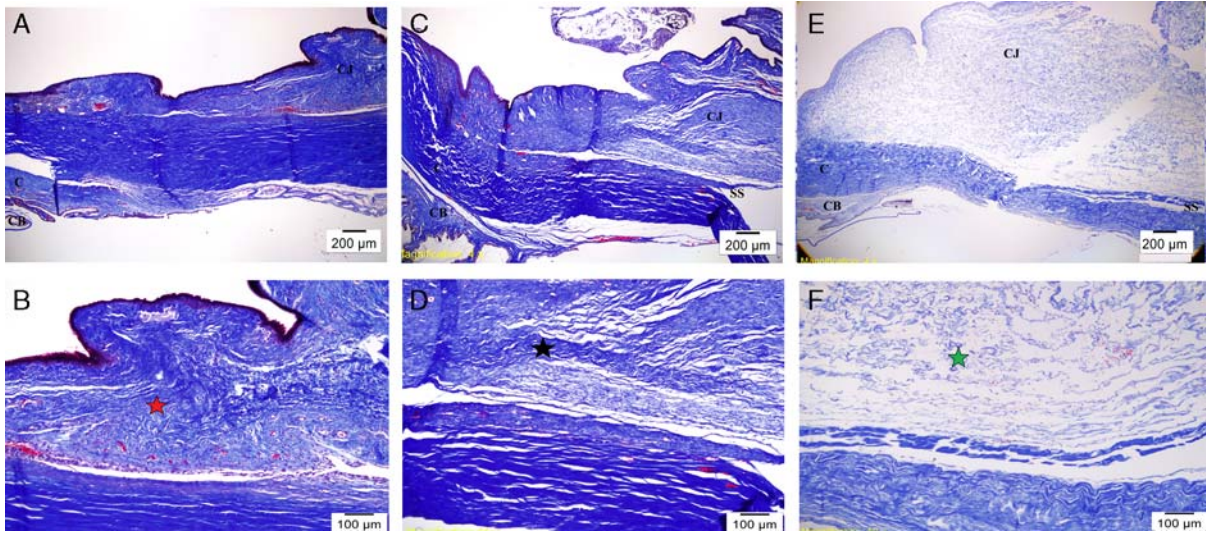


FIGURE 3. Tissues stained with Masson trichrome on day 28. Tissues shown in (A and B) are from the control group, (C and D) from the ALA group, and (E and F) from the MMC group. In the control group: moderate collagen disorganization/shortened, focal perpendicular sequence of collagen fibers. In the ALA group: weak collagen disorganization/long, discrete collagen fibers, and in the MMC group: strong collagen disorganization/shortened and pointing in all directions; collagen fibers can be seen. ALA indicates α -lipoic acid; C, cornea; CB, ciliary body; Cj, conjunctiva; MMC, mitomycin-C; SS: sclerostomy site. ★: moderate disorganization of collagen fibers. ★: weak disorganization of collagen fibers. ★: strong disorganization of collagen fibers.

there was statistically significant difference among all the groups (ALA < control < MMC) (Table 1).

Masson trichrome staining showed a shortened, focal perpendicular sequence of collagen fibers in the CG, organized collagen fibers in the ALAG, and collagen fibers that were much looser and pointed in all directions, hypocellular connective tissue, and rare blue collagen deposition in the MMC group (Fig. 3). When Masson trichrome collagen organization scores were evaluated, there were

statistically significant differences among all the groups (ALA < MMC < control) (Table 1).

When α -SMA staining scores (H-scores) were evaluated, there were statistically significant differences among all groups (MMC < ALA < control). ALA significantly reduced the population of cells expressing α -SMA, indicating less fibroblast differentiation into the myofibroblast phenotype ($P < 0.05$) when compared with the CG (Fig. 4) (Table 1).

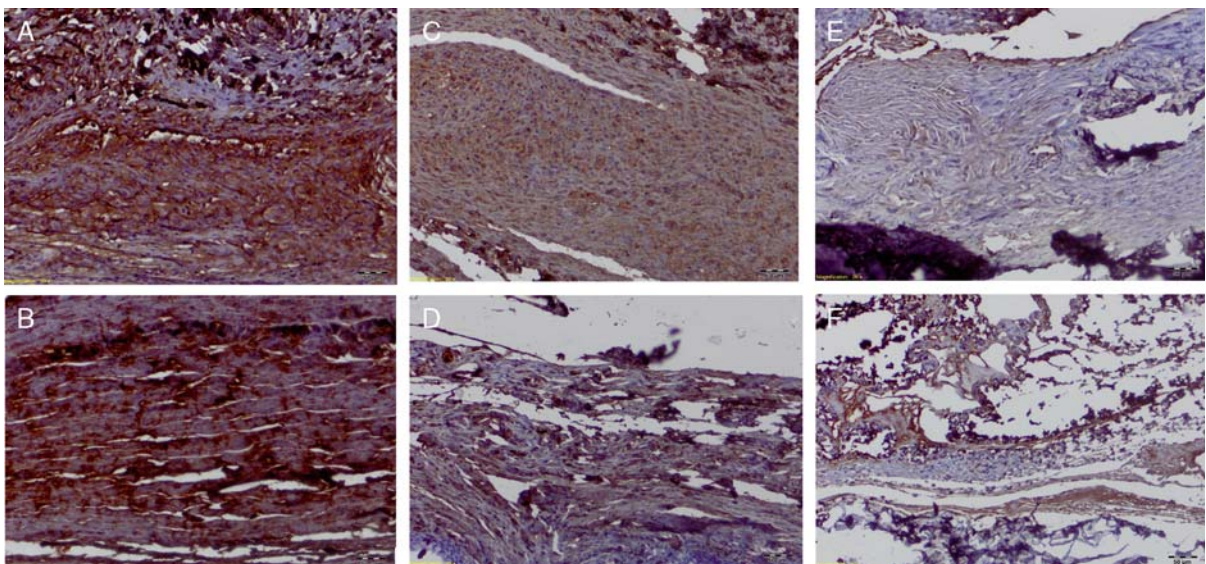


FIGURE 4. Immunohistochemical staining of filtration blebs on day 28. Tissues shown in (A and B) are from the control group, (C and D) is the ALA group and (E and F) is the MMC group. There was a reduction in the number of α -SMA-expressing cells in ALA(C-D) and MMC (E and F) groups compared with the control (A and B) group. The brown color stained the myofibroblasts (activated collagen secreting α -SMA⁺ fibroblast). ALA indicates α -lipoic acid; MMC, mitomycin-C; SMA, smooth muscle actin.

DISCUSSION

Trabeculectomy is a filtering procedure. Its long-term efficiency is entirely dependent on the permanency of the surgically created fistula. It is unanimously agreed that fistula obstruction arises from an abnormal subconjunctival tissue regeneration process.^{4,27} Many procedures have been developed to inhibit unwanted fibrotic activity in the trabeculectomy area, using different pharmacological agents with variable success. Among these, the most commonly used has been MMC perioperatively applied. However, its use has been reported to be associated with a high complication rate.¹⁶

In this study we investigated inhibitory effect of topically applied ALA on inflammation and proliferation; and we observed that it can be used as an agent to reduce scar tissue formation in trabeculectomy surgery and can provide filtering bleb patency, which increases the success of the surgery.

To the best of our knowledge, this is the first experimental study in which topical ALA has been used in rabbit eyes undergoing trabeculectomy to prevent scar tissue formation at the trabeculectomy area, and in which trepan blue dye has been used to evaluate filtering bleb patency.

Tissue healing is a very complex biological mechanism. It involves inflammation, inducing fibroblast proliferation, and revascularization as 2 main components. Angiogenesis is a key element of the proliferative phase of healing, supplying oxygen and nutrients to support the rapid growth of the cells and mediating repair.²⁸ Fibroblasts play the most important role in scar formation. When activated, they transform into myofibroblasts (activated collagen secreting α -SMA⁺ fibroblast).²⁹ Chronic inflammation and repair can trigger excessive accumulation of ECM components, which leads to the formation of fibrotic scarring. During this period, profibrotic cytokines and growth factors, such as transforming growth factor β (TGF- β), IL-13 and platelet-derived growth factor play a critical role.³⁰ Some chemokines/cytokines and their functions on tissue healing are shown in Table 2.

MMC is an antibiotic agent with antiproliferative properties and is classified as a cell cycle nonspecific alkylating agent. Thus, it inhibits both DNA replication and protein synthesis.³⁹ MMC causes DNA damage directly by generating OH-free radicals after a bioreductive process, causes apoptotic cell death by alkylating guanine in the

DNA structure, and activates caspase-3, caspase-8, and caspase-9, which causes apoptosis and necrosis.⁴⁰ The inhibition of DNA synthesis results in long-term inhibition of Tenon’s fibroblast proliferation.⁴¹ Despite the favorable effect of this agent on the long-term outcome of trabeculectomy, it is has been demonstrated that its perioperative use is associated with various complications such as toxicity to corneal endothelial cells, hypotony, blebitis, and endophthalmitis.¹⁶ In this study, we observed that in the MMC group there was high inflammatory cell infiltration, the collagen fibers were disorganized with a decrease in density, the ciliary body was congested, and the SMA-expressing cells were reduced. When the filtering bleb patency was evaluated on 28th day by using 0.1% trepan blue dye, it was observed that none of the blebs had failed.

Lipoic acid (LA) is derived from octanoic acid. The effects of ALA on chemokines/cytokines are shown in Table 2. In the literature, in various studies it is shown that ALA reduces the development of oral submucous fibrosis, postoperative peritoneal adhesions, fibrosis, and epidural fibrosis.⁴² Rats have been found to be protected by ALA against carbon tetrachloride (CCl₄)-induced liver fibrosis; possibly through its antioxidant activity, its capacity to induce matrix metalloproteinase-13, and through its inhibitory effect on the TGF- β .⁴³

Trivedi et al⁴⁴ showed that in the aqueous humor, glaucoma patients’ levels of TGF- β 2 (a strong profibrotic agent) are higher than those of nonglaucoma patients. In addition, Cvenkel et al⁴⁵ determined that in unsuccessful trabeculectomy surgery there are increased IL-6 and TNF- α levels in the aqueous humor. Previously, it has been shown that topical ALA, which is used as a drop, penetrates to the cornea and the anterior chamber of the eye and its concentration in the aqueous humor increases.⁴⁶ Studies have shown that ALA decreases TGF- β 2, IL-6 VE, and IL-11, and also decreases IL-1 and TNF- α .³⁸ According to above-mentioned literature, ALA penetrates to the anterior chamber and can decrease the levels of profibrotic agents TGF- β 2, IL-6, and TNF- α in the aqueous humor and the filtering bleb area, which supports the direct effects on the surgical area of topically applied ALA. In our study, less inflammatory cells infiltration and lower collagen fiber density were observed; the collagen fibers were better organized and the number of α -SMA-expressing cells was lower than for the control group. When the filtering bleb

TABLE 2. The Effect of ALA on Chemokines/Cytokines Which are Important in Tissue-healing Process

Chemokines/Cytokines	Function in Tissue Healing	Effect of ALA
Transforming growth factor- β (TGF- β)	Inhibition of matrix protein removal ³¹ Stimulation of the expression of protease inhibitors including plasminogen activator inhibitor-1 (PAI-1) ³²	Inhibition of TGF- β
Plasminogen activator inhibitor-1	Accumulation of ECM Inhibition of fibrinolysis Inhibition of plasmin and metalloproteinase-mediated ECM degradation ³³	Decreases TGF- β -induced PAI-1 expression ³⁶
Reactive oxygen species (ROS)	Inhibition of the deposition of ECM ³⁴	Inhibition of ROS-induced endothelial injury ³⁷
Interleukin-6 and interleukin-17	Regulation of the expression of other important cytokines such as interleukin-1 and TNF- α ³⁵	Decreases serum Interleukin-6 and interleukin-17 levels. ³⁸
Adhesion molecule-1 (ICAM-1) and vascular cell adhesion molecule (VCAM-1)	Key roles on angiogenesis	Prevents upregulation of ICAM-1 and VCAM-1 ³⁸

ALA indicates α -lipoic acid; ECM, extracellular matrix.

patency was evaluated using 0.1% trypan blue dye, it was observed that 2 (33%) blebs had failed in the ALAG on 28th day. This result did not reach statistical significance when compared with the control group, but in our opinion, and as Whitley et al⁴⁷ and Petrie et al⁴⁸ defined, a result can be of clinical significance but not statistical significance because of a small number of subjects.

All the above-mentioned studies and our findings indicate that ALA may be able to prevent and/or reduce fibrosis in the human body, by inhibiting the pathways of inflammation, revascularization, and the accumulation of ECM.

In the literature it has been reported that topically instilled trehalose onto eyes after simple conjunctival incision or trabeculectomy,⁴⁹ intraoperative subconjunctival implantation of a sustained-release dexamethasone implant,⁵⁰ at a concentration of 0.2 mg/mL, or postoperative subconjunctival injections of Iomostat¹⁷ and postoperative use of 0.5% pirlfenidone eye drops¹⁶ prolongs bleb survival and may also act as a potential adjuvant treatment when MMC alone is inadequate.

The weaknesses of our study are as follows: we determined the doses of ALA as $5 \times 1/d$ independently, due to the lack of reference to the use of ALA as drops in the literature. We used hematoxylin and eosin staining for the identification of inflammatory and endothelial cells in our study but instead we could have used specific immune staining. Only the bleb function was evaluated in our study; a more detailed evaluation could be done by adding the bleb area/calculated volume and bleb vascularity; to the study.

In conclusion, this study shows that peroperatively and postoperatively topically applied ALA may regulate scar tissue formation at the site of trabeculectomy by blocking collagen synthesis, delays tissue regeneration and provides a more functional and permanent fistula in rabbit eyes. ALA can be used as a potential adjuvant agent when MMC alone is inadequate. Clinical studies are needed to investigate the safety of the topical application of ALA in human eyes, and its long-term efficacy in reducing scar tissue formation in the postoperative period of trabeculectomy.

REFERENCES

- Cairns JE. Trabeculectomy—a preliminary report of a new method. *Am J Ophthalmol*. 1968;66:673–679.
- Skuta GL, Parrish RK II. Wound healing in glaucoma filtering surgery. *Surv Ophthalmol*. 1987;32:149–170.
- Mietz H, Arnold G, Kirchhof B, et al. Histopathology of episcleral fibrosis after trabeculectomy with and without mitomycin C. *Graefes Arch Clin Exp Ophthalmol*. 1996;234:364–368.
- Bruno C, Fisher G, Moroi S. Is “scarless wound healing” applicable to glaucoma surgery? *Expert Rev Ophthalmol*. 2007;2:79–90.
- Crowston JG. Long-term outcomes of trabeculectomy. *Clin Exp Ophthalmol*. 2008;36:705–706.
- Raddatz G, Bisswanger H. Receptor site and stereospecificity of dihydro-lipoamide dehydrogenase for R- and S-lipoamide: a molecular modeling study. *J Biotechnol*. 1997;58:89–100.
- Murabayashi A, Yamada M. Effects of the oral administration of hepatoprotective drugs on the prevention of hepatic disorders after lung surgery. *Kyobu Geka*. 1964;17:372–374.
- Kummer P, Ott A. Studies on liver circulation under the influence of thioctic acid and other medications. *Munch Med Wochenschr*. 1959;101:2399–2402.
- Mijnhout GS, Alkhalaf A, Kleefstra N, et al. Alpha lipoic acid: a new treatment for neuropathic pain in patients with diabetes? *Neth J Med*. 2010;68:158–162.
- Ying Z, Kherada N, Farrar B, et al. Lipoic acid effects on established atherosclerosis. *Life Sci*. 2010;86:95–102.
- Ghibu S, Richard C, Vergely C, et al. Antioxidant properties of an endogenous thiol: alpha-lipoic acid, useful in the prevention of cardiovascular diseases. *J Cardiovasc Pharmacol*. 2009;54:391–398.
- Zhang WJ, Wei H, Hagen T, et al. Alpha-lipoic acid attenuates LPS-induced inflammatory responses by activating the phosphoinositide 3-kinase/Akt signaling pathway. *Proc Natl Acad Sci*. 2007;104:4077–4082.
- Abdin AA, El-Hamid MA, El-Seoud SH, et al. Effect of pentoxifylline and/or alpha lipoic acid on experimentally induced acute pancreatitis. *Eur J Pharmacol*. 2010;643:289–296.
- Nationale Research Council. *Guide for the Care and Use of Laboratory Animals*. Washington, DC: National Academy Press; 1996.
- Miller MH, Grierson I, Unger WI, et al. Wound healing in an animal model of glaucoma fistulizing surgery in the rabbit. *Ophthalmic Surg*. 1989;20:350–357.
- Zhong H, Sun G, Lin X, et al. Evaluation of pirlfenidone as a new postoperative antiscarring agent in experimental glaucoma surgery. *Invest Ophthalmol Vis Sci*. 2011;52:3136–3142.
- Wong TT, Mead AL, Khaw PT. Prolonged antiscarring effects of ilomostat and MMC after experimental glaucoma filtration surgery. *Invest Ophthalmol Vis Sci*. 2005;46:2018–2022.
- Cordeiro MF, Constable PH, Alexander RA, et al. Effect of varying the mitomycin-C treatment area in glaucoma filtration surgery in the rabbit. *Invest Ophthalmol Vis Sci*. 1997;38:1639–1646.
- Jhanji V, Chan E, Das S, et al. Trypan blue dye for anterior segment surgeries. *Eye*. 2011;25:1113–1120.
- Agrawal S, Agrawal J, Agrawal TP. Use of trypan blue to confirm the patency of filtering surgery. *J Cataract Refract Surg*. 2005;31:235–237.
- Dada T, Muralidhar R, Sethi HS. Staining of filtering bleb with trypan blue during phacoemulsification. *Eye (Lond)*. 2006;20:858–859.
- Grigg J, Jang JD, Fung AT, et al. Trypan blue to assess Baerveldt tube patency after repair of its obstruction. *J Glaucoma*. 2011;20:571–572.
- Polak MB, Valamanesh F, Felt O, et al. Controlled delivery of 5-chlorouracil using poly(ortho esters) in filtering surgery for glaucoma. *Invest Ophthalmol Vis Sci*. 2008;49:2993–3003.
- Aptel F, Charrel T, Palazzi X, et al. Histologic effects of a new device for high-intensity focused ultrasound cyclocoagulation. *Invest Ophthalmol Vis Sci*. 2010;51:5092–5098.
- Janin-Manificat H, Rovère MR, Galiacy SD, et al. Development of ex vivo organ culture models to mimic human corneal scarring. *Mol Vis*. 2012;18:2896–2908.
- Çırpanlı T, Terek MC, Özçakır HT, et al. Evaluation of VEGF, EGF-R and TGF- α in placenta of pregnancies with preeclampsia by immunohistochemistry. *N TJOD Derg*. 2008;5:40–45.
- Yu DY, Morgan WH, Sun X, et al. The critical role of the conjunctiva in glaucoma filtration surgery. *Prog Retin Eye Res*. 2009;28:303–328.
- Wilgus TA, Ferreira AM, Oberyszyn TM, et al. Regulation of scar formation by vascular endothelial growth factor. *Lab Invest*. 2008;88:579–590.
- Honjo M, Tanihara H, Kameda T, et al. Potential role of Rho-associated protein kinase inhibitor Y-27632 in glaucoma filtration surgery. *Invest Ophthalmol Vis Sci*. 2007;48:5549–5557.
- Wynn TA. Cellular and molecular mechanisms of fibrosis. *J Pathol*. 2008;214:199–210.
- Liu X, Hu H, Yin JQ. Therapeutic strategies against TGF- β signaling pathway in hepatic fibrosis. *Liver Int*. 2006;26:8–22.
- Nakamura T, Ueno T, Sakamoto M, et al. Suppression of transforming growth factor- β results in upregulation of

- transcription of regeneration factors after chronic liver injury. *J Hepatol*. 2004;41:974–982.
33. Wang H, Zhang Y, Heuckeroth RO. Tissue-type plasminogen activator deficiency exacerbates cholestatic liver injury in mice. *Hepatology*. 2007;45:1527–1537.
 34. Hui AY, Friedman SL. Molecular basis of hepatic fibrosis. *Expert Rev Mol Med*. 2003;5:1–23.
 35. Salinthon S, Yadav V, Schillace RV, et al. Lipoic acid attenuates inflammation via cAMP and protein kinase A signaling. *PLoS One*. 2010;5: pii: e13058.
 36. Min AK, Kim MK, Seo HY, et al. Alpha-lipoic acid inhibits hepatic PAI-1 expression and fibrosis by inhibiting the TGF-beta signaling pathway. *Biochem Biophys Res Commun*. 2010;393:536–541.
 37. Lee WJ, Lee IK, Kim HS, et al. Alpha-lipoic acid prevents endothelial dysfunction in obese rats via activation of AMP activated protein kinase. *Arterioscler Thromb Vasc Biol*. 2005;25:2488–2494.
 38. Chaudhary P, Marracci GH, Bourdette DN. Lipoic acid inhibits expression of ICAM-1 and VCAM-1 by CNS endothelial cells and T cell migration into the spinal cord in experimental autoimmune encephalomyelitis. *J Neuroimmunol*. 2006;175:87–96.
 39. Salmon SE, Sartorelli AC. Cancer chemotherapy. In: Katsung BG, ed. *Basic and Clinical Pharmacology*. 3rd ed. Norwalk, CT: Appleton and Lange; 1987:680–681.
 40. Wu KY, Wang HZ, Hong SJ. Mechanism of mitomycin induced apoptosis in cultured corneal endothelial cells. *Mol Vis*. 2008;14:1705–1712.
 41. Lam DS, Wong AK, Fan DS, et al. Intraoperative mitomycin C to prevent recurrence of pterygium after excision: a 30-month follow-up study. *Ophthalmology*. 1998;105:901–904.
 42. Kaya M, Yildirim CH, Kosemehmetoglu K, et al. Alpha-lipoic acid reduces peridural fibrosis after laminectomy of lumbar vertebrae in rabbits. *Acta Neurochir (Wien)*. 2012;154:1241–1245.
 43. Morsy MA, Abdalla AM, Mahmoud AM, et al. Protective effects of curcumin, α -lipoic acid, and N-acetylcysteine against carbon tetrachloride-induced liver fibrosis in rats. *J Physiol Biochem*. 2012;68:29–35.
 44. Trivedi RH, Nutaitis M, Vroman D, et al. Influence of race and age on aqueous humor levels of transforming growth factor-beta 2 in glaucomatous and nonglaucomatous eyes. *J Ocul Pharmacol Ther*. 2011;27:477–480.
 45. Cvenkel B, Kopitar AN, Ihan A. Inflammatory molecules in aqueous humour and on ocular surface and glaucoma surgery outcome. *Mediat Inflamm*. 2010;2010:939602.
 46. Cagini C, Leontiadis A, Ricci MA, et al. Study of alpha-lipoic acid penetration in the human aqueous after topical administration. *Clin Exp Ophthalmol*. 2010;38:572–576.
 47. Whitley E, Ball J. Statistics review 4: sample size calculations. *Crit Care*. 2002;6:335–341.
 48. Petrie A, Bulman JS, Osborn JF. Further statistics in dentistry. Part 4: clinical trials 2. *Br Dent J*. 2002;193:557–561.
 49. Takeuchi K, Nakazawa M, Ebina Y, et al. Inhibitory effects of trehalose on fibroblast proliferation and implications for ocular surgery. *Exp Eye Res*. 2010;91:567–577.
 50. SooHoo JR, Seibold LK, Laing AE, et al. Bleb morphology and histology in a rabbit model of glaucoma filtration surgery using Ozurdex or mitomycin-C. *Mol Vis*. 2012;18:714–719.