ORIGINAL ARTICLE

Combined use of optical coherence tomography and intravascular ultrasound imaging in patients undergoing coronary interventions for stent thrombosis

Fernando Alfonso, Jaime Dutary, Manuel Paulo, Nieves Gonzalo, Maria J Pérez-Vizcayno, Pilar Jiménez-Quevedo, Javier Escaned, Camino Bañuelos, Rosana Hernández, Carlos Macaya

See Editorial, p 1187

Department of Interventional Cardiology, Cardiovascular Institute, Clínico San Carlos University Hospital, Madrid, Spain

Correspondence to
Dr Fernando Alfonso, Interventional Cardiology, Cardiovascular Institute, Clínico 'San Carlos' University Hospital, IdISSC, Ciudad Universitaria, Plaza de Cristo Rey, Madrid 28040, Spain; falf@hotmail.com

Accepted 17 April 2012

ABSTRACT

Objective This prospective study sought to assess the diagnostic value of optical coherence tomography (OCT) compared with intravascular ultrasound (IVUS) in patients presenting with stent thrombosis (ST).

Design and setting Although the role of IVUS in this setting has been described, the potential diagnostic value of OCT in patients suffering ST remains poorly defined. Catheterization Laboratory, University Hospital.

Patients and interventions Fifteen consecutive patients with ST undergoing rescue coronary interventions under combined IVUS/OCT imaging guidance were analysed.

Mean outcome measures Analysis and comparison of OCT and IVUS findings before and after interventions.

Results Before intervention, OCT visualised the responsible thrombus in all patients (thrombus area 4.7±2.5 mm^2, stent obstruction 82±14%). Minimal stent area was 4.7±2.1 mm^2 leading to severe stent underexpansion (expansion 60±21%). Although red or mixed thrombus (14 patients) induced partial strut shadowing (total length 12.3±6 mm), malapposition (six patients), inflow-outflow disease (five patients), uncovered struts (nine patients) and associated in-stent restenosis (five patients, four showing neoatherogenesis) was clearly recognised. IVUS disclosed similar findings but achieved poorer visualisation of thrombus—lumen interface and strut malapposition, and failed to recognise uncovered struts and associated neoatherosclerosis. After interventions, OCT demonstrated a reduced thrombus burden (2.4±1.6 mm^2) and stent obstruction (24±14%) with improvements in stent area (6.8±2.9 mm^2) and expansion (75±21%) (all $p<0.05$). IVUS and OCT findings proved to be complementary.

Conclusions OCT provides unique insights on the underlying substrate of ST and may be used to optimise results in these challenging interventions. In this setting, OCT and IVUS have complementary diagnostic values.

Stent thrombosis (ST) represents a rare but dreaded complication following percutaneous coronary interventions (PCI).[1 2] Despite early successful management, this complication remains associated with significant morbidity and mortality.[1 2] Therefore, new insights on potential predisposing factors and preventive strategies would be of major clinical value. Likewise, additional information to guide and optimise the results of rescue PCI in these challenging patients would be of paramount importance.

The pathophysiology of ST appears to be multifaceted. Mechanical factors, related to the implanted stent, may provide a predisposing '*vulnerable*' underlying substrate.[2] Alternatively, a *thrombogenic milieu* (including enhanced platelet reactivity, stagnant flow or delayed endothelisation), appears to play a critical role to trigger ST.[2] Both etiologies are likely implicated in most patients suffering from this feared complication.

Intravascular ultrasound (IVUS) has been classically used to gain morphological information in patients undergoing coronary stenting.[3] IVUS enables to detect mechanical problems (underexpansion, malapposition, edge-dissections and residual inflow-outflow disease) after stent implantation.[3–7] Notably, most of these are not recognised by coronary angiography. Therefore, the use of IVUS has been proposed in patients with ST to unravel potentially predisposing factors, and to optimise results of repeated interventions.[4–7] More recently, optical coherence tomography (OCT) has become available for clinical use.[8–11] OCT has a unique resolution (15 μm), 10 times higher than IVUS.[8] However, its potential value in the diagnosis and treatment of ST remains unsettled.

In this prospective study, we sought to assess the diagnostic value of OCT in patients suffering from ST. We compared OCT and IVUS findings during PCI in this challenging setting.

METHODS

Patients and interventions

From October 2008 to April 2011, 15 consecutive patients suffering from ST and undergoing rescue PCI under combined OCT and IVUS imaging guidance were included in this prospective study. Our protocol in patients experiencing ST has been previously described.[4 7] Whenever feasible, both IVUS and OCT were performed before and after interventions. However, patient safety was emphasised and pre-intervention OCT/IVUS imaging was only performed in hemodynamically stable patients with re-established anterograde flow. In patients with only a TIMI 0-1 coronary

flow after guidewire crossing, the advancement of a previously inflated, small-diameter, balloon catheter across the target stent (without inflation) was suggested to obtain a TIMI 2 flow.[4 7] However, if this manoeuvre failed to guarantee an adequate anterograde coronary flow direct thrombus aspiration was performed before imaging.

Patients received at least 300 mg of aspirin and were pretreated with a loading dose of 600 mg of clopidogrel at the diagnosis of ST. The use of IIbIIIa platelet inhibitors was strongly recommended as adjunctive therapy. Unfractionated heparin was administered (100 IU/Kg or 70 IU/Kg in patients receiving IIbIIIa platelet inhibitors) and subsequently monitored (activated clotting time) to ensure an adequate anticoagulation throughout the procedure. Based on our previous experience in these procedures, thrombus aspiration followed by relatively high-pressure dilations with non-compliant balloons was also recommended.[4 7] Balloon size and final pressures were chosen after reviewing the material used during the initial procedure, the angiographic results and IVUS/OCT findings. Stent under-expansion and malapposition were aggressively managed with high-pressure dilations and larger balloons, respectively.[4 7] Repeat stenting was discouraged but this technique was selected to tackle residual dissections, severe inflow/outflow disease or adjacent ruptured plaques. No specific quantitative IVUS or OCT criteria were predefined to guide repeated interventions, and the degree of optimisation based upon image findings was left to the judgement of the attending interventional cardiologist.

The ARC criteria were used to define ST.[12] All patients included in this study fulfilled the criteria for 'definitive' ST, and all of them showed an occluded stent or an angiographic filling defect highly suggestive of a stent-related thrombus.[12 13] Serial ECG and enzyme determinations were systematically obtained for 48 h after interventions. Patients were discharged on aspirin (300 mg/day) and clopidogrel (75 mg/day) for at least 1 year.

The protocol of intravascular imaging in patients suffering ST in our institution has been previously described in detail.[4 7] The current study was performed according to the provisions of the Declaration of Helsinki. All patients gave informed consent to the procedure.

Angiographic analysis

Intracoronary nitroglycerin was systematically administered (200 μg) at the culprit coronary artery, and multiple angulated projections were obtained. Care was taken to avoid views inducing foreshortening or side-branch overlap on the target coronary segment (culprit stent). High-resolution digital angiography (30 images/s) was used in selected cases. The TIMI grade classification was used to assess coronary flow. Qualitative angiographic characteristics were evaluated using conventional angiographic criteria.[13]

Off-line, quantitative coronary angiography (CASS II, System, Pie Medical, Maastricht, The Netherlands) was performed by experienced personnel blinded to the results of the imaging techniques, using standard methodology.[7 13]

Optical coherence tomography

Initial studies (two patients) were performed with time-domain systems (Image wire, M3, Light Lab Imaging, Inc, Westford, Massachusetts, USA), but since 2009 (13 patients), frequency-domain systems (C7-XR and Dragon Fly, Light Lab, St. Jude Medical, USA) were used. The latest technology enabled faster pullbacks (20 mm/s) and unrestricted visualisation of relatively long coronary segments.[8 14] The non-occlusive flushing technique was always used to remove blood from the vessel using contrast media. In cases where the OCT catheter was wedged within the thrombus, thereby obstructing coronary flow, visualisation of distal structures was attempted by simultaneously injecting contrast media through the distal port of the imaging catheter (gently flushing) in addition to conventional flushing through the guiding catheter. Before starting the automatic pullback, the radiopaque catheter tip marker was positioned 10 mm beyond the distal edge of the stent. When suboptimal image quality was obtained, the pullback was repeated after modifying the engagement of the guiding catheter, flushing intensity or probe position. Qualitative OCT features were jointly analysed by two observers. Thrombus was classified according to border and backscatter signal characteristics (red thrombus: signal-rich protrusions inducing dorsal shadowing, white thrombus: signal-rich protrusions without shadowing) using previously defined criteria.[15–18] Malapposition was considered in the presence of stent struts detached from the vessel wall on visual assessment after magnification.[8 14] Number and maximum arc of malapposed struts and its association with intracoronary thrombus was assessed. Uncovered struts were defined as those without any identifiable material on their surface, also after magnification.[15–18] The presence of residual dissections at the edges of the stent or significant residual atherosclerotic plaque was analysed.[8 14]

Quantitative offline OCT measurements were performed using proprietary software (LightLab Imaging, Westford, Massachusetts, USA). Care was taken to adjust the z-offset to ensure adequate calibration. Malapposition maximal distance, area and length were measured. Minimal stent area, minimal lumen area and reference segment lumen were measured. Stent area was not analysed when thrombus shadowing was >1 quadrant. Maximal thrombus area, maximal stent obstruction (thrombus area/stent area) and thrombus length were also determined. All features were carefully reviewed along the entire length of the image sequence using the longitudinal OCT image display for additional guidance. Findings were re-evaluated once coronary flow was re-established, and also at the end of the procedure.

Intravascular ultrasound

IVUS studies were performed using commercially available mechanical catheters (Atlantis SR Pro, 40-MHz catheter; Boston Scientific, Fremont, California, USA) with a motorised pullback at 0.5 mm/s.[4 7] Qualitative IVUS findings were analysed jointly by two expert observers following previously reported criteria.[4 7] Thrombus was defined as any protruding echogenic material within the stent.[4 7] In cases of associated neointimal proliferation, however, the morphological appearance seen in adjacent frames, together with the distinct echogenicity and scintillating patterns, were used for thrombus recognition. Malapposition was defined as a lack of contact between at least one stent strut and the underlying vessel wall showing blood speckling and not encompassing the take-off of side-branches.[4 7]

Quantitative analyses were performed using a validated system (QIVUS, Medis, Leiden, The Netherlands). Reference segments were selected as the most normal-looking segment within 10 mm proximal and distal to the stent edge. Minimal lumen area, minimal stent area, maximal thrombus burden, maximal stent obstruction (maximal thrombus/stent area) and maximal malapposition area were identified. Matching of the target segment, pre- and post-intervention, was ensured by comparison of IVUS sequences after identifying the stent edges and related side-branches as fiduciary sites. Stent

underexpansion was defined as a minimum stent area <80% of the reference lumen area.[4 7] The MUSIC criteria for expansion were also evaluated.[19]

Statistical analysis

Continuous variables are presented as mean (±SD) or median (IQR). Normality was assessed with the Kolmogorov–Smirnov test. The Student's t-test or the median test (continuous data), and the χ^2, Fisher's exact test or the McNemar test (cualitative variables), were used, where appropriate, to check differences between groups. A p value <0.05 was considered statistically significant.

RESULTS

Baseline clinical characteristics of the study patients are presented in table 1. Most STs occurred late (n=2) or very late (n=7) after stenting. All patients presented with an acute myocardial infarction. Five patients initially seen in other centres received thrombolysis before angiography. Angiographic characteristics are summarised in table 2. All patients showed angiographic evidence of stent-related thrombus, and 11 had a TIMI flow <2. Results of quantitative coronary angiography at the time of stent implantation and after the rescue interventions are summarised in table 2. Thrombus aspiration and intracoronary administration of IIbIIIa platelet inhibitors were used in most patients. Very high final dilation pressures were eventually required to ensure adequate results (table 2). In five patients, additional stents were used to treat residual dissections or edge disease.

Intracoronary imaging was performed before any intervention in 13 patients. In two patients, however, pre-intervention imaging was only possible after thrombus aspiration (n=1) or pre-dilation with an undersized balloon (n=1). In two patients with ST located at segments of stent overlap, pre-intervention advancement of IVUS catheters was difficult, and the most distal part of the stents could not be visualised (OCT catheters, however, were easily advanced in these patients).

Table 1 Baseline clinical characteristics

Age (years)	64±11
Male	15 (100%)
Risk factors	
Smoking	7 (45%)
Diabetes mellitus	5 (33%)
Hypertension	12 (80%)
Hyperlipidaemia	13 (87%)
Initial (original) stent for acute coronary syndrome	12 (80%)
ST on dual antiplatelet therapy	7 (47%)
Early* clopidogrel withdrawal	1 (7%)
Time elapsed from initial stent implantation (days)	1288±1524 (median 347, IQR 27–2452)
Time from initial symptoms to diagnosis (hours)	28±48 (median 12, IQR 5–24)
Thrombolytic therapy before angiography	5 (33%)
Clinical presentation	
STEMI	11 (73%)
NSTEMI	4 (27%)
Clinical outcome during hospitalisation	
CPK (IU)/peak	2435±2606
Q-wave myocardial infarction	10 (67%)

*Before 1 month after bare-metal stent, and 1 year after drug-eluting stent.
ST, stent thrombosis; STEMI, ST-segment elevation myocardial infarction; NSTEMI, Non-ST-segment elevation myocardial infarction.

Table 2 Angiographic and procedural characteristics

Multivessel disease	11 (73%)
Stents in other vessels	7 (47%)
Left ventricular ejection fraction (%)	43±15
Culprit vessel	
LAD	6 (40%)
LCX	5 (33%)
RCA	4 (27%)
Angiographic thrombus	15 (100%)
Initial TIMI grade (0/1/2/3)	(10/1/1/3)
Multiple stenting	7 (47%)
Stent overlap	6 (40%)
Stent type (DES/BMS)	(7/8)
Quantitative coronary angiography	
After initial (original) stent implantation	
Reference diameter (mm)	2.8±0.5
Minimal lumen diameter (mm)	1.9±0.6
Diameter stenosis (%)	32±11
After the repeated intervention for ST	
Reference diameter (mm)	2.5±0.3
Minimal lumen diameter (mm)	2.1±0.5
Diameter stenosis (%)	21±15*
Procedural chracateristics	
Initial (original) stent implantation	
Maximal pressure (atm)	17.7±6
Largest balloon used	3.2±0.4
During rescue interventions for ST	
Maximal pressure (atm)	25.6±5**
Largest balloon used	3.3±0.6
IIbIIIa platelet inhibitors	10 (67%)
Thrombus aspiration catheters	11 (74%)
Additional stents required (DES/BMS)	5 (33%) 3/2

*p<0.05 (vs initial stent), **p<0.01 (vs pre-intervention).
LAD, left anterior descending coronary artery; LCX, left circumflex artery; RCA, right coronary artery; DES, drug-eluting stents (3 paclitaxel-eluting and 4 everolimus-eluting stents); BMS, bare-metal stents.

Main IVUS findings are displayed in table 3. All patients showed an occlusive thrombus within the stent. All stents showed underexpansion, and only two patients fulfilled the MUSIC criteria for optimal stent implantation (figures 1 and 2). In six patients (40%), malapposition was visualised; five at the initial examination and one after thrombus aspiration (figure 2). Edge-dissections were only recognised in two patients, but proximal or distal disease was frequent (table 3). Associated neoatherosclerosis was not recognised by IVUS in any patient. However, in eight patients, severe calcification (napkin-ring image) was visualised at the area showing stent underexpansion. At these segments, individual stent struts were poorly recognised. Maximal stent asymmetry (table 3) tended to be located at heavily calcified areas. Images suggestive of stent fracture were not identified in any patient. After the procedure, stent expansion improved, thrombus size was reduced and extent of malapposition was diminished (table 3). However, residual-lining thrombi were detected in most patients and, despite high-pressure dilations, residual malapposition was still recognised on IVUS in four patients.

Main OCT findings are summarised in table 4. Several runs were required to visualise the entire stent segment. In some cases, sequential pullbacks were needed to obtain overlapping imaging sequences encompassing the entire stent segment, but in two patients, at least one edge of the stent could not be visualised. Bilateral flushing was used in four patients, pre-intervention, to allow visualisation of the distal vessel in the presence of obstructive OCT catheters. In all these cases,

Table 3 Intravascular ultrasound findings

	Pre-intervention	Post-intervention
Total image length (mm)	47±17	52±22
Inflow/outflow disease	5/7	5/4
Reference segment lumen area (mm^2)	9.1±3.3	9.5±2.7*
Stent		
Minimal stent area (mm^2)	6.2±2.4	7.6±2.6***
Maximal stent area (mm^2)	10.1±2.7	10.9+2.2***
Minimal stent expansion (%)	69±14	79±14**
Severe underexpansion	10 (67%)	6 (40%)
MUSIC criteria	2 (13%)	6 (40%)
Maximal asymmetry	0.83±0.1	0.88±0.1
Thrombus	15 (100%)	12 (80%)
Maximal thrombus area (mm^2)	5.4±2.7	2.7±2.0***
Minimal residual lumen (mm^2)	1.9±0.9	6.1±2.1***
Obstruction largest thrombus (%)	58±18	22±11**
Maximal stent obstruction (%)	75.6±8.9	23.5±19.2***
Malapposition	6 (40%)	4 (27%)†
Maximal distance (mm)	0.72±0.3	0.5±0.3
Maximal area (mm^2)	1.9±0.7	1.3±0.6*
Length (mm)***	5.2±3.4	4.5±3.8*
Edge-dissections	2 (14%)	3 (20%)
Related side-branches	11 (73%)	11 (73%)

*p<0.1; **p<0.05; ***p<0.01.
†1 additional patient had malapposition in a newly implanted stent.

however, imaging was repeated after thrombus aspiration to better analyse the distal segment. The length of the OCT imaging sequence was shorter (p<0.05) than IVUS sequences (tables 3 and 4). A red or mixed thrombus was visualised in 14 patients. In these patients, attenuation of distal structures prevented a complete visualisation of the stent struts for a total length of 12.3±6 mm. However, in most of these patients, visualisation of the stent struts was obtained through the thrombus itself, in areas opposite to the red thrombus, and a complete analysis of stent struts was always possible, proximal or distal to the thrombus (figures 1 and 2). Signal attenuation, once the strut was reached through the thrombus, prevented further quantitative analysis of dorsal structures. In patients with a large thrombus burden, OCT was repeated after thrombus aspiration.

Most stents showed severe underexpansion on OCT (table 4). Malapposition was detected in six patients (figure 2). Of interest, in one patient with OCT-demonstrated malapposition after stent implantation (attempts to correct this problem proved unsuccessful), this finding could not be recognised at the time of ST (due to the presence of a large thrombus filling the segment) but malapposition was unravelled during intervention. OCT revealed that one IVUS-detected malapposition was, in fact, a well-apposed stent on a soft plaque, whereas, one OCT-detected malapposition was not recognised by IVUS due to poor image resolution.

Stent coverage only could be assessed in areas free from thrombus. Despite this, uncovered struts were clearly recognised in nine patients (60%) at segments close to thrombus location (table 4). Finally, significant neointimal proliferation (>50% stent area) related to thrombus location was detected in five patients, all with very late ST, (four patients had images suggestive of neoatherosclerosis and one associated plaque

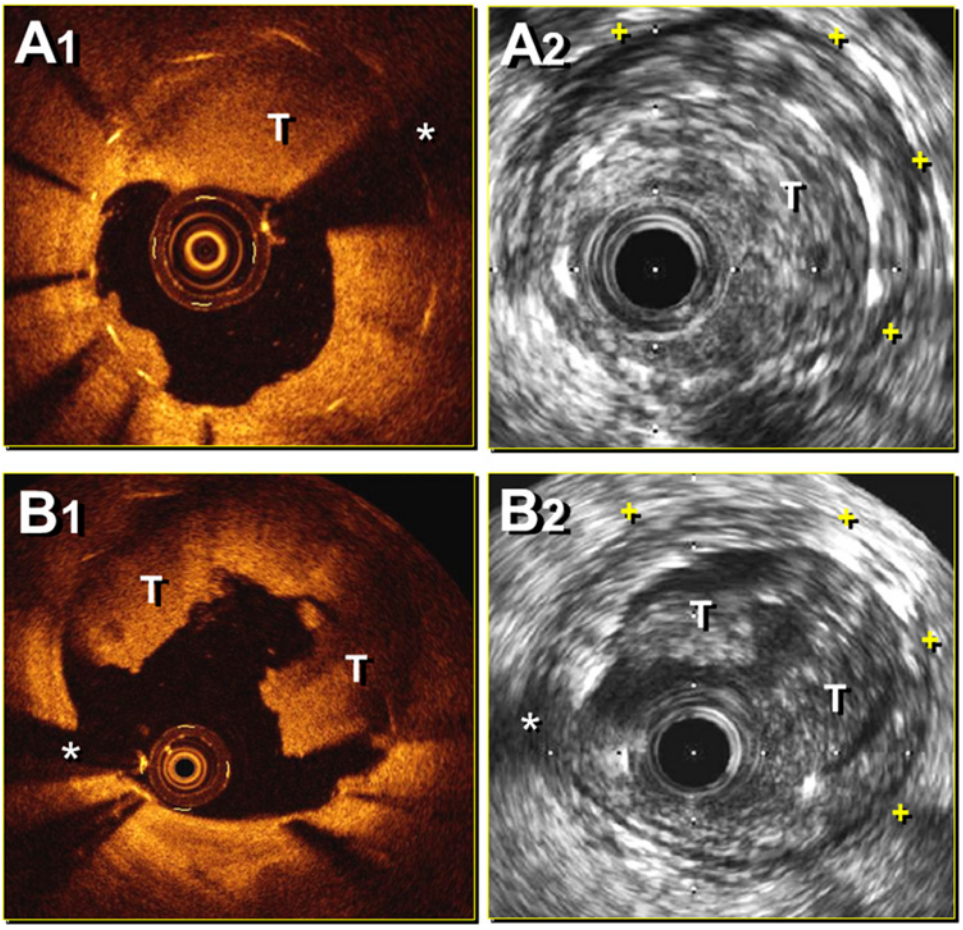

Figure 1 Images of stent thrombosis *before* intervention in two different patients (left, optical coherence tomography (OCT); right, intravascular ultrasound (IVUS)). (A1) Stent thrombosis as detected by OCT with mild shadowing of some struts. (A2) The same stent visualised with IVUS. Notice clear visualisation of the external elastic lamina (+) and stent struts, but poor visualisation of the lumen—thrombus interface. (B1) Stent thrombosis presenting a lobulated pattern by OCT. Thrombus causes partial dorsal shadowing of the stent struts. (B2) The same thrombus morphology is recognised with IVUS; all stent struts are readily visualised behind the thrombus although, again, the lumen—thrombus interface is less clear. T, thrombus; (*), wire artefact; (+), external elastic lamina.

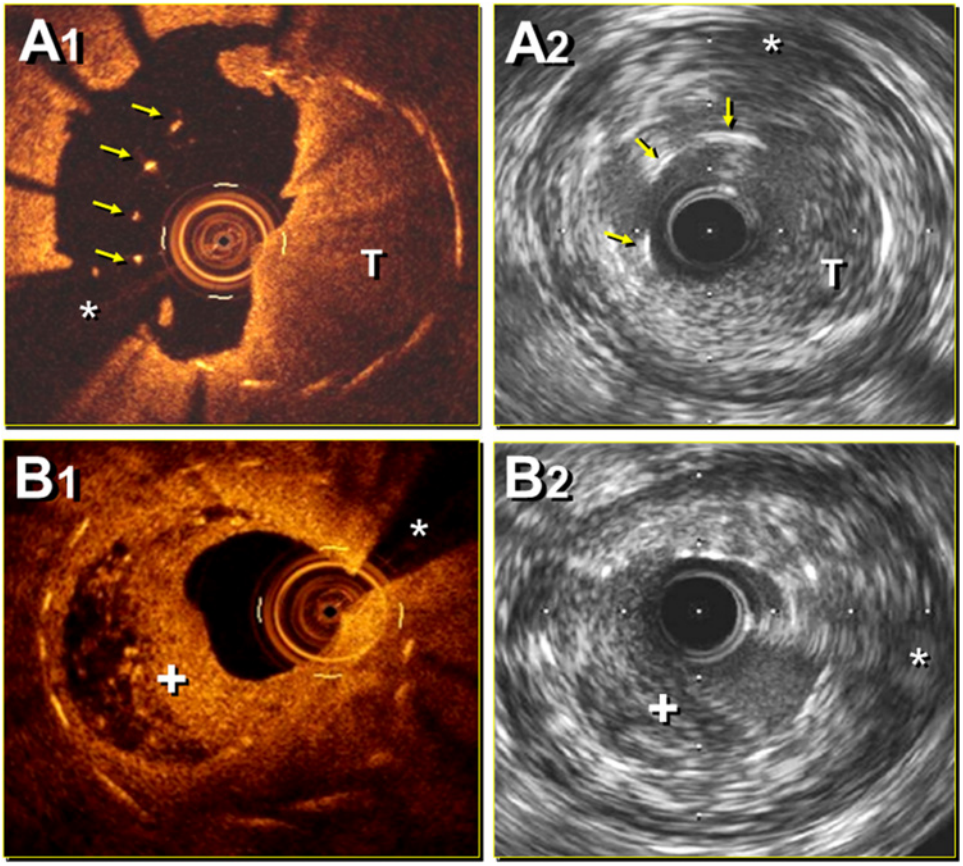

Figure 2 Images of stent thrombosis *before* intervention (all from the same patient) (left, optical coherence tomography (OCT); right, intravascular ultrasound (IVUS)). (A1) Severe malapposition and associated stent thrombosis depicted by OCT. Malapposed struts (yellow arrows) are sharply delineated, and thrombus is not obscuring the underlying stent. (A2) Same stent segment on IVUS. Malapposition (yellow arrows) and thrombi with a similar morphology are also recognised. (B1) Neoatherosclerosis (+) was identified by OCT in the adjacent stent segment. (B2) At this location, IVUS only showed an image (+) consistent with additional thrombus. T, thrombus; (*), wire artefact.

rupture) (figure 3). Furthermore, two patients presented images of atherosclerotic plaque rupture outside the stented segment.[20] After interventions, thrombus size decreased, lumen area improved and stent size increased, leading to an improved stent expansion on OCT (table 4, figure 4). However, underexpansion persisted after the procedure in half of the patients. Moreover, although smaller in size, residual malapposition was detected in five patients, including one patient in whom IVUS suggested that malapposition had been resolved. In half the cases minor residual edge-dissections were detected by OCT after interventions related to either the original stent or to newly implanted stents (table 4, figure 4).

No complications occurred related to the imaging techniques. No patient died or required coronary surgery during hospitalisation. All patients recovered uneventfully, (hospital stay 8±6.4 days, median 6 days), although one patient required re-intervention for recurrent ST. Most patients underwent platelet function testing after discharge, and were treated with a double dose of clopidogrel (n=2) or prasugrel (n=4), as required.

DISCUSSION

This is the first study in patients with ST where culprit thrombus has been systematically assessed with OCT and IVUS before interventions. Furthermore, this is the first study were both techniques were used to optimise interventions and to analyse final results of these challenging rescue procedures. The main findings of our study are the following: (1) an occlusive thrombus—red and/or white—is readily visualised with OCT in all patients suffering from ST; (2) despite the partial dorsal shadowing induced by red thrombus, pre-intervention OCT provides unique insights on potentially predisposing factors; (3) during rescue interventions, OCT consistently discloses underlying anatomic problems, including severe underexpansion, malapposition and inflow-outflow disease; (4) OCT findings may be used to tackle anatomic factors potentially generating a *'vulnerable'* stent, and are of major value to guide repeated interventions; (5) despite optimisation efforts, residual thrombus is systematically detected by OCT, frequently associated with a variable degree of underexpansion and residual malapposition; (6) OCT findings are similar—but not identical—to those detected by IVUS, and the information provided by these techniques seems to be complementary. Indeed, in this challenging scenario, OCT provides a crisp delineation of the thrombus–lumen interface, readily differentiates red from white thrombus, nicely visualises struts on heavily calcified segments, and sharply depicts even minor degrees of malapposition and edge dissections. Although a comprehensive assessment of strut coverage in this setting remains problematic, uncovered stent struts are frequently detected by OCT. Finally, OCT may detect in-stent neoatherosclerosis which remains largely elusive to IVUS. Conversely, IVUS provides a more complete picture of the entire vessel wall and nicely recognises stent struts behind any type of thrombus.

Previous IVUS studies

The role of IVUS during interventions for ST has been previously reported.[4–7] Most studies showed consistent results regarding the predisposing risk of underexpansion, inflow/outflow disease and residual dissections. However, until more recently, the significance of strut malapposition has been controversial. Malapposition was frequently detected in early drug-eluting stents (DES) trials with routine late IVUS imaging, but this finding did not appear to correlate with adverse clinical

Table 4 Optical coherence tomography findings

	Pre-intervention	Post-intervention
Number of OCT runs	2.1±0.4	1.8±0.9
Total image length (mm)	36.7±8.3	36.1±10
Inflow/outflow disease	5/5	3/3
Reference segment lumen area (mm^2)	7.9±2.4	8.9±2.9
Stent		
Minimal stent area (mm^2)	4.7±2.1	6.8±2.9***
Maximal stent area (mm^2)	8.8±3.4	10.9±3.5***
Minimal stent expansion (%)	60±21	75±21**
Severe underexpansion	13 (87%)	6 (40%)
Maximal asymmetry	0.84±0.1	0.86±0.1
Thrombus	15 (100%)	15 (100%)
Red/White/Both	7/1/7	7/1/7
Shadowing Length (mm)	12.3±6	9.3±5***
Maximal thrombus area (mm^2)	4.7±2.5	2.4±1.6***
Minimal residual lumen (mm^2)	1.2±1.4	5.4±2.3***
Obstruction at largest thrombus (%)	63±25	24±13***
Maximal stent obstruction (%)	82±14	24±14***
Malapposition	6 (47%)	5 (33%)†
Maximal distance (mm)	0.97±0.4	0.56±0.4*
Maximal area (mm^2)	2.0±1.2	0.86±0.9*
Length (mm)	6.7±4.5	4.9±3.4*
Uncovered struts	9 (60%)	9 (60%)
Number per image	4.6±2.7	4.6±2.3
Maximal Arc (°)	72±100	69±101
Associated in-stent restenosis	5 (33%)	–
Neoatherogenesis/plaque rupture	4 (24%) 1	–
Edge dissections	3 (20)	8 (54%)
Related side-branches	12 (80)	12 (80)

*p<0.1; **p<0.05; ***p<0.01.
†1 additional patient had malapposition in a newly implanted stent.
OCT, Optical coherence tomography.

outcomes.[21] However, a recent meta-analysis confirmed that malapposition is a risk factor for ST.[22] In addition, malapposition is frequently detected in patients undergoing rescue interventions for ST. In our previous experience, IVUS-detected malapposition was found in 30% and 50% of patients with ST in bare-metal stents and DES, respectively.[4 7] More recently, it has been suggested that the 'extent' of malapposition might be a major prognostic marker.[4 6] In patients with very late ST, large areas of malapposition are frequently detected.[6] Likewise, although even rarer, in patients developing DES-related coronary aneurysms, the size of the aneurysm—as measured by IVUS—appears to have prognostic implications.[23]

Previous OCT studies

The value of OCT to characterise red and white thrombi has been well established.[15] In *asymptomatic* patients, OCT studies late after stent implantation demonstrated the presence of small, angiographically silent, stent-related thrombi in 14%–26% of cases.[16–18] Kim *et al*[17] suggested that the number of malapposed struts was important, and that the prevalence of thrombi was threefold higher in stents with ≥8 malapposed struts. OCT-detected intracoronary thrombi was more prevalent in sirolimus-eluting stents, long stents and stents with asymmetric expansion or uneven neointimal formation.[16–18] Using IVUS and OCT after DES implantation Ozaki *et al*[18] demonstrated that IVUS underestimated the presence of incomplete apposition as a result of its limited axial resolution and stent-related artifacts. Thrombus was visualised in 21% of malapposed struts at follow-up. Interestingly, thrombus occurred more frequently in relation to malapposed struts than to uncovered but well-apposed struts.[18] These OCT studies in *asymptomatic* patients confirm previous coronary angioscopy and pathologic findings suggesting the association of red thrombus with uncovered and malappossed DES struts.[24 25]

However, only scarce evidence suggests the value of OCT in patients suffering from *clinical episodes* of ST. Anecdotal single-case reports[26–28] suggested the value of OCT to unravel underlying predisposing factors. Notably, in patients with 'evolving' thrombus formation, striking spider web-like images within the stent—interpreted as ongoing fibrin strands formation—have been identified in the early stages of ST.[27]

Finally, in patients with in-stent restenosis the presence on OCT of microvessels[29] or neoatherosclerosis[10] have been associated with disease progression or rupture and ST.

Combined use of IVUS and OCT in patients with ST

In a recent study, Guagliumi *et al*[30] reported the results of 18 patients with late DES thrombosis analysed with OCT and IVUS. They found that patients suffering ST frequently had uncovered and malapposed stents on OCT and positive remodelling on IVUS.[30] Underexpansion, however, could not be identified as a marker of ST because patients in the control group

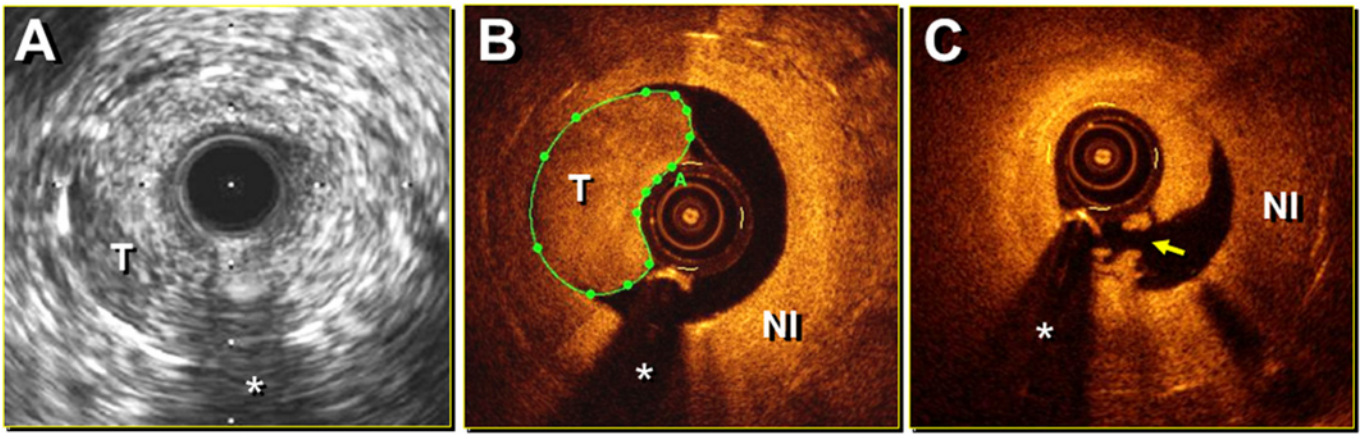

Figure 3 Findings in a patient suffering very late stent thrombosis. (A) intravascular ultrasound (IVUS) showing a characteristic image of stent thrombosis. (B) With optical coherence tomography (OCT), thrombus may be readily measured and differentiated from associated neointimal proliferation (NI) that was not recognised by IVUS. (C) OCT in the adjacent segment showing a plaque rupture (yellow arrow) and NI again not clearly detected on IVUS. T, thrombus; (*), wire artefact.

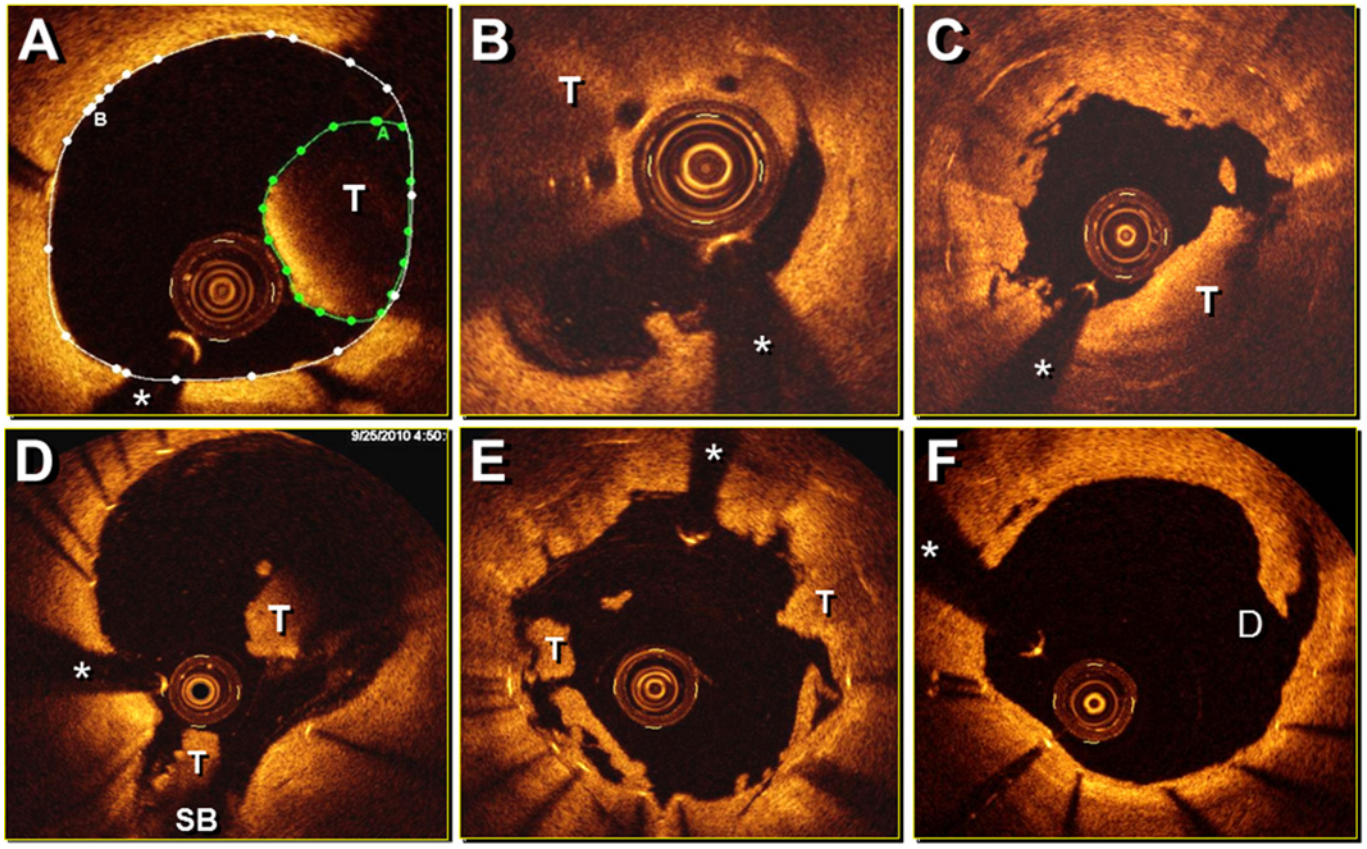

Figure 4 Optical coherence tomography (OCT) findings during rescue interventions. (A) Lumen and thrombus measurements. Areas were not measured when red thrombi induced shadowing >1 quadrant of the vessel circumference. (B) OCT magnification showing details of a red thrombus with michrochannels. (C) Residual thrombus after the use of an aspiration catheter. (D) Residual red thrombi after intervention, with fragmentated thrombi partially occluding a side-branch (SB). (E): Final result after thrombus aspiration and high-pressure balloon inflation. (F) Residual dissection (D) at the stent edge. T, thrombus; (*), wire artefact.

were matched for vessel and stent size. They used time-domain OCT systems with an occlusive technique, and always performed multiple sequences of thromboaspiration before imaging. However, in the current study, we used frequency-domain systems with a non-occlusive technique (thus facilitating a comprehensive anatomic analysis and better image quality), and systematically imaged the baseline thrombus '*before*' any mechanical intervention. Accordingly, in our study, thrombus characteristics and size could be carefully analysed. Furthermore, Guagliumi *et al*[30] did not assess the results of interventions (including residual thrombus) with these imaging techniques. However, we systematically used OCT and IVUS to guide and optimise the procedure. Therefore, final results of interventions were analysed with both techniques and compared with baseline findings. Notably, although stent-related mechanical problems were significantly improved, and thrombus volume was clearly reduced, residual thrombus was consistently visualised within the stent after PCI.

We found that pre-intervention imaging was feasible in this setting and that it provided valuable information on the underlying mechanisms of ST. From a technical point of view, the advancement of novel OCT catheters along the occluded stent was found to be easier than the advancement of IVUS catheters but, eventually, the image length was shorter with OCT. Overlapping OCT runs may circumvent this problem, but the need for repeated imaging runs might represent a problem in highly unstable patients. Conversely, the pullback speed is much faster with current OCT systems, as compared with IVUS, and this is an attractive feature in patients with ongoing ischaemia. When thrombus is occlusive, improved OCT visualisation of distal structures may be achieved by bilateral flushing although the image quality improves following thromboaspiration. This problem is not seen with IVUS because ultrasound does not require a field clear of blood for imaging.

The main disadvantage of OCT in this scenario remains the shadowing generated by large red thrombi. However, our findings clearly demonstrate that, in most patients, pre-intervention OCT unravels unique findings and discloses underlying factors presumably related to the pathophysiology of ST. Actually, despite the presence of thrombi, a comprehensive analysis of the underlying anatomy was obtained in all patients. In addition, after initial aspiration and pre-dilation, additional morphologic clues were disclosed. Finally, residual thrombi, systematically seen by OCT at the end of the procedure, were relatively small and did not affect stent visualisation. Some studies have suggested that, in this setting, the aspirated material predominantly consist of platelet-rich thrombi,[30] and this might help to explain adequate OCT visualisation despite significant thrombus burden. From a pragmatic standpoint, in routine clinical practice, exclusively performing OCT at the end of procedure may be sufficient to identify those patients requiring further optimisation efforts.

OCT clearly recognises stent struts on heavily calcified areas, whereas, this may be difficult with IVUS. Furthermore, OCT has 10 times the resolution of IVUS and produces near-field images of superb quality. In our series, OCT was clearly superior

to IVUS, delineating the thrombus–lumen interface. Furthermore, the precise interpretation on IVUS of small hypoechogenic areas behind stent struts may be problematic, and the differential diagnosis between true malapposition (empty space), malapposition filled with thrombi and even soft plaque behind the stent, may be challenging. In fact, OCT after interventions was able to recognise residual malapposition or dissections that were undetected by IVUS. However, the clinical implications of these 'minor' residual OCT findings remain to be determined.[31] Furthermore, OCT produced a sharper delineation of the neointimal-thrombus boundary and provided a reliable diagnosis of associated in-stent restenosis or neoatherosclerosis. In our experience, differentiating residual thrombus from associated neointimal proliferation with IVUS remains extremely difficult.

Finally, from a quantitative standpoint, we found that OCT measured areas smaller than those obtained with IVUS. This is of interest, and previous studies have also recognised similar discrepancies.[32] Blurred thrombus-lumen contours on IVUS may be implicated. However, it is important to emphasise that in our study, attempts to precisely correlate IVUS and OCT measurements—matched at the same location—were not performed due to inherent differences between these imaging modalities and the areas shadowed by red thrombi on OCT.

Limitations

First, due to the rarity of ST and the complex logistics involved in simultaneously performing OCT and IVUS imaging during these rescue procedures, the number of cases included was relatively low. Second, our series encompassed heterogeneous patients with either DES or bare-metal stents and experiencing early, late or very late ST. Third, baseline and residual red thrombi induces attenuation of posterior structures on OCT. Therefore, measurements were only obtained from selected images, and an exhaustive (strut level) analysis of the entire stent segment was not attempted, nor was volumetric data obtained. Finally, the lack of a control group should be acknowledged.

Conclusion

OCT provides an attractive technique to fully characterise the pattern of ST and its underlying substrate, and represents a novel useful tool to guide and optimise repeated interventions in this challenging setting. Our findings suggest that in patients suffering from ST, OCT and IVUS are of complementary nature.

Contributors All authors were involved in the design of the protocol, in the drafting of the manuscript and in a critical review of its final content.

Competing interests None.

Patient consent Oral informed consent was obtained from all patients.

Ethics approval Ethics approval was provided by the Institutional Review Board.

Provenance and peer review Not commissioned; externally peer reviewed.

REFERENCES

1. **Iakovou I,** Schmidt T, Bonizzoni E, *et al*. Incidence, predictors and outcome of thrombosis after successful implantation of drug-eluting stents. *JAMA* 2005;**293**:2126–30.
2. **Alfonso F.** The "vulnerable" stent why so dreadful? *J Am Coll Cardiol* 2008;**51**:2403–6.
3. **Mintz GS,** Nissen SE, Anderson WD, *et al*. American College of Cardiology clinical expert consensus document on standards for acquisition, measurement and reporting of intravascular ultrasound studies (IVUS). *J Am Coll Cardiol* 2001;**37**:1478–92.
4. **Alfonso F,** Suarez A, Angiolillo DJ, *et al*. Findings of intravascular ultrasound during acute stent thrombosis. *Heart* 2004;**90**:1455–9.
5. **Fujii K,** Carlier SG, Mintz GS, *et al*. Stent underexpansion and residual reference segment stenosis are related to stent thrombosis after drug-eluting stent implantation. An intravascular ultrasound study. *J Am Coll Cardiol* 2005;**45**:995–8.
6. **Cook S,** Wenaweser P, Togni M, *et al*. Incomplete stent apposition and very late stent thrombosis after drug-eluting stent implantation. *Circulation* 2007;**115**:2426–34.
7. **Alfonso F,** Suárez A, Pérez-Vizcayno MJ, *et al*. Intravascular ultrasound findings during episodes of drug-eluting stent thrombosis. *J Am Coll Cardiol* 2007;**50**:2095–7.
8. **Prati F,** Regar E, Mintz GS, *et al*. Expert review document on methodology, terminology, and clinical applications of optical coherence tomography: physical principles, methodology of image acquisition, and clinical application for assessment of coronary arteries and atherosclerosis. *Eur Heart J* 2010;**31**:401–15.
9. **Lindsay AC,** Viceconte N, Di Mario C. Optical coherence tomography: has its time come? *Heart* 2011;**97**:1361–2.
10. **Hou J,** Qi H, Zhang M, *et al*. Development of lipid-rich plaque inside bare metal stent: possible mechanism of late stent thrombosis? An optical coherence tomography study. *Heart* 2010;**96**:1187–90.
11. **Prati F,** Stazi F, Dutary J, *et al*. Detection of very early stent healing after primary angioplasty: an optical coherence tomographic observational study of chromium cobaltum and first-generation drug-eluting stents. The DETECTIVE study. *Heart* 2011;**97**:1841–6.
12. **Mauri L,** Hsieh W, Massaro JM, *et al*. Stent thrombosis in randomized clinical trials of drug-eluting stents. *N Engl J Med* 2007;**356**:1020–9.
13. **Alfonso F,** Rodriguez P, Phillips P, *et al*. Clinical and angiographic implications of coronary stenting in thrombus-containing lesions. *J Am Coll Cardiol* 1997;**29**:725–33.
14. **Gonzalo N,** Escaned J, Alfonso F, *et al*. Is refined OCT guidance of stent implantation needed? *EuroIntervention* 2010;**6**(Suppl G):G145–53.
15. **Kume T,** Akasaka T, Kawamoto T, *et al*. Assessment of coronary arterial thrombus by optical coherence tomography. *Am J Cardiol* 2006;**97**:1713–17.
16. **Otake H,** Shite J, Ako J, *et al*. Local determinants of thrombus formation following sirolimus-eluting stent implantation assessed by optical coherence tomography. *JACC Cardiovasc Interv* 2009;**2**:459–66.
17. **Kim JS,** Hong MK, Fan C, *et al*. Intracoronary thrombus formation after drug-eluting stents implantation: optical coherence tomographic study. *Am Heart J* 2010;**159**:278–83.
18. **Ozaki Y,** Okumura M, Ismail TF, *et al*. The fate of incomplete stent apposition with drug-eluting stents: an optical coherence tomography-based natural history study. *Eur Hear J* 2010;**31**:1470–6.
19. **de Jaegere P,** Mudra H, Figulla H, *et al*. Intravascular ultrasound-guided optimized stent deployment: immediate and 6-months clinical and angiographic results from the multicenter ultrasound stenting in coronary arteries study (MUSIC study). *Eur Heart J* 1998;**19**:1214–23.
20. **Alfonso F,** Gonzalo N, Hernández R. A rare cause of late drug-eluting stent thrombosis unraveled by optical coherence tomography. *Circ Cardiovasc Interv* 2011:**4**:399–400.
21. **Tanabe K,** Serruys PW, Degertekin M, *et al*. Incomplete stent apposition after implantation of paclitaxel-eluting stents or bare metal setnts. Insights from the randomized TAXUS II trial. *Circulation* 2005;**111**:900–5.
22. **Hassan AK,** Bergheanu SC, Stijnen T, *et al*. Late stent malapposition risk is higher after drug-eluting stent compared with bare-metal stent implantation and associates with late stent thrombosis. *Eur Heart J* 2010;**31**:1172–80.
23. **Alfonso F,** Pérez-Vizcayno MJ, Ruiz M, *et al*. Coronary aneurysms after drug-eluting stent implantation: clinical, angiographic, and intravascular ultrasound findings. *J Am Coll Cardiol* 2009;**53**:2053–60.
24. **Awata M,** Kotani J, Uematsu M, *et al*. Serial angioscopic evidence of incomplete neointimal coverage after sirolimus-eluting stent implantation: comparison with bare-metal stents. *Circulation* 2007;**116**:910–16.
25. **Finn AV,** Joner M, Nakazawa G, *et al*. Pathological correlates of late drug-eluting stent thrombosis: strut coverage as a marker of endothelialization. *Circulation* 2007;**115**:2435–41.
26. **Itoh T,** Fusazaki T, Kimura T, *et al*. "Intracoronary whirling current phenomenon" and thrombus formation after sirolimus-eluting stent implantation visualized by optical coherence tomography. *Circ Cardiovasc Intervent* 2009;**2**:264–7.
27. **Zakhem B,** Fernandez-Ortiz A, Alfonso F. Optical coherence tomography findings during "evolving" stent thrombosis. *J Invasive Cardiol* 2011;**23**:E222–5.
28. **Jimenez-Valero S,** Moreno R, Sanchez-Recalde A. Very late drug-eluting stent thrombosis related to incomplete endothelialization: in-vivo demonstration by optical coherence tomography. *J Invasive Cardiol* 2009;**21**:488–90.
29. **Kim BK,** Kim JS, Shin DH, *et al*. Optical coherence evaluation of in-stent restenotic lesions with visible microvessels. *J Invasive Cardiol* 2012;**24**:116–20.
30. **Guagliumi G,** Sirbu V, Musumeci G, *et al*. Examination of the in vivo mechanisms of late drug-eluting stent thrombosis. Findings from optical coherence tomography and intravascular ultrasound imaging. *J Am Coll Cardiol Intv* 2012;**5**:12–20.
31. **Alfonso F,** Canales E, Dutary J, *et al*. Coronary dissection healing patterns: from complete resolution to restenosis, insights from optical coherence tomography. *EuroIntervention* 2011;**7**:270–3.
32. **Gonzalo N,** Serruys PW, García-García HM, *et al*. Quantitative ex vivo and in vivo comparison of lumen dimensions measured by optical coherence tomography and intravascular ultrasound in human coronary arteries. *Rev Esp Cardiol* 2009;**62**:615–24.

Heart

Combined use of optical coherence tomography and intravascular ultrasound imaging in patients undergoing coronary interventions for stent thrombosis

Fernando Alfonso, Jaime Dutary, Manuel Paulo, Nieves Gonzalo, Maria J Pérez-Vizcayno, Pilar Jiménez-Quevedo, Javier Escaned, Camino Bañuelos, Rosana Hernández and Carlos Macaya

Heart 2012 98: 1213-1220
doi: 10.1136/heartjnl-2012-302183