

J. Neurol. Neurosurg. Psychiat., 1952, **15**, 99.

WOUNDS OF THE VISUAL PATHWAY

PART I: THE VISUAL RADIATION

BY

J. M. K. SPALDING

From the Department of Neurology, Radcliffe Infirmary, Oxford

The representation of the visual field in the visual radiation has received comparatively little attention. In reporting cases of head injury in the first world war, Holmes (1918) stressed the frequency of precise quadrantanopia in wounds of the visual radiation and suggested, though tentatively, that there might be an anatomical interval between the lower half of the radiation subserving the upper quadrant of the visual field and the upper half subserving the lower quadrant. Anatomical studies in monkeys and man have shown, however, that this apparent interval is occupied by fibres subserving central vision which, as elsewhere in the visual pathways, are extremely numerous compared with the area of the visual field they subserve (Polyak, 1934, 1942). Polyak has shown that in the posterior part of the radiation the fibres of central vision separate completely the fibres of peripheral vision which lie above and below them, but in his investigations he apparently examined only the posterior half of the radiation, and Walker and Fulton (1938) have found that in the chimpanzee the anatomy of the anterior radiation is quite different. The present paper reports the

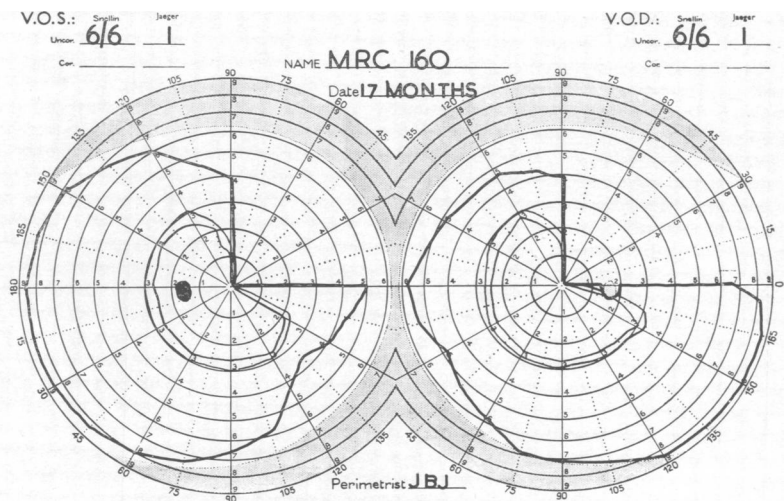
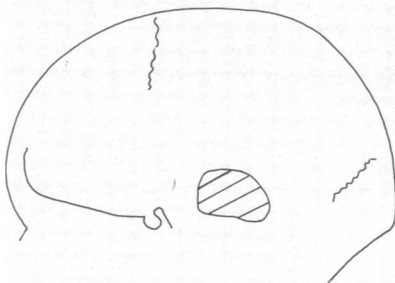
defects in the visual field which follow injuries to the radiation in man and describes the anatomical deductions which can be made from them with particular reference to the anterior half of the radiation.

Material

The material is taken from a series of 958 cases of penetrating head injuries, mainly gunshot wounds. One hundred and eighty-eight of these had defects in the visual field attributable to injury to the visual radiation or striate cortex, and this paper is concerned with the 62 cases in which there was a lesion of part of the visual radiation. Cases with severe lesions causing complete or almost complete hemianopia were excluded. The aspects of the cases mentioned in the text are those which are immediately relevant, and case histories are given in the appendix.

The visual fields were plotted with 3/330 and 2/2000 white isopters and also in abnormal areas with 20/2000 white isopter. The interval between injury and examination is shown on each chart.

FIG. 1.—Temporal wound (Case 1) causing precise upper quadrantanopia due to damage to the lower half of the visual radiation.



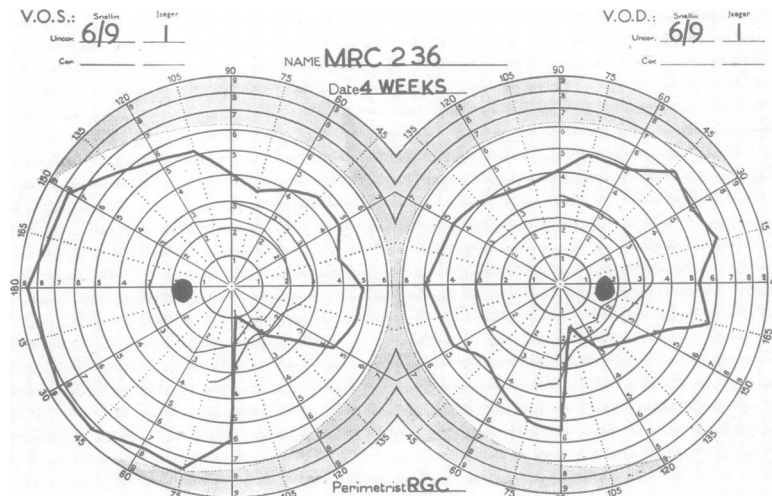
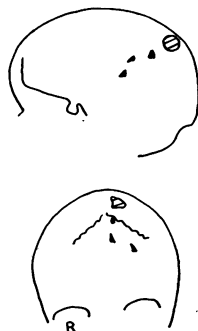

FIG. 2.—High posterior parietal wound (Case 2) causing a partial lower quadrantanopia with sparing of the horizontal meridian and a projection toward the fixation point in the vertical meridian; attributable to damage to the upper margin of the anterior radiation.

In the tracings of radiographs a coarsely hatched area indicates a bony defect in the skull and dense black a radio-opaque foreign body.

Precise quadrantanopia occurred, of which Case 1 (Fig. 1) is an example, but it was the cases with field defects of less than one quadrant that have been of particular interest. The most characteristic field defect is a partial quadrantanopia as illustrated by Cases 2 and 3 (Figs. 2 and 3) in which the striking features are that the horizontal meridian is spared and in the vertical meridian the defect projects towards the fixation point. The site of injury in quadrantic and partial quadrantic field defects is



which enabled Meyer to draw Cushing's attention to the fact that the lower margin of the visual radiation "plunges far forward in the temporal

considered in detail below, and it is sufficient to mention here that these two cases are typical, for that with a defect in the lower quadrant received a parasagittal parietal wound, that with a defect in the upper quadrant, a temporal wound. It is impossible to give a precise estimate of the frequency of defects of this type, for they are difficult to assess in the relatively slight cases (Case 4, Fig. 4), but they forced themselves on my attention at a time when their explanation was quite unknown to me. They have moreover been reported before, though without explanation of their shape, and Fig. 5 shows a very characteristic example taken from the first illustration in Cushing's paper (1921) on visual field defects in temporal lobe lesions. Other examples may be found in this and other papers, but this has a particular interest not only because it was one of the earliest of such cases to be recognized (1910), but also because it was the case

FIG. 3.—Temporal wound (Case 3) causing a partial upper quadrantanopia with sparing of the horizontal meridian and a projection toward the fixation point in the vertical meridian; attributable to damage to the lower margin of the anterior radiation.

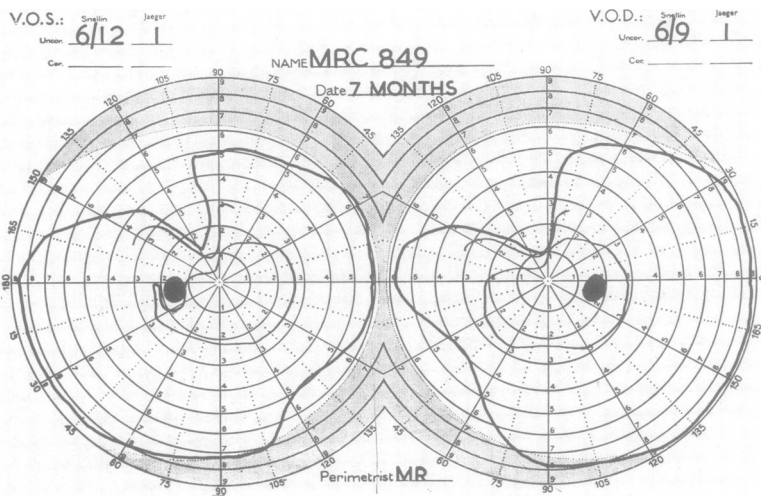
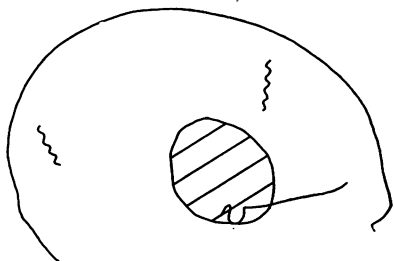
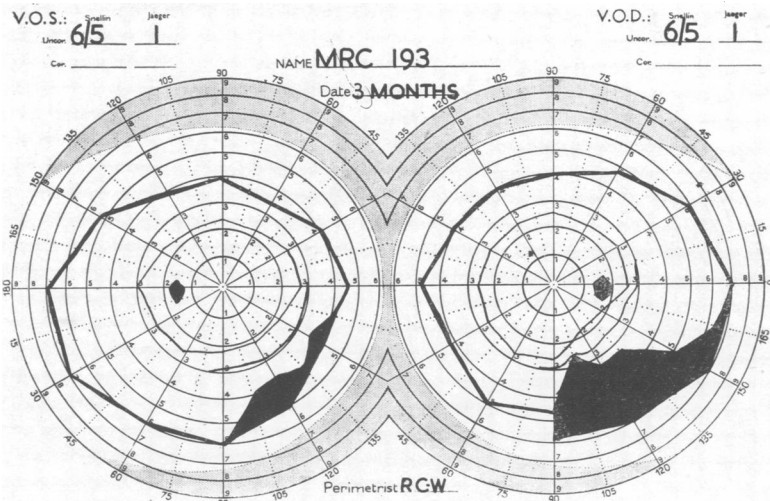




FIG. 4.—High posterior parietal wound (Case 4) causing a minimal partial quadrantanopia; attributable to damage to the extreme upper margin of the anterior radiation.



lobe to sweep around the horn of the ventricle".

The other and more striking field defect is that shown in Case 5 (Fig. 6). It is a narrow, sector-shaped defect in the horizontal meridian involving part of both quadrants and reaching to the fixation point. It is a rare defect occurring in only four cases in this series.

It is clearly important to relate the site of injury in these four cases to the site of injury in other cases of injury to the visual radiation, and this was done by plotting the site of injury in all cases on to a single skull outline by the method described by Russell (1947).

In Fig. 7 are shown the sites of injury in wounds involving the upper part of the radiation (U), the lower part of the radiation (L), and in wounds causing sector-shaped defects (S) of the type shown in Fig. 6. The cases of wounds to the upper

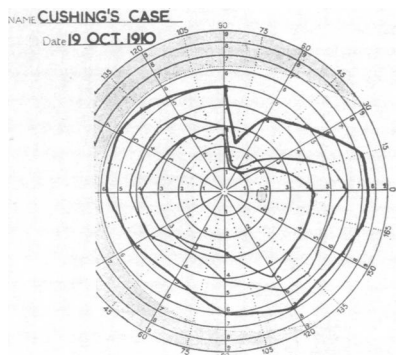


FIG. 5.—From Cushing (1921): partial quadrantanopia in a case of penetrating injury of the temporal lobe, with sparing of the horizontal meridian and a projection toward the fixation point in the vertical meridian; attributable to damage to the lower margin of the anterior radiation.

radiation are selected because the wounds are small. This was necessary to exclude, for instance, wounds involving a large part of the anterior half of the brain but appearing in this series because they extended backwards far enough to involve the upper margin of the visual radiation. The cases indicated by "U" in Fig. 7, therefore, include all cases of wounds of the visual radiation which showed partial or complete lower homonymous quadrantanopia and in which the post-traumatic amnesia was less than 24 hours. The last provision assured that the wound was relatively localized. Cases of injury to the lower radiation are less common than those of the upper, and to exclude cases with post-traumatic amnesia over 24 hours would unduly reduce the total number. The five cases with injuries to the eye penetrating backwards into the temporal lobe were excluded, as were one case with two wounds and one for which there is no satisfactory radiograph available. The remainder comprise the cases indicated with an "L" in Fig. 7, and with the above exceptions represent all cases of wounds of the radiation causing a complete or partial upper quadrantanopia. It should be emphasized that the cases of injury to the upper and lower radiation were selected in accordance with the criteria mentioned above, and that *all* cases which fulfilled the necessary qualification are included in Fig. 7.

It is plain that narrow, sector-shaped defects in the horizontal meridian are due to lesions of the intermediate part (that is, the part lying midway between the upper and lower margins) of the visual radiation in its anterior part. Case 5 (Fig. 6) shows that they are due to a lesion in the whole horizontal thickness of that part of the radiation, for the

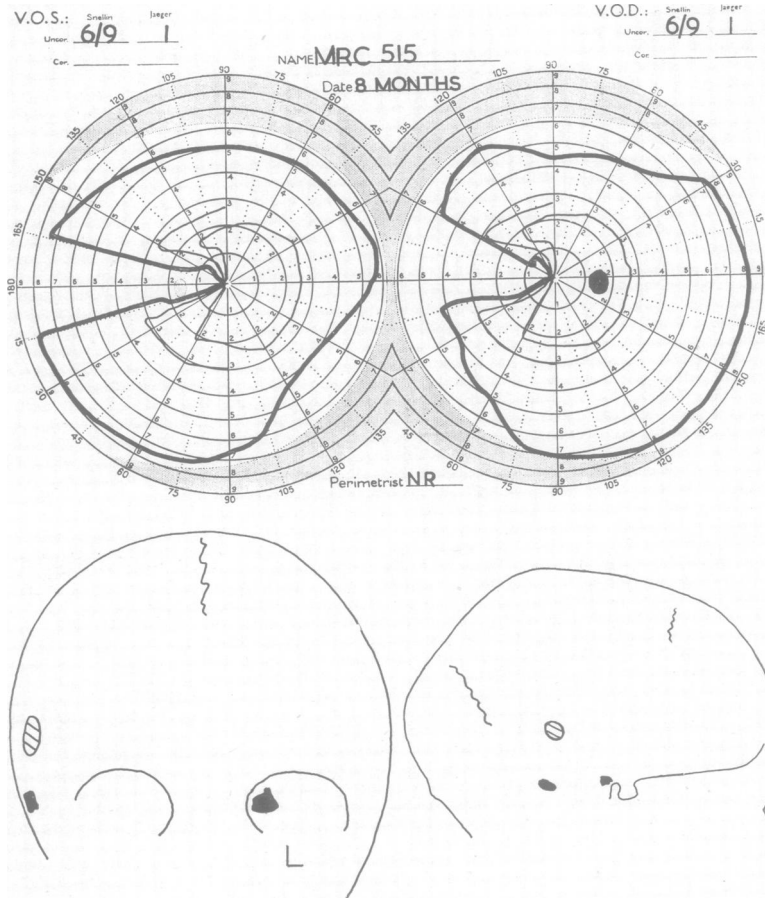


FIG. 6.—Right temporo-parietal wound (Case 5) with a foreign body crossing the mid-line, causing a sector-shaped defect in the horizontal meridian reaching to the fixation point; attributable to damage to the intermediate part (i.e., neither upper nor lower margin) of the anterior radiation.

foreign body which is indicated on the side opposite to the site of entry passed right through the radiation. We have, therefore, to find an explanation for these phenomena, namely: (1) sector-shaped defects in the horizontal meridian of the visual field due to lesions of the intermediate part of the anterior radiation; (2) partial quadrantanopia sparing the horizontal meridian and projecting towards the fixation point in the vertical meridian due to a lesion of the upper or lower margin of the anterior radiation.

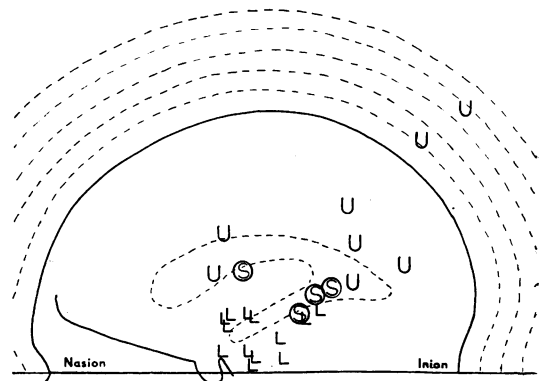
These phenomena indicate the anatomical relationship of fibres in the visual radiation, but before considering this it is necessary to review the shape and relations of the visual radiation. Fig. 8a shows the visual radiation as it fans out from the

lateral geniculate body round the anterior aspect of the trigone of the ventricle and the anterosuperior aspect of the temporal horn and passes back along the lateral aspect of the ventricle to reach the striate cortex.

The lines I and II in Fig. 8a indicate two planes, through the trigone and through the posterior horn of the ventricle respectively. Fig. 8b shows a coronal section in plane I of the left cerebral hemisphere seen from behind. The visual radiation forms a relatively flat plate on the lateral aspect of the trigone. Fig. 8c shows a similar section in plane II. The visual radiation turns medially at its upper and lower margins so that in this plane it appears as a horseshoe-shaped structure embracing the posterior horn of the ventricle. From the two ends of the horseshoe the visual radiation enters the anterior part of the striate cortex. Fig. 9 shows in diagrammatic form the right visual half-field (a), left lateral geniculate body (b) and the left visual

radiation in planes I (c) and II (d), and the representation of the visual field in these structures. The left lateral geniculate body is sectioned about the

FIG. 7.—Sites of injury in wounds involving the upper part of the radiation (U), the lower part of the radiation (L), and in wounds causing sector-shaped defects (S) of the type shown in Fig. 7.



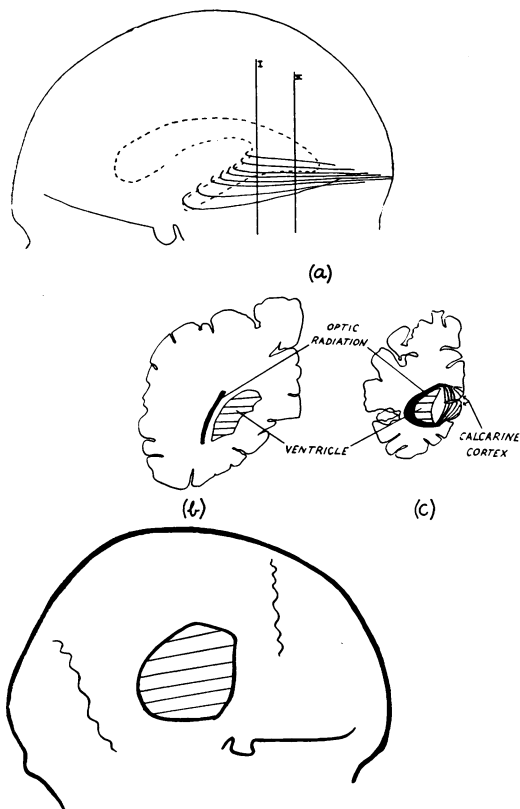


FIG. 8.—(a) Visual radiation fanning out from the lateral geniculate body and passing back along the lateral aspect of the ventricle. Plane I through the trigone of the ventricle, plane II through the posterior horn. (b) Coronal section, seen from behind, of the left cerebral hemisphere in plane I. (c) Similar section in plane II.

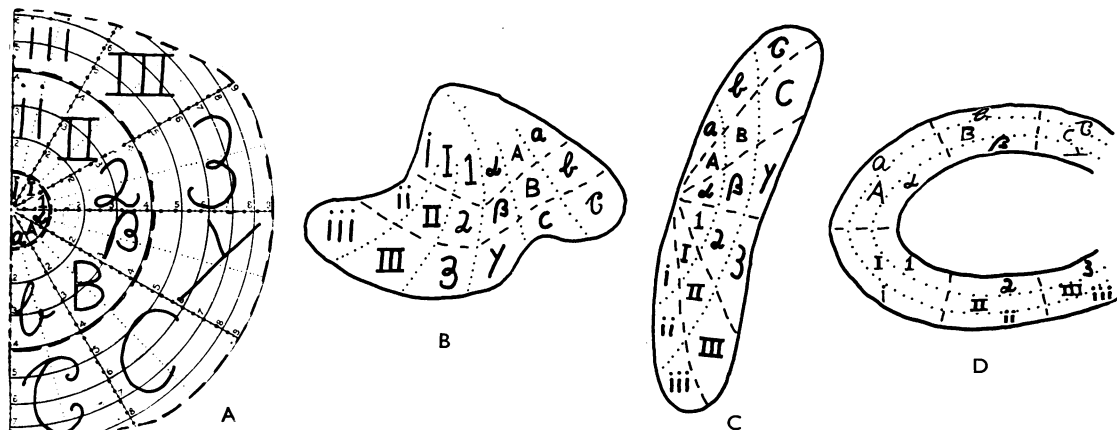


FIG. 9.—(A) Right visual half field, (B) left lateral geniculate body, in coronal section seen from behind, (C) left visual radiation in plane I, and (D) in plane II. The representation of the visual field is shown in these structures. Consecutive series (e.g., i, ii, iii, 1, 2, 3, or A, B, C) indicates a sector, and corresponding symbols from adjoining series (e.g., ii, II, 2, c, C, γ) indicate an arc of the visual field.

middle of its antero-posterior diameter. It is recognized that the level of section alters the appearance of the lateral geniculate body and, in particular, the proportion of the area of cut surface which is devoted to central and to peripheral vision. But for the present purposes neither the differences at different levels of section nor the mode of termination of the optic nerve fibres in the six layers of the lateral geniculate body (Glees and Le Gros Clark, 1941) are important. The anterior visual radiation (c) shows the representation of the visual field necessary to explain the phenomena mentioned above (Fig. 10). The posterior visual radiation (Fig. 9D) shows the representation of the visual field which has been demonstrated by Polyak and others.

Diagrams of this type are notoriously difficult to follow, and therefore the conventions may usefully be explained in some detail. In the visual field the different parts of the upper quadrant are indicated by numbers, the lower by letters. In both quadrants each series runs from centre to periphery so that any one series (e.g., i, ii, iii, 1, 2, 3, or A, B, C) indicates a sector, whereas the corresponding symbols from adjoining series (e.g., ii, II, 2, c, C, γ) indicate an arc of the visual field. Radii dividing the visual field are represented by dotted lines whereas linear arcs are represented by dashed lines.

In the lateral geniculate body (B) central vision is represented in cells lying superiorly, and peripheral vision in those lying inferiorly. The upper quadrant of the visual field is represented laterally, the lower medially, and the horizontal meridian approximately vertically. In the anterior radiation the orientation of fibres has turned anti-clockwise

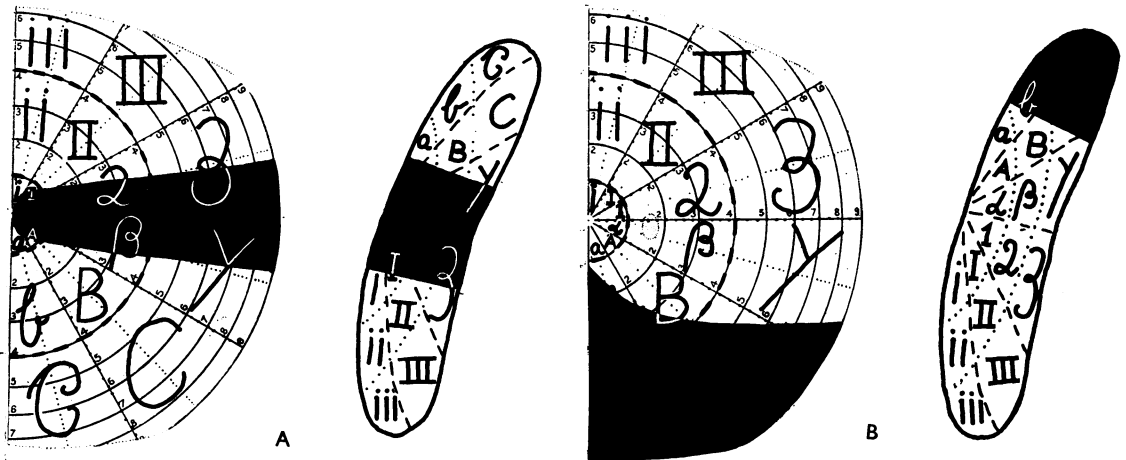


FIG. 10.—Schema showing the effect of lesions of the anterior radiation assuming the representation of the visual field proposed in Fig. 9: (A) lesion of the intermediate part, and (B) lesion of the upper margin.

through nearly a right angle. The fibres representing central vision now lie spread out over a large part of the lateral aspect of the visual radiation though tending to concentrate on its intermediate part, whereas the fibres of peripheral vision are spread out over the medial aspect of the visual radiation tending to concentrate at the upper and lower margins and to thin out over the intermediate part. The horizontal meridian, therefore, is represented more or less horizontally in the intermediate part of the radiation at this point. In the posterior radiation (D) the fibres of central vision have come to occupy the whole of the intermediate part of the radiation and lie lateral to the posterior horn of the ventricle as they pass back to the posterior pole of the occipital lobe. The fibres of peripheral vision have become concentrated at the margins of the radiation, that is, at the two ends of the horseshoe, a position which they must occupy, since in this plane they are already entering the anterior part of the striate cortex.

The suggested arrangement of fibres in the anterior radiation is, therefore, quite compatible with what is already known of the arrangement of the cell bodies of those fibres in the lateral geniculate body and with their course in the posterior radiation.

Briefly, the evidence presented above shows that, contrary to previous beliefs, in the anterior radiation the fibres of central vision are spread out on the lateral aspect of the radiation and tend to be concentrated in the intermediate part, whereas the fibres of peripheral vision are spread out on the medial aspect of the radiation and tend to be concentrated on the upper and lower margins. In the light of this interpretation it is easy to understand

why Holmes (1918) found no case of paracentral scotoma due to a wound of the visual radiation in the first world war. For a wound of the anterior radiation that caused such a scotoma would have to involve the intermediate part of the radiation in only half its thickness, and a wound of the posterior radiation that involved the fibres of central vision would be separated by little more than the posterior horn of the ventricle from the remainder of the radiation and from the striate cortex. The chances of such an injury occurring are extremely slight. Because of its rarity and because it is of interest in view of the above remarks, a case of paracentral scotoma due to a wound of the anterior radiation is shown. This man (Case 6) received rather a large right temporo-parietal wound (Fig. 11), and in the acute stage was thought on confrontation to have a complete left homonymous hemianopia. Twenty-five days after injury, when he was first fit to be fully tested, the visual fields showed a wide sector-shaped defect above and below the horizontal meridian. Nineteen months after injury he had improved markedly and had only a small triangular paracentral scotoma running along and just below the horizontal meridian. It is submitted that the site of injury combined with the wide sector defect at 25 days indicate an injury to the anterior radiation, and that the scotoma is evidence of permanent damage confined to the lateral part of the intermediate section of the anterior radiation.

Discussion

This investigation is based on a series of 62 cases of injury to the visual radiation by wounds, mainly gunshot, which penetrated the dura mater. As

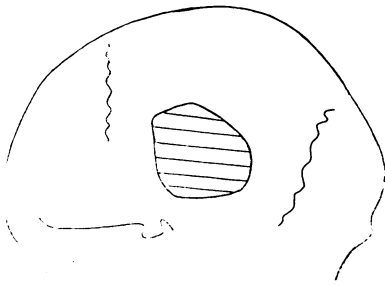
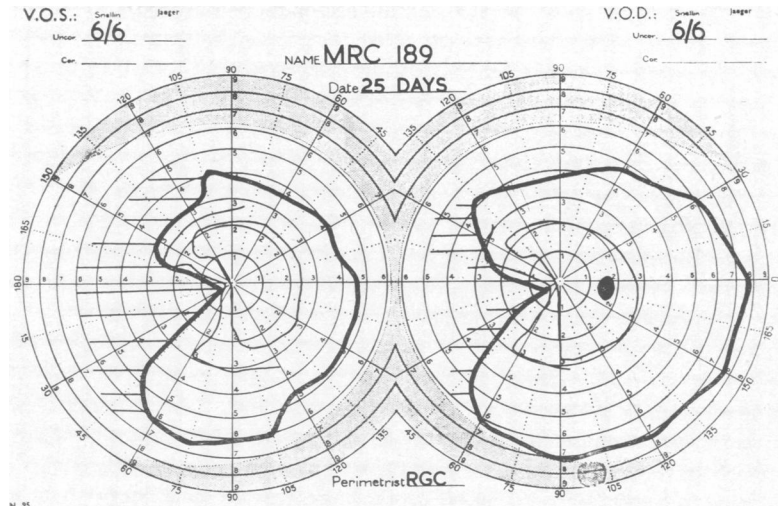


FIG. 11.—Temporo-parietal wound (Case 6) causing after 25 days a wide, sector-shaped defect above and below the horizontal meridian; attributable to a lesion of the intermediate part of the anterior radiation involving permanently only half the horizontal thickness of the radiation. In the coarsely hatched area a moving object was occasionally detected.



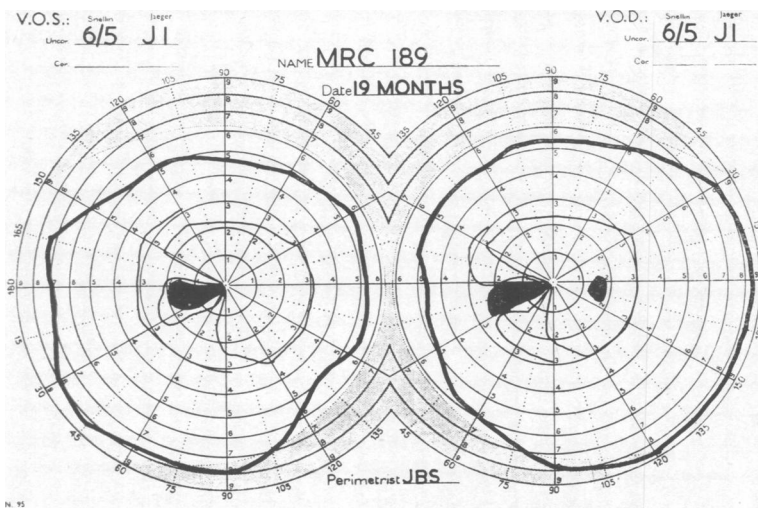
well as the cases with precise quadrantanopia which the experience of the first world war had led us to expect, defects also occurred in the visual field which involve less than a complete quadrant and they fall into two clearly distinguishable categories. The commoner is that in which part of one quadrant is affected and in which the horizontal meridian is spared and in the vertical meridian the field defect projects towards the fixation point. These are referred to below as "partial quadrantanopias". The other and much rarer type of defect in the visual field is the narrow, sector-shaped defect in the horizontal meridian.

Partial quadrantanopia has been reported before (Cushing, 1921), and the present series confirms the previous view that partial quadrantanopia in the

upper quadrant occurs in lesions of the lower margin of the visual radiation in its anterior (temporal) part; that is, in lesions of Meyer's loop (Meyer, 1907). Similarly partial quadrantanopia in the lower quadrant is due to a lesion of the upper margin of the visual radiation in its anterior part.

Sector-shaped defects in the horizontal meridian, on the other hand, have not previously been recognized as a possible sequel of a lesion of the visual radiation, and indeed Polyak (1942) specifically denies that they can occur in this way, and states that they are always due to a lesion of the striate cortex as in the case described by Holmes (1931). The four cases mentioned above are the only cases with this type of field defect in this series of 188 cases which have injuries involving the visual radiation or striate cortex, and the sites of injury close together in the temporo-parietal region prove that the injury is to the visual radiation not to the striate cortex. Moreover, it is clear that the injury must be to the whole horizontal thickness of the visual radiation, for in the case illustrated (Fig. 5) a foreign body has entered through a relatively small bony defect in the skull and crossed the midline coming to rest in a position which can only have been reached by traversing the visual radiation on the side of entry.

As Fig. 7 shows, the injuries



which produce narrow, horizontal, sector-shaped defects lie intermediately between those which produce upper and those which produce lower quadrant defects. This type of sector-shaped defect is, therefore, due to injury of the intermediate part of the visual radiation, that is, to that part of the radiation lying midway between its upper and lower margins. Moreover these injuries are anterior to or at the level of the trigone and can properly be presumed to have involved the anterior part of the visual radiation, a part which, unlike its neighbours in the visual system, the lateral geniculate body and the posterior part of the radiation, has received little or no attention from the anatomists.

It has been stated by several authors and most emphatically by Polyak (1942) that the upper part of the radiation is concerned with vision in the lower quadrant of the visual field, the lower part with vision in the upper quadrant and that the intermediate part is occupied by fibres concerned with central vision. This thesis, though put forward as applicable to the whole visual radiation, is based on experimental and clinical material in which apparently only the posterior horseshoe-shaped part (Figs. 8c, 9D) has been examined, and is incompatible with the occurrence of narrow, horizontal, sector-shaped defects of the visual field in injuries of the intermediate part of the anterior radiation. The implication of this type of sector-shaped defect is that in the anterior radiation the peripheral field in the horizontal meridian is represented in the same horizontal plane as is central vision. The arrangement of fibres which will explain the phenomena is that shown in Fig. 9, in which the fibres subserving central vision are spread out over the lateral aspect of the radiation tending to congregate towards the intermediate part, whereas the fibres subserving peripheral vision are spread out on the medial aspect tending to congregate at the upper and lower margin.

This arrangement may be postulated merely from the site of injury in cases of narrow, horizontal, sector-shaped defects, but it receives much support from consideration of the effect of an injury to the upper or lower margin of the anterior radiation. If the proposed arrangement is correct, we should expect a partial quadrant field defect in which the horizontal meridian is spared and in the vertical meridian the defect projects towards the fixation point (Fig. 10). That is to say, this arrangement of fibres also accounts for the occurrence of partial quadrant defects which are characteristic in shape and are common both in present and in previous material, but whose aetiology was previously unknown. The sparing of the horizontal meridian

occurs because this part of the visual field is represented in the intermediate part of the anterior radiation as is shown by the cases of sector-shaped defect. The projection of the defect towards the fixation point appears because a lesion of the upper or lower margin of the anterior radiation, as illustrated diagrammatically in Fig. 10, will involve a few of the fibres of central vision, and if these fibres are arranged in an orderly manner at all (as they undoubtedly are) the fibres involved will be those of central or pericentral vision in the vertical meridian.

This arrangement of fibres in the anterior radiation is therefore necessary to explain the observed facts. It remains to fit it in with what is known of the anatomy of the lateral geniculate body and the posterior part of the radiation. In the lateral geniculate body (Fig. 9b) central vision is represented superiorly, upper peripheral vision infero-laterally, and lower peripheral vision infero-medially (Brouwer and Zeeman, 1926; Mackenzie, Meighan, and Pollock, 1933; Le Gros Clark and Penman, 1934; Chacko, 1948). The horizontal meridian of the visual field is represented approximately vertically. In the anterior radiation, according to the suggested arrangement, the representation of the visual field follows the same general pattern as in the lateral geniculate body, but the axis of the system is turned through nearly a right angle in an anticlockwise direction. (This refers as before to the left hemisphere seen from behind.) The fibres of central vision thus come to lie on the lateral aspect of the radiation, the fibres of peripheral vision on the medial aspect, and the horizontal meridian is represented approximately horizontally. The fibres of peripheral vision thin out in the intermediate part of the anterior radiation, tending to congregate in the upper and lower margin, and this process continues so that in the posterior radiation peripheral vision is represented in the upper and lower limbs of the "horseshoe" corresponding to the upper and lower margins of the anterior radiation. This arrangement in the posterior radiation has been clearly demonstrated (Putnam, 1926; Brouwer, 1934; Polyak, 1934, 1941, 1942).

The postulated arrangement of fibres in the anterior radiation therefore fits in well with what is known of the anatomy of its neighbours in the visual pathways, the lateral geniculate body and the posterior radiation. It is moreover in accord with the very scanty evidence on the subject obtained from animal experiment, namely Walker and Fulton's (1938) observation that

"the degeneration in the lateral geniculate body . . . following the temporal lobe lesion was quite different

from that following an occipital lobe injury. The patchy degeneration of the lateral geniculate body in the first instance probably indicates that the component parts of the visual radiation do not maintain an exact constant relationship throughout their course, and that there is some intermingling of fibres".

We must conclude that there is good evidence in favour of, and none against, the proposition that in the anterior part of the radiation the fibres of central vision are spread out on the lateral aspect of the visual radiation, tending to congregate at its intermediate part, and the fibres of peripheral vision are spread out on the medial aspect, tending to congregate at its upper and lower margins. This also accounts for the extreme rarity of paracentral scotomata in injuries to the anterior radiation though they occur very occasionally as in Case 6 (Fig. 11) above.

Summary

A series of 958 cases of penetrating head injury, mainly gunshot wounds, has been reviewed to determine what light they throw on the anatomy of

the visual radiation. In 188 of these there was a visual field defect attributable to injury to the visual radiation or striate cortex, and the conclusions are based on the 62 of these cases in which injury was confined to the visual radiation.

Wounds involving the upper or lower margins of the anterior part of the visual radiation cause partial quadrantanopia in which the horizontal meridian is spared and the field defect projects towards the fixation point in the vertical meridian.

Wounds involving the intermediate part of the anterior radiation cause narrow, sector-shaped defects in the horizontal meridian reaching to the fixation point.

It follows that in the anterior radiation fibres subserving central vision lie on the lateral aspect, tending to congregate at the intermediate part, and fibres subserving peripheral vision lie on the medial aspect, tending to congregate at the upper and lower margins. This arrangement, though contrary to previous beliefs, is in accord with both experimental and clinical evidence.

A P P E N D I X

Case 1.—M.R.C.160,* a man aged 30, on July 31, 1944, received a left temporal gunshot wound (Fig. 1) with a post-traumatic amnesia between one and three weeks. Thirty hours after injury his wound was excised. The skull defect was found to involve the apex of the mastoid air cells, and there was a cavity the size of a large plum filled with debris in the posterior inferior temporal convolution, with an extension upwards and medially to involve the posterior portion of the temporal horn of the ventricle.

On arrival at the Military Hospital for Head Injuries, Oxford, four days after injury, he was conscious but profoundly aphasic. He was thought to have a right homonymous hemianopia, and had a minimal hemiparesis which cleared up within six weeks. His convalescence was delayed by a chronic "aseptic" meningitis which persisted for five months after injury. An air encephalogram four months after injury showed considerable focal dilatation of the trigone and the whole of the temporal horn of the left lateral ventricle.

It was first possible to examine the visual fields thoroughly about five weeks after injury, when the patient had a complete right upper quadrantic defect. The visual fields were re-examined on several occasions, and on December 20, 1945, 19 months after injury, the complete and precise quadrantanopia persisted (Fig. 1). At this time the patient was able to hold a labouring job, and though he could barely read or write, his dysphasia did not handicap him in his daily life.

Case 2.—M.R.C.236, a man aged 24, on August 11, 1944, received a parasagittal wound in the left posterior parietal region (Fig. 2). Retrograde amnesia was less than 24 hours and post-traumatic amnesia less than a week.

On arrival at the Hospital for Head Injuries the following day he was drowsy, but could be roused, and though he was not obviously dysphasic he could not read. He had, to confrontation, a right homonymous hemianopia with spatial disorientation in the left half field; the right lower limb was very weak, and postural sensation, graphaesthesia, and appreciation of light touch were impaired. There was some increase in the reflexes in both lower limbs and both plantar responses were extensor. Fifty hours after injury the wound was excised, and debris removed from a track running beside the falx to a depth of 6 cm. The most lateral of the bone fragments was left *in situ*.

The patient made a satisfactory recovery, and four months after injury the only abnormal physical signs

were considerable impairment of postural sensation in the right toes and the defects in the visual field.

The visual fields were first fully examined three weeks after injury, when they showed a partial quadrantanopia with sparing of the horizontal meridian and a projection towards the fixation point in the vertical meridian. In addition all objects in the right half field appeared blurred and he had difficulty in localizing objects in that half field. The spatial disorientation on the left cleared up entirely. Psychometric tests showed marked incapacity in all tests involving visual imagery or spatial sense.

Case 3.—M.R.C.849, a man aged 24, on April 11, 1945, received a right temporo-parietal injury (Fig. 3) and also wounds of the right side of the chest. There was no retrograde amnesia and post-traumatic amnesia was one or two days. The head wound was caused by a metallic foreign body, which, at operation two days later, was found to have passed downwards and forwards, shattering the zygoma and coming to rest in the right cheek. There was considerable damage to the cerebral cortex, but apparently the temporal horn of the ventricle was not penetrated.

On admission to the Hospital for Head Injuries three months after injury he had a right facial weakness due to partial involvement of the facial nerve in the injury, and a minimal weakness of the left face and arm with slight increase in the reflexes in the left upper and lower limbs, and a flexor plantar response. There was no sensory loss, and the hemiplegia cleared up entirely six months after injury.

Seven months after injury the visual fields showed a left upper partial quadrantic field defect sparing the horizontal meridian and projecting towards the fixation point in the vertical meridian (Fig. 3).

Case 4.—M.R.C.193, a man aged 27, on August 6, 1944, received a parasagittal wound in the left posterior parietal region (Fig. 4). Retrograde amnesia was only a few seconds and post-traumatic amnesia five to 10 minutes.

On arrival at the Hospital for Head Injuries two days later he was alert and well orientated. He had no dysphasia. There was slight weakness of the right upper and of both lower limbs with slight increase in the reflexes in the right upper and lower limbs. Both plantar responses were, however, flexor, and there was no disturbance of any modality of sensation.

At operation, 60 hours after injury, the wound was excised and the dural defect found to measure 3 × 2 cm. Pulped brain and some relatively superficial foreign bodies were removed from the track which penetrated

* Reference number of the M.R.C. Penetrating Head Injury File, Military Hospital, Wheatley, Oxford.

for 4 cm. The patient made a good recovery and was left with no abnormal signs except the visual field defect.

Before operation he was thought, to confrontation, to have a right homonymous hemianopia, possibly not reaching to the fixation point. Two weeks after the injury the fields were first fully examined, and showed an almost complete right lower homonymous quadrant-anopia with 10° sparing around the fixation point in the vertical meridian rising to about 20° in the horizontal meridian. The visual fields continued to improve so that three months after injury there was only a slight defect in the periphery of the right lower quadrant sparing the horizontal meridian (Fig. 4).

Case 5.—M.R.C.515, a man aged 33, on November 24, 1944, received a gunshot wound in the right temporo-parietal region, and a metallic foreign body crossed the midline coming to rest immediately above and behind the left petrous temporal bone (Fig. 6). Twenty hours after injury the wound was excised, and in addition to the track passing medially caused by the foreign body which crossed the midline, there was a track passing inferiorly with a small laceration in the tentorium. Six days after injury it was necessary to decompress the posterior fossa and to release a tense loculus of cerebro-spinal fluid.

On admission to the Hospital for Head Injuries 16 days after injury he was still drowsy and moderately disorientated. There was a slight relative left hemiparesis with exaggerated reflexes in all limbs and bilateral extensor plantar responses. There was dysarthria with gross cerebellar ataxia worse on the left than the right. To confrontation there was thought to be a left homonymous hemianopia. He made an excellent recovery, and eight months after injury he showed a slight left hemiparesis with extensor plantar response on that side and exaggerated tendon jerks in all limbs. There was moderate cerebellar ataxia. The visual field showed a narrow, sector-shaped defect in the horizontal meridian reaching to the fixation point (Fig. 6).

Case 6.—M.R.C.189, a man aged 20, on August 3, 1944, received a gunshot wound low in the right parietal area (Fig. 11), which caused left hemiparesis, hemianaesthesia, and probably hemianopia. At operation 48 hours later there was a rather large bone defect with several fissures running out from it. A considerable amount of brain debris and bone fragments was removed, but the wound did not enter the ventricle.

On arrival at the Hospital for Head Injuries, he was fairly rational and orientated but not able to cooperate well. He had a left hemiparesis, most marked in the face, with impairment of postural sense and appreciation of pin prick on the left side. The hemiparesis improved markedly so that 10 months after injury it was represented only by minimal left facial weakness and slight hyperreflexia in the left upper limb. At that time sensation was normal except for minimal hypalgesia on the left side of the face, minimal astereognosis in the left hand, and slight delay in appreciation of temperature on the left hand.

Five days after injury he was thought to have, on confrontation, a left homonymous hemianopia. Three and a half weeks after injury when first fully examined he had a wide sector defect above and below the horizontal meridian (Fig. 11b), and 19 months after injury he had improved further and had only a left homonymous paracentral wedge-shaped scotoma on and below the horizontal meridian (Fig. 11c).

I wish to express my thanks to Dr. W. Ritchie Russell for his constant help and encouragement. I would also like to thank the surgeons and physicians of the Military Head Injuries Units both at Oxford and in the field for their detailed records, and to the orthoptists, in particular Miss Coates White, D.B.O., for their help with the visual field charts.

REFERENCES

- Brouwer, B. (1934). *Res. Publ. Ass. nerv. ment. Dis.*, **13**, 529.
 —, and Zeeman, W. P. C. (1926). *Brain*, **49**, 1.
 Chacko, L. W. (1948). *Journal of Neurology, Neurosurgery and Psychiatry*, **11**, 211.
 Clark, W. E. Le Gros, and Penman, G. G. (1934). *Proc. roy. Soc. B.*, **114**, 291.
 Cushing, H. (1921). *Brain*, **44**, 341.
 Glees, P., and Clark, W. E. Le Gros (1941). *J. Anat., Lond.*, **75**, 295.
 Holmes, G. (1918). *Brit. J. Ophthal.*, **2**, 353.
 — (1931). *Brain*, **54**, 470.
 Mackenzie, I., Meighan, S., and Pollock, E. N. (1933). *Trans. ophthal. Soc., U.K.*, **53**, 142.
 Meyer, A. (1907). *Trans. Ass. Amer. Phys.*, **22**, 7.
 Polyak, S. L. (1934). *Res. Publ. Ass. nerv. ment. Dis.*, **13**, 535.
 — (1941). "The Retina." Chicago.
 — (1942). *J. Mt Sinai Hosp.*, **9**, 698.
 Putnam, T. J. (1926). *Arch. Neurol. Psychiat.*, Chicago, **16**, 566, 683.
 Russell, W. R. (1947). *Brain*, **70**, 225.
 Walker, A. E., and Fulton, J. F. (1938). *Ibid.*, **61**, 250.





WOUNDS OF THE VISUAL PATHWAY: PART I: THE VISUAL RADIATION

J. M. K. Spalding

J Neurol Neurosurg Psychiatry 1952 15: 99-109
doi: 10.1136/jnp.15.2.99

Updated information and services can be found at:
<http://jnp.bmj.com/content/15/2/99.citation>

Email alerting service

These include:

Receive free email alerts when new articles cite this article. Sign up in the box at the top right corner of the online article.

Notes

To request permissions go to:
<http://group.bmj.com/group/rights-licensing/permissions>

To order reprints go to:
<http://journals.bmj.com/cgi/reprintform>

To subscribe to BMJ go to:
<http://group.bmj.com/subscribe/>