

Tunnelized Preauricular Transposition Flap for Reconstruction of Anterior Auricular Defects

P Sánchez-Sambucety, T Alonso-Alonso, and MA Rodríguez-Prieto

Servicio de Dermatología, Complejo Asistencial de León, León, Spain

To the Editor:

Reconstruction of the anterior aspect of the auricle of the ear after oncologic surgery is often complicated and requires imagination when planning the surgical technique. The techniques usually used are direct suture, grafts, second-intention healing, and postauricular pedicle flaps, in particular the "revolving door" flap.¹ We describe an ingenious preauricular transposition flap that is situated in the defect through an incision in the posterior aspect of the antihelix.

The patient was an 81-year-old man with a history of chronic bronchitis who was seen for extensive lesions on the anterior and posterior aspects of the auricle of the ear that were clinically and histologically compatible with squamous cell carcinoma and had been present for more than 1 year. We performed excision of both lesions including the perichondrium and respecting the cartilage; the defects were repaired using 2 preauricular and postauricular transposition flaps.

We first marked the flaps on the skin and then administered local anesthesia (bupivacaine with epinephrine) using the circumferential technique, infiltrating the whole circumference of the auricle starting at the lobule. For reconstruction of the defect of the antihelix, we designed a transposition flap using the preauricular region. The surface that was to be interposed in the auricular area was de-epithelialized (Figure 1). The flap was dissected above the superficial temporal vessels and passed through an incision on the posterior aspect of the antihelix to situate it over the defect (Figure 2). Finally, we used silk to suture the flap and preauricular region (Figure 3). For reconstruction of the posterior defect, we designed a rotational postauricular flap that was dissected and sutured to the defect.

Surgery to the auricle of the ear is complex, particularly when the disorder affects the anterior aspect, which is more visible and therefore requires better esthetic results; this

is even more complex if there is a second tumor on the same auricle. When the tumor is situated on the antihelix, reconstruction depends on the size of the resulting defect and on whether cartilage or perichondrium has been excised. Small defects can be sutured directly, sacrificing the helix, or if the perichondrium is intact, by second-intention healing or a graft. In defects of more than 1 cm that do not involve the perichondrium, we use these same techniques; if cartilage has been excised, postauricular flaps are used either as a revolving door island flap or as a transposition flap in 2 stages.^{2,3}

In our case, we describe a novel flap that, in a single surgical procedure, provides skin with a similar color and texture to the defect. The flap is well vascularised and has a good consistency and can be used for defects with or without alterations of the cartilage and perichondrium, particularly when we cannot use postauricular flaps or grafts.

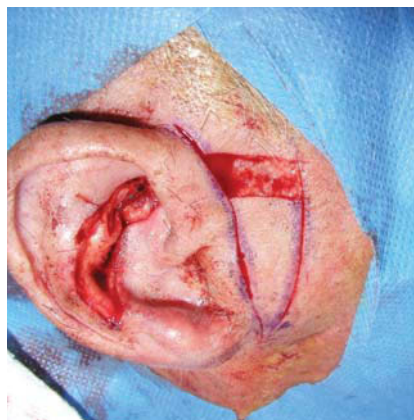


Figure 1. Preauricular transposition flap and de-epithelialization of the flap.

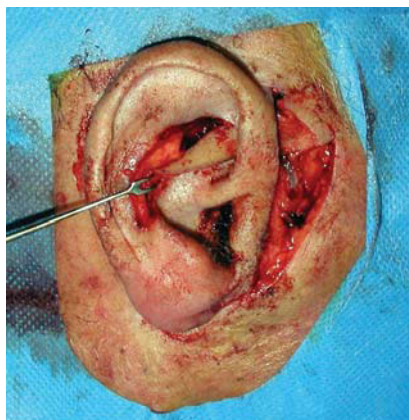


Figure 2. Tunneling the flap

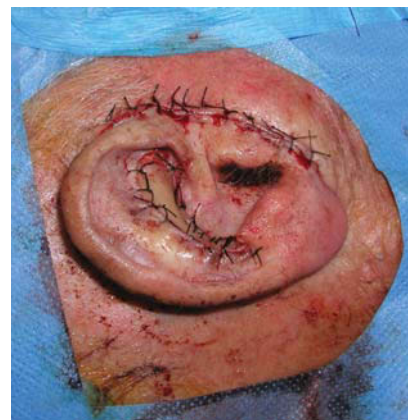


Figure 3. Suture.

References

1. Sánchez P, Rodríguez MA, Martínez M, Ruiz I. Leiomiomas cutáneos del pabellón auricular. Tratamiento quirúrgico. *Piel*. 2001;16:365.
2. Lázaro P, Suárez-Fernández R. Cirugía del pabellón auricular. In: Serrano Ortega S, editor. *Perfiles Quirúrgicos en Dermatología*. Barcelona, Madrid: Len/Mayo; 2005. p. 113-32.
3. Ciria G, Piqueras JM, Bengoechea MP, Pellicer D, Pellicer JL, Abascal A. Reconstrucción auricular de defectos secundarios a patologías adquiridas. In: Gil-Carcedo LM, Vallejo Valdezate LA, editors. *El oído externo*. Madrid: Ediciones Ergon, S.A.; 2001. p. 177-258.

Resolution of Recalcitrant Condylomata Acuminata in a Patient With Human Immunodeficiency Virus Treated With Topical Cidofovir

A Tejera-Vaquerizo, RJ Bosch-García, A Fernández-Orland, and E Herrera-Ceballos

Servicio de Dermatología, Hospital Universitario Virgen de la Victoria, Facultad de Medicina, Málaga, Spain

To the Editor:

Infection by the human papillomavirus (HPV) is the most frequent sexually transmitted infection and will affect between 1% and 35% of the population in their lifetimes.¹ Current data suggest that this percentage is increasing, especially among white men infected with the human immunodeficiency virus (HIV).² The medical costs of managing these cases have been calculated at €30 million in the United Kingdom alone in 2003.³ Currently available treatment for condylomata acuminata includes cryotherapy, podophyllotoxin, trichloroacetic acid, laser therapy, electrocautery, and, more recently, imiquimod—an immune-response modifier.⁴

We report the case of a patient infected by HIV who had condylomata acuminata resistant to conventional therapies; the condylomata acuminata was successfully treated with 3% topical cidofovir.

The patient was a 37-year-old man who had developed verruciform lesions around a year earlier on the inside of the foreskin and the coronal sulcus of the penis (Figure, A). The patient had been treated with podophyllotoxin, imiquimod, cryotherapy, electrocautery, and laser therapy, resulting in rapid reappearance of the lesions. The patient was infected by HIV and had a low CD4 lymphocyte count ($120 \times 10^6/L$). He was prescribed a 3% cidofovir cream to be applied once daily. Treatment was suspended after 5 days due to an intense inflammatory response in the treated areas. The treated area displayed marked erythema and small erosions in some of the condylomata (Figure, B). At this point, the treatment regimen was replaced by treatment with zinc sulphate and topical antibiotics. All the lesions and the erythema had disappeared 4 weeks later (Figure, C). After 1 year of follow-up the patient continued to show no evidence of recurrence.

Cidofovir is a nucleotide analogue of deoxycytidine monophosphate with a broad spectrum of action against DNA viruses, including HPV. To date, cidofovir has only been approved for intravenous use in the treatment of retinitis due to cytomegalovirus in HIV patients resistant to ganciclovir and foscarnet. It has, however, been shown to be effective as a topical treatment for some viral lesions including warts and *Molluscum contagiosum*.⁵ It has also been shown to be effective in some neoplastic lesions such as cervical intraepithelial neoplasia, erythroplasia of Queyrat, respiratory tract papillomatosis, Kaposi sarcoma, nasopharyngeal carcinomas associated with the Epstein-Barr virus, squamous cell carcinoma, basal cell carcinoma, and melanoma.^{6,7} The mechanism of action of cidofovir in cutaneous lesions caused by HPV is thought to be due to its antiviral and antiproliferative effect on the infected cells, which divide readily.⁸

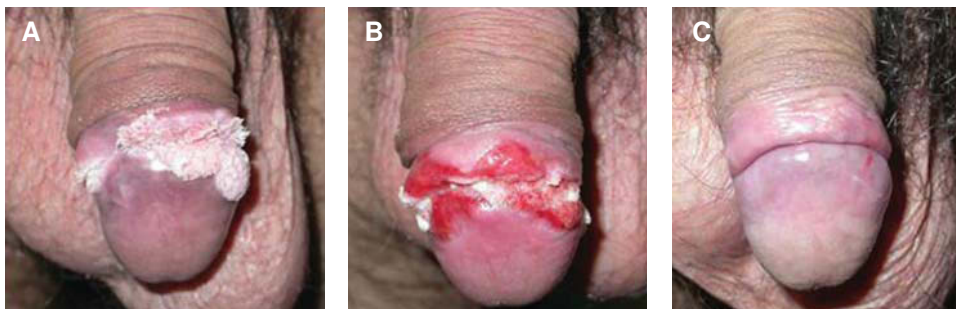


Figure 1. A, Verruciform condylomata acuminata on the inside of the foreskin and the coronal sulcus (Week 0). B, Inflammatory response to topical cidofovir with erythema and erosions (Week 1). C, Complete remission of the lesions at 4 weeks (Week 4).