

Cortical Language Activation in Stroke Patients Recovering From Aphasia With Functional MRI

Yue Cao, Eric M. Vikingstad, K. Paige George, Alex F. Johnson and K. M. A. Welch

Stroke. 1999;30:2331-2340

doi: 10.1161/01.STR.30.11.2331

Stroke is published by the American Heart Association, 7272 Greenville Avenue, Dallas, TX 75231

Copyright © 1999 American Heart Association, Inc. All rights reserved.

Print ISSN: 0039-2499. Online ISSN: 1524-4628

The online version of this article, along with updated information and services, is located on the World Wide Web at:

<http://stroke.ahajournals.org/content/30/11/2331>

Permissions: Requests for permissions to reproduce figures, tables, or portions of articles originally published in *Stroke* can be obtained via RightsLink, a service of the Copyright Clearance Center, not the Editorial Office. Once the online version of the published article for which permission is being requested is located, click Request Permissions in the middle column of the Web page under Services. Further information about this process is available in the [Permissions and Rights Question and Answer](#) document.

Reprints: Information about reprints can be found online at:
<http://www.lww.com/reprints>

Subscriptions: Information about subscribing to *Stroke* is online at:
<http://stroke.ahajournals.org/subscriptions/>

Cortical Language Activation in Stroke Patients Recovering From Aphasia With Functional MRI

Yue Cao, PhD; Eric M. Vikingstad, BS; K. Paige George, MA;
Alex F. Johnson, PhD; K.M.A. Welch, MD

Background and Purpose—Two mechanisms for recovery from aphasia, repair of damaged language networks and activation of compensatory areas, have been proposed. In this study, we investigated whether both mechanisms or one instead of the other take place in the brain of recovered aphasic patients.

Methods—Using blood oxygenation level–dependent functional MRI (fMRI), we studied cortical language networks during lexical-semantic processing tasks in 7 right-handed aphasic patients at least 5 months after the onset of left-hemisphere stroke and had regained substantial language functions since then.

Results—We found that in the recovered aphasic patient group, functional language activity significantly increased in the right hemisphere and nonsignificantly decreased in the left hemisphere compared with that in the normal group. Bilateral language networks resulted from partial restitution of damaged functions in the left hemisphere and activation of compensated (or recruited) areas in the right hemisphere. Failure to restore any language function in the left hemisphere led to predominantly right hemispheric networks in some individuals. However, better language recovery, at least for lexical-semantic processing, was observed in individuals who had bilateral rather than right hemisphere–predominant networks.

Conclusions—The results indicate that the restoration of left-hemisphere language networks is associated with better recovery and inversely related to activity in the compensated or recruited areas of the right hemisphere. (*Stroke*. 1999;30:2331-2340.)

Key Words: aphasia ■ brain ■ magnetic resonance imaging, functional ■ recovery ■ stroke, ischemic

Despite a large body of work on the roles of the left and right hemispheres during recovery from aphasia, there is limited understanding of cortical reorganization of language networks after stroke. Studies of recovering stroke patients with aphasia using cerebral blood flow (CBF) and metabolism measured at rest and during language tasks have demonstrated increased right-hemisphere involvement in language processing.¹⁻⁴ This has been further supported by worsening of language impairments in aphasic patients with a left-hemisphere infarct who suffered a subsequent right-hemisphere stroke.⁵ A similar decline in language abilities has been observed in patients with left-hemisphere stroke who underwent amygdala inactivation of right-hemisphere function.⁶ The right hemisphere also has been shown to contribute more to recovery of language comprehension than to production.⁷ Improvement of language also has been associated with the recruitment of undamaged regions in the left hemisphere.¹⁻³ Even with these findings, little is known about the precise role of the right hemisphere, the impact of undamaged left-hemisphere language regions, and the interaction of the 2

hemispheres in recovery from aphasia after left-hemisphere ischemic stroke.

The purpose of this study was to investigate brain mechanisms for recovery from aphasia via the study of the functional anatomy of aphasic patients who regained substantial language ability after left-hemisphere stroke. Using blood oxygenation level–dependent (BOLD)⁸ functional MRI (fMRI), we studied cortical language networks during lexical-semantic processing tasks in aphasic patients at least 5 months after stroke onset. We hypothesize that language activity in the compensated or recruited areas of the right hemisphere is inversely related to the restoration of left-hemisphere language networks.

Subjects and Methods

Subjects

Seven recovering aphasic stroke patients (2 men, 5 women; age range 20 to 56 years) participated in a picture-naming study (Table 1). Four (patients 1, 3, 6, and 7) also participated in a verb generation study. Inclusion criteria for patients were as follows:

Received June 10, 1999; final revision received August 12, 1999; accepted August 19, 1999.

From NMR Research Center, Department of Neurology, Henry Ford Health Sciences Center, Case Western Reserve University, Detroit, Mich (Y.C., E.M.V., K.P.G., A.F.J.); Department of Radiology, The University of Chicago Hospitals, Chicago, Ill (E.M.V.); and University of Kansas Medical Center, Kansas City, Kan (K.M.A.W.).

Correspondence to Yue Cao, PhD, Department of Radiology, Michigan State University, 184 Radiology Building, East Lansing, MI 48824. E-mail yue@radiology.msu.edu

© 1999 American Heart Association, Inc.

Stroke is available at <http://www.strokeaha.org>

TABLE 1. Right-Handed Recovering Stroke Patients With Aphasia

Patient No.	Sex	Age, y	Occlusion	Infarct Location	Lesion Extent (A-P/S-I/L-R), mm	Aphasia Type, day 1/day 4	Initial ADPASS, percentile	TI, mo	Aphasia Type at Study	ADPASS at Study, percentile
1	F	53	MCA	L frontal and operculum	25/48/33	Mixed nonfluent/TCM	8	32†	Anomic	89
2	F	20	MCA	L frontotemporoparietal and basal ganglia	82/66/34	Global/Global	<1	22*	Anomic	81
3	F	39	ICA	L inferior parietotemporal	80/54/40	Wernicke's/Wernicke's	18	5†	Conduction	79
4	M	31	MCA	L temporoparietal and insula	21/36/39	Wernicke's/Wernicke's	30	27*	Normal	99
5	F	56	MCA	L frontoparietal and basal ganglia	25/42/33	Global/TCS	<1	30*	TCS	73
6	F	26	ICA	L anterior superior frontal	42/42/38	TCM/TCM	N/A	5†	Anomic	92
7	M	54	MCA	L frontoparietal and insula	39/36/31	Global/Broca's	N/A	144†	Anomic	84

MCA indicates middle cerebral artery; ICA, internal carotid artery; TI, time interval between stroke onset and the fMRI study; Lesion Extent, largest extent of lesion in each direction; A-P, anterior-posterior; S-I, superior-inferior; L-R, left-right; TCM, transcortical motor; and TCS, transcortical sensory.

*Patient participated in picture naming paradigm only.

†Patient participated in picture naming and verb generation paradigms.

(1) right handedness, (2) native English speaker, (3) single unilateral left-hemisphere ischemic infarct with aphasia diagnosed by a certified speech-language pathologist and a neurologist, (4) no previous neurological or psychiatric disorders, (5) no history of dementia, and (6) significant recovery of language ability over months to years, as documented by a standardized language test, the Aphasia Diagnostic Profiles (ADP),⁹ and other clinical language measures. The control subjects were 37 neurological normal adults (18 men, 19 women; mean age 35 years), all of whom performed the picture-naming task. Of this group, a subset of 24 subjects (10 men, 14 women; mean age 38 years) performed the verb generation task. All subjects were right-handed, native English speakers. Handedness was assessed by the Edinburgh Inventory.¹⁰

The protocol was approved by the Human Rights Committee of Henry Ford Hospital. Written consent was obtained from all subjects. All subjects participated in a single functional imaging session.

Assessment of Aphasia Type and Severity

Aphasia type and severity were assessed with the ADP between 1 and 14 days after stroke onset in 5 patients (Table 1); each had an ADP aphasia severity score (ADPASS) below the 30th percentile. Initial ADP assessment was not carried out in 2 patients (patients 6 and 7), but their aphasia types and clinic presentations were documented with clinical bedside testing. Recovery of language ability was monitored using the ADP and other language measures (including picture naming, verb generation, rhyme, and semantic category judgment). Patients whose ADPASS exceeded the 70th percentile were enrolled in the fMRI study.

MRI Protocol

All scanning was performed on a 3T MRI scanner (Magnetom Scientific) with resonator head coil and SMIS console. BOLD contrast functional images were acquired with an RF-spoiled multi-slice interleaved excitation cycles (MUSIC)¹¹ gradient echo-pulse sequence with TE/TR=30/58 ms, FOV 240 mm, matrix size 128×64, slice thickness 9 mm, and flip angle 25°. With this sequence, 4 (5 in the case of patient 3) contiguous axial sections were acquired simultaneously through the perisylvian region in 3.6 s. During each language paradigm, 40 functional images per anatomic section were acquired, making the total scanning time 144 s. Four (or 5) T1-weighted anatomic images (TE/TR=22 ms/600 ms, FOV 240 mm, matrix size 256×192, slice thickness 9 mm) were acquired at locations corresponding to the functional images. In addition, T2-weighted anatomic images (TE/TR=68 ms/2800 ms, FOV 240 mm, matrix size 256×192, slice thickness 5 mm) that covered the entire brain were acquired in all stroke patients to accurately assess lesion size.

Language Task Paradigms

Picture Naming Paradigm

In the activation condition, a set of 36 black-and-white line drawings of common concrete objects, chosen from the Peabody Picture Vocabulary Test,¹² was shown to the subject. The subject was instructed to silently name the objects as they appeared. In the control condition, nonsense black-and-white line drawings were shown to the subject to remove activation for early visual processing. The subject was instructed to look at the nonsense line drawings without trying to name them or to find any recognizable feature in them. The nonsense drawings matched the angle of the visual field subtended in the activation condition and approximately matched the visual complexity of the line drawings.

Verb Generation Paradigm

In the activation condition, a set of 36 common concrete nouns was shown to the subject, who was instructed to silently generate a verb associated with each presented noun (eg, shown the word "cake," the subject thinks "eat"). In the control condition, 5 forward slashes were presented to the subject to remove activation for early visual processing. The subject was asked to merely look at these slashes without doing anything.

For both paradigms, task sets were divided equally into 4 task performance periods and interleaved with 4 control condition periods. During each task performance period, 9 items were presented at a rate of 1 every 2 s, except in the case of patient 2, for whom 6 items were presented at a rate of 1 every 3 s to compensate for her slower performance. Thus, each period was 18 s long, and an entire paradigm was completed in 144 s. A PC-driven, MRI-compatible video system was used to project language tasks onto a screen placed at one end of the scanner bore. Subjects viewed the presented tasks through mirrored goggles while lying supine in the scanner.

Before the scanning, all subjects were trained for the tasks, using stimuli sets different from those presented during scanning. All patients showed that they could perform a task within 2 to 3 s (the rate used during fMRI scanning) and correctly performed at least 70% of the training tasks. If a patient did not meet these standards, the fMRI study was postponed, and the patient was tested again after 3 months.

During fMRI scanning, subjects were interviewed about their task performance immediately after each paradigm performance. They were asked how many pictures (or verbs) they were able to name (or generate). If there was a large discrepancy compared with prescan testing, the patients' data were discarded. One patient who could not reliably describe his performance was excluded from the study (and not reported in this article).

Image Processing

Functional images were brought into alignment by in-planer translation and rotation before statistical analysis.¹³ If major movement of

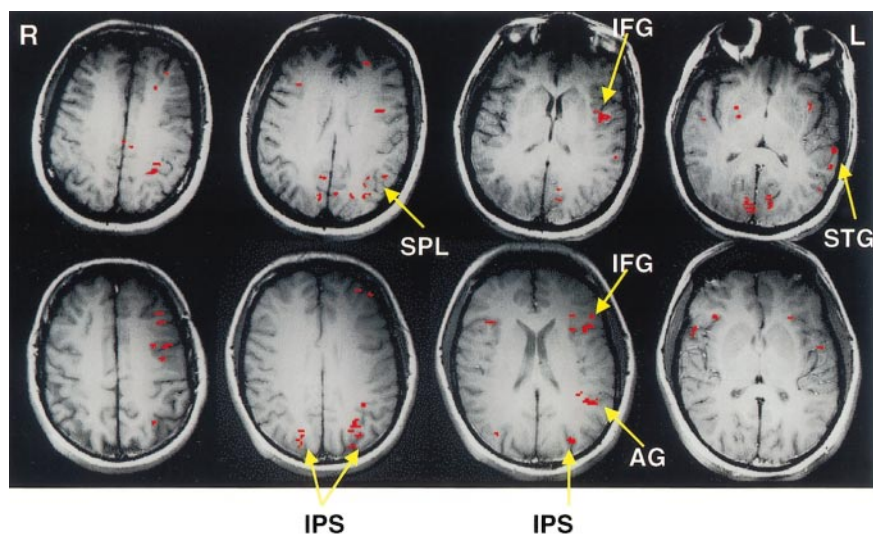


Figure 1. Activation patterns observed in typical normal subjects during silent picture naming (top row images) and silent verb generation (bottom row images). Two cortical regions in the left hemisphere: inferior frontal lobe and inferior parietal–superior temporal lobes, were markedly activated during picture naming. Activation was also observed in the left insula, bilateral occipital lobe, and left primary sensorimotor cortex. During verb generation, 3 cortical regions in the left hemisphere (inferior frontal lobe, inferior parietal–superior temporal lobes, and the banks of the intraparietal sulcus) were activated to a large degree. To a smaller extent, the right homologous regions were also activated.

the head occurred, motion artifact could not be corrected (usually >1.5 -mm translation) and the data were discarded.

Statistical analysis of the functional images was accomplished by a combination of complex temporal cross-correlation (cc), with sine and cosine waves having the periodicity of task performance (36 s)^{14,15} and cluster-size thresholding.¹⁶ All pixels were thresholded at a level of cc magnitude equal to 0.406 and cc phase centered at -45° and ranging between -90° and 45° , to yield an estimated 1-tailed type I error of 0.005. Pixels passing the cc threshold were subject to cluster-size thresholding (≥ 7 (pixels) $\times 0.88$ mm² = 6.2 mm²), resulting in an estimated false-positive rate of <0.0006 per pixel to justify the multiple (pixel) comparisons in an image. This cluster-size threshold, based on true neural activity that tends to stimulate signal changes over contiguous pixels, can independently and reliably reject false-positives without incurring unacceptable losses of power (increase of false-negatives) due to decreased false-positives.¹⁶

Using the phase of the complex temporal cross-correlation of a pixel, we assessed whether the infarct in the brains of chronic stroke patients caused any hemodynamic time delay of the activated pixels in the left (infarcted) hemisphere compared with the right (noninfarcted) hemisphere.

Localization of Activated Pixels

The pixels that passed both cc and cluster-size thresholds in the functional images were overlapped on the T1-weighted MR images. Then, each activated pixel was localized to its specific anatomic gyrus in each individual hemisphere, with use of the anatomic T1-weighted images and a brain atlas of computerized images.¹⁷ Based on previous observations that language networks are widely distributed and may extend beyond classic language areas,^{18,19} we computed activated volumes in 2 extended putative cortical language regions. The anterior region (labeled inferior frontal lobe [IFL] in the Results section) included the inferior and middle frontal gyri, and the posterior region (labeled inferior parietal and superior temporal lobes [IPSTL] in Results) included the supramarginal, angular, and superior temporal gyri.

Hemispherical Language Lateralization

A lateralization index (LI)^{20–22} was calculated by subtracting the activated volume observed in a region of the right hemisphere (V_R) from the activated volume in the same region of the left hemisphere (V_L) and dividing the difference ($V_L - V_R$) by the total activated volume in that region ($V_L + V_R$). Thus, an $LI = (V_L - V_R) / (V_L + V_R)$ of 1.0 corresponded to complete left lateralization, an LI of 0.0 indicated bilateral activation, and an LI of -1.0 indicated complete right lateralization. Statistical differences of activated volumes in the left and right hemisphere as well as the total activated volumes of both hemispheres between the patient and normal group were

assessed by the Student *t* test. If the total activated volumes of the 2 groups were approximately equal, an LI could be used to identify any shift of hemispheric language lateralization in the patient group compared with the normal group. To validate this, in the 2 cortical regions defined above, differences of activated volumes in the left and right sides and LIs between the patient and normal groups were assessed. The Mann-Whitney Rank test and Student *t* test were used to analyze LIs and activated volumes between the 2 groups, respectively. Because these statistical analyses (left, right, and total) were done in 2 separated cortical regions, $P=0.01$ was used as a significance level to justify multiple comparisons.

Factors Contributed to Recovery

Factors contributed to recovery of naming ability were assessed. A multiple regression model (probability 0.05 of F-to-enter) was used to test whether naming scores measured by the ADP at the time of fMRI study were significantly determined by any of following factors: recovery time (measured by time intervals between stroke onset and the study), fMRI measures (eg, activated volumes in left and/or right cortical regions and LIs in the anterior or posterior cortical regions), initial naming deficits, and age.

Results

Control Subjects

Cortical networks activated during picture naming involved 2 primary loci: the left inferior frontal lobe (IFL), including the inferior frontal gyri (IFG) and middle frontal gyri (MFG), and the left inferior parietal/superior temporal lobes (IPSTL), including the supramarginal, angular, and superior temporal gyri (SMG, AG, and STG, respectively). A typical example is shown in Figure 1 (top row). To a smaller extent, there was activation in the right homologous regions. The respective mean \pm SEM volumes of activated tissue in the left and right IFL were 0.59 ± 0.09 cm³ and 0.21 ± 0.04 cm³, with a mean LI of 0.51 (Table 2). The respective mean \pm SEM volumes of activated tissue in the left and right IPSTL were 0.84 ± 0.14 cm³ and 0.29 ± 0.05 cm³, with a mean LI of 0.45 (Table 2). Other activated cortical brain regions included the occipital lobe, insula, superior parietal lobule (SPL), and anterior cingulate gyrus. The cortical regions adjacent to the intraparietal sulcus (IPS) were rarely activated. The average volumes of activated cortical tissue in the left and right hemispheres were 2.93 ± 0.29 cm³ and 1.39 ± 0.20 cm³ (mean \pm SEM), respectively.

TABLE 2. Activated Volumes in the Left and Right Hemispheres and LIs from the Patient and Normal Groups

	Picture Naming			Verb Generation		
	Patients, mean±SD (n=6)	Normals, mean±SD (n=37)	<i>P</i>	Patients, mean±SD (n=4)	Normals, mean±SD (n=23)	<i>P</i>
IFL						
L volume, cc	0.29±0.25	0.59±0.58	0.22	1.25±0.85	1.34±0.94	0.86
R volume, cc	0.69±0.62	0.21±0.24	<0.001	0.90±1.05	0.34±0.40	0.06
LI	-0.43±0.44	0.51±0.39	<0.001	0.39±0.44	0.58±0.34	0.43
IPSTL						
L volume, cc	0.43±0.23	0.84±0.87	0.26	0.29±0.20	0.67±0.74	0.32
R volume, cc	0.74±0.76	0.29±0.33	<0.02	0.99±0.42	0.26±0.36	<0.001
LI	-0.10±0.46	0.45±0.52	<0.02	-0.55±0.18	0.48±0.52	<0.01

L indicates left hemisphere; R, right hemisphere.

The verb generation task activated a cortical network that mainly included the left IFL and IPSTL, and the regions adjacent to the left IPS. A typical example is shown in Figure 1 (bottom row). To a smaller extent, the right homologous regions were also activated. During this task, respective activated volumes of tissue in the left and right IFL were 1.34 ± 0.19 cm³ and 0.34 ± 0.08 cm³ (mean±SEM), with a mean LI of 0.583 (Table 2). Activated volumes in the respective left and right IPSTL were 0.67 ± 0.15 cm³ and 0.26 ± 0.07 cm³ (mean±SEM), with a mean LI of 0.475 (Table 2). Activated volume in the left IPS was 0.59 ± 0.13 cm³ (mean±SEM). Other activated cortical structures included the occipital lobe, and to a small degree the insula, and anterior cingulate gyrus. The mean volumes of cortical activation in the left and right hemispheres were 3.56 ± 0.43 cm³ and 1.59 ± 0.22 cm³ (mean±SEM), respectively.

Although for the control group as a whole, left-hemispheric language dominance was observed during both tasks, in men LI primarily lateralized to left; in women, approximately half had left lateralization and the other half bilateral representation. No age difference was observed.

Clinical Presentation of Patients

At initial clinical evaluation (on the first day of symptom onset), 3 patients (patients 2, 5, and 7) had global aphasia, 2 (patients 3 and 4) had Wernicke's aphasia, 1 (patient 6) had a transcortical motor aphasia, and 1 (patient 1) had mixed nonfluent aphasia (Table 1). In 4 patients (patients 2, 3, 4, and 6), the initial aphasia types were stable over the first 4 days. In the other 3 patients, by 4 days after onset of stroke their aphasia profiles had evolved (Table 1). Aphasia was caused by occlusion of the left middle cerebral artery in 5 patients (patients 1, 2, 4, 5, and 7), by occlusion of the left internal carotid artery in patient 3, and by dissection of the left internal carotid artery in patient 6. Figure 2 illustrates the extent of the infarct of the patients, and a brief description of the location of the infarct is also provided in Table 1. The largest dimension of the infarct, measured on cross-sectional T2-weighted MR images obtained at the time of the fMRI study, varied from 39 to 82 mm (Table 1). By the time of study, 5 to 144 months after the onset of aphasia, all patients

had made substantial improvement in their language abilities, with the ADPASS at least in the 73rd percentile, but the majority still had a mild aphasia (Table 1). Their scores on a naming subtest of ADP varied from the 63rd to 91st percentiles (Table 3).

Activation Patterns of Individual Patients

To elucidate the individuality of activation patterns in aphasic patients, we will briefly highlight below some of the unique differences in each patient.

Patient 1 participated in the picture naming and verb generation tasks 32 months after stroke onset, through which her ADPASS has improved from the 8th to the 89th percentiles (Table 1). During picture naming, extensive activated tissue volumes were observed in the left SMG (0.75 cm³, 290% of mean activated control volume), the cortical regions adjacent to the left IPS (1.35 cm³, 830% of control volume), the right STG and MTG (0.89 cm³, 440% of control volume), and the right IFG (0.325 cm³, 200% of control volume). No activation was observed in the left IFG and the MFG, part of which was damaged by infarct.

During verb generation, tissue volumes were activated in the left MFG anterior to the infarct (0.49 cm³, 35% of control volume), the right SMG and AG (0.39 cm³, 370% of control volume), and the right insula (0.21 cm³, 240% of control volume). Activity in the left inferior parietal lobe (SMG and AG) and left IPS was negligible despite this region's being structurally intact.

Patient 2 participated in the picture naming paradigm 22 months after stroke onset, through which her ADPASS has improved from <1st to the 81st percentiles (Table 1). During the naming study, activation was in right-hemisphere structures almost exclusively (accounting for 92% of all cortical activity). Activated volumes were found in the right SMG and AG (0.96 cm³, 825% of mean control volume), the right IFG and MFG (0.47 cm³, 225% of normal volume), the right insula (0.48 cm³, 600% of normal volume), and the right STG (1.31 cm³, 740% of normal volume). The left hemisphere was markedly void of activity (Figure 3); activation was detected only in the left MFG and left STG (65% and 20% of control volume, respectively).

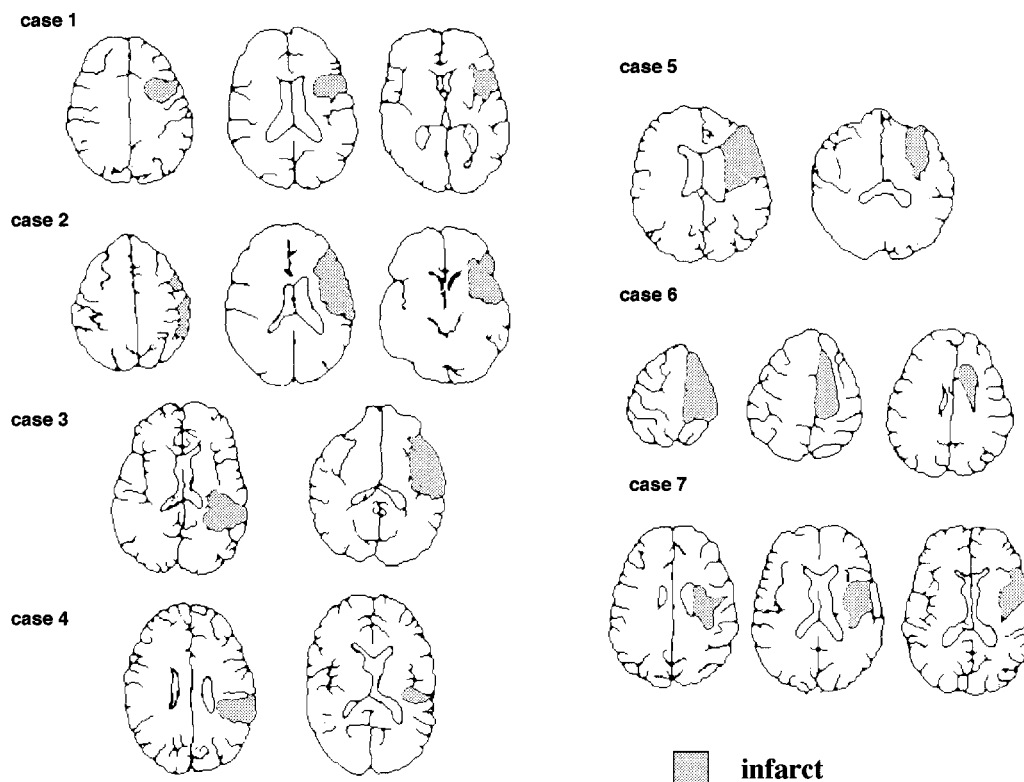


Figure 2. The extent of the infarct in 7 stroke patients. The shaded areas represent the infarct.

Patient 3 participated in the picture naming and verb generation tasks 5 months after stroke onset, through which her ADPASS has improved from the 18th to the 79th percentiles (Table 1). During picture naming, large-order

TABLE 3. Variables to Determine the Extent of Recovery of Naming Ability

Patient No.	Naming Scores		
	at Study, percentile	LI in IFL (IFG+MFG)	TI, mo
1	75	-1.00	32
2	75	-0.68	22
3	63	-0.54	5
4	82	-0.51	27
5	91	-0.14	30
6	91	0.26	5

	Regression Model		
	Constant	Independent Variable 1 (LI)	Independent Variable 2 (TI)
B	77.351	26.895	0.687
SE	3.034	4.237	0.152
β		1.094	0.777
<i>t</i>	25.497	6.347	4.506
Significance	0.000	0.008	0.020

A multiple regression model was used to test that naming scores measured at the time of fMRI study were significantly correlated with LI in the IFL and recovery time ($F=21.2, P<0.017$). TI indicates time intervals between stroke onset and the study.

activation was observed in the right IFG and MFG (0.97 cm³, 470% of mean control volume), the right STG (0.35 cm³, 200% of control volume), the right insula (940% of control volume), and the cingulate gyrus bilaterally (anterior, 500% of control volume; posterior, 600% of control volume). Activated volumes were decreased in the left SMG and AG (0.16 cm³, 30% of control volume) and the left STG (0.09 cm³, 50% of control volume).

During verb generation, large-order activation was observed in the right SMG and AG (0.56 cm³, 530% of control volume), the right anterior cingulate gyrus (0.11 cm³, 200% of control volume), and the STG and MTG bilaterally (right, 1.02 cm³, 570% of control volume; left, 0.70 cm³, 230% of normal volume). Activation in left and right inferior frontal regions did not differ from normals. Despite the infarct's involving only a small portion of the anterior-inferior parietal lobe, the entire inferior parietal lobe failed to activate.

Patient 4 participated in the picture naming paradigm 27 months after his stroke, through which his ADPASS has improved from the 30th to the 99th percentiles (Table 1). During picture naming, there was marked activation in the right IFG and MFG (1.83 cm³, 880% of control volume) and 3 separate posterior brain regions: the left postcentral gyrus immediately anterior to the infarct (0.48 cm³, 800% of normal volume), the left inferior parietal region, including the SPL posterior to the infarct (0.64 cm³, 570% of control volume), and the left STG inferior to the infarct (0.54 cm³, 150% of control volume). Left inferior frontal activity was normal.

Patient 5 participated in the picture naming paradigm 30 months after stroke, through which her ADPASS has improved from <1st to the 73rd percentiles (Table 1). During

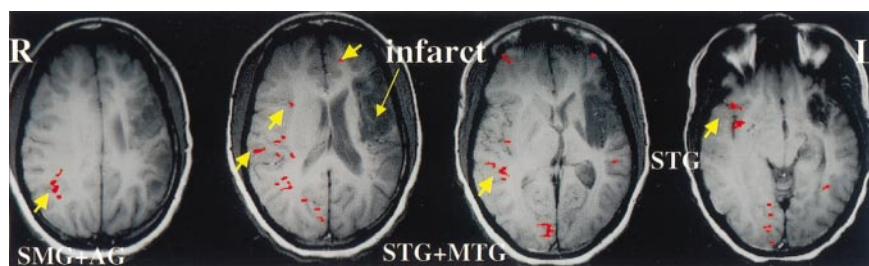


Figure 3. Activation obtained from patient 2 during picture naming 22 months after stroke. Almost exclusively, activation was in the right-hemisphere structures (comprising 92% of all cortical activity). These right anatomic structures included the SMG and AG, the IFG and MFG, the insula, and the STG. The left hemisphere was markedly void of activity; activation was detected only in the left MFG and left STG.

picture naming there was bilateral activation in both inferior frontal and inferior parietal regions. In the right IFG and MFG, activated volumes did not differ from mean control volumes (0.21 cm^3 ; however, left IFG and MFG activity was markedly reduced to 0.16 cm^3 (25% of control volume) and shifted anterior to the infarct. The activated volume in the right SMG and AG was increased (0.62 cm^3 530% of normal volume), whereas left SMG and AG activated volumes were normal compared with control volume (0.51 cm^3). Minimum activation was observed in superior temporal regions.

Patient 6 participated in the picture naming and verb generation paradigms 5 months after stroke, through which her language abilities have improved, her aphasia type has changed from mixed transcortical aphasia to anomia, and her ADPASS has reached the 92nd percentile (Table 1). During picture naming, activated volumes were observed in the IFG and MFG bilaterally (left, 0.58 cm^3 , equal to mean control volume; right, 0.35 cm^3 , 170% of control volume) and in the AG bilaterally (left, 0.22 cm^3 , equal to control volume; right, 0.26 cm^3 , 510% of control volume). There was a small volume of activation in the left anterior STG. No activity was recorded in undamaged left SMG, despite this region's being activated in normal controls.

During verb generation, the activated network in this patient compared with control subjects was mirrored across the midhemispheric line (Figure 4). Large volumes were activated in the right SMG and AG (0.98 cm^3 , 930% of mean control volume), the banks of the right IPS (1.57 cm^3 , 740% of control volume), the right STG (0.36 cm^3 , 200% of control volume), and the IFG and MFG bilaterally (left, 2.46 cm^3 , 180% of control volume; right, 2.40 cm^3 , 700% of control volume). Small volumes of tissue were also activated along the banks of the left IPS (0.35 cm^3 , 60% of control volume) and the left STG (0.14 cm^3 , 50% of control volume). As with picture naming, activity was depressed in the left inferior parietal lobe, including the SMG and AG.

Patient 7 participated in the study 12 years after his stroke. At the time of study, he still suffered anomia, and his

ADPASS was at the 84th percentile (Table 1). Data collected during picture naming were discarded due to motion artifact. During verb generation, activated volumes were observed in the bilateral IFG and MFG (left, 1.09 cm^3 , equal to mean control volume; right, 0.81 cm^3 , 240% of control volume), the right MTG (0.49 cm^3 , 21-fold larger than control volume), the right SMG and AG (1.06 cm^3 , 10-fold larger than control volume), the left posterior cingulate gyrus (1.13 cm^3 , 45-fold larger than control volume), and the left STG (0.32 cm^3 , equal to control volume). Such bilateral activation in the IFG and MFG was rarely observed in normal males. The activated volume along the banks of the left IPS was 0.39 cm^3 (60% of control volume), whereas the left SMG and AG were void of activity, despite being structurally intact.

Summary of Patient Group

(1) The infarct that caused language deficits in the patients did not reduce the total activated brain volumes after patients had substantially regained their language abilities. The mean total activated volumes observed in the patient group during picture naming and verb generation were $4.27 \pm 0.73 \text{ cm}^3$ (mean \pm SEM) and $5.35 \pm 1.25 \text{ cm}^3$ (mean \pm SEM), respectively, and were not significantly different from those observed in the control group ($3.79 \pm 0.44 \text{ cm}^3$ and $5.15 \pm 0.57 \text{ cm}^3$, respectively) (Figure 5). However, activated volumes in the patient group were increased in the right hemisphere and decreased in the left hemisphere during both paradigms compared with those in the normal group (Figure 5). The increased right-hemisphere activation in the patient group was statistically significant ($P < 0.03$) during picture naming and marginally significant ($P < 0.06$) during verb generation. The decreased activation in the left hemisphere of the patient group was not significant during either paradigm ($P > 0.1$).

(2) The increased role of the right hemisphere in lexical-semantic processing of the patients was clearly evidenced by activation in the 2 extended putative cortical language regions (IFL and IPSTL). During picture naming, activation in the IFL and IPSTL of the patient group was significantly right

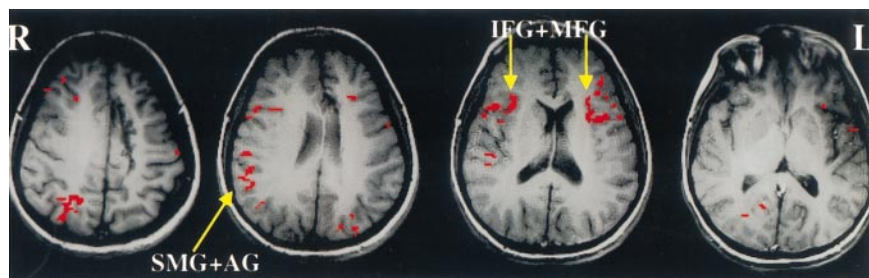


Figure 4. Activation obtained from patient 6 during verb generation 5 months after stroke onset. The cortical regions in the bilateral inferior frontal lobe, the bilateral insula, the right inferior parietal lobe, and the banks of the right IPS were markedly activated. Left superior temporal cortex was also activated. Left SMG, structurally intact and commonly activated in normal subjects, failed to activate.

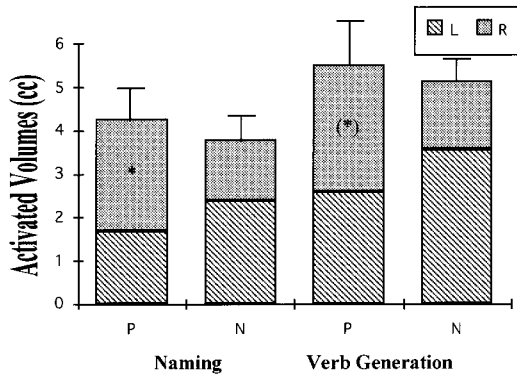


Figure 5. Activated volumes from the patient (P) and normal (N) groups during picture naming and verb generation. The total activated volumes in both hemispheres were approximately equal in the 2 groups during each paradigm. In the patient group, the increased activated volumes in the right hemisphere were significant during picture naming, and marginally significant during verb generation compared with those in the normal group. The activated volumes in the left hemisphere of the patient group was decreased during both paradigms compared with that in the normal group. L indicates left hemisphere; R, right hemisphere.

shifted with $P < 0.001$ and $P < 0.02$, respectively (Table 2). These right shifts were supported by both right-shifted LIs or increased activated volumes on the right side (Table 2). During verb generation, a significant right-shifted activation was observed in the posterior cortical language region (IP-STL) of the patient group compared with that of the normal group. Again, this right shift was evidenced from either the right-shifted LI ($P < 0.01$) or the increased activated volume on the right side ($P < 0.001$; Table 2). However, in the IFL region, the patient group showed increased activation on the right side ($P < 0.06$), whereas the 2 groups had approximately equal activation volumes on the left side, which was substantially involved in verb generation in normal subjects²³ (Table 2).

(3) Activation in the patients' left hemispheres was shifted posteriorly or anteriorly, away from the site of the infarct. Such shifts were often associated with decreased activity in other intact regions of the left hemisphere. This behavior was observed during picture naming in patient 4, in whom activity had shifted both anteriorly and posteriorly to his left inferior parietal infarct. In patient 5, IFL activity during naming shifted anteriorly to the infarct, located in the left frontal and parietal lobes, and the basal ganglia. In patient 1, in whom the infarct was located in the frontal and opercular regions, activation during naming shifted posteriorly in the region of the IPS.

(4) Some undamaged regions in the patients' left hemispheres, usually activated in normal subjects, failed to activate. Specifically, during verb generation, activity in the left SMG was completely absent in 3 patients (patients 3, 6, and 7), and during picture naming it was absent in 4 patients (patients 2, 3, 4, and 6). During verb generation, the left AG was always activated in normal subjects but was not activated in any of the patients, despite only 2 patients having damaged part of the AG. The region surrounding the left IPS (in which activation was observed in normal subjects and believed to be associated with written lexicon decoding and early semantic

processing; findings will be published elsewhere) was activated to some extent (40% of normal volume), even though no patients had infarcts in this region. Possibly, language networks linked to these regions were disrupted.

(5) The naming score at the time of fMRI study was significantly correlated with 2 independent variables: recovery time and LI in the IFL region ($R^2 = 0.934$, $F = 21.2$; $P < 0.017$, by multiple regression). This was assessed in the 6 patients whose picture naming data were reported here. Details of the regression model are provided in Table 3. There was no significant interaction between recovery time, the LI, initial naming deficits, and age. Age was not significantly correlated with the extent of recovery of naming ability or any fMRI measurements (LI and activated volumes). Lesion size, interacted with initial naming deficits, was marginally correlated with the final naming scores.

(6) No delay response of BOLD effects in the left infarcted hemisphere was detected. With a temporal resolution of 3.7 s, no abnormal time delay of BOLD effects in the activated pixels of the patients' left hemispheres was detected, compared with those in the right hemisphere.

Discussion

The purpose of this study was to investigate neural mechanisms for recovery from aphasia via the study of the functional anatomy of aphasic patients who regained substantial language ability after left-hemisphere stroke. Two neural mechanisms for recovery have been proposed: restitution of damaged left-hemisphere language regions and activation of compensatory right-hemisphere areas.^{3,24} Previous PET studies have provided supporting evidence for the redistribution of language networks bilaterally after left-hemisphere stroke. Improved outcome in aphasic patients was associated with increased cerebral glucose metabolism in the infarct, its contralateral region, and Broca's area during spontaneous speech.²⁵ Left frontal and right perisylvian activation has been observed in patients recovering from Wernicke's aphasia.³ Such right-hemisphere involvement has been assumed to rely on reactivation of compensatory regions that are part of a preexisting bilateral language network. Also, structural repair of damaged language regions has been called a major factor in the restitution of left-hemisphere language functions.^{3,24} We observed that in 7 patients recovering from aphasia, repair of left-damaged language functions in combination with right-hemisphere activation was associated with a better outcome. Patients with right-predominant networks recovered substantially but still had obvious language dysfunction.

In PET studies, the restitution of left-hemisphere language functions has been mainly attributed to structural repair of the damaged region rather than to the compensatory activation of the areas bordering the infarct.^{3,24} The use of intersubject averaging may obscure the evidence of activation in border zones. In our fMRI study, shifted language activity within 1 or 2 gyri of the infarct margin is often observed in patients whose initial aphasia is less severe, eg, patients 1 and 4. Both structural repair of damaged tissue and activation in these border zone regions should be considered to contribute to the restitution of damaged left-hemisphere networks.

Whether right-hemisphere activation in recovering aphasics involves the re-activation of a preexisting language network^{3,24} or recruitment of new language areas is unanswered. No evidence in the literature clearly supports one hypothesis over another. In a recent study of 37 normal right-handed adults, lexical-semantic processing networks were completely left dominant in only 32% of the subjects and bilaterally distributed in 26%, with a higher prevalence of bilaterality in females than males.²⁶ In the remaining subjects, the distribution of the networks varied between completely left dominant and bilateral. Visual tachistoscopic studies have shown that the right hemisphere has some rudimentary language ability.²⁷ Split-brain studies have shown that the right hemisphere is capable of processing simple linguistic inputs but is not quite capable of language output.²⁸ These findings suggestively support, but not exclusively, the hypothesis that after left-hemisphere damage, preexisting language areas in the right hemisphere are reactivated.

There is little doubt that the right hemisphere contributes to recovery from aphasia after left-hemisphere stroke. The question remains as to its precise role and how the hemispheres interact during recovery. A longitudinal (1-year) CBF study¹ of recovering aphasic patients given a word comprehension task showed that good recovery in patients with left inferior-frontal lesions was associated with diffuse right-hemisphere CBF activation within 3 months after stroke but with an increase in left posterior temporal–inferior parietal activation at 5 to 12 months after stroke. In contrast, patients with left posterior temporal-parietal lesions and poor recovery had higher CBF in the right inferior frontal region 5 to 12 months after stroke than within 3 months. In our patients, who still had mild residual anomia at the time of the study but had improved substantially in naming ability, we observed a significant rightward shift of activation during picture naming compared with that in normal controls. The degree of right shift in the inferior frontal lobe was inversely correlated with the extent of recovery of naming ability (Table 3). In other words, better recovery was associated more with bilateral activation in the inferior frontal lobe than with activation that was predominantly right sided. For example, in patients 1 and 2, who had not only severe left frontal damage but also slow recovery of naming ability, activation was primarily on the right side. In patient 6, whose infarct spared the inferior frontal lobe and who recovered naming ability more quickly, activation in the inferior frontal lobe was bilateral, with weak left dominance. During aphasia recovery, the right inferior frontal lobe was recruited in these patients, forming either a right-dominant or bilateral network. Nevertheless, the right inferior frontal lobe alone seems less effective than both inferior frontal lobes working together. The statistical analysis of the data across the sample indicates that the restoration of left-hemisphere networks is associated with better recovery and inversely related to language activity in the right hemisphere. A recent investigation of the aphasic brain reported a similar finding: the metabolic recovery of the left superior temporal cortex was significantly inversely correlated with fluency task–induced activation of the right superior temporal cortex and the number of errors made in the Token test.²⁴ The authors concluded that the permanent loss

of left superior temporal activity reinforced the compensatory activity of the right hemisphere and that the left-hemispheric structural reorganization was significantly more effective than the right-hemisphere compensation.²⁴ Our data provide support for these types of recovery mechanisms. A longitudinal study in the future will evaluate these hypotheses further.

The observation of the conservation of the total activated volumes in this study also supports the concept of left- and right-hemisphere interaction during recovery. The infarct did not significantly reduce or increase the total activated volumes in our patients. Intuitively, a bilateral or right-sided network would require more cortical regions to accomplish a language task than the original left-sided network, particularly since the right hemisphere seems to be less effective for language than the left hemisphere. Our data do not support this assumption. Instead, they provide further evidence that the compensatory (or recruited) activity in the right hemisphere is inversely related to the degree of recovery in the left hemisphere. We are aware that we considered only the regions activated above a threshold, and subthreshold activity could be relevant as well. The conservation of the total activated volumes needs to be further evaluated in a large longitudinal study. Along with the scientific interest of the conservation of the total activated volumes in both hemispheres, this unique finding also allows us to use the LI to assess a language hemispheric shift, because activated volumes decrease on one side and increase on the other. This has been validated in our data by assessing activated volumes in the left and right hemispheres, respectively, as well as the LI (Table 2). Furthermore, 2 other fMRI studies^{21,22} have validated the lateralization index during semantic decision tasks when compared with intracarotid amobarbital assessment of hemispheric dominance in epilepsy patients.

Speech-language disorders can be caused by disruption anywhere in the complex language networks. In the aphasic brain, failure to activate undamaged left-hemisphere structures usually activated in healthy controls is common. Instead, other right- or left-hemisphere regions are often activated. For example, in patient 6, who had a superior frontal infarct, no activation was seen in the left inferior parietal regions, but the right mirror region was activated (Figure 4). The deactivation in the left inferior parietal region appears to be caused by a disconnection from the rest of the language network, which is subsequently connected with the right homologous region for compensation of the loss of function. Similar observations have been made of metabolic depression that extended beyond the infarct into other regions of the affected hemisphere and even into the unaffected hemisphere.²⁹

We studied brain activation in a group of aphasic patients who had different lesion sites and linguistic processing disturbances. This heterogeneity reflects the nature of the stroke population. The different patterns of the redistributed language networks in recovering aphasics also reflect individualized recovery process, which can be affected by many factors, including lesion size and location, recovery time, aphasia severity, age, and therapeutic intervention. With individual patients, the redistributed language networks may

also vary greatly according to specific language task demands and depending on the specific functions disrupted after stroke onset. Functional MRI appears to be an ideal method to investigate these factors in patients with different behavioral, anatomic, and pathological profiles. Despite the variation, all of our patients had recovered a considerable degree of language function since stroke onset. In this initial study, we grouped the patients' data to elucidate general roles of the left and right hemispheres in language recovery after stroke. Patients who progress toward normal, even though they have different types and degrees of language disruption initially, may share similar recovery mechanisms.

In this study, we used language tasks generally applied to heterogeneous aphasic populations. For example, we chose a confrontation-naming task because naming problems occur in all types of aphasia, although failure to name an object can have different underlying processing disturbances. An additional consideration of the chosen tasks was that the underlying cognitive-linguistic components and their associated functional anatomy have been well established.^{19,30–32} According to information-processing models,³³ picture naming is composed of (1) early visuospatial processing of a picture, (2) visual recognition of an object, (3) semantic processing, and (4) phonological retrieval of the word. Our control condition, viewing nonsense line drawings, reasonably removes early visual processing but might not eliminate processing associated with object recognition. Separating object recognition processing from the retrieval of an object's name is quite difficult. Neuroimaging data, however, indicate several cortical regions associated with object recognition—the right lateral-posterior occipital lobe³⁴ and the bilateral posterior fusiform gyri.³⁵ We therefore excluded these areas from our analysis of language activation. On the other hand, semantic processing and phonological retrieval of a word have been shown to be left hemisphere–dominant functions in normal right-handers.^{19,26,30} Verb generation involves (1) visuospatial processing of the seen word, (2) orthographic processing of the individual letters and whole word, (3) semantic processing, and (4) phonological retrieval of the word. Also, a verb is functionally distinct from a noun.³³ To remove early visual processing, we used 5 forward slashes as a control condition, which has been previously used in an fMRI study of word reading.³⁶ Again, orthographic processing of the individual letters and whole word is left-hemisphere dominant in normal right-handers.³⁰ Considering that our patients had no occipital infarcts and no visual and object-recognition deficits, there is little reason to suppose that the anatomic locations of these functions in the patients differed from those in normal persons. Therefore, the cortical regions included in our analysis most likely are not part of the networks involved in the visuospatial processing and object recognition. Another challenge faced in the study was controlling for task difficulty and attention. Increase of task difficulty may enlarge activated volumes.³⁷ In this initial study, we selected a group of patients who had mild deficits after a prolonged period of recovery. The task, although designed to be simple, may still be cognitively challenging for patients. This is an unavoidable difficulty for this kind of study. Because the total volume of activated tissue was

approximately equal in the control and patient groups, task difficulty most likely was not a major factor altering brain activity patterns in the patients.

Because of concerns over motion artifact caused by mouth movement,³⁸ language production during the fMRI scanning was done “silently,” with subjects thinking their answers, not speaking them. As a result, we did not monitor subject performance during scanning, which may have been a shortcoming in our method. Nevertheless, “silent language” produced activation patterns similar to those of spoken language.³⁸ To ensure that subjects followed the instructions and performed the tasks, before scanning we evaluated and documented the subjects' naming and verb generation abilities. We also interviewed them immediately after each paradigm to confirm that they had been attentive and performed the task successfully.

In summary, with fMRI we investigated cortical language activation in patients recovering from aphasia after a single left-hemisphere ischemic infarct. The results indicate that 2 factors contributed to recovery—restitution of damaged left-hemisphere language networks and activation of compensated (or recruited) areas in the right hemisphere. The results also suggest that after focal left-hemisphere damage, a bilaterally reorganized language network works more effectively than a right-predominant network. Finally, it appears that compensatory right-hemisphere language activity is inversely related to the restoration of the left-hemisphere language networks, which is associated with a better outcome.

Acknowledgments

This work was supported in part by AHA Grant-in-Aid 96009160 and Established Investigator Award 9940132N. The authors would like to thank Dr Steven Levine for patient referral; Will Hula, MS, for assistance in patients' language testing; and Dr Mike Boska for methodological advice in the NMR Lab.

References

- Knopman DS, Rubens AB, Selnes OA, Klassen AC, Meyer MW. Mechanisms of recovery from aphasia: evidence from serial xenon 133 cerebral blood studies. *Ann Neurol*. 1984;15:530–535.
- Demeurisse G, Capon A. Brain activation during a linguistic task in conduction aphasia. *Cortex*. 1991;27:285–294.
- Weiller C, Isensee C, Rijntjes M, Huber W, Muller S, Bier D, Dutschka K, Woods RP, Noth J, Diener HC. Recovery from Wernicke's aphasia: a positron emission tomographic study. *Ann Neurol*. 1995;37:723–732.
- Ohyama M, Senda M, Kitamura S, Ishii K, Mishina M, Terashi A. Role of the nondominant hemisphere and undamaged area during word repetition in poststroke aphasics. *Stroke*. 1996;27:897–903.
- Basso A, Gardelli M, Grassi MP, Mariotti M. The role of the right hemisphere in recovery from aphasia: two case studies. *Cortex*. 1989;25:555–566.
- Kinsbourne M. The minor hemisphere as a source of aphasic speech. *Arch Neurol*. 1971;25:302–306.
- Gainotti G. The riddle of the right hemisphere's contribution to the recovery of language. *Eur J Disord Commun*. 1993;28:227–246.
- Ogawa S, Lee T, Nayak AS, Glynn P. Oxygenation-sensitive contrast in magnetic resonance image of rodent brain at high magnetic fields. *Magn Reson Med*. 1990;14:68–78.
- Helm-Estabrooks N. *Aphasia Diagnostic Profiles*. San Antonio, Tex: Special Press; 1991.
- Oldfield RC. The assessment and analysis of handedness the Edinburgh Inventory. *Neuropsychologia*. 1971;9:97–113.
- Loenneker T, Hennel F, Henning J. Multislice interleaved excitation cycles (MUSIC): an efficient gradient-echo technique for functional MRI. *Magn Reson Med*. 1996;35:870–874.

12. Dunn A. *The Peabody Picture Vocabulary Test*. Minneapolis, Minn: American Guidance Service; 1965.
13. Cao Y, Towle VL, Levin DN, Balter JM. Functional mapping of human motor cortical activation by conventional MRI at 1.5 T. *J Magn Reson Imaging*. 1993;3:869–875.
14. Bandettini PA, Jesmanowicz A, Wong EC, Hyde JS. Processing strategies for time-course data sets in functional MRI of the human brain. *Magn Reson Med*. 1993;30:161–165.
15. Lee AT, Glover GH, Meyer CH. Discrimination of large venous vessels in time-course spiral blood-oxygen-level-dependent magnetic-resonance functional neuroimaging. *Magn Reson Med*. 1995;33:745–754.
16. Forman SD, Cohen JD, Fitzgerald M, Eddy WF, Mintun MA, Noll DC. Improved assessment of significant activation in functional magnetic resonance imaging (fMRI): use of a cluster-size threshold. *Magn Reson Med*. 1995;33:636–647.
17. Damasio H. *Human Brain Anatomy in Computerized Images*. New York, NY: Oxford University Press; 1995.
18. Binder JR, Frost JA, Hammeke TA, Cox RW, Rao SM, Prieto T. Human brain language areas identified by functional magnetic resonance imaging. *J Neurosci*. 1997;17:353–362.
19. Bookheimer SY, Zeffiro TA, Blaxton T, Gaillard W, Theodore W. Regional cerebral blood flow during object naming and word reading. *Hum Brain Mapping*. 1995;3:93–106.
20. Vikingstad EM, Cao Y, George KP, Faull J, Johnson A, Welch KMA. Studies of language systems in recovered aphasic stroke patients using functional MRI. *J Cereb Blood Flow Metab*. 1997;17(suppl 1):S272. Abstract.
21. Binder JR, Swanson SJ, Hammeke TA, Morris GL, Mueller WM, Fischer M, Benbadis S, Frost JA, Rao SM, Houghton VM. Determination of language dominance using functional MRI: a comparison with the Wada test. *Neurology*. 1996;46:978–984.
22. Desmond JE, Sum JM, Wagner AD, Demb JB, Shear PK, Glover GH, Gabrieli JDE, Morell MJ. Functional MRI measurement of language lateralization in Wada-tested patients. *Brain*. 1995;118:1411–1419.
23. Petersen E, Fox PT, Posner M, Mintun M, Raichle M. PET studies of the cortical anatomy of single word processing. *Nature*. 1988;331:585–589.
24. Karbe H, Thiel A, Weber-Luxenburger G, Herholz K, Kessler J, Heiss WD. Brain plasticity in poststroke aphasia: what is the contribution of the right hemisphere. *Brain Lang*. 1998;64:215–230.
25. Heiss W-D, Kessler J, Karbe H, Fink GR, Pawlik G. Cerebral glucose metabolism as a predictor of recovery from aphasia in ischemic stroke. *Arch. Neurology*. 1993;50:958–964.
26. Vikingstad EM, Cao Y, George KP, Faull JA, Johnson AF, Welch KMA. Studying distributions in cortical language lateralization using functional MRI. *J Cereb Blood Flow Metab*. 1997;17(suppl 1):S273. Abstract.
27. Iacoboni M, Zaidel E. Hemispheric independence in word recognition: evidence from unilateral and bilateral presentations. *Brain Lang*. 1996;53:121–140.
28. Kutas M, Hillyard SA, Gazzaniga MS. Processing of semantic anomaly by right and left hemispheres of commissurotomy patients: evidence from event-related brain potentials. *Brain*. 1988;111:553–576.
29. Cappa SF, Perani D, Grassi F, Bressi S, Alberoni M, Franceschi M, Bettinardi V, Todde S, Fazio F. A PET follow-up study of recovery after stroke in acute aphasics. *Brain Lang*. 1997;56:55–67.
30. Petersen SE, Fiez JA. The processing of single words studied with positron emission tomography. *Annu Rev Neurosci*. 1993;16:509–530.
31. Damasio AR, Tranel D. Nouns and verbs are retrieved with differently distributed neural systems. *Proc Natl Acad Sci U S A*. 1993;90:4957–4960.
32. Kertesz A, Harlock W, Coates R. Computer tomographic localization, lesion size and prognosis in Aphasia and nonverbal impairment. *Brain Lang*. 1979;8:34–50.
33. Ellis AW, Young AW. *Human Cognitive Neuropsychology*. Hillsdale, NJ: Lawrence Erlbaum Associates; 1988.
34. Malach R, Reppas JB, Benson RR, Kwong KK, Jiang H, Kennedy WA, Ledden PJ, Brady TJ, Rosen BR, Tootell RB. Object-related activity revealed by functional magnetic resonance imaging in human occipital cortex. *Proc Natl Acad Sci U S A*. 1995;92:8135–8139.
35. Haxby JV, Ungerleider LG, Clark VP, Schouten JL, Hoffman EA, Martin A. The effect of face inversion on activity in human neural systems for face and object perception. *Neuron*. 1999;22:189–199.
36. Pugh KR, Shaywitz BA, Shaywitz SE, Constable RT, Skudlarski P, Fulbright RK, Bronen RA, Shankweiler DP, Katz L, Fletcher JM, Gore JC. Cerebral organization of component processes in reading. *Brain*. 1996;119:1221–1238.
37. Metter EJ. PET in aphasia and language. In: Kirshner HS, ed. *Handbook of Neurological Speech and Language Disorders*. New York, NY: Marcel Dekker; 1995; 187–221.
38. Yetkin FZ, Hammeke TA, Swanson SJ, Morris GL, Mueller WM, McAuliffe TL, Houghton VM. A comparison of functional MR activation patterns during silent and audible language tasks. *AJNR Am J Neurodiol*. 1995;16:1087–1092.