

See discussions, stats, and author profiles for this publication at: <https://www.researchgate.net/publication/250924965>

Pendrin expression in nodular and non-nodular thyroid tissues

Article in *Endokrynologia Polska* · July 2013

Impact Factor: 0.99 · Source: PubMed

READS

33

9 authors, including:



Yersu Kapran

Istanbul University

86 PUBLICATIONS 781 CITATIONS

SEE PROFILE



Duran Ustek

Medipol University

99 PUBLICATIONS 862 CITATIONS

SEE PROFILE



Fatih Tunca

Istanbul University

39 PUBLICATIONS 295 CITATIONS

SEE PROFILE



Faruk Alagol

Koc University

79 PUBLICATIONS 543 CITATIONS

SEE PROFILE



Pendrin expression in nodular and non-nodular thyroid tissues

Ekspresja pendryny w guzkowej i pozaguzkowej tkance tarczycowej

Berna Temel¹, Nurdan Gul¹, Faruk Kutluturk², Yersu Kapran³, Sema Sirma⁴, Duran Ustek⁴, Fatih Tunca⁵, Yasemin Giles⁵, Faruk Alago¹

¹Department of Endocrinology and Metabolism, Istanbul University, Faculty of Medicine, Istanbul, Turkey

²Department of Endocrinology and Metabolism, Gaziosmanpasa University, Faculty of Medicine, Tokat, Turkey

³Department of Pathology, Istanbul University, Faculty of Medicine, Istanbul, Turkey

⁴Department of Genetics, Institute for Experimental Medical Research (DETAE), University of Istanbul, Istanbul, Turkey

⁵Department of General Surgery, Istanbul University, Faculty of Medicine, Istanbul, Turkey

Abstract

Introduction: Different mechanisms for the expression of pendrin which is an apical iodide transporter have been reported in nodular thyroid tissues compared to normal thyroid. The aim of the present study was to determine the alterations of pendrin expression in nodular and surrounding non-nodular thyroid tissues and clarify the role of pendrin in the functional behaviour of nodular lesions.

Material and methods: Twenty-six nodular and paired non-nodular normal thyroid tissues were collected at the same centre. Patients were divided into two groups based on the function of the dominant thyroid nodule; hot nodules (n = 18) and cold nodules (n = 8). mRNA levels of pendrin were evaluated by quantitative RT-PCR. Pendrin protein expression was determined by immunohistochemical analysis. Results of dominant nodules were compared to non-nodular thyroid tissue of the same patient.

Results: No statistically significant difference was found with respect to qualitative and quantitative measurements of pendrin expression between hot and cold nodules. However, percent immunohistochemical staining of pendrin was significantly higher in both hot and cold nodules compared to non-nodular thyroid tissue of the same patients. RT-PCR revealed comparable mRNA levels of pendrin gene between hot nodules and corresponding normal thyroid tissues. However, in cold nodules, significantly decreased mRNA levels of pendrin were observed compared to normal thyroid tissue. mRNA levels of pendrin showed significant positive correlation with TSH in corresponding non-nodular thyroid tissues.

Conclusions: The present study demonstrates that expression of pendrin could not be influenced by TSH in thyroid nodules and expression level of pendrin seems not to have an effect on nodule function. (*Endokrynol Pol* 2013; 64 (3): 208–214)

Key words: pendrin, expression, nodular thyroid disease

Streszczenie

Wstęp: W guzkowej tkance tarczycowej opisano odmienny od pozaguzkowej tkanki tarczycowej mechanizm ekspresji pendryny — transportera jodu zlokalizowanego w części szczytowej komórki. Celem badania było ustalenie zmian w ekspresji pendryny w guzkowej tkance tarczycowej i otaczającej ją pozaguzkowej tkance tarczycowej, aby wyjaśnić rolę pendryny w zachowaniu czynnościowym zmian guzkowych.

Materiał i metody: W tym samym ośrodku pobrano 26 wycinków guzkowej tkanki tarczycowej i sparowanych wycinków pozaguzkowej prawidłowej tkanki tarczycowej. Pacjentów podzielono na dwie grupy w zależności od statusu czynnościowego guzka dominującego: grupę z guzkami gorącymi (n = 18) i grupę z guzkami zimnymi (n = 8). Poziom mRNA i pendryny oznaczono ilościowo metodą RT-PCR. Ekspresję białka pendryny oznaczono metodą immunohistochemiczną. Wyniki dla guzków dominujących porównano z wynikami dla tkanki pozaguzkowej u tego samego pacjenta.

Wyniki: Nie stwierdzono statystycznie znamiennych różnic pomiędzy guzkami gorącymi i zimnymi, jeżeli chodzi o wyniki oznaczenia ilościowego i jakościowego ekspresji pendryny. Procentowe barwienie immunohistochemiczne w kierunku pendryny było natomiast znamienne większe zarówno w przypadku guzków gorących, jak i zimnych w porównaniu z tkanką pozaguzkową u tych samych pacjentów. RT-PCR wykazało porównywalne poziomy mRNA genu kodującego pendrynę w guzkach gorących i prawidłowej tkance tarczycowej u tych samych pacjentów. Z kolei w przypadku guzków zimnych stwierdzono znamienne niższe poziomy pendryny w porównaniu z prawidłową tkanką tarczycową. Stwierdzono też korelację dodatnią poziomu mRNA pendryny i poziomu TSH w korespondujących tkankach pozaguzkowych.

Wnioski: W przeprowadzonym badaniu wykazano, że na ekspresję pendryny nie może mieć wpływu TSH w guzkach tarczycy oraz że poziom ekspresji pendryny nie wydaje się wpływać na czynność guzków. (*Endokrynol Pol* 2013; 64 (3):208–214)

Słowa kluczowe: pendryna, ekspresja, guzki tarczycy

This project was funded by The Society of Science Research Projects in Istanbul University, project number: T-497/25062004.



Faruk Kutluturk M.D., Assoc. Prof., Gaziosmanpasa University, Faculty of Medicine, Department of Endocrinology and Metabolism, 60100 Tokat, Turkey, tel.: +90 507 247 73 98, fax: +90 356 212 21 42, e-mail: fkutluturk@yahoo.com

Introduction

Nodular goitre is a complex disease with a high prevalence but its pathogenesis is still not completely understood. Both genetic and environmental factors have been found to play a role [1–3]. The best known environmental factor is iodine deficiency [4]. Cigarette smoking, nutritional goitrogens, and radiation exposure are the other known environmental factors. Constitutional parameters like age and female gender are also important in the aetiology of nodules. Genetic background is a factor in whether all the abovementioned environmental factors will cause nodule development [1–3].

The development of nodular goitre is thought to be a continuous process starting from thyroid hyperplasia and simple diffuse goitre. Therefore, genes coding for thyroglobulin (Tg), thyroid peroxidase (TPO), sodium-iodide symporter (NIS) and pendrin, which are important proteins in thyroid physiology and hormone synthesis, are candidate genes for the development of nodular goitre [5–9].

Pendrin is a hydrophobic transmembrane glycoprotein located at the apical membrane of thyrocytes [7, 8, 10, 11]. The gene coding for pendrin known as pendred gene (PDS) was cloned in 1997 [12]. It is located at chromosome 7q 22-31 and composed of 2,343 base pairs. PDS (SLC26A4) is a member of an anion transporter family known as SCL26A. Besides thyroid, PDS is expressed mainly in the inner ear and kidney. In the inner ear and kidney, pendrin functions as a Cl⁻/HCO₃⁻ exchanger [13, 14].

Pendrin in the thyroid is thought to be responsible for iodide efflux from the follicular epithelium to the follicular lumen where organification of iodide takes place [15, 16]. Pendred Syndrome is an autosomal recessive disorder caused by mutations in the PDS gene and is associated with goitre and sensorineural hearing loss [17, 18]. The goitre in Pendred Syndrome is variable in its expression. When present, it is often multinodular, develops around puberty, and is generally characterised by a positive perchlorate discharge test whereby iodide is inappropriately discharged from the thyroid upon stimulation with perchlorate [18].

Pendrin expression of normal and tumoural thyroid tissues has been investigated in various studies [10, 17, 19, 20]. In the present study, we investigated the expression of pendrin in benign nodules and their surrounding normal thyroid tissue samples by both PCR and immunohistochemistry. Our aim was to determine the differences between the expression level of pendrin both in nodular and paired non-nodular thyroid tissue and to detect the correlation between pendrin expression and functional status of the nodule.

Material and methods

This prospective study was designed from Endocrinology and Metabolism, Surgery and Pathology Department of Istanbul University Faculty of Medicine. Thyroid tissue specimens were collected from 52 unrelated patients undergoing total or near total thyroidectomy for removal of solitary nodule or multinodular goitre. All patients were negative for anti-thyroglobulin and anti-thyroperoxidase antibodies. Fifteen patients had a family history of goitre.

Tissue samples

Tissue specimens of the dominant thyroid nodule and surrounding normal-appearing (non-nodular) thyroid were collected from each patient at the time of surgery. They were frozen in liquid nitrogen and stored at –80°C. Detailed information on the nodules of each patient was obtained by physical examination, scintigraphy and ultrasonography, so that the dominant nodule could be identified unequivocally both at the time of specimen taking during surgery and at post-operative histological examination. Histological examination was done by two experienced pathologists at different times. Lymphocytic thyroiditis was observed in paired non-nodular thyroid tissue of 20 patients and six patients were found to have papillary carcinoma in the dominant nodule. The abovementioned 26 cases were excluded from the study.

Nodules were divided into two groups as hot (n = 18) or cold (n = 8) based on the scintigraphic features of the dominant nodule. Diagnosis of toxic adenoma and toxic multinodular goitre was based on the signs and symptoms of thyrotoxicosis, increased serum free thyroid hormones and suppressed TSH concentration (i.e. TSH < 0.270 mU/mL; lower limit of normal range), associated with a nodular goitre presenting predominant technetium uptake in one (or more) nodule(s) as shown by the scintigraphy. The diagnosis of euthyroid nodular goitre was made by finding normal TSH (i.e. 0.27–4.0 IU/mL) in the presence of nodular goitre. Table 1 summarises the clinical and histological characteristics of the remaining 26 patients.

Immunohistochemistry

Immunohistochemistry was performed on paraffin-embedded tissues. Tissue blocks of the 26 patients were obtained from the archival material of the Pathology Department of Istanbul University, Faculty of Medicine. 0.5–2 μm thick sections of the dominant nodule and paired non-nodular thyroid tissue were cut and mounted on glass slides, deparaffinised by serial passages in xylene and alcohol series. Subsequently, for heat antigen retrieval (AR), microwave pretreatment (three

cycles of 5 min each) was performed in 10 mM EDTA buffer (pH:8). Then endogenous peroxidase activity was quenched with % 3H₂O₂ for 20 min. Blockade of the proteins was done using Large Volume Ultra V Block (cat no: TA-015-UB). Sections were subsequently incubated for two hours at RT with the monoclonal Anti-Pendrin antibody (Clone UIRE, 01065 Code No:KO143) diluted at 1/100. After washing with PBS, the sections were incubated with biotinylated goat anti-polyvalent antibody (Cat no: TP-015-BN) for 25 min at RT and washed in PBS again. Following this, incubation with streptavidin peroxidase (Cat no: TS-015-HR) for 25 min was performed. After washing with PBS, staining was completed by incubation with a substrate chromogen solution (AEC chromogen; Cat no: TA-015-HAS). Negative controls were obtained by studying non-thyroid tissues and by studying thyroid tissues incubated with preimmune antisera and immune sera preabsorbed with excess corresponding peptide.

Immunohistochemical evaluation

The number of positive cells was counted in ten microscopic fields at a magnification of x 200. The percentage of stained cells in every microscopic field was determined and then the mean percentage of immunostaining was calculated. This was done for both the dominant nodule and the paired non-nodular thyroid tissue of each patient. Immunostaining intensity was also taken into account in immunohistochemical analysis (grade 0 = no staining; grade 1 = faint, grade 2 = intermediate between 1 and 3; and grade 3 = strong).

Extraction of RNA

Frozen samples of nodules and their paired normal thyroid tissue corresponding to those examined in immunohistochemical study were analysed for their mRNA content. Total RNA was isolated using an RNA extraction kit (RNeasy Fibrous Tissue Kit, Qiagen, Germany) according to the manufacturer's instructions. The quality of RNA was assessed by conventional gel electrophoresis. Only RNAs showing the clear band intensity of 28S and 18S rRNAs were selected for further analysis.

Reverse Transcription RT

Complementary DNA (cDNA) was synthesised from total RNA. One microgram of total RNA was reverse transcribed in a 20- μ L reaction volume containing 5 μ g/mL random hexamers, 0.5 mM dNTP, 0.01 M DTT, 1 U/ μ L ribonuclease inhibitor, 2.5 U/ μ L reverse transcriptase (all enzymes and chemicals were supplied from MBI Fermentas, Germany). The thermal cycling for cDNA synthesis consisted of 10 min of hybridisation of random hexamers and total RNA at 70°C, 1 h of RT

reaction at 37°C and 5 min of RT-inactivation at 99°C. cDNA synthesised by PCR was stored at -20°C prior to quantitative PCR analysis.

Real-time Quantitative PCR

Expression levels of pendrin mRNA and the housekeeping gene β ₂-microglobulin (B2MG) as endogenous control were analysed by quantitative PCR using LightCycler (Roche Diagnostics GmbH, Germany). We used the SYBR Green 1 dye (Roche, Mannheim, Germany) binding method. Oligonucleotide primers for pendrin and (B2MG) as endogenous control were as follows: pendrin forward primer, 5'-CGGATATGGTCTCTACTCTGC-3'; pendrin reverse primer, 5'-TGCTGCTGGATACGAGAAAGTG-3'. B2MG forward primer, 5'-TGC CGT GTG AAC CAT GTG AC-3' and B2MG reverse primer, 5'-ACC TCC ATG ATG CTG CTT ACA-3'.

The following amplification programme was used: one cycle of 60 seconds (s) at 95°C, followed by 45 cycles consisting of 10 s at 95°C, 5 s at 58°C, and 20 s at 72°C. Melting curve analysis consisted of 0 s at 95°C, 10 s at 65°C, and 10 s at 95°C. A standard run curve was generated for each amplification using serial dilutions of a cDNA mixture expressing the genes analysed. Expression of each gene was calculated with a programme found in LightCycler software. Quantification results were expressed in relative expression units [REUs]. REUs were calculated using expression of β ₂-microglobulin as endogenous control. (REU = target gene (pendrin) expression/ β ₂-microglobulin expression \times 100).

The protocol of this study was approved by the Ethical Committee of Istanbul University Medical Faculty. Informed consent was obtained from all patients before the procedures.

Statistical analysis

Data was entered and analysed by Software Package for Social Sciences version 13 [SPSS 13]. Data was expressed as percentage, frequency; mean \pm standard deviation [SD]. Expression levels were compared using nonparametric Wilcoxon signed-rank test. Correlation of pendrin gene expression with clinical parameters was analysed using Spearman's test and $p < 0.05$ was considered statistically significant.

Results

Pendrin Protein Expression

Pendrin protein expression was investigated by immunohistochemistry in all thyroid tissue samples (Table I). In thyrocytes, pendrin immunostaining was restricted to the apical membrane, and neither intracellular nor intraluminal staining was observed. Immunostaining was specific for the follicular epithelium. Stromal cells such as

Table I. Clinical and histological characteristics, immunohistochemical staining of pendrin, quantitative measurement of mRNA of pendrin in nodular and surrounding non-nodular thyroid tissues of the study group**Tabela I. Charakterystyka kliniczna i histologiczna, barwienie immunohistochemiczne w kierunku pendryny, pomiar ilościowy mRNA pendryny w guzkowej tkance tarczycy i otaczającej tkance pozaguzkowej tarczycy w badanej grupie**

No	Sex/age (yr)	TSH at the time of surgery [IU/mL]	Nodule diameter [mm]	Scintigraphy	Histo-pathology	IHK positivity of nodules (%)	IHK intensity of nodules	IHK positivity of surrounding non-nodular tissue (%)	IHK intensity of surrounding non-nodular tissue	Pendrin mRNA REU in nodules	Pendrin mRNA REU in surrounding non-nodular tissue
1	F/53	0.005	45	Hot	AN	90	3	0	0	0.043	0.149
2	M/48	0.007	23	Hot	AN	25	2	5	1	0.007	0.043
3	F/73	0.571	51	Cold	AN	80	1	10	1	0.238	0.948
4	M/37	0.462	47	Hot	AN	70	1	10	1	0.447	0.455
5	F/74	0.967	45	Cold	AN	50	1	0	0	0.350	0.372
6	F/54	0.071	38	Hot	AN	20	1	0	0	0.022	0.293
7	M/53	0.023	49	Hot	AN	—*	—	—	—	0.113	0.039
8	F/52	0.149	28	Hot	AN	80	3	15	1	0.753	0.253
9	F/53	0.018	28	Hot	AN	100	3	10	1	0.281	0.553
10	M/57	0.006	45	Hot	AN	80	3	0	0	0.399	—**
11	F/70	2.66	34	Cold	FA	100	3	0	0	0.235	0.106
12	M/60	0.022	33	Hot	AN	90	3	0	0	0.245	0.145
13	M/50	0.248	43	Hot	AN	50	1	10	1	0.532	0.413
14	M/40	0.499	30	Hot	AN	80	2	40	1	0.133	0.195
15	F/57	0.054	25	Hot	AN	30	1	0	0	0.270	0.411
16	F/72	0.008	27	Hot	AN	70	3	0	0	0.292	0.321
17	F/41	1.82	23	Cold	AN	10	1	0	0	0.256	0.570
18	M/54	1.15	38	Cold	FA	50	2	0	0	0.079	0.305
19	F/56	0.013	45	Hot	AN	100	3	10	1	—**	0.361
20	M/39	0.440	14	Hot	AN	75	2	40	2	0.496	0.327
21	M/51	0.019	35	Hot	AN	100	3	5	1	1.629	0.286
22	F/59	2.2	12	Cold	AN	70	1	20	1	0.103	1.906
23	F/57	0.186	25	Hot	AN	10	1	0	0	0.791	0.020
24	M/38	0.277	40	Cold	AN	90	3	0	0	0.764	0.884
25	F/19	0.686	20	Cold	AN	0	0	0	0	0.651	1.781
26	F/52	0.153	32	Hot	AN	80	2	10	1	1.463	0.761

*Number 7 of the study group could not be immunostained; **For patients 10 and 19, mRNA measurements of pendrin could not be completed for technical reasons. REU (relative expression unit) = Target gene (pendrin)expression/ β 2-microglobulin expression \times 100; M — male; F — female; MNG — Multinodular goitre; SN — Solitary nodule; TMNG — Toxic multinodular goitre; TA — Toxic adenoma; AN — Adenomatous goitre; FA — Follicular adenoma; NA — Not available; IHK — Immunohistochemistry

vascular endothelial cells, lymphocytes, and macrophages did not show any reaction with the anti-pendrin antibody. Pendrin immunostaining was heterogeneous between follicles and thyrocytes of the same patient (Fig. 1). In the whole group, pendrin immunostaining percentage was significantly higher in nodular thyroid tissue compared to corresponding non-nodular thyroid tissue (64% *v.* 7%, $p < 0.001$) (Fig. 2A).

Quantitative measurements of pendrin mRNA by RT-PCR in nodular and paired normal thyroid tissue

were performed successfully in 24 patients (Table I). No statistically significant difference was observed with respect to quantitative mRNA measurements between nodular and normal thyroid tissues (0.42 ± 0.42 *v.* 0.48 ± 0.49 , $p = 0.657$) (Fig. 2B).

Hot Thyroid Nodules ($n = 18$)

Pendrin immunohistochemical staining was significantly higher in hot nodules compared to corresponding normal thyroid tissue (67% *v.* 9%, $p < 0.001$)

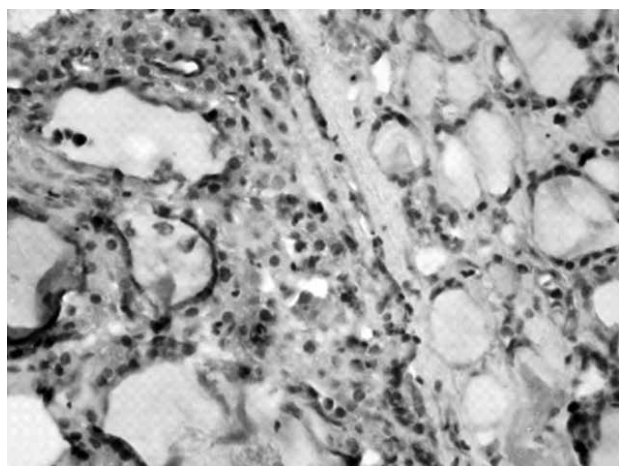


Figure 1. Immunostaining for pendrin in nodular/non-nodular thyroid tissues. The staining is heterogeneous and profound in nodules compared to surrounding tissue

Rycina 1. Barwienie immunohistochemiczne w kierunku pendryny w guzkowej i pozaguzkowej tkance tarczycowej. Poziom wybarwienia jest niejednorodny i silnie wyrażony w guzku w porównaniu z tkanką otaczającą

(Fig. 2A). However, quantitative measurement of pendrin mRNA was not significantly different in nodular tissue compared to surrounding non-nodular thyroid tissue (0.44 ± 0.44 v. 0.32 ± 0.22 respectively, $p = 0.326$) (Fig. 2B). No significant correlation was observed between mRNA level and percent immunostaining both in non-nodular thyroid tissue and hot nodules ($p = 0.735$ and $p = 0.309$, respectively).

Cold Thyroid Nodules ($n = 8$)

Pendrin immunostaining was significantly higher in cold thyroid nodules compared to corresponding normal thyroid tissue (56% v. 3% , $p = 0.017$) (Fig. 2A). RT-PCR revealed significantly decreased pendrin mRNA levels in cold nodular thyroid tissue compared to normal parenchyma (0.33 ± 0.25 v. 0.86 ± 0.67 , $p = 0.036$). No significant correlation was found between mRNA concentrations and percent immunostaining in non-nodular thyroid tissues and cold nodules ($p = 0.098$ and $p = 0.740$ respectively).

No statistically significant difference was found between hot and cold nodules with respect to quantitative pendrin mRNA measurements and percent immunostaining ($p = 0.710$ and $p = 0.440$ respectively). Nor was any significant difference evident with respect to percent immunostaining between corresponding normal thyroid parenchyma of hot and cold nodules ($p = 0.23$). However, pendrin mRNA level was significantly lower in hot nodules' corresponding normal parenchyma compared to cold nodules' corresponding normal tissues ($p = 0.031$) (Fig. 2B).

Patients with hot nodules had significantly lower TSH concentration at the time of operation compared to TSH of patients with cold nodules (0.13 ± 0.17 mIU/L v. 1.26 ± 0.87 mIU/L, $p < 0.001$).

A statistically significant correlation was observed between TSH and mRNA level of pendrin in normal thyroid parenchyma in the whole group ($r = 0.397$, $p < 0.05$). However, this association was lost in nodular thyroid tissues in the whole group ($r = 0.012$, $p = 0.953$).

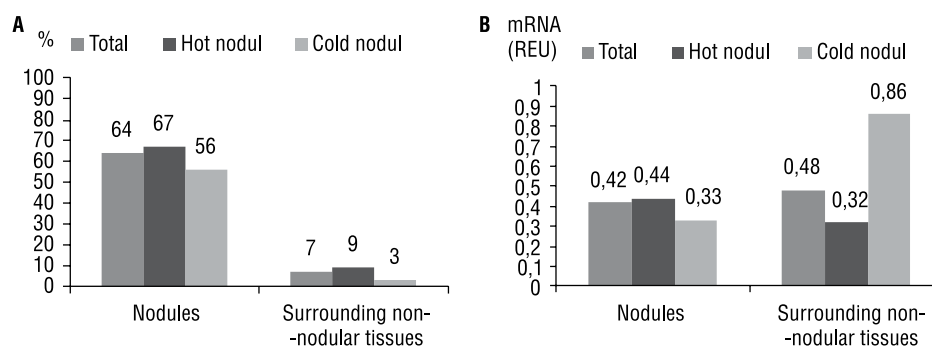


Figure 2A. Percent immunostaining of nodular and surrounding non-nodular thyroid tissues ($p < 0.001$). Pendrin immunohistochemical staining was significantly higher in hot nodules ($p < 0.001$) and in cold thyroid nodules ($p = 0.017$) compared to in adjacent normal tissue. **B.** No statistically significant difference was observed with respect to quantitative mRNA measurements between nodular and normal thyroid tissues ($p = 0.657$). Pendrin mRNA level was significantly lower in hot nodules' corresponding normal parenchyma compared to cold nodules' corresponding normal tissues ($p = 0.031$)

Rycina 2 A. Procentowe barwienie immunohistochemiczne w guzkowej i pozaguzkowej tkance tarczycowej ($p < 0,001$). Barwienie immunohistochemiczne w kierunku pendryny było znacznie bardziej nasilone w guzkach gorących ($p < 0,001$) i zimnych ($p = 0,017$) niż w przylegających tkankach prawidłowych. **B.** Nie stwierdzono statystycznie znacznej różnicy odnośnie do pomiarów ilościowych mRNA pomiędzy tkanką guzkową a prawidłową tkanką pozaguzkową tarczycy ($p = 0,657$). Poziom mRNA pendryny był znacznie niższy w prawidłowym miąższu odpowiadającym guzkom gorącym niż w prawidłowych tkankach odpowiadających guzkom zimnym ($p = 0,031$)

Discussion

The main finding of this study is that no significant difference has been found with respect to percent immunostaining and mRNA level of pendrin between hot and cold nodules. However, immunohistochemical staining of pendrin has been found to be significantly higher in both hot and cold nodular thyroid tissues compared to surrounding normal parenchyma. Cold nodules have had a significantly lower mRNA level of pendrin compared to surrounding non-nodular thyroid parenchyma. Therefore post-transcriptional mechanisms could be associated with the increased pendrin immunostaining in cold thyroid nodules. In addition, no association was evident between TSH and quantitative measurement of pendrin mRNA in nodular thyroid tissue. Therefore different regulatory mechanisms, other than TSH, could be involved in pendrin expression in thyroid nodules and there is no association between the level of pendrin expression and function of the nodule.

Studies involving pendrin expression pattern in normal and nodular or differentiated cancer tissues of thyroid showed different results with respect to pendrin protein and gene expression level. It has been reported that pendrin mRNA expression was reduced in thyroid cancer compared to normal thyroid tissue [19]. Mian et al. [20] identified three types of follicular cells in thyroid tissue: NIS-negative/pendrin-negative cells, NIS-positive/pendrin-positive cells, and NIS-negative/pendrin-positive cells. They suggested that the first two types of cells were resting and active cells respectively, but the functional status of the third type of cells was not clear.

A dissociation between pendrin immunohistochemical staining and mRNA expression level has also been previously observed [15]. Bidart et al. [10] indicated that in hyperfunctioning adenomas, pendrin mRNA level did not differ from normal tissue but strong immunohistochemical staining was observed. In hypofunctional adenomas, although mRNA level of pendrin was not different from normal thyroid tissue, pendrin immunostaining was reported to be highly variable. It has been shown that retention of pendrin in the endoplasmic reticulum is a major mechanism for Pendred Syndrome, leading to endoplasmic reticulum retention and defective plasma membrane targeting [15, 17]. Shepshelovich et al. [21] demonstrated that pendrin is a slow-folding protein. When it is overexpressed, it shows a propensity to form aggregates, therefore being unable to reach the apical membrane and function properly. Shepshelovich's observation may indicate that in situations where pendrin expression is increased, slow folding is responsible for dissociation between functional protein and gene expression level. This could be an explanation for the dissociation between immuno-

histochemistry and quantitative mRNA concentrations in some studies.

Russo et al. [22] investigated both pendrin and NIS expression in nodular and normal thyroid tissues of the same patients by Western blot analysis. They found that in cold nodules from patients with MNG and detectable TSH levels, pendrin protein by Western blot was found to be decreased compared to normal tissue. However, pendrin protein levels were slightly increased in hot and cold nodules of toxic MNG.

In our study, although MNG and toxic MNG patients were evaluated together, no significant difference was found between hot and cold nodules with respect to mRNA level and percent immunostaining of pendrin. In surrounding normal thyroid tissue of hot nodules, pendrin mRNA concentrations were decreased compared to surrounding normal thyroid tissue of cold nodules. This observation could be explained by decreased TSH concentrations in our patients with hot nodules, since, in our study, a significant association has been observed between TSH and mRNA level of pendrin only in non-nodular thyroid tissue.

In the present study, we did not detect a significant association between pendrin mRNA level and TSH concentrations in nodules. Although pendrin expression is greatly influenced by TSH, some *in vitro* studies have indicated that TSH could not have a role in pendrin expression [6, 11]. Bruno et al. [23] also indicated that although reduction of TSH stimulation caused decreases in NIS, apical iodide transporter gene expression in normal thyroid tissues by RT-PCR, no significant effect was observed on pendrin. Both in hot and cold nodules, different mechanisms other than TSH could be responsible for increased pendrin immunohistochemical staining, although mRNA concentrations were decreased in cold nodules compared to surrounding parenchyma. It should be mentioned that immunohistochemistry could not reflect the quantitative measurements of protein content, therefore our suggestion should be supported by Western blot determination.

Krause et al. [24] showed increased expression of proteins involved in cell proliferation, thyroglobulin processing and hydrogen peroxide detoxifying system in cold nodules compared to surrounding normal thyroid parenchyma. This observation has been explained by a compensatory increase in these proteins in a cold nodule with decreased iodine uptake and decreased expression of NIS. In Krause's study [24], pendrin expression was weak and no difference was observed between cold nodules and surrounding parenchyma. In our study, the observed increase in immunohistochemical staining of pendrin compared to surrounding parenchyma in cold nodules could be explained by a compensatory mechanism for intranodular iodine deficiency.

The limitations of this study are that we could not measure pendrin protein quantitatively in tissues. It is well known that immunostaining is not a surrogate marker for quantitative measurement of protein expression.

Conclusions

Our study demonstrates that there is no significant difference with respect to pendrin mRNA level between hot and cold thyroid nodules. TSH and pendrin mRNA level showed a significant positive association in non-nodular thyroid tissue. Therefore we suggest that expression of pendrin could not be influenced by TSH in thyroid nodules, and that the expression level of pendrin seems not to have an effect on nodule function.

References

- Vanderpump MP. The epidemiology of thyroid disease. *Br Med Bull* 2011; 99: 39–51.
- Park SM, Chatterjee VK. Genetics of congenital hypothyroidism. *J Med Genet* 2005; 42: 379–89.
- Ris-Stalpers C, Bikker H. Genetics and phenomics of hypothyroidism and goiter due to TPO mutations. *Mol Cell Endocrinol* 2010; 322: 38–43.
- Laurberg P, Bulow Pedersen I, Knudsen N et al. Environmental iodine intake affects the type of non-malignant thyroid disease. *Thyroid* 2011; 11: 457–69.
- Kim YH, Pham TD, Zheng W et al. Role of pendrin in iodide balance: going with the flow. *Am J Physiol Renal Physiol* 2009; 297: 1069–1079.
- Pesce L, Bizhanova A, Caraballo JC et al. TSH regulates pendrin membrane abundance and enhances iodide efflux in thyroid cells. *Endocrinology* 2012; 153: 512–521.
- Dossena S, Nofziger C, Tamma G et al. Molecular and functional characterization of human pendrin and its allelic variants. *Cell Physiol Biochem* 2011; 28: 451–466.
- Wolff J. What is the role of pendrin? *Thyroid* 2005; 15: 346–348.
- Dohan O, De la Vieja A, Paroder V et al. The sodium/iodide Symporter (NIS): characterization, regulation, and medical significance. *Endocr Rev* 2003; 24: 48–77.
- Bidart JM, Mian C, Lazar V et al. Expression of pendrin and the pendred syndrome (PDS) gene in human thyroid tissues. *J Clin Endocrinol Metab* 2000; 85: 2028–2033.
- Royaux IE, Suzuki K, Mori A et al. Pendrin the protein encoded by the Pendred syndrome gene (PDS) is an apical porter of iodide in the thyroid and is regulated by thyroglobulin in FTRL-5 cells. *Endocrinology* 2000; 141: 839–845.
- Everett LA, Glaser B, Beck JC et al. Pendred syndrome is caused by mutations in a putative sulphate transporter gene (PDS). *Nat Genet* 1997; 17: 411–422.
- Grimaldi R, Capuano P, Miranda N et al. Pendrin: physiology, molecular biology and clinical importance. *G Ital Nefrol* 2007; 24: 288–294.
- Fugazzola L, Cerutti N, Mannavola D et al. The role of pendrin in iodide regulation. *Exp Clin Endocrinol Diabetes* 2001; 109: 18–22.
- Bizhanova A, Kopp P. Controversies concerning the role of pendrin as an apical iodide transporter in thyroid follicular cells. *Cell Physiol Biochem* 2011; 28: 485–490.
- Yoshida A, Taniguchi S, Hisatome I et al. Pendrin is an iodide-specific apical porter responsible for iodide efflux from thyroid cells. *J Clin Endocrinol Metab* 2002; 87: 3356–3361.
- Rotman-Pikielny P, Hirschberg K, Maruvada P et al. Retention of pendrin in the endoplasmic reticulum is a major mechanism for Pendred syndrome. *Hum Mol Genet* 2002; 11: 2625–2633.
- Bizhanova A, Kopp P. Genetics and phenomics of Pendred syndrome. *Mol Cell Endocrinol* 2010; 322: 83–90.
- Skubis-Zegadlo J, Nikodemaska A, Przytula A et al. Expression of pendrin in benign and malign human thyroid tissues. *Br J Cancer* 2005; 93: 144–151.
- Mian C, Lacroix L, Alzieu L et al. Sodium iodide symporter and pendrin expression in human thyroid tissues. *Thyroid* 2001; 11: 825–830.
- Shepshelovich J, Goldstein-Magal L, Globerson A et al. Protein synthesis inhibitors and the chemical chaperone TMAO reverse endoplasmic reticulum perturbation induced by overexpression of the iodide transporter pendrin. *J Cell Sci* 2005; 118: 1577–1586.
- Russo D, Bulotta S, Bruno R, Arturi F et al. Sodium/iodide symporter (NIS) and pendrin are expressed differently in hot and cold nodules of thyroid toxic multinodular goiter. *Eur J Endocrinol* 2001; 145: 591–597.
- Bruno R, Ferretti E, Tosi E et al. Modulation thyroid-specific gene expression in normal and nodular human thyroid tissues from adults: an in vivo effect of thyrotropin. *J Clin Endocrinol Metab* 2005; 90: 5692–5697.
- Krause K, Karger S, Schierhorn A et al. Proteomic profiling of cold thyroid nodules. *Endocrinology* 2007; 148: 1754–1763.