

DTIC FILE COPY

2

USAFSAM-TP-89-11

CHOROIDAL NEVI IN USAF AVIATORS

AD-A233 042

**Daniel L. Vandivort, Second Lieutenant, USAF
Thomas J. Tredici, M.D.
Robert P. Green, Jr., Colonel, USAF, MC, FS**

December 1990

**DTIC
ELECTE
MAR 18 1991
S B D**

Interim Report for Period June 1988 - June 1989

Approved for public release; distribution is unlimited.

**USAF SCHOOL OF AEROSPACE MEDICINE
Human Systems Division (AFSC)
Brooks Air Force Base, TX 78235-5301**



91 3 12 171

NOTICES

This interim report was submitted by personnel of the Ophthalmology Branch, Clinical Sciences Division, USAF School of Aerospace Medicine, Human Systems Division, AFSC, Brooks Air Force Base, Texas, under job order 7755-24-02.

When Government drawings, specifications, or other data are used for any purpose other than in connection with a definitely Government-related procurement, the United States Government incurs no responsibility or any obligation whatsoever. The fact that the Government may have formulated or in any way supplied the said drawings, specifications, or other data, is not to be regarded by implication, or otherwise in any manner construed, as licensing the holder or any other person or corporation; or as conveying any rights or permission to manufacture, use, or sell any patented invention that may in any way be related thereto.

The Office of Public Affairs has reviewed this report, and it is releasable to the National Technical Information Service, where it will be available to the general public, including foreign nationals.

This report has been reviewed and is approved for publication.



THOMAS J. TREDICI, M.D.
Project Scientist



ROBERT P. GREEN, Jr., Col, USAF, MC, FS
Supervisor



GEORGE E. SCHWENDER, Colonel, USAF, MC, CFS
Commander

REPORT DOCUMENTATION PAGE

Form Approved
OMB No. 0704-0188

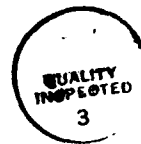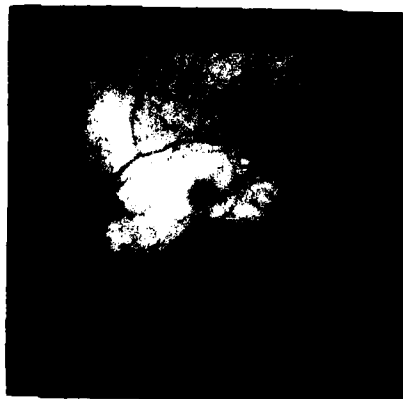Public reporting burden for this collection of information is estimated to average 1 hour per response, including the time for reviewing instructions, searching existing data sources, gathering and maintaining the data needed, and completing and reviewing the collection of information. Send comments regarding this burden estimate or any other aspect of this collection of information, including suggestions for reducing this burden, to Washington Headquarters Services, Directorate for Information Operations and Reports, 1215 Jefferson Davis Highway, Suite 1204, Arlington, VA 22202-4302, and to the Office of Management and Budget, Paperwork Reduction Project (0704-0188), Washington, DC 20503.

1. AGENCY USE ONLY (Leave blank)		2. REPORT DATE Dec 1990	3. REPORT TYPE AND DATES COVERED Interim 88/06-89/06	
4. TITLE AND SUBTITLE Choroidal Nevi in USAF Aviators			5. FUNDING NUMBERS PE 62202F PR 7755 TA 24 WU 02	
6. AUTHOR(S) Vandivort, Daniel L.; Tredici, Thomas J.; Green, Robert P., Jr.				
7. PERFORMING ORGANIZATION NAME(S) AND ADDRESS(ES) USAF School of Aerospace Medicine Human Systems Division (AFSC) Brooks Air Force Base, TX 78235-5301			8. PERFORMING ORGANIZATION REPORT NUMBER USAFSAM-TP-89-11	
9. SPONSORING / MONITORING AGENCY NAME(S) AND ADDRESS(ES) USAF School of Aerospace Medicine Human Systems Division (AFSC) Brooks Air Force Base, TX 78235-5301			10. SPONSORING / MONITORING AGENCY REPORT NUMBER	
11. SUPPLEMENTARY NOTES				
12a. DISTRIBUTION / AVAILABILITY STATEMENT Approved for public release; distribution is unlimited.			12b. DISTRIBUTION CODE	
13. ABSTRACT (Maximum 200 words) A choroidal nevus may be mistaken for a melanoma or it may develop into a malignant melanoma. We reviewed the records of over 5,000 aviators examined over the past 14 years at the USAF School of Aerospace Medicine. One hundred and fourteen aviators were noted to have one or more choroidal nevi (2.2%). These lesions were found not to affect the aviators' visual performance. However, it is recommended that these lesions be followed at regular intervals by an ophthalmologist.				
14. SUBJECT TERMS Nevi; Ocular tumors; Ocular pigmentation			15. NUMBER OF PAGES 9	
			16. PRICE CODE	
17. SECURITY CLASSIFICATION OF REPORT Unclassified	18. SECURITY CLASSIFICATION OF THIS PAGE Unclassified	19. SECURITY CLASSIFICATION OF ABSTRACT Unclassified	20. LIMITATION OF ABSTRACT UL	

CHOROIDAL NEVI IN USAF AVIATORS

The discovery of a choroidal nevus on fundusoscopic examination prompts two very important questions. Is this a small malignant melanoma? Will the pigmented area transform into a malignant melanoma? Treatment of malignant melanoma often entails enucleation, with its attendant visual and cosmetic debilities. Histopathologic study of the choroidal malignant melanoma led Yanoff and Zimmerman (1) to conclude that most, if not all, had arisen from preexisting nevi. This finding gave some foundation to concerns about nevus transformation into malignancy.

To help answer these questions, we reviewed the records of more than 5,000 aviators examined, over the past 14 years, in the Ophthalmology Branch at the United States Air Force School of Aerospace Medicine (USAFSAM). All subjects were USAF aviators being evaluated for medical conditions, ocular or otherwise, which might result in termination of their flying status. They underwent a complete physical and laboratory evaluation, including a full ophthalmologic examination with pupillary dilation and indirect ophthalmoscopy. Drawings or photographs were made of positive findings (Figure 1). Several patients also had Goldmann visual fields.



Accession For	
NTIS GRA&I	<input checked="" type="checkbox"/>
DTIC TAB	<input type="checkbox"/>
Unannounced	<input type="checkbox"/>
Justification	
By _____	
Distribution/	
Availability Codes	
Dist	Avail and/or Special
A-1	

Figure 1. The appearance of a choroidal nevus.

The records of all patients, with the diagnosis of choroidal nevus, who were evaluated during the years of 1975 through 1988 were reviewed. The patient group (N=5194) consisted of 5,114 (98.5%) men and 80 (1.5%) women. Of the patients with choroidal nevi, 112 (98.2%) were male and 2 (1.8%) were female, an equal sex distribution considering our population. All aviators were referred for reasons other than melanocytic tumors.

Of these 5,194 aviators, 114 (2.2%) were found to have one or more choroidal nevi. Age-specific prevalences are listed in Table 1. Five individuals had bilateral nevi, while two had multiple nevi in the same eye. Of the 121 nevi seen, 58 (48%) occurred in the right eye while 63 (52%) occurred in the left eye. The aviators' ages at diagnosis ranged from 20 to 56 years, with the mean being 38 years.

TABLE 1. CHOROIDAL NEVI IN DIFFERENT AGE GROUPS

Age	Number of patients examined	Number of patients with choroidal nevi (%)
20-29	1327	25 (1.9)
30-39	1715	33 (1.9)
40-49	1767	47 (2.7)
50-59	385	9 (2.3)
Total	5194	114 (2.2)

The size of the choroidal nevi ranged from 0.25 disc diameter (DD) to 5.0 DD; the average size was 1.0 DD. None of the lesions were described to be elevated more than 1 diopter. Seven nevi (6.1%) were located partially in macula, although none were situated directly under the fovea. Only 5 (4.4%) nevi were located forward of the equator. The distribution of choroidal nevi in the fundus is depicted in Figure 2. One nevus (0.9%) was described to be amelanotic, while the remainder were the usual green to gray color. Associated ophthalmoscopic findings included drusen overlying three of the nevi. None of the lesions were associated with subretinal fluid or choroidal neovascularization.

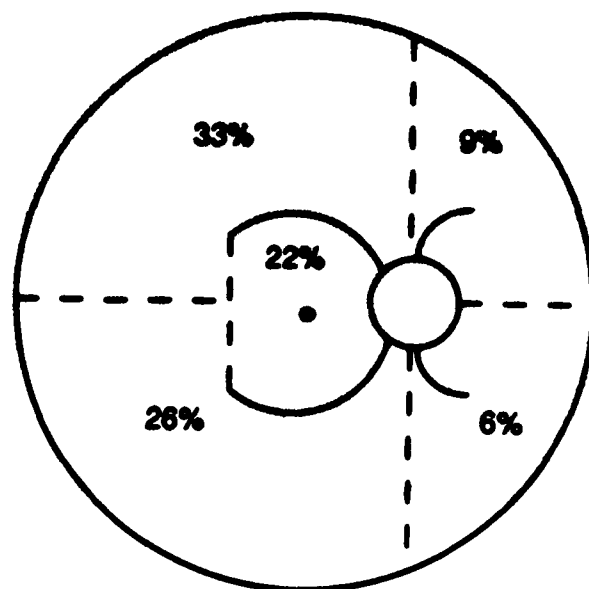


Figure 2. Distribution of choroidal nevus in the fundus.

None of the aviators had any defect in visual acuity, stereopsis, or color vision which could be attributed solely to a nevus. Standard Goldmann perimetry likewise failed to show corresponding field defects in 4 subjects tested. Follow-up examinations were conducted on 23 (20%) of the patients with choroidal nevi over a range of 6 months to 13 years (mean of 4.2 years). During this time, no significant growth or change occurred in any of the lesions.

Our finding of choroidal nevi in 2.2% of aviators is fairly consistent with reported clinical studies (2,3). Of prime importance, however, is determining whether such a lesion is truly a benign choroidal nevus or something much more ominous--a small malignant melanoma. Associated findings such as impairment of visual acuity, corresponding visual field defects, elevation of the lesion, subretinal fluid, or retinal detachment have, in the past, commonly favored the diagnosis of malignant melanoma. However, recent studies have shown that these features may accompany choroidal nevi as well (3,4). The lack of such associated findings in our study may be due in part to our population. These aviators were originally selected for their excellent ocular health.

Tamler and Maumenee (3) suggest that the prevalence of choroidal nevi increases with age, possibly due to the accelerated growth of nevus cell rests during adolescence or early adulthood. While such a trend appears to exist in our study (Table 1), statistical significance was not achieved ($P > 0.05$ by chi-square). The majority of nevi observed were located towards the posterior and temporal aspects of the fundus (Figure 2). Interestingly, a similar distribution is seen with malignant melanomas (1). The fact that none of the choroidal nevi followed in this study underwent growth or malignant degeneration, which would have prompted a re-evaluation at USAFSAM, only emphasizes the rarity of

such an occurrence, estimated to be one malignant melanoma per 5,000 choroidal nevi followed per year (5).

The flight surgeon should be aware that 2% to 3% of aircrew will have one or more choroidal nevi. While choroidal nevi, generally, will not affect vision or visual performance, the lesions should be photographically documented and followed at regular intervals by an ophthalmologist.

REFERENCES

1. Yanoff, M., and Zimmerman, L.E. Histogenesis of malignant melanomas of the uvea. *Cancer* 20:493-507 (1967).
2. Ganley, J.P., and Comstock, G.W. Benign nevi and malignant melanomas of the choroid. *Am J Ophthalmol* 76:19-25 (1973).
3. Tamler, E., and Maumenee, A.E. A clinical study of choroidal nevi. *Arch Ophthalmol* 62:196-202 (1959).
4. Gonder, J.R., Augsburger, J.J., McCarthy, E.P., and Shields, J.A. Visual loss associated with choroidal nevi. *Ophthalmology* 89:961-965 (1982).
5. Gass, J.D.M. Problems in the differential diagnosis of choroidal nevi and malignant melanomas. *Am J Ophthalmol* 83:299-323 (1977).