

# Leydig cell tumors of the testis: A case report

Dr Neha Singh<sup>1</sup>, Dr Jitender Singh Chauhan<sup>2</sup>

<sup>1</sup>Senior Resident, Department of Pathology, BPSGMC, Khanpur Kalan, Sonipat road, Haryana, India

<sup>2</sup>Resident, Department of Surgery, PGIMS, Rohtak, Haryana, India

---

## ABSTRACT

**Leydig cell tumor is a rare form of testicular neoplasm which comprises 1-3% of all testicular tumors and only about 3% of these tumors are bilateral. This tumor is always benign in children and approximately 90% are benign in adults.**

**Keywords: Benign, Leydig cell tumor, Testis, Orchidectomy.**

---

## INTRODUCTION

Leydig cell tumors are rare testicular tumors of the male gonadal stroma and account for 1-3% of all testicular tumors in adults and 4% in prepubertal children.<sup>1,2,3</sup> They are frequently hormonally active, leading to feminizing or virilizing syndromes. In the last few years, the incidence of LCTs is gradually increasing well above the literature predictions. One possible explanation for this phenomenon is the increasing use of better ultrasound technology and the subsequent increased detection of small nodules that have not been found in historical series.<sup>4</sup> We are hereby presenting a case of Leydig cell tumor with markedly elevated testosterone serum level.

## CASE REPORT

A 13-year-old patient presented with a painless swelling in the right testis since 3 years. There was precocious puberty since 3 years. His general physical examination showed acne over face, secondary sexual characters and palpable inguinal lymph nodes. The right testicular examination revealed enlarged testis. The testicular sensation was preserved. Examination of the left testis was normal. His routine investigations such as hemogram, renal function tests, liver function tests and urinalysis were normal. Serum testosterone was >1600 ng/dl (normal 43 ng/dl), serum LDH was 690 U/L, serum alpha feto protein and b-HCG was normal. Chest X-ray was unremarkable. Ultrasound of the right scrotum revealed a testicular mass of size 5X3.3X4.1 cm, enlarged with multiple areas of altered echogenicity with significantly increased vascularity and the left testis was normal. Spiral CT of the abdomen, pelvis and scrotum showed intensely enhancing well defined soft tissue density nodular lesion of size 39X51 mm seen in right hemi-scrotum with prominent right cribriform plexes with normal left testis and multiple enlarged B/L inguinal lymph nodes.

The patient underwent right high inguinal orchidectomy. The cut section of testicular specimen revealed a gritty sensation and a well circumscribed tumor mass measuring 6X6X3.5 cm. No normal testicular tissue was identified (figure1). Spermatic cord was 8.5 cm long. The histopathological examination of the specimen was reported as leydig cell tumor composed of small clusters of round to polygonal cells with central nuclei and prominent nucleoli with eosinophilic cytoplasm (figure2). The mitotic figures were not discernible. This patient was doing well with no evidence of metastasis.

## DISCUSSION

Leydig cell tumor of testis are relatively rare; comprise only 13% of testicular neoplasms. Clinically, they can present as testicular enlargement, gynecomastia, sexual disturbances such as decreased libido, infertility and azoospermia.<sup>5</sup> Semen analysis may show oligozoospermia, cryptozoospermia or azoospermia<sup>6</sup>. In prepubertal cases, presenting manifestations are usually those of isosexual precocity. In 20% of the tumors, they have increased estradiol and testosterone serum level, leading to adult feminization and children masculinization respectively<sup>7,8</sup>. Approximately 10% of Leydig cell tumors are bilateral and 10% are malignant. The mean age for benign and malignant leydig cell tumors is 48 and 62.1 years respectively.<sup>9</sup> The histopathological findings for malignant leydig cell tumors include numerous and atypical mitoses,

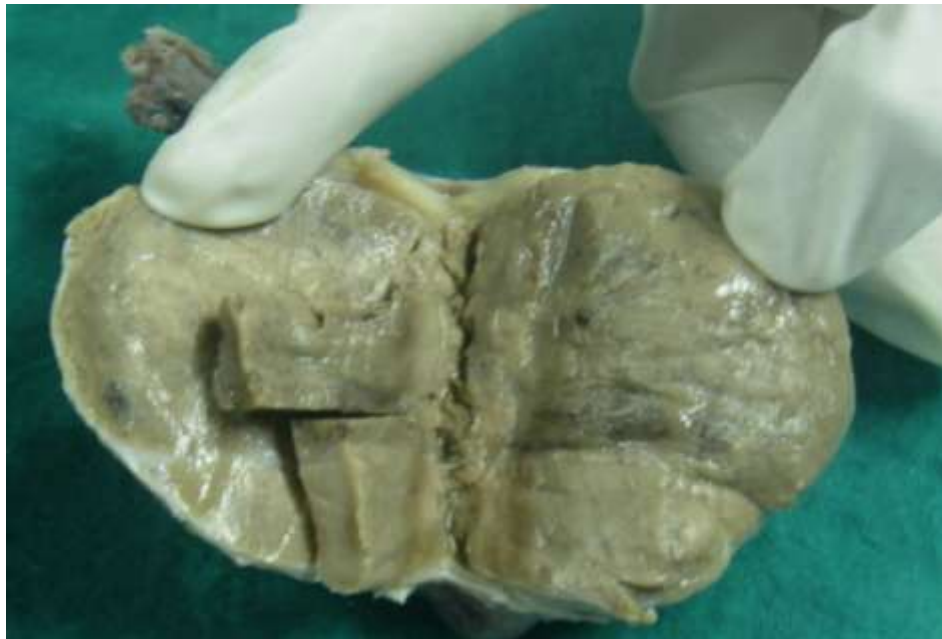marked cellular pleomorphism with atypical nuclei, necrosis, angiolymphatic invasions, tumor size >5 cm, extension of the tumor into the spermatic cord or invasion of the capsule and mitotic figures >3/10 hpf. While differentiating between benign and malignant leydig cell tumors, the presence of metastasis is the most accepted criterion for malignancy. Metastases have been reported as long as 8 and 17 years later.<sup>10,11,12</sup> Immunohistochemistry for oncogenic markers of Ki - 67, p53 and bcl-2 could be of diagnostic value in the identification of malignant and borderline cases (positive) of Leydig cell tumor.<sup>13</sup> Radical inguinal orchidectomy is the initial treatment of choice. Retroperitoneal lymph node dissection, chemotherapy and radiotherapy (relatively radioresistant) has been recommended in patients whose Leydig cell tumors appear histologically or biochemically malignant. The prognosis for benign Leydig cell tumors is excellent. The average survival time in malignant cases is approximately 3 years after surgery. Clinical and hormonal manifestations subside in 90% of patients following orchidectomy.<sup>1,5,14</sup>

## CONCLUSIONS

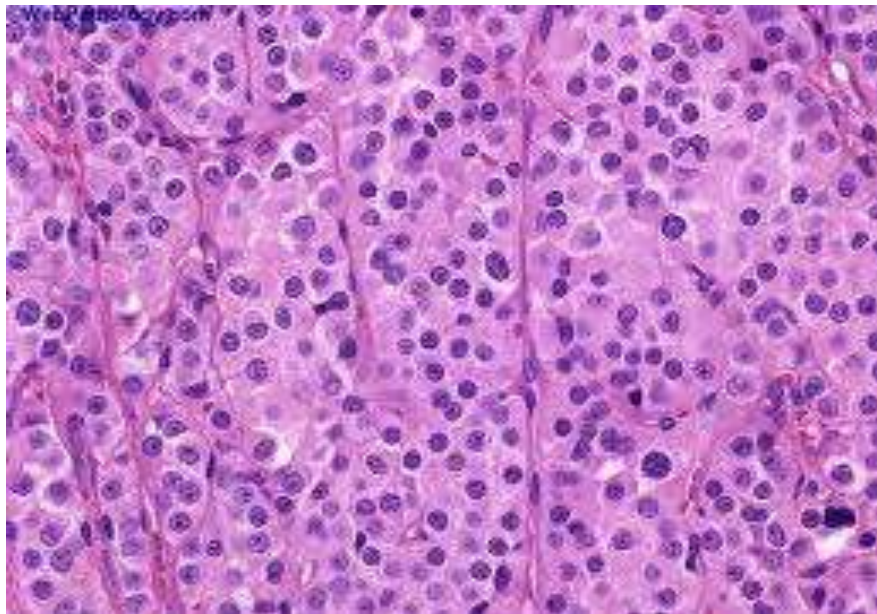
Leydig cell tumors are uncommon neoplasms arising from gonadal stroma. It is critical for physicians to remember and do not overlook the possibility of this rare tumor. The self-examination of testicles appears to be a very important step for the diagnosis of testicular tumors. In Leydig cell tumors orchiectomy is the elected therapeutic decision. In the absence of any sign of malignancy, long-term follow-up is necessary to exclude recurrence or metastasis.

## REFERENCES

- [1] Walsh PC. Campbell's Urology. Saunders; 2007. pp. 925–7.
- [2] Emerson RE, Ulbright TM: Morphological approach to tumours of the testis and paratestis. *J Clin Pathol* 2007, 60:866–880.
- [3] Cheville JC: Classification and pathology of testicular germ cell and sex cord-stromal tumors. *Urol Clin North Am* 1999, 26:595–609.
- [4] Leonhartsberger N, Ramoner R, Aigner F, Stoehr B, Pichler R, Zangerl F, Fritzer A, Steiner H: Increased incidence of Leydig cell tumours of the testis in the era of improved imaging techniques. *BJU Int* 2011, 108:1603–1607.
- [5] Kim I, young RH, Scully RE. Leydig cell tumors of the testis a clinicopathological analysis of 40 cases and review of the literature. *Am J Surg pathol* 1985; 9: 177-192.
- [6] Kondoh N, Koh E, Nakamura M. Bilateral leydig cell tumor and male infertility: case report. *Urol Int* 1991; 46: 104-06.
- [7] Bercovici JP, Nahoul K, Ducasse M, Tater D, Kerlan V, Scholler R. Leydig cell tumor with gynecomastia. *J clin Endocrinol Metab* 1985; 61:957-962.
- [8] Freeman DA. Steroid hormone-producing tumors of the adrenal, ovary and testes. *Endocrinol Metab clin North Am* 1991; 20: 751-766.
- [9] Once de leon Roca J, Algaba Arrea F, Bassas Arnau, Villavicencio Marrich H. Leydig cell tumor of the testis. *Arch ESP Urol* 2002; 53:453-458.
- [10] Gulbahce HE, Lindeland AT, Engel W, Lillemo T. Metastatic leydig cell tumor with sarcomatoid differentiation. *Arch Pathol Lab Med* 1999; 23: 1104-7.
- [11] Cheville JC, Sebo TL Lager DJ, Bostwick DG, Farrow GM. Leydig cell tumor of the testis. A clinico pathologic, DNA content and MIB-1 comparison of non-metastasizing and metastasizing tumors. *Am J Surg Pathol* 1998; 22: 1361-7.
- [12] Powari M, Kakkar N. Singh SK, Rai RS, Jogai S. Malignant leydig cell tumor of the testis. *Urol Int* 2002; 68: 63-5.
- [13] Hekimgil M , Altay B , Yakut BD , Soydan S, Ozyurt C , Killi R. Leydig cell tumor of testis: Comparison of histopathological and immunohistochemical features of three azoospermic cases. *Pathol Int* 2001; 51(10): 792-796.
- [14] Walsh P. CAMPBELL'S Urology. SAUNDERS 2002; 1504-1505, 2905-2910.



**Figure 1:** Gross photograph showed capsulated tumor mass having grey firm cut surface. -No normal testicular tissue is identified.



**Figure 2:** The testicular tumor was composed of nesting pattern. The tumor cells were large, polygonal, with acidophilic to vacuolated cytoplasm and regular round nuclei, some with visible nucleoli. Mitoses were scarce. (H&EX40)