JMG Online First, published on January 7, 2014 as 10.1136/jmedgenet-2013-102030

ORIGINAL ARTICLE

NECAP1 loss of function leads to a severe infantile epileptic encephalopathy

Anas M Alazami,[1] Hadia Hijazi,[1] Amal Y Kentab,[2] Fowzan S Alkuraya[1,3]

[1]Department of Genetics, King Faisal Specialist Hospital and Research Center, Riyadh, Saudi Arabia
[2]Division of Pediatric Neurology, Department of Pediatrics, College of Medicine, King Saud University, Riyadh, Saudi Arabia
[3]Department of Anatomy and Cell Biology, College of Medicine, Alfaisal University, Riyadh, Saudi Arabia

Correspondence to
Dr Fowzan S Alkuraya, Developmental Genetics Unit, King Faisal Specialist Hospital and Research Center, MBC-03 PO Box 3354, Riyadh 11211, Saudi Arabia; falkuraya@kfshrc.edu.sa

Received 2 September 2013
Revised 25 November 2013
Accepted 4 December 2013

ABSTRACT

Background Epileptic encephalopathy is a broad clinical category that is highly heterogeneous genetically.
Objective To describe a multiplex extended consanguineous family that defines a molecularly novel subtype of early infantile epileptic encephalopathy.
Methods Autozygosity mapping and exome sequencing for the identification of the causal mutation. This was followed by expression analysis of the candidate gene.
Results In an extended multigenerational family with six affected individuals, a single novel disease locus was identified on chromosome 12p13.31-p13.2. Within that locus, the only deleterious novel exomic variant was a homozygous truncating mutation in *NECAP1*, encoding a clathrin-accessory protein. The mutation was confirmed to trigger nonsense-mediated decay. Consistent with previous reports, we show that NECAP1 is highly enriched in the central nervous system.
Conclusions NECAP1 is known to regulate clathrin-mediated endocytosis in synapses. The mutation we report here links for the first time this trafficking pathway in early infantile epileptic encephalopathy.

INTRODUCTION

Epileptic encephalopathy is a clinical term used to describe a group of neurological disorders in which intractable epileptic activity is accompanied by an insult to the developing brain.[1] When the onset of epilepsy is in the first few months of life, the term early infantile epileptic encephalopathy (EIEE) is used.[2] Affected children often suffer from profound and global developmental delay, and physical damage to brain cells can manifest with stunted or decelerating brain growth. Distinct clinical subtypes have been recognised for example, Ohtahara syndrome based on characteristic EEG patterns but the clinical relevance of assigning these subtypes is not clear since they do not significantly alter management or prognosis and are not always predictive of the specific underlying aetiology (see below).[3]

EIEE is very heterogeneous in aetiology and an increasing number of patients have been found to harbour single gene mutations (including autosomal recessive and X linked), with a number of recent reports highlighting novel genes with de novo variants.[4–7] While several genes encode channel proteins (SLC25A22, SCN1A, SCN2A, KCNQ2, PLCB1, KCNT1), others code for proteins with a wide range of other functions including transcriptional regulation (ARX), protein modification (CDKL5, PNKP, ST3GAL3), synaptic vesicle fusion (STXBP1), cytoskeleton regulation (SPTAN1), gamma-Aminobutyric acid (GABA) signalling (ARHGEF9), cell-cell adhesion (PCDH19), cell signalling (PLCB1) and regulation of neurite length (TBC1D24).[8] The diversity of biological functions whose perturbation can lead to EIEE highlights the complex nature of the developing brain and its vulnerability. It also suggests that identification of additional EIEE disease genes is likely to add to our understanding of the disease network.

Recently, it has been possible to multiplex a large number of known epilepsy genes in a single assay using next-generation sequencing and this revealed that most patients have no mutation in any of these genes, highlighting the need for research to uncover additional disease genes.[9] In this study, we describe the identification of a novel EIEE candidate gene that we uncovered in the course of studying a multiplex family with this phenotype.

SUBJECTS AND METHODS

Human subjects

Affected members of a consanguineous extended family, along with parents and unaffected siblings when available, were recruited using a King Faisal Specialist Hospital and Research Center IRB-approved protocol (RAC# 2080006) with informed consent. Blood was collected in EDTA tubes from all members in addition to Na-heparin tubes from some of the affected members.

Autozygosity mapping and linkage analysis

DNA was extracted from whole blood using standard protocols. This was followed by genome-wide SNP genotyping and autozygosity mapping as described before.[10] Briefly, the AxiomGWH SNP Chip platform was used following the manufacturer's protocol (Affymetrix, Santa Clara, California, USA). The genotyping files (containing 587 352 SNP calls each) were fed into the AutoSNPa software for determination of the entire set of autozygous intervals per individual (autozygome).[11] An autozygous interval that is exclusively shared between the affected members only was considered a candidate disease locus. Multipoint linkage analysis was performed using the EasyLinkage package assuming a fully penetrant autosomal recessive model with disease allele frequency of 0.0001, with a consanguinity loop for each of the two affected nuclear families.[12]

Exome sequencing

Exome capture was performed using the TruSeq Exome Enrichment kit (Illumina, San Diego, California, USA) following the manufacturer's

To cite: Alazami AM, Hijazi H, Kentab AY, *et al*. *J Med Genet* Published Online First: [*please include* Day Month Year] doi:10.1136/jmedgenet-2013-102030

protocol. Samples were prepared as an Illumina sequencing library, and in the second step, the sequencing libraries were enriched for the desired target using the Illumina Exome Enrichment protocol. The captured libraries were sequenced using Illumina HiSeq 2000 Sequencer. The reads were mapped against University of California, Santa Cruz (UCSC) hg19 (http://genome.ucsc.edu/) by Burrows-Wheeler Aligner (BWA) (http://bio-bwa.sourceforge.net/). The SNPs and indels were detected by SAMTOOLS (http://samtools.sourceforge.net/). Only homozygous novel coding/splicing variants within the candidate disease locus were considered in the variant analysis.

Nonsense-mediated decay analysis

Lymphoblastoid cell lines were established from one patient using standard protocols. RNA extraction was followed by cDNA analysis and PCR using exon-exon spanning primers to avoid genomic DNA amplification (primers and conditions available upon request). QuantiTect SYBR Green mix (Qiagen, Limburg, Netherlands) was used for quantification and the delta Ct method was used to calculate fold difference compared with normal controls (with *GAPDH* for internal normalisation).

Immunohistochemistry

Sections from flash-frozen E14.5 mouse embryos were stained with anti-NECAP1 antibody (Proteintech Group, Chicago, Illinois, USA) and counterstained with 4′,6-diamidino-2-phenylindole (DAPI). To evaluate the specificity of staining a peptide competition assay was performed by preincubating the antibody 1:4 with the immunising antigen, for 1 h at room temperature, prior to staining sections. For each experiment at least two embryos were assessed. Images were captured on a Zeiss Axio Imager.Z2 microscope, then tiled on Photoshop after normalisation of brightness and contrast levels.

RESULTS

Clinical report

A family from southern Saudi Arabia, in which parents are healthy first cousins once removed, presented for counselling because of recurrence of intractable seizures and profound global developmental delay in four children (figure 1). The clinical picture of the four children is strikingly similar. They are all born after term pregnancy complicated by decreased fetal movements. Growth parameters including head circumference are normal at birth. Generalised hypotonia with poor feeding is evident since birth. Severe intractable seizures in the form of fragmented multifocal clonic and tonic seizures started in early infancy then changed in frequency and intensity to more intractable generalised tonic type associated with life-threatening cyanosis. Seizures were resistant to multiple antiepileptic medications including phenobarbitone, clonazepam and valproic acid, but partial response was achieved with a combination of carbamazepine and levetiracetam. EEG showed generalised slowing consistent with diffuse encephalopathy in addition to frequent generalised epileptiform discharges, occasionally with partial component. MRI was performed on two of the four children and in both cases it showed non-specific generalised brain atrophy. All four had profound global developmental delay and persistent severe axial hypotonia (none achieved head control) as well as appendicular hypertonia. The systemic examination including dysmorphology evaluation was negative. The oldest

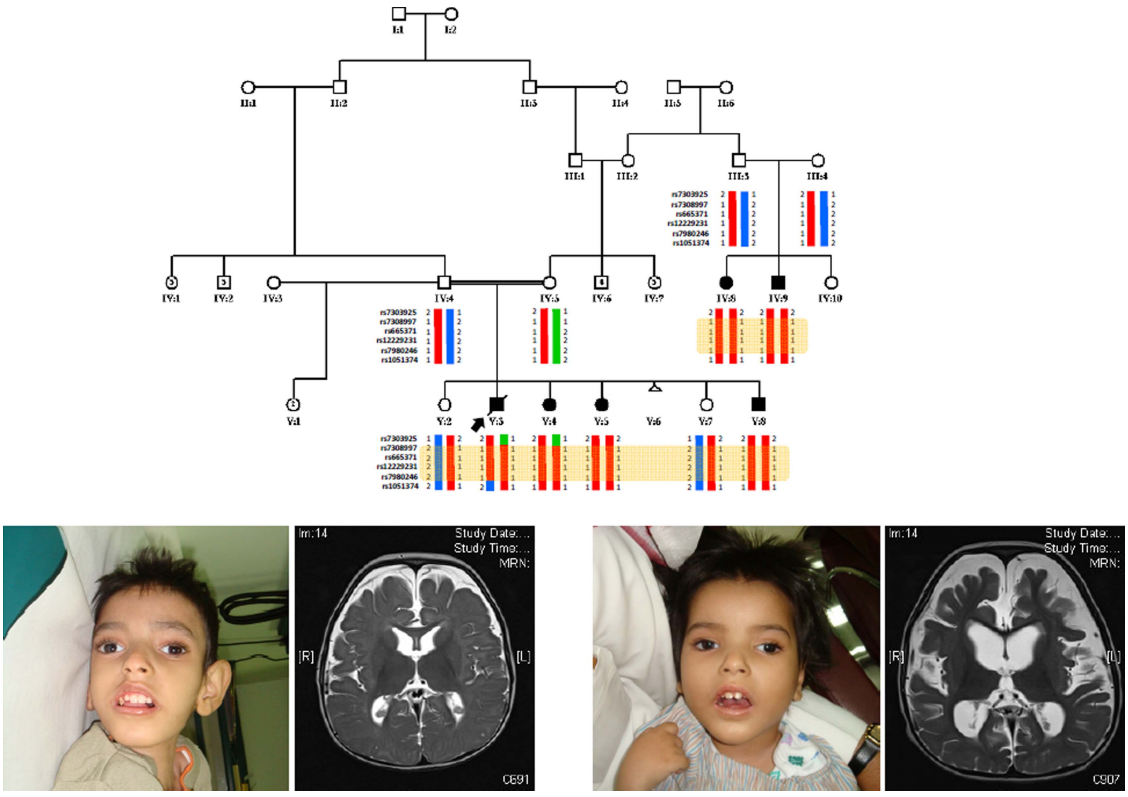

Figure 1 Upper panel: Pedigree of the extended family. The index case is indicated with an arrow, and inferred haplotypes for the region surrounding the *NECAP1* locus are listed beneath the family members who were genotyped for this study. The minimal interval is shaded in the offspring. Lower panel: Facial photographs of two of the six affecteds (V:3 and V:4) and a representative brain MRI cut for each showing non-specific brain atrophy.

child died at the age of 7 years with uncontrolled seizures and lower respiratory infection. A metabolic work up (blood gases, liver function test, serum lactate, serum ammonia, plasma amino acids, acylcarnitines, urine organic acids and biotindase) was within normal limits. Muscle biopsy and sural nerve biopsy were normal. Visual evoked potential, electroretinogram and brain stem auditory potentials were all normal. Neuro-ophthlmological evaluation did not reveal pigmentary retinopathy or cherry red spot. Subsequently we were alerted to the presence of two additional affecteds within the extended pedigree (figure 1), whose parents are not seemingly related but hail from the same locality. Genotype analysis revealed regions of autozygosity in these children, indicating at least distant consanguinity in the parents.

Identification of a novel EIEE locus defined by a homozygous truncating mutation in *NECAP1*

Consistent with the pedigree structure, a single autozygous interval was identified on chromosome 12p13.31-p13.2 that was exclusively shared by the affected children only (figure 1). This locus was further confirmed by linkage analysis, which yielded only one significant peak genome-wide, with Log of odds (LOD) score of 5.0447 (figure 2A). The minimal interval is defined by heterozygosity of the telomeric SNP rs7964540 and the centromeric SNP rs10744003, spanning 4.78 Mb and 147 genes. Analysis of the exome variants after inclusion of all filters (figure 2B) revealed a single novel homozygous mutation in *NECAP1*, predicting premature truncation of the protein near its N-terminus (NM_015509.3; c.142C>T; p.R48*) (figure 2C). The variant was not present in 350 ethnically matched exomes, nor in an additional 184 matched controls (a total of 1068 chromosomes). Consistent with the nature of the mutation, we observed significant deficiency of *NECAP1* mRNA in patient lymphoblasts compared with controls, most likely as a result of nonsense-mediated decay acting upon the aberrant transcripts (figure 2D).

Within the same autozygous interval we also uncovered a novel missense variant in *PRB2* (NM_006248; p.P350A), a secreted salivary protein. This variant did not survive the final filtration step as it was predicted to be benign by SIFT and MutationAssessor. In addition the Exome Variant Server lists one truncating variant for *PRB2* at a fairly high allele frequency of 1.45%, further discounting a role for this gene in EIEE.

NECAP1 is highly expressed in the Central nervous system (CNS)

Previous reports have suggested enrichment of NECAP1 expression in rat brain.[13] Immunohistochemical analysis of head sections from E14.5 mouse embryos showed intense NECAP1 expression spread throughout the entire brain tissue (figure 3A). Similarly intense expression in sections of the spinal cord indicated that NECAP1 is not limited to the brain but has strong domains of expression in the entire CNS (figure 3B). Obliteration of these signals with the use of a peptide competition assay confirmed their specificity.

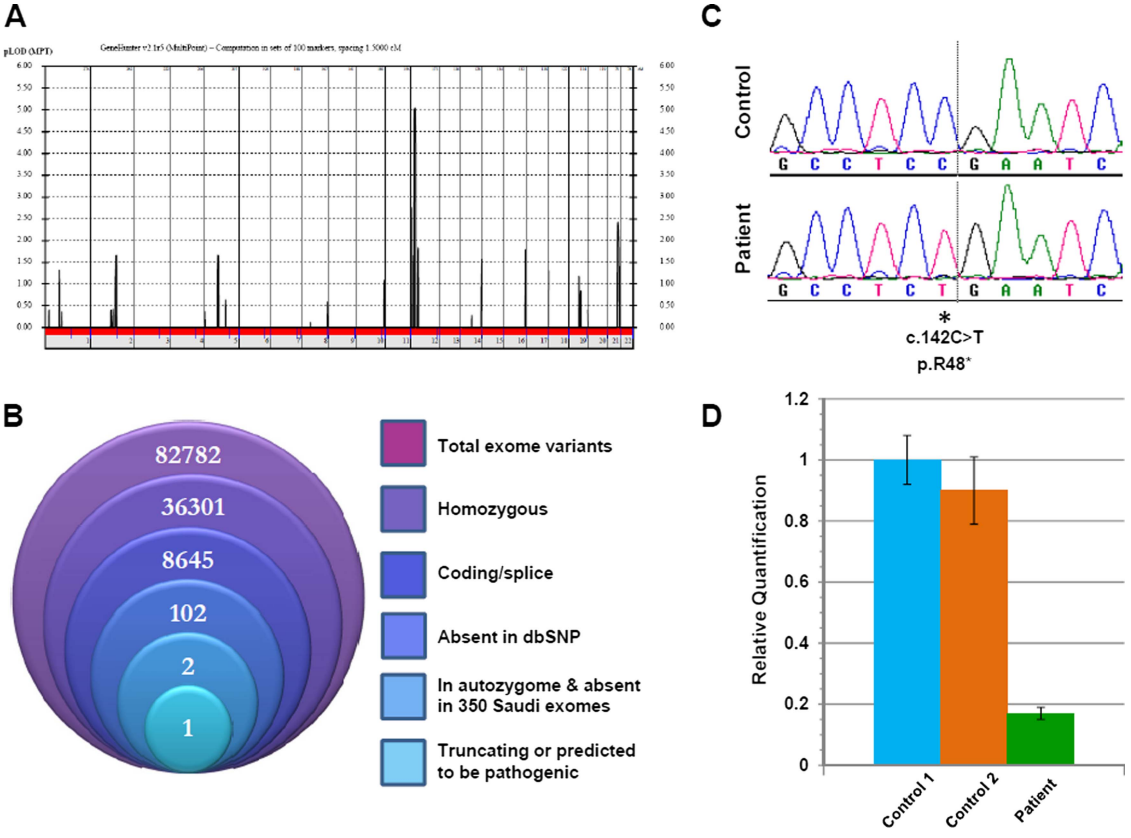

Figure 2 A truncating mutation in *NECAP1* causes severe encephalopathy. (A) Multipoint linkage analysis of the extended family, using the EasyLinkage software package, defines a single peak on chromosome 12 with a LOD score of 5.0447. (B) Graphic representation of exome data following inclusion of various filters. For the final filter SIFT and MutationAssessor were used for predicting pathogenicity. (C) Sequence chromatogram of the *NECAP1* nonsense mutation, with a control sequence for reference. (D) Real-time (RT)-PCR of control and patient lymphoblast cell lines, indicating drastically reduced expression of *NECAP1* in patient cells.

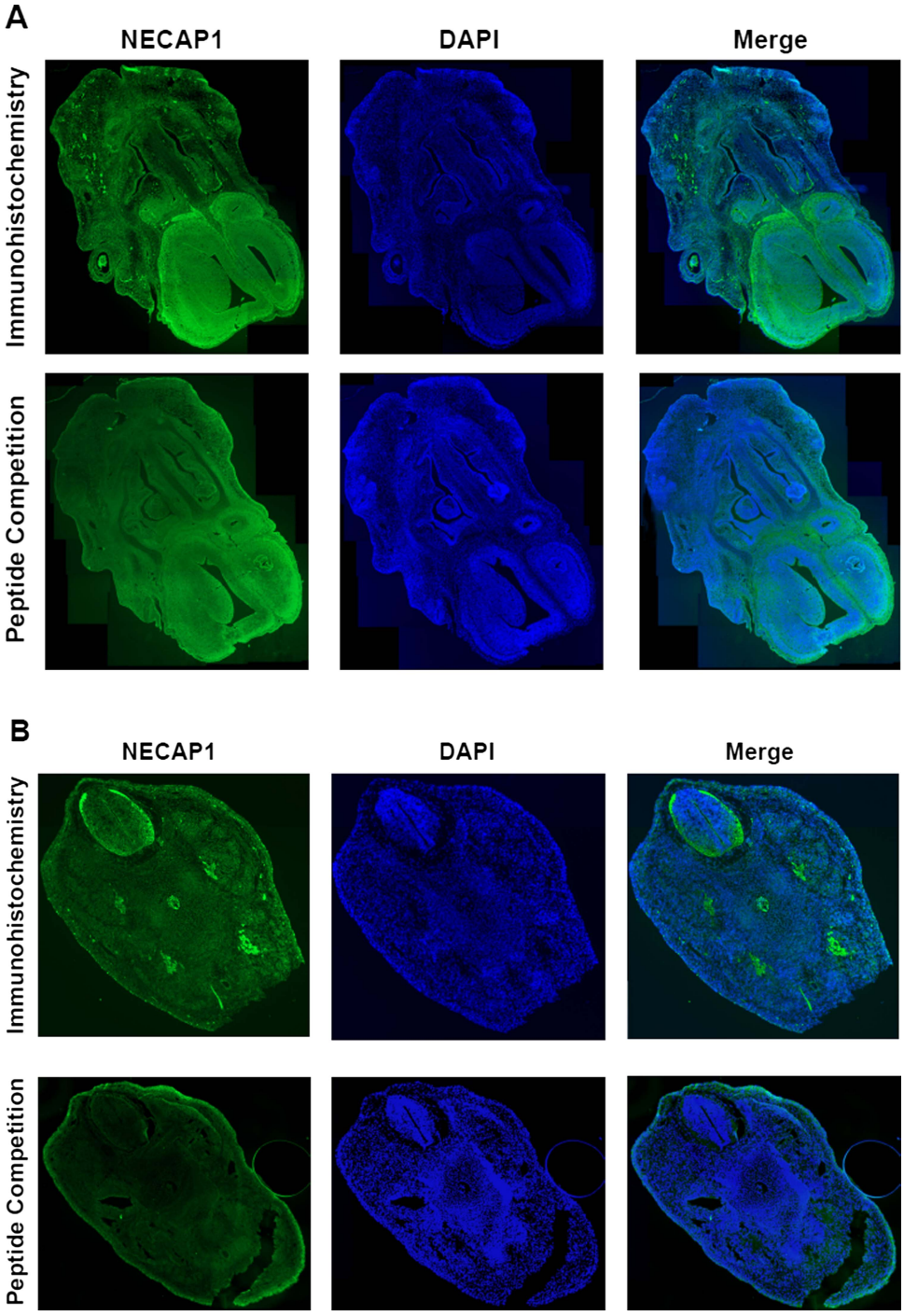

Figure 3 NECAP1 is strongly expressed in the developing mouse brain. Sections of brain (A) and spinal cord (B) from an E14.5 mouse embryo were stained with an anti-NECAP1 antibody and counterstained with DAPI. Peptide competition assay (1:4 antibody to antigen ratio) illustrates the specificity of the staining.

DISCUSSION

Several lines of evidence support the *NECAP1* stopgain variant as the causative mutation in our family. At the genetic level it is the only variant that survived filtration of our exome data (which included assessing all loci with LOD score greater than 2). The variant was not present in 1068 ethnically matched chromosomes. No variant that would be clearly expected to cause nonsense-mediated decay has been deposited for this gene in the Exome Variant Server, and the Database of Genomic Variants reveals no genomic deletion encompassing this gene. At the developmental level the highly enriched expression of NECAP1 in the CNS mirrors our patient phenotype.

Clathrin-mediated endocytosis (CME) is a well-studied trafficking pathway in which clathrin-coated vesicles (CCVs) originate as invaginating pits in plasma membranes that eventually pinch off, and the resulting vesicles carry cargo proteins to their destinations.[14] One important component of CCV is the adaptor protein (AP)-2 that recruits accessory proteins through its cytosol-facing surface. NECAP1 is one such accessory protein that was identified in a proteomic survey of CCV.[13] With the exception of its paralog

NECAP2, the two proteins bear no significant similarity to other protein families. Unlike NECAP2, NECAP1 has a restricted pattern of expression primarily in the brain.

A functional role for NECAP1 in CME comes from several lines of evidence. First, it is enriched in the purified CCV where it was found to bind α-ear component of the heterotetrameric protein AP-2.[15] Second, overexpression of a truncated form of NECAP1 that retains the binding motif of AP-2 in its C-terminus significantly interferes with CME-dependent internalisation of transferrin, presumably through competing with the functional NECAP1 for the same binding site on AP-2.[16] Third, knockdown of NECAP1 also results in significant impairment of CME.[17]

CME plays a critical role at the site of synapsis where it allows recapture of presynaptic plasma membrane that is used in the formation of synaptic vesicles.[18] Therefore, the severe deficiency of NECAP1, in terms of quantitative reduction as well as loss of the C-terminus which is necessary for its participation in CME through the binding with AP-2, is likely to impair synapse-mediated neuronal communication and this may be the basis for the severe EIEE phenotype we observed in the study family. The weak expression of NECAP2 in the brain suggests that any potential functional redundancy between the two proteins (not proven experimentally) may not be sufficient to rescue the neuronal phenotype we observe secondary to NECAP1 deficiency.

Surprisingly, genes encoding components of CME have not been implicated in the pathophysiology of neurological disorders despite the established role of CME synapse physiology and the demonstration of its perturbation in a number of neurological disorders such as Charcot-Marie-Tooth disease, Parkinsonism, Alzheimer's disease and Huntington's disease.[19–21] To the best of our knowledge, the mutation we report in *NECAP1* defines the first human neurological disorder that is caused by a mutation in a core CME component.

Acknowledgements The authors would like to thank the family for their enthusiastic participation. The authors also thank Fatema Alzahrani for technical assistance, and the Sequencing and Genotyping Core Facilities at KFSHRC for their expert help.

Contributors AMA, AK and FSA: collected and analysed data and wrote the manuscript. HH: collected and analysed data.

Funding This work was funded in part by DHFMR Collaborative Research Grant (FSA).

Competing interests None.

Patient consent Obtained.

Ethics approval KFSHRC IRB.

Provenance and peer review Not commissioned; externally peer reviewed.

REFERENCES

1 Dulac O. Epileptic encephalopathy. *Epilepsia* 2001;42(Suppl 3):23–6.
2 Zupanc ML. Clinical evaluation and diagnosis of severe epilepsy syndromes of early childhood. *J Child Neurol* 2009;24(8 Suppl):6S–14S.
3 Ohtahara S, Yamatogi Y. Ohtahara syndrome: with special reference to its developmental aspects for differentiating from early myoclonic encephalopathy. *Epilepsy Res* 2006;70(Suppl 1):S58–67.
4 Carvill GL, Heavin SB, Yendle SC. Targeted resequencing in epileptic encephalopathies identifies de novo mutations in CHD2 and SYNGAP1. *Nat Genet* 2013;45:825–30.
5 Epi KC, Epilepsy Phenome/Genome P, Allen AS. De novo mutations in epileptic encephalopathies. *Nature* 2013;501:217–21.
6 Kodera H, Nakamura K, Osaka H. De novo mutations in SLC35A2 encoding a UDP-galactose transporter cause early-onset epileptic encephalopathy. *Hum Mutat* 2013;34:1708–14.
7 Nakamura K, Kodera H, Akita T. De Novo mutations in GNAO1, encoding a Galphao subunit of heterotrimeric G proteins, cause epileptic encephalopathy. *Am J Hum Genet* 2013;93:496–505.
8 Tavyev Asher YJ, Scaglia F. Molecular bases and clinical spectrum of early infantile epileptic encephalopathies. *Eur J Med Genet* 2012;55:299–306.
9 Lemke JR, Riesch E, Scheurenbrand T. Targeted next generation sequencing as a diagnostic tool in epileptic disorders. *Epilepsia* 2012;53:1387–98.
10 Alkuraya FS. The application of next-generation sequencing in the autozygosity mapping of human recessive diseases. *Hum Genet* 2013;132:1197–211.
11 Carr IM, Flintoff KJ, Taylor GR. Interactive visual analysis of SNP data for rapid autozygosity mapping in consanguineous families. *Hum Mutat* 2006;27:1041–6.
12 Hoffmann K, Lindner TH. easyLINKAGE-Plus--automated linkage analyses using large-scale SNP data. *Bioinformatics* 2005;21:3565–7.
13 Ritter B, Philie J, Girard M. Identification of a family of endocytic proteins that define a new α-adaptin ear-binding motif. *EMBO Reports* 2003;4:1089–93.
14 Ritter B, McPherson PS. *Molecular mechanisms in clathrin-mediated membrane budding*. Springer: Regulatory Mechanisms of Intracellular Membrane Transport, 2004:9–37.
15 McPherson PS, Ritter B. Peptide motifs: building the clathrin machinery. *Mol Neurobiol* 2005;32:73–87.
16 Murshid A, Srivastava A, Kumar R. Characterization of the localization and function of NECAP 1 in neurons. *J Neurochem* 2006;98:1746–62.
17 Ritter B, Denisov AY, Philie J. The NECAP PHear domain increases clathrin accessory protein binding potential. *EMBO J* 2007;26:4066–77.
18 Blondeau F, Ritter B, Allaire PD. Tandem MS analysis of brain clathrin-coated vesicles reveals their critical involvement in synaptic vesicle recycling. *Proc Natl Acad Sci USA* 2004;101:3833–38.
19 Borgonovo JE, Troncoso M, Lucas JJ. Mutant huntingtin affects endocytosis in striatal cells by altering the binding of AP-2 to membranes. *Exp Neurol* 2013;241:75–83.
20 Matta S, Van Kolen K, da Cunha R. LRRK2 controls an EndoA phosphorylation cycle in synaptic endocytosis. *Neuron* 2012;75:1008–21.
21 Yuyama K, Yanagisawa K. Late endocytic dysfunction as a putative cause of amyloid fibril formation in Alzheimer's disease. *J Neurochem* 2009;109:1250–60.

NECAP1 loss of function leads to a severe infantile epileptic encephalopathy

Anas M Alazami, Hadia Hijazi, Amal Y Kentab and Fowzan S Alkuraya

J Med Genet published online January 7, 2014