

Comparison of Magnetic Resonance Imaging and Transesophageal Echocardiography in Detection of Thrombus in the Left Atrial Appendage

Hideo Ohyama, Naohisa Hosomi, Tsutomu Takahashi, Katsufumi Mizushige, Kunihiro Osaka, Masakazu Kohno and James A. Koziol

Stroke. 2003;34:2436-2439; originally published online September 11, 2003;
doi: 10.1161/01.STR.0000090350.73614.0F

Stroke is published by the American Heart Association, 7272 Greenville Avenue, Dallas, TX 75231
Copyright © 2003 American Heart Association, Inc. All rights reserved.
Print ISSN: 0039-2499. Online ISSN: 1524-4628

The online version of this article, along with updated information and services, is located on the World Wide Web at:

<http://stroke.ahajournals.org/content/34/10/2436>

Permissions: Requests for permissions to reproduce figures, tables, or portions of articles originally published in *Stroke* can be obtained via RightsLink, a service of the Copyright Clearance Center, not the Editorial Office. Once the online version of the published article for which permission is being requested is located, click Request Permissions in the middle column of the Web page under Services. Further information about this process is available in the [Permissions and Rights Question and Answer](#) document.

Reprints: Information about reprints can be found online at:
<http://www.lww.com/reprints>

Subscriptions: Information about subscribing to *Stroke* is online at:
<http://stroke.ahajournals.org/subscriptions/>

Comparison of Magnetic Resonance Imaging and Transesophageal Echocardiography in Detection of Thrombus in the Left Atrial Appendage

Hideo Ohyama, MD; Naohisa Hosomi, MD; Tsutomu Takahashi, MD; Katsufumi Mizushige, MD; Kunihiro Osaka, MD; Masakazu Kohno, MD; James A. Koziol, PhD

Background and Purpose—A noninvasive technique of visualizing the left atrial appendage (LAA) and its thrombus in patients with atrial fibrillation would be of great interest. This study examined the utility of MRI for the assessment of thrombus in the LAA.

Methods—We evaluated 50 subjects with nonrheumatic continuous atrial fibrillation and a history of cardioembolic stroke. Each patient received an MRI and a transesophageal echocardiography (TEE) on the same day for thrombus detection in the LAA. Both double- and triple-inversion recovery sequences were used for the MRI evaluations.

Results—In all subjects, the LAA was readily visualized with MRI. High-intensity masses in the LAA were clearly distinguishable from the LAA wall in the triple-inversion recovery sequences. Concordance between detection of high-intensity mass with MRI and thrombus with TEE was high: no mass (MRI), no thrombus (TEE), 31 patients; mass (MRI), thrombus (TEE), 16 patients; and mass (MRI), no thrombus (TEE), 3 patients (overall $\kappa=0.876$, $SE=0.068$).

Conclusions—MRI is a noninvasive and reproducible modality for thrombus detection in the LAA of patients with nonrheumatic continuous atrial fibrillation and previous cardioembolic stroke. (*Stroke*. 2003;34:2436-2439.)

Key Words: atrial fibrillation ■ magnetic resonance imaging ■ stroke, cardioembolic ■ thrombi

Transesophageal echocardiography (TEE) has been well established for the detection of thrombus in the left atrium (LA) or left atrial appendage (LAA). However, because TEE requires esophageal intubation and the presence of ancillary personnel,¹ a less invasive technique of visualizing the LAA and its thrombus would be of great interest. The aim of this study was to evaluate the operating characteristics of MRI, a noninvasive modality, for the assessment of thrombus in the LAA of patients with atrial fibrillation (AF).

Materials and Methods

Subjects

The hospital review board of the Osaka Neurosurgical Hospital approved the study protocol. At the outset of the study, 89 patients with nonrheumatic continuous AF and a history of cardioembolic stroke were being seen at the outpatient clinic at Osaka Neurosurgical Hospital consecutively from October 1, 2000, through January 31, 2002. Cardioembolic stroke was diagnosed as a stroke with the demonstration of a cardiac-transcardiac source of embolus and no evidence of other causes of stroke according to the classification schema of the National Institute of Neurological Disorders and Stroke.² Continuous AF was confirmed with ECG. Exclusion criteria included implanted metallic devices (n=3; artificial pacemaker [3 of 3] or prosthetic valve [0 of 3]), claustrophobia (n=1), unsuccessful TEE probe insertion (n=11), and refusal to grant written informed

consent (n=24). The 50 remaining patients (mean age, 76.0 ± 6.7 years; range, 57 to 90 years; 18 women, 32 men) received MRI examinations followed by TEE studies during the same clinic visit. The duration from the cardioembolic stroke incident was 16.0 ± 16.6 months (range, 0.2 to 59.0 months). All patients had been receiving either ticlopidine (n=19) or warfarin (n=31) to prevent an intracardiac thrombus.

MRI Study

MRI was performed on a 1.5-T whole-body MRI system (23 mT/m; slew rate, $120\text{ mT}\cdot\text{m}^{-1}\cdot\text{ms}^{-1}$; General Electric Medical Systems). A body coil was used for excitation. A 4-element (2 anterior elements, 2 posterior elements) phased-array coil was used for signal reception to obtain an improved signal-to-noise ratio. Patients were positioned supine, and ECG electrodes were attached to trigger data acquisition.

A long-axis image of the heart, which included the LAA, mitral valve, and apex cordis, was scanned on adjusting the angle and location with the fast gradient-echo (segmented k space) sequence. This long-axis image approximately represented the longitudinal 2-chamber view used for LAA evaluation with TEE. The first slice for the double- and triple-inversion recovery (IR) sequence was set on the plane in which the LAA was visualized with the fast gradient-echo sequence. Then, 3 slices were registered on each side of the first slice. The double-IR sequence reduced the blood signal and related artifacts and improved visualization of cardiac anatomy compared with nonprepared images. The delay time was manually adjusted for each examination scanning the LAA to visualize the

Received November 18, 2002; final revision received April 15, 2003; accepted April 24, 2003.

From the Second Department of Internal Medicine, Kagawa Medical University (H.O., N.H., T.T., K.M., M.K.) and Osaka Neurosurgical Hospital (K.O.), Kagawa, Japan, and Department of Molecular and Experimental Medicine, Scripps Research Institute, La Jolla, Calif.

Reprint requests to Naohisa Hosomi, MD, PhD, Second Department of Internal Medicine, Kagawa Medical University, 1750-1 Ikenobe, Miki-Cho, Kagawa 761-0793, Japan. E-mail naohisa@kms.ac.jp

© 2003 American Heart Association, Inc.

Stroke is available at <http://www.strokeaha.org>

DOI: 10.1161/01.STR.0000090350.73614.0F

systolic image. Finally, after the inversion time, a standard spin-echo slice-selective pulse was applied, and the image data were acquired. An additional third IR preparation pulse was applied for fat suppression and modification of image contrast (triple-IR sequence). The inversion time for the third IR pulse was set to 120 ms. The imaging parameters were as follows: repetition time, 2 RR intervals; echo time, 44 ms; field of view, 36 cm; slice thickness, 4 mm; interslice gap, 0; acquisition matrix, 256×128; number of samples averaged, 1; echo train length, 32; data sampling, 62.5 kHz; and delay time, 200 to 400 ms. The LAA was detected in 3 to 4 slices and a thrombus in 1 to 3 slices.

All subjects were instructed to suspend breathing at the end of expiration to minimize respiratory motion (no longer than 15 seconds in each scanning). We experienced 1 instance of an ECG gating problem, resulting in a limited cardiac motion artifact. Seven patients could not hold their breath; we found strong respiratory motion artifacts in these patients.

TEE Study

TEE was performed with a 5-MHz multiplane probe (LOGIC 500 with P509; General Electric). For each patient, all images were recorded as movie images on digital videotape in real time for display and evaluation. The images of the LA and the LAA were evaluated in both the horizontal (0°) plane and the plane obtained by rotation of the imaging sector from 0° to 180° during continuous visualization of the LAA. An LAA thrombus was defined as a well-circumscribed, uniformly consistent, echo-reflective mass of different texture from the LAA wall. Among the 50 patients, no thrombus was detected in the LA, excluding the LAA.

The severity of spontaneous echo contrast (SEC) was graded as poor (absence of detectable echogenicity), mild (swirling pattern and/or echogenicity located in the LAA), or severe (intense echodensity and swirling pattern in the LAA, generally associated with some density in the main cavity).³

Image Analysis

The MRI and TEE images were evaluated by different physicians (N.H. for MRI, H.O. for TEE), each of whom was blinded to the other's findings. The MRI intensities of the LAA lumen, abnormal mass in the LAA, LAA wall, left ventricular lumen, and left ventricular wall were analyzed with an eFilm Workstation (eFilm Medical Inc). Relative intensities were calculated as a percentage of that of the left ventricular wall. LA dimension and LAA area were measured in the longitudinal 2-chamber view at the end-systolic cardiac cycle on the basis of the ECG with TEE.^{4,5} In TEE, the largest sizes in 10 consecutive cardiac cycles per patient were taken as LA dimension and LAA area. In MRI, LA dimension and LAA area were measured as with TEE, in the long-axis image that visualized the LAA with the double-IR sequence. The areas of a high-intensity mass and a thrombus were measured by tracing their surfaces manually⁶ from the images depicting their largest forms.

To estimate the reproducibility of thrombus detection and measurements of intensity, dimension, and area with MRI, the MRI images of 10 patients (5 with a high-intensity mass in the LAA, 5 with no mass) were evaluated by 10 trained cardiologists who were not involved in this study. There was no discrepant judgment of thrombus detection with MRI; intraobserver coefficients of variation of intensity, dimension, and area of MRI were 1.0%, 2.0%, and 1.2%, respectively, and interobserver coefficients of variation of intensity, dimension, and area of MRI were 2.2%, 3.6%, and 2.8%, respectively.

Summary statistics are presented as mean±SD. Comparison of LA dimension and LAA area measurements between TEE and MRI was assessed with concordance correlation coefficients (r_c),⁷ along with jackknife estimates of their respective standard errors. Agreement between detection of high-intensity mass with MRI and thrombus with TEE was assessed with κ statistics. Association between high-intensity MRI masses and SEC grade was assessed with the Cochran-Armitage χ^2 test for trend.

Results

In all 50 subjects, the LAA was visualized clearly with MRI. The r_c between LA dimension measured with MRI (47.1 ± 5.5 mm) and with TEE (48.4 ± 5.0 mm) was 0.74 (SE=0.07; n=50). The r_c between the LAA area measured with MRI (540 ± 145 mm²) and with TEE (535 ± 125 mm²) was 0.80 (SE=0.06).

The double- and triple-IR sequences were taken in all patients. In the subjects with no abnormal mass in LAA (13 women, 18 men), the LAA lumen was observed with MRI as low intensity in both the double-IR sequence ($53.3\pm 29.9\%$) and the triple-IR sequence ($57.2\pm 38.5\%$; Figure 1A and 1B). A high-intensity mass in the LAA was detected with MRI in 19 subjects (5 women, 14 men; Figure 1C and 1D). This high-intensity mass was well-circumscribed and uniformly consistent and had relative isointensity to the left ventricular wall in the double-IR sequence and relative high intensity in the triple-IR sequence with MRI (Figure 1C and 1D). The relative intensity to the left ventricular wall of this high-intensity mass in LAA was higher in the triple-IR sequence ($186.2\pm 44.4\%$) than in the double-IR sequence ($142.9\pm 44.7\%$; $P<0.005$; n=19). The LAA wall was detected as relative high intensity to the left ventricular wall in the double-IR sequence and relative isointensity in the triple-IR sequence (Figure 1C and 1D). The intensity of the LAA wall relative to the left ventricular wall was lower in the triple-IR sequence ($91.1\pm 31.2\%$) than in the double-IR sequence ($170.7\pm 54.9\%$; $P<0.001$; n=50). A high-intensity mass was thus clearly distinguishable from the LAA wall in the triple-IR sequence.

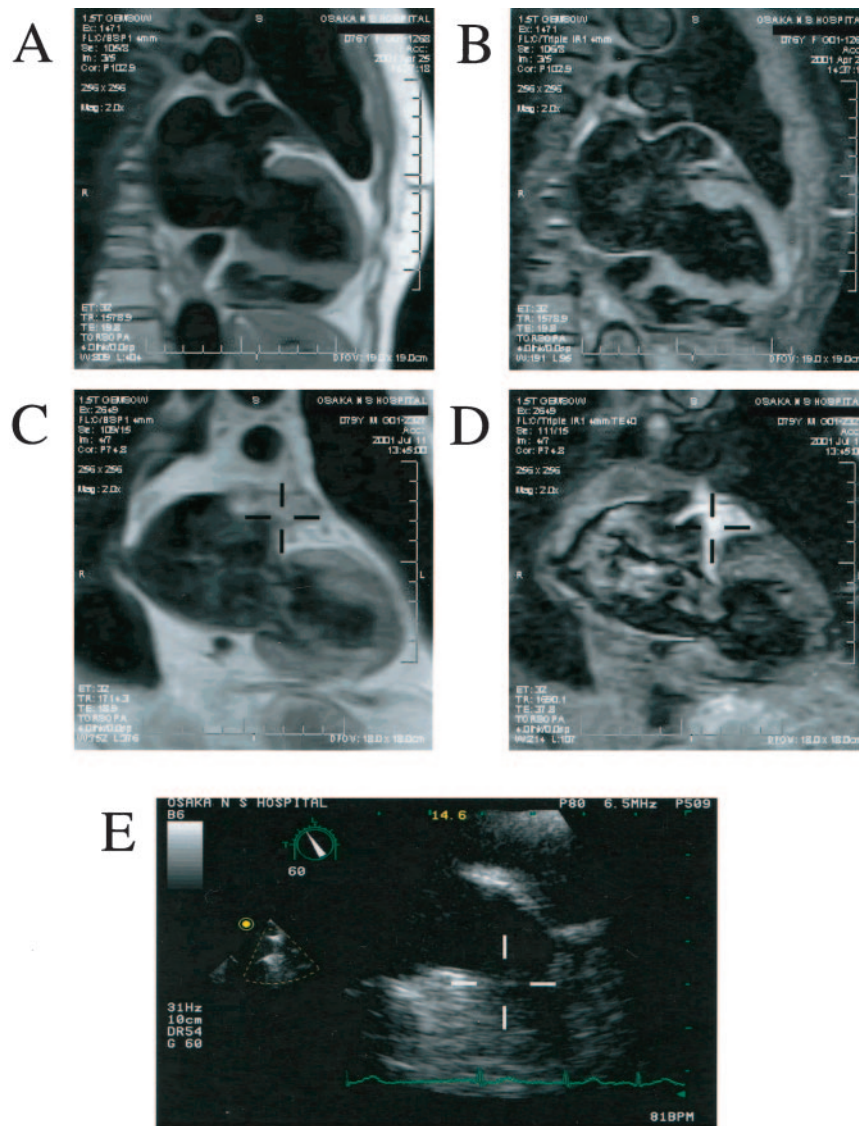
Agreement between detection of high-intensity mass with MRI and thrombus with TEE was high (the Table): overall $\kappa=0.876$ (SE=0.068). On the other hand, sizes of high-intensity masses in MRI (71.1 ± 16.3 mm²) were consistently greater than corresponding thrombus sizes in TEE (58.3 ± 14.6 mm²); a 95% confidence interval for the difference is 9.2 to 16.4 mm², with sizes being $\approx 23\%$ larger with MRI than with TEE.

High-intensity masses were more likely to be found in patients with severe SEC grades (the Table; Cochran-Armitage χ^2 test for trend, $\chi^2_1=18.9$; $P<0.0001$). Similarly, intensities of LAA lumen increased with increasing SEC grade (the Table). Of the 3 patients with a high-intensity mass on MRI but without a thrombus echo on TEE, SEC was categorized as severe in 2 and mild in the third.

Discussion

We have shown that MRI can visualize the LAA and its thrombus in patients with nonrheumatic continuous AF and previous cardioembolic stroke. A high-intensity mass, which may be a thrombus, and the LA wall had a relative intensity similar to the left ventricular wall in the double-IR sequence with MRI. In the triple-IR sequence, the relative intensity of thrombus had increased compared with the double-IR sequence; conversely, the relative intensity of the LA wall had decreased. Therefore, a thrombus is easily distinguishable from the LAA wall with MRI.

In subjects with severe SEC, the LAA lumen had relatively high intensity (the Table). When there was a thrombus in SEC, a high-intensity mass came up in SEC with much higher intensity in the triple-IR sequence image. The relative inten-



In subjects with no abnormal mass in the LAA, the LAA in MRI was clear and had low intensity in both the double-IR (A) and triple-IR (B) sequences. High-intensity mass in the LAA was detected as high intensity in both the double-IR (C) and triple-IR (D) sequences. Bars showed a high-intensity mass in the LAA. Thrombus was detected with TEE (E) in the same region in the LAA where a high-intensity mass was detected with MRI (C, D). Bars show a thrombus in the LAA.

sity of thrombus was significantly higher than the relative intensity of SEC in the triple-IR sequence. Hence, we could differentiate thrombus from SEC.

MRI is a noninvasive and reproducible modality for thrombus detection. We experienced unsuccessful TEE probe insertion in 11 patients in this study. With regard to accuracy, MRI and TEE provided equivalent LA dimension and LAA area measurements in our cohort. On the other hand, high-intensity masses in MRI

were consistently $\approx 20\%$ larger than thrombus sizes on TEE. In addition, MRI may be more sensitive than TEE; high-intensity masses were detected in 3 patients with no corresponding thrombus in TEE. We have also reported the deletion of LAA thrombus detected with MRI after warfarin treatment in the preliminary case report.⁸ However, MRI cannot altogether replace TEE; patients who have implanted metallic devices (eg, artificial pacemaker or prosthetic valve) or claustrophobia are

MRI, TEE, and SEC Profiles

	TEE		SEC		
	No Thrombus	Thrombus	Poor	Mild	Severe
MRI finding					
No abnormal mass	31	0	18	8	5
High-intensity mass	3	16	1	4	14
LAA lumen intensity, %					
Double IR	56.3 \pm 32.7	106.1 \pm 37.5*	39.1 \pm 17.5	67.7 \pm 24.0†	108.2 \pm 38.0†
Triple IR	60.9 \pm 40.4	127.0 \pm 41.5*	36.5 \pm 23.4	79.8 \pm 32.1†	128.9 \pm 37.3†

* $P < 0.001$ vs subjects with no thrombus; † $P < 0.001$ vs subjects with poor SEC.

not suitable for MRI evaluation. We have experienced patients who had implanted metallic devices (n=3; artificial pacemaker [3 of 3], prosthetic valve [0 of 3]) or claustrophobia (n=1) in this study. We could not evaluate a mobility of thrombus and blood flow velocity with MRI. Additionally, the utility of MRI in patients with small thrombi or small LAA is unknown. Two subjects who showed a high-intensity mass in the LAA with MRI but no thrombus echo with TEE had strong respiratory motion artifacts, which could confound MRI findings. Because MRI is an evolving technology, an increase in magnet strength would reduce acquisition time of scans, which in turn might ameliorate potential motion artifacts. With improving cine MRI, we may be able to detect the mobility of LAA thrombus in the near future. MRI has several advantages over the methods or imaging modalities currently available for an assessment of cardiovascular disease.

At our institution, the cost of cardiac MRI is 70% greater than TEE, precluding its routine use for thrombus detection. Rather, MRI is used primarily with patients unsuitable for TEE. We are currently evaluating the utility of MRI in patients with small thrombi or small LAA.

Acknowledgments

This study was supported by a research grant from the Takeda Science Foundation.

We would like to show our appreciation to Yasuaki Kamada and Yuko Takahashi in Osaka Neurosurgical Hospital for their technical support on the MRI setting.

References

1. Daniel WG, Erbel R, Kasper W, Visser CA, Engberding R, Sutherland GR, Grube E, Hanrath P, Maisch B, Dennig K. Safety of transesophageal echocardiography: a multicenter survey of 10,419 examinations. *Circulation*. 1991;83:817–821.
2. Special report from the National Institute of Neurological Disorders and Stroke: classification of cerebrovascular diseases, III. *Stroke*. 1990;21:637–676.
3. Fatkin D, Kelly RP, Feneley MP. Relations between left atrial appendage blood flow velocity, spontaneous echocardiographic contrast and thromboembolic risk in vivo. *J Am Coll Cardiol*. 1994;23:961–969.
4. Block M, Hourigan L, Bellows WH, Reeves J 3rd, Romson JL, Tran M, Pastor D, Schiller NB, Leung JM. Comparison of left atrial dimensions by transesophageal and transthoracic echocardiography. *J Am Soc Echocardiogr*. 2002;15:143–149.
5. Pollick C, Taylor D. Assessment of left atrial appendage function by transesophageal echocardiography: implications for the development of thrombus. *Circulation*. 1991;84:223–231.
6. Bashir M, Asher CR, Garcia MJ, Abdalla I, Jasper SE, Murray RD, Grimm RA, Thomas JD, Klein AL. Right atrial spontaneous echo contrast and thrombi in atrial fibrillation: a transesophageal echocardiography study. *J Am Soc Echocardiogr*. 2001;14:122–127.
7. Lin LI. A concordance correlation coefficient to evaluate reproducibility. *Biometrics*. 1989;45:255–268.
8. Ohyama H, Mizushige K, Hosomi N. Magnetic resonance imaging of left atrial thrombus. *Heart*. 2002;88:233.