

ORIGINAL RESEARCH

Transarterial embolization of intractable nasal and oropharyngeal hemorrhage using liquid embolic agents

Seth B Hayes,¹ Jeremiah N Johnson,¹ Zachary Most,¹ Mohamed Samy Elhammady,¹ Dileep Yavagal,^{1,2} Mohammad Ali Aziz-Sultan^{1,3}

¹Department of Neurosurgery, University of Miami, Miller School of Medicine, Miami, Florida, USA

²Department of Neurology, University of Miami, Miller School of Medicine, Miami, Florida, USA

³Department of Neurosurgery, Brigham and Women's Hospital, Boston, Massachusetts, USA

Correspondence to

Dr Mohammad Ali Aziz-Sultan, Department of Neurosurgery, Brigham and Women's Hospital, 75 Francis Street, PBB-311, Boston, MA 02115, USA; sultan@partners.org

Received 22 March 2014

Revised 28 April 2014

Accepted 2 May 2014

ABSTRACT

Introduction Intractable hemorrhage of the nasal or oropharyngeal cavities can be life threatening, and endovascular embolization is one of the few effective treatments for severe recurrent bleeds. Traditionally, embolic particles have been used for transarterial embolization.

Objective To investigate the safety and efficacy of a less commonly performed treatment—namely, feeding artery occlusion with liquid embolic agents.

Methods We retrospectively reviewed our neurointerventional database for patients who had undergone transarterial embolization for intractable nasal and oropharyngeal hemorrhage with Onyx, N-butyl-2 cyanoacrylate (n-BCA) glue, or both, at our institution over a 5-year period from 2008 to 2013.

Results Forty-six patients who underwent a total of 51 procedures met the inclusion criteria. Causes of hemorrhage included neoplasm n=35 (68.6%), trauma n=12 (23.5%), and idiopathic n=4 (7.9%). The bleeding was oropharyngeal in 66.7%, nasal in 29.4%, and 3.9% originated from both sites. Embolic agents used were n-BCA in 26 cases (51.0%), Onyx in 22 cases (43.1%), and both agents in three cases (5.9%). Mean total procedural time was 93.1 min (range 34–323 min), and mean fluoroscopy time was 39.1 min (10–121 min). Mean follow-up time was 7.4 months (0.25–36 months). Five of the 46 patients (10.9%) required re-embolization and one (2.0%) rebled during the same hospital stay. One periprocedural cardiovascular adverse event occurred that was unrelated to the embolic agent used, but no other complications were seen.

Conclusions Transarterial embolization with n-BCA or Onyx is a safe and effective treatment for patients with intractable nasal and oropharyngeal hemorrhage. Further prospective studies are warranted to confirm these findings.

INTRODUCTION

Transarterial embolization (TAE) has proved to be a safe and effective treatment for a variety of head and neck pathologies, including preoperative tumor embolization.¹ Epistaxis, maxillofacial trauma, and intractable tumor bleeding are acute conditions that often require transarterial endovascular embolization when conservative management and superficial treatments fail to provide reliable hemostasis.¹

The two main categories of modern transarterial embolic agents used in this setting are particle embolic agents and liquid embolic agents. Particles are the

most commonly used class of embolic agents for the treatment of intractable nasal and oropharyngeal bleeding.² Liquid embolic agents have been used off-label to devascularize central nervous system lesions and head and neck tumors safely and effectively, but little is known about their use for the treatment of intractable nasal and oropharyngeal hemorrhage.^{3–6} We describe our institutional experience using N-butyl-2 cyanoacrylate (n-BCA) and Onyx to treat intractable bleeding of these cavities and compare our outcomes with those reported in the literature.

METHODS

A retrospective review was performed of consecutive patients undergoing TAE with liquid embolic agents for intractable nasal or oropharyngeal hemorrhage between July 2007 and May 2013. This review was approved by our local institutional review board (protocol No 20120857). During the study period, 48 patients underwent intra-arterial treatment for intractable nasal or oropharyngeal hemorrhage, of whom 46 underwent treatment solely with liquid embolic agents, thereby meeting inclusion criteria. The other two patients did not meet the inclusion criteria: one was excluded owing to inadequate procedural documentation and one because both liquid and particle embolic agents were used, thus clouding the evaluation of efficacy/complications of the agents used.

Patient characteristics were recorded, including age, sex, and use of antiplatelet agents or anticoagulants or the presence of a coagulopathy at presentation. Hemorrhages were categorized as neoplastic, traumatic, or idiopathic. In this series, indications for treatment included acute life-threatening hemorrhage or intractable bleeding, resulting in symptomatic anemia. For all patients conservative/topical hemostasis maneuvers had failed or they had life-threatening hemorrhage. The location of bleeding was categorized as either nasal or oropharyngeal. The two liquid embolic agents used were n-BCA (Trufill, Cordis Miami Lakes, Florida, USA) and Onyx (ethylene vinyl alcohol copolymer in dimethylsulfoxide solution; ev3 Microtherapeutics Inc, Irvine, California, USA). The n-BCA–ethiodol mixture ranged from 1:1 to 1:4, and in all cases using Onyx, an Onyx 18 (6% ethylene vinyl alcohol) formulation was used.

Our objective was to determine the efficacy of embolization with liquid embolic agents as defined

To cite: Hayes SB, Johnson JN, Most Z, et al. *J NeuroInterv Surg* Published Online First: [please include Day Month Year] doi:10.1136/neurintsurg-2014-011101

by the rebleed rate, and to evaluate the safety profile of these agents in this setting by documenting adverse events. Inpatient data were obtained from our institution's electronic medical record. After the procedure, all patients had neurological examinations performed by the neurointerventional service, which during the study period comprised neurosurgery and neurology trained fellows and attendings. The otolaryngology team also followed up each patient during hospitalization. Outpatient follow-up information was collected from our institution's outpatient clinic medical records. The clinic notes from each outpatient visit after embolization were carefully reviewed for evidence of rebleeds or complications. After hospital discharge, the majority of patients were assessed and followed up as outpatients by the otolaryngology department; however, seven patients were followed up in internal medicine or neurointerventional clinics only.

RESULTS

Our cohort included 46 patients who underwent a total of 51 procedures (table 1) carried out in 44 male and seven female subjects. The mean age was 52.0 years (6–80 years). Six patients (11.8%) were taking antiplatelets, anticoagulants, or presented with a coagulopathy at the time of hemorrhage. Causes of hemorrhage included 35 neoplasms (68.6%), 12 traumatic (23.5%), and four idiopathic (7.9%). Bleeding from the oropharynx comprised 66.7%, 29.4% originated from the nasal passages, and 3.9% of the cases had bleeding from both sites. The mean total procedural time was 93.1 min (34–323 min), and mean fluoroscopy time was 39.1 min (10–121 min). n-BCA, Onyx, or a combination of both agents was used in 26 (51.0%), 22 (43.1%), and three (5.9%) of cases, respectively. Forty-one patients (80.4%) had a unilateral embolization, and the mean number of vascular pedicles embolized for each patient was 1.5. Five patients (10.9%) had rebleeds requiring re-embolization. One patient (2.0%) rebled during the same hospital stay while two patients (3.9%) rebled ≥ 5 months after the initial treatment.

Table 1 Patient characteristics and procedural variables

	Idiopathic	Trauma	Neoplasm	Total
Procedures, N (%)	4 (7.9)	12 (23.5)	35 (68.6)	51
Age (years)	56.5	37.0	57.5	52.0
Sex (M:F)	4:0	10:2	30:5	44:7
Anticoagulation/antiplatelet	2	2	2	6 (11.8)
Bleeding site:				
OP	–	4	30	34 (66.7)
Nasal	4	6	5	15 (29.4)
OP+nasal	–	2	–	2 (3.9)
Pedicles embolized:				
Unilateral	3	12	26	41 (80.4)
Bilateral	1	0	9	10 (19.6)
No. embolized (mean)	1.5	1.3	1.6	1.5
Pseudoaneurysms	1	6	2	9 (17.6)
Embolic agent:				
n-BCA	3	10	13	26 (51.0)
Onyx	1	2	19	22 (43.1)
n-BCA+Onyx	–	–	3	3 (5.9)
Re-embolization	0	0	5	5 (10.9)
Complication	0	0	1	1 (2.0)

Results are shown as number or number (%) unless stated otherwise.
F, Female; M, Male; n-BCA, N-butyl-2 cyanoacrylate; OP, oropharyngeal.

The mean time from embolization to rebleed was 3.2 months (0.1–8 months).

In all patients requiring re-embolization, the etiology of the hemorrhage was an unresectable squamous cell carcinoma of the nasal passages or oropharyngeal cavity, and one of the five patients was coagulopathic (table 2). Onyx was the embolic agent used in three of these patients and n-BCA in the other two. Four additional patients with neoplasm had minor tumor oozing, noted at follow-up visits, but none required any form of treatment. All 16 procedures performed for traumatic or idiopathic bleeding were successful (100%), no patients were re-embolized and one patient had minor postembolization oozing that was controlled topically at the bedside. One patient (2.0%) who was hemodynamically unstable before embolization sustained a cardiac arrest on the angiography table. She was resuscitated and transported back to the intensive care unit. There were no additional periprocedural or postprocedural complications. Of the 46 patients in this series, four died in the hospital owing to systemic disease unrelated to the procedure or recurrent bleeding, two were discharged to a hospice, and 40 were discharged home with 36 (90%) of them having clinical follow-up available for review. The mean length of follow-up was 7.4 months (range 0.25–36 months).

DISCUSSION

Although liquid embolic agents are often used for the treatment of intractable nasal and oropharyngeal hemorrhage at many institutions, there is little reported information about their safety and efficacy in this setting. This series found that liquid embolic agents safety and efficacy similar to that of particle embolic agents^{1 2 7 8} (table 3). In this series of 46 patients, 89.1% were recurrence free, 10.9% underwent a second embolization, and an additional 10.9% were noted to have minor tumor oozing during follow-up visits that did not necessitate further intervention. All five patients requiring re-embolization were patients with a tumor. One cardiovascular adverse event occurred in a critically ill patient that was unrelated to the embolic material used.

Numerous embolic materials have been used for the treatment of intractable hemorrhage, including coils, gelfoam sponges, particle and liquid embolic agents; however, in modern endovascular practice, particle embolic agents and liquid embolic agents are the two most commonly used materials. Particle embolic agents include microspheres, polyvinyl alcohol (PVA), and gelatin sponges, while the liquid embolic agents used are n-BCA and Onyx. In the literature, PVA (Boston Scientific/Target Therapeutics, Cork Ltd, Cork, Ireland; Cordis J&J Endovascular, Miami, Florida, USA) is by far the most commonly used embolic agent for the treatment of intractable nasal and oropharyngeal hemorrhage.²

The properties of particulate embolic agents differ from those of liquid embolic agents. Particles vary in size, with smaller particles having a greater likelihood of deep penetration but a higher risk of inadvertent embolization of normal vessels via anastomotic branches.⁹ While larger particles decrease the risk of inadvertent embolization, they do not allow deep tissue penetration and bleeding can persist from collateral channels distal to the occlusion. Disadvantages of particle embolic agents include the inability to control their distal spread, lack of visualization of their dispersal, and ability to be resorbed by the body over time, even potentially resulting in delayed vessel recanalization.^{10 11}

Onyx and n-BCA are liquid embolic agents that solidify upon contact with an ionic solution (blood), leading to vessel

Table 2 Patients requiring re-embolization

	Patient 1	Patient 2	Patient 3	Patient 4	Patient 5
Etiology	Tumor* (tongue SCC)	Tumor* (tongue SCC)	Tumor* (tongue SCC)	Tumor* (laryngeal SCC)	Tumor* (nasal SCC)
Antiplatelet/anticoagulation	No	No	No	Yes	No
Bleeding site	OP	OP	OP	OP	NP
Artery embolized (initial procedure)	L Lingual, L Facial	R Lingual	R Lingual	R APA branch R Superior thyroid	L Facial
Artery embolized (repeat procedure)	R Lingual R APA	L Lingual	R Facial Branch	R APA branch	L and R Imax
Embolic agent	Onyx	Onyx	n-BCA	Onyx	n-BCA
Time to rebleed (months)	1.5	0.07	8	5	1.5

*Unresectable.

APA, ascending pharyngeal artery; Imax, internal maxillary artery; L, left; n-BCA, N-butyl-2 cyanoacrylate; NP, nasopharyngeal; OP, oropharyngeal; R, right; SCC, squamous cell carcinoma.

obstruction.¹² Glue polymerizes quickly and depending on the ratio of n-BCA glue to ethiodol oil, can be used to create a proximal vessel occlusion or penetrate distally.¹¹ Compared with n-BCA, Onyx is typically used to penetrate deep into the vascular pedicle, obliterating distal anastomotic channels and filling deep tumor feeders, but it takes longer to deliver. The vessel penetration of particles is determined by the manufactured particle size (40–1300 µm); however, the penetration ability of liquid embolic material is less well understood. A laboratory study by Natarajan *et al*¹³ found that liquid embolic agents occluded arteriovenous malformation arterial branches as small as 20 and 5 µm after n-BCA and Onyx embolization, respectively. Thus, like small particles, liquid embolic agents have the ability to penetrate into small distal branches, but have the advantage of being radio-opaque allowing the operator to guide vessel penetration and avoid potentially dangerous collaterals.

In this series, neoplasms accounted for the majority of cases (69%). In advanced head and neck cancer, intractable bleeding can occur in up to 10% of patients.⁷ Conservative treatment often fails and surgical vessel ligation can be dangerous and difficult, particularly in patients with large recurrent tumors or in

those who have received adjuvant radiation treatments.⁸ Major complications from non-liquid embolic interventional series for bleeding neoplasms range from 0% to 10%.^{14–16} The rebleeding rate in these series ranged from 0% to 33%.^{1 8} In 2010, Chen *et al* reported their series of 25 patients with head and neck cancer undergoing non-liquid agent TAE for intractable hemorrhage. Twenty per cent rebled within 2 months and there were no complications in this series.⁷ Little information is available about the use of liquid embolic agents for palliative embolization of bleeding neoplasms. Several large nasal and oropharyngeal hemorrhage series, using a mixture of embolic agents, have included patients treated with liquid embolic agents, but the outcomes and complications were not analyzed separately (table 3). In our series, all five patients (10.9%) who had rebleeds requiring a second endovascular treatment harbored unresectable carcinomas, and the mean time to re-treatment was 3.2 months (0.07–8 months) (table 2).

Epistaxis is common in the adult population with 6% of cases requiring evaluation by a physician, accounting for 0.46% of all visits to the emergency department.^{17 18} The vast majority of these hemorrhages originate from Kiesselbach's plexus located

Table 3 Reported use of liquid embolic agents for nasal and oropharyngeal hemorrhage

Study	Patients	Indication	Embolic material	Complications (%)	Rebleed rate (%)
This study	46	Neoplasm (35) Trauma (12) Idiopathic (4)	n-BCA Onyx	2.0	10.9
Sagara <i>et al</i> (2013) ²³	5	Trauma	n-BCA	0	0
Maoriello <i>et al</i> (2012) ²⁴	1	Trauma	Onyx	0	0
Thiex <i>et al</i> (2011) ²⁵	7*	Trauma	Onyx	14†	29
Shuster <i>et al</i> (2011) ²⁶	1	Idiopathic	n-BCA	0	0
Chou <i>et al</i> (2007) ²⁷	20‡	Neoplasm	n-BCA	0	32§
Luo <i>et al</i> (2006) ²⁸	17	Neoplasm (14) Trauma (3)	n-BCA	0	18¶
Mahadevia <i>et al</i> (2005) ²⁹	4	Trauma	n-BCA	0	0
Luo <i>et al</i> (2000) ³⁰	7**	Neoplasm (5) Trauma (2)	n-BCA	0	0

*Part of a larger study of 22 patients; the rest did not receive liquid embolic agents.

†One patient had 'significant pain'.

‡Part of a larger study of 63 patients; the rest did not receive liquid embolic agents.

§The study did not directly indicate the rebleed rate. Thirty of 93 procedures were repeated (this number includes non-n-BCA patients, although the authors mention that there were no significant differences based on embolization technique).

¶All bleeds were stopped acutely. Three rebleeds occurred (3, 4, and 8 months later), two of which were bleeding from a different location.

**Part of a larger study of 19 patients; the rest did not receive liquid embolic agents.

n-BCA, N-butyl-2 cyanoacrylate.

in the anterior nasal septum, which is fed by numerous external carotid artery (ECA) branches.¹⁹ Failure of conservative and transnasal management strategies occurs in about 5% of cases, particularly when the source of bleeding is in the posterior nasal cavity. Multiple modern series have established endovascular embolization as an acceptable treatment for intractable epistaxis.^{20–22} In a review of 15 series from 1994 to 2008 totaling 690 patients, using primarily PVA, the bleed control rates ranged between 79% and 96%, there was a 0–24% bleeding recurrence rate, and a 3% major complication rate.² Little has been written on the use of liquid embolic agents for the embolization for intractable epistaxis or traumatic hemorrhage (table 3).^{23–30} In our series, 16 patients underwent embolization for traumatic or idiopathic epistaxis. Of these, one patient experienced minor oozing controlled topically after the procedure, no patients required re-embolization, and no periprocedural complications occurred.

Comparison of our liquid embolic embolization series with the particle embolization literature for intractable epistaxis and tumor hemorrhage, shows that the procedure efficacy and complications are similar. The rebleed rate in our series was 10.9%, which is within the 0–24% range reported for particle embolic materials in the epistaxis literature and the 0–33% rate reported in the intractable tumor hemorrhage literature. In our series, all five patients requiring re-treatment harbored unresectable squamous cell neoplasms, and all had unilateral arterial embolizations. Three of the five patients requiring re-embolization had lingual tumors, and owing to fear of tongue necrosis, only one lingual artery feeder was embolized during the initial embolization procedure. Only one patient required re-embolization during the same hospital stay, two patients were re-treated at 6 weeks, and two were re-treated ≥ 5 months after initial embolization (table 2). All five repeat

embolization procedures were successful; there were no further rebleeds and no complications from re-embolization. In the re-embolization procedures, there was no difficulty in accessing tumor feeders for re-embolization as there was always obvious recruitment or increased tumor blush of bordering ECA branches that were cannulated and occluded. The complication rate in our series was 2.0% and was not related to the embolic materials. This compares favorably with the major complication rates reported as 3% in the epistaxis literature and 0–10% in the tumor literature.

In this study, the choice of liquid embolic agent (n-BCA vs Onyx) was made based on the pathology being treated and its angiographic features. Trufill (n-BCA) glue was used for pathologies where hemostasis was thought to be achievable by occluding a single vessel, such as arterial pseudoaneurysms in cases of trauma, idiopathic nasal hemorrhage, or carcinomatous vessel wall erosion (figure 1D–F). In contrast, Onyx was used when there was a large network of vascular feeders (such as in large tumors), there was no bleeding point identified angiographically, or when bleeding was felt to be diffuse (figure 1A–C). The authors did not use either double-catheter Onyx embolization techniques or the D5W guide catheter flush technique to facilitate the antegrade flow of n-BCA in this series. In the three cases where n-BCA and Onyx were both used, the patients harbored large neoplasms with multiple ECA feeders. In these cases, the dominant feeders were embolized with Onyx with the aim of penetrating and occluding the tumor's vascular network; subsequently, the remaining feeders outside the area of Onyx penetration were occluded with n-BCA rather than Onyx to shorten the procedure time, reduce radiation exposure, and decrease procedural thromboembolic risk.

The liquid embolic series reported here is the largest reported to date for the treatment of intractable nasal and oropharyngeal

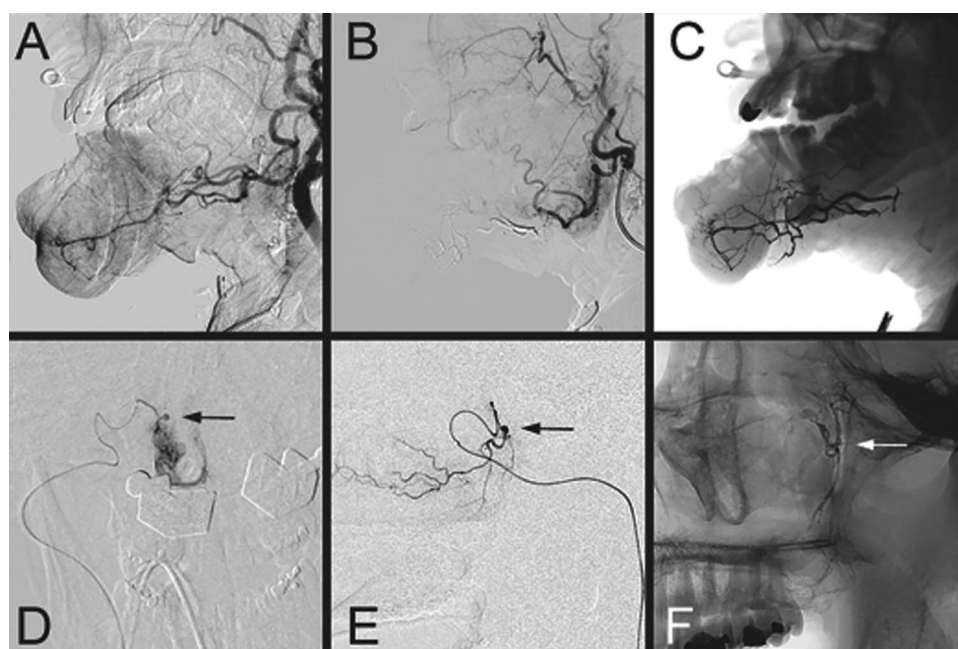


Figure 1 (A–C) A patient with squamous cell carcinoma of the mandible that was bleeding profusely, resulting in symptomatic anemia. (A) Lateral view pre-embolization angiogram showing tumor vascularity. (B) Lateral view postembolization angiogram showing tumor devascularization. (C) Lateral postembolization X-ray picture showing Onyx cast in the facial artery feeders bilaterally. (D–F) A patient with intractable epistaxis 3 days after endoscopic sinus surgery. (D) Anteroposterior microangiogram of the right sphenopalatine artery and traumatic pseudoaneurysm (arrow). (E) Lateral view of the right sphenopalatine artery microangiogram demonstrating the pseudoaneurysm (arrow). (F) Lateral postembolization X-ray picture showing the N-butyl-2 cyanoacrylate cast in the sphenopalatine artery (arrow).

hemorrhage. Confirmatory data are needed, but in this series, liquid embolic agents were safe and effective. Limitations of the study include its single-center retrospective design, the lack of a control group, and the heterogeneity of the pathologies treated. Follow-up was limited by the palliative end-of-life nature of many of the embolizations for nasal and oropharyngeal neoplasms and the varying length of follow-up between patients.

CONCLUSION

TAE with n-BCA or Onyx is a safe and effective treatment for patients with intractable nasal and oropharyngeal hemorrhage. Further studies are warranted to confirm these findings and to determine the optimal embolization strategy for the different causes of nasal and oropharyngeal bleeding.

Contributors All authors contributed to the conception and design, or analysis and interpretation of data. All authors read, provided editorial direction, and approved the final version of the manuscript.

Competing interests MAA-S is a proctor for eV3 and Codman.

Ethics approval Local institutional review board: protocol No 20120857.

Provenance and peer review Not commissioned; externally peer reviewed.

REFERENCES

- Risley J, Mann K, Jones NS. The role of embolisation in ENT: an update. *J Laryngol Otol* 2012;126:228–35.
- Smith TP. Embolization in the external carotid artery. *J Vasc Interv Radiol* 2006;17:1897–912; quiz 913.
- Gobin YP, Murayama Y, Milanese K, et al. Head and neck hypervascular lesions: embolization with ethylene vinyl alcohol copolymer—laboratory evaluation in swine and clinical evaluation in humans. *Radiology* 2001;221:309–17.
- Kim LJ, Albuquerque FC, Aziz-Sultan A, et al. Low morbidity associated with use of n-butyl cyanoacrylate liquid adhesive for preoperative transarterial embolization of central nervous system tumors. *Neurosurgery* 2006;59:98–104; discussion 98–04.
- Gore P, Theodore N, Brasiliense L, et al. The utility of onyx for preoperative embolization of cranial and spinal tumors. *Neurosurgery* 2008;62:1204–11; discussion 11–2.
- Elhammady MS, Wolfe SQ, Ashour R, et al. Safety and efficacy of vascular tumor embolization using Onyx: is angiographic devascularization sufficient? *J Neurosurg* 2010;112:1039–45.
- Chen YF, Lo YC, Lin WC, et al. Transarterial embolization for control of bleeding in patients with head and neck cancer. *Otolaryngol Head Neck Surg* 2010;142:90–4.
- Kakizawa H, Toyota N, Naito A, et al. Endovascular therapy for management of oral hemorrhage in malignant head and neck tumors. *Cardiovasc Intervent Radiol* 2005;28:722–9.
- Nakabayashi K, Negoro M, Handa T, et al. Evaluation of particulate embolic materials with MR imaging, scanning electron microscopy, and phase-contrast microscopy. *AJNR Am J Neuroradiol* 1997;18:485–91.
- Siskin GP, Dowling K, Virmani R, et al. Pathologic evaluation of a spherical polyvinyl alcohol embolic agent in a porcine renal model. *J Vasc Interv Radiol* 2003;14:89–98.
- Vaidya S, Tozer KR, Chen J. An overview of embolic agents. *Semin Intervent Radiol* 2008;25:204–15.
- Lubarsky M, Ray C, Funaki B. Embolization agents—which one should be used when? Part 2: small-vessel embolization. *Semin Intervent Radiol* 2010;27:99–104.
- Natarajan SK, Born D, Ghodke B, et al. Histopathological changes in brain arteriovenous malformations after embolization using Onyx or N-butyl cyanoacrylate. Laboratory investigation. *J Neurosurg* 2009;111:105–13.
- Mok JS, Marshall JN, Chan M, et al. Percutaneous embolization to control intractable epistaxis in nasopharyngeal carcinoma. *Head Neck* 1999;21:211–16.
- Remonda L, Schroth G, Caversaccio M, et al. Endovascular treatment of acute and subacute hemorrhage in the head and neck. *Arch Otolaryngol Head Neck Surg* 2000;126:1255–62.
- Morrissey DD, Andersen PE, Nesbit GM, et al. Endovascular management of hemorrhage in patients with head and neck cancer. *Arch Otolaryngol Head Neck Surg* 1997;123:15–19.
- Small M, Murray JA, Maran AG. A study of patients with epistaxis requiring admission to hospital. *Health Bull (Edinb)* 1982;40:20–9.
- Pallin DJ, Chng YM, McKay MP, et al. Epidemiology of epistaxis in US emergency departments, 1992 to 2001. *Ann Emerg Med* 2005;46:77–81.
- Koh E, Frazzini VI, Kagetsu NJ. Epistaxis: vascular anatomy, origins, and endovascular treatment. *AJR Am J Roentgenol* 2000;174:845–51.
- Elden L, Montanera W, Terbrugge K, et al. Angiographic embolization for the treatment of epistaxis: a review of 108 cases. *Otolaryngol Head Neck Surg* 1994;111:44–50.
- Tseng EY, Narducci CA, Willing SJ, et al. Angiographic embolization for epistaxis: a review of 114 cases. *Laryngoscope* 1998;108(4 Pt 1):615–19.
- Ernst RJ, Bulas RV, Gaskill-ShIPLEY M, et al. Endovascular therapy of intractable epistaxis complicated by carotid artery occlusive disease. *AJNR Am J Neuroradiol* 1995;16:1463–8.
- Sagara Y, Kiyosue H, Tanoue S, et al. Selective transarterial embolization with n-butyl-2-cyanoacrylate for the treatment of arterial hemorrhage after third molar extraction. *Neuroradiology* 2013;55:725–31.
- Maioriello AV, Stanley DJ, Ho T, et al. Successful Onyx embolization of life threatening traumatic posterior jugal artery fistula following mandibular fracture. *J Neurointerv Surg* 2012;4:e15.
- Thiex R, Wu I, Mulliken JB, et al. Safety and clinical efficacy of Onyx for embolization of extracranial head and neck vascular anomalies. *AJNR Am J Neuroradiol* 2011;32:1082–6.
- Shuster A, Gunnarsson T, Klurfan P, et al. N-butyl cyanoacrylate proved beneficial to avoid a nontarget embolization of the ophthalmic artery in endovascular management of epistaxis. A neurointerventional report and literature review. *Interv Neuroradiol* 2011;17:17–21.
- Chou WC, Lu CH, Lin G, et al. Transcutaneous arterial embolization to control massive tumor bleeding in head and neck cancer: 63 patients' experiences from a single medical center. *Support Care Cancer* 2007;15:1185–90.
- Luo CB, Teng MM, Chang FC, et al. Transarterial embolization of acute external carotid blowout syndrome with profuse oronasal bleeding by N-butyl-cyanoacrylate. *Am J Emerg Med* 2006;24:702–8.
- Mahadevia AA, Murphy KJ, O Bray R, et al. Embolization for intractable epistaxis. *Tech Vasc Interv Radiol* 2005;8:134–8.
- Luo CB, Teng MM, Lirng JF, et al. Endovascular embolization of intractable epistaxis. *Zhonghua Yi Xue Za Zhi (Taipei)* 2000;63:205–12.



Transarterial embolization of intractable nasal and oropharyngeal hemorrhage using liquid embolic agents

Seth B Hayes, Jeremiah N Johnson, Zachary Most, Mohamed Samy Elhammady, Dileep Yavagal and Mohammad Ali Aziz-Sultan

J NeuroIntervent Surg published online May 26, 2014

Updated information and services can be found at:

<http://jnis.bmj.com/content/early/2014/05/26/neurintsurg-2014-011101>

These include:

References

This article cites 30 articles, 7 of which you can access for free at: <http://jnis.bmj.com/content/early/2014/05/26/neurintsurg-2014-011101#BIBL>

Email alerting service

Receive free email alerts when new articles cite this article. Sign up in the box at the top right corner of the online article.

Topic Collections

Articles on similar topics can be found in the following collections

[Head and neck](#) (57)

Notes

To request permissions go to:

<http://group.bmj.com/group/rights-licensing/permissions>

To order reprints go to:

<http://journals.bmj.com/cgi/reprintform>

To subscribe to BMJ go to:

<http://group.bmj.com/subscribe/>