

Rescue, Combined, and Stand-Alone Thrombectomy in the Management of Large Vessel Occlusion Stroke Using the Solitaire Device: A Prospective 50-Patient Single-Center Study

Timing, Safety, and Efficacy

Vincent Costalat, MD; Paolo Machi, MD; Kyriakos Lobotesis, MBBS; Igor Maldonado, MD; Jean François Vendrell, MD; Carlos Riquelme, MD; Isabelle Mourand, MD; Didier Milhaud, MD; Chérif Héroum, MD; Pierre-François Perrigault, MD, PhD; Caroline Arquizan, MD*; Alain Bonafé, MD, PhD*

Background and Purpose—Large vessel occlusion in ischemic stroke is associated with a high degree of morbidity. When intravenous thrombolysis fails, mechanical thrombectomy can provide an alternative and synergistic method for flow restoration. In this study we evaluate the safety and efficacy of our stroke management protocol (RECAST study).

Methods—Fifty consecutive ischemic stroke patients with large vessel occlusion were included. After clinical and MRI imaging assessment, 3 treatment strategies were selected according to time of symptom onset and location of vessel occlusion: rescue therapy; combined therapy; and stand-alone thrombectomy (RECAST study). MRI ASPECT score <5 was the main exclusion criterion. Mechanical thrombectomy was performed exclusively with the Solitaire flow restoration device. Clinical outcome was assessed after treatment, on day 1, and at discharge.

Results—Mean patient age was 67.6 years, mean NIHSS score was 14.7, and mean ASPECT score was 6 on presentation. Vessel occlusions were in the middle cerebral artery (40%), the internal carotid artery (28%), and the basilar artery (32%). Rescue treatment represented 24%, combined therapy represented 56%, and stand-alone thrombectomy represented 20%. Mean recanalization time from symptoms onset was 377 minutes, with overall recanalization rate TICI 3 of 84%. NIHSS score at discharge was 6.5, with 60% of patients demonstrating NIHSS score 0 to 1 or an improvement of >9 points. Symptomatic complication rate was 10%. At 3 months, 54% of patients had a modified Rankin scale score of 0 to 2, with an overall mortality rate of 12%.

Conclusions—The present integrated stroke management protocol (RECAST study) demonstrated rapid, safe, and effective recanalization. We postulate that the Solitaire device contributed to high recanalization and patient selection using MRI ASPECT score to low and complication rates, therefore avoiding futile and dangerous interventions. (*Stroke*. 2011;42:1929-1935.)

Key Words: ischemic stroke ■ mechanical recanalization ■ reperfusion ■ self-expanding stent ■ thrombectomy

The use of intravenous (IV) recombinant human tissue plasminogen activator for cerebral arterial occlusion was initiated in the early 1990s, with recanalization rates ranging from 25% to 55% in the middle cerebral artery (MCA).¹⁻⁶ However, thrombus within large vessels is relatively resistant to plasminogen activators and IV thrombolysis alone does not result in rapid recanalization.⁷⁻¹¹ Because the neurological outcome is dependent mainly on the time required for recanalization, new therapeutic strategies in stroke units are increasingly involving direct endovascular techniques.

Intra-arterial fibrinolysis has been shown to improve target vessel recanalization in PROACT II, with a maximum recan-

alization rate of 66% in the MCA.⁷ It also has shown a significant clinical impact on patient outcome but a high hemorrhagic transformation rate.^{9,11,12} Recently, endovascular mechanical thrombectomy devices have demonstrated to successfully restore large vessel patency and therefore provide an alternative and synergistic method for large vessel recanalization.^{10,13-16}

There has been an increasing number of new thrombectomy devices currently introduced with varying theoretical mechanisms of action.^{8,10,13-15} Although these have dramatically improved the capacity of neurointerventionalist to conduct endovascular recanalization, they mainly are used as

Received November 29, 2010; accepted February 8, 2011.

From the CHU Montpellier Neuroradiology (V.C., P.M., K.L., I.M., J.F.V., C.R., A.B.), Montpellier, France; CHU Montpellier Neurology (I.M., D.M., C.H., C.A.), Montpellier, France; CHU Montpellier (P.F.P.), SARC, Anesthesiology, Montpellier, France.

*C.A. and A.B. contributed equally to this work.

Correspondence to Vincent Costalat, MD, CHU Montpellier, Neuroradiology, Av Augustin Fliche, Montpellier, France. E-mail vincentcost@hotmail.com

© 2011 American Heart Association, Inc.

Stroke is available at <http://stroke.ahajournals.org>

DOI: 10.1161/STROKEAHA.110.608976

a second-line therapy after IV fibrinolysis failure or lapse of IV fibrinolysis therapeutic windows. The exact role of this new technique, therefore, is not fully determined, leading to divergent therapeutic decisions among stroke practitioners.

As a consequence, a common algorithm was developed and unanimously accepted by the various members of our stroke multidisciplinary team (neurologists, neuroradiologists, and anesthesiologists) to streamline and ascertain a coalescent decision-making process in all patients with confirmed ischemic stroke secondary to large vessel occlusion. This integrated stroke management protocol included both IV fibrinolysis and thrombectomy, depending on the time of symptom onset and vessel occlusion location. All patients undergoing thrombectomy were treated using the Solitaire mechanical thrombectomy device (Solitaire flow restoration device or Solitaire FR device; ev3). The objective of this study was to evaluate and appraise the timing, safety, and efficacy of this integrated stroke management protocol (Rescue, Combined, and Stand-Alone Thrombectomy [RECAST] study).

Materials and Methods

Multidisciplinary Consensus: Organization

Ethical approval for this study was obtained by the local ethics committee in our institution after review of the stroke protocol. The Solitaire FR device in the European Union is certified for thrombectomy by the "Communauté Européenne." After a number of multidisciplinary stroke team meetings between May and August 2009, a unified strategy for stroke management was finalized in our stroke center. Detailed documentation describing the particulars regarding IV fibrinolysis, thrombectomy, and anesthesiology were also provided by each team. Clinical information, time of symptom onset, arrival in the stroke unit, start and end of imaging, duration of anesthesia, time to recanalization, and morphological and functional MRI information were all reported. In the angiographic suite, the time of puncture, the number of passes of the thrombectomy device, the time of recanalization, and the thrombolysis in cerebral infarction (TICI) score were all reported in the "acute phase proforma."

Acute Phase Management

A stroke neurologist systematically evaluated all patients with suspicion of an acute ischemic stroke. A comprehensive urgent MRI of brain with cerebral angiography and perfusion were performed as part of the initial patient work-up. All ischemic stroke patients presenting with a proximal major vessel occlusion (MCA, internal carotid artery, and basilar artery [BA]) confirmed clinically and on MRI (within 6 hours for the anterior circulation and within 24 hours for the posterior circulation) were included in the study. If no proximal large vessels occlusion was identified on imaging, then standard IV fibrinolysis was performed and managed independently by the neurologist.

Patients with a major vessel occlusion who met the inclusion/exclusion criteria listed in Table 1 were placed within 1 of 3 therapeutic arms, depending on the time from symptom onset and the location of vessel occlusion. These 3 therapeutic arms of the protocol, detailed in Table 1, consisted of rescue therapy, combined therapy, and stand-alone thrombectomy. MRI played a significant role in patient selection. More specifically, an ASPECT score^{17,18} based on lesion location found on diffusion-weighted imaging (DWI)¹⁹ was systematically evaluated by the on-call neuroradiologist in all cases of an anterior circulation stroke. Patients with an ASPECT score <5 were excluded to avoid futile and dangerous treatment. For the posterior circulation, extensive brain stem lesions on DWI were the main criterion for exclusion and no specific scale was consistently utilized. Once the decision for thrombectomy was made, the anesthetist would be immediately informed and the angiographic suite was prepared. Consent for intervention was

Table 1. Inclusion/Exclusion Criteria and Stroke Management Protocol Algorithm Depending on Time Windows and Vessel Occlusion

	0 h–4 h 30 min	4 h 30 min–6 h	>6 h
MCA	Rescue	Stand-alone thrombectomy	...
Terminal ICA	Combined	Stand-alone thrombectomy	...
BA	Combined	Combined	Combined

Inclusion criteria: (1) proximal major vessel occlusion: MCA (M1, M1–M2), terminal ICA, or BA; (2) all stroke patients with a relevant deficit; time window <6 h or no changes on T2 for the anterior circulation; time window <24 h for the posterior circulation.

Exclusion criteria: (1) ASPECT score <5; extensive brain stem involvement; spontaneous NIHSS score improvement.

ASPECT indicates Alberta Stroke Program Early CT; BA, basilar artery; ICA, internal carotid artery; MCA, middle cerebral artery; NIHSS, National Institutes of Health Stroke scale.

obtained from the patient or the family of the patient, depending on the neurological status.

Rescue Therapy: Definition

All patients with MCA occlusion in segment M1 or M1–M2 presenting within 4.5 hours and satisfying the inclusion criteria entered the rescue arm of the protocol. The clinical diagnosis of ischemic stroke was made by the on-call neurologist and IV fibrinolysis was initiated as soon as possible. The neuroradiologist and anesthesiologists in the meantime would prepare for potential rescue thrombectomy. Sixty minutes after initiation of the IV fibrinolysis, the neurologist would reassess the patient and obtain a second NIHSS. If the second NIHSS score was ≥ 8 or if there was a relevant neurological deficit present with a significant impact on the patient's quality of life, then this would be interpreted as a failed IV fibrinolysis and an urgent rescue thrombectomy would be performed.

Combined Therapy: Definition

Combined therapy was applied to all patients with terminal internal carotid artery or tandem occlusions presenting within 4.5 hours, and to all BA occlusions presenting within 24 hours. Combined therapy would involve immediate IV fibrinolysis, which would continue as a bridging mechanism until the angiographic suite would be prepared for an urgent thrombectomy. In contrast to the rescue arm, no second neurological assessment would be obtained before thrombectomy. IV fibrinolysis would continue during the endovascular procedure and, hence, the term combined therapy.

Stand-Alone Thrombectomy: Definition

Stand-alone thrombectomy was performed in patients presenting outside the IV fibrinolysis therapeutic window, ie, between 4.5 and 6 hours for MCA and terminal internal carotid artery occlusions. It was also applied in patients with any contraindications to IV fibrinolysis, eg, warfarin anticoagulation therapy (international normalized ratio >2), recent surgery, or history of hemorrhage/hematoma.

MRI Protocol

MRI was performed by using a 1.5-T magnet (33 mT/m hypergradients; Intera, release 10; Philips Medical System) with a phase-array head coil. First, a T2 gradient echo was performed to screen for intracranial hemorrhage and to approximately localize the thrombus in the intracranial circulation. Second, DWI sequences b0, b500, and b1000 were acquired, as was an Apparent Diffusion Coefficient (ADC) map to identify the necrotic core. FLAIR and T2 were also used to corroborate information about the time from symptom onset.²⁰ A time-of-flight sequence focused on the circle of Willis was then obtained to screen for large vessel occlusion. Finally, perfusion-weighted imaging using IV gadolinium (Prohance; Bracco) was acquired with colorimetric mapping after the time to peak parameter.

In case of MRI contraindication, a CT noncontrast angiography and perfusion were performed.

IV Fibrinolysis Protocol

IV thrombolysis with recombinant human tissue plasminogen activator (full dose, 0.9 mg/kg) was considered in all patients presenting within 4.5 hours from symptom onset. A loading dose of 10% was administered as soon as possible. Patient contraindications for IV fibrinolysis were: pregnancy, serum glucose <50 and >400 mg/dL; known hemorrhagic diathesis; known coagulation factor deficiency; oral anticoagulation treatment with international normalized ratio >1.5; use of heparin with a prothrombin time >2-times normal; platelet count <100 000/mL; sustained systolic blood pressure >185 mm Hg or diastolic blood pressure >110 mm Hg despite treatment; and life expectancy <3 months.

Mechanical Thrombectomy Protocol

All procedures were performed via a femoral artery approach and using general anesthesia (GA). In the anterior circulation, an 8-Fr or 9-Fr balloon guide catheter (Merci Balloon Guide Catheter; Concentric Medical) was introduced through a femoral sheath into the concerned carotid artery. In the posterior circulation, a 6-Fr Envoy (Cordis) guide catheter was placed into the dominant or most navigable vertebral artery. A 0.21-inch internal diameter microcatheter (Prowler Select Plus; Cordis or Vasco 21; Balt) was navigated distal to the point of occlusion over a 0.014-inch steerable microwire. The microwire was exchanged with the mechanical thrombectomy device. All patients undergoing mechanical thrombectomy were treated using the Solitaire FR or AB device (ev3). An intravenous bolus of 1000 IU of standard heparin was administered after Solitaire FR device deployment. On Solitaire FR device deployment, an angiographic control was performed to evaluate the correct placement and expansion of the device. The device was left in place for 2 to 7 minutes, allowing full expansion of the nitinol stent through the thrombus. Then, the fully deployed Solitaire FR device together with the delivery microcatheter were gently pulled back as a single unit and recovered. Before this retrieval, the balloon guide catheter was inflated and manual aspiration performed with a 50 mL syringe through the hemostatic valve to reverse the flow in the target artery and therefore reduce the risk of thromboembolism. Successful recanalization was defined as Thrombolysis In Cerebral Infarction (TICI) 3 in all treatable vessels. If the treatable vessel was not opened to at least TICI 2 with a maximum of 5 passes of the thrombectomy device, then the treatment was considered as a failure. No intra-arterial fibrinolytics were administered at any point during this study, even if the recanalization attempt was unsuccessful. Groin punctures were routinely closed with an Angio-Seal (St. Jude Medical, St. Paul, MN).

Anesthetic Protocol

After the decision for thrombectomy, rapid evaluation was performed by the anesthetist. If no significant contraindication was identified, then the patient was transferred to the angiography suite, where urinary bladder catheterization and intubation were performed. The blood pressure was carefully monitored during anesthetic induction and during the procedure, with a minimal threshold set at 90 mm Hg (mean arterial pressure). Following any complications, the patient was maintained under GA and transferred to the intensive care unit.

Postoperative Management

A CT scan was performed in the angiographic suite after all procedures to screen for immediate hemorrhagic transformation or any unforeseen procedural complications. Prompt extubation in elderly patients was preferred to avoid anesthetic complications. If the postprocedural neurological status did not allow immediate extubation, then patients were managed in the intensive care unit with prophylactic anticoagulation for the first 24 hours using fractionated heparin injection (0.2–0.6 mL). The number of days until extubation was recorded for all such patients. A further CT or MRI

Table 2. Distribution of Patient Between the 3 Arms Defined and Described in Table 1

	Combined	Rescue	Stand-Alone Thrombectomy	Overall
MCA	5*	12	3	20 (40%)
Terminal ICA	13	0	1	14 (28%)
BA	10	0	6†	16 (32%)
Overall	28 (56%)	12 (24%)	10 (20%)	50

BA indicates basilar artery; ICA, internal carotid artery; IV, intravenous; MCA, middle cerebral artery.

*Five protocol deviations were observed with 5 MCA occlusions undergoing combined instead of rescue therapy.

†Six patients with a BA occlusions underwent stand-alone thrombectomy as a consequence of IV contraindications.

was performed at 24 hours. If no hemorrhage was present, then antiplatelet monotherapy was administered while awaiting cardiac exploration. If a cardioembolic etiology was strongly suspected, then IV heparin was initiated with a target ACT score between 2 and 3, depending on the extent of the brain lesions on the 24-hour scan.

Adverse Event Definition

Clinically significant procedural complications were defined as procedural complications resulting in a ≥4-point NIHSS score decline, death, or groin complication requiring surgery or blood transfusion. Symptomatic intracranial hemorrhage was defined as a ≥4-point NIHSS score decline within 24 hours with blood products identified on the 24-hour head CT/MRI scan (petechial hemorrhage, parenchymal hematoma, or subarachnoid hemorrhage) or any intracranial hemorrhage in which no further NIHSS scores were available beyond baseline and the patient died. All 24-hour CT/MRI scans were reviewed by a second neuroradiologist and adjudicated as subarachnoid hemorrhage or as ECASS hemorrhagic infarction types I or II or ECASS parenchymal hematoma types I and II.

Patient

Patient neurological status was scored with a further NIHSS, immediately after extubation, on day 1, and at discharge. All patients were scheduled for a 3-month evaluation with a stroke practitioner. Good neurological outcome was defined as a NIHSS score of 0 or 1 or a NIHSS score improvement of >9 points at discharge or both.

Statistical Analysis

Patients and treatment characteristics were presented using median and range (or mean and SD) for continuous variables and frequencies and proportions for categorical variables. Times were compared between groups (defined by the procedure) using Student or Wilcoxon rank test as appropriate. Correlations were performed using Spearman correlation coefficient along with 95% CI. Statistical significance threshold was set at 5%. Statistical analysis was performed using SAS version 9.1 (SAS Institute).

Results

Population

Three hundred fifty-five patients were admitted to our stroke unit between August 2009 and May 2010. Among these, 57 arrived within 6 hours and presented with a proximal vessel occlusion. Seven were excluded: 5 because of an ASPECT score <5 and 2 because of extensive brain stem lesions. Fifty patients were included in this study and had a mean age of 67.6 years (median, 70 years; SD, 14.6 years) and a sex ratio of 50%. Cardiovascular risk factors were hypertension in 23%, diabetes in 15%, smoking in 10%, and dyslipidemia in 8%. Mean initial NIHSS score was 14.7 (median, 15; range,

Table 3. Technical Results of RECAST Study

Procedural Issues and Timing	TICI 3	Procedural Time (Groin Puncture to Maximum TICI) (min)	Mean No. of Device Passes	Symptomatic Perioperative Complication Rate
MCA, n=20	86% (19/20)	40	1.5	10% (2/20)
Terminal ICA, n=14	71% (10/14)	55.5	2.4	0% (0/14)
BA, n=16	81% (13/16)	56.2	2.1	19% (3/16)
Overall, n=50	84%	54	2	10%

BA indicates basilar artery; ICA, internal carotid artery; IV, intravenous; MCA, middle cerebral artery; RECAST, Rescue, Combined, and Stand-Alone Thrombectomy; TICI, thrombolysis in cerebral infarction.

3–23). Sixteen patients (32%) had an abnormal Glasgow coma scale score quoted by the emergency medical team on arrival.

Acute MRI

An MRI was performed upon admission in 48 of the 50 patients. In the anterior circulation, mean ASPECT score on DWI was 6.^{3–10} Two patients had MRI contraindications and were assessed by CT with CTA and CT perfusion. Four patients (8.3%) demonstrated significant motion artifact but DWI sequences were nevertheless available for all cases. Mean time for MRI was 22 minutes (range, 9–45 minutes).

Protocol Deviation

Protocol deviation regarding patient inclusion was observed in 5 cases (10%), with patients included despite an ASPECT score <5. The ASPECT score was 4 in 4 cases and 3 in 1 case

on the initial DWI. Among these, 2 patients died within the first week, 1 had a NIHSS score of 20 at discharge, and 2 were quoted NIHSS score of 0 at discharge. Deviation to the stroke management algorithm was also observed in another 5 cases (10%) with MCA occlusions. In these patients, combined therapy was performed instead of rescue treatment. All 5 had NIHSS score of 0 at discharge.

Technical Results

A total of 50 patients were included in this study, 12 in the rescue therapy group, 28 in the combined therapy group, and 10 in the stand-alone thrombectomy group, as previously described (Table 2). Recanalization TICI 3 was achieved in 84% and TICI 2B was achieved in 4%, with a primary end point of 88% (TICI 3 and TICI 2B). We observed 2 cases of TICI 2A and 4 cases of TICI 0. Mean passes of the thrombectomy device were 2 (median, 2; range, 1–5). Results per location of the vessel occlusion are summarized in Table 3. Solitaire FR or AB devices were used in all cases.

Workflow Timing

Mean time between symptom onset and presentation was 2 hours 56 minutes, with a marked discrepancy between anterior and posterior circulation, as expected (1 hour 51 minutes for anterior circulation and 5 hours 20 minutes for posterior circulation). Mean time between presentation and MRI was 59 minutes, with a mean MRI procedure time of 22 minutes. Mean time between groin puncture to maximum final TICI was 54 minutes (median, 48 minutes; range, 15–243 minutes), with no significant difference observed between anterior and posterior circulation. The workflow timing results are summarized in detail in Table 4.

Table 4. Work Flow Timing

Work Flow Timing	Overall Lesions (n=50)	Anterior Circulation (n=34)	Posterior Circulation (n=16)
Symptoms onset, door			
Mean	02:56	01:51	05:20
Median	02:07 (00:30–11:40)	01:55 (00:45–04:00)	04:07 (01:28–11:40)
Door to MRI arrival			
Mean	00:59	00:37	01:01
Median	00:34 (00:04–11:41)	00:34 (00:10–01:43)	00:40 (00:04–05:49)
MRI procedure			
Mean	00:22	00:21	00:22
Median	00:23 (00:09–00:45)	00:22 (00:09–00:35)	00:21 (00:15–00:38)
End MRI to groin puncture			
Mean	01:21	01:14	01:20
Median	01:05 (00:09–04:33)	01:05 (00:22–03:16)	01:08 (00:09–03:30)
Groin puncture to maximum TICI			
Mean	00:54	00:47	01:11
Median	00:48 (00:15–04:03)	00:49 (00:16–01:53)	00:56 (00:15–04:03)
Symptoms onset to maximum TICI			
Mean	06:17	04:54	09:22
Median	05:27 (02:58–16:10)	04:54 (02:58–06:57)	09:17 (03:42–16:10)

Data shown are hours and minutes.

MRI indicates magnetic resonance imaging; TICI, thrombolysis in cerebral infarction.

Table 5. Major Clinical Outcome by Location

Location	Total (n=50)	MCA (n=20)	Terminal ICA (n=14)	BA (n=16)
Discharge NIHSS score 0–1 or NIHSS score improvement >9 points	60% (30/50)	75% (15/20)	57% (8/14)	44% (7/16)
3-mo mRS score 0–2 or NIHSS score 0–1	54% (27/50)	70% (14/20)	43% (6/14)	44% (7/16)
3-mo mortality	12% (6/50)	0%	14% (2/14)	25% (4/16)

BA indicates basilar artery; ICA, internal carotid artery; MCA, middle cerebral artery; mRS, modified Rankin scale; NIHSS, National Institutes of Health Stroke scale.

Complications

Symptomatic complications were seen in 5 patients (10%), with 4 adverse embolic infarcts in a new territory observed on the DWI and one posterior fossa hemorrhagic transformation. New ischemic lesions were seen in 8 cases (16%) on DWI sequences, including the 4 cases of adverse embolic events described above. At day one, 7 hemorrhagic complications were demonstrated on CT or MRI imaging, 5 parenchymal hematomas (4 parenchymal hematoma1, 1 parenchymal hematoma2), and 2 persisting subarachnoid hemorrhages. Only one parenchymal hematoma2 (2%) hematoma was symptomatic according to the ECASS definition,⁶ following an initial BA occlusion.

Clinical Results

Sixty percent (30/50) had NIHSS score improvement of >9 points or NIHSS score 0 to 1 at discharge (Table 5). Mean NIHSS score was 6.5 at discharge (Figure). For the BA occlusions, 8 of 16 (50%) patients had a normal Glasgow coma scale score at discharge but with 4 deaths recorded (25%). At 3 months, 70% of MCA patients had a modified Rankin scale score 0 to 2 or NIHSS score 0 to 1 or both, 44% of internal carotid artery occlusions, and 43% of BA occlusions, with an overall rate of 54%. The overall mortality rate at 3 months was 12% (6 of 50 patients; Table 5).

Discussion

Stroke Management Pathway

Our stroke management pathway clearly focuses on patients with large vessel occlusions and the evidence to date shows that these patients respond poorly to IV fibrinolysis.^{4,7,21} The

location of the occlusion and the time from symptom onset were the determining criteria (Table 1).

In MCA occlusions, IV fibrinolysis was initiated as soon as possible in accordance with ECASS 3 protocol⁶ up to 4.5 hours. A 60-minute window was allowed to assess any clinical improvement. Interestingly, in the 12 patients of the rescue arm with an MCA stroke, only 2 improved clinically after IV fibrinolysis, with a good outcome at discharge (NIHSS scores 0 and 1) and did not undergo a complementary mechanical thrombectomy. Ten patients with MCA strokes underwent thrombectomies that were therefore possibly unnecessarily delayed. Further investigation is needed to assess the appropriateness of rescue therapy compared to a unified combined strategy.

Imaging-Based Patient Selection

The approved medical therapy in acute ischemic stroke remains IV fibrinolysis within 4.5 hours.⁶ However, there is increasing evidence²² that by using advanced imaging techniques, it is possible to facilitate safe and effective treatment in patients beyond these windows. Endovascular treatment in patients with a clinical/DWI mismatch may prevent clinical worsening and promote improvement.²³ The ASPECT scoring system¹⁹ for rating ischemic lesions has been demonstrated to be a reliable and reproducible “location-weighted” system to assess the initial necrotic core on DWI.

In our center, the ASPECT score after MRI played a pivotal role in patient selection for stroke management. All patients with an ASPECT score of ≥5 were selected for treatment. It is important to notice that among the 5 patients with protocol deviation with ASPECT score inclusion <5, 2 died and 1 was quoted NIHSS score of 20 at discharge. This is in accordance with the work by Kimura et al²⁴ and, more recently, Nezu et al,¹⁹ who demonstrated that the ASPECT score is a good and reliable predictive factor for brain lesion recovery. This has allowed us to safely and cautiously extend our therapeutic options beyond the traditional time constraints of the IV fibrinolysis.

Contrary to the anterior circulation, in the posterior fossa, ischemic lesions are associated with an increased mortality and practitioners constantly face a therapeutic and ethical dilemma. Doing nothing usually leads to death, but intervention, even if successful, can leave the patient in a vegetative state, especially when the lesions are widespread. The ASPECT scoring system in the posterior fossa lesion published by the Calgary team²⁵ suggests that with an ASPECT score <8, no good clinical outcome can be ex-

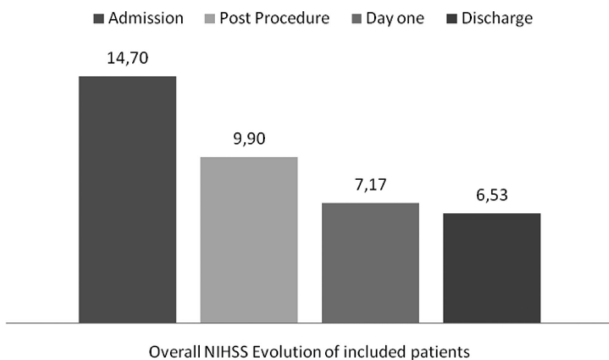


Figure. Graph showing National Institutes of Health Stroke Scale Score from admission to discharge in all included patients.

pected. Renard et al²⁶ similarly presented that a maximum score of 3 points predicted a poor outcome on a 10-point grading scale. In our opinion, there is still insufficient data regarding the relationship between BA occlusion prognosis and DWI to define a fixed therapeutic strategy in the posterior fossa. Hence, in this study, although extensive brain stem lesions on DWI were a main criterion for exclusion, no specific cut-off was consistently utilized. Patient selection in this location is still a challenge.

Recanalization Rate

The use of the Solitaire device facilitated a very high rate of recanalization (TICI 3) in 84%, in comparison with the Penumbra trial¹³ (27.2%) and the Multimerci trial¹⁰ (69.5%). Mazhigi et al²⁷ also demonstrated in the internal carotid artery a recanalization rate of only 46% in comparison to 71% in our study. Clearly, the Solitaire FR device has allowed rapid and effective mechanical thrombectomy with a low number of passes (mean, 2) and satisfactory recanalization results (TICI 2B/TICI 3 achieved in 88%). Another interesting point is that in 22 patients (44%), only 1 pass was sufficient to obtain a TICI 2B/TICI3 recanalization. These results are supported by other recent Solitaire FR device studies.^{15,28} Castaño et al¹⁵ also demonstrated a recanalization rate of 90% (TICI 2B/TICI3) in 18 of the 20 patients using the Solitaire device in MCA occlusions.

General Anesthesia

In our study, all procedures except 2 were performed using GA according to the protocol described in the Materials and Methods. Patient motion could lead to longer and less efficient treatments or, even worse, to vascular injury and catastrophic intracranial hemorrhage. Jumaa et al²⁹ and Abou-Chebl et al³⁰ compared the outcome of patients treated with conscious sedation and GA. They observed an increased mortality rate in the group with GA with no difference in the length of treatment and hemorrhagic complication rate. The main problem, however, with these studies was a selection bias. Patients who received GA were more likely to have more significant vessel occlusions and higher NIHSS scores, therefore representing more extensive lesions. Consequently, it is now not possible to conclude that conscious sedation is safer than GA. Interestingly, there was no difference in length of treatment or hemorrhagic complication rate observed between the 2 groups.

However, if time to recanalization is the main objective, then clearly conscious sedation will help to reduce this time in most cases. Furthermore, there might be further theoretical advantages of conscious sedation related to the cerebral autoregulation and blood pressure changes that are altered by anesthetic agent. The authors would welcome a randomized prospectively study between conscious sedation and GA. In our study, immediate extubation was observed in 67% of the patients. Interestingly, of the patients with a final modified Rankin scale score 0 to 2, 75% were extubated immediately, compared to 59% in the group with modified Rankin scale score >2 ($P=0.26$). However, one has to interpret these results with some caution and consider the same selection

bias described regarding the studies by Jumaa et al²⁹ and Abou-Chebl et al.³⁰

Clinical Results

The NIHSS score dramatically improved from day 1 to discharge (14.7 to 6.5), as shown in Figure 1. This was also reported by Castano et al,¹⁵ showing a mean NIHSS score of 9.4 at day 7. As expected, differences were observed between locations, with a significant improvement of 75% in the MCA patients in contrast to 43% in the vertebrobasilar system. Overall, we reported a favorable neurological outcome in 60% of patients at discharge (NIHSS score 0–1, or NIHSS score improvement by 9 points). This is in accordance with the study by Roth et al,²⁸ who recently reported a 63% good neurological outcome at discharge. Our 3-month follow-up results were also similar to those observed in other Solitaire studies. We demonstrated modified Rankin scale score 0 to 2 at 3 months in 54% of patients in comparison to 45% reported by Castaño et al¹⁵ and 50% reported by Roth et al.²⁸ Interestingly, we observed a lower mortality rate of 12% in our series in contrast to the studies by Castano et al (20%)¹⁵ and Roth et al (18%).²⁸ We hypothesize that the systematic utilization of DWI ASPECT for patient selection most likely contributed to this.

Therapeutic Safety

Safety in this small series was satisfactory, with a rate of symptomatic intracranial hemorrhage of 2% (1 of 50) representing following a case of BA recanalization. This rate is less than the rates reported in the PROACT II study⁷ and the IMS studies,^{21,31} and similar to the 2.5% reported in the ECASS III trial^{6,32} and the SITS-ISTR registry.⁵ Our study, as well as PROACT-II, IMS, and Recalyze, only included patients with documented large artery occlusions, which was not the case in the ECASS III trial or the SITS-ISTR registry. This difference in the inclusion criteria is reflected in the median baseline NIHSS score, which was only 9 to 10 in ECASS III and only 11 in the SITS-ISTR registry, compared to 14.7 in our study. The DWI ASPECT inclusion criteria used in our protocol probably reduced the number of interventions in patients with extensive lesions and most likely contributed to the low hemorrhagic rate reported. Also, it must be noted that 20% (10 of 50) of the patients in this study were treated with mechanical thrombectomy alone and no IV fibrinolysis, and therefore potentially lowering the hemorrhagic risk. Symptomatic embolic events occurred in 4 cases and appeared to be the most common procedural complication of the technique. Although 2 cases were observed in the anterior and 2 in the posterior circulation, these represented 6% (2/34) and 12.5% (2/16) of cases in each territory. This discrepancy may reflect the fact that a balloon-mounted guide catheter was used only in the anterior circulation.

Our perioperative mortality rate was 0%. Again, this is in line with the low complication rate demonstrated and indicates the safety of the thrombectomy protocol and patient selection. At 3 months, the overall mortality rate was 12% (6 of 50), which again is very favorable compared to other thrombectomy studies.^{13–15,28}

Conclusions

In this study, the integrated Stroke Management Protocol (RECAST study) allowed rapid and safe recanalization (TICI 3 and TICI 2B in 88%). The efficacy and safety of the Solitaire device cannot be ignored, especially given the excellent angiographic results and low complication rates. An overall clinical outcome with a mean NIHSS score of 6.5 was observed at discharge compared to an initial mean NIHSS score of 14.7 at entry. NIHSS score 0 to 1 was observed in 38% (19 of 50) of the patients at discharge, and 60% had an early neurological improvement. Overall symptomatic complication rate was 10%, with 4 cases of adverse embolic events during thrombectomy and 1 case of symptomatic hemorrhagic complication, representing only 2% in this series. At 3 months, we demonstrated a modified Rankin scale score 0 to 2 in 54% of patients with an overall mortality rate of 12%. We postulate that the use of the DWI ASPECT score has contributed to this by providing careful selection of patients and therefore avoiding futile and dangerous recanalization.

Disclosures

A.B. is a consultant for ev3 Inc.

References

- Lees KR, Bluhmki E, von Kummer R, Brott TG, Toni D, Grotta JC, et al. Time to treatment with intravenous alteplase and outcome in stroke: An updated pooled analysis of ecass, atlantis, ninds, and epithet trials. *Lancet*. 375:1695–1703.
- del Zoppo GJ, Poeck K, Pessin MS, Wolpert SM, Furlan AJ, Ferbert A, Alberts MJ, Zivin JA, Wechsler L, Busse O, et al. Recombinant tissue plasminogen activator in acute thrombotic and embolic stroke. *Ann Neurol*. 1992;32:78–86.
- Hacke W, Kaste M, Fieschi C, von Kummer R, Davalos A, Meier D, et al. Randomised double-blind placebo-controlled trial of thrombolytic therapy with intravenous alteplase in acute ischaemic stroke (ECASS II). Second European-Australasian Acute Stroke Study Investigators. *Lancet*. 1998;352:1245–1251.
- Tissue plasminogen activator for acute ischemic stroke. The National Institute of Neurological Disorders and Stroke rt-PA stroke study group. *N Engl J Med*. 1995;333:1581–1587.
- Wahlgren N, Ahmed N, Dávalos A, Hacke W, Millán M, Muir K, et al. Thrombolysis with alteplase 3–4.5 h after acute ischaemic stroke (SITS-ISTR): An observational study. *Lancet*. 2008;372:1303–1309.
- Bluhmki E, Chamorro A, Dávalos A, Machnig T, Sauce C, Wahlgren N, et al. Stroke treatment with alteplase given 3.0–4.5 h after onset of acute ischaemic stroke (ECASS III): Additional outcomes and subgroup analysis of a randomised controlled trial. *Lancet Neurol*. 2009;8:1095–1102.
- Furlan A, Higashida R, Wechsler L, Gent M, Rowley H, Kase C, et al. Intra-arterial prourokinase for acute ischemic stroke. The PROACT II study: A randomized controlled trial. *Prolyse in Acute Cerebral Thromboembolism*. *JAMA*. 1999;282:2003–2011.
- Mahon BR, Nesbit GM, Barnwell SL, Clark W, Marotta TR, Weill A, et al. North American clinical experience with the EKOS MicroLysis infusion catheter for the treatment of embolic stroke. *AJNR Am J Neuroradiol*. 2003;24:534–538.
- Lindsberg PJ, Mattle HP. Therapy of basilar artery occlusion: A systematic analysis comparing intra-arterial and intravenous thrombolysis. *Stroke*. 2006;37:922–928.
- Gobin YP, Starkman S, Duckwiler GR, Grobelny T, Kidwell CS, Jahan R, et al. MERCI I: A phase I study of mechanical embolus removal in cerebral ischemia. *Stroke*. 2004;35:2848–2854.
- Saqqur M, Uchino K, Demchuk AM, Molina CA, Garami Z, Calleja S, et al. Site of arterial occlusion identified by transcranial doppler predicts the response to intravenous thrombolysis for stroke. *Stroke*. 2007;38:948–954.
- Khatri P, Neff J, Broderick JP, Khoury JC, Carrozzella J, Tomsick T. Revascularization end points in stroke interventional trials: Recanalization versus reperfusion in IMS-I. *Stroke*. 2005;36:2400–2403.
- The penumbra pivotal stroke trial: Safety and effectiveness of a new generation of mechanical devices for clot removal in intracranial large vessel occlusive disease. *Stroke*. 2009;40:2761–2768.
- Smith WS, Sung G, Starkman S, Saver JL, Kidwell CS, Gobin YP, et al. Safety and efficacy of mechanical embolectomy in acute ischemic stroke: Results of the MERCI trial. *Stroke*. 2005;36:1432–1438.
- Castano C, Dorado L, Guerrero C, Millan M, Gomis M, Perez de la Ossa N, et al. Mechanical thrombectomy with the solitaire ab device in large artery occlusions of the anterior circulation: A pilot study. *Stroke*. 2010;41:1836–1840.
- Breckenfeld C, Schroth G, El-Koussy M, Nedeltchev K, Reinert M, Slotboom J, et al. Mechanical thromboembolectomy for acute ischemic stroke: Comparison of the catch thrombectomy device and the merci retriever in vivo. *Stroke*. 2008;39:1213–1219.
- Barber PA, Demchuk AM, Zhang J, Buchan AM. Validity and reliability of a quantitative computed tomography score in predicting outcome of hyperacute stroke before thrombolytic therapy. ASPECTS study group. Alberta Stroke Programme Early CT Score. *Lancet*. 2000;355:1670–1674.
- Hill MD, Demchuk AM, Tomsick TA, Palesch YY, Broderick JP. Using the baseline CT scan to select acute stroke patients for IV-IA therapy. *AJNR Am J Neuroradiol*. 2006;27:1612–1616.
- Nezu T, Koga M, Kimura K, Shiokawa Y, Nakagawara J, Furui E, et al. Pretreatment aspects on DWI predicts 3-month outcome following rt-PA: SAMURAI rt-PA Registry. *Neurology*. 2010;75:555–561.
- Toyoda K, Ida M, Fukuda K. Fluid-attenuated inversion recovery intraarterial signal: An early sign of hyperacute cerebral ischemia. *AJNR Am J Neuroradiol*. 2001;22:1021–1029.
- The interventional management of stroke (ims) ii study. *Stroke*. 2007;38:2127–2135.
- Albers GW, Thijs VN, Wechsler L, Kemp S, Schlaug G, Skalabrini E, et al. Magnetic resonance imaging profiles predict clinical response to early reperfusion: The diffusion and perfusion imaging evaluation for understanding stroke evolution (DEFUSE) study. *Ann Neurol*. 2006;60:508–517.
- Janjua N, El-Gengaihy A, Pile-Spellman J, Qureshi AI. Late endovascular revascularization in acute ischemic stroke based on clinical-diffusion mismatch. *AJNR Am J Neuroradiol*. 2009;30:1024–1027.
- Kimura K, Iguchi Y, Shibazaki K, Terasawa Y, Inoue T, Uemura J, et al. Large ischemic lesions on diffusion-weighted imaging done before intravenous tissue plasminogen activator thrombolysis predicts a poor outcome in patients with acute stroke. *Stroke*. 2008;39:2388–2391.
- Puetz V, Sylaja PN, Hill MD, Coutts SB, Dzialowski I, Becker U, et al. CT angiography source images predict final infarct extent in patients with basilar artery occlusion. *AJNR Am J Neuroradiol*. 2009;30:1877–1883.
- Renard D, Landragin N, Robinson A, Brunel H, Bonafe A, Heroum C, Milhaud C. MRI-based score for acute basilar artery thrombolysis. *Cerebrovasc Dis*. 2008;25:511–516.
- Mazighi M, Serfaty JM, Labreuche J, Laissy JP, Meseguer E, Lavallée PC, et al. Comparison of intravenous alteplase with a combined intravenous-endovascular approach in patients with stroke and confirmed arterial occlusion (RECANALISE study): A prospective cohort study. *Lancet Neurol*. 2009;8:802–809.
- Roth C, Papanagiotou P, Behnke S, Walter S, Haass A, Becker C, et al. Stent-assisted mechanical recanalization for treatment of acute intracerebral artery occlusions. *Stroke*. 2010;41:2559–2567.
- Jumaa MA, Zhang F, Ruiz-Ares G, Gelzinis T, Malik AM, Aleu A, et al. Comparison of safety and clinical and radiographic outcomes in endovascular acute stroke therapy for proximal middle cerebral artery occlusion with intubation and general anesthesia versus the nonintubated state. *Stroke*. 2010;41:1180–1184.
- Abou-Chebl A, Lin R, Hussain MS, Jovin TG, Levy EI, Liebeskind DS, et al. Conscious sedation versus general anesthesia during endovascular therapy for acute anterior circulation stroke: Preliminary results from a retrospective, multicenter study. *Stroke*. 2010;41:1175–1179.
- Tomsick T, Broderick J, Carrozzella J, Khatri P, Hill M, Palesch Y, et al. Revascularization results in the Interventional Management of Stroke II trial. *AJNR Am J Neuroradiol*. 2008;29:582–587.
- Davis S, Donnan G. The ECASS III results and the tPA paradox. *Int J Stroke*. 2009;4:17–18.

Rescue, Combined, and Stand-Alone Thrombectomy in the Management of Large Vessel Occlusion Stroke Using the Solitaire Device: A Prospective 50-Patient Single-Center Study: Timing, Safety, and Efficacy

Vincent Costalat, Paolo Machi, Kyriakos Lobotesis, Igor Maldonado, Jean François Vendrell, Carlos Riquelme, Isabelle Mourand, Didier Milhaud, Chérif Héroum, Pierre-François Perrigault, Caroline Arquizan and Alain Bonafé

Stroke. 2011;42:1929-1935; originally published online May 19, 2011;

doi: 10.1161/STROKEAHA.110.608976

Stroke is published by the American Heart Association, 7272 Greenville Avenue, Dallas, TX 75231

Copyright © 2011 American Heart Association, Inc. All rights reserved.

Print ISSN: 0039-2499. Online ISSN: 1524-4628

The online version of this article, along with updated information and services, is located on the World Wide Web at:

<http://stroke.ahajournals.org/content/42/7/1929>

Permissions: Requests for permissions to reproduce figures, tables, or portions of articles originally published in *Stroke* can be obtained via RightsLink, a service of the Copyright Clearance Center, not the Editorial Office. Once the online version of the published article for which permission is being requested is located, click Request Permissions in the middle column of the Web page under Services. Further information about this process is available in the [Permissions and Rights Question and Answer](#) document.

Reprints: Information about reprints can be found online at:
<http://www.lww.com/reprints>

Subscriptions: Information about subscribing to *Stroke* is online at:
<http://stroke.ahajournals.org/subscriptions/>