

Thyroid Nodules

Last Updated: March 10, 2012

Authors

- **Leslie J. DeGroot, M.D.**
Research Professor, Univ. of Rhode Island/Providence, 80 Washington St (room 302), Providence, RI 02903
- **Furio Pacini, M.D.**
Istituto Di Endocrinologia Metodologia Clinica E Medicina Del Lavoro Universita Degli Studi Di Pisa Via Paradisa 2, 56018 Pisa, Italy Tel: 011-39-50-540748 Fax: 011-39-50-578772

Introduction

Thyroid cancer accounts for only 0.4% of all cancer deaths, with an incidence of 11 cases and about 0.5-0.6 deaths per 100,000 population in the United States each year, according to the November 2011 SEER report (<http://seer.cancer.gov/statfacts/html/thyro.html>). Its clinical importance, by contrast, is out of all proportion to its incidence, because cancers of the thyroid must be differentiated from the much more frequent benign adenomas and multinodular goiters. The latter, depending on the criteria employed, occur in up to 4% of the population, and thyroid nodules may be present in 20% or more of adults subjected to routine thyroid echography.

The differential diagnosis of thyroid nodules is now easily accomplished by fine needle aspiration cytology in 60-90% of the cases, allowing a significant reduction in the number of thyroid surgeries performed for thyroid nodules. This chapter is concerned with the clinical and pathological description of benign and malignant thyroid nodules and with the diagnostic and therapeutic approach to them. What will be said applies also to nodules found within a multinodular goiter, although as a separate entity this disease is discussed in Chapter 17.

Numerous classifications of thyroid tumors have been proposed. The one we currently follow groups the lesions on the basis of histologic findings (Table 18-1). The frequently encountered papillary tumors can be subdivided into the small proportion that have only papillary histologic characteristics and the larger group having, in addition, follicular elements. There is no agreement that these groups differ functionally, and current terminology treats them as one.

Definition

The thyroid adenoma is a benign neoplastic growth contained within a capsule. The term adenoma and nodule are often used interchangeably in the literature. This practice is imprecise because adenoma implies a specific benign new tissue growth with a glandlike cellular structure, whereas a nodule could as well be a cyst, carcinoma, lobule of normal tissue, or other focal lesion different from the normal gland. In the following section, the term nodule appears frequently when there is need for a nonspecific term.

Table 18-1. Neoplasms of the Thyroid (Adapted, and Revised, from WHO Classification)(1)

1. Adenomas (Fig. 18-1, below)
 1. Follicular
 1. Colloid variant
 2. Embryonal
 3. Fetal
 4. Hurthle cell variant
 2. Papillary (probably malignant)
 3. Teratoma
2. Malignant Tumors
 1. Differentiated
 1. Papillary adenocarcinoma
 1. Pure papillary adenocarcinoma
 2. Mixed papillary and follicular carcinoma (variants including tall cell, follicular, oxyphil, solid)
 2. Follicular adenocarcinomas (variants: “malignant adenoma”, Hurthle cell carcinoma or oxyphil carcinoma, clear-cell carcinoma, insular carcinoma)
 2. Medullary carcinoma- (not a tumor of follicular cells)
 3. Undifferentiated
 1. Small cell (to be differentiated from lymphoma)
 2. Giant cell
 3. Carcinosarcoma
 4. Miscellaneous
 1. Lymphoma, sarcoma
 2. Squamous cell epidermoid carcinoma
 3. Fibrosarcoma
 4. Mucoepithelial carcinoma
 5. Metastatic tumor

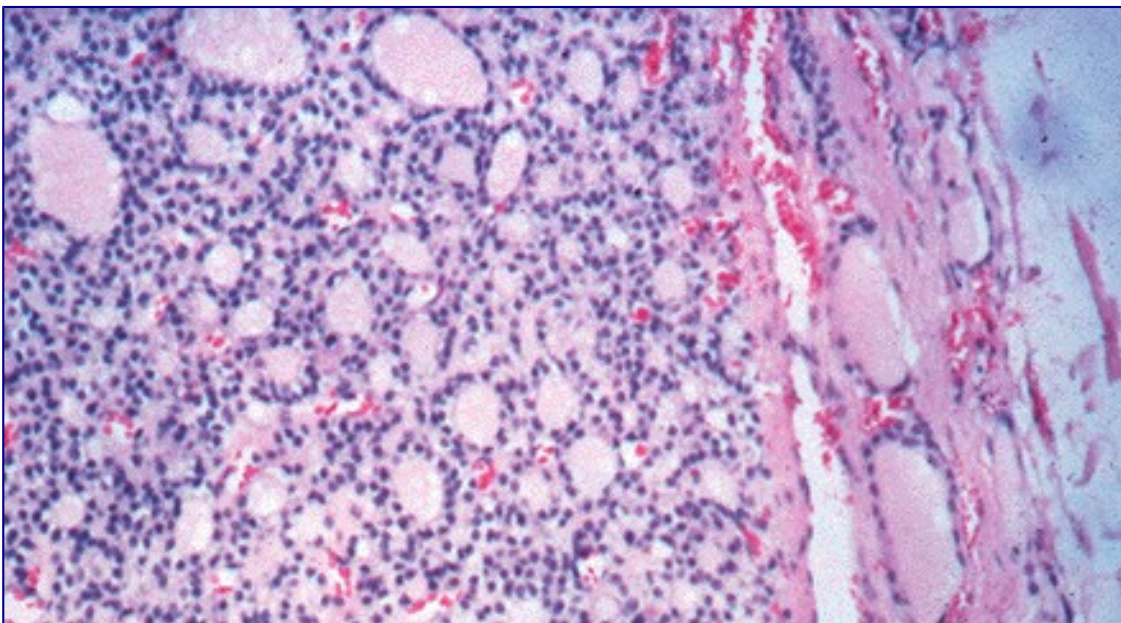


Figure 18-1. A) Follicular and microfollicular adenoma. The nodule shows microfollicles, is sharply circumscribed by a delicate even fibrous capsule, and there is no invasion of the capsule or blood

vessels by the tumor.

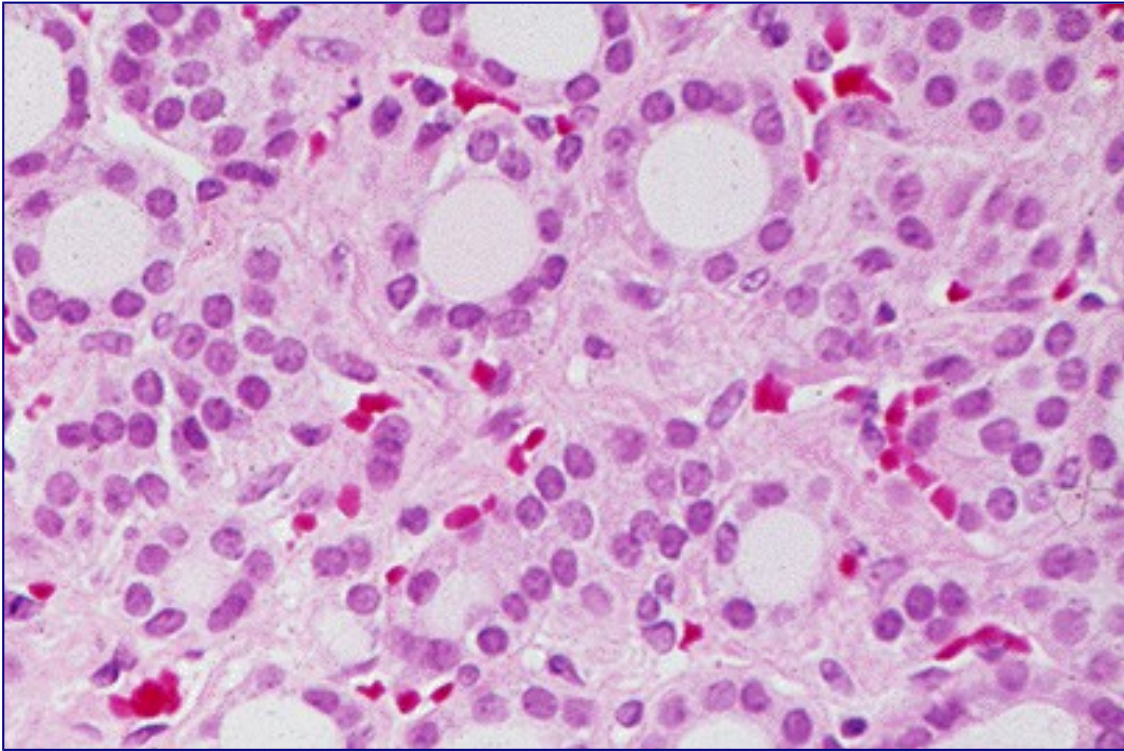


Figure 18-1. B) The central area of a microfollicular adenoma displays regular nuclei and some interfollicular edema.

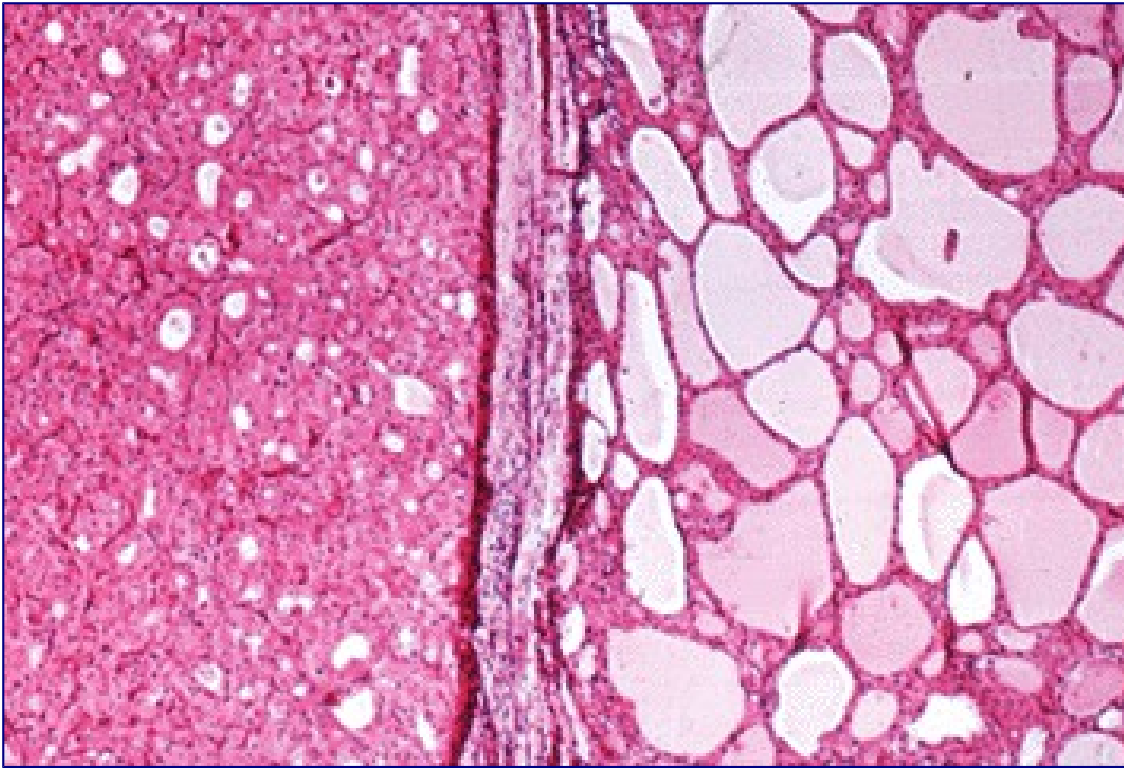


Figure 18-1. C) Hurthle (oxyphile) cell tumor, lower half of photomicrograph, with well circumscribed margin established by an intact delicate fibrous capsule. This is a Hurthle cell tumor of low malignant potential (an adenoma).

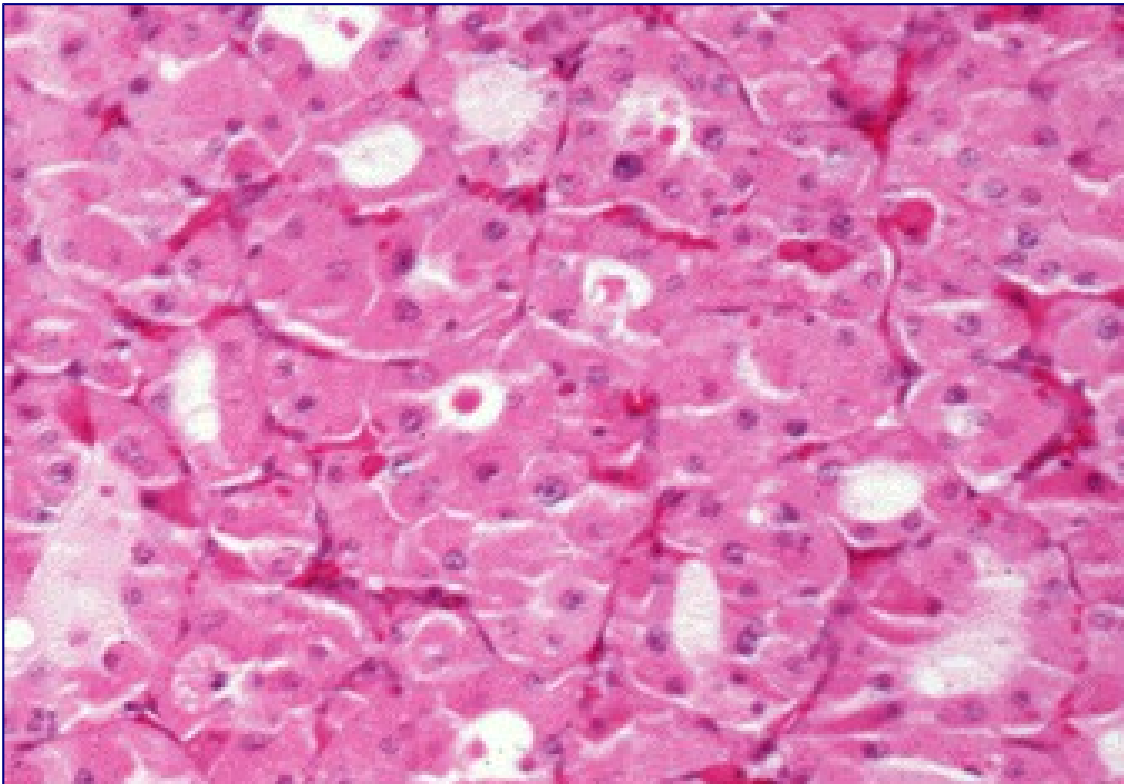


Figure 18-1. D) High power view of a Hurthle cell tumor made up of microfollicles lined by large acidophilic cell, the cytoplasm of which is granular and filled with mitochondria.

Pathology of Nodules

Thyroid nodules are not expression of a single disease but are the clinical manifestation of a wide range of different diseases. Non-neoplastic nodules are the result of glandular hyperplasia arising spontaneously or following partial thyroidectomy; rarely, thyroid hemiagenesia may present as hyperplasia of the existing lobe, mimicking a thyroid nodule. Non-neoplastic thyroid diseases, such as Hashimoto's thyroiditis or subacute thyroiditis may appear as thyroid lumps which are not true nodules but just the expression of the underlying thyroid disease.

Benign neoplastic nodules are divided into embryonal, fetal, follicular, Hurthle, and possibly papillary adenomas on the basis of their characteristic pattern ¹². Examples appear in Figure 18-1 (above). The adenomas usually exhibit a uniform orderly architecture and few mitoses, and show no lymphatic or blood vessel invasion. They are characteristically enveloped by a discrete fibrous capsule or a thin zone of compressed surrounding thyroid tissue. All types of nodules may become partially cystic, presumably through necrosis of a portion of the growth. Cyst formation is very common in colloid nodules.

Whether papillary adenoma is a real entity is debatable; most observers believe that all papillary tumors should be considered as carcinomas. Others consider that some papillary tumors are benign adenomas. It is our impression that papillary tumors are best thought of as carcinomatous, although the degree of invasive potential may be very slight in some instances. The same confusion extends to Hurthle cell adenomas. Many pathologists consider all of these tumors as low-grade carcinomas in view of their frequent late recurrences. For this reason, the nondefinitive term Hurthle cell tumor is commonly used. Pathologists usually grade them on the probability of being malignant, based on factors such as invasion of the thyroid tumor capsule or blood vessels, without differentiation into benign and malignant. Hurthle cell tumors are found on electron microscopy to be packed with mitochondria, which accounts for their special eosinophilic staining quality.

Nearly half of all single nodules have on gross inspection a gelatinous appearance, are composed of large colloid-filled follicles, and are not completely surrounded by a well-defined fibrous capsule. These nodules are listed as colloid variants of follicular adenomas in our classification. Many pathologists report these as colloid nodules, and suggest that each is a focal process perhaps related to multinodular goiter rather than a true adenoma. These tumors are usually not surrounded by a capsule of compressed normal tissue, and often show degeneration of parenchyma, hemosiderosis, and colloid phagocytosis (Fig. 18-2). Recent studies indicate that most adenomas, as well as carcinomas, are truly clonal — derived from one cell — whereas colloid nodules, at least in multinodular goiters, tend to be polyclonal (2).

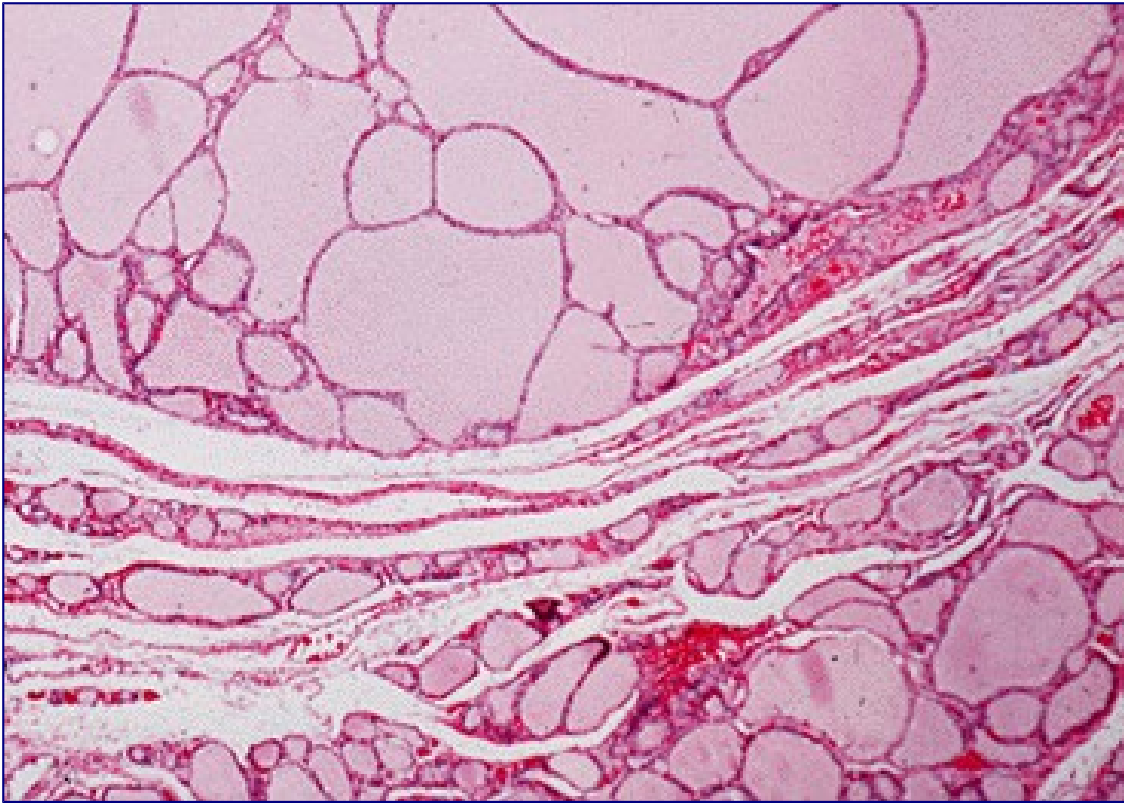


Figure 18-2. A) "Colloid nodules" display macrofollicles lined by flattened thyroid epithelial cells. The nodules are circumscribed and do not have a fibrous capsule.

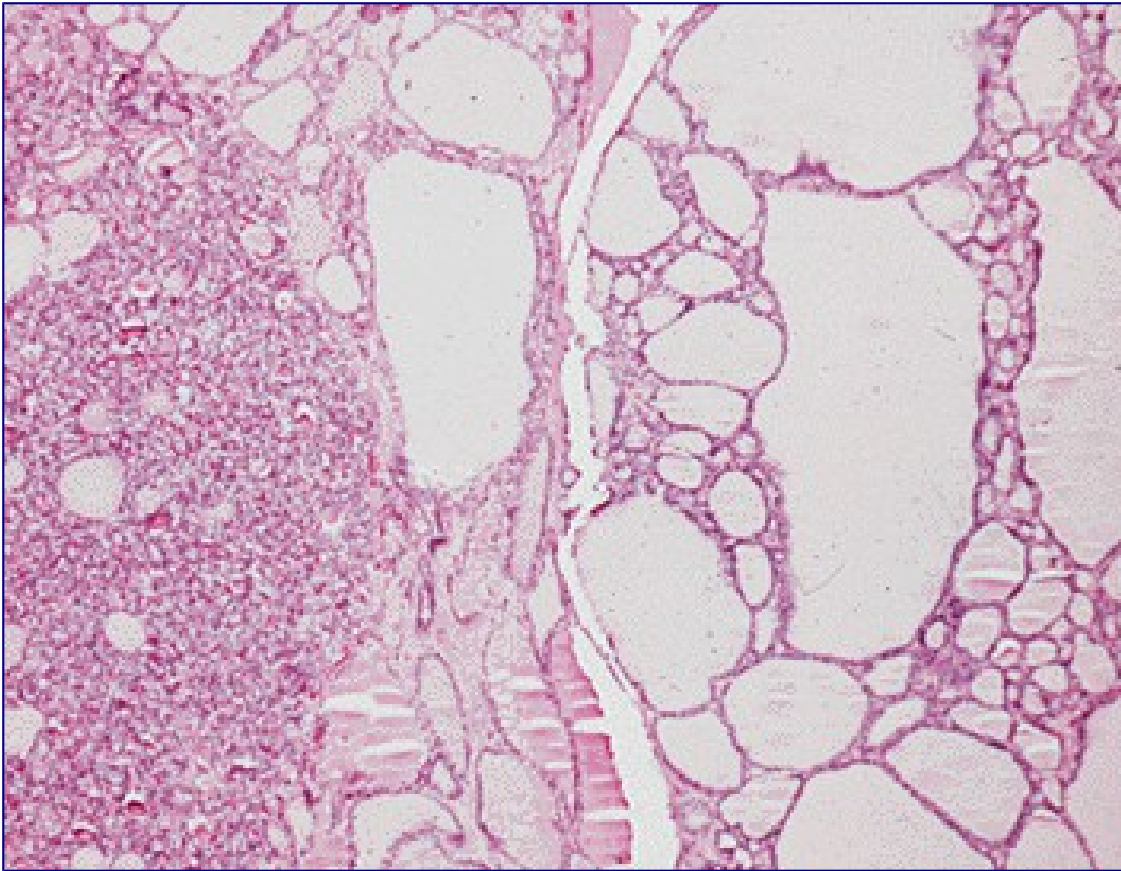


Figure 18-2. B) Possible evolution of a "colloid nodule". An area of nodular hyperplasia on left, and a "developing" colloid nodule on right, with macrofollicles and some remaining focal hyperplasia.

Cause Of Nodules

Thyroid adenomas are monoclonal "new growths" that are formed in response to the same sort of stimuli as are carcinomas. Heredity does not appear to play a major role in their appearance. One clue to their origin is that they are four times more frequent in women than in men, although no definitive relation of estrogen to cell growth has been demonstrated. Thyroid radiation, chronic TSH stimulation, and oncogenes believed to be related to the origin of these lesions are discussed below in the section on thyroid cancer. Of specific interest in relation to benign nodules is the remarkable observation by Vassart and colleagues that activating mutations of the TSH receptor are the specific cause of most autonomously functioning thyroid nodules (3) including those found in the context of a multinodular goiter (4). Please see the discussion on causation under "Carcinoma".

Course and Symptoms of Nodules

Thyroid nodules grow slowly and may remain dormant for years. This is presumably related to the fact that adult thyroid cells normally divide once in eight years. (5) Pregnancy tends to make nodules increase in size, and to cause development of new nodules. The nodule may first come to attention because the patient accidentally finds a lump in the neck or because a physician discovers it upon routine examination. Rarely, symptoms such as dysphagia, dysphonia, or stridor may develop, but it is

unusual for these tumors to attain sufficient size to cause significant symptoms in the neck. Typically, they are entirely asymptomatic. Occasionally there is bleeding into the tumor, causing a sudden increase in size and local pain and tenderness. After bleeding into a nodule, transient symptoms of thyrotoxicosis may appear with elevated serum T4 levels, and suppression of TSH. In the last ten years or so, however, the way of presentation of thyroid nodules is largely changed due to the more and more frequent discovery of thyroid nodule at ultrasound neck examination performed for non-thyroidal indication. These nodules are usually of small size, less than 2 cm, and totally asymptomatic. Consequently, nowadays the most frequent presentation of thyroid nodules is fortuitous and that of clinically noted nodules is decreasing.

M.G., 47-Year-Old Woman: Hemorrhage into a Nodule

When the patient was first examined, enlargement of the thyroid had been known for at least 6 years. A scan showed a cold nodule in the left lobe. The patient was thought to have a thyroid nodule and to be euthyroid. There was on exam a normal right thyroid lobe, and a 4 x 5 cm soft mass occupying the position of the left lobe. The impression at this time was that she had an adenoma that might be cystic. Antithyroid antibodies were not detectable.

The patient was examined by several observers who palpated the thyroid. One-half hour after leaving the clinic, the patient's neck gradually began to enlarge, and she developed pain in the area of the thyroid and a rasping hoarseness. She had no difficulty in swallowing or breathing. The pain was significant enough to keep her awake that night, and she returned to the hospital the next day. The patient was very anxious, and there was a 10 x 12-cm tender fluctuant swelling occupying the area of the thyroid. Inspiratory stridor was present, and there were a few rhonchi in the lungs.

During the subsequent 3 days the pain in the neck gradually diminished, but the size of the mass remained more or less the same. Chest x-ray films revealed marked deviation of the trachea to the right. Operation was elected. A greatly enlarged left lobe of the thyroid was found, with hemorrhage into an adenoma. The encapsulated mass measured 6.5 x 5.5 cm and was smooth and cystic. There was a large multiloculated hematoma and considerable necrotic tissue. A left lobectomy was performed. Microscopic examination showed a microfollicular thyroid adenoma with recent hemorrhage and necrosis. The postoperative course was unremarkable. The patient remained well after surgery without further difficulty.

Usually hemorrhage occurs without known provocation, but occasionally is seen after trauma to the neck. In this instance, palpation may have been sufficient to induce bleeding.

Does thyroid nodule ever develop into a carcinoma? At the practical level, thyroid nodules appear to be benign from the start and most thyroid carcinomas are likewise malignant from their inception, and do not appear on pathological examination to originate in preexisting benign nodules. Perhaps this has to do with the specific discrete mutational event causing their development. However, in animals chronically given ¹³¹I and antithyroid drugs, a gradual progression of types of lesions from adenomas to carcinomas is seen. Pathologic examination occasionally gives evidence for conversion of an adenoma to a carcinoma. Transformation of hyperplastic thyroid tissue into invasive cancer occurs in occasional patients with congenital goitrous hypothyroidism, and occasionally cancers are seen inside an adenoma or in a gland that was known to have harbored a nodule for many years. However some authors : considered follicular adenomas to represent true pre-malignant lesions that may eventually progress to follicular carcinomas upon collection of additional mutational events. Occasionally a patient develops metastatic cancer years after resection of an embryonal, follicular or Hurthle cell adenoma. Rearrangement of the RET gene or BRAF mutations, the genetic abnormalities responsible for a subset of papillary thyroid carcinoma, is frequently found in microcarcinoma, suggesting that this lesion is malignant from the beginning without the need for accumulating several genetic lesions (6).

Furthermore, no case of RET/PTC positive anaplastic cancer has been found up to now, again suggesting that there is no transition from papillary, at least RET/PTC positive, carcinoma to anaplastic cancer (6). However the transition of BRAF positive papillary cancer to anaplastic thyroid cancer has been reported. All of these points suggest that transformation of an adenoma into a carcinoma occurs occasionally, but it appears to be an unusual sequence of events.

Hot Nodules

About 10% of thyroid follicular adenomas are functional enough (are “hot” on scan) to produce overt thyrotoxicosis or subclinical hyperthyroidism (suppressed TSH being the only abnormality) and account for perhaps 2% of all thyrotoxic patients. Another 10% may be borderline in function and are classified as warm or “hot” (or hyperfunctioning, in comparison to the remainder of the thyroid gland) on isotopic scans. Although hyperfunctioning nodules may remain unchanged for years, some gradually develop into toxic nodules, especially if their diameter exceeds 3 cm (7). Others undergo spontaneous necrosis with a return of function in the formerly suppressed normal gland. Patients with functioning autonomous nodules may be overtly thyrotoxic; more commonly, however, the nodule functions enough to suppress the remainder of the gland, but not enough to produce clinical hyperthyroidism (8). In such patients, T3 levels may be slightly elevated, serum TSH below normal, and the pituitary response to TRH is typically suppressed (9). If the nodule is resected, the gland resumes normal function, and serum TSH and the TRH response is normalized (see also Chapter 13).

In certain areas such as Switzerland, up to one-third of all thyrotoxic patients have hyperfunctioning adenomas (10), largely in multinodular glands. Perhaps this situation is generally true in endemic goiter areas.

Activating TSH receptor mutations have been found by Vassart and co-workers (11) to be the cause of most hyperfunctional nodules, and are now known to be common in “hot” nodules in patients with multi-nodular goiter. These mutations generally involve the extracellular loops of the transmembrane domain and the transmembrane segments, and are proven to induce hyperfunction by transfection studies. Mutations of the stimulatory GTP binding protein subunit are also present in some patients with hyperfunctioning thyroid adenomas (12).

Metabolic Function of Nodules

The biochemical defect responsible for diminished iodine metabolism in the “cold” (i.e., inactive) nodule can result from deletion of specific metabolic processes required for hormone synthesis. Slices of cold nodules incubated *in vitro* were unable to accumulate iodide against a concentration gradient, although peroxidase and iodide organification activities were present (13). This finding was consistent with a specific defect of the iodide transport process. Others have also observed this phenomenon and have shown that TSH can bind to the membranes of the cells and activate adenyl cyclase as usual, but that subsequent metabolic steps are not induced (14). Activity of the sodium-potassium-activated ATPase, thought to be related to iodide transport, is intact, and ATP levels are normal, even though iodide transport is inoperative. Other nodules appear to be cold because they lack peroxidase (15). These nodules can be “hot” when scanned with $^{99m}\text{TcO}_4$ due to active transport of the isotope, but relatively cold on scanning at 24 hours after ^{131}I is given, since iodide binding is poor (16). The adenyl cyclase system in the plasma membrane of some hyperfunctioning nodules has been found to be hyper-responsive to TSH in some studies (17) but not in others (18). As noted above, most hyperfunctional nodules are associated with- presumably caused by- activating mutations of the TSH

receptor. All of the foregoing reports suggest that adenoma formation is associated with mutational events that cause loss or dysfunction of normal metabolic activities. The recent cloning of the sodium/iodide symporter gene (NIS) (19) has allowed the study of its expression in thyroid nodules. NIS expression is increased, with respect to normal thyroid tissue, in hyperfunctioning nodules and low or absent in cold nodules both benign and malignant (20).

CLINICAL EVALUATION AND MANAGEMENT OF NODULES

Table 18-2. Differential Diagnosis of the Thyroid Nodule

- Adenoma
- Cyst
- Carcinoma
- Multinodular goiter
- Hashimoto's thyroiditis
- Subacute thyroiditis
- Effect of prior operation or ¹³¹I therapy
- Thyroid hemigenesis
- Stasis
- Parathyroid cyst or adenoma
- Thyroglossal cyst
- Nonthyroidal lesions
 - Inflammatory or neoplastic nodes
 - Cystic hygroma
 - Aneurysm
 - Bronchocele
 - Laryngocele

History of nodules

Conditions to be considered in the differential diagnosis are listed in Table 18-2. They include adenoma, cyst, multinodular goiter, a prominent area of thyroiditis, an irregular regrowth of tissue if surgery has been performed, thyroid hemigenesis, and of course, thyroid cancer. Hashimoto's thyroiditis often presents with a lumpy gland on physical exam, and a nodular or pseudo-nodular appearance on ultrasound is frequent. In some patients Hurthle cell rich nodular areas develop, and of course some patients have coexistent but (presumably) etiologically distinct adenomas or cancers.

Factors that must be considered in reaching a decision for management include the history of the lesion, age, sex, and family history of the patient, physical characteristics of the gland, local symptoms, and laboratory evaluation. The age of the patient is an important consideration since the ratio of malignant to benign nodules is higher in youth and lower in older age. Male sex carries a similar importance (21). Nodules are less frequent in men, and a greater proportion are malignant.

Rarely, the family history may be helpful in the decision regarding surgery. Patients with the hereditary multiple endocrine neoplasia syndrome (MEN), type I, may have thyroid adenomas,

parathyroid adenomas, islet cell tumors, and adrenal tumors, whereas patients with MEN types II, have pheochromocytomas, medullary thyroid carcinomas, hyperparathyroidism, and mucosal neuromas(22-24) (vi). Further, we have observed that 6% of our patients with thyroid carcinoma have a history of malignant thyroid neoplasm in other family members, and familial medullary cancer (without MEN) is well known. Familial thyroid tumors occur in Cowden's disease, Gardner's syndrome, and familial polyposis coli (vi.)

A most important piece of information regarding a nodule is a history of prior neck irradiation. Any irradiation above 50 rads (50 cGrays) to the thyroid during childhood should be viewed with concern. Exposure to 100-700 rads during the first 3 or 4 years of life has been associated with a 1-7% incidence of thyroid cancer occurring 10-30 years later (25-30). Radiation exposure during adolescence or early adulthood for acne or for other reasons has also been identified as a cause of this disease. Although this association was known by 1950, patients were still being seen with radiation-related tumors who received x-ray treatment as late as 1959. Radiation therapy for other benign or malignant lesions in the neck is still in use in selected patients; such exposure will thus continue to be a relevant part of the history. Because of the high prevalence (20-40%) of carcinoma in nodules resected from irradiated glands, the finding of one or more clear-cut nodules in a radiated gland, or a cold area on scan, must be viewed with alarm and requires consideration for a complete diagnostic iter, including FNAC. In this case, multiple nodules do not indicate that the lesions are benign. In contrast, prior exposure to internal radiation from ¹³¹I for diagnostic or therapeutic purposes is not associated with an increased risk of developing thyroid carcinoma.

The history of the neck lump itself is important. Recent onset, growth, hoarseness, pain, nodes in the supraclavicular fossae, symptoms of brachial plexus irritation, and local tenderness all suggest malignancy, but of course do not prove it. The usual cause of sudden swelling and tenderness in a nodule is hemorrhage into a benign lesion. Although the presence of a nodule for many years suggests a benign process, some cancers grow slowly. In our series, the average time from recognition of a nodule to diagnosis of cancer was 3 years. A history of residence in an endemic goiter zone during the first decades of life is also relevant and must raise the possibility of multinodular goiter as the true diagnosis. Although, all the above signs may be important, the most informative tool suggesting the suspicion of malignancy is the ultrasonographic pattern (US). In expert hands, typical features of malignancy are easily recognized (see Ultrasound paragraph).

Physical findings

When palpable, the nodule is typically felt as a discrete lump in an otherwise normal gland, and it moves with the thyroid. Enlarged lymph nodes should be carefully sought, particularly in the area above the isthmus, in the cervical chains, and in the supra-clavicular areas. Their presence suggests malignant disease unless a good alternative diagnosis is apparent, such as recent oro-pharyngeal sepsis or viral infection. Fixation of the nodule to strap muscles or the trachea is alarming. Characteristically a benign thyroid nodule is part of the thyroid and moves with deglutition, but can be moved in relation to strap muscles and within the gland substance to some extent. Pain, tenderness, or sudden swelling of the nodule usually indicates hemorrhage into the nodule but can also indicate an invasive malignancy. Hoarseness may arise from pressure or by infiltration of a recurrent laryngeal nerve by a neoplasm. Obviously the presence of a firm, fixed lesion, associated with pain, hoarseness, or any one of these features, should signal some degree of alarm. The converse situation, the absence of such characteristics, suggests but does not prove benignity. Fluctuance in the lesion suggest the presence of a cyst that is, usually, benign.

The presence of a diffusely multinodular gland, ascertained on the basis of palpation, US, or scanning,

has in past years been interpreted as a sign of safety. Multinodular goiters coming to surgery have a significant prevalence of carcinoma (4-17%), but this finding was believed to be due largely to selection of patients for surgery, and not to be typical of multinodular goiters in the general population (31,32). However, in an era of generalized iodine sufficiency, when multinodular goiters are less common, this opinion needs re-evaluation. Frates et al (32.1) evaluated outcome in 1985 patients who underwent 3483 FNAs. Solitary nodules had the expected higher incidence of cancer than non-solitary nodules. However on a “per patient” basis, patients with MNG had the same incidence of diagnosed cancer (14.9%) as did patients with a solitary nodule (14.8%). Male sex, non-cystic nature, hypo-echogenicity, and stippled calcifications were associated with increased risk of malignancy per nodule. Usually FNA has been recommended for dominant or growing nodules. Frates et al recommend that for exclusion of malignancy in a thyroid with multiple nodules larger than 10mm, up to four nodules should be considered for FNA, and that the risk factors noted above may guide selection of nodules for biopsy.

Occasionally the gland has, in addition to a nodule, the diffuse enlargement and firm consistency of chronic thyroiditis, a palpable pyramidal lobe, and antibody test results that may be positive. These findings strongly suggest thyroiditis but do not disclose the nature of the nodule, which must be evaluated independently. It should be remembered that 14 – 20% (30, 33) of thyroid cancer specimens contain diffuse or focal thyroiditis. In addition, a positive association of thyroid cancer and Hashimoto’s thyroiditis has been reported, but is not proven (v.i.).

Thyroid function tests

The patient is usually euthyroid, and this impression is supported by normal values for the serum FTI and T3 levels. Thyrotoxicity produced by an adenoma is discussed below. Low free thyroid hormones or elevated TSH results should raise the question of thyroiditis.

Curiously, it has been observed and confirmed that there is a direct correlation between TSH levels in patients with nodules and the risk of thyroid malignancy, and also with the degree of aggressiveness of the tumor (33.1)

The serum TG concentration may be elevated, as in all other goitrous conditions, and therefore is not a valuable tool in differential diagnosis. Soft tissue x-ray films of the neck may disclose indentation or deviation of the trachea if the tumor is more than 3 or 4 cm in diameter. Fine, stippled calcifications through the tumor (psammoma bodies) identified at thyroid US are virtually pathognomonic of papillary cancer. Patchy or “signet ring” calcification occurs in old cysts and degenerating adenomas, and has no such connotation.

Calcitonin assays

Although MTC constitutes a small fraction of thyroid malignancies, and an even smaller proportion of thyroid nodules, several reports suggest that routine screening of nodular goiters by CT assay is an appropriate approach (34-37). The issue of serum Calcitonin (CT) measurement is controversial. While European authors recommend screening of any thyroid nodule by serum CT as a clue to the pre-operative diagnosis of unsuspected MTCs based on robust prospective clinical trials, this concept has not been agreed by American authors. The recent American Thyroid Association guidelines for thyroid nodules and cancer state that it is not possible to recommend in favour or against serum CT measurement in the diagnostic work up of thyroid nodules (37.0) . Such screening offers the possibility of finding tumors before they have metastasized, and MTC is rarely found on FNA. Whether the

considerable expense is justified is yet indeterminate. While calcitonin levels above 60 typically signal the presence of MTC, abnormal levels between 10 and 60 may be present with C-cell hyperplasia or no objective abnormality, and may spontaneously normalize(37.1). Of course serum CT measurement it is recommended whenever there is a clinical or cytological suspicion of MTC or when the patient has a familial history of MTC.

Thyroid Ultrasound

It is accepted practice to perform ultrasound examination of all thyroid nodules as the first study, or in conjunction with FNA. Good technique demonstrates nodules if more than 3 mm in size, indicates cystic areas, may demonstrate a capsule around the nodule, and the size of the lobes. (Fig 18-10) It often displays multiple nodules when only one is noted clinically. The technique is more sensitive than scintiscanning, is noninvasive, involves less time, allows serial exams, and is usually less expensive. From 3-20% of lesions are found to be totally or partially cystic. Purely cystic lesions are reported to have a lower incidence of malignancy than solid tumors (3% versus 10%), and diagnosis of a cyst raises the possibility of aspiration therapy (52). Mixed solid and cystic lesions allegedly have a higher frequency of malignant change than either pure cysts or solid lesions. While US can not diagnose malignancy, certain features such as irregular borders of the nodule, lack of a “halo”, hypoechogenicity, evidence of calcium flakes, marginal nodules in a cyst, increased blood flow, and growth on serial ultrasounds, are suggestive signs. Schlumberger and coworkers found that cystic appearance, hyperechoic punctuations, loss of hilum, and peripheral vascularization were major ultrasound criteria of lymph node malignancy. LNs with hyperechoic punctuations are highly suspicious of malignancy. LNs with a hyperechoic hilum should be considered benign. Peripheral vascularization has the best sensitivity-specificity compromise. Round shape, hypoechogenicity, and the loss of hilum taken as single criteria are not specific enough to suspect malignancy (52.1). Ultrasound gives also valuable information on the extranodular thyroid tissue, that may be useful for the differential diagnosis: a typical pattern of diffuse hypoechogeneity is almost synonymous with autoimmune thyroiditis (53).

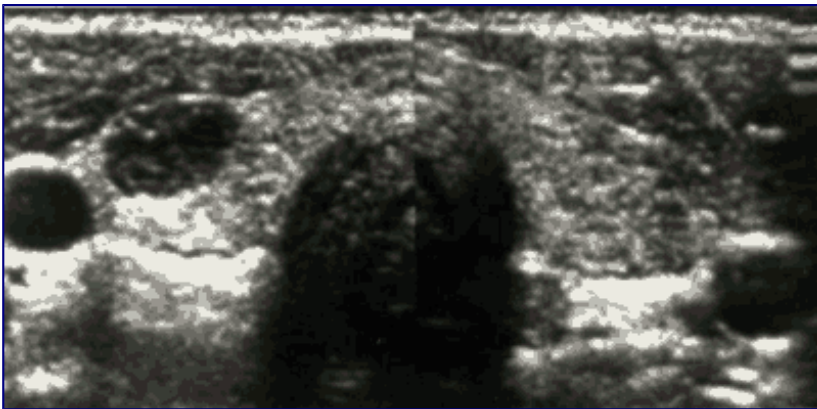


Figure 18-10. Ultrasooigraphic examination by transverse image of the thyroid containing a solid nodule in the right lobe and a homogeneous appearance of the left lobe. The structure peripheral to the nodule is the internal jugular vein.

A current problem is the proper way to manage thyroid nodules found incidentally on ultrasounds or CAT scans done for other purposes. As noted above, US-detectable nodules are present in a large proportion of all adults- perhaps 20 % as an average figure. If these are actually palpable, they fit into the schema just outlined. Whether to do US guided FNA on all non-palpable nodules, those generally smaller than 1cm and often as small as 3-5mm, is a question not clearly answered. Many patients request biopsy because they are anxious about the problem. Some studies have indicated that the

incidence of carcinoma in these clinically non-detectable nodules is effectively the same as in larger nodules. At present our operational approach is to attempt biopsy in nodules 5-10 mm in size, and base treatment on the results. In smaller nodules or those judged very difficult to sample, the patient is advised to have repeated follow-up by exam and US at 6-12 month intervals. In a study of this problem by Papini et al (NR2), 7% of nodules under 1 cm in size were found to harbor carcinomas. These authors believe that FNA is generally indicated, and especially if the nodule is solid and hypo-echogenic, has irregular margins, intranodular vascular spots, or microcalcifications.

A new extension of thyroid US is represented by thyroid elastosonography (ES). This technique is based on the information given by the study of the elasticity of the nodule transmitted to a probe similar to the one used for US. Benign nodules have usually higher elasticity than malignant ones and, in recent reports (53.1-53.2), it has been shown that the grade of elasticity correlated with a correct diagnosis with very high sensitivity and specificity.

Isotope Scans

The scintiscan received much attention in the past as an aid in the differential diagnosis of thyroid lesions (Chapter 6). The scan can provide evidence for a diagnosis in a multinodular goiter, in Hashimoto's thyroiditis, and rarely in thyroid cancer when functioning cervical metastases are seen. If the scan demonstrates a hyperfunctioning nodule suppressing the remainder of the gland, and the patient is thyrotoxic as demonstrated by an elevated serum FT4 or FT3 level, or suppressed sTSH, the chance of malignancy is very low. Tumors that accumulate RAI in a concentration equal to or greater than that of the surrounding normal thyroid tissue, but that do not produce thyrotoxicosis, are also typically benign (54, 55). In fact, some observers insist that functioning nodules cannot be malignant (55), in spite of reports of malignant change in occasional warm or hot nodules (55-59). Malignant tumors usually fail to accumulate iodide to a degree equal to that of the normal gland. However, most cold nodules turn out to be benign adenomas and cysts, not cancers. (Figure 18-3, below) The reported incidence of cancer in cold nodules is highly variable; a review of 400 cases found 10% to be cancer (60), and this experience is typical. Tumors smaller than 1 cm in size are below the discriminating power of most of the available scanning devices. Thus, a nodule 1 cm or less in diameter that fails to collect RAI (cold nodule) might not be delineated at all on the scintiscan. Further, many nodules turn out to be neither cold nor hot (preferential isotope accumulation); rather, they accumulate RAI in approximately the same concentration as the surrounding thyroid tissue. Normal tissue in front of or behind the nodule may also accumulate isotope and in this way obscure a deficit in collection within the lesion itself. For all of these reasons, it is our impression that the thyroid scintiscan has value, but except for the clearly toxic nodule, does not form an absolute predictor as to whether a palpable nodule is malignant or benign. Usually pertechnetate scanning provides the same information as RAI scanning, but exceptions occur. The first-line diagnostic procedures consist of ultrasound and TSH measurements. Thyroid scan is applied only when serum TSH is low or suppressed to confirm the presence of an autonomously functioning nodules.

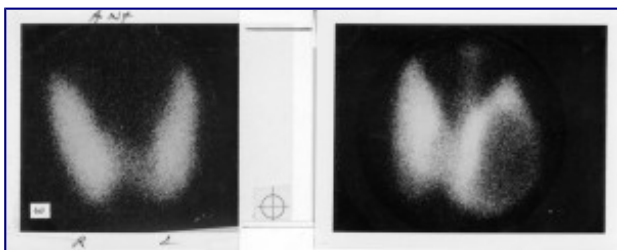


Figure 13-3. Scintiscans of thyroid. The scan on the left is normal. A typical scan of a "cold" thyroid

nodule failing to accumulate iodide isotope is shown on the right. Incidentally, a pyramidal lobe is also seen on this scan, which might suggest the presence of Hashimoto's Thyroiditis.

Several alternative isotopes, such as selenomethionine, radioactive phosphate, gallium, and technetium-labeled bleomycin, have been introduced for scanning, but none has proven to give clear cut evidence of malignancy or to be diagnostically superior to FNA. The same is true for other imaging techniques such as thyroid thermography, CT scan or MRI. All these techniques should not be used in daily clinical practice. Interestingly, fluorodeoxyglucose-PET scanning for other purposes occasionally turns up a hot spot in the thyroid.. On examination these thyroid nodules have a high rate of malignancy (61).

Fine needle aspiration cytology

For many years core needle biopsy of the thyroid was employed successfully in some clinics to provide a histologic diagnosis on which to base therapy (38). Difficulties in acceptance of the procedure by surgeons, patients, and pathologists prevented its widespread application. As an alternative technique, thin needle aspiration cytologic examination has been widely adopted after favorable reports by Walfish et al (39) and Gershengorn et al (40). The procedure is technically simple and acceptable to patients, but requires an experienced operator and collaboration with a skilled cytopathologist (Figure 18-4). Two to four aspirations of the nodule, in different areas of the nodule, are recommended by many expert cytologists, particularly when the nodule is large enough (41). One common technique for sampling the whole nodule, is to introduce the needle in the center of the nodule, aspirate and then move the needle in another direction and aspirate again. FNA should always be performed under US-guide.

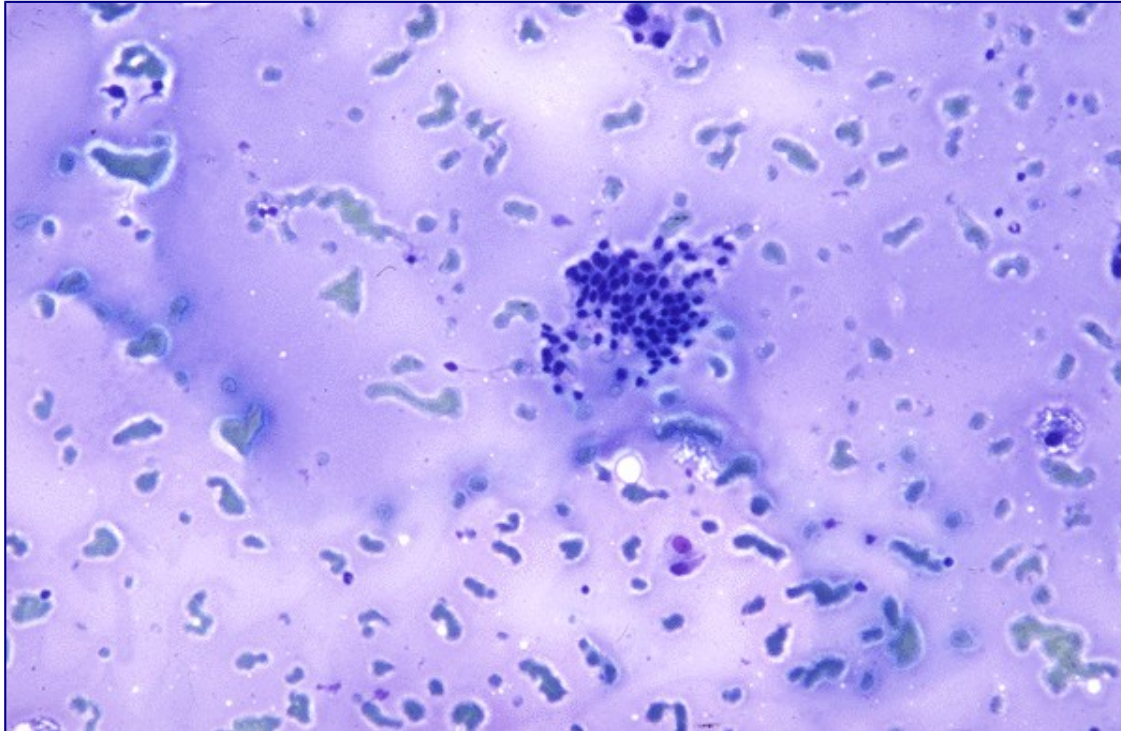


Figure 18-4a. Fine needle aspiration cytology specimens. (A) Benign epithelial cells, colloid, and occasional macrophages, typical of a "colloid nodule".

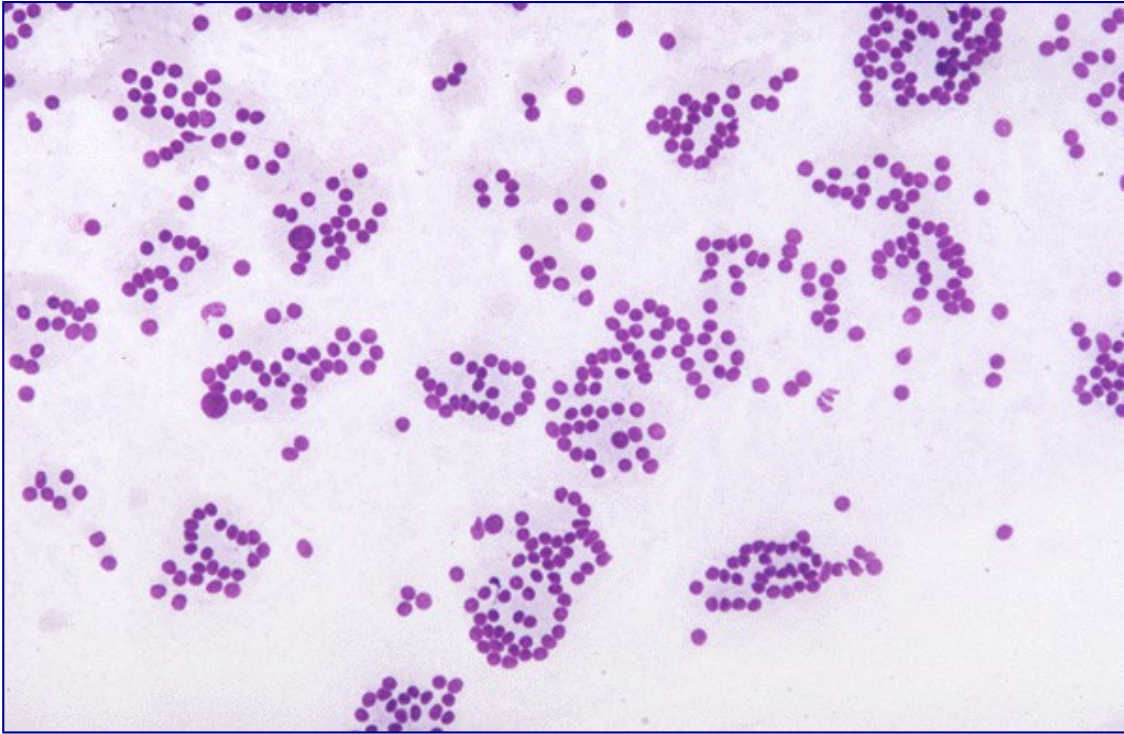

Figure 18-4b. Fine needle aspiration cytology specimens. (B) Epithelial cells in a follicular arrangement suggesting adenoma, but which could be from a follicular carcinoma.

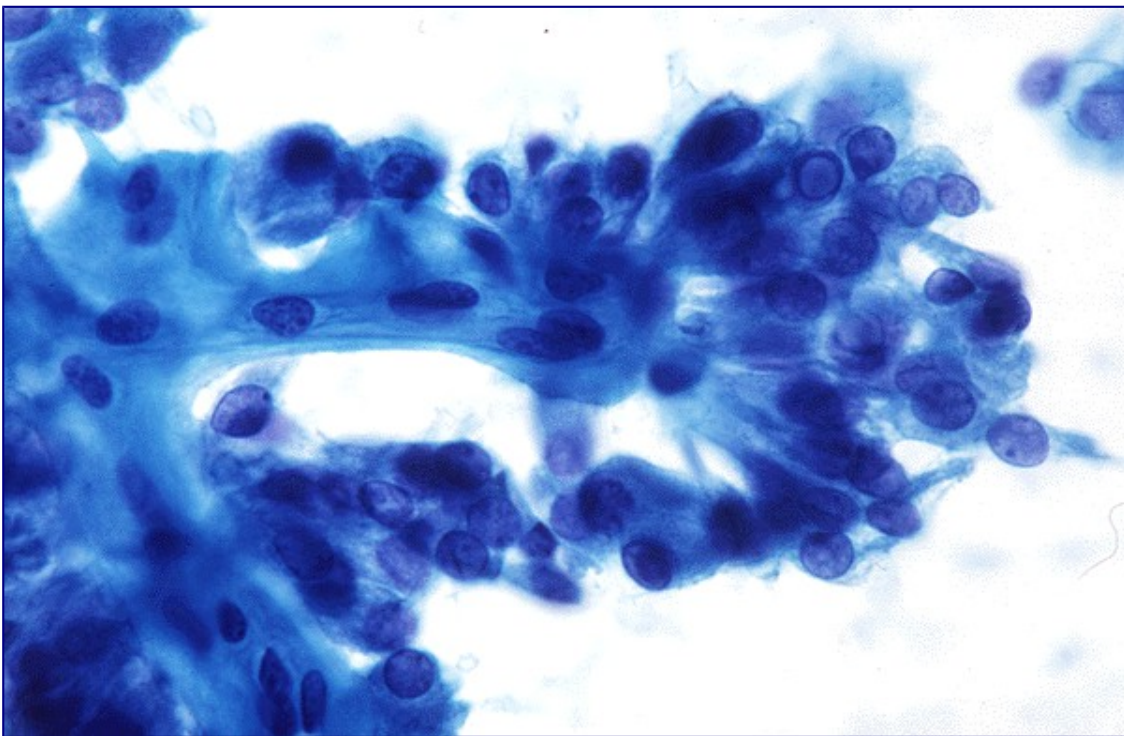


Figure 18-4c. Fine needle aspiration cytology specimens. (C) Epithelial cells in a papillary formation from a papillary thyroid carcinoma. Nuclear grooves are also apparent. (Courtesy of Dr. Richard

DeMay, University of Chicago/Chicago Lying-in Hospital)

Significant complications such as bleeding, infection, induced necrosis, or cyst formation are rare. Surprisingly the release of thyroglobulin into the blood stream appears to induce development of anti-thyroxine antibodies, of IgG or IgM class, in some (2-20%) patients, especially those with prior evidence of autoimmune thyroid disease (42). Adequate specimens can be obtained in over 90% of patients. False-negative and false-positive diagnoses do of course occur, but are each under 5% with experienced hands. Willems and Lowhagen (43), in reviewing a collected series of nearly 4,000 surgically proven fine needle aspiration studies, found that 11.8% were considered to be malignant lesions. False-negative diagnoses of cancer were made in 6.6-27.5% and false-positive diagnoses in only 0-2%. Currently the results of FNA are viewed as the “gold standard” for diagnosis in most cases, and play a crucial role in the selection of patients for operation. Gharib and co-workers recently analyzed data on 10,000 FNAs, and found the procedure to be the preferred first step in diagnosis (44). The diagnostic accuracy was nearly 98%, with under two percent false positives and false negatives. Miller et al.⁵² compared fine needle aspiration, large needle aspiration, and cutting needle biopsy. They found fine needle aspiration cytologic examination was able to detect almost all carcinomas, but believe that cutting needle biopsy is a useful additional procedure, especially in larger (over 2-3 cm) nodules. A word of caution comes from a study by Tee et al, who reviewed published studies and concluded that FNA may miss up to a third of all thyroid malignancies (44.1)

A particular problem is posed when cytology discloses a follicular proliferation or a Hurthle cell proliferation. FNA cannot differentiate follicular adenoma from follicular carcinoma, since this distinction can only be based on the presence of capsular or vascular invasion, which cannot be detected on a cytologic smear. In these cases, the histological verification of the lesion is mandatory, even though only 10-20% of nodules with follicular histology are proven to be malignant. An additional indication for FNA is the diagnostic evaluation of extra-thyroidal neck masses, especially lymph nodes, both at presentation and when the diagnosis of thyroid carcinoma has already been established. In these cases FNA may be integrated with the measurement of thyroglobulin content in the liquid recovered after washing the needle. If the lesion is metastatic from a differentiated thyroid cancer, thyroglobulin concentrations are very high (45).

In our practice, 5-8% of aspirates are found diagnostic of malignancy, 10-20% are considered suspicious (including those with follicular proliferation) but not diagnostic, 2-5% fail to provide an adequate specimen, and the remainder are considered benign, usually suggestive of a “colloid nodule” or thyroiditis. An inadequate specimen should lead to reaspiration. In a recent review of 153 patients with nondiagnostic FNAs, 60 patients had reaspiration. Of these 38% remain nondiagnostic. Of the group that went to operation, 37% had a malignancy. The authors conclude that nondiagnostic FNAs should not be considered benign, and that reaspiration, if uninformative, should be followed by selective surgical treatment (46). Non-palpable nodules can be biopsied under ultrasound guidance. Non-palpable thyroid nodules, typically < 1 cm in size, are usually non-malignant. It is uncertain whether ultrasound guided fine needle aspiration biopsy is appropriate in these individuals. However, considering that 4% are reported to be papillary cancers when diagnosed under ultrasound guidance, probably most careful physicians will elect to do such a biopsy, if possible (47). Of course a positive diagnosis of cancer leads to surgery. We, as others, tend to operate on patients with suspicious FNA histology, since about 25% prove at surgery to be malignant. In the remainder, continued observation and suppressive thyroxine therapy are offered (v.i.). Patients who are not operated are seen at 6 or 12 month intervals, and examined for any sign such as pain, growth, hoarseness, or nodes that might indicate a change in the character of the tumor. Patients are usually re-biopsied after 2-3 years and again after 5-8 years to document the benign nature of the lesion. The outcome of reaspiration of benign nodular thyroid disease was investigated by Erdogan et al in studies on more than 200 patients

(48). Three of 216 patients had a diagnosis changed from benign to papillary carcinoma at the time of the second biopsy. The authors conclude that a second aspiration of clinically suspicious nodules can correct some initial false negative results, but routine reaspiration was not useful in clinically stable disease. A variety of techniques have been applied to improve accuracy of interpretation of FNA cytology or histology.

Genetic Diagnosis- There is great current interest in demonstrating expression of individual or multiple mutated genes, or mRNA expression patterns, that are diagnostic of a specific type of adenoma or cancer. This field is evolving rapidly. The MUC1 gene, and telomerase activity, are highly expressed in carcinomas rather than in adenomas in operative specimens (49, 50). Overexpression of cyclin D1 and underexpression of p27 predict metastatic behavior in papillary nodules (51). Expression of c-MET, galectin, VEGF, cathepsin B, thymosin, and HMG1 has been correlated with increased probability of malignancy. Dipeptidyl aminopeptidase IV activity is almost universally present in follicular carcinomas, and usually negative in adenomas(51a). In several studies (51.1-51.2-51.3) screening FNA samples for mutated BRAF, RAS, RET/PTC and PAX8/PPRgamma, was found to greatly improve diagnostic accuracy of FNA samples. Search of BRAF V600E mutation alone is not sufficient to improve the diagnostic accuracy of FNAC, since it cover only 40% of papillary thyroid cancer. Search of all known mutations should be performed. Nikiforev et al found that in each of the indeterminate categories (using the Bethesda classification, atypia of undetermined significance/follicular lesion of undetermined significance, follicular or oncocytic Hurthle cell neoplasm, and suspicious for malignant cells, addition of the mutation screening changed diagnostic accuracy from 14-54%, up to 88-95%. Similar results have been reported by Cantara et al. in a large surgical series. Diagnosis by determining expression of relevant genes using gene microarray technology logically should be informative, since expression profiles of hundreds of genes can be analyzed at one time. Studies using the methodology on samples derived from FNA are currently being reported, although none has as yet reached practical clinical utility. Durand et al analyzed the level of expression of 200 potentially informative genes in 56 thyroid tissue samples (benign or malignant tumors and paired normal tissue) using nylon macroarrays. Expression patterns of a series of 19 genes allowed discrimination between follicular adenomas+normal tissue, from follicular thyroid and papillary thyroid carcinomas. The procedure is believed applicable to the material collected by FNAB, but needs testing in a prospective study (51b). Mazeh et al evaluated quantitative polymerase chain reaction analysis of a set of microRNAs from FNA samples, and reported near 100% specificity and positive predictive accuracy Other researchers have suggested that expression level of 3 genes (PCSK2, PLAB, CCND2) could distinguish benign from malignant FNA biopsy specimens, but this has not been confirmed (51c). Basically, we still wait a proven genetic diagnostic technique that can be applied to FNA samples with perfect reliability and accuracy. However screening for mutated BRAF, RAS, RET/PTC and PAX8/PPRgamma, has already successfully become a part of routine examination of thyroid nodule cytology in some clinics.

The Decision for Surgery

All thyroid nodules once discovered should undergo a complete diagnostic evaluation, regardless of the presenting manifestation or size. This allows the selection of patients with nodules that are malignant or suspicious of malignancy and therefore eligible for surgery. In addition, surgical treatment may be needed for some benign nodules, either single or associated with multinodular goiter, when they are large or associated with signs and symptoms of compression, discomfort, or for cosmetic concerns. All the other nodules are candidates either for medical therapy or simply follow-up with no therapy. A simple and practical flow-chart for the management of thyroid nodules, based on the results of the diagnostic evaluation is offered in Table 18-4.

What is the prognosis, with or without treatment, for these thyroid malignancies? The majority are papillary or mixed papillary-follicular tumors, with fewer pure follicular and rare solid or anaplastic carcinomas. In general, the death rate due to thyroid carcinoma, 5-6 per 10-6 persons per year in the USA in reported by the SEER program and possibly 6/million/year indicated recently, is approximately 5% of the incidence rate of 110 per million people each year (62, 63, <http://seer.cancer.gov/statfacts/html/thyro.html>). (Incidence rates are 160/10-6 women and 56/10-6 men) Although it would be comforting to believe that the difference between the incidence and death rates is due to the effectiveness of surgical and medical therapy, it also reflects the remarkable benignity of many of these tumors. Some patients carry them throughout their lives and die from other causes. Although no controlled series is available, it seems obvious that some carcinomas that occur first as nodules will cause death. About all that can be stated with certainty is that some patients do die from thyroid carcinoma, and that if the surgeon removes a nodule that is really an invasive tumor before it has metastasized, or while it is still under the control of the defense mechanisms of the body, a cure is effected.

Therapy for Nodules (Table 18-3,18-4) (Figure 18-13)

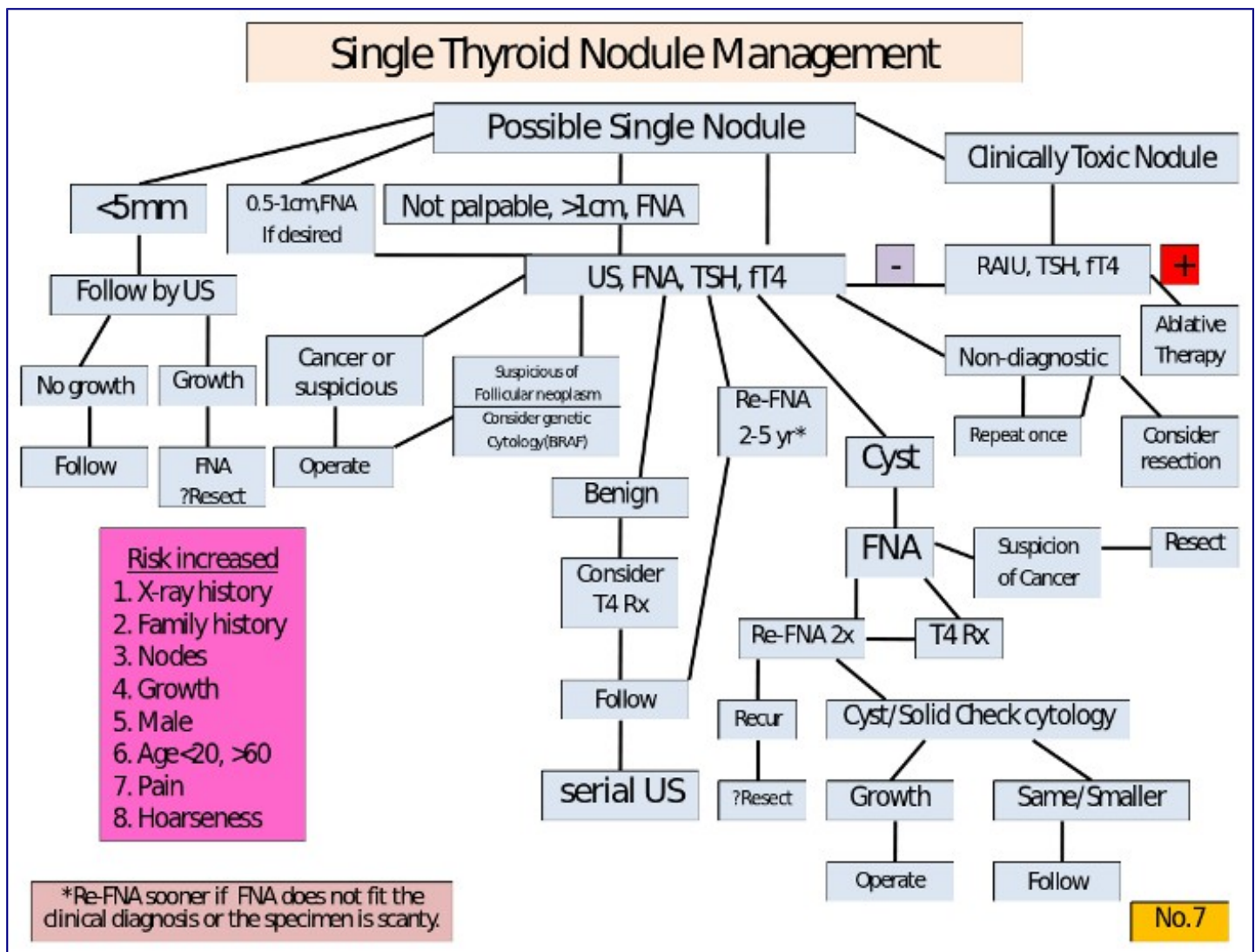


Figure 18-13. Diagnostic sequence and therapeutic decisions in managing a patient with an apparent single nodule of the thyroid.

Toxic Nodules

Three therapeutic options are available for toxic nodules: surgery, ¹³¹I therapy and ethanol injection. Antithyroid drugs can be used if necessary prior to definitive therapy, for example during pregnancy. Radioiodine is a very effective therapy and is becoming the treatment of choice in most patients over 25 years of age and particularly in older patients and those with coincident serious illness, because of its ease and convenience, slightly lower expense, avoidance of a scar, and avoidance of hospitalization. The activity of ¹³¹I to be administered will depend on the size of the nodule and usually ranges between 185 and 740 MBq (5-20 mCi). Euthyroidism and a variable shrinkage of the nodule are obtained in most patients. When one single dose is ineffective, the procedure may be repeated. With time, hypothyroidism may develop in up to 30-40% of the patients, since the remainder of the gland receives 1,000-8,000 rads (64). Hypothyroidism is more frequent in patients with positive anti-thyroid autoantibodies prior to therapy (59a). Further, the patient receives 30-60 rads of whole body irradiation (65). Although, in theory, this radiation could induce cancer formation, this has not been reported.

Surgery is indicated for large nodules, particularly when they have a large cystic component, in very young patients (although rare) and in those refusing radioiodine therapy. Surgery consists of a total lobectomy and must be performed after restoration of a normal thyroid function by antithyroid drugs. Also after surgery, late hypothyroidism is common (30-40% in our experience), while the occurrence of surgical complications is nearly absent in the hands of experienced surgeons.

The third option for the treatment of toxic or pre-toxic nodules, ethanol injections, has been proposed by Italian authors (66, 67). The procedure consists in percutaneous intra-nodular ethanol injection, which induces cellular dehydration followed by coagulative necrosis and vascular thrombosis and occlusion. Volumes of .4 – 2 ml are injected, and patients may receive up to 9 or more treatments at intervals of several days. The technique requires a well-trained staff. Transient, sometimes severe, local pain is the most frequent side effect, followed by transient fever, and occasionally transient dysphonia. Long term follow-up studies have shown that the rate of recurrence is limited to a few patients, and almost no patient developed hypothyroidism (68). However, in our opinion, this therapeutic option should be limited to highly selected cases, such as small nodules, well accessible to palpation, in patients at surgical risk or refusing radioiodine. Small autonomous functioning thyroid nodules, without thyrotoxicosis, can be left untreated and followed. Nearly 30-40% will eventually evolve into toxic nodules (69), but many may stay as they are or even undergo spontaneous cystic degeneration.

Cysts

Cystic lesions are aspirated and often reaspirated one or more times. Possibly long-term suppression with thyroid hormone tends to prevent recurrence, although this outcome is uncertain (70). If, after repeated aspiration, the lesion is still clearly evident, it must be considered a mixed solid/cystic lesion and probably should be resected. Cytologic examination of the aspirated fluid should be done, but the specimens are often not satisfactory for diagnosis. Some physicians attempt to sclerose cysts by aspirating fluid, and then reinjecting one-half volume of a 10/1 mixture of saline and an injectable form of tetracycline containing 100 mg/ml of the drug. Care must be taken to avoid subcutaneous leakage which is very painful. The technique is not widely used, but is reported to be effective (71).

Sclerotherapy by ethanol injection is an other promising method of treatment for thyroid cysts. A major reduction in cyst volume, with very low rate of recurrence has been reported in two recent publications (72, 73). Large cysts (over 40 ml volume) can also be treated by ethanol injection in several sessions with > 50% reduction in size in most cases (74).

Solid nodules

Solid, mixed, functioning, or “cold” nodules constitute the remaining group and indeed the majority of cases. Here major reliance is placed on aspiration cytology. If the results are positive for carcinoma, resection is offered. If no specimen is obtained, reaspiration is performed. If the specimen is suspicious, reaspiration or resection is mandatory. Usually “suspicious” cytology and follicular proliferation leads to resection, since about 25% of nodules with this cytological picture are carcinomas at final pathology

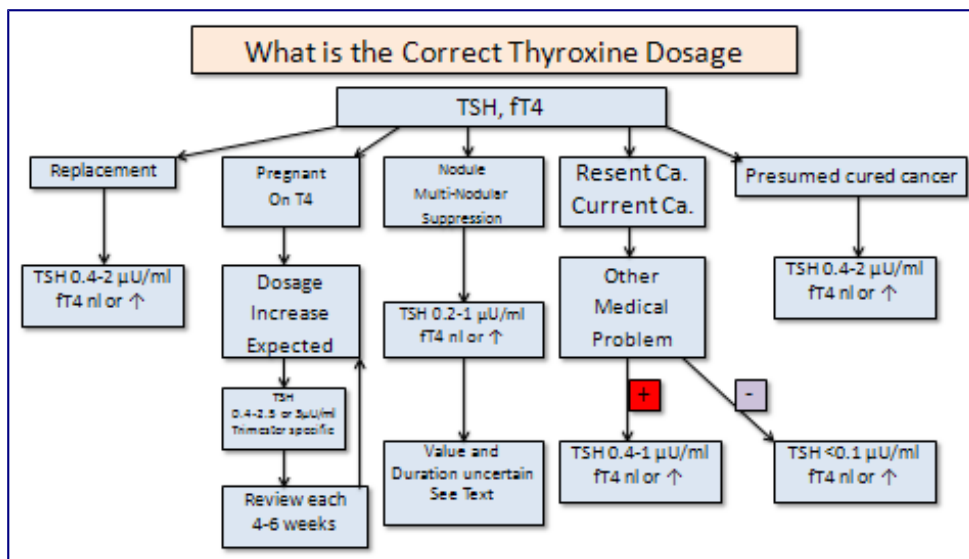
Table 18-3. Factors to be Considered in Management of Cold Nodules

History	Physical Examination	Laboratory tests
Radiation	Size	FTI

Age	Fixation	Antithyroid antibodies
Sex	Cystic nature	TG
Duration	Tenderness	Chest Xray film
Local Symptoms	Adenopathy	Fine needle aspiration
Growth	Diffuse/local process	Ultrasound scan
MEN Syndrome	Vocal cord paralysis	?) Isotope scan
Thyrotoxicity	Single vs multiple	?) Xray soft tissues of neck
Geographic residence		
Family History		

Thyroxin treatment

If a benign result is obtained on cytologic examination, the patient is followed intermittently and may, or may not, be given mildly “suppressive” doses of thyroxine. There is no unanimity on the value of this treatment, and many endocrinologists do not believe thyroid therapy is useful. However solid evidence for the value (modest) of the treatment, and lack of problems, is gradually accumulating. Patients are given thyroxine in a dose adjusted to keep TSH in the minimally depressed range — e.g. 0.1-0.3 $\mu\text{U/ml}$. (Fig. 18-17, below) It is recognized that the efficacy of this treatment to shrink nodules is modest, but it does appear to reduce the size of 10-20% of the lesions (75-79), may prevent further growth, and keeps patients under observation.. Meta-analyses of studies on thyroid hormone suppressive therapy for solitary thyroid nodules were presented by Castro et al (80) and Zelmanovitz et al (81). A 50% reduction in nodule volume was found in 17% more of T4-treated patients than those left untreated, and nodule volume increased more than 50% in a larger proportion of untreated patients. Nodules which are recent, small, colloid or showing degenerative changes at cytology are those more prone to respond to thyroxin treatment (82,83). An almost identical result (84) was found in a randomized, double-blind, placebo controlled study done by a group of French clinicians, who also noted that thyroxin treatment dramatically reduced the number of newly recognized nodules during follow-up. Sdano et al (83a) did a meta-analysis of 9 randomized studies, with 609 subjects. Subjects were 88% more likely to experience >50% nodule volume reduction with THST than placebo or no treatment (relative risk = 1.88; 95% CI = 1.18-3.01; P = 0.008). However studies with follow-up after thyroxine withdrawal demonstrate rapid increase in thyroid nodule and goiter volumes, and these authors did not advise routine use for benign nodules. Age is also important in the selection process. We prefer to treat young adult patient up to 60 years of age. In older patients therapy must be considered on an individual basis, after excluding other underlying chronic diseases, such as heart problems. If a patient is already on L-T4 and has a good compliance with no side effects, treatment may be continued after 60 years, slightly reducing the daily dose. In case of multinodular goiter, a condition frequently associated with intra-glandular areas of functional autonomy, particular attention should be paid to the TSH pre-treatment level. If this is already in the low-normal range, as frequently seen, it is advisable to start l-T4 at very low daily doses (25 $\mu\text{g/day}$), increasing the dose gradually according to the TSH modifications, to avoid iatrogenic thyrotoxicosis. The level of hormone replacement is chosen in the belief that it is unlikely to cause symptoms of hyperthyroidism, such as palpitations, and unlikely to cause osteoporosis, even with prolonged use, while presumably does reduce growth stimulation to the nodule. The usual l-T4 dose is 1 and 2.0 $\mu\text{g/Kg/day}$, to be administered in the morning and while fasting. The appropriate dose should be checked by measuring FT3 and TSH, 3-4 months after its institution. Normal free T3 values exclude significant over-treatment, even when FT4 is in the upper limit of normal.



It is not appropriate to maintain postmenopausal women, on doses of hormone that produce even mild hyperthyroidism for a long period, in view of the potential induction of osteoporosis and arrhythmias. However it should be noted that prolonged suppression of TSH to about 0.1uU/ml by T4 doses just above physiological in premenopausal women does not appear to induce bone loss, nor is it certain that this therapy increases fracture risk in older women (85). Serum TG is usually measured at each visit. Suppression of TG to a normal level by T4 therapy is a gratifying and reassuring response, and is correlated with nodule shrinkage (86). Progressive elevation suggests resection should be considered.

Patients receiving thyroxin therapy, or not, are followed indefinitely at 6- to 12-month intervals, and future management varies with the patient's course. Adverse factors to be noted include growth, development of local symptoms, or adenopathy. In all patients under age 25, all men, and those with a history of neck irradiation, any change usually constitutes grounds for resection. In women 25 years of age and up, the situation should be carefully reviewed and reaspiration performed. If the changes can be explained in the context of a benign process and the reaspirate is benign, continued careful medical follow-up is acceptable, but operation will often be preferred by the patient or physician. The desired course in follow-up is for a gradual reduction and disappearance of the offending lesion. Although this result occasionally is seen, most often the lump remains the same or a bit smaller and persists year after year.

Table 18 - 4. Management of Nodules

Thyrotoxic hot nodule	Lobectomy, or 131I therapy, or (?) sclerotherapy
“Mainly cystic”	Aspirate for Dx and therapy; reaspirate as needed; T4 therapy; resection; (?) sclerotherapy <ul style="list-style-type: none"> • Aspiration cytology – Probable cancer — operate • Inadequate specimen — reaspirate • Suspicious or hypercellular — operate
Other nodules	<ul style="list-style-type: none"> • Benign—follow with/with out T4 therapy and periodic exam , US, and FNA.

Surgical resection

The most important requirement for surgery is the selection of an experienced surgeon in an institution with an adequate Department of Pathology. The patient is occasionally pretreated for several weeks with of thyroid hormone to suppress the normal thyroid and thereby better delineate the nodule from the normal gland. The surgeon should be prepared to do a lobectomy if the lesion is benign, or a more extensive operation and appropriate lymph node removal if, from the operative findings and examination of frozen sections, it is malignant. If the lesion is described as a hypercellular follicular adenoma, we feel it is best to do a lobectomy and contralateral subtotal lobectomy. Many of these lesions turn out on final pathology to be malignant, and reoperation is then avoided.

The first operation is the time for definitive surgery. Although a surgeon with limited experience in neck surgery can remove a thyroid nodule, an adequate near-total thyroidectomy and modified radical neck dissection requires experience, if damage to the recurrent laryngeal nerves or induction of hypoparathyroidism is to be avoided. In this day of specialization, patients deserve a surgeon who has more than a casual interest in the field. Indeed, in the absence of such surgical skill, medical therapy may offer significantly fewer problems for certain patients with nodules than those arising out of inadequate surgery.

Lobectomy for benign solitary adenomas is a relatively harmless procedure. The incidence of death, recurrent laryngeal nerve paralysis, or permanent hypoparathyroidism should be zero. It is less of a procedure than is subtotal thyroidectomy for Graves' disease. Only 1-2 days are required in the hospital, and currently some surgeons do thyroid lobectomy as an "outpatient" procedure.. Post-operative morbidity is slight and transient, and the cosmetic appearance is almost always satisfactory. Complications increase if a carcinoma is discovered, and thyroidectomy and node dissection are required. However, this risk is more than balanced by the benefits (87), since long-term survival after surgery for intrathyroidal or locally metastatic thyroid carcinoma is almost equal to that of the "normal" population.

A satisfactory outcome often depends on a pathologist competent in thyroid histopathology. Occasionally the difficulty of interpreting frozen sections will lead to thyroidectomy for a tumor that is ultimately classified as benign. Performance of an occasional unnecessary thyroidectomy is not a serious problem in the hands of a surgeon who has few operative complications. On the other hand, reoperation at a later date for cancer erroneously diagnosed at initial surgery as benign is all too often required, and does not offer the patient the best chance of operative cure and freedom from operative complications.

After operation many thyroidologists favor treating patients with long-term replacement therapy with thyroid hormone. Although the recurrence of "solitary" nodules is infrequent, replacement therapy is safe, inexpensive, and probably provides some protection. There is no general agreement on this point. We note that thyroxin treatment has been shown to decrease recurrence of nodules in patients operated for thyroid disease induced by childhood irradiation (88).

Occasionally, when the patient is recuperating from lobectomy for a presumed benign lesion, the permanent tissue sections indicate to the pathologist that the diagnosis is actually carcinoma of the follicular or papillary type. If the lesion is over 1 cm in size, there is a history of irradiation, or the lesion is follicular, completion of the thyroidectomy is advisable, as discussed below, since up to 30% of such re-operations disclose residual tumor. This is certainly appropriate if there is nodularity in the residual thyroid on US exam. An alternative approach is to ablate the residual lobe with 30 mCi of RAI, which is effective in eliminating most of the tissue. Although easy for the patient, and certainly free of surgical complications, whether this provides the same protection as re-operation is not known.

Sclerotherapy

Bennedbaek and Hegedus have carefully evaluated percutaneous ethanol injection therapy in benign solitary solid cold thyroid nodules. Ninety-eight percent ethanol (25 – 50% of nodule volume) was injected under ultrasound guidance intending to achieve uniform spread throughout the nodule. The overall reduction in nodule volume at six months was 46 – 51%. While the majority of patients benefited from reduction in nodule size, significant side effects included transient thyrotoxicosis, permanent facial dysesthesia, paranodular fibrosis, pain, and tenderness. They conclude that the optimum strategy is yet uncertain and that the procedure is limited, especially by local pain and the significant number of side effects, so that caution is advisable in routine use (89). Dossing et al treated 78 euthyroid outpatients with a benign solitary solid and scintigraphically cold thyroid nodule causing local discomfort, with *Interstitial Laser Photocoagulation* (ILP). using one laser fiber under ultrasound (US) guidance and an output power of 1.5-3.5 W. The overall median nodule volume decreased from 8.2 ml (range 2.0-25.9) to 4.1 ml (range 0.6-33.0; $P < 0.001$) at the final evaluation. After 12–96 months (median 38 months) of ILP, 21 patients (29%) had thyroid surgery because of an unsatisfactory result. US-guided ILP results in a satisfactory long-term clinical response in the majority of patients with a benign solitary solid cold thyroid nodule, but further large-scale studies are needed (89.1).

THYROID NODULES IN CHILDREN

In areas of iodide deficiency diffuse thyroid enlargement is found during pre-teen years, and multinodularity commonly occurs by teenage. In contrast, in an iodide-replete country, discovery of a nodule in the thyroid of a child is (fortunately) uncommon, and always raises alarm because of the risk of neoplasia. There is a +/- 5% incidence of cancer in “single nodules” in adults, but up to 18% of those found in children are malignant. This high incidence raises the issue whether all such nodules should be immediately resected, or if it is legitimate to employ the available diagnostic tests to select those for whom surgery should be advised?

Nodules in children are infrequently cystic, perhaps because cystic nodules represent an end stage in some long standing benign growths. Of course cystic lesions can be malignant. We have observed that a significant proportion of enlarging thyroid masses in children produce hyperthyroidism and turn out to be “hyperplastic colloid nodules” on pathological exam, although there are reports that up to 1/4 of “hot nodules” in children are papillary cancers. The majority are inactive on isotope scanning, solid on ultrasound, do not produce hyperthyroidism, and are painless.

If there is rapid growth, if possibly related nodes are present or if there is any other suggestion of malignancy, or if the nodule is the apparent cause of hyperthyroidism, resection is inevitable. For the remaining patients, a question is whether to do a fine needle aspiration cytological exam, or offer resection without this examination. Many thyroidologists caring for pediatric patients would suggest resection directly, but the alternative position is to do an FNA, be guided by the results, and to follow the patient closely with resection in mind if any unfavorable sign occurs (90). Our attitude is to perform FNA in virtually all cases, the reason being not only the selection of therapy, but, even if surgery is already planned, to provide the surgeon with the most likely diagnosis, thus allowing better planning of the surgical procedure. Also, this approach is taken in view of the occasional false positive or false negative diagnosis by intra-operative pathological examination. Since the natural history of such nodules is to enlarge, many will ultimately come to operation. In these patients thyroxine treatment may have value as reported by Renshaw et al(90.1). These authors found in a study of 78 euthyroid children with benign nodules, that T4 treatment reduced size up to 50%, while untreated nodules typically enlarged.

The operative approach is comparable to that used in adults. If the nodule is definitively benign at surgical pathological exam and the remainder of the thyroid is normal, lobectomy or more limited resection is performed. If the lesion is a hypercellular follicular adenoma or if there is uncertainty in the exam, or if other nodules are found, a lobectomy and contra-lateral sub-total resection is often performed. Near-total thyroidectomy with/without node resection is done for malignancy.

INCIDENTALOMAS

Wide spread use of ultrasound for exam of any neck pathology has resulted in frequent recognition of thyroid nodules that are too small to be palpated on clinical examination. Usually such nodules are < 1 cm in largest diameter, typically they are asymptomatic, and are not associated with lymph nodes or other suggestions of malignancy. Often incidentally found, such nodules produce a problem because of the difficulty in achieving a specific diagnosis, which is desired by the patient.

The usual differential diagnostic possibilities, described above, are present. The probability of malignancy is lower than in larger lesions, although exactly how much so is uncertain. In a recent meta-analysis by Tan and Gharib (91), the risk for malignancy in incidentalomas ranged between 0.45% and 13%. Tiny cystic lesions are especially unlikely to harbor a malignancy. Presence of neck adenopathy, local symptoms such as pain or dysphonia, growth under observation, or a history of external radiation to the neck, signal concern and suggest that resection is the proper course.

If the lesion can be palpated it is appropriate to offer FNA cytological exam and proceed as for management of larger lesions. More typically the nodule can not be precisely demarcated on exam. Ultrasound guided FNA is possible for lesions closer to 1 cm in size, and in patients who clearly want every diagnostic assurance available. The smaller lesions are difficult to aspirate with certainty even under ultrasonic guidance. (See discussion above) Considering the probable benign nature of most such lesions, the slow growth and spread of differentiated thyroid cancers, and our ability to offer close surveillance via yearly (or more frequent) ultrasound exams, a common alternative course is “observe” tiny lesions periodically and reserve resection for those that grow or produce other symptoms. Probably, the best option is to submit to FNA only those micronodules which have suspicious features at US.

Suppressive doses of thyroxin can be offered to patients being followed medically. It is clear that shrinkage can be anticipated in only a small fraction of lesions, but this treatment may help reduce future growth, provides a reason for the patient to remain under medical observation, and may, by shrinking the normal tissue, make the nodule palpable and thus more easily examined. Growth under observation and in the absence of cytological diagnosis, or development of nodes or local symptoms, indicate the need for resection.

References

1. Hedinger, C, Dillwyn Williams, E, Sobin, L 1989. The WHO histological classification of thyroid tumors. A commentary on the second edition. *Cancer* 63:908-911
2. Namba, H, Matsuo, K, Fagin, J 1990 Clonal composition of benign and malignant human thyroid tumors. *J Clin In* 86:.
3. Parma, J, Duprez, L, Van Sande, J, et al. 1993. Somatic mutations in the thyrotropin receptor gene cause hyperfunctioning thyroid adenomas. *Nature* 365:649-651
4. Tonacchera, M, Chiovato, L, Pinchera, A, et al. 1998 Hyperfunctioning thyroid nodules in toxic

- multinodular goiter share activating thyrotropin receptor mutations with solitary toxic adenoma. *J Clin Endocrinol Metab* 83:492-8
5. Coclet, J, Foureau, F, Ketelbant, P, Galand, P, Dumont, J 1989. Cell population kinetics in dog and human adult thyroid. *Clinical Endocrinol* 31:655-665
 6. Viglietto, G, Chiappetta, G, Martinez-Tello, F J, et al. 1995 RET/PTC oncogene activation is an early event in thyroid carcinogenesis. *Oncogene* 11:1207-10
 7. Hamburger, J I 1980; Evolution of toxicity in solitary nontoxic autonomously functioning thyroid nodules. *J Clin Endocrinol Metab* 50:1089-1093
 8. Silverstein, G, Burke, G, Cogan, R 1967. The natural history of the auto-nomous hyperfunctioning thyroid nodule. *Ann Intern Med* 67:539
 9. Evered, D, Clark, F, Peterson, V 1974. Thyroid function in euthyroid subjects with autonomous thyroid nodules. *Clin Endocrinol* 3:149
 10. Horst, W, Rosler, H, Schneider, C, Labhart, A 1967. 306 cases of toxic adenoma. Clinical aspects; findings in radioiodine diagnostics; radiochromatography and histology; results of ¹³¹I and surgical treatment. *J Nucl Med* 8:515
 11. Parma, J, Duprez, L, Van Sande, J, et al. 1993. Somatic mutations in the thyrotropin receptor gene cause hyperfunctioning thyroid adenomas. *Nature* 365:649-651
 12. Suarez, H, du Villard, J, Caillou, B, Schlumberger, M, Parmentier, C, Monier, M 1991. Gsp mutations in human thyroid tumors. *Oncogene* 6:677-679
 13. see 10
 - 13a. DeGroot, L 1970. Lack of iodide trapping in “cold” thyroid nodules. *Acta Endocrinol Panam* 1:27
 14. Field, J, Larsen, P, Yamashita, K, Mashiter, K, Dekke, A 1973. Demonstration of iodide transport defect but normal iodide organification in nonfunctioning nodules of human thyroid glands. *J Clin Invest* 52:2404
 15. Fragu, P, Nataf, B 1977. Human thyroid peroxidase activity in benign and malignant thyroid disorders. *J Clin Endocrinol Metab* 45:1089
 16. Demeester-Mirkine, N, Van Sande, J, Corvilain, H, Dumont, J 1975. Benign thyroid nodule with normal iodide trap and defective organification. *J Clin Endocrinol Metab* 41:1169
 17. Burke, G, Szabo, M 1972. Dissociation of in vivo and in vitro “autonomy” in hyperfunctioning thyroid nodules. *J Clin Endocrinol Metab* 35:199
 18. Sande Van, J, Mockel, J, Boeynaems, J, Dor, P, Andry, G, Dumont, J 1980. Regulation of cyclic nucleotide and prostaglandin formation in normal human thyroid tissue and in autonomous nodules. *J Clin Endocrinol Metab* 50:776
 19. Smanik, P, Ryu, K-Y, Thel, K, Mazzaferri, E, Jhiang, S 1997. Expression; exon-intron organization; and chromosome mapping of the human sodium iodide symporter. *Endocrinology* 138:3555-8
 20. Arturi, F, Russo, D, Schlumberger, M, et al. 1998. Iodine symporter gene expression in human thyroid tumors. *J Clin Endocrinol Metab* 83:2493-96
 21. Thomas, C J, Buckwalter, J, Staab, E, Kerr, C 1976. Evaluation of dominant thyroid masses. *Ann Surg* 183:464
 22. Sipple, J H 1984 Multiple endocrine neoplasia type 2 syndromes: historical perspectives. *Henry*

Ford Hosp Med J 32:219-21

23. Schimke, R, Hartmann, W, Prout, T, Rimoin, D 1968. Syndrome of bilateral pheochromocytoma; medullary thyroid carcinoma; and multiple neuromas. N Engl J Med 279:1

24. Sapira, J, Altman, M, Vandyk, K, Shapiro, A 1965. Bilateral adrenal pheo-chromocytoma and medullary thyroid carcinoma. N Engl J Med 273:140

25. Duffy, B J, Fitzgerald, P 1950. Cancer of the thyroid in children. A report of twenty-eight cases. J Clin Endocrinol 10:1296

26. Clark, D 1955. Association of irradiation with cancer of the thyroid in children and adolescents. JAMA 159:1007

27. Modan, B, Ron, E, Werner, A 1977. Thyroid cancer following scalp irradiation. Therapeutic Radiology 123:741

28. DeGroot, L, Frohman, L, Kaplan, E, Refetoff, S e 1977. Radiation-Associated Thyroid Carcinoma. New York Grune & Stratton:539 pages

29. Refetoff, S, Harrison, J, Karanfilski, B, Kaplan, E, DeGroot, L, Bekerman, C 1975. Continuing occurrence of thyroid carcinoma after irradiation to the neck in infancy and childhood. N Engl J Med 292:171

30. DeGroot, L, Paloyan, E 1973. Thyroid carcinoma and radiation. A Chicago endemic. JAMA 225:487

31. Sokal, J 1959. The problem of malignancy in nodular goiter — recapitulation and a challenge. JAMA 170:61

32. Veith, F, Brooks, J, Grigsby, W, Selenkow, H 1964. The nodular thyroid gland and cancer. N Engl J Med 270:431

32.1 [Frates MC, Benson CB, Doubilet PM, Kunreuther E, Contreras M, Cibas ES, Orcutt J, Moore FD Jr, Larsen PR, Marqusee E, Alexander EK](#). Prevalence and distribution of carcinoma in patients with solitary and multiple thyroid nodules on sonography. J Clin Endocrinol Metab. 2006 Sep;91(9):3411-7.

33. Hoffman, G, Thompson, N, Heffron, C 1972. The solitary thyroid nodule. Arch Surg 105:379

33.1 Haymart MR, Replinger DJ, Levenson GE, Elson DF, Sippel RS, Jaume JC, Chen H. [Higher serum thyroid stimulating hormone level in thyroid nodule patients is associated with greater risks of differentiated thyroid cancer and advanced tumor stage](#). J Clin Endocrinol Metab. 2008 Mar;93(3):809-14.

34. Pacini, F, Fontanelli, M, Fugazzola, L, et al. 1994. Routine measurement of serum calcitonin in nodular thyroid diseases allows the preoperative diagnosis of unsuspected sporadic medullary thyroid carcinoma. J Clin Endocrinol Metab 78:826-9

35. Rieu, M, Lame, M, Richard, A, et al. 1995. Prevalence of sporadic medullary thyroid carcinoma. the importance of routine measurement of serum calcitonin in the diagnostic evaluation of thyroid nodules. Clin Endocrinol (Oxf) 42:453-7

36. Niccoli, P, Wion-Barbot, N, Caron, P, et al. 1997. Interest of routine measurement of serum calcitonin. Study in a large series of thyroidectomized patients. J Clin Endocrinol Metab 82:338-341

37. Gagel, R 1997. The goitrous patient with an elevated serum calcitonin — what to do? J Clin Endocrinol Metab 82:335

37.0. American Thyroid Association (ATA) Guidelines Taskforce on Thyroid Nodules and

Differentiated Thyroid Cancer, Cooper DS, Doherty GM, Haugen BR, Kloos RT, Lee SL, Mandel SJ, Mazzaferri EL, McIver B, Pacini F, Schlumberger M, Sherman SI, Steward DL, Tuttle RM. Revised American Thyroid Association management guidelines for patients with thyroid nodules and differentiated thyroid cancer. *Thyroid*, 19:1167-214, 2009.

37.1 [Cherenko M](#) , [Slotema E](#) , [SebagF](#) , [DeMicco C](#) , [HenryJF](#) .Mild hypercalcaemia and sporadic thyroid disease. *Br J Surg* 2010 May;97 (5) :684-90

38. Hamlin, E, Vickery, A 1956. Needle biopsy of the thyroid gland. *N Engl J Med* 254:742

39. Walfish, P, Hazani, E, Strawbridge, H, Miskin, M, Rosen, B 1977. Combined ultrasound and needle aspiration cytology in the assessment and management of hypofunctioning thyroid nodule. *Ann Intern Med* 87:270

40. Gershengorn, M, McClung, M, Chu, W, Hanson, T, Weintraub, B, Robbins, J 1977. Fine-needle aspiration cytology in the preoperative diagnosis of thyroid nodules. *Ann Intern Med* 87:265

41. Baloch, Z, Sack, M, Livolsi, V, Gupta, P 1998. Fine-needle aspiration of thyroid. an institutional experience. *Thyroid* 8:565-9

42. Benvenga, S, Bartolone, L, Squadrito, S, Trimarchi, F 1997. Thyroid hormone autoantibodies elicited by diagnostic fine needle biopsy. *J Clin Endocrinol Metab* 82:4217-4223

43 Wilems, J-S, Lowhagen, T 1981. Fine needle aspiration cytology in thyroid disease. . *Clin Endocrinol Metab* 2:247

44 Gharib, H, Goellner, J, Johnson, D 1993. Fine needle aspiration cytology of the thyroid. A 12-year experience with 11;000 biopsies. *Clin Lab Med* 13:699-709

44.1 Tee YY, Lowe AJ, Brand CA, Judson RT. [Fine-needle aspiration may miss a third of all malignancy in palpable thyroid nodules: a comprehensive literature review.](#) *Ann Surg.* 2007 Nov;246(5):714-20.

45. Pacini, F, Fugazzola, L, Lippi, F, et al. 1992 Detection of thyroglobulin in fine needle aspirates of nonthyroidal neck masses. a clue to the diagnosis of metastatic thyroid cancer. *J Clin Endocrinol Metab* 74:1401-4

46. Chow, L S, Gharib, H, Goellner, J R, van Heerden, J A 2001 Nondiagnostic thyroid fine-needle aspiration cytology: management dilemmas. *Thyroid* 11:1147-51

47. Khurana, K, Richards, V, Chopra, P, Izquierdo, R, Rubens, D, Mesonero, C 1998. The role of ultrasonography-guided fine-needle aspiration biopsy in the management of nonpalpable and palpable thyroid nodules. *Thyroid* 8:511

48. Erdogan, M, Kamel, N, Aras, D, Akdogan, A, Baskal, N, Erdogan, G 1998. Value of reaspirations in benign nodular thyroid disease. *Thyroid* 8:1087

49. Bieche, I, Ruffet, E, Zweibaum, A, Vilde, F, Lidereau, R, Franc, B 1997. MUC1 Mucin gene; transcripts; and protein in adenomas and papillary carcinomas of the thyroid. *Thyroid* 7:725

50 Brousset, P, Chaouche, N, Leprat, F, et al. 1997. Telomerase activity in human thyroid carcinomas originating from the follicular cells. *J Clin Endocrinol Metab* 82:4214-4216

51 Khoo, M L, Beasley, N J, Ezzat, S, Freeman, J L, Asa, S L 2002 Overexpression of cyclin D1 and underexpression of p27 predict lymph node metastases in papillary thyroid carcinoma. *J Clin Endocrinol Metab* 87:1814-8

51.1 [Ferraz C](#) , [Eszlinger M](#) , [Paschke R](#) . [Current state and future perspective of molecular diagnosis of](#)

[fine-needle aspiration biopsy of thyroid nodules](#). J Clin Endocrinol Metab. 2011 Jul;96(7):2016-26).

51.2 Nikiforov YE , Ohori NP, Hodak SP , Carty SE, Lebeau SO, Ferris RL, Yip L, Seethala RR, Tublin ME, Stang MT, Coyne C, Johnson JT, Stewart AF, Nikiforova MN. [Impact of Mutational Testing on the Diagnosis and Management of Patients with Cytologically Indeterminate Thyroid Nodules: A Prospective Analysis of 1056 FNA Samples](#). J Clin Endocrinol Metab . 2011 Nov;96(11):3390-7.

51.3. Silvia Cantara, Marco Capezzone, Stefania Marchisotta, Serena Capuano, Giulia Busonero, Paolo Toti, Andrea Di Santo, Giuseppe Caruso, Anton Ferdinando Carli, Lucia Brillì, Annalisa Montanaro, and Furio Pacini. Impact of Proto-Oncogene Mutation Detection in Cytological Specimens from Thyroid Nodules Improves the Diagnostic Accuracy of Cytology. J Clin Endocrinol Metab. 95:1365-69, 2010

51a. Maruta, J; Hashimoto, H; Yamashita, H; Yamashita, H; Noguchi, S. Diagnostic applicability of dipeptidyl aminopeptidase IV activity in cytological samples for differentiating follicular thyroid carcinoma from follicular adenoma. Arch Surg 139 83-88 2004.

51b. Durand S, Ferraro-Peyret C, Selmi-Ruby S, Paulin C, El Atifi M, Berger F, Berger-Dutrieux N, Decaussin M, Peix JL, Bournaud C, Orgiazzi J, Borson-Chazot F, Rousset B Evaluation of gene expression profiles in thyroid nodule biopsy material to diagnose thyroid cancer. J Clin Endocrinol Metab. 2008 Apr;93(4):1195-202.

51c Shibru D, Hwang J, Khanafshar E, Duh QY, Clark OH, Kebebew E. [Does the 3-gene diagnostic assay accurately distinguish benign from malignant thyroid neoplasms?](#) Cancer. 2008 Sep 1;113(5):930-5.

52 Clark, O, Okerlund, M, Cavalieri, R, Greenspan, F 1979. Diagnosis and treatment of thyroid; parathyroid; and thyroglossal duct cysts. J Clin Endocrinol Metab 48:983

52.1 [Leboulleux S , Girard E , Rose M , Travagli JP , Sabbah N , Caillou B , Hartl DM , Lassau N , Baudin E , Schlumberger M](#) Ultrasound criteria of malignancy for cervical lymph nodes in patients followed up for differentiated thyroid cancer. J Clin Endocrinol Metab. 2007 Sep;92(9):3590-4

53. Marcocci, C, Vitti, P, Cetani, F, Catalano, F, Concetti, R, Pinchera, A 1991. Thyroid ultrasonography helps to identify patients with diffuse lymphocytic thyroiditis who are prone to develop hypothyroidism. J Clin Endocrinol Metab 72:209-13.

53.1 [Real-time elastosonography: useful tool for refining the presurgical diagnosis in thyroid nodules with indeterminate or nondiagnostic cytology](#). 2010 Rago T, Scutari M, Santini F, Loiacono V, Piaggi P, DiCoscio G, Basolo F, Berti P, Pinchera A, **Vitti P** . J Clin Endocrinol Metab. 95:5274-80.

53.2 [Elastography: new developments in ultrasound for predicting malignancy in thyroid nodules](#). 2007 Rago T, Santini F, Scutari M, Pinchera A, **Vitti P** . J Clin Endocrinol Metab. 92:2917-22.

54. Kendall, L, Condon, R 1969. Prediction of malignancy in solitary thyroid nodules. Lancet 1:1071

55. Miller, J, Hamburger, J 1965.. The thyroid scintigram. 1. The hot nodule. Radiology 84:66

56. Attie, J 1960. The use of radioactive iodine in the evaluation of thyroid nodules. Surgery 47:611

57. Dische, S 1964. The radioisotope scan applied to the detection of carcinoma in thyroid swellings. Cancer 17:473

58. Fujimoto, Y, Oka, A, Nagataki, S 1972. Occurrence of papillary carcinoma in hyperfunctioning thyroid nodule. Report of a case. Endocrinol Jpn 19:371

59. Scott, M, Crawford, J 1976. Solitary thyroid nodules in childhood. Is the incidence of thyroid carcinoma declining? *Pediatrics* 58:521
60. Messaris, G, Evangelou, G, Tountas, C 1973. Incidence of carcinoma in cold nodules of the thyroid gland. *Surgery* 74:447
61. Van den Bruel, A, Maes, A, De Potter, T, et al. 2002 Clinical relevance of thyroid fluorodeoxyglucose-whole body positron emission tomography incidentaloma. *J Clin Endocrinol Metab* 87:1517-20
62. Hakama, M Berlin; Springer-Verlag Different world thyroid cancer rates; in Hedinger CE (ed). *Thyroid Cancer. International Union Against Cancer Monograph Series:Vol 12.*
63. Young, J J, Percy, C, Asire, A e 1082 pages Surveillance; Epidemiology; and End Results. Incidence and Mortality Data; 1973-77. National Cancer Institute Monograph 57 NIH Publication No. 81:2330
64. Goldstein, R, Hart, I 1983. Follow-up of solitary autonomous thyroid nodules treated with 131I. *New Engl J Med* 309:1473
65. Gorman, C, Robertson, J 1978. Radiation dose in the selection of 131I or surgical treatment for toxic thyroid adenoma. *Ann Intern Med* 89:85
66. Paracchi, A, Ferrari, C, Livraghi, T, et al. 1992. Percutaneous intranodular ethanol injection. A new treatment for autonomous thyroid adenoma. *J Endocrinol Invest* 15:353-362
67. Lippi, F, Ferrari, C, Manetti, L, et al. 1996. Treatment of solitary autonomous thyroid nodules by percutaneous ethanol injection. results of an Italian multicenter study. The Multicenter Study Group. *J Clin Endocrinol Metab* 81:3261-3264
68. Monzani, F, Caraccio, N, Goletti, O, et al. S54-8 Treatment of hyperfunctioning thyroid nodules with percutaneous ethanol injection. Eight years' experience. *Exp Clin Endocrinol Diabetes* 106: Suppl 4
69. Hamburger, J I 1980; Evolution of toxicity in solitary nontoxic autonomously functioning thyroid nodules. *J Clin Endocrinol Metab* 50:1089-1093
70. McCowen, K, Reed, J, BL., F 1980. The role of thyroid therapy in patients with thyroid cysts. *Amer J Med* 68:853
71. Treece, G, Georgitis, W, Hofeldt, F 1983 Resolution of recurrent thyroid cysts with tetracycline instillation. *Arch Int Med* 143: 2285.
72. Monzani, F, Lippi, F, Goletti, O, et al. 1994. Percutaneous aspiration and ethanol sclero-therapy for thyroid cysts. *J Clin Endocrinol Metab* 78:800-802
73. Zingrillo, M, Torlontano, M, Ghiggi, M, et al. 1996. Percutaneous ethanol injection of large thyroid cystic nodules. *Thyroid* 6:403-8
74. Del Prete, S, Caraglia, M, Russo, D, et al. 2002 Percutaneous ethanol injection efficacy in the treatment of large symptomatic thyroid cystic nodules: ten-year follow-up of a large series. *Thyroid* 12:815-21
75. see 70
76. Papini, E, Bacci, V, Panunzi, C, et al. 1993. A prospective randomized trial of levothyroxine suppressive therapy for solitary thyroid nodules. *Clin Endocrinol* 38:507-513
77. Burch, H 1995. Evaluation and management of the solid thyroid nodule. *Endocrinol Metab Clin N Am* 24:663-710

78. Mainini, E, Martinelli, I, Morandi, G, Villa, S, Stefani, I, Mazzi, C 1995. Levothyroxine suppressive therapy for solitary thyroid nodule. *J Endocrinol Invest* 18:796-799
79. Cooper, D 1995. Clinical review 66. Thyroxine suppression therapy for benign nodular disease. *J Clin Endocrinol Metab* 80:331-334
80. Castro, M R, Caraballo, P J, Morris, J C 2002 Effectiveness of thyroid hormone suppressive therapy in benign solitary thyroid nodules: a meta-analysis. *J Clin Endocrinol Metab* 87:4154-9
- 81 Zelmanovits, F, Genro, S, Gross, J 1998. Suppressive therapy with levothyroxine for solitary thyroid nodules. A double-blind controlled clinical study and cumulative meta-analyses. *J Clin Endocrinol Metab* 83:3881-3885
82. Herms, A, Huysmans, D 1998. Treatment of benign nodular thyroid disease. *N Engl J Med* 312:601-4
83. Larosa, G, Ippolito, A, Luppo, L, et al. 1996. Cold thyroid nodule reduction with l-thyroxine can be predicted by initial nodule volume and cytological characteristics. *J Clin Endocrinol Metab*; 81:4385-7
- 83.a. Sdano MT, Falciglia M, Welge JA, Steward DL. Efficacy of thyroid hormone suppression for benign thyroid nodules: meta-analysis of randomized trials *Otolaryngol Head Neck Surg*. 2005 Sep;133(3):391-6
84. Wemeau, J L, Caron, P, Schvartz, C, et al. 2002 Effects of thyroid-stimulating hormone suppression with levothyroxine in reducing the volume of solitary thyroid nodules and improving extranodular nonpalpable changes: a randomized, double-blind, placebo-controlled trial by the French Thyroid Research Group. *J Clin Endocrinol Metab* 87:4928-34
- 85 see 77
- 86 Morita, T, Tamai, H, Ohshima, A, et al. 1989. Changes in serum thyroid hormone; thyrotropin and thyroglobulin concentrations during thyroxine therapy in patients with solitary thyroid nodules. *J Clin Endocrinol Metab* 69:227
- 87 Woolner, L, Beahrs, O, Black, B, McConahey, W, Keating, F J vol 12 Long term survival rates. in Hedinger Chr E (ed). *Thyroid Cancer*. International Union Against Cancer: Monograph Series
88. Fogelfeld, L, Wiviott, M, Shore-Freedman, E, et al. 1989. Recurrence of thyroid nodules after surgical removal in patients irradiated in childhood for benign conditions. *N Engl J Med* 320:835-840
89. Bennedbaek, F, Hegedus, L 1999. Percutaneous ethanol injection therapy in benign solitary solid cold thyroid nodules. A randomized trial comparing one injection with three injections. *Thyroid* 9:225-233
- 89.1 [Døssing H](#) , [Bennedbæk FN](#) , [Hegedüs L](#) . [Long-term outcome following interstitial laser photocoagulation of benign cold thyroid nodules](#). *Eur J Endocrinol*. 2011 Jul;165(1):123-8.
90. Khurana, K, Labrador, E, Izquierdo, R, Mesonero, C, Pisharodi, L 1999. The role of fine-needle aspiration biopsy in the management of thyroid nodules in children; adolescents; and young adults. A multi-institutional study. *Thyroid* 9:383
91. Tan, G, Gharib, H 1997. Thyroid incidentalomas. management approaches to nonpalpable nodules discovered incidentally on thyroid imaging. *Ann Intern Med* 126:226-31
92. Franceschi, S, Boyle, P, Maissonneuve, P, et al. 1993. The epidemiology of thyroid carcinoma. *Critical Reviews in Oncogenesis* 4:25
93. Parkin, D, Muir, C, Whelan, S, Gao, Y, Fenlay, J, Powell, J Vol. 6 Cancer incidence in five

- continents. IARC Scientific Publication 120 International Agency for Research on Cancer: Lyon
- 94 Goodman, M, Yoshizawa, C, Kolonel, L 1988. Descriptive epidemiology of thyroid cancer in Hawaii. *Cancer* 61:1272
95. Spitz, M, Sider, J, Katz, R, Pollack, E, Newell, G 1988. Ethnic patterns of thyroid cancer incidence in the United States; 1973-1981. *Int J Cancer* 42:549
- 95.1. Davies L, Welch HG Increasing incidence of thyroid cancer in the United States, 1973-2002. *JAMA*. 2006 May 10;295(18):2164-7.
- 95.2. Enewold L, Zhu K, Ron E, Marrogi AJ, Stojadinovic A, Peoples GE, Devesa SS. Rising thyroid cancer incidence in the United States by demographic and tumor characteristics, 1980-2005. *Cancer Epidemiol Biomarkers Prev*. 2009 Mar;18(3):784-91
96. Mortensen, J, Woolner, L, Bennett, W 1955. Gross and microscopic findings in clinically normal thyroid glands. *J Clin Endocrinol Metab* 15:1270
97. Silverberg, S, Vidone, R 1966. Metastatic tumors in the thyroid. *Pac Med & Surg* 74:175
98. Hundahl, S A, Fleming, I D, Fremgen, A M, Menck, H R 1998 A National Cancer Data Base report on 53,856 cases of thyroid carcinoma treated in the U.S., 1985-1995 [see comments]. *Cancer* 83:2638-48
99. Wahner, H, Cuello, C, Correa, P, Uribe, L, Gaitan, E 1966. Thyroid carcinoma in an endemic goiter area; Cali; Colombia. *Am J Med* 40:58
100. Belfiore, La Rosa, G, La Porta, G, et al. 1992. Cancer risk in patients with cold thyroid nodules. relevance of iodine intake; sex; age; and multinodularity. *Am J Med* 93:363
- 100.1. Sandeep TC, Strachan MW, Reynolds RM, Brewster DH, Scelo G, Pukkala E, Hemminki K, Anderson A, Tracey E, Friis S, McBride ML, Kee-Seng C, Pompe-Kirn V, Kliewer EV, Tonita JM, Jonasson JG, Martos C, Boffetta P, Brennan P. Second primary cancers in thyroid cancer patients: a multinational record linkage study. *J Clin Endocrinol Metab*. 2006 May;91(5):1819-25
101. Namba, H, Matsuo, K, Fagin, J 1990 Clonal composition of benign and malignant human thyroid tumors. *J Clin In* 86:.
102. Coclet, J, Foureau, F, Ketelbant, P, Galand, P, Dumont, J 1989. Cell population kinetics in dog and human adult thyroid. *Clinical Endocrinol* 31:655-665
103. Curran, P, DeGroot, L 1991. The effect of hepatic enzyme-inducing drugs on thyroid hormones and the thyroid gland. *Endocrine Rev* 12:135-150
104. Namba, H, Gutman, R, Matsuo, K, Alvarez, A, Fagin, J 1990 H-Ras protooncogene mutations in human thyroid neoplasms. *J Clin Endocrinol Metab* 71: .
105. Namba, H, Rubin, S, Fagin, J 1990. Point mutations of Ras oncogenes are an early event in thyroid tumorigenesis. *Molecul Endocrinol* 4:1474
106. Karga, H, Lee, J-K, Vickery, A, Thor, A, Gaz, R, Jameson, J 1991. Ras oncogene mutations in benign and malignant thyroid neoplasms. *J Clin Endocrinol Metab* 73:832
- 106a. [Lupi C, Giannini R, Ugolini C, Proietti A, Berti P, Minuto M, Materazzi G, Elisei R, Santoro M, Miccoli P, Basolo F](#). Association of BRAF V600E mutation with poor clinicopathological outcomes in 500 consecutive cases of papillary thyroid carcinoma. *J Clin Endocrinol Metab*. 2007 Nov;92(11):4085-90.
- 106b [Costa AM](#) , [Herrero A](#) , [Fresno MF](#) , [Heymann J](#) , [Alvarez JA](#) , [Cameselle-Teijeiro J](#) , [García-](#)

- [Rostán G](#) . BRAF mutation associated with other genetic events identifies a subset of aggressive papillary thyroid carcinoma. *Clin Endocrinol (Oxf)*. 2007 Dec 5
107. Santoro, M, Carlomagno, F, Hay, I, et al. 1992. Ret oncogene activation in human thyroid neoplasms is restricted to the papillary cancer subtype. *J Clin Invest* 89:1517-1522
108. Jhiang, S, Sagartz, J, Tong, Q, et al. 1996. Targeted expression of the ret/PTC1 oncogene induces papillary thyroid carcinomas. *Endocrinology* 137:375-378
- 108a. Nikiforova, MN; Kimura, ET; Gandhi, M; Biddinger, PW; Knauf, JA; Basolo, F; Zhu, Z; Giannini, R; Salvatore, G; Fusco, A; Santoro, M; Fagin, JA; Nikiforov, YE. BRAF mutations in thyroid tumors are restricted to papillary carcinomas and anaplastic or poorly differentiated carcinomas arising from papillary carcinomas. *J Clin Endocrinol Metab* 88 5399-5404 2003.
- 108b. Giannini R, Ugolini C, Lupi C, Proietti A, Elisei R, Salvatore G, Berti P, Materazzi G, Miccoli P, Santoro M, Basolo F. The Heterogeneous Distribution of Distinct Tumor BRAF mutations in Multifocal Papillary J Clin Endocrinol Metab. 2007 Sep;92(9):3511-6
- 109 Kroff, T, Sarraf, P, Pecciarini, L, et al. 2000. PAX8-PPAR(1 fusion oncogene in human thyroid carcinoma. *Science* 289:1357-1360
- 109a. Powell, JG; Allard, BL; Sahin, M; Wang, X-L; Wang, X; Hay, ID; Hiddinga, HJ; Deshpande, SS; Kroll, TG; Grebe, SKG; Eberhardt, NL; McIver, B. The PAX8/PPAR(fusion oncoprotein transforms immortalized human thyrocytes through a mechanism probably involving wild-type PPAR(inhibition. *Oncogene* 2003.
110. Marques, A R, Espadinha, C, Catarino, A L, et al. 2002 Expression of PAX8-PPAR gamma 1 rearrangements in both follicular thyroid carcinomas and adenomas. *J Clin Endocrinol Metab* 87:3947-52
- 110.1Nikiforova MN, Lynch RA, Biddinger PW, Alexander EK, Dorn II GW, Tallini G, Kroll TG, Nikiforov YE. RAS point mutations and PAX8-PPARg rearrangement in thyroid tumors: evidence for distinct molecular pathways in thyroid follicular carcinoma. *J Clin Endocrinol Metab* 88:2318-2326, 2003.
111. Vivaldi, A, Pacini, F, Martini, F, et al. 2003 Simian virus 40-like sequences from early and late regions in human thyroid tumors of different histotypes. *J Clin Endocrinol Metab* 88:892-9
112. Puzianowska-Kuznicka, M, Krystyniak, A, Madej, A, Cheng, S Y, Nauman, J 2002 Functionally impaired TR mutants are present in thyroid papillary cancer. *J Clin Endocrinol Metab* 87:1120-8
- 112a. Takano, T; Miyauchi, A; Yoshida, H; Nakata, Y; Kuma, K; Amino, N. Expression of TR(1 mRNAs with functionally impaired mutations is rare in thyroid papillary carcinoma. *J Clin Endocrinol Metab* 88 3447-3449 2003.
- 113.Liu, R T, Huang, C C, You, H L, et al. 2002 Overexpression of tumor susceptibility gene TSG101 in human papillary thyroid carcinomas. *Oncogene* 21:4830-7
114. Parma, J, Duprez, L, Van Sande, J, et al. 1993. Somatic mutations in the thyrotropin receptor gene cause hyperfunctioning thyroid adenomas. *Nature*365:649-651
- 115.Suarez, H,du Villard,J, Caillou,B, Schlumberger,M, Parmentier,C, Monier,M 1991.Gsp mutationsin humanthyroid tumors.*Oncogene*6:677-679
- 116.Matsuo, K,Friedman, E,Gejman, P,Fagin, J1993. The thyrotropin receptor (TSH-R) is not an oncogene for thyroid tumors. Structural studies of the TSH-R and the -subunit of GS in human thyroid neoplasms. *J Clin Endocrinol Metab* 76:1446-1451

117. Shi, Y, Zou, M, Farid, N 1993. Expression of thyrotrophin receptor gene in thyroid carcinoma is associated with a good prognosis. *Clinical Endocrinol* 39:269-274
- 118 Fagin, J, Matsuo, K, Karmakar, A, Chen, D, Tang, S-H, Koeffler, H 1993. High prevalence of mutations of the p53 gene in poorly differentiated human thyroid carcinomas. *J Clin Invest* 91:179-184
- 119 Wada, N, Duh, Q Y, Miura, D, Brunaud, L, Wong, M G, Clark, O H 2002 Chromosomal aberrations by comparative genomic hybridization in hurthle cell thyroid carcinomas are associated with tumor recurrence. *J Clin Endocrinol Metab* 87:4595-601
120. Larsson, C, Skogseid, B, Oberg, K, Nakamura, Y, Nordenskjold, M 1988. Multiple endocrine neoplasia type I gene maps to chromosome 11 and is lost in insulinoma. *Nature* 332:85-87
121. Quadro, L, Panariello, L, Salvatore, D, et al. 1994. Frequent RET proto-oncogene mutations in multiple endocrine neoplasia type 2A. *J Clin Endocrinol Metab* 79:590-594
122. Marsh, D, Learoyd, D, Robinson, B 1995. Medullary thyroid carcinoma. Recent advances and management update. *Thyroid* 5:407
123. Wohllk, N, Cote, G, Bugalho, M, et al. 1996. Relevance of RET proto-oncogene mutations in sporadic medullary thyroid carcinoma. *J Clin Endocrinol Metab* 81:3740-3745
124. Loh, K C 1997 Familial nonmedullary thyroid carcinoma: a meta-review of case series. *Thyroid* 7:107-13.
125. Fagin, J 1997. Familial nonmedullary thyroid carcinoma – The case for genetic susceptibility. *J Clin Endocrinol Metab* 82:342-344
- 126.1 Capezzone M, Cantara S, Marchisotta S, Filetti S, De Santi MM, Rossi B, Ronga G, Durante C, Pacini F *J Clin Endocrinol Metab*. 2008 Oct;93(10):3950-7.
127. no entry
128. Lloyd, K, Dennis, M 1963. Cowden's disease. A possible new symptom complex with multiple system involvement. *Annals Int Med* 58:136
- 129.see 134a
- 130.see 132
- 131.Camiel, M, Mule, J, Alexander, L, Benninghoff, D 1968. Association of thyroid carcinoma with Gardner's syndrome in siblings. *N Engl J Med* 278:1056
- 132.Parkin, J 1981. Familial multiple glomus tumors and pheochromocytomas. *Ann Otol* 90:.60
- 132a. Hemminki K, Eng C, Chen B J FAMILIAL RISKS FOR NON-MEDULLARY THYROID CANCER *Clin Endocrinol Metab*. 2005 Jul 19;.
133. Stratakis, C, Courcoutsakis, N, Abati, A, et al. 1997. Thyroid gland abnormalities in patients with the syndrome of spotty skin pigmentation; myxomas; endocrine overactivity; and schwannomas (Carney Complex). *J Clin Endocrinol Metab* 82:2037-2043
- 134 Malchoff, C, Sarfarazi, M, Tendler, B, et al. 2000. Papillary thyroid carcinoma associated with papillary renal neoplasia. genetic linkage analysis of a distinct heritable tumor syndrome. *J Clin Endocrinol Metab* 85:1758-1764
- 134a. Malchoff, C D, Malchoff, D M 2002 The genetics of hereditary nonmedullary thyroid carcinoma. *J Clin Endocrinol Metab* 87:2455-9
135. Wollman, S 1963. Production and properties of transplantable tumors of the thyroid gland in the

Fischer rat. *Recent Prog Hormone Research* 19:579

136 Frantz, V, Kligerman, M, Harland, W, Phillips, M, Quimby, E 1957. A comparison of the carcinogenic effect of internal and external irradiation on the thyroid gland of the male Long- Evans rat. *Endocrinology* 61:574

137 Doniach, I 1953. The effect of radioactive iodine alone and in combination with nethylthiouracil upon tumor production in the rat's thyroid gland. *Br J Cancer* 7:181

138.to be entered

139.to be entered

140.Maloof, F, Dobyns, B, Vickery, A 1952. The effects of various doses of radioactive iodine on the function and structure of the thyroid of the rat. *Endocrinology* 50:612

141.Dobyns, B, Didschenko, I 1961. Nuclear changes in thyroidal epithelium following radiation from radioiodine. *J Clin Endocrinol Metab* 21:699

142. . Duffy, B J, Fitzgerald, P 1950. Cancer of the thyroid in children. A report of twenty-eight cases. *J Clin Endocrinol* 10:1296

143. Clark, D 1955. Association of irradiation with cancer of the thyroid in children and adolescents. *JAMA* 159:1007

144. Modan, B, Ron, E, Werner, A 1977. Thyroid cancer following scalp irradiation. *Therapeutic Radiology* 123:741

145 DeGroot, L, Frohman, L, Kaplan, E, Refetoff, S e 1977. *Radiation-Associated Thyroid Carcinoma*. New York Grune & Stratton:539 pages

146. Refetoff, S, Harrison, J, Karanfilski, B, Kaplan, E, DeGroot, L, Bekerman, C 1975. Continuing occurrence of thyroid carcinoma after irradiation to the neck in infancy and childhood. *N Engl J Med* 292:171

147. DeGroot, L, Paloyan, E 1973. Thyroid carcinoma and radiation. A Chicago endemic. *JAMA* 225:487

.148.Pifer, J, Hempelmann, L, Dodge, H, Hodges, F 1968. Neoplasms in the Ann Arbor Series of thymus-irradiated children; a second survey. *Am J Roent; Rad Ther & Nucl Med* 103:13

149. Saenger, E, Silverman, F, Sterling, T, Turner, M 1960. Neoplasia following therapeutic irradiation for benign conditions in childhood. *Radiology* 74:.889

150 Beach, S, Dolphin, G 1962. A study of the relationship between X-ray dose delivered to the thyroids of children and the subsequent development of malignant tumors. *Phys Med Biol* 6:583

151. Winship, T, Rosvoll, R 1961. Thyroid carcinoma in childhood. *Cancer* 14:734

152.. Maxon, H, Thomas, S, Saenger, E, Buncher, C, Kereiakes, J 1977. Ionizing irradiation and the induction of clinically significant disease in the human thyroid gland. *Am J Med* 63:967

152a. [Sadetzki S, Chetrit A, Lubina A, Stovall M, Novikov I](#). Risk of thyroid cancer after childhood exposure to ionizing radiation for tinea capitis.*J Clin Endocrinol Metab*. 2006 Dec;91(12):4798-804

153. see 147

154 see 144

154a. Hollowell, JG; Staehling, NW; Flanders, WD; Hannon, WH; Gunter, EW; Spencer, CA; Braverman, LE. Serum TSH, T4, and thyroid antibodies in the United States population (1988 to 1994):

National Health and Nutrition Examination Survey (NHANES III). *J Clin Endocrinol Metab* 87:489-499 2002.

155. see 152

156. Perkel, V, Gail, M, Lubin, J, et al. 1988. Radiation-induced thyroid neoplasms. Evidence for familial susceptibility factors. *J Clin Endocrinol Metab* 66:1316

157. Hanford, J, Quinby, E, Frantz, V 1962. Cancer arising many years after radiation therapy. *JAMA* 181:404

158. DeLawter, D, Winship, T 1963. Follow-up study of adults treated with Roentgen rays for thyroid disease. *Cancer* 16:1028

159 Parker, L, Belsky, J, Yamamoto, T, Kawamoto, S, Keehn, R 1974. Thyroid carcinoma after exposure to atomic radiation. *Ann Intern Med* 80:600

160. Hancock, S, Cox, R, McDougall, I 1991. Thyroid diseases after treatment of Hodgkin's disease. *N Engl J Med* 325:599

161. Pacini, F, Vorontsova, T, Demidchik, E, et al. 1997. Post-chernobyl thyroid carcinoma in Belarus children and adolescents. Comparison with naturally occurring thyroid carcinoma in Italy and France. *J Clin Endocrinol Metab* 82:3563-3569

161.1. Cardis E, Kesminiene A, Ivanov V, Malakhova I, Shibata Y, Khrouch V, Drozdovitch V, Maceika E, Zvonova I, Vlassov O, Bouville A, Goulko G, Hoshi M, Abrosimov A, Anoshko J, Astakhova L, Chekin S, Demidchik E, Galanti R, Ito M, Korobova E, Lushnikov E, Maksimov M, Masyakin V, Nerovnia A, Parshin V, Parshkov E, Piliptsevich N, Pinchera A, Polyakov S, Shabeka N, Suonio E, Tenet V, Tsyb A, Yamashita S, Williams D. Risk of thyroid cancer after exposure to ¹³¹I in childhood *J Natl Cancer Inst.* 2005 May 18;97(10):724-32.

162. see 147

162.a [Lyon JL, Alder SC, Stone MB, Scholl A, Reading JC, Holubkov R, Sheng X, White GL Jr, Hegmann KT, Anspaugh L, Hoffman FO, Simon SL, Thomas B, Carroll R, Meikle AW.](#) Thyroid Disease Associated With Exposure to the Nevada Nuclear Weapons Test Site Radiation: A Reevaluation Based on Corrected Dosimetry and Examination Data. *Epidemiology.* 2006 Nov;17(6):604-614

163. see 146

164. Favus, J, Schneider, A, Stachura, M, et al. 1976. Thyroid cancer occurring as a late consequence of head-and-neck irradiation. *N Engl J Med* 294:1019

165. Maxon, H, Thomas, S, Saenger, E, Buncher, C, Kereiakes, J 1977. Ionizing irradiation and the induction of clinically significant disease in the human thyroid gland. *Am J Med* 63:967

166. Spitalnik, P, Straus, F 1978. Patterns of human thyroid parenchymal reaction following low-dose childhood irradiation. *Cancer* 41:1098

167. Roudebush, C, Asteris, G, DeGroot, L 1978. Natural history of radiation-associated thyroid cancer. *Arch Intern Med* 138:1631

168. Rao, D, Frame, B, Miller, M, Kleerekoper, M, Block, M, Parfitt, A 1980. Hyperparathyroidism following head and neck irradiation. *Arch Intern Med* 140:205

169. Conard, R 1975. A twenty-year review of medical findings in a Marshallese population accidentally exposed to radioactive fallout. Published by Brookhaven National Laboratory (BNL No. 50424) Upton: New York

- 169.1. Lyon JL, Alder SC, Stone MB, Scholl A, Reading JC, Holubkov R, Sheng X, White GL Jr, Hegmann KT, Anspaugh L, Hoffman FO, Simon SL, Thomas B, Carroll R, Meikle AW. Thyroid disease associated with exposure to the Nevada nuclear weapons test site radiation: a reevaluation based on corrected dosimetry and examination data. *Epidemiology*. 2006 Nov;17(6):604-14.
170. Vickery, A The Williams & Wilkins Co Thyroid alterations due to irradiation. The Thyroid International Academy of Pathology Monograph No 5: Baltimore
- 171 Cantolino, S, Schmickel, R, Ball, M, Cisar, C 1966. Persistent chromosomal aberrations following radioiodine therapy for thyrotoxicosis. *N Engl J Med* 275:739
172. Sheline, G, Lindsay, S, McCormack, K, Galante, M 1962. Thyroid nodules occurring late after treatment of thyrotoxicosis with radioiodine. *J Clin Endocrinol Metab* 2: 8
- 173 Dobyns, B, Sheline, G, Workman, J, Tompkins, E, McConahey, W, Becker, D 1974. Malignant and benign neoplasms of the thyroid in patients treated for hyperthyroidism. A report of the cooperative thyrotoxicosis therapy follow-up study. *J Clin Endocrinol Metab* 38:976
- 174 Holm, L-E, Dahlqvist, I, Israelsson, A, Lundell, G 1980. Malignant thyroid tumors after iodine 131-therapy. *N Engl J Med* 303:188
- 175 Holm, L-E, Eklund, G, Lundell, G 1980. Incidence of malignant thyroid tumors in humans after exposure to diagnostic doses of iodine-131. II. Estimation of thyroid gland size; thyroid radiation; and predicted versus observed number of malignant thyroid tumors. *J Natl Cancer Inst* 65:1221
176. Stanbury, J F g p 273 in Stanbury, JB; Wyngaarden, JB; Fredrickson, DS (eds). *The Metabolic Basis of Inherited Disease*. New York: McGraw-Hill Book Co Inc
177. McGirr, E, Clement, W, Currie, A, Kennedy, J 1959. Impaired dehalogenase activity as a cause of goiter with malignant changes. *Scott Med J* 4:232
178. Elman, D 1958. Familial association of nerve deafness with nodular goiter and thyroid carcinoma. *N Engl J Med* 259:219
179. Medeiros-Neto, G, Oliveira, N 1970. Follicular adenocarcinoma of thyroid associated with congenital hyperplastic goiter. *Acta Endocrinol Panam* 1:73
180. Cooper, D, Axelrod, L, DeGroot, L, Vickery, A, Maloof, F 1981. Congenital goiter and the development of metastatic follicular carcinoma with evidence for a leak of nonhormonal iodide. Clinical; pathological; kinetic; and biochemical studies and a review of the literature. *J Clin Endocrinol Metab* 52:294
181. Sloan, L 1954. Of the origin; characteristics and behaviour of thyroid cancer. *J Clin Endocrinol Metab* 14:1309
182. Ellenbert, A, Goldman, L, Gordan, G, Lindsay, S 1962. Thyroid carcinoma in patients with hyperparathyroidism. *Surgery* 51:708
183. LiVolsi, V, Feind, C 1976. Parathyroid adenoma and nonmedullary thyroid carcinoma. *Cancer* 38:1391
184. Shapiro, S, Friedman, N, Perzik, S, Catz, B 1970. Incidence of thyroid carcinoma in Graves' disease. *Cancer* 26:1261
185. see 147
186. see 184
187. Belfiore, A, Garofalo, M, Giuffrida, D, et al. 1990. Increased aggressiveness of thyroid cancer in

- patients with Graves' disease. *J Clin Endocrinol Metab* 70:830
188. Pellegriti, G, Belfiore, A, Giuffrida, D, Lupo, L, Vigneri, R 1998. Outcome of differentiated thyroid cancer in Graves' patients. *J Clin Endocrinol Metab* 83:2805
189. Filetti, S, Belfiore, A, Amir, S, et al. 1988. The role of thyroid-stimulating antibodies of Graves' disease in differentiated thyroid cancer. *N Engl J Med* 318:753
190. see DeGroot/Paloyan
191. Belfiore, A, Garofalo, M, Giuffrida, D, et al. 1990. Increased aggressiveness of thyroid cancer in patients with Graves' disease. *J Clin Endocrinol Metab* 70:830
192. Valenta, L, Lemarchand-Beraud, T, Nemecek, J, Griessen, M, Bednar, J 1970. Metastatic thyroid carcinoma provoking hyperthyroidism; with elevated circulating thyrostimulators. *Am J Med* 48:72
193. Greenspan, F, Lowenstein, J, West, M, Okerlund, M 1972. Immunoreactive material to bovine TSH in plasma from patients with thyroid cancer. *J Clin Endocrinol Metab* 35:795
194. Greenspan, F, Lew, W, Okerlund, M, Lowenstein, J 1974. Falsely positive bovine TSH radioimmunoassay responses in sera from patients with thyroid cancer. *J Clin Endocrinol Metab* 38:1121
195. see 191
196. Mazzaferri, E 1990. Thyroid cancer and Graves' disease. *J Clin Endocrinol Metab* 70:826
197. Panza, N, Del Vecchio, L, Maio, M, et al. 1982. Strong association between an HLA- DR antigen and thyroid carcinoma. *Tissue Antigens* 20:155
198. Sampson, R, Woolner, L, Bahn, R, Kurland, L 1974. Occult thyroid carcinoma in Olmsted County; Minnesota. Prevalence at autopsy compared with that in Hiroshima and Nagasaki; Japan. *Cancer* 34:2072
199. Fukunaga, F, Yatani, R 1975. Geographic pathology of occult thyroid carcinomas. *Cancer* 36:1095
- 200 Hazard, J, Hawk, W, Crile, G J 1959. Medullary (solid) carcinoma of the thyroid. A clinicopathologic entity. *J Clin Endocrinol Metab* 19:152
- 200.1. Khurana R., Agarwal A, Bajpai VK, Verma N, Sharma AK, Gupta RP, Madhusudan KP. Unraveling the amyloid associated with human medullary thyroid carcinoma., *Endocrinology*. 2004 Dec;145(12):5465-70
201. Meier, D, Woolner, L, Beahrs, O, McConahey, W 1959. Parenchymal findings in thyroid carcinoma. Pathologic study of 256 cases. *J Clin Endocrinol Metab* 19:162
202. Lindsay, S, Dailey, M 1955. Malignant lymphoma of the thyroid gland and its relation to Hashimoto's disease. A clinical and pathologic study of 8 patients. *J Clin Endocrinol Metab* 15:1332
203. Rayfield, E, Nishiyama, R, Sisson, J 1971. Small cell tumors of the thyroid. A clinicopathologic study. *Cancer* 28:1023
204. Black, B, Kirk, T J, Woolner, L 1960. Multicentricity of papillary adenocarcinoma of the thyroid. Influence on treatment. *J Clin Endocrinol Metab* 20:130
205. Iida, F, Yonekura, M, Miyakawa, M 1969. Study of intraglandular dissemination of thyroid cancer. *Cancer* 24:764
- 205.1 Giannini R, Ugolini C, Lupi C, Proietti A, Elisei R, Salvatore G, Berti P, Materazzi G, Miccoli P, Santoro M, Basolo F. [The heterogeneous distribution of BRAF mutation supports the independent](#)

[clonal origin of distinct tumor foci in multifocal papillary thyroid carcinoma](#). J Clin Endocrinol Metab. 2007 Sep;92(9):3511-6.

206. Reed, R, Russin, D, Krementz, ET. 1966. Latent metastases from occult sclerosing carcinoma of the thyroid. JAMA 196:233

207. Hazard, J 1960. Small papillary carcinoma of the thyroid. Lab Invest 9:86
208.

208. Studer, H, Veraguth, P, Wyss, F 1961. Thyrotoxicosis due to a solitary hepatic metastasis of thyroid carcinoma. J Clin Endocrinol Metab 21:1334

209. Hunt, W, Crispell, K, McKee, J 1960. Functioning metastatic carcinoma of the thyroid producing clinical hyperthyroidism. Am J Med 28:995

210. Pochin, E 1960. Leukemia following radioiodine treatment of thyrotoxicosis. Br Med J 2:1545

211. Wyse, E, Hill, C, Ibanez, M, Clark, R 1969. Other malignant neoplasms associated with carcinoma of the thyroid. Thyroid carcinoma multiplex. Cancer 24:701

212. Shimaoka, K, Takeuchi, S, Pickren, J 1967. Carcinoma of thyroid associated with other primary malignant tumors. Cancer 20:1000

213. Halnan, K 1966. Influence of age and sex on incidence and prognosis of thyroid cancer. Cancer 19:1534

214. Russel, M, Gilbert, E, Jaeschke, W 1975. Prognostic features of thyroid cancer. A long term follow-up of 68 cases. Cancer 36:553

215. see 213

216. Rosvoll, R, Winship, T 1965. Thyroid carcinoma and pregnancy. Surg Gynecol Obstet 121:1039

217. Franssila, K 1975. Prognosis in thyroid carcinoma. Cancer 36:1138

218. Woolner, L, Lemmon, M, Beahrs, O, Black, B, Keating, F J 1960. Occult papillary carcinoma of the thyroid. Study of 140 cases observed in a 30-year period. J Clin Endocrinol Metab 20:89-113

218a. Passler, C; Prager, G; Scheuba, C; Niederle, BE; Kaserer, K; Zettinig, G; Niederle, B. Follicular variant of papillary thyroid carcinoma: a long-term follow-up. Arch Surg 138 1362-1366 2003.

218b. Shattuck TM, Westra WH, Ladenson PW, Arnold A. Independent clonal origins of distinct tumor foci in multifocal papillary thyroid carcinoma. N Engl J Med. 2005 Jun 9;352(23):2406-12.

219. McConahey, W, Taylor, W, Gorman, C, Woolner, L Field Educational Italia Retrospective study of 820 patients treated for papillary carcinoma of the thyroid at the Mayo Clinic between 1946 and 1971. in Andreoli, M; Monaco, F; Robbins, J (eds). Advances in Thyroid Neoplasia: Rome

220. Franssila, K 1975. Prognosis in thyroid carcinoma. Cancer 36:1138

221. McDermott, W J, Morgan, W, Hamlin, E J, Cope, O 1954. Cancer of the thyroid. J Clin Endocrinol Metab 14:1336

222 Schlumberger, M, De Vathaire, F, Travagli, J, et al. 1987. Differentiated thyroid carcinoma in childhood. Long term follow-up of 72 patients. J Clin Endocrinol Metab 65:1088

223 Cady, B, Sedgwick, C, Meissner, W, Bookwalter, J, Romagosa, V, Werber, J 1976. Changing clinical; pathologic; therapeutic; and survival patterns of differentiated thyroid carcinoma. Ann Surg 184:541

224. Mazzaferri, E, Young, R 1981. Papillary thyroid carcinoma. A ten year follow-up report of the impact of therapy in 576 patients. *Am J Med* 70:511
225. see 223
- 256 Harwood, J, Clark, O, Dunphy, J 1978. Significance of lymph node metastasis in differentiated thyroid cancer. *Am J Surg* 136:107
257. Mazzaferri, E, Young, R, Oertel, J, Kemmerer, W, Page, C 1977. Papillary thyroid carcinoma. The impact of therapy in 576 patients. *Medicine* 56:171
258. Terry, J, St John, S, Karkowski, F, al., e 1994. Tall cell papillary thyroid cancer. Incidence and prognosis. *Am J Surg* 168:459
259. Burman, K, Ringel, M, Wartofsky, L 1996. Unusual types of thyroid neoplasms. *Endocrinol Metab Clinics North America* 25:49-68
- 259.1. Elisei R, Ugolini C, Viola D, Lupi C, Biagini A, Giannini R, Romei C, Miccoli P, Pinchera A, Basolo F BRAF(V600E) mutation and outcome of patients with papillary thyroid carcinoma: a 15-year median follow-up study. *J Clin Endocrinol Metab.* 2008 Oct;93(10):3943-9
- 260.see 223
- 261.see 224
- 262.see 257
- 263.Frazell, E, Duffy, B 1954. Invasive papillary cancer of the thyroid. *J Clin Endocrinol Metab* 14:1362
264. Franssila, K 1975. Prognosis in thyroid carcinoma. *Cancer* 36:1138
265. Woolner, L, Lemmon, M, Beahrs, O, Black, B, Keating, F J 1960. Occult papillary carcinoma of the thyroid. Study of 140 cases observed in a 30-year period. *J Clin Endocrinol Metab* 20:89
266. see 223
- 266a. Chao, TC; Lin, JD; Chen, MF. Insular carcinoma: Infrequent subtype of thyroid cancer with aggressive clinical course. *World J Surg* 2004.
267. Young, R, Mazzaferri, E, Rahe, A, Dorfman, S 1980. Pure follicular thyroid carcinoma. Impact of therapy in 214 patients. *J Nucl Med* 21:733
268. Justin, E, Seabold, J, Robinson, R, Walker, W, Gurll, N, Hawe, D 1991. Insular carcinoma. A distinct thyroid carcinoma with associated Iodine-131 localization. *J Nucl Med* 32:1358-1363
- 268.1. Pulcrano M, Boukheris H, Talbot M, Caillou B, Dupuy C, Virion A, De Vathaire F, Schlumberger M. Poorly Differentiated Follicular Thyroid Carcinoma: Prognostic Factors and Relevance of Histological Classification. *Thyroid.* 2007 Jul;17(7):639-646
269. McDermott, W J, Morgan, W, Hamlin, E J, Cope, O 1954. Cancer of the thyroid. *J Clin Endocrinol Metab* 14:1336
270. see 267
271. see 269
272. see 223
273. see 267
274. Caplan, R, Abellera, R, Kiskan, W 1994. Hurthle cell neoplasms of the thyroid gland.

Reassessment of functional capacity. *Thyroid* 4:243

275. Cheung, C, Ezzat, S, Ramyar, L, Freeman, J, Asa, S 2000. Molecular basis of Hurthle cell papillary thyroid carcinoma. *J Clin Endocrinol Metab* 85:878-882

276 see 274

277. Harada, T, Ito, K, Shimaoka, K, Hosoda, Y, Yakumara, K 1977. Fatal thyroid carcinoma. Anaplastic transformation of adenocarcinoma. *Cancer* 39:2588

278. Oppenheim, al., e 1983. Anaplastic thyroid cancer presenting with hyperthyroidism. *Amer J Med* 75:702

279. Leedman, P, Sheridan, W, Downey, W, Fox, R, Martin, F 1990. Combination chemotherapy as single modality therapy for stage IE and IIE thyroid lymphoma. *Med J Australia* 152:40

280. Butler, J, Brady, L, Amendola, B 1990. Lymphoma of the thyroid. Report of five cases and review. *Amer J Clin Oncol (CCT)* 13:64

281. Souhami, L, Simpson, W, Carrothers, J 1980. Malignant lymphoma of the thyroid gland. *Int J Radiat Oncol Biol Phys* 6:1143

282. Kini, S, Miller, J, Hamburger, J 1981. Problems in the cytologic diagnosis of the "cold" thyroid nodule in patients with lymphocytic thyroiditis. *Acta Cytol* 25:506

283 Grimley, R, Oates, G 1980. The natural history of malignant thyroid lymphomas. *Br J Surg* 67:475

284. Siroto, D, Segal, R 1979. Primary lymphomas of the thyroid. *JAMA* 242:1743

284a [Sandeep TC, Strachan MW, Reynolds RM, Brewster DH, Scelo G, Pukkala E, Hemminki K, Anderson A, Tracey E, Friis S, McBride ML, Kee-Seng C, Pompe-Kirn V, Kliwer EV, Tonita JM, Jonasson JG, Martos C, Boffetta P, Brennan P](#). Second primary cancers in thyroid cancer patients: a multinational record linkage study *J Clin Endocrinol Metab*. 2006 May;91(5):1819-25

284b [Brown AP, Chen J, Hitchcock YJ, Szabo A, Shrieve DC, Tward JD](#). The Risk of Second Primary Malignancies up to Three Decades after the Treatment of Differentiated Thyroid Cancer. *J Clin Endocrinol Metab*. 2008 Feb;93(2):504-15.

285. Cignarelli, M, Ambrosi, A, Marino, A, Lamacchia, O, Cincione, R, Neri, V 2002 Three cases of papillary carcinoma and three of adenoma in thyroglossal duct cysts: clinical-diagnostic comparison with benign thyroglossal duct cysts. *J Endocrinol Invest* 25:947-54

286. Hazard, J, Hawk, W, Crile, G J 1959. Medullary (solid) carcinoma of the thyroid. A clinicopathologic entity. *J Clin Endocrinol Metab* 19:152

287. see 22

288. see 23

289. Suarez, H, du Villard, J, Caillou, B, Schlumberger, M, Parmentier, C, Monier, M 1991. Gsp mutations in human thyroid tumors. *Oncogene* 6:677-679

290. Manning, P, Molnar, G, Black, M, Priestley, J, Woolner, L 1963. Pheochromocytoma; hyperparathyroidism; and thyroid carcinoma occurring coincidentally. *N Engl J Med* 268:68

291. Gorlin, R, Sedano, H, Vickers, R, Cervenka, J 1968. Multiple mucosal neuromas; pheochromocytoma; and medullary carcinoma of the thyroid — a syndrome. *Cancer* 22:293

292. no entry

293. Gagel, R, Robinson, M, Donovan, D, Alford, B 1993. Medullary thyroid carcinoma. Recent

progress. *J Clin Endocrinol Metab* 76:809-814

294. Carney, J, Go, V, Sizemore, G, Hayles, A 1976. Alimentary-tract ganglioneuromatosis. *N Engl J Med* 295:1287

295 Noel, M, Delehay, M-C, Segond, N, et al. 1991. Study of calcitonin and thyroglobulin gene expression in human mixed follicular and medullary thyroid carcinoma. *Thyroid* 1:249

296. DeGroot, L, Hoyer, K, Refetoff, S, Van Herle, A, Asteris, G, Rochman, H 1977. Serum antigens and antibodies in the diagnosis of thyroid cancer. *J Clin Endocrinol Metab* 45:1220

297. Sobol, H, Narod, S N, Y, Boneu, A, et al. 1989. Screening for multiple endocrine neoplasia type 2a with DNA-polymorphism analysis. *N Engl J Med* 321:996-1001

298. Wolfe, H, Melvin, K, Cervi-Skinner, S, et al. 1973. C-cell hyperplasia preceding medullary thyroid carcinoma. *N Engl J Med* 289:437

299. Cox, T, Fagan, E, Hillyard, C, Allison, D, Chadwick, V 1979. Role of calcitonin in diarrhea associated with medullary carcinoma of the thyroid. *Gut* 20:629

300 Pacini, F, Basolo, F, Elisel, R, Fugazzola, L, Cola, A, Pinchera, A *Amer J Clin Pathol.* 95 300: 1991.

301- Kanamoto N, Akamizu T, Hosoda H, Hataya Y, Ariyasu H, Takaya K, Hosoda K, Saijo M, Moriyama K, Shimatsu A, Kojima M, Kangawa K, and Nakao K. Substantial production of Ghrelin by a human medullary thyroid carcinoma cell line. *J Clin Endocrinol Metab* 86:4984-4990, 2001

302. Cohen, S, Graham-Smith, D, MacIntyre, I, Walker, J 1973. Alcohol- stimulated calcitonin release in medullary carcinoma of the thyroid. *Lancet* 2:1172

303. Melvin, K, Tashjian, A 1968. The syndrome of excessive thyrocalcitonin produced by medullary carcinoma of the thyroid. *Proc Natl Acad Sci USA* 59:1216

304. see 200

305.. Larsson, C, Skogseid, B, Oberg, K, Nakamura, Y, Nordenskjold, M 1988. Multiple endocrine neoplasia type I gene maps to chromosome 11 and is lost in insulinoma. *Nature* 332:85-87

306 Quadro, L, Panariello, L, Salvatore, D, et al. 1994. Frequent RET proto-oncogene mutations in multiple endocrine neoplasia type 2A. *J Clin Endocrinol Metab* 79:590-594

307. Marsh, D, Learoyd, D, Robinson, B 1995. Medullary thyroid carcinoma. Recent advances and management update. *Thyroid* 5:407

308. Wohllk, N, Cote, G, Bugalho, M, et al. 1996. Relevance of RET proto-oncogene mutations in sporadic medullary thyroid carcinoma. *J Clin Endocrinol Metab* 81:3740-3745

309. Melvin, K, Miller, H, Tashjian, A 1971. Early diagnosis of medullary carcinoma of the thyroid gland by means of calcitonin assay. *N Engl J Med* 285:1115

310. Wahner, H, Cuello, C, Aljure, F 1968. Hormone-induced regression of medullary (solid) thyroid carcinoma. *Am J Med* 45:789

311. Barbot, N, Calmettes, C, Schuffenecker, I, et al. 1994. Pentagastrin stimulation test and early diagnosis of medullary thyroid carcinoma using an immunoradiometric assay of calcitonin. Comparison with genetic screening in hereditary medullary thyroid carcinoma. *J Clin Endocrinol Metab* 78:114-120

312. see 311

313. Calmettes, C, Moukhtar, M, Milhaud, G 1977. Correlation between calcitonin and carcinoembryonic antigen levels in medullary carcinoma of the thyroid. *Biomedicine* 27:52
314. Hoefnagel, C, Delprat, C, Zanin, D, Van Der Schoot, J 1988. New radionuclide tracers for the diagnosis and therapy of medullary thyroid carcinoma. *Clin Nucl Med* 13:159
315. see 311
316. Pacini, F, Ceccherini, I, Martino, E, et al. Abstract No. 182. Screening for ret gene mutations in multiple endocrine neoplasia (MEN) type 2 and in sporadic medullary thyroid carcinoma (MTC). clinical applications. Sixty-eighth annual meeting of the American Thyroid Association Chicago; IL: September 28-October 1; 1994
317. Sobol, H, Narod, S N, Y, Boneu, A, et al. 1989. Screening for multiple endocrine neoplasia type 2a with DNA-polymorphism analysis. *N Engl J Med* 321:996-1001
318. Lips, C, Landsvater, R, Hoppener, J, et al. 1994. Clinical screening as compared with DNA analysis in families with multiple endocrine neoplasia type 2A. *N Engl J Med* 331:828-835
319. Black, H, Capen, C, Young, D 1973. Ultimobranchial thyroid neoplasms in bulls. *Cancer* 32:865
- 319a. Machens, A; Niccoli-Sire, P; Hoegel, J; Frank-Raue, K; van Vroonhoven, TJ; Roehner, H-D; Wahl, RA; Lamesch, P; Raue, F; Conte-Devolx, B; Dralle, H. Early malignant progression of hereditary medullary thyroid cancer. *N Engl J Med* 349 1517-1525 2003.
320. Graze, K, Spiler, I, Tashijan, A J, et al. 1978. Natural history of familial medullary thyroid carcinoma. *N Engl J Med* 299:980
- 320.1 Scollo C, Baudin E, Travagli J-P, Caillou B, Bellon N, Leboulleux S, Schlumberger M. Rationale for central and bilateral lymph node dissection in sporadic and hereditary medullary thyroid cancer. *J Clin Endocrinol Metab* 88:2070-2075, 2003.
321. . Deftos, L, Stein, M 1980. Radioiodine as an adjunct to the surgical treatment of medullary thyroid carcinoma. *J Clin Endocrinol Metab* 50:967
322. Hellman, D, Kartchner, M, Van Antwerp, J, Salmon, S, Patton, D, O'Mara, R 1979. Radioiodine in the treatment of medullary carcinoma of the thyroid. *J Clin Endocrinol Metab* 48:451
323. Kim, S, Morimoto, S, Kawa, i Y, Koh, E, Onishi, T, Ogihara, T 1989. Circulating levels of calcitonin gene-related peptide in patients with medullary thyroid carcinoma. *J Clin Chem Clin Biochem* 27:423
324. Moley, J, Wells, S, Dilley, W, Tisell, L 1993. Reoperation for recurrent or persistent medullary thyroid cancer. *Surgery* 114:1090-1095
325. Frank-Raue, K, Raue, F, Buhr, H, Baldauf, G, Lorenz, D, Ziegler, R 1992. Localization of occult persisting medullary thyroid carcinoma before microsurgical reoperation. High sensitivity of selective venous catheterization. *Thyroid* 2:113
326. Simpson, W 1975. Radiotherapy in thyroid cancer. *Can Med Assoc J* 113:115
327. Brierley, J, Tsang, R, Simpson, W, Gospodarowicz, M, Sutcliffe, S, Panzarella, T 1996. Medullary thyroid cancer. Analyses of survival and prognostic factors and the role of radiation therapy in local control. *Thyroid* 6:305-310
328. Fersht, N, Vini, L, A'Hern, R, Harmer, C 2001 The role of radiotherapy in the management of elevated calcitonin after surgery for medullary thyroid cancer. *Thyroid* 11:1161-8
329. Samaan, N, Schultz, P, Hickey, R Medullary thyroid carcinoma. Prognosis of familial versus

nonfamilial disease and the role of radiotherapy.

330. Hoefnagel, C, Delprat, C, Zanin, D, Van Der Schoot, J 1988. New radionuclide tracers for the diagnosis and therapy of medullary thyroid carcinoma. *Clin Nucl Med* 13:159

331 DeGroot, L 1970. Lack of iodide trapping in “cold” thyroid nodules. *Acta Endocrinol Panam* 1:27

332. Kim, B W, Daniels, G H, Harrison, B J, et al. 2003 Overexpression of type 2 iodothyronine deiodinase in follicular carcinoma as a cause of low circulating free thyroxine levels. *J Clin Endocrinol Metab* 88:594-8

333. Huang, S A, Fish, S A, Dorfman, D M, et al. 2002 A 21-year-old woman with consumptive hypothyroidism due to a vascular tumor expressing type 3 iodothyronine deiodinase. *J Clin Endocrinol Metab* 87:4457-61

334. Abe, Y, Ichikawa, Y, Muraki, T, Ito, K, Momma, M 1981. Thyrotropin (TSH) receptor and adenylate cyclase activity in human thyroid tumors. Absence of high affinity receptor and loss of TSH responsiveness in undifferentiated thyroid carcinoma. *J Clin Endocrinol Metab* 52:23

335. Carayon, P, Thomas-Morvan, C, Castanas, E, Tubiana, M 1980. Human thyroid cancer. Membrane thyrotropin binding and adenylate cyclase activity. *J Clin Endocrinol Metab* 51:915

336. 1. Burke, G, Szabo, M 1972. Dissociation of in vivo and in vitro “autonomy” in hyperfunctioning thyroid nodules. *J Clin Endocrinol Metab* 35:199

337. 1. Van Sande, J, Mockel, J, Boeynaems, J, Dor, P, Andry, G, Dumont, J 1980. Regulation of cyclic nucleotide and prostaglandin formation in normal human thyroid tissue and in autonomous nodules. *J Clin Endocrinol Metab* 50:776

337a. Castro P, Rebocho AP, Soares RJ, Magalhaes J, Roque L, Trovisco V, Vieira de Castro I, Cardoso-de-Oliveira M, Fonseca E, Soares P, Sobrinho-Simoes M. PAX8-PPARgamma rearrangement is frequently detected in the follicular variant of papillary thyroid carcinoma *J Clin Endocrinol Metab*. 2006 Jan;91(1):213-20.

337b. Xing M, Westra WH, Tufano RP, Cohen Y, Rosenbaum E, Rhoden KJ, Carson KA, Vasko V, Larin A, Tallini G, Tolaney S, Holt EH, Hui P, Umbricht CB, Basaria S, Ewertz M, Tufano AP, Califano JA, Ringel MD, Zeiger MA, Sidransky D, Ladenson PW. BRAF mutation predicts a poorer clinical prognosis for papillary thyroid cancer *J Clin Endocrinol Metab*. 2005 Dec;90(12):6373-9

337.c Guarino V, Faviana P, Salvatore G, Castellone MD, Cirafici AM, De Falco V, Celetti A, Giannini R, Basolo F, Melillo RM, Santoro M. Osteopontin is overexpressed in human papillary thyroid carcinomas and enhances thyroid carcinoma cell invasiveness. *Clin Endocrinol Metab*. 2005 Sep;90(9):5270-8

338. 1. Franklin, W, Mariotti, S, Kaplan, D, DeGroot, L 1982. Immunofluorescence localization of thyroglobulin in metastatic thyroid cancer. *Cancer* 50:939

339. Goudie, R, McCallum, H 1963. Loss of tissue-specific autoantigens in thyroid tumors. *Lancet* 1:348

340. Pontius, K, Hawk, W 1980. Loss of microsomal antigen in follicular and papillary carcinoma of the thyroid. An immunofluorescence and electron-microscope study. *Am J Pathol* 74:620

341. Meier, D, Woolner, L, Behrs, O, McConahey, W 1959. Parenchymal findings in thyroid carcinoma. Pathologic study of 256 cases. *J Clin Endocrinol Metab* 19:162

342. to be entered

343. to be entered

344 DeGroot, L, Hoyer, K, Refetoff, S, Van Herle, A, Asteris, G, Rochman, H 1977. Serum antigens and antibodies in the diagnosis of thyroid cancer. *J Clin Endocrinol Metab* 45:1220

345 Aoki, N, DeGroot, L 1979. Lymphocyte blastogenic response to human thyroglobulin in Graves' disease; Hashimoto's thyroiditis; and metastatic thyroid cancer. *Clin Exp Immunol* 38:523

346. Amino, N, Pysker, T, Cohen, E, DeGroot, L 1975. Immunologic aspects of human thyroid cancer. *Cancer* 36:963

347. Mariotti, S, DeGroot, L, Scarborough, D, Medof, M 1979. Study of circulating immune complexes in thyroid diseases. Comparison of Raji cell radioimmunoassay and specific thyroglobulin-antithyroglobulin radioassay. *J Clin Endocrinol Metab* 49:679

348. Pacini, F, Mariotti, S, Formica, N, et al. 1988 Thyroid autoantibodies in thyroid cancer. Incidence and relationship with tumour outcome. *Acta Endocrinol (Copenh)* 119:373

349. Rubello, D, Casara, D, Girelli, M, Piccolo, M, Busnardo, B 1992. Clinical meaning of circulating antithyroglobulin antibodies in differentiated thyroid cancer. a prospective study. *J Nucl Med* 33:1478

350. Rocklin, E, Gagel, R, Feldman, Z, Tashjian, A J 1977. Cellular immune responses in familial medullary thyroid carcinoma. *N Engl J Med* 296:835

351. Belfiore, A, Garofalo, M, Giuffrida, D, et al. 1990. Increased aggressiveness of thyroid cancer in patients with Graves' disease. *J Clin Endocrinol Metab* 70:830

352. Pellegriti, G, Belfiore, A, Giuffrida, D, Lupo, L, Vigneri, R 1998. Outcome of differentiated thyroid cancer in Graves' patients. *J Clin Endocrinol Metab* 83:2805

353. Filetti, S, Belfiore, A, Amir, S, et al. 1988. The role of thyroid-stimulating antibodies of Graves' disease in differentiated thyroid cancer. *N Engl J Med* 318:753

354. Wu, P-C, Leslie, P, McLaren, K, Toft, A 1989. Diffuse sclerosing papillary carcinoma of thyroid. A wolf in sheep's clothing. *Clin Endocrinol* 31:535

355. Cignarelli, M, Triggiani, V, Ciampolillo, A, et al. 2001. High frequency of incidental diagnosis of extrathyroidal neoplastic diseases at the fine-needle aspiration biopsy of laterocervical lymph nodes in patients with thyroid nodules. *Thyroid* 11:65

356. Van Herle, A, Uller, R 1975. Elevated serum thyroglobulin. A marker of metastases in differentiated thyroid carcinomas. *J Clin Invest* 56:272

356a. [Costante G](#) , [Meringolo D](#) , [Durante C](#) , [Bianchi D](#) , [Nocera M](#) , [Tumino S](#) , [Crocetti U](#) , [Attard M](#) , [Maranghi M](#) , [Torlontano M](#) , [Filetti S](#) Predictive value of serum calcitonin levels for preoperative diagnosis of medullary thyroid carcinoma in a cohort of 5817 consecutive patients with thyroid nodules. *J Clin Endocrinol Metab*. 2007 Feb;92(2):450-5

357. Meighan, J, Dworkin, H 1969. Failure to detect 131I positive thyroid metastases with 99mTc. *J Nucl Med* 11:173

358. Fairweather, D, Bradwell, A, Watson-James, S, Dykes, P, Chandler, S, Hoffenberg, R 1983. Detection of thyroid tumors using radio-labelled thyroglobulin. *Clin Endocrinol* 18:563

359. O'Byrne, K, Hamilton, D, Robinson, I, al., e 1992. Imaging of medullary carcinoma of the thyroid using 111In-labelled anti-CEA monoclonal antibody fragments. *Nucl Med Commun* 13:142

360. Thomas, C, Pepper, F, Owen, J 1969. Differentiation of malignant from benign lesions of the thyroid gland using complementary scanning with 75Selenomethionine and radioiodide. *Ann Surg*

170:396

361 Yano, K, Morita, S, Furukawa, Y, al., e 1978. Diagnosis of malignant neoplasms with ²⁰¹Ti chloride. *Jpn J Nucl Med* 15:989

362. to be added

363. Higashi, T, Ito, K, Nishikawa, Y, al., e 1988. Gallium-67 imaging in the evaluation of thyroid malignancy. *Clin Nucl Med* 13:792

364. Skowsky, W, Wilf, L 1991. ¹³¹Iodine metaiodobenzylguanidine scintigraphy of medullary carcinoma of the thyroid. *South Med J* 84:636

365. Lamberts, S, Reubi, J-C, Krenning, E 1993. Validation of somatostatin receptor scintigraphy in the localization of neuroendocrine tumors. *Acta Oncol* 32:167

366. see 359

367. Wang, W, Larson, S, Fazzari, M, et al. 2000. Prognostic value of [¹⁸F]-Fluorodeoxy-glucose positron emission tomographic scanning in patients with thyroid cancer. *J Clin Endocrinol Metab* 85:1107-1113

367.1 van Tol KM, Jager PL, Piers A, Pruim J, de Vries EGE, Dullaart RPF, Links TP. Better yield of ¹⁸F-fluorodeoxyglucose-positron emission tomography in patients with metastatic differentiated thyroid carcinoma during thyrotropin stimulation. *Thyroid* 12:381, 2002.

367a. Chin, BB; Patel, P; Cohade, C; Ewertz, M; Wahl, R; Ladenson, P. Recombinant human thyrotropin stimulation of fluoro-D-glucose positron emission tomography uptake in well-differentiated thyroid carcinoma. *J Clin Endocrinol Metab* 89 91-95 2004.

367b. Kim JM, Ryu JS, Kim TY, Kim WB, Kwon GY, Gong G, Moon DH, Kim SC, Hong SJ, Shong YK. ¹⁸F-fluorodeoxyglucose positron emission tomography does not predict malignancy in thyroid nodules cytologically diagnosed as follicular neoplasm. *J Clin Endocrinol Metab*. 2007 May;92(5):1630-4

368. Ridder, R, Willeke, F, Lacroix, J, et al. Detection of thyroglobulin mRNA in peripheral blood of patients with thyroid cancer.

369a. Elisei, R; Vivaldi, A; Agate, L; Molinaro, E; Nencetti, C; Grasso, L; Pinchera, A; Pacini, F. Low specificity of blood thyroglobulin messenger ribonucleic acid assay prevents its use in the follow-up of differentiated thyroid cancer patients. *J Clin Endocrinol Metab* 89 29-32 2004.

369b. [Chia SY, Milas M, Reddy SK, Siperstein A, Skugor M, Brainard J, Gupta MK](#). Thyroid-stimulating hormone receptor messenger ribonucleic acid measurement in blood as a marker for circulating thyroid cancer cells and its role in the preoperative diagnosis of thyroid cancer. *J Clin Endocrinol Metab*. 2007 Feb;92(2):468-75

370. Harmer, M Springer-Verlag Application of TNM classification rules to malignant tumors of the thyroid gland; in Hedinger CE (ed). *Thyroid Cancer*. UICC Monograph Series 12.64: Berlin

371. Sobin LH, Wittekind Ch (eds) *TNM Classification of Malignant Tumors*, 6th Edition . Wiley-Liss, New York, pp 52-56

371a. Tennvall J, Biorklund A, Moller T et al. Is the EORTC prognostic index of thyroid cancer valid in differentiated thyroid Carcinoma? *Cancer* 57:1405, 1986

371b. Pasiaka JL, Zedenius J, Azuer G et al; Addition of nuclear content to the AMES risk-group classification for papillary thyroid cancer: *Surgery* 112:1154, 1992.

- 371c. Hay ID, Bergstralh EJ, Goellner JR, et al. Predicting outcome in papillary thyroid carcinoma. *Surgery* 114: 1050, 1993.
372. Yano, K, Morita, S, Furukawa, Y, al., e 1978. Diagnosis of malignant neoplasms with 201Ti chloride. *Jpn J Nucl Med* 15:989
373. Van Herle, A, Uller, R 1975. Elevated serum thyroglobulin. A marker of metastases in differentiated thyroid carcinomas. *J Clin Invest* 56:272
374. see 370
375. to be added
376. Buckwalter, J, Thomas, C 1972. Selection of surgical treatment for well differentiated thyroid carcinomas. *Ann Surg* 176:565
377. Tollefsen, H, Shah, J, Huvos, A 1972. Papillary carcinoma of the thyroid. Recurrence in the thyroid gland after initial surgical treatment. *Am J Surg* 124:468
378. Rickey, O, Howard, R 1967. Cancer of the thyroid. *Am J Surg* 112:637
379. to be added
380. Clark, R, Ibanez, M, White, E 1966. What constitutes an adequate operation for carcinoma of the thyroid? *Arch Surg* 92:23
381. Rustad, W, Lindsay, S, Dailey, M 1963. Comparison of the incidence of complications following total and subtotal thyroidectomy for thyroid carcinoma. *Surg Gynecol Obstet* 116:109
382. Thompson, N, Harness, J; 1970. Complications of total thyroidectomy for carcinoma. *Surg Gynecol Obstet* 131:861
383. Samaan, N, Schultz, P, Hickey, R, et al. 1992. The results of various modalities of treatment of well differentiated thyroid carcinoma. A retrospective review of 1599 patients. *J Clin Endocrinol Metab* 75:714-720
384. Tollefson, H, DeCosse, J 1964. Papillary carcinoma of the thyroid. The case for radical neck dissection. *Am J Surg* 108:547
385. Crile, G J, Suhrer, J J, Hazard, J 1955. Results of conservative operations for malignant tumors of the thyroid. *J Clin Endocrinol Metab* 15:1422
386. Crile, G J 1971. Changing end results in patients with papillary carcinoma of the thyroid. *Surg Gynecol Obstet* 132:460
387. Glass, H, Waldron, G, Allen, H J, Brown, W 1960. A rational approach to the thyroid malignancy problem. *Am Surg* 26:81
388. see 385
389. see 386
390. Cady, B, Sedgwick, C, Meissner, W, Bookwalter, J, Romagosa, V, Werber, J 1976. Changing clinical; pathologic; therapeutic; and survival patterns of differentiated thyroid carcinoma. *Ann Surg* 184:541
391. see 376.
392. see 376
- 393.

394. Shands, W, Gatling, R 1970. Cancer of the thyroid. Review of 109 cases. *Ann Surg* 171:735
- 395.
396. see 384
- 397.
398. to be entered
- 399.
400. see 378
- 401.
402. see 376
- 403.
404. see 380
- 405.
406. see 378
- 407.
400. Tollefsen, H, Shah, J, Huvos, A 1972. Papillary carcinoma of the thyroid. Recurrence in the thyroid gland after initial surgical treatment. *Am J Surg* 124:468
401. Rosvoll, R, Winship, T 1965. Thyroid carcinoma and pregnancy. *Surg Gynecol Obstet* 121:1039
402. Samaan, N, Schultz, P, Hickey, R, et al. 1992. The results of various modalities of treatment of well differentiated thyroid carcinoma. A retrospective review of 1599 patients. *J Clin Endocrinol Metab* 75:714-720
403. Hay, I, Grant, C, Bergstralh, E, Thompson, G, van Heerden, J, Goellner, J 1998. Unilateral total lobectomy. Is it sufficient surgical treatment for patients with AMES low-risk papillary thyroid carcinoma? *Surgery* 124:958-966
404. Rustad, W, Lindsay, S, Dailey, M 1963. Comparison of the incidence of complications following total and subtotal thyroidectomy for thyroid carcinoma. *Surg Gynecol Obstet* 116:109
405. Thompson, N, Harness, J; 1970. Complications of total thyroidectomy for carcinoma. *Surg Gynecol Obstet* 131:861
406. Mazzaferri, E, Young, R, Oertel, J, Kemmerer, W, Page, C 1977. Papillary thyroid carcinoma. The impact of therapy in 576 patients. *Medicine* 56:171
407. Tollefson, H, DeCosse, J 1964. Papillary carcinoma of the thyroid. The case for radical neck dissection. *Am J Surg* 108:547
408. see 407
409. Glass, H, Waldron, G, Allen, H J, Brown, W 1960. A rational approach to the thyroid malignancy problem. *Am Surg* 26:81
410. Hirabayashi, R, Lindsay, S 1961. Carcinoma of the thyroid gland—a statistical study of 390 patients. *J Clin Endocrinol Metab* 21:1596
411. Hay, I, Bergstralh, E, Goellner, J, Ebersold, J, Grant, C 1993. Predicting outcome in papillary thyroid carcinoma. development of a reliable prognostic scoring system in a cohort of 1779 patients

- surgically treated at one institution during 1940 through 1989. *Surgery* 114:1050-1057
412. Meissner, W, Colcock, B, Achenback, H 1955. The pathologic evaluation of radical neck dissection for carcinoma of the thyroid gland. *J Clin Endocrinol Metab* 15:1432
- 412.1 Bonnet S, Hartl D, Leboulleux S, Baudin E, Lumbroso JD, Al Ghuzlan A, Chami L, Schlumberger M, Travagli JP. [Prophylactic lymph node dissection for papillary thyroid cancer less than 2 cm: implications for radioiodine treatment.](#) *J Clin Endocrinol Metab.* 2009 Apr;94(4):1162-7.
- 412.2 Chung YS, Kim JY, Bae JS, Song BJ, Kim JS, Jeon HM, Jeong SS, Kim EK, Park WC. [Lateral lymph node metastasis in papillary thyroid carcinoma: results of therapeutic lymph node dissection.](#) *Thyroid.* 2009 Mar;19(3):241-6.
- 412.3 Lim YC, Choi EC, Yoon YH, Kim EH, Koo BS. [Central lymph node metastases in unilateral papillary thyroid microcarcinoma.](#) *Br J Surg.* 2009 Mar;96(3):253-7.
- 412.4 White ML, Gauger PG, Doherty GM. [Central lymph node dissection in differentiated thyroid cancer.](#) *World J Surg.* 2007 May;31(5):895-904.
413. see 411
414. Block, G, Wilson, S 1971. A modified neck dissection for carcinoma of the thyroid. *Surg Clin North Am* 51:139
415. Mustard, R 1970. Treatment of papillary carcinoma of the thyroid with emphasis on conservative neck dissection. *Am J Surg* 120:697
416. McGovern, J, Mannex, H J 1967. Thirty year experience with thyroid cancer. *NY State J Med* 67:2207
417. Exelby, P, Frazell, E 1969. Carcinoma of the thyroid in children. *Surg Clin North Am* 49:249
418. Werk, E, Vernon, B, Gonzalez, J, Ungaro, P, McCoy, R 1984. Cancer in thyroid nodules. A community hospital survey. *Arch Intern Med* 144:474
- 418a [Triponez F, Poder L, Zarnegar R, Goldstein R, Roayaie K, Feldstein V, Lee J, Kebebew E, Duh QY, Clark OH.](#) Hook needle-guided excision of recurrent differentiated thyroid cancer in previously operated neck compartments: a safe technique for small, nonpalpable recurrent disease. *J Clin Endocrinol Metab.* 2006 Dec;91(12):4943-7
419. Klapp, C, Rosvoli, R, Winship, T 1967. Is destructive surgery ever necessary for treatment of thyroid cancer in children? *Ann Surg* 165:745
420. Wolf, G, Kohek, P, Geyer, E, et al. 1996. Intraoperative radiation therapy; endotracheal hyperthermia and IR-192-brachytherapy in patients with advanced thyroid cancer. *Acta Medica Austriaca* 23:76-79
421. Nishida, T, Nakao, K, Hamaji, M 1997. Differentiated thyroid carcinoma with airway invasion. Indication for tracheal resection based on the extent of cancer invasion. *J Thorac Cardiovas Surg* 114:84-92
422. Ozaki, O, Sugino, K, Mimura, T, Ito, K 1995. Surgery for patients with thyroid carcinoma invading the trachea. Circumferential sleeve resection followed by end-to-end anastomosis. *Surgery* 117:268-271
423. Sugeno, A, Matsuo, K, Asanuma, K, et al. 1995. Management of tracheal wall resection for thyroid carcinoma by tracheocutaneous fenestration and delayed closure using auricular cartilage. *Head & Neck* 17:339-342

424. Schlumberger, M, Arcangioli, O, Piekarski, J, Tubiana, M, Parmentier, C 1988. Detection and treatment of lung metastases of differentiated thyroid carcinoma in patients with normal chest X-rays. *J Nucl Med* 29:1790-1794
425. Ruegamer, J, Hay, I, Bergstrahl, E, Ryan, J, Offord, K, Gorman, C 1988. Distant metastases in differentiated thyroid carcinoma. A multivariate analysis of prognostic variables. *J Clin Endocrinol Metab* 67:501-508
- 425.1 Hovens GC, Stokkel MP, Kievit J, Corssmit EP, Pereira AM, Romijn JA, Smit JW. [Associations of serum thyrotropin concentrations with recurrence and death in differentiated thyroid cancer.](#) *J Clin Endocrinol Metab.* 2007 Jul;92(7):2610-5.
426. Exelby, P, Frazell, E 1969. Carcinoma of the thyroid in children. *Surg Clin North Am* 49:249
427. Klapp, C, Rosvoli, R, Winship, T 1967. Is destructive surgery ever necessary for treatment of thyroid cancer in children? *Ann Surg* 165:745
428. Liechty, R, Safaie-Shirazi, S, Soper, R 1972. Carcinoma of the thyroid in children. *Surg Gynecol Obstet* 134:595
429. Pacini, F, Gasperi, M, Fugazzola, L, et al. 1994. Testicular function in patients with differentiated thyroid carcinoma treated with radioiodine. *J Nucl Med* 35:1418
430. McClellan, D, Francis, G 1996. Thyroid cancer in children; pregnant women; and patients with Graves' disease. *Endocrinol Metab Clinics North America* 25:27-48
431. Casara, D, Rubello, D, Saladini, G, et al. 1993. Pregnancy after therapeutic doses of iodine-131 in differentiated thyroid cancer. potential risks and recommendations. *Eur J Nucl Med* 20:192
432. Schlumberger, M, De Vathaire, F, Ceccarelli, C, et al. 1996. Exposure to radioactive iodine-131 for scintigraphy or therapy does not preclude pregnancy in thyroid cancer patients. *J Nucl Med* 37:606
433. Schlumberger, M, De Vathaire, F, Travagli, J, et al. 1987. Differentiated thyroid carcinoma in childhood. Long term follow-up of 72 patients. *J Clin Endocrinol Metab* 65:1088
- 433a. [Ali N, Sebastian C, Foley RR, Murray I, Canizales AL, Jenkins PJ, Drake WM, Plowman PN, Besser GM, Chew SL, Grossman AB, Monson JP, Britton KE.](#) The management of differentiated thyroid cancer using 123I for imaging to assess the need for 131I therapy. *Nucl Med Commun.* 2006 Feb;27(2):165-9.
434. Cady, B, Sedgwick, C, Meissner, W, Bookwalter, J, Romagosa, V, Werber, J 1976. Changing clinical; pathologic; therapeutic; and survival patterns of differentiated thyroid carcinoma. *Ann Surg* 184:541
435. Mazzaferri, E, Young, R, Oertel, J, Kemmerer, W, Page, C 1977. Papillary thyroid carcinoma. The impact of therapy in 576 patients. *Medicine* 56:171
436. Mazzaferri, E, Young, R 1981. Papillary thyroid carcinoma. A ten year follow-up report of the impact of therapy in 576 patients. *Am J Med* 70:511
- 437.see 436
438. Samaan, N, Schultz, P, Hickey, R, et al. 1992. The results of various modalities of treatment of well differentiated thyroid carcinoma. A retrospective review of 1599 patients. *J Clin Endocrinol Metab* 75:714-720
- 438.1 Mazzaferri EL. Management of low-risk differentiated thyroid cancer. *Endocr Pract.* 2007 Sep-Oct;13(5):498-512

- 438.2 Hay ID. Management of patients with low-risk papillary thyroid carcinoma. *Endocr Pract.* 2007 Sep-Oct;13(5):521-33
- 438.3 Hay ID, Hutchinson ME, Gonzalez-Losada T, McIver B, Reinalda ME, Grant CS, Thompson GB, Sebo TJ, Goellner JR. Papillary thyroid microcarcinoma: a study of 900 cases observed in a 60-year period. *Surgery.* 2008 Dec;144(6):980-7
439. DeGroot, L, Reilly, M 1982. Comparison of 30- and 50-mCi doses of iodine-131 for thyroid ablation. *Ann Intern Med* 96:51
440. Roos, D e a 1999. Review of trials assessing low dose radioactive iodine ablation for thyroid remnants in patients with thyroid cancer. *International J Rad Oncol Biol Physiol* 44:493-495. 1.
- 440.1 Hackshaw A, Harmer C, Mallick U, Haq M, Franklyn JA. 131I Activity for Remnant Ablation Ablation in Patients with Differentiated Thyroid Cancer: A Systematic Review. *J Clin Endocrinol Metab.* 2007 Jan;92(1):28-38.
- 440.2 Pilli T, Brianzoni E, Capocchetti F, Castagna MG, Fattori S, Poggiu A, Rossi G, Ferretti F, Guarino E, Burrioni L, Vattimo A, Cipri C, Pacini F. A Comparison of 1850 (50 mCi) and 3700 MBq (100 mCi) 131-Iodine Administered Doses for Recombinant Thyrotropin-Stimulated Postoperative Thyroid Remnant Ablation in Differentiated Thyroid Cancer. *J Clin Endocrinol Metab.* 2007 Sep;92(9):3542-6
- 440.4 Van Nostrand D, Aiken M, Atkins F, Moreau S, Garcia C, Acio E, Burman K, Wartofsky L. The Utility of Radioiodine Scans Prior to (131)I Ablation in Patients with Well-Differentiated Thyroid Cancer. *Thyroid.* 2009 Mar 13.
- 440a. [Torlontano M](#) , [Crocetti U](#) , [Augello G](#) , [D'Aloiso L](#) , [Bonfitto N](#) , [Varraso A](#) , [Dicembrino F](#) , [Modoni S](#) , [Frusciante V](#) , [Di Giorgio A](#) , [Bruno R](#) , [Filetti S](#) , [Trischitta V](#) . Comparative Evaluation of Recombinant Human Thyrotropin-Stimulated Thyroglobulin Levels, 131I Whole-Body Scintigraphy, and Neck Ultrasonography in the Follow-Up of Patients with Papillary Thyroid Microcarcinoma Who Have Not Undergone Radioiodine Therapy. *J Clin Endocrinol Metab.* 2006 Jan;91(1):60-3.
- 440b. [Czepczynski R](#) , [Ziemnicka K](#) , [Baczyk M](#) , [Oleksa R](#) , [Ruchala M](#) , [Sowinski J](#) . Fractionated dosage of radioiodine for the ablation of differentiated thyroid carcinoma. *Thyroid.* 2005 Nov;15(11):1261-5.
- 440c. *Nucl Med Commun.* 2003 May;24(5):489-95. Influence of diagnostic and therapeutic doses on thyroid remnant ablation rates. Karam M, Gianoukakis A, Feustel PJ, Cheema A, Postal ES, Cooper JA.
441. Wartofsky, L, Sherman, S, Gopal, J, Schlumberger, M, Hay, I 1998. The use of radioactive iodine in patients with papillary and follicular thyroid cancer. *J Clin Endocrinol Metab* 83:4195-4203
442. Caplan, R, Abellera, R, Kiskin, W 1994. Hurthle cell neoplasms of the thyroid gland. Reassessment of functional capacity. *Thyroid* 4:243
423. Carcangiu, M, Bianchi, S, Savino, D, Voynick, I, Rosai, J 1991. Follicular Hurthle cell tumors of the thyroid gland. *Cancer* 68:1944-1953
- 424.
444. Pacini, F, Molinaro, E, Castagna, M G, et al. 2002 Ablation of thyroid residues with 30 mCi (131)I: a comparison in thyroid cancer patients prepared with recombinant human TSH or thyroid hormone withdrawal. *J Clin Endocrinol Metab* 87:4063-8
445. Robbins, R J, Tuttle, R M, Sonenberg, M, et al. 2001 Radioiodine ablation of thyroid remnants after preparation with recombinant human thyrotropin. *Thyroid* 11:865-9

- 445a. Kuijt WJ, Huang SA.; Children with Differentiated Thyroid Cancer Achieve Adequate Hyperthyrotropinemia within 14 Days of Levothyroxine Withdrawal. *J Clin Endocrinol Metab.* 2005 Aug 9
446. Guimaraes, V, DeGroot, L 1996. Moderate hypothyroidism in preparation for whole body 131I scintiscans and thyroglobulin testing. *Thyroid* 6:69-73
447. Schlumberger, M 1998. Papillary and follicular thyroid carcinoma. *N Engl J Med* 338:297-306
448. Dow, K, Ferrell, B, Anello, C 1997. Quality of life changes in patients with thyroid cancer after withdrawal of thyroid hormone therapy. *Thyroid* 7:613-619
449. Ramirez, L, Braverman, L, White, B, Emerson, C 1997. Recombinant human thyrotropin is a potent stimulator of thyroid function in normal subjects. *J Clin Endocrinol Metab* 82:2836-2839
450. Meier, C, Braverman, L, Ebner, S, et al. 1994. Diagnostic use of recombinant human thyrotropin in patients with thyroid carcinoma (phase I/II study). *J Clin Endocrinol Metab*; 78:188-96
451. Ladenson, P, Braverman, L, Mazzaferri, E, al., e 1997. Comparison of administration of recombinant human thyrotropin with withdrawal of thyroid hormone for radioactive iodine scanning in patients with thyroid carcinoma. *N Engl J Med* 337:888-95
452. Haugen, B, Pacini, F, Reiners, C, et al. 1999. A comparison of recombinant human thyrotropin and thyroid hormone withdrawal for the detection of thyroid remnant or cancer. *J Clin Endocrinol Metab* 84:3877-3885
- 452.1 Driedger, AA; Kotowycz, N. Two cases of thyroid carcinoma that were not stimulated by recombinant human thyrotropin. *J Clin Endocrinol Metab* 89 585-590 2004.
- 452.2 Hänscheid H, Lassmann M, Luster M, Thomas SR, Pacini F, Ceccarelli C, Ladenson PW, Wahl RL, Schlumberger M, Ricard M, Driedger A, Kloos RT, Sherman SI, Haugen BR, Carriere V, Corone C, Reiners C. Iodine biokinetics and dosimetry in radioiodine therapy of thyroid cancer: procedures and results of a prospective international controlled study of ablation after rhTSH or hormone withdrawal. *J Nucl Med.* 2006 Apr;47(4):648-54
- 452.3 Pacini F, Molinaro E, Castagna MG, Lippi F, Ceccarelli C, Agate L, Elisei R, Pinchera A. Ablation of thyroid residues with 30 mCi (131)I: a comparison in thyroid cancer patients prepared with recombinant human TSH or thyroid hormone withdrawal. *J Clin Endocrinol Metab.* 2002 Sep;87(9):4063-8
- 452.4 Berg G, Andersson T, Sjodell L, Jansson S, Nystrom E. Development of severe thyroid-associated ophthalmopathy in a patient with disseminated thyroid cancer treated with recombinant human thyrotropin/radioiodine and retinoic acid. *Thyroid.* 2005 Dec;15(12):1389-94
- 452a. Sorvillo, F; Mazziotti, G; Carbone, A; Piscopo, M; Rotondi, M; Cioffi, M; Musto, P; Biondi, B; Iorio, S; Amato, G; Carella, C. Recombinant human thyrotropin reduces serum vascular endothelial growth factor levels in patients monitored for thyroid carcinoma even in the absence of thyroid tissue. *J Clin Endocrinol Metab* 88 4818-4822 2003.
- 452b [Luster M, Lippi F, Jarzab B, Perros P, Lassmann M, Reiners C, Pacini F.](#) rhTSH-aided radioiodine ablation and treatment of differentiated thyroid carcinoma: a comprehensive review. *Endocr Relat Cancer.* 2005 Mar;12(1):49-64.
453. Bachelot, A, Cailleux, A F, Klain, M, et al. 2002 Relationship between tumor burden and serum thyroglobulin level in patients with papillary and follicular thyroid carcinoma. *Thyroid* 12:707-11
454. Pacini, F, Capezzone, M, Elisei, R, Ceccarelli, C, Taddei, D, Pinchera, A 2002 Diagnostic 131-

iodine whole-body scan may be avoided in thyroid cancer patients who have undetectable stimulated serum Tg levels after initial treatment. *J Clin Endocrinol Metab* 87:1499-501

455. Pacini F, Molinaro E, Lippi F, Castagna MG, Agate L, Ceccarelli C, Taddei D, Elisei R, Capezzone M, and Pinchera A. Prediction of disease status by recombinant human TSH-stimulated serum Tg in the postsurgical follow-up of differentiated thyroid carcinoma. *J Clin Endocrinol Metab* 86:5686-5690, 2001

455a. [Phan HT](#) , [Jager PL](#) , [van der Wal JE](#) , [Sluiter WJ](#) , [Plukker JT](#) , [Dierckx RA](#) , [Wolffenbuttel BH](#) , [Links TP](#) . The follow-up of patients with differentiated thyroid cancer and undetectable thyroglobulin (Tg) and Tg antibodies during ablation. *Eur J Endocrinol*. 2008 Jan;158(1):77-83 : *Eur J Endocrinol*. 2008 Jan;158(1):77-83.

455b. [Castagna MG](#) , [Brilli L](#) , [Pilli T](#) , [Montanaro A](#) , [Cipri C](#) , [Fioravanti C](#) , [Sestini F](#) , [Capezzone M](#) , [Pacini F](#) . Limited value of repeat recombinant human thyrotropin (rhTSH)-stimulated thyroglobulin testing in differentiated thyroid carcinoma patients with previous negative rhTSH-stimulated thyroglobulin and undetectable basal serum thyroglobulin levels. *J Clin Endocrinol Metab*. 2008 Jan;93(1):76-81

456. Mazzaferri, E, Kloos, R 2002. Is diagnostic Iodine-131 scanning with recombinant human TSH useful in the follow-up of differentiated thyroid cancer after thyroid ablation? *J Clin Endocrinol Metab* 87:1490-1498

457. Wartofsky, L 2002. Using baseline and recombinant human TSH-stimulated tg measurements to manage thyroid cancer without diagnostic 131I scanning. *J Clin Endocrinol Metab* 87:1486-1489

458. Wartofsky, L 2002 Management of low-risk well-differentiated thyroid cancer based only on thyroglobulin measurement after recombinant human thyrotropin. *Thyroid* 12:583-90

459a Pacini F, Schlumberger M, Harmer C, Berg GG, Cohen O, Duntas L, Jamar F, Jarzab B, Limbert E, Lind P, Reiners C, Sanchez Franco F, Smit J, Wiersinga W. Post-surgical use of radioiodine (131I) in patients with papillary and follicular thyroid cancer and the issue of remnant ablation: a consensus report *Eur J Endocrinol*. 2005 Nov;153(5):651-9.

459b. David A, Blotta A, Rossi R, Zatelli MC, Bondanelli M, Roti E, Braverman LE, Busutti L, degli Uberti EC. Clinical value of different responses of serum thyroglobulin to recombinant human thyrotropin in the follow-up of patients with differentiated thyroid carcinoma. *Thyroid*. 2005 Mar;15(3):267-73. -

459c. Bachelot A, Leboulleux S, Baudin E, Hartl DM, Caillou B, Travagli JP, Schlumberger M. Neck recurrence from thyroid carcinoma: serum thyroglobulin and high-dose total body scan are not reliable criteria for cure after radioiodine treatment. *Clin Endocrinol (Oxf)*. 2005 Mar;62(3):376-9.

459d. [Smallridge RC](#), [Meek SE](#), [Morgan MA](#), [Gates GS](#), [Fox TP](#), [Grebe S](#), [Fatourechi V](#). Monitoring Thyroglobulin in a Sensitive Immunoassay Has Comparable Sensitivity to Recombinant Human TSH-Stimulated Thyroglobulin in Follow-Up of Thyroid Cancer Patients. *J Clin Endocrinol Metab*. 2007 Jan;92(1):82-7.

460.see 457

461.see 454

462. Lippi, F, Capezzone, M, Angelini, F, et al. 2001 Radioiodine treatment of metastatic differentiated thyroid cancer in patients on L-thyroxine, using recombinant human TSH. *Eur J Endocrinol* 144:5-11

463. Galloway, R, Smallridge, R 1996. Imaging in thyroid cancer. *Endocrinol Metab Clinics North America* 25:93-113

464. Park, H-M, Perkins, O, Edmondson, J, Schnute, R, Manatunga, A 1994. Influence of diagnostic radioiodines on the uptake of ablative dose of Iodine-131. *Thyroid* 4:49
- 464a. Lassmann, M Luster M, Hanscheid H, Reiners C. Impact of 131I diagnostic Activities on the Biokinetics of Thyroid Remnants. *J Nucl Med* 45: 619-625, 2004.
465. Morris, L F, Waxman, A D, Braunstein, G D 2001 The nonimpact of thyroid stunning: remnant ablation rates in 131I-scanned and nonscanned individuals. *J Clin Endocrinol Metab* 86:3507-11
- 465a. Nucl Med Commun. 2004 Aug;25(8):799-805. Treatment of advanced differentiated thyroid carcinoma with high activity radioiodine therapy. Haq MS, McCready RV, Harmer CL.)(*J Nucl Med*. 2003 Mar;44(3):451-6.
- 465b. Dosimetry-guided radioactive iodine treatment in patients with metastatic differentiated thyroid cancer: largest safe dose using a risk-adapted approach. Dorn R, Kopp J, Vogt H, Heidenreich P, Carroll RG, Gulec SA.)
- 465.1. Cailleux, A, Baudin, E, Travagli, J, Ricard, M, Schlumberger, M 2000. Is diagnostic Iodine-131 scanning useful after total thyroid ablation for differentiated thyroid cancer? *J Clin Endocrinol Metab* 85:175-178
- 465.2. Van Nostrand, D, Atkins, F, Yeganeh, F, Acio, E, Bursaw, R, Wartofsky, L 2002. Dosimetrically determined doses of radioiodine for the treatment of metastatic thyroid carcinoma. *Thyroid* 12:121-134
- 465.3. O'Connell, M, Flower, M, Hinton, P, Harmer, C, McCready, V 1993. Radiation dose assessment in radioiodine therapy. Dose-response relationships in differentiated thyroid carcinoma using quantitative scanning and PET. *Radiotherapy-Oncology* 28:16-26
- 465.31 [Tuttle RM](#) , [Leboeuf R](#) , [Robbins RJ](#) , [Qualey R](#) , [Pentlow K](#) , [Larson SM](#) , [Chan CY](#) . Empiric radioactive iodine dosing regimens frequently exceed maximum tolerated activity levels in elderly patients with thyroid cancer. *J Nucl Med*. 2006 Oct;47(10):1587-91.
- 465.4. Maxon, H, Thomas, S, Hertzberg, V, et al. 1983. Relation between effective radiation dose and outcome of radioiodine therapy for thyroid cancer. *N Engl J Med* 309:937
- 465.5. Koong, S-S, Reynolds, J, Movius, E, et al. 1999. Lithium as a potential adjuvant to 131I therapy of metastatic; well differentiated thyroid carcinoma. *J Clin Endocrinol Metab* 84:912-916
- 465.6. Carcangiu, M, Bianchi, S, Savino, D, Voynick, I, Rosai, J 1991. Follicular Hurthle cell tumors of the thyroid gland. *Cancer* 68:1944-1953
- 465.7. Fatourechi, V, Hay, I, Mullan, B, et al. 2000. Are posttherapy radioiodine scans informative and do they influence subsequent therapy of patients with differentiated thyroid cancer? *Thyroid* 10:573
- 465.8. Pelikan, D, Lion, H, Hermans, J, Goslings, B 1997. The role of radioactive iodine in the treatment of advanced differentiated thyroid carcinoma. *Clin Endocrinol* 47:713-720
- 465.9. Menzel, C, Grunwald, F, Schomburg, A, et al. 1996. "High-dose" radioiodine therapy in advanced differentiated thyroid carcinoma. *J Nucl Med* 37:1496-1503
- 465.10. Taylor, T, Specker, B, Robbins, J, et al. 1998. Outcome after treatment of high-risk papillary and non-Hurthle-cell follicular thyroid carcinoma. *Ann Intern Med* 129:622-627
- 465.11. Pittas, A, Adler, M, Fazzari, M, et al. 2000. Bone metastases from thyroid carcinoma. clinical characteristics and prognostic variables in one hundred forty-six patients. *Thyroid* 10:261-268
- 465.12. [Durante C](#) , [Haddy N](#) , [Baudin E](#) , [Leboulleux S](#) , [Hartl D](#) , [Travagli JP](#) , [Caillou B](#) , [Ricard M](#) ,

- [Lumbroso JD](#) , [De Vathaire F](#) , [Schlumberger M](#) Long-term outcome of 444 patients with distant metastases from papillary and follicular thyroid carcinoma: benefits and limits of radioiodine therapy. *J Clin Endocrinol Metab.* 2006 Aug;91(8):2892-9.
467. Van Tol, K, Hew, J, Jager, P, Vermey, A, Dullaart, R, Links, T 2000. .Embolization in combination with radioiodine therapy for bone metastases from differentiated thyroid carcinoma. *Clin Endocrinol* 52:653-659
468. . Meier, C, Braverman, L, Ebner, S, et al. 1994. Diagnostic use of recombinant human thyrotropin in patients with thyroid carcinoma (phase I/II study). *J Clin Endocrinol Metab*; 78:188-96
469. Hamburger, J, Desai, P Mannitol augmentation of I131 uptake in the treatment of thyroid carcinoma. *Metabolism* 15 1055: 1966.
- 369a. Elisei, R; Vivaldi, A; Agate, L; Molinaro, E; Nencetti, C; Grasso, L; Pinchera, A; Pacini, F. Low specificity of blood thyroglobulin messenger ribonucleic acid assay prevents its use in the follow-up of differentiated thyroid cancer patients. *J Clin Endocrinol Metab* 89 29-32 2004.
470. Hamburger, J 1969. Diuretic augmentation of 131I uptake in inoperable thyroid cancer. *N Engl J Med* 280:1091
471. Pacini, F, Lippi, F, Formica, N, et al. 1987. Therapeutic doses of iodine-131 reveal undiagnosed metastases in thyroid cancer patients with detectable serum thyroglobulin levels. *J Nucl Med* 28:1888
472. Schlumberger, M, Arcangioli, O, Piekarski, J, Tubiana, M, Parmentier, C 1988. Detection and treatment of lung metastases of differentiated thyroid carcinoma in patients with normal chest X-rays. *J Nucl Med* 29:1790-1794
473. Pineda, J, Lee, T, Ain, K, Reynolds, J, Robbins, J 1995. Iodine-131 therapy for thyroid cancer patients with elevated thyroglobulin and negative diagnostic scan. *J Clin Endocrinol Metab* 80:1488
474. McDougall, I 1997 131I treatment of 131I negative whole body scan; and positive thyroglobulin in differentiated thyroid carcinoma. what is being treated? *Thyroid* 7:669
475. Wartofsky, L, Sherman, S, Gopal, J, Schlumberger, M, Hay, I 1998. The use of radioactive iodine in patients with papillary and follicular thyroid cancer. *J Clin Endocrinol Metab* 83:4195-4203
476. Fatourechi, V, Hay, I D, Javedan, H, Wiseman, G A, Mullan, B P, Gorman, C A 2002 Lack of impact of radioiodine therapy in tg-positive, diagnostic whole-body scan-negative patients with follicular cell-derived thyroid cancer. *J Clin Endocrinol Metab* 87:1521-6
- 476a. Alzahrani AS, Mohamed G, Al Shammary A, Aldasouqi S, Abdal Salam S, Shoukri M Long-term course and predictive factors of elevated serum thyroglobulin and negative diagnostic radioiodine whole body scan in differentiated thyroid cancer. *J Endocrinol Invest.* 2005 Jun;28(6):540-6.
- 476.1 Koh J-M, Kim ES, Ryu JS, Hong SJ, Kim WB, Shong YK. Effects of therapeutic doses of 131I in thyroid papillary carcinoma patients with elevated thyroglobulin level and negative 131I whole-body scan: comparative study. *Clin Endocrinol* 58:421-427, 2003.
477. Maxon, H, Thomas, S, Hertzberg, V, et al. 1983. Relation between effective radiation dose and outcome of radioiodine therapy for thyroid cancer. *N Engl J Med* 309:937
478. Benua, R, Cicale, N, Sonenberg, M, Rawson, R 1971 The relation of radioiodine dosimetry to results and complications in the treatment of metastatic thyroid cancer. *Am J Roentgenol Rad Ther Nucl Med*: 87
479. Van Nostrand, D, Atkins, F, Yeganeh, F, Acio, E, Bursaw, R, Wartofsky, L 2002. Dosimetrically determined doses of radioiodine for the treatment of metastatic thyroid carcinoma. *Thyroid* 12:121-134

480. Grigsby, P, Siegel, B, Baker, S, Eichling, J 2000. Radiation exposure from outpatient radioactive iodine (131I) therapy for thyroid carcinoma. *J Amer Med Assn* 283:2272-2274
481. see 477
482. Seidlin, S, Yalow, R, Siegel, E 1952. Blood radioiodine concentration and blood radiation dosage during I131 therapy for metastatic thyroid carcinoma. *J Clin Endocrinol Metab* 12:1197
- 482b. Kim SJ, Choi HY, Kim IJ, Kim YK, Jun S, Nam HY, Kim JS. Limited cytoprotective effects of amifostine in high-dose radioactive iodine 131-treated well-differentiated thyroid cancer patients: analysis of quantitative salivary scan. *Thyroid*. 2008 Mar;18(3):325-31
- 482.1 Mandel SJ, Mandel L. Radioactive iodine and the salivary glands. *Thyroid* 13:265-271, 2003. Guma M, Salinas I, Reverter JL, Roca J, Valls-Roc M, Juan M, Olive A. Frequency of antineutrophil cytoplasmic antibody in Graves' disease patients treated with methimazole. *J Clin Endocrinol Metab* 88:2141-2146, 2003.
- 482a. Nakada K, Ishibashi T, Takei T, Hirata K, Shinohara K, Katoh S, Zhao S, Tamaki N, Noguchi Y, Noguchi S. Does lemon candy decrease salivary gland damage after radioiodine therapy for thyroid cancer? *J Nucl Med*. 2005 Feb;46(2):261-6.
483. Raymond, J, Izembart, M, Marliac, V, et al. 1989. Temporary ovarian failure in thyroid cancer patients after thyroid remnant ablation with radioactive iodine. *J Clin Endocrinol Metab* 69:186
484. Pacini, F, Gasperi, M, Fugazzola, L, et al. 1994. Testicular function in patients with differentiated thyroid carcinoma treated with radioiodine. *J Nucl Med* 35:1418
485. Ceccarelli, C, Battisti, P, Gasperi, M, et al. 1999. Radiation dose to the testes after 131I therapy for ablation of postsurgical thyroid remnants in patients with differentiated thyroid cancer. *J Nucl Med* 40:1716
- 485a. [Rosario PW, Barroso AL, Rezende LL, Padrao EL, Borges MA, Guimaraes VC, Purisch S.](#) Testicular function after radioiodine therapy in patients with thyroid cancer. *Thyroid*. 2006 Jul;16(7):667-70
486. Pochin, E 1960. Leukemia following radioiodine treatment of thyrotoxicosis. *Br Med J* 2:1545
487. Wiseman, J, Hales, I, Joasoo, A 1982. Two cases of lymphoma of the parotid gland following ablative radioiodine therapy for thyroid carcinoma. *Clin Endocrinol* 17:85
488. Rall, J, Alpers, J, Lewallen, C, Sonenberg, M, Berman, M, Rawson, R 1957. Radiation pneumonitis and fibrosis. A complication of I131 treatment of pulmonary metastases from cancer of the thyroid. *J Clin Endocrinol Metab* 17:1263
489. Exelby, P, Frazell, E 1969. Carcinoma of the thyroid in children. *Surg Clin North Am* 49:249
490. to be added
491. Trunnell, J, Marinelli, L, Duffy, B J, Hill, R, Peacock, W, Rawson, R 1949. The treatment of metastatic thyroid cancer with radioactive iodine. Credits and debits. *J Clin Endocrinol Metab* 19:1138
492. Lin, J, Wang, H, Weng, H, Kao, P 1998. Outcome of pregnancy after radioactive iodine treatment for well differentiated thyroid carcinomas. *J Endocrinol Invest* 21:662-667
- 492a. . Bal C, Kumar A, Tripathi M, Chandrashekar N, Phom H, Murali NR, Chandra P, Pant S.; High-dose radioiodine treatment for differentiated thyroid carcinoma is not associated with change in female fertility or any genetic risk to the offspring. *Int J Radiat Oncol Biol Phys*. 2005 Aug 9
493. Schlumberger, M, De Vathaire, F, Ceccarelli, C, et al. 1996. Exposure to radioactive iodine-131 for

- scintigraphy or therapy does not preclude pregnancy in thyroid cancer patients. *J Nucl Med* 37:606
- 494.. Trunnell, J, Marinelli, L, Duffy, B J, Hill, R, Peacock, W, Rawson, R 1949. The treatment of metastatic thyroid cancer with radioactive iodine. Credits and debits. *J Clin Endocrinol Metab* 19:1138
495. Lin, J, Wang, H, Weng, H, Kao, P 1998. Outcome of pregnancy after radioactive iodine treatment for well differentiated thyroid carcinomas. *J Endocrinol Invest* 21:662-667
496. Varma, V, Beierwaltes, W, Nofal, M, Nishiyama, R, Copp, J 1437 Treatment of thyroid cancer. Death rates after surgery and after surgery followed by sodium iodide. I131 *JAMA*: 214
497. Leeper, R 1973. The effect of 131I therapy on survival of patients with metastatic papillary or follicular thyroid carcinoma. *J Clin Endocrinol Metab* 36:1143
498. Mazzaferri, E, Young, R 1981. Papillary thyroid carcinoma. A ten year follow-up report of the impact of therapy in 576 patients. *Am J Med* 70:511
499. see 496
500. see 497
501. Marcocci, C, Pacini, F, Elisei, R, et al. 1989. Clinical and biologic behavior of bone metastases from differentiated thyroid carcinoma. *Surgery* 106:960
- 502.O'Connell, M, Flower, M, Hinton, P, Harmer, C, McCready, V 1993. Radiation dose assessment in radioiodine therapy. Dose-response relationships in differentiated thyroid carcinoma using quantitative scanning and PET. *Radiotherapy-Oncology* 28:16-26
503. Rall, J, Alpers, J, Lewallen, C, Sonenberg, M, Berman, M, Rawson, R 1957. Radiation pneumonitis and fibrosis. A complication of I131 treatment of pulmonary metastases from cancer of the thyroid. *J Clin Endocrinol Metab* 17:1263
504. Exelby, P, Frazell, E 1969. Carcinoma of the thyroid in children. *Surg Clin North Am* 49:249
505. Lin, J, Wang, H, Weng, H, Kao, P 1998. Outcome of pregnancy after radioactive iodine treatment for well differentiated thyroid carcinomas. *J Endocrinol Invest* 21:662-667
506. Saenger, E, Barrett, C, Passino, J, Seltzer, R, Dooley, W 1964. Experiences with I131 in the management of carcinoma of the thyroid. *Radiology* 83:892
507. Varma, V, Beierwaltes, W, Nofal, M, Nishiyama, R, Copp, J 1437 Treatment of thyroid cancer. Death rates after surgery and after surgery followed by sodium iodide. I131 *JAMA*: 214
508. Marcocci, C, Pacini, F, Elisei, R, et al. 1989. Clinical and biologic behavior of bone metastases from differentiated thyroid carcinoma. *Surgery* 106:960
509. Harness, J, Thompson, N, Sisson, J, Beierwaltes, W 1974. Differentiated thyroid carcinomas. Treatment of distant metastases. *Arch Surg* 108:410
510. Solomon, B, Wartofsky, L, Burman, K 1996. Current trends in the management of well differentiated papillary thyroid carcinoma. *J Clin Endocrinol Metab* 81:333-339
511. Shands, W, Gatling, R 1970. Cancer of the thyroid. Review of 109 cases. *Ann Surg* 171:735
512. Solomon, B, Wartofsky, L, Burman, K 1996. Current trends in the management of well differentiated papillary thyroid carcinoma. *J Clin Endocrinol Metab* 81:333-339
513. Schlumberger, M 1998. Papillary and follicular thyroid carcinoma. *N Engl J Med* 338:297-306
514. Sherman, S, Tielens, E, Sostre, S, Wharam, M J, Ladenson, P 1994. Clinical utility of post-treatment radioiodine scans in the management of patients with thyroid cancer. *J Clin Endocrinol*

- 514.1 Hovens GC, Stokkel MP, Kievit J, Corssmit EP, Pereira AM, Romijn JA, Smit JW. Associations of serum thyrotropin concentrations with recurrence and death in differentiated thyroid cancer. *J Clin Endocrinol Metab.* 2007 Jul;92(7):2610-5.
515. Charles, M, Dodson, L, Waldeck, N, et al. 1980. Serum thyroglobulin levels predict total body iodine scan findings in patients with treated well-differentiated thyroid carcinoma. *Am J Med* 69:401
516. Pacini, F, Pinchera, A, Giani, C, Grasso, L, Baschieri, L 1980. Serum thyroglobulin concentrations and ¹³¹I whole body scans in the diagnosis of metastases from differentiated thyroid carcinoma (after thyroidectomy). *Clin Endocrinol* 13:107
517. Barsano, C, Skosey, C, DeGroot, L, Refetoff, S 1982. Serum thyroglobulin in the management of patients with thyroid cancer. *Arch Intern Med* 142:763
518. Pacini, F, Pinchera, A, Giani, C, Grasso, L, Doveri, F, Baschieri, L 1980. Serum thyroglobulin in thyroid carcinoma and other thyroid disorders. *J Endocrinol Invest* 3:283
519. Johansen, K, Woodhouse, N 1992. Comparison of thyroglobulin and radioiodine scintigraphy during follow-up of patients with differentiated thyroid carcinoma. *Eur J Med* 1:403-406
520. Cailleaux, A, Baudin, E, Travagli, J, Ricard, M, Schlumberger, M 2000. Is diagnostic iodine-131 scanning useful after total thyroid ablation for differentiated thyroid cancer? *J Clin Endocrinol Metab* 85:175
521. Capezzone, M, Sculli, M, Agate, L, Ceccarelli, C, Pacini, F 2000. Diagnostic ¹³¹I whole body scan after total thyroidectomy and thyroid ablation is useless in thyroid cancer patients with undetectable serum thyroglobulin off l-thyroxine therapy. *J Endocrinol Invest (Suppl)* 23:3
522. Haugen, B, Pacini, F, Reiners, C, et al. 1999. A comparison of recombinant human thyrotropin and thyroid hormone withdrawal for the detection of thyroid remnant or cancer. *J Clin Endocrinol Metab* 84:3877-3885
523. Sisson, J, Thompson, N, Giordano, T, England, B, Normolle, D 2000. Serum thyroglobulin levels after thyroxine withdrawal in patients with low risk papillary thyroid carcinoma. *Thyroid* 10:165
- 523a. Chiovato, L; Latrofa, F; Braverman, LE; Pacini, F; Capezzone, M; Masserini, L; Grasso, L; Pinchera, A. Disappearance of humoral thyroid autoimmunity after complete removal of thyroid antigens. *Ann Intern Med* 139 346-351 2003.
524. Fugazzola, L, Mihalich, A, Persani, L, et al. 2002 Highly sensitive serum thyroglobulin and circulating thyroglobulin mRNA evaluations in the management of patients with differentiated thyroid cancer in apparent remission. *J Clin Endocrinol Metab* 87:3201-8
525. Pujol, P, Daures, J-P, Nsakala, N, Baldet, L, Bringer, J, Jaffiol, C 1996. Degree of thyrotropin suppression as a prognostic determinant in differentiated thyroid cancer. *J Clin Endocrinol Metab* 81:4318-4323
526. Cooper, D, Specker, B, Ho, M, et al. 1998 *Thyroid* 8: 737
527. Marcocci, C, Golia, F, Bruno-Bossio, G, Vignali, E, Pinchera, A 1994. Carefully monitored lecothyroxine suppressive therapy is not associated with bone loss in premenopausal women. *J Clin Endocrinol Metab* 78:818-23
528. Kim, J, Leeper, R 1983. Treatment of anaplastic and spindle cell carcinoma of the thyroid gland with combination adriamycin and radiation therapy. *Cancer* 52:954

- 528a. *Int J Radiat Oncol Biol Phys*. 2004 Nov 15;60(4):1137-43 ,Combined treatment of anaplastic thyroid carcinoma with surgery, chemotherapy,and hyperfractionated accelerated external radiotherapy. De Crevoisier R, Baudin E, Bachelot A, Leboulleux S, Travagli JP, Caillou B,Schlumberger M.
529. Ain, K 1998. Anaplastic thyroid carcinoma. Behavior; biology; and therapeutic approaches. *Thyroid* 8:715
530. Butler, J, Brady, L, Amendola, B 1990. Lymphoma of the thyroid. Report of five cases and review. *Amer J Clin Oncol (CCT)* 13:64
531. Souhami, L, Simpson, W, Carrothers, J 1980. Malignant lymphoma of the thyroid gland. *Int J Radiat Oncol Biol Phys* 6:1143
532. Grimley, R, Oates, G 1980. The natural history of malignant thyroid lymphomas. *Br J Surg* 67:475
533. Leedman, P, Sheridan, W, Downey, W, Fox, R, Martin, F 1990. Combination chemotherapy as single modality therapy for stage IE and IIE thyroid lymphoma. *Med J Australia* 152:40
534. Chak, L, Hoppe, R, Burke, J, Kaplan, H 1981. Non- Hodgkin's lymphoma presenting as thyroid enlargement. *Cancer* 48:2712
535. Matsuzuka, F, Miyauchi, A, Katayama, S, et al. 1993. Clinical aspects of primary thyroid lymphoma. Diagnosis and treatment based on our experience of 119 cases. *Thyroid* 3:93-99
536. Tubiana, M 1981. External radiotherapy and radioiodine in the treatment of thyroid cancer. *World J Surg* 5:75
537. Simpson, W 1975. Radiotherapy in thyroid cancer. *Can Med Assoc J* 113:115
538. Riccabona, G 1979. Radiotherapy and nuclear medicine in malignant tumors of the thyroid gland. *Therapiewoche* 29:3448
539. Tubiana, M, Lacour, J, Monnier, J, et al. 1975. External radiotherapy and radioiodine in the treatment of 359 thyroid cancers. *Br J Radiol* 48:894
540. Brierley, J, Tsang, R 1996. External radiation therapy in the treatment of thyroid malignancy. *Endocrinol Metab Clinics North America* 25:141-157
541. Lin, J-D, Tsang, N-M, Huang, M-J, Weng, H-F 1997. Results of external beam radiotherapy in patients with well differentiated thyroid carcinoma. *Jpn J Clin Oncol* 27:244-247
542. Farahati, J, Reiners, C, Stuschke, M, et al. 1996. Differentiated thyroid cancer. Impact of adjuvant external radiotherapy in patients with perithyroidal tumor infiltration (Stage pT4). *Cancer* 77:172-179
543. Tsang, R, Brierley, J, Simpson, W, Panzarella, T, Gospodarowicz, M, Sutcliffe, S 1998. The effects of surgery; radioiodine; and external radiation therapy on the clinical outcome of patients with differentiated thyroid carcinoma. *Cancer* 82:375-387
- 543a. *Int J Radiat Oncol Biol Phys*. 2003 Jul 15;56(4):1067-72. Is there a role for radiation therapy in the management of Hurthle cell carcinoma? Foote RL, Brown PD, Garces YI, McIver B, Kasperbauer JL.
- 544 . Harada, T, Nishikawa, Y, Suzuki, T, Ito, K, Baba, S 1971. Bleomycin treatment for cancer of the thyroid. *Am J Surg* 122:53
545. Gottlieb, J, Hill, C, Ibanez, M, Clark, R 1972. Chemotherapy of thyroid cancer. An evaluation of experience with 37 patients. *Cancer* 30:848
546. Jereb, B, Stjernsward, J, Lowhagen, T 1975. Anaplastic giant-cell carcinoma of the thyroid.

Cancer 35:1293

547. Shimaoka, K, Reyes, J American Elsevier Chemotherapy of thyroid carcinoma. in Robbins, J; Braverman, L (eds). Thyroid Research: New York

548. see546

549. Riccabona, G, Zechmann, W, Fill, H American Elsevier Cytostatic drug therapy of thyroid cancer. in Robbins, J; Braverman, L (eds) Thyroid Research: New York

550. De Besi, P, Busnardo, B, Toso, S, et al. 1991. Combined chemotherapy with bleomycin; adriamycin; and platinum in advanced thyroid cancer. J Endocrinol Invest 14:475

551. Committee, C, Surgery., T J S o T 1995. Intensive chemotherapy for anaplastic thyroid carcinoma. combination of cisplatin; doxorubicin; etoposide; and peplomycin with granulocyte colony-stimulating factor support. Jpn J Clin Oncol 25:203-207

552 Ain, K, Egorin, M, DeSimone, P 2000. Treatment of anaplastic thyroid carcinoma with Paclitaxel. phase 2 trial using ninety-six hour infusion. Thyroid 10:587

553. Busnardo, B, Daniele, O, Pelizzo, M, et al. 2000. A multimodality therapeutic approach in anaplastic thyroid carcinoma. Study on 39 patients. J Endocrinol Invest 23:755-761

553a. [Gilliam LK](#) , [Kohn AD](#) , [Lalani T](#) , [Swanson PE](#) , [Vasko V](#) , [Patel A](#) , [Livingston RB](#) , [Pickett CA](#) . Capecitabine therapy for refractory metastatic thyroid carcinoma: a case series. Thyroid. 2006 Aug;16(8):801-10.

554. Santini, F, Bottici, V, Elisei, R, et al. 2002 Cytotoxic effects of carboplatinum and epirubicin in the setting of an elevated serum thyrotropin for advanced poorly differentiated thyroid cancer. J Clin Endocrinol Metab 87:4160-5

554.1 de Groot JW, Zonnenberg BA, van Ufford-Mannesse PQ, de Vries MM, Links TP, Lips CJ, Voest EEA Phase II Trial of Imatinib Therapy for Metastatic Medullary Thyroid Carcinoma. J Clin Endocrinol Metab. 2007 Sep;92(9):3466-9

554.2 Pennell NA, Daniels GH, Haddad RI, Ross DS, Evans T, Wirth LJ, Fidias PH, Temel JS, Gurubhagavatula S, Heist RS, Clark JR, Lynch TJ A Phase II Study of Gefitinib in Patients with Advanced Thyroid Cancer. Thyroid. 2008 Mar;18(3):317-23

554.3 Sherman SI, Wirth LJ, Droz JP, Hofmann M, Bastholt L, Martins RG, Licitra L, Eschenberg MJ, Sun YN, Juan T, Stepan DE, Schlumberger MJ; Motesanib Thyroid Cancer Study Group. [Motesanib diphosphate in progressive differentiated thyroid cancer](#). N Engl J Med. 2008 Jul 3;359(1):31-42.

554.4 Kloss RT, Ringel MD, Knopp MV, et al:Phase II trial of sorafenib in metastatic thyroid cancer J Clin Oncol. 27:1675-84. 2009

554.5 Waguespack SG, Sherman SI, Williams MD, Clayman GL, Herzog CE. [The successful use of sorafenib to treat pediatric papillary thyroid carcinoma](#). Thyroid. 2009 Apr;19(4):407-12.

554.6 Dawson SJ, Conus NM, Toner GC, Raleigh JM, Hicks RJ, McArthur G, Rischin D [Sustained clinical responses to tyrosine kinase inhibitor sunitinib in thyroid carcinoma](#). . Anticancer Drugs. 2008 Jun;19(5):547-52.

554.7 Morabito A, Piccirillo MC, Falasconi F, De Feo G, Del Giudice A, Bryce J, Di Maio M, De Maio E, Normanno N, Perrone F. [Vandetanib \(ZD6474\), a dual inhibitor of vascular endothelial growth factor receptor \(VEGFR\) and epidermal growth factor receptor \(EGFR\) tyrosine kinases: current status and future directions](#). Oncologist. 2009 Apr;14(4):378-90.

- 554.8 Cohen EE, Rosen LS, Vokes EE, Kies MS, Forastiere AA, Worden FP, Kane MA, Sherman E, Kim S, Bycott P, Tortorici M, Shalinsky DR, Liau KF, Cohen RB. [Axitinib is an active treatment for all histologic subtypes of advanced thyroid cancer: results from a phase II study.](#) J Clin Oncol. 2008 Oct 10;26(29):4708-13.
555. Simon, D, Koehrlle, J, Reiners, C, et al. 1998. Redifferentiation therapy with retinoids. therapeutic option for advanced follicular and papillary thyroid carcinoma. World J Surg 22:569-574
- 555a. Furuya, F; Shimura, H; Suzuki, H; Taki, K; Ohta, K; Haraguchi, K; Onaya, T; Endo, T; Kobayashi, T. Histone deacetylase inhibitors restore radioiodine uptake and retention in poorly differentiated and anaplastic thyroid cancer cells by expression of the sodium/iodide symporter thyroperoxidase and thyroglobulin. Endocrinology 2004.
- 555b. Fortunati, N; Catalano, MG; Arena, K; Brignardello, E; Piovesan, A; Boccuzzi, G. Valproic acid induces the expression of the Na⁺/I⁻ symporter and iodine uptake in poorly differentiated thyroid cancer cells. J Clin Endocrinol Metab 89 1006-1009 2004.
556. Schmutzler, C, Kohrle, J 2000. Retinoic acid redifferentiation therapy for thyroid cancer. Thyroid 10:393-406
557. Martelli, M L, Iuliano, R, Le Pera, I, et al. 2002 Inhibitory effects of peroxisome poliferator-activated receptor gamma on thyroid carcinoma cell growth. J Clin Endocrinol Metab 87:4728-35
558. Portella, G, Scala, S, Vitagliano, D, Vecchio, G, Fusco, A 2002 ONYX-015, an E1B gene-defective adenovirus, induces cell death in human anaplastic thyroid carcinoma cell lines. J Clin Endocrinol Metab 87:2525-31
561. Tanaka, K; Towata, S; Nakao, K; Mizuguchi, H; Hayakawa, T; Niwa, M; Ishii, N; Nagayama, Y. Thyroid cancer immunotherapy with retroviral and adenoviral vectors expressing granulocyte macrophage colony stimulating factor and interleukin-12 in a rat model. Clin Endocrinol 59 734-742 2003.
562. Schuck, A; Biermann, M; Pixberg, MK; Muller, SB; Heinecke, A; Schober, O; Willich, N. Acute toxicity of adjuvant radiotherapy in locally advanced differentiated thyroid carcinoma. First results of the multicenter study on differentiated thyroid carcinoma (MSDS). Strahlenther Onkol 179 832-839 2003.
563. Schoenberger, J; Grimm, D; Kossmehl, P; Infanger, M; Kurth, E; Eilles, C. Effects of PTK787/ZK222584, a tyrosine kinase inhibitor, on the growth of a poorly differentiated thyroid carcinoma: an animal study. Endocrinology 145 1031-1038 2004.
564. Braga-Basaria, M; Ringel, MD. Beyond radioiodine: A review of potential new therapeutic approaches for thyroid cancer. J Clin Endocrinol Metab 88 1947-1960 2003.