

REVIEW

HLH-2004: Diagnostic and Therapeutic Guidelines for Hemophagocytic Lymphohistiocytosis

Jan-Inge Henter, MD, PhD,^{1*} AnnaCarin Horne, MD,¹ Maurizio Aricó, MD,² R. Maarten Egeler, MD, PhD,³ Alexandra H. Filipovich, MD,⁴ Shinsaku Imashuku, MD,⁵ Stephan Ladisch, MD,⁶ Ken McClain, MD, PhD,⁷ David Webb, MD,⁸ Jacek Winiarski, MD, PhD,⁹ and Gritta Janka, MD, PhD¹⁰ for the Histiocyte Society

In HLH-94, the first prospective international treatment study for hemophagocytic lymphohistiocytosis (HLH), diagnosis was based on five criteria (fever, splenomegaly, bicytopenia, hypertriglyceridemia and/or hypofibrinogenemia, and hemophagocytosis). In HLH-2004 three additional criteria are introduced; low/absent NK-cell-activity, hyperferritinemia, and high-soluble interleukin-2-receptor levels. Altogether five of these eight criteria must be fulfilled, unless family history or molecular diagnosis is consistent with HLH. HLH-2004 chemo-immunotherapy includes etoposide, dexamethasone, cyclo-

porine A upfront and, in selected patients, intrathecal therapy with methotrexate and corticosteroids. Subsequent hematopoietic stem cell transplantation (HSCT) is recommended for patients with familial disease or molecular diagnosis, and patients with severe and persistent, or reactivated, disease. In order to hopefully further improve diagnosis, therapy and biological understanding, participation in HLH studies is encouraged. Pediatr Blood Cancer © 2006 Wiley-Liss, Inc.

Key words: diagnosis; hemophagocytic lymphohistiocytosis; survival; treatment

INTRODUCTION

Hemophagocytic lymphohistiocytosis (HLH) is a disease with major diagnostic and therapeutic difficulties. HLH comprises two different conditions that may be difficult to distinguish from one another: a primary [1] and a secondary form [2]. The primary autosomal recessive form, familial hemophagocytic lymphohistiocytosis (FHL), has an estimated incidence of around 1:50,000 live-born children [3]. FHL is a fatal disease with a median survival of less than 2 months after diagnosis if untreated, and that typically has its onset during infancy or early childhood [4]. Despite its name, family history is often negative since the disease is recessive. Importantly, the onset of FHL and bouts of the disease may be triggered by infections [5].

Secondary HLH (sHLH) may develop as a result due to strong immunological activation of the immune system, which may, for example, be caused by a severe infection. sHLH has been described in immunocompromised hosts in association with viral infections, virus-(infection) associated hemophagocytic syndrome (VAHS, or IAHS) [2,6]. However, most patients with sHLH are *not* obviously immunosuppressed. sHLH may also develop during malignancies (malignancy-associated hemophagocytic syndrome, MAHS); it may either be the presenting clinical picture and initially mask an underlying malignancy, or it may develop during the treatment for a known malignancy [2].

In 1991, the Histiocyte Society presented the first set of diagnostic guidelines for HLH [7], and in 1994 the first prospective international treatment protocol (HLH-94) was introduced [8]. The cumulative experiences from HLH-94 and other studies have led to the development of a

new treatment protocol presented here, HLH-2004, which includes updated diagnostic and therapeutic guidelines from the Histiocyte Society.

DIAGNOSIS OF HLH

Clinical Presentation

The most typical findings of HLH are fever, hepatosplenomegaly and cytopenias. Other common findings include hypertriglyceridemia, coagulopathy with hypofibrinogenemia, liver dysfunction, elevated levels of ferritin and serum

¹Childhood Cancer Research Unit, Department of Woman and Child Health, Karolinska University Hospital, Karolinska Institutet, Stockholm, Sweden; ²Pediatric Hematology/Oncology, Ospedale dei Bambini, Palermo, Italy; ³Department of Pediatrics IHOBA, Leiden University Medical Center, Leiden, The Netherlands; ⁴Children's Hospital Medical Center, Cincinnati Ohio; ⁵Department of Pediatrics, Takasago-Seibu Hospital, Japan; ⁶Children's Research Institute, Washington, District of Columbia; ⁷Pediatric Hematology/Oncology, Texas Children's Hospital, Houston, Texas; ⁸Great Ormond Street Hospital, London, UK; ⁹Department of Pediatrics, Karolinska University Hospital Huddinge, Karolinska Institutet, Stockholm, Sweden; ¹⁰Department of Hematology Oncology, Children's University Hospital, Hamburg, Germany

Grant sponsor: Children's Cancer Foundation of Sweden; Grant sponsor: Cancer and Allergy Foundation of Sweden; Grant sponsor: Swedish Research Council; Grant sponsor: Tobias Foundation; Grant sponsor: Märta and Gunnar V Philipson Foundation; Grant sponsor: Histiocytosis Association of America.

*Correspondence to: Jan-Inge Henter, Childhood Cancer Research Unit, Karolinska Hospital Q6:05, SE-171 76 Stockholm, Sweden. E-mail: Jan-Inge.Henter@ki.se

Received 19 February 2006; Accepted 21 July 2006

transaminases, and neurological symptoms that may be associated with a spinal fluid hyperproteinemia and a moderate pleocytosis [1,4,9,10]. Other, less common, initial clinical findings include lymphadenopathy, skin rash, jaundice, and edema. Spontaneous partial remissions are observed [11]. The onset of the primary (genetic) form is typically during early infancy but presentation in adolescents and adults have also been reported [12].

Histopathological findings include a widespread accumulation of lymphocytes and mature macrophages, sometimes with hemophagocytosis, affecting especially the spleen, lymph nodes (if enlarged), the bone marrow, the liver, and the cerebral spinal fluid (CSF) [13]. In the liver, a histological picture similar to chronic persistent hepatitis is commonly found [7,13]. Other frequent abnormal laboratory findings in HLH are low natural killer (NK) cell activity [14–18], and a hypercytokinemia, in particular elevated soluble interleukin-2 receptor (sIL-2r) levels (sCD25) [18,19] in serum and in the CSF [19,20].

Importantly, it is still often difficult to distinguish between the familial and secondary forms of HLH despite advances regarding molecular diagnosis. Infection-associated forms of HLH may subside spontaneously, but may also be associated with increased mortality [2]. Furthermore, proving an acute infection at onset of symptoms is not of major diagnostic or therapeutic assistance, since not only sHLH but also FHL often feature a triggering infectious agent [5].

Differential Diagnoses

Many conditions can lead to the clinical picture of HLH, including malignancies (leukemia, lymphoma, other solid tumors), infections (viral, bacterial or parasitic), and rheumatoid disorders. In addition, there are diseases which develop a true HLH episode during their clinical course, such as X-linked lymphoproliferative syndrome (XLP), and Chédiak–Higashi and Griscelli (type 2) syndromes [2,7,21–24]. Some differential diagnoses are Langerhans cell histiocytosis (that may be complicated by HLH), lysinuric protein intolerance [25], severe combined immunodeficiency [26], DiGeorge syndrome, and Omenn's syndrome [27].

Viral infections, especially Epstein–Barr virus (EBV), may trigger primary as well as secondary forms of HLH [2]. Patients with severe sHLH due to EBV infections can be treated with this protocol [28]. It is possible that patients presently considered to have sHLH may have some, as yet unknown, subtle, inborn immune defect.

Macrophage activation syndrome (MAS), a serious complication of systemic rheumatoid arthritis and other childhood systemic inflammatory disorders, is thought to be caused by excessive activation and proliferation of T lymphocytes and macrophages. It is also a complication of autoimmune diseases in adults. The recognition that MAS belongs to the secondary or reactive hemophagocytic

syndromes has led to a proposal to rename it according to the contemporary classification of histiocytic disorders [29]. Moreover, and in the same way as in HLH, it has been shown that in addition to corticosteroids, cyclosporin A (CSA) is also effective in patients with MAS [30].

Diagnostic Guidelines

Guidelines 1991. In 1991, diagnostic guidelines for HLH were presented by the Histiocyte Society, based on common clinical, laboratory and histopathological findings [7]. However, HLH may also have an atypical and insidious course in some patients in whom all criteria are not always fulfilled [7]. Moreover, a number of patients may develop one or more of the diagnostic criteria late during the course of the disease [7,31]. With these concerns in mind and an extended knowledge on clinical and laboratory findings [10,18,19], the diagnostic guidelines have now been revised [32,33].

Guidelines 2004. The five criteria in the 1991 guidelines are still relevant: 1/fever, 2/splenomegaly, 3/cytopenias affecting at least two of three lineages in the peripheral blood, 4/hypertriglyceridemia and/or hypofibrinogenemia, and 5/hemophagocytosis in bone marrow, spleen, or lymph nodes [7]. In addition, three additional criteria have been introduced: 6/low or absent NK-cell activity, 7/hyperferritinemia, and 8/high levels of sIL-2r (Table I). Altogether five of the eight criteria must be fulfilled, but patients with a molecular diagnosis consistent with HLH do not necessarily need to fulfill the diagnostic criteria [32,33].

NK-cell activity is typically low or absent in HLH, and most perforin deficient patients have abnormal NK-cell activity [15–18,34]. Data on ferritin, an important diagnostic parameter [10], were available in 31 of 48 eligible children with familial disease (defined as having an affected sibling), registered in HLH-94 between July 1994 and June 2002, and 26/31 had a ferritin level above 500 µg/L (sensitivity 0.84). Soluble IL-2r (sCD25) also appears to be a valuable serum parameter in the diagnosis of HLH (sensitivity 0.93) [19,32,33].

Molecular Diagnosis

FHL has, in some patients, been shown to be associated with decreased apoptosis triggering [35]. Subsequently, it was shown that one of the underlying gene defect involves mutations in the gene encoding perforin (*PRF*), which account for 20–40% of all affected FHL families and up to 50% in a cohort of North American families [36–38]. Perforin, which is co-localized with granzyme B in granules of cytotoxic cells, is secreted from cytotoxic T lymphocytes and NK cells upon conjugation between effector and target cells. In the presence of calcium it is able to insert (perforate) into the membrane of the target cell, where it polymerizes to form a cell death-inducing pore (reviewed in Reference [39]). It has been suggested that pore formation may lead to

TABLE I. Revised Diagnostic Guidelines for HLH

The diagnosis HLH can be established if one of either 1 or 2 below is fulfilled

- (1) A molecular diagnosis consistent with HLH
- (2) Diagnostic criteria for HLH fulfilled (five out of the eight criteria below)
 - (A) Initial diagnostic criteria (*to be evaluated in all patients with HLH*)
 - Fever
 - Splenomegaly
 - Cytopenias (affecting ≥ 2 of 3 lineages in the peripheral blood):
 - Hemoglobin < 90 g/L (in infants < 4 weeks: hemoglobin < 100 g/L)
 - Platelets $< 100 \times 10^9/L$
 - Neutrophils $< 1.0 \times 10^9/L$
 - Hypertriglyceridemia and/or hypofibrinogenemia:
 - Fasting triglycerides ≥ 3.0 mmol/L (i.e., ≥ 265 mg/dl)
 - Fibrinogen ≤ 1.5 g/L
 - Hemophagocytosis in bone marrow or spleen or lymph nodes
 - No evidence of malignancy
 - (B) New diagnostic criteria
 - Low or absent NK-cell activity (according to local laboratory reference)
 - Ferritin ≥ 500 $\mu\text{g/L}$
 - Soluble CD25 (i.e., soluble IL-2 receptor) $\geq 2,400$ U/ml

Comments:

- (1) If hemophagocytic activity is not proven at the time of presentation, further search for hemophagocytic activity is encouraged. If the bone marrow specimen is not conclusive, material may be obtained from other organs. Serial marrow aspirates over time may also be helpful.
- (2) The following findings may provide strong supportive evidence for the diagnosis: (a) spinal fluid pleocytosis (mononuclear cells) and/or elevated spinal fluid protein, (b) histological picture in the liver resembling chronic persistent hepatitis (biopsy).
- (3) Other abnormal clinical and laboratory findings consistent with the diagnosis are: cerebrospinal fluid symptoms, lymph node enlargement, jaundice, edema, skin rash. Hepatic enzyme abnormalities, hypoproteinemia, hyponatremia, VLDL \uparrow , HDL \downarrow .

destruction of target cells by allowing the entry of granzymes, which trigger apoptosis. However, perforin concentrations which are lower than necessary for pore formation, together with granzyme B, may induce targeted cell death. Recent studies suggest that entry of granzyme B into target cells can also occur in a perforin-independent manner, but granzyme alone is not sufficient to induce toxicity [39].

In 2003, it was shown that mutations in the gene *UNC13D* (17q25) also cause FHL [40]. The encoded protein, Munc 13-4, is essential for the priming step of cytolytic granule secretion preceding vesicle membrane fusion and a deficiency results in defective cytolytic granule exocytosis. A third gene defect associated with FHL (*STX11* on chromosome 6q24) was recently identified encoding a protein, syntaxin 11, which

is postulated to play a role in intracellular trafficking, although its precise function is not known [41]. Mutations in *UNC13D* and *STX11* affect up to 20 and 10% of FHL patients in various series, respectively [42,43].

In XLP, 60–70% of patients have mutations in the gene *SAP* (SLAM-associated protein), also termed *SH2-DIA* (SH2-domain containing gene 1A) or *DSHP*. This gene, located at Xq25, regulates a protein involved in signal transduction in T and NK cells. In T cells, the protein binds to the Signaling Lymphocyte Activation Molecule (SLAM, known as CDw150) and in NK cells it binds to 2B4, an NK-cell-activating receptor [21]. Chédiak–Higashi syndrome is linked to the *LYST*-gene (lysosomal trafficking regulator gene, 1q42), and Griscelli syndrome type 2 is linked to mutations in *RAB27a*, a key effector of cytotoxic granule exocytosis [24].

TREATMENT OF HLH

Therapeutic Background

The first major achievement in the treatment of HLH came when the use of the epipodophylotoxin derivatives etoposide, and later teniposide, in combination with steroids were shown to induce prolonged symptomatic resolution [44–46]. The immunosuppressive drugs CSA and antithymocyte globulin (ATG) are also effective in FHL [47]. In HLH-94, etoposide and dexamethasone were combined with CSA [8,48].

Cerebral involvement may cause severe and irreversible damage [43,49,50]. In children with HLH, CNS disease at diagnosis often resolves with systemic therapy. Therefore, systemic therapy including dexamethasone, which penetrates the blood-brain barrier better than prednisolone, was first line therapy in HLH-94, and also in cases of CNS involvement. Intrathecal methotrexate was added after 2 weeks in children with progressive neurological symptoms or if an abnormal CSF had not improved.

However, although chemo-immunotherapy is effective in prolonging survival, in some patients more than 5 years after onset [11], it has not been possible to ultimately cure any child with FHL with chemo-immunotherapy alone. It was therefore a major therapeutic advance when allogeneic hematopoietic stem cell transplantation (HSCT) was shown to provide cure for FHL [51–53].

In HLH-94, the estimated 3-year probability of survival overall in HLH-94 at a median follow-up of 3.1 years was 55% (95% confidence interval $\pm 9\%$) ($\pm 9\%$) ($n = 113$) [48]. In children with an affected sibling, that is familial disease, the 3-year probability of survival was 51% for eligible patients recruited during the 4-year period, July 1994–June 1998 [48].

Proposed Revision of HLH-94 Protocol

Since the pre-HSCT therapy was successful in allowing as many as 80% of the patients with verified familial disease,

that is with an affected sibling, to survive to HSCT, the revised protocol was based on the achievements made by HLH-94 [48]. In addition, minor revisions are included, as presented below.

Initial therapy (weeks 1–8). Not surprisingly in a disease characterized by severe cytopenias and an immunodeficiency, dose modifications in HLH-94 were common. In particular, the doses of VP-16 were decreased in a substantial number of the patients. For dexamethasone, the amount administered was often increased during the induction phase.

During the first 4 years of HLH-94, six patients were reported to have died during the first month of treatment and six more during the second month of treatment. It was sometimes difficult to clarify whether death was caused by the disease or by its treatment, in particular in case of infections associated with neutropenia. However, most deaths were considered to be due to the HLH disease by the reporting physicians. Because of the data cited above, it was proposed that treatment intensity be increased during the first 2 months of therapy with a drug that does not induce myelotoxicity. As a result, in HLH-2004 CSA is initiated upfront instead of after 8 weeks.

Continuation therapy. Of the six children who died during weeks 9–24 on the HLH-94 protocol, all were reported as death due to HLH disease, and at least three of these children had CNS-involvement. We considered including CSF analysis every fourth week in all children (at least for cells and protein, and cytopin in case of CSF pleocytosis) in order to detect early reactivation in the CNS. As a minimum, it is recommended to perform CSF analysis at the time of systemic reactivation or new onset or reactivation of neurological symptoms. Brain MRI is also recommended at diagnosis in these situations.

Intrathecal therapy. With available HLH-94 data, it has not yet been possible to determine whether intrathecal therapy, in addition to the systemic HLH-94 therapy, is beneficial or not. Systemic therapy, as provided in HLH-94, will in most patients reduce CNS disease activity. It cannot be ruled out that intrathecal therapy may have additional beneficial effects, at least in some patients, but potential side-effects also have to be considered [46,48,54,55]. Intrathecal therapy is recommended for patients with signs of persistent active CNS disease and in cases of CNS reactivation. As in HLH-94, up to four intrathecal doses are recommended weeks 3–6, if the neurological symptoms are progressive during the first 2 weeks or if an abnormal CSF at onset has not improved after 2 weeks. With the potential beneficial effect of systemic corticosteroids in mind, it is now suggested to add corticosteroids to the intrathecal therapy.

Hematopoietic cell transplantation. The estimated overall 3-year probability of survival after HSCT for HLH-94 patients recruited during the period 1995–2000 was 64% (CI = $\pm 10\%$) ($n = 86$); $71 \pm 18\%$ with matched related donors ($n = 24$), $70 \pm 16\%$ with matched unrelated donors

($n = 33$), $50 \pm 24\%$ with family haploidentical donors ($n = 16$), and $54 \pm 27\%$ with mismatched unrelated donors ($n = 13$) [56]. The HLH-94 results also suggest that some degree of disease activity at the time for transplantation should not automatically preclude HSCT [56]. The recommended dosages for chemotherapy used in the preparative regimen and the graft-versus-host-disease (GVHD) prophylaxis have been modified slightly in the HLH-2004 protocol to reflect more recent HSCT experience.

HLH-2004 Study Design

The HLH-2004 protocol is designed for the patients with HLH, with or without evidence of familial or genetic disease, regardless of suspected or documented viral infections. The Japanese experience has demonstrated that patients with EBV infection and a clinical picture of HLH have a significant advantage when treated according to this approach [57]. Initial therapy (weeks 1–8) is based on etoposide, dexamethasone, and CSA; only selected patients will receive intrathecal therapy with methotrexate and prednisolone. For a general overview of the patient treatments options in HLH-2004, see Figure 1.

In patients without a known family history who achieve complete resolution of the disease after 8 weeks of therapy, treatment is stopped in order to avoid HSCT in a child that may have sHLH. All children with familial disease or with a diagnosis verified by genetic testing, as well as children with a non-familial disease that is severe and persistent, or reactivated, are recommended to receive continuation therapy with etoposide, dexamethasone, and CSA. HSCT should be performed as early as possible, when an acceptable donor is available.

Patients less than 18 years of age at onset of therapy who fulfil the diagnostic criteria of HLH, and who have not received prior cytotoxic or CSA treatment for HLH, are eligible to be enrolled. Patients with HLH aged 18 years or more and patients who do not fulfil the diagnostic criteria will be studied separately. Similarly, patients with XLP, Chediak–Higashi syndrome, Griscelli syndrome type 2, as well as patients with MAS secondary to known rheumatoid diseases, may be registered and will be studied separately.

Initial therapy. The initial therapy covers the first 8 weeks of treatment (Fig. 2). The complete protocol is available for request at www.histio.org/society/protocols. Maximal initial supportive care is suggested, and appropriate broad-spectrum antibiotics (until culture results) are made available. The supportive therapy includes prophylactic cotrimoxazole, an oral antimycotic during the initial therapy, consideration of antiviral therapy in patients with ongoing viral infections, and IvIG (0.5 g/kg IV) once every 4 weeks (during the initial and continuation therapy). Gastroprotection with ranitidine or some other gastroprotective agent is also suggested. If there is clinical evidence after 2 weeks of progressive neurological symptoms or if an abnormal CSF




Fig. 1. Flow-sheet of treatment options for children with hemophagocytic lymphohistiocytosis in HLH-2004. If there is a treatable infection it should be treated but be aware that this may not be sufficient and the patient may need HLH-treatment in addition. If HLH is persistent or recurring consider that the patient may have an undiagnosed inherited disease. HLH may also develop secondary to a number of other diseases as malignancies, rheumatic diseases, and metabolic disorders, requiring a different treatment. Start therapy if the patient has a genetically verified disease, a familial form of HLH, or if the disease is severe, persistent, or recurrent. (HSCT = hematopoietic stem cell transplantation.)

(cell count and protein) has not improved, 4 weekly intrathecal injections are recommended [46,48,54].

Continuation therapy. Patients without a family history of HLH and without genetic evidence of the disease are recommended to start continuation therapy if the disease is active after the initial therapy. Increasing disease activity may make it necessary to intensify the treatment in some children (see below).

Reactivation therapy. FHL is characterized by frequent reactivations, or even more or less continuous disease activity. In particular, reactivation of the disease is common as therapeutic intensity is reduced, such as during the later part of the initial therapy. Accordingly, a reactivation will commonly respond to an intensification of the initial therapy.

Reactivations may also occur following immune response triggering, such as infections and vaccinations. In cases of reactivation, broad-spectrum antibiotics, antiviral therapy, and antifungal therapy should also be considered as supportive or therapeutic measures.

If the patient develops a reactivation, intensification of therapy is recommended, such as to restart from week 2, in which case the initial therapy may be less than 8 weeks, and then continue with modified continuation therapy. Intrathecal therapy is recommended in cases of CNS-reactivation [46,48,54]. HSCT has high priority.

Salvage therapy. The HLH-2004 protocol does not include a salvage protocol. We want to mention an alternative approach of inducing remission, with a regimen including a

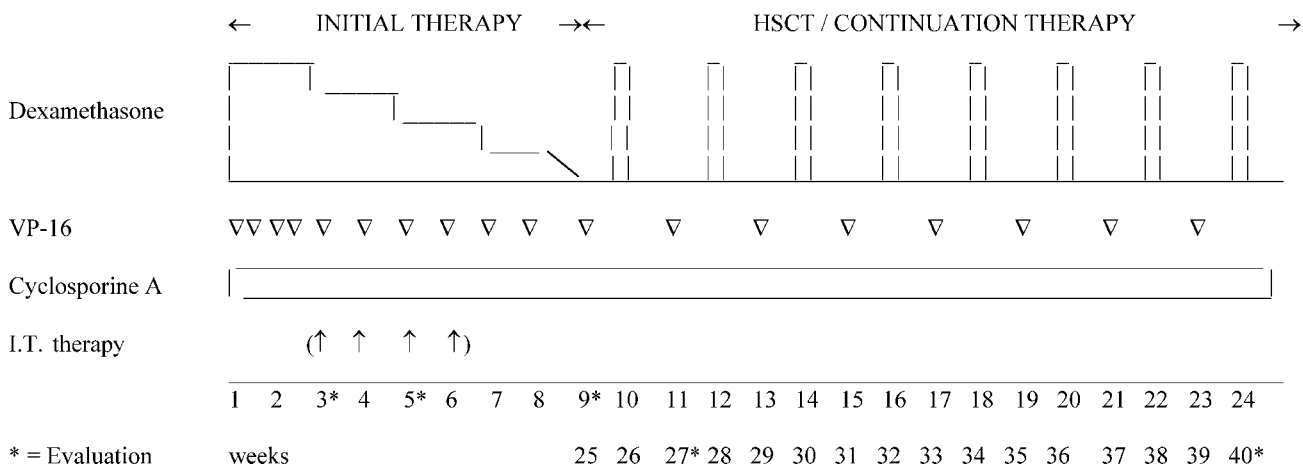


Fig. 2. Schematic treatment overview of the HLH-2004 protocol. For information on whether to start continuation therapy and perform stem-cell transplantation, see text and Figure 1. The complete protocol is available for request at www.histio.org/society/protocols. (VP-16 = etoposide, I.T. therapy = intrathecal methotrexate and corticosteroids, HSCT = hematopoietic stem cell transplantation.)

treatment with steroids, CSA, and ATG [47]. However, in our experience ATG usually fails in patients that are non-responders. It is therefore suggested that salvage therapy is discussed with the local sub-center. Note that early after HSCT, the immunodysregulation may induce a sHLH picture, which may be related to engraftment but delayed lymphocyte recovery, necessitating reinstatement of some form of HLH therapy [56].

Stopping therapy. Stopping therapy is only recommended in children with complete resolution of the disease. Close follow-up is warranted, including evaluation for fevers, hepatosplenomegaly, neurological abnormalities, anemia, thrombocytopenia, neutropenia, as well as elevation of ferritin, serum transaminases, and sCD25.

Hematopoietic Cell Transplantation

The choice of the donor rests with the treating physician. If an HLA-identical relative is not available, a matched unrelated donor is recommended. The risk of a sibling carrying the disease must be considered. If a genetic marker (such as for *PRF*, *UNC13D*, or *STX11*) is not available, NK-cell activity can be considered as a surrogate marker of immune dysfunction, although healthy siblings may also have persistently decreased NK-cell activity [16].

If there is no matched donor available, use of a partially mismatched donor is sought. Outcome in the HLH-94 study with regard to various donors has been presented [57]. Results with mismatched donors are improving [52,53,56,58,59]. If no other donor is available, HSCT with a haplo-identical family donor is suggested. The use of peripheral blood or cord blood HSCT may be considered, at the discretion of the physician.

Preparative regimen and GVHD prophylaxis. The preparative regimen for HSCT and the GVHD prophylaxis rests with the transplantation unit, but a suggested regimen is provided. It proposes including etoposide, in addition to busulfan and cyclophosphamide, in the conditioning regimen, in accordance with previous experiences [48,53]. The dosages suggested are outlined in the complete protocol, available for request at www.histio.org/society/protocols. The marrow infusion is preferably made with $\geq 3 \times 10^8$ nucleated cells/kg, and non-T-cell-depleted. In haplo-identical and antigen mismatched unrelated transplants, T-cell-depletion may need to be considered. Since there is evidence that donor T cells and NK cells are instrumental in curing HLH, use of T-cell-depletion should be carefully weighted. The GVHD prophylaxis for unmanipulated T-cell replete grafts is based on CSA and a short course of methotrexate, and methotrexate may be substituted by mycophenolate mofetil. Additional treatment for unrelated donor transplants include ATG [53].

Reduced intensity conditioning. There are limited data available on reduced intensity conditioning in HLH [59]. It is

not yet possible to make definitive suggestions regarding the preference for such regimens in HLH.

BIOLOGICAL STUDIES

HLH-94 had a number of associated biological studies, including analyses of NK-cell and T-cell cytotoxicity, preparation of DNA for genetic analyses, as well as EBV-associated studies. These studies have all been successful and they have improved diagnostics and therapy, and increased the biological understanding of the disease as well as of normal human immune modulation.

Recent studies have shown that the disease is associated with decreased apoptosis triggering [35,39]. This causes the defect in the NK and T-cell cytotoxicity that has been recognized for long [15,16], with three causative gene defects known today; *PRF* [9], *UNC13D* [40], and *STX11* [41]. It is possible to identify a cohort of individuals with *PRF* gene mutations by the use of flow cytometry for the perforin protein [17]. Moreover, it has also recently been shown that the cytotoxicity defect can be grouped in four subtypes [18], and that group 3 patients will most likely need a HSCT in order to survive [34].

The biological studies in HLH-2004 address these recent novel findings. The goals are to: (1) gather biological material in order to identify additional genetic defects; (2) study the correlation of genetic mutations and associated flow cytometry results; (3) study genotype–phenotype associations; (4) and study the biological and clinical significance of cytotoxic subgroups. It is therefore recommended that study patients be analyzed for genetic mutations, by flow cytometry, and for NK and T-cell cytotoxicity.

CONCLUSION

Survival for patients with HLH has improved dramatically during the last decades as has the understanding of the underlying biological mechanisms. The HLH-94 treatment protocol has been widely accepted, and patients from 29 countries have been registered in the database. Based on the cumulative experiences from HLH-94 and other studies, a new treatment protocol, HLH-2004, has been developed which includes diagnostic and therapeutic guidelines. In order to attempt to further improve diagnosis, therapy and biological understanding, participation in HLH clinical trials is encouraged.

REFERENCES

1. Henter J-I, Arico M, Elinder G, et al. Familial hemophagocytic lymphohistiocytosis (primary HLH). *Hematol Oncol Clin North Am* 1998;12:417–433.
2. Janka G, Elinder G, Imashuku S, et al. Infection- and malignancy-associated hemophagocytic syndromes: Secondary hemophagocytic lymphohistiocytosis. *Hematol Oncol Clin North Am* 1998;12: 435–444.

3. Henter J-I, Söder O, Öst Å, et al. Incidence and clinical features of familial hemophagocytic lymphohistiocytosis in Sweden. *Acta Paediatr Scand* 1991;80:428–435.
4. Janka GE. Familial hemophagocytic lymphohistiocytosis. *Eur J Pediatr* 1983;140:221–230.
5. Henter J-I, Ehrnst A, Andersson J, et al. Familial hemophagocytic lymphohistiocytosis and viral infections. *Acta Paediatr* 1993;82:369–372.
6. Risdall RJ, McKenna RW, Nesbit ME, et al. Virus-associated hemophagocytic syndrome. A benign histiocytic proliferation distinct from malignant histiocytosis. *Cancer* 1979;44:993–1002.
7. Henter J-I, Elinder G, Öst Å, the FHL Study Group of the Histiocyte Society. Diagnostic guidelines for hemophagocytic lymphohistiocytosis. *Semin Oncol* 1991;18:29–33.
8. Henter J-I, Arico M, Egeler M, et al. HLH-94: A treatment protocol for hemophagocytic lymphohistiocytosis. *Med Pediatr Oncol* 1997;28:342–347.
9. Arico M, Janka G, Fischer A, et al. Hemophagocytic lymphohistiocytosis: Diagnosis, treatment and prognostic factors. Report of 122 children from the international registry. *Leukemia* 1996;10:197–203.
10. Esumi N, Ikushima S, Todo S, et al. Hyperferritinemia in malignant histiocytosis, virus-associated hemophagocytic syndrome and familial hemophagocytic lymphohistiocytosis. *Acta Paediatr Scand* 1989;78:268–270.
11. Henter J-I, Elinder G. Familial hemophagocytic lymphohistiocytosis. Clinical review based on the findings in seven children. *Acta Paediatr Scand* 1991;80:269–277.
12. Clementi R, Emmi L, Maccario R, et al. Adult onset and atypical presentation of hemophagocytic lymphohistiocytosis in siblings carrying PRF1 mutations. *Blood* 2002;100:2266–2267.
13. Favara B. Hemophagocytic lymphohistiocytosis: A hemophagocytic syndrome. *Semin Diagn Pathol* 1992;9:63–74.
14. Ladisch S, Poplack DG, Holiman B, et al. Immunodeficiency in familial erythrophagocytic lymphohistiocytosis. *Lancet* 1978;1:581–583.
15. Perez N, Virelizier J, Arenzana-Seisdedos F, et al. Impaired natural killer cell activity in lymphohistiocytosis syndrome. *J Pediatr* 1984;104:569–573.
16. Sullivan KE, Delaat CA, Douglas SD, et al. Defective natural killer cell function in patients with hemophagocytic lymphohistiocytosis and in first degree relatives. *Pediatr Res* 1998;44:465–468.
17. Kogawa K, Lee SM, Villanueva J, et al. Perforin expression in cytotoxic lymphocytes from patients with hemophagocytic lymphohistiocytosis and their family members. *Blood* 2002;99:61–66.
18. Schneider EM, Lorenz I, Müller-Rosenberger M, et al. Hemophagocytic lymphohistiocytosis (HLH) is associated with deficiencies of cellular cytolysis but normal expression of transcripts relevant to killer cell induced apoptosis. *Blood* 2002;100:2891–2898.
19. Komp DM, McNamara J, Buckley P. Elevated soluble interleukin-2 receptor in childhood hemophagocytic histiocytic syndromes. *Blood* 1989;73:2128–2132.
20. Henter J-I, Elinder G, Söder O, et al. Hypercytokinemia in familial hemophagocytic lymphohistiocytosis. *Blood* 1991;78:2918–2922.
21. Nichols KE. X-linked lymphoproliferative disease: Genetics and biochemistry. *Rev Immunogenet* 2000;2:256–266.
22. Arico M, Imashuku S, Clementi R, et al. Hemophagocytic lymphohistiocytosis due to germline mutations in SH2D1A, the X-linked lymphoproliferative disease gene. *Blood* 2001;97:1131–1133.
23. Ward DM, Shiflett SL, Kaplan J. Chediak–Higashi syndrome: A clinical and molecular view of a rare lysosomal storage disorder. *Curr Mol Med* 2002;2:469–477.
24. Bizario JC, Feldmann J, Castro FA, et al. Griscelli syndrome: Characterization of a new mutation and rescue of T-cytotoxic activity by retroviral transfer of RAB27A gene. *J Clin Immunol* 2004;24:397–410.
25. Duval M, Fenneteau O, Doireau V, et al. Intermittent hemophagocytic lymphohistiocytosis is a regular feature of lysinuric protein intolerance. *J Pediatr* 1999;134:236–239.
26. Schmid I, Reiter K, Schuster F, et al. Allogeneic bone marrow transplantation for active Epstein–Barr virus-related lymphoproliferative disease and hemophagocytic lymphohistiocytosis in an infant with severe combined immunodeficiency syndrome. *Bone Marrow Transplant* 2002;29:519–521.
27. Aleman K, Noordzij JG, de Groot R, et al. Reviewing Omenn syndrome. *Eur J Pediatr* 2001;160:718–725.
28. Imashuku S, Hibi S, Ohara T, et al. Effective control of Epstein–Barr virus-related hemophagocytic lymphohistiocytosis with immunochemotherapy. *Blood* 1999;93:1869–1874.
29. Ramanan AV, Baildam EM. Macrophage activation syndrome is hemophagocytic lymphohistiocytosis—need for the right terminology. *J Rheumatol* 2002;29:1105.
30. Stephan JL, Kone-Paut I, Galambrun C, et al. Reactive haemophagocytic syndrome in children with inflammatory disorders. A retrospective study of 24 patients. *Rheumatology (Oxford)* 2001;40:1285–1292.
31. Henter J-I, Elinder G. Cerebrospinal fluid hemophagocytic lymphohistiocytosis. *Lancet* 1992;339:104–107.
32. Janka GE, Schenider EM. Modern management of children with haemophagocytic lymphohistiocytosis. *Br J Haematol* 2004;124:4–14.
33. Henter J-I, Tondini C, Pritchard J. Histiocytic syndromes. *Crit Rev Oncol Hematol* 2004;50:157–174.
34. Horne AC, Zheng C, Lorenz I, et al. Subtyping of natural killer cell cytotoxicity deficiencies in hemophagocytic lymphohistiocytosis provides therapeutic guidance. *Br J Haematol* 2005;129:658–666.
35. Fadeel B, Orrenius S, Henter J-I. Induction of apoptosis and caspase activation in cells obtained from familial haemophagocytic lymphohistiocytosis patients. *Br J Haematol* 1999;106:406–415.
36. Stepp SE, Dufourcq-Lagelouse R, Le Deist F, et al. Perforin gene defects in familial hemophagocytic lymphohistiocytosis. *Science* 1999;286:1957–1959.
37. Ericson KG, Fadeel B, Nilsson-Ardnor S, et al. Spectrum of perforin gene mutations in familial hemophagocytic lymphohistiocytosis. *Am J Hum Genet* 2001;68:590–597.
38. Molleran Lee S, Villanueva J, Sumegi J, et al. Characterisation of diverse PRF1 mutations leading to decreased natural killer cell activity in North American families with haemophagocytic lymphohistiocytosis. *J Med Genet* 2004;41:137–144.
39. Fadeel B, Orrenius S, Henter J-I. Familial hemophagocytic lymphohistiocytosis: Too little cell death may seriously damage your health. *Leuk Lymphoma* 2001;42:13–20.
40. Feldmann J, Callebaut I, Raposo G, et al. Munc13-4 is essential for cytolytic granules fusion and is mutated in a form of familial hemophagocytic lymphohistiocytosis (FHL3). *Cell* 2003;115:461–473.
41. Zur Stadt U, Schmidt S, Kasper B, et al. Linkage of familial hemophagocytic lymphohistiocytosis (FHL) type-4 to chromosome 6q24 and identification of mutations in syntaxin 11. *Hum Mol Genet* 2005;14:827–834.
42. Zur Stadt U, Beutel K, Kolberg S, et al. Mutation spectrum in children with primary hemophagocytic lymphohistiocytosis: Molecular and functional analyses of PRF1, UNC13D, STX11, and RAB27A. *Hum Mutat* 2006;27:62–68.
43. Rudd E, Ericson KG, Zheng CY, et al. Spectrum and clinical implications of syntaxin 11 gene mutations in familial hemophagocytic

- lymphohistiocytosis: Association with disease-free remissions and hematopoietic malignancies. *J Med Genet* 2006; 43:e14.
44. Ambruso DR, Hays T, Zwartjes WJ, et al. Successful treatment of lymphohistiocytic reticulosis with phagocytosis with epipodophyllotoxin VP 16-213. *Cancer* 1980;45:2516–2520.
 45. Henter J-I, Elinder G, Finkel Y, et al. Successful induction with chemotherapy including teniposide in familial erythrophagocytic lymphohistiocytosis. *Lancet* 1986;2:1402.
 46. Fischer A, Virelizier JL, Arenzana-Seisdedos F, et al. Treatment of four patients with erythrophagocytic lymphohistiocytosis by a combination of epipodophyllotoxin, steroids, intrathecal methotrexate and cranial irradiation. *Pediatrics* 1985;76:263–268.
 47. Stephan JL, Donadieu J, Ledeist F, et al. Treatment of familial hemophagocytic lymphohistiocytosis with antithymocyte globulins, steroids and cyclosporin A. *Blood* 1993;82:2319–2323.
 48. Henter J-I, Samuelsson-Horne AC, Arico M, et al. Treatment of hemophagocytic lymphohistiocytosis with HLH-94 immunotherapy and bone marrow transplantation. *Blood* 2002; 100:2367–2373.
 49. Haddad E, Sulis ML, Jabado N, et al. Frequency and severity of central nervous system lesions in hemophagocytic lymphohistiocytosis. *Blood* 1997;89:794–800.
 50. Henter J-I, Nennesmo I. Neuropathological findings and neurological symptoms in 23 children with hemophagocytic lymphohistiocytosis. *J Pediatr* 1997;130:358–365.
 51. Fischer A, Cerf-Bensussan N, Blanche S, et al. Allogeneic bone marrow transplantation for erythrophagocytic lymphohistiocytosis. *J Pediatr* 1986;108:267–270.
 52. Jabado N, de Graeff-Meeder ER, Cavazzana-Calvo M, et al. Treatment of familial hemophagocytic lymphohistiocytosis with bone marrow transplantation from HLA genetically nonidentical donors. *Blood* 1997;90:4743–4748.
 53. Dürken M, Horstmann M, Bieling P, et al. Improved outcome in haemophagocytic lymphohistiocytosis after bone marrow transplantation from related and unrelated donors: A single-centre experience of 12 patients. *Br J Haematol* 1999;106:1052–1058.
 54. Al-Lamki Z, Wali YA, Pathare A, et al. Clinical and genetic studies of familial hemophagocytic lymphohistiocytosis in Oman: Need for early treatment. *Pediatr Hematol Oncol* 2003;20:603–609.
 55. Vezmar S, Becker A, Bode U, et al. Biochemical and clinical aspects of methotrexate neurotoxicity. *Chemotherapy* 2003;49: 92–104.
 56. Imashuku S, Kuriyama K, Teramura T, et al. Requirement for etoposide in the treatment of Epstein–Barr virus-associated hemophagocytic lymphohistiocytosis. *J Clin Oncol* 2001;19: 2665–2673.
 57. Horne AC, Janka G, Egeler RM, et al. Hematopoietic stem cell transplantation in hemophagocytic lymphohistiocytosis. *Br J Haematol* 2005;129:622–630.
 58. Ouachee-Chardin M, Elie C, de Saint Basile G, et al. Hematopoietic stem cell transplantation in hemophagocytic lymphohistiocytosis: A single-center report of 48 patients. *Pediatrics* 2006;117: e743–e750.
 59. Cooper N, Rao K, Gilmour K, et al. Stem cell transplantation with reduced intensity conditioning for haemophagocytic lymphohistiocytosis. *Blood* 2006;107:1233–1236.