

EDITOR'S
CHOICE

Histological patterns in drug-induced liver disease

R Ramachandran,¹ S Kakar²

¹ Department of Pathology, University of California, San Francisco, California, USA;

² Department of Pathology, University of California, San Francisco, and Veterans Affairs Medical Center, San Francisco, California, USA

Correspondence to:

Dr Sanjay Kakar, Department of Pathology, UCSF and VA Medical Center, San Francisco, CA 94143, USA; sanjay.kakar@ucsf.edu

Accepted 19 December 2008

ABSTRACT

The diagnosis of drug-induced liver injury (DILI) is a challenging problem, often confounded by incomplete clinical information and the difficulty of eliciting exposure to herbal products, over-the-counter agents and toxins. The task is further rendered difficult on biopsy, as drugs can mimic all the patterns found in primary liver disease. Acute hepatitis, with or without cholestasis, is the most common histological pattern of DILI, and drugs such as acetaminophen are the leading causes of acute liver failure. Most cases of DILI resolve on discontinuation of the drug, but recovery can take months or rarely the disease can progress despite drug withdrawal. Drugs such as methotrexate can lead to chronic hepatitis and cirrhosis, while others such as minocycline, nitrofurantoin and methyldopa are implicated in autoimmune hepatitis. Prolonged cholestasis and ductopenia resembling primary chronic biliary disease can occur. Drug-induced steatohepatitis is also an uncommon pattern, but is well described with drugs such as amiodarone and irinotecan. In the presence of risk factors such as obesity and diabetes, some drugs such as tamoxifen, oestrogens and nifedipine can precipitate or exacerbate steatohepatitis. Other observed patterns include granulomatous hepatitis, vascular injury (eg, sinusoidal obstruction syndrome), Ito cell lipodosis and neoplasms (eg, adenomas).

Evaluation of liver biopsy for adverse drug reaction is one of the most challenging problems in liver pathology. Drug-related injury can mimic all the patterns observed in primary liver disease, and an unequivocal histological diagnosis is not possible in the majority of cases. Inadequate clinical history and multiple drugs being taken simultaneously often compound the problem. It can be difficult to elicit information about herbal agents, over-the-counter medications, and exposure to household or industrial toxins. The list of drugs associated with hepatotoxicity is long, although the association of many drugs with liver injury remains tenuous and can be found only in case reports.

MECHANISMS OF INJURY

It is widely recognised that drug-induced liver injury (DILI) is mediated by two chief mechanisms: intrinsic and idiosyncratic hepatotoxicity. Intrinsic hepatotoxins cause hepatocellular damage in a predictable dose-dependent manner directly by the drug or indirectly by its metabolite. Some drugs, such as acetaminophen, cause intrinsic hepatotoxicity, but the majority of agents in this category are industrial, household or environmental toxins such as carbon tetrachloride and alkaloids in mushrooms. The majority of drugs lead to idiosyncratic liver injury and can be classified into metabolic and immunological categories. In the former, the drug is metabolised into a

toxic metabolite in predisposed individuals, while the latter is akin to “drug allergy” or hypersensitivity following sensitisation to the drug. In general, intrinsic hepatotoxicity manifests with hepatocellular necrosis with little inflammation, while idiosyncratic drug reactions often show inflammation-dominant hepatic injury.

ESTABLISHING DRUG AS THE CAUSATIVE AGENT

The temporal profile is crucial to establish the diagnosis of DILI, as the onset of liver disease follows drug ingestion. However, the manifestation of liver toxicity may occur weeks or months after drug ingestion and even after the drug has been stopped. Liver enzyme elevations can persist for up to several months after the drug has been discontinued. In some instances, measurement of serum levels of the drug or its metabolite can be helpful in diagnosis, such as in acetaminophen toxicity. Since the list of drugs capable of causing liver injury is long, a systematic literature search for each drug that the patient has been taking is necessary. The case for DILI is strengthened if the reported pattern of injury in the literature is in keeping with the observed clinical and histological picture. Rechallenge with the drug can help establish the drug aetiology, but it is often not done due to the inherent risk involved. Since diverse histological patterns of DILI can mimic virtually any primary liver disease, appropriate imaging and laboratory tests are necessary to exclude other aetiologies before the diagnosis of DILI can be accepted.

Liver injury can be classified as hepatocellular, cholestatic or mixed, based on criteria established by the Council for International Organizations of Medical Sciences (CIOMS)^{1 2} (table 1).

The CIOMS system also is used for causality assessment of DILI by scoring parameters such as time to onset of symptoms, laboratory data, additional drug regimen, known toxicity of suspected drug, non-drug causes, and response to rechallenge. The total score is categorised into ranges of causality: highly probable, probable, possible, unlikely and excluded.³⁻⁵ The remaining discussion is devoted to the patterns observed in DILI with emphasis on morphological features, common drugs and differential diagnosis for each pattern (table 2).

ACUTE HEPATITIS

DILI accounts for ~10% of acute hepatitis and is perhaps the most common cause of cholestatic hepatitis.⁶ A wide variety of drugs can cause acute hepatocellular injury (box 1).

Herbal and botanical drugs are an important but often overlooked cause of hepatotoxicity (table 3).

Table 1 CIOMS consensus criteria for terminology in drug-induced liver injury

Terminology	Criteria
Hepatocellular injury	Isolated increase in ALT >twice normal, or ALT/ALP \geq 5
Cholestatic injury	Isolated increase in ALP >twice normal, or ALT/ALP \leq 2
Mixed injury	ALT and ALP are increased, and 2<ALT/ALP<5
Acute injury	Above changes present for <3 months
Chronic injury	Above changes present for >3 months
Chronic liver disease	This term is used only after histological confirmation

ALP, alkaline phosphatase; ALT, alanine aminotransferase; CIOMS, Council for International Organizations of Medical Sciences.

These are not regulated by the Food and Drug Administration and hence are not subject to rigorous testing. More than 20 000 herbal products are marketed in forms including powders, essential oils and teas, and more than \$5 billion are spent on these annually. Nearly 20% of American adults have used herbal remedies, and usage is higher in selected groups including Chinese,²⁰ South African²¹ and Native American²² cultures. Definitive identification of an herbal product can require chemical analysis, as mistranslation or misidentification can be an issue. Eliciting a detailed herbal history is imperative.²³ Certain commonly consumed herbal agents now being investigated for their hepatoprotective effects, such as turmeric (*Curcuma longa*)²⁴ and mate tea (*Ilex paraguariensis*),²⁵ are listed as potentially hepatotoxic in various patient literature. Finally, contaminants of herbal supplements should be considered,

including heavy metals such as arsenic, cadmium, lead or mercury.²⁶

The following morphological patterns can be observed in acute hepatocellular injury.

- ▶ Acute hepatitis. The hallmarks of acute hepatocellular injury are portal and parenchymal inflammation, hepatocellular injury, and/or necrosis (fig 1). By definition, fibrosis is absent. Regenerative features such as binucleate hepatocytes and thick cell plates are common. Prominent Kupffer cells often are present in the sinusoids. The term “cholestatic hepatitis” is used when these changes are accompanied by cholestasis (see Acute cholestatic injury).
- ▶ Necrosis. Acute hepatocellular injury can result in necrosis affecting single (spotty necrosis) or groups of hepatocytes (confluent necrosis). In some cases, confluent necrosis can be zonal and may be helpful in diagnosis. Centrizonal (zone 3) necrosis is characteristic of acetaminophen and halothane, and toxins such as carbon tetrachloride. Isolated necrosis affecting zones 1 and 2 is rare; toxins such as cocaine and ferrous sulfate typically affect zone 1, while beryllium has been implicated in zone 2 necrosis. When extensive, confluent necrosis can lead to acute hepatic failure.
- ▶ Resolving hepatitis. If biopsy is performed later in the disease course, hepatocellular injury and inflammation may be minimal (fig 2). The presence of numerous macrophages in the sinusoids is a helpful clue for the diagnosis of resolving hepatitis. The stain periodic acid–Schiff with diastase can be used to highlight the macrophages (fig 3).

Table 2 Overview of drug-induced liver injury patterns

Histological pattern	Differential diagnosis	Common drugs involved
Acute hepatitis and cholestatic hepatitis	Viral hepatitis, autoimmune hepatitis, Wilson disease, idiopathic	See table 3
Acute liver failure		
Necrosis with marked inflammation	Autoimmune hepatitis, viral hepatitis, Wilson disease	Isoniazid, monoamine oxidase inhibitors, anticonvulsants (phenytoin, valproate), antimicrobials (sulfonamides, cotrimoxazole, ketoconazole)
Necrosis with little or no inflammation	Herpes simplex or adenoviral hepatitis, Wilson disease, malignant infiltration	Acetaminophen, cocaine, MDMA (ecstasy), carbon tetrachloride
Microvesicular steatosis with little or no inflammation	Acute alcohol intoxication, Reye syndrome, fatty liver of pregnancy	Tetracycline, nucleoside analogues
Chronic hepatitis		
Autoimmune marker-negative	Autoimmune hepatitis, chronic viral hepatitis, Wilson disease	Lisinopril, sulfonamides, trazodone, uracil, tegafur, tamoxifen, methotrexate
Drug-induced autoimmune hepatitis	Autoimmune hepatitis	Minocycline, nitrofurantoin, methyl dopa, clometacin
Cholestasis		
Bland cholestasis	Sepsis, cardiac failure, shock, large duct obstruction, benign intrahepatic cholestasis, intrahepatic cholestasis of pregnancy	Anabolic/androgenic steroids, oestrogenic steroids, NSAIDs (nimesulide, piroxicam)
Cholestatic hepatitis (cholangiolitic or hypersensitivity cholestasis)	Viral hepatitis, large duct obstruction	Chlorpromazine, clarithromycin
Granulomatous hepatitis	Infections, sarcoidosis, primary biliary cirrhosis, talc, metal toxicity	Isoniazid, interferon, phenytoin, allopurinol (also see box 2)
Steatosis/steatohepatitis		
Macrovesicular steatosis	Diabetes, obesity, Wilson disease, hepatitis C	Alcohol, steroids, total parenteral nutrition, gold, chlorinated hydrocarbons, chemotherapeutic agents (5-fluorouracil)
Microvesicular steatosis	Fatty liver of pregnancy, carnitine deficiency, Reye syndrome	Cocaine, tetracycline, valproic acid, zidovudine
Steatohepatitis	(See macrovesicular steatosis differential)	Amiodarone, chemotherapeutic agents (irinotecan), perhexiline
Vascular abnormalities		
Sinusoidal obstruction syndrome	Myeloablation, venous outflow obstruction, right heart disease	Oxaliplatin, pyrrolizidine alkaloids, chemotherapy for ALL

ALL, acute lymphoblastic leukaemia; MDMA, 3,4-methylenedioxyamphetamine; NSAID, non-steroidal anti-inflammatory drug.

Box 1 Drugs associated with acute hepatitis pattern of injury**Non-steroidal anti-inflammatory drugs**

- ▶ Diclofenac*, indomethacin, tolmetin, sulindac, ibuprofen, ketoprofen, mefenamic acid, celecoxib

Anaesthetic agents

- ▶ Halothane,⁷ methoxyflurane

Anticonvulsants

- ▶ Phenytoin, carbamazepine*, valproic acid, chlorpromazine*

Antibacterial agents

- ▶ Ampicillin, amoxicillin–clavulanic acid,^{5 8 9} oxacillin, cephalosporins, tetracycline, sulfonamides, erythromycin, trimethoprim–sulfamethoxazole*

Antifungal agents

- ▶ Griseofulvin, fluconazole, ketoconazole*

Antiparasitic agents

- ▶ Albendazole, thiabendazole, fansidar

Antituberculous agents

- ▶ Isoniazid, rifampin

Antiviral agents

- ▶ Zidovudine, ribavirin, nevirapine*, efavirenz*

Antitumour agents

- ▶ 6-Mercaptopurine, azathioprine, L-asparaginase, mithramycin, vincristine, cyclophosphamide, carmustine

Antihypertensive agents

- ▶ Methyl dopa, hydralazine, lisinopril, labetalol

Antiarrhythmic agents

- ▶ Quinidine, nifedipine, procainamide

Hypolipidaemics

- ▶ Statins, clofibrate, nicotinic acid, ezetimibe*

Hypoglycaemics*

- ▶ Rosiglitazone, troglitazone

Antiandrogens*

- ▶ Flutamide

Other

- ▶ Sulfonylureas, troglitazone, dantrolene, chlorzoxazone, dextropropoxyphene, allopurinol, gold

Toxins

- ▶ Aflatoxin, death cap mushroom (*Amanita phalloides*), carbon tetrachloride, ethylene dichloride, allyl compounds, ferrous sulfate, phosphorus, MDMA (ecstasy)

*Primarily cholestatic pattern

Differential diagnosis

The histological features can be indistinguishable from other causes of acute hepatitis such as acute viral hepatitis, initial presentation of autoimmune hepatitis and Wilson disease. The presence of bile duct injury, prominent eosinophilic infiltrate, granulomas, sharply defined perivenular necrosis, or cholestasis

out of proportion to hepatocellular injury, favours adverse drug reaction, but none of these features is specific.

ACUTE LIVER FAILURE (FULMINANT HEPATITIS)

Acute liver failure (ALF) is defined as the onset of hepatic encephalopathy within 8 weeks of onset of symptoms. Drugs are the most common cause of ALF in the USA, accounting for 25–50% of cases.^{27–30}

Based on morphological features, ALF can be subdivided into three categories.

- ▶ Extensive microvesicular steatosis. This pattern is rare and has been observed with tetracycline and nucleoside analogues such as zidovudine (see Steatosis and steatohepatitis).
- ▶ Necrosis with marked inflammatory activity. This is the most common pattern seen in idiosyncratic adverse drug reactions. It is similar to the acute hepatitis pattern discussed above except that the confluent necrosis involves most of the liver parenchyma (massive/submassive hepatic necrosis). The most commonly implicated drugs are isoniazid,^{31 32} other antimicrobial agents (sulfonamides, cotrimoxazole, ketoconazole), monoamine oxidase inhibitors, and anticonvulsants (phenytoin,³¹ valproate). Any drug that causes acute hepatitis can potentially cause ALF.
- ▶ Necrosis with little or no inflammation. This pattern is seen with acetaminophen (fig 4), recreational drugs such as cocaine and 3,4-methylenedioxymethylamphetamine (MDMA; ecstasy), industrial organic compounds such as carbon tetrachloride, and some herbal preparations. Necrosis can be accompanied by steatosis.

Acetaminophen

Acetaminophen toxicity is the leading drug-related cause, implicated in nearly 40% of ALF, the remaining being attributed to idiosyncratic drug reactions.^{27–29 33} Acetaminophen is a very safe drug within its therapeutic window (3–4 g/day), but can cause dose-dependent toxicity with overdose whether accidental (1/3 of cases) or with suicidal intent (2/3 of cases). At low doses, the drug is conjugated to water-soluble metabolites in the liver and is excreted in the urine. At higher doses, glutathione depletion leads to saturation of the conjugation mechanism, leaving the parent compound to be metabolised to toxic intermediates. The minimum toxic dose in adults is 7.5–10 g, but severe liver damage occurs with ingestion of 15–25 g. Acetaminophen blood levels taken 4–16 h after ingestion are the best predictor of outcome. Chronic alcohol consumption, obesity, and drugs that induce the P-450 cytochrome system, such as isoniazid, phenytoin, carbamazepine or cimetidine, can lower the toxic threshold of acetaminophen.

Patients typically experience gastrointestinal symptoms for the first 12–24 h and a latent phase at 24–48 h. The onset of acute hepatitis/acute liver failure occurs 72–96 h after drug ingestion. Hepatotoxicity can be prevented with early presentation and institution of acetyl-cysteine therapy within 12 h. The highest mortality is encountered in late presenters.

CHRONIC HEPATITIS

Chronic liver disease typically refers to persistent biochemical abnormalities beyond 6 months.³⁴ In some series, the cut-off of 3 months has been used for hepatocellular injury and 6 months for cholestatic or mixed injury.³⁵ Progression to chronicity has been reported in 5–10% of adverse drug reactions and is higher for the cholestatic/mixed injury pattern.³⁶ Histologically proven drug-induced chronic hepatitis with fibrosis is a rare

Table 3 Herbal products with known hepatotoxicity

Herbal product ¹⁰⁻¹¹	Intended use	Biopsy findings
Chaparral leaf (creosote bush, <i>Larrea tridentata</i>), ¹² teas and capsules	Antimicrobial, anti-aging, skin conditions	Acute hepatitis, cholestasis, hepatocellular necrosis
Germander (<i>Teucrium</i> genus), ¹³⁻¹⁴ teas and tablets	Antiseptic, antipyretic, abdominal ailments, obesity	Acute hepatitis, centrilobular necrosis, rarely chronic liver disease with cirrhosis
Pennyroyal (<i>Mentha pulegium</i> , <i>Hedeoma pulegioides</i>), ¹⁵ "squaw mint" oil	Emmenagogue, abortifacient, anti-flea agent for pets	Centrilobular necrosis
Glue thistle (<i>Atractylis gummifera</i>), ¹⁶ found in Mediterranean region and North Africa	Emetic, diuretic, antipyretic	Centrilobular necrosis, panacinar necrosis
Jin bu huan (<i>Lycopodium serratum</i>), ¹⁷ marketed as anodyne tablets in 1990s	Sleeping aid, analgesic	Acute hepatitis, chronic hepatitis, microvesicular steatosis
Kava (<i>Piper methysticum</i>) ²⁻¹⁸	Stress relief, anti-anxiety, sleeping aid, premenstrual syndrome	Acute hepatitis, fulminant hepatitis
Mistletoe (<i>Phoradendron</i> and <i>Viscum geni</i>) ¹⁹	Digestive aid, heart tonic, sedative	Acute hepatitis

phenomenon. Some specific patterns and clinicopathological situations are discussed below.

Chronic hepatitis with negative autoimmune markers

The histological features are indistinguishable from chronic viral hepatitis, and progression to fibrosis and even cirrhosis can occur. The features of acute hepatitis may be seen to a variable degree. Drugs associated with this pattern include lisinopril (antihypertensive), sulfonamide (antibiotic), trazodone (anti-depressant), and chemotherapeutic agents such as uracil, 5-fluorouracil prodrug tegafur and tamoxifen. Isolated case reports implicate numerous other drugs including phenytoin³⁷ and the Chinese herb Jin bu huan.³⁸ Progression to fibrosing cholestatic hepatitis has been reported in a hepatitis C patient after administration of cyclophosphamide and corticosteroids for glomerulonephritis.³⁹ Discontinuation of the drug may lead to a favourable outcome, but if the fibrosis is advanced the resolution may be slow or the disease may progress.

Autoimmune hepatitis

Several drugs can cause chronic hepatitis that is serologically and morphologically indistinguishable from de novo autoimmune hepatitis (AIH). The hepatic disease may be accompanied by features of hypersensitivity such as rash, arthralgia and peripheral eosinophilia.

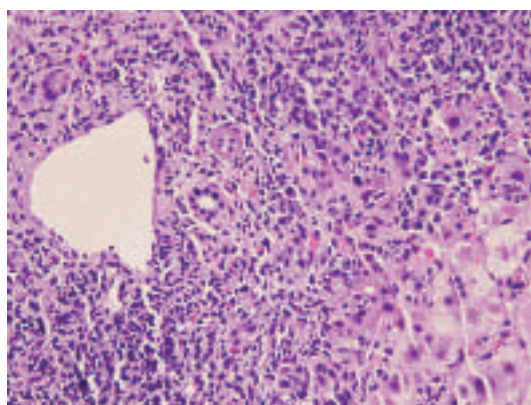


Figure 1 Atorvastatin-induced acute hepatitis. Mixed parenchymal inflammation is present, consisting of lymphocytes, plasmahistiocytic cells, and neutrophils. There is no bile duct damage or fibrosis. H&E, $\times 200$.

Minocycline

Long-term use of minocycline, a synthetic tetracycline for treatment of acne, can lead to hepatitis that can mimic lupus-related hepatitis, AIH or overlap syndrome. Autoimmune disease can develop within days of starting the drug or may be delayed for many years. High titres of antinuclear antibodies (ANAs) are common, but smooth muscle (SMA) and other autoantibodies often are negative. Autoimmune markers may be elevated in chronic hepatitis due to drugs (drug-induced autoimmune hepatitis). Inflammatory activity can be minimal to mild, and eosinophils are typically inconspicuous (fig 5). Marked fibrosis and cirrhosis are rare, and patients often improve after drug withdrawal.⁴⁰ Microvesicular and macrovesicular steatosis in response to minocycline have been reported, but these followed high-dose intravenous therapy rather than oral administration.⁴¹

Nitrofurantoin

Nitrofurantoin is used to treat urinary tract infections. The hepatic injury can manifest as self-limited acute hepatitis, chronic hepatitis, and rarely as hepatic failure.⁴² Chronic hepatitis can be indistinguishable from de novo AIH and is often associated with ANA and SMA.⁴³ Discontinuation of the drug generally leads to clinical and biochemical improvement. In some cases, the disease may progress despite drug withdrawal. In contrast to minocycline, significant fibrosis and cirrhosis can occur.

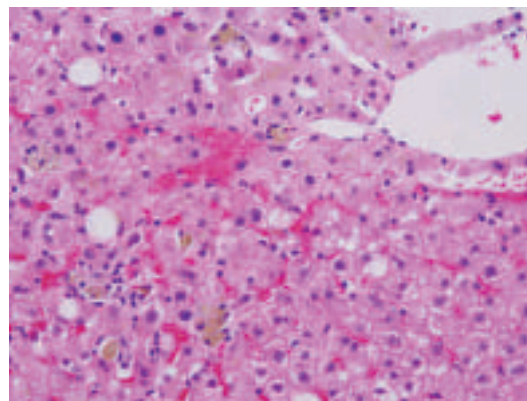


Figure 2 Resolving hepatitis. Parenchymal infiltrate is diminished in comparison to acute hepatitis. Hepatocellular injury is minimal. Pigment accumulation in sinusoidal macrophages is prominent. H&E, $\times 200$.

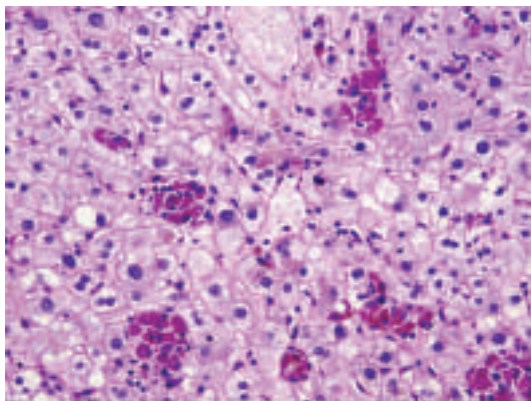


Figure 3 Resolving hepatitis. Sinusoidal macrophages are evident with periodic acid–Schiff (PAS)-positive diastase-resistant cytoplasmic contents. PAS with diastase, $\times 200$.

Others

Other drugs implicated in AIH include methyldopa (antihypertensive)⁴⁴ and clometacin non-steroidal anti-inflammatory drug (NSAID).⁴⁵ Antibodies to liver-kidney-microsomal antibodies, akin to type 2 AIH, have been described in hepatitis related to hydralazine (antihypertensive) and tienilic acid (ticrynafen, a diuretic withdrawn from the American market), but this association is not clearly defined.⁴⁶

Methotrexate

Methotrexate is a folate antagonist that is used for long-term treatment of rheumatoid arthritis, psoriasis and inflammatory bowel disease. The canals of Hering may be the target of methotrexate-related scarring.⁴⁷ The risk of liver toxicity is exacerbated with heavy alcohol use, pre-existing liver disease, daily dosing and high cumulative dose.⁴⁸ Minor elevation in liver enzymes occurs in 20–50% of patients but does not necessarily imply significant toxicity.

The histological features of methotrexate-related toxicity range from minor fatty change, hepatocyte anisonucleosis, mild portal-based inflammation, and focal necrosis to more severe hepatocellular necrosis, fibrosis and cirrhosis (fig 6). Methotrexate may exacerbate or precipitate steatohepatitis in patients with risk factors such as obesity and diabetes. Some patients with high cumulative dose can have steatohepatitis-like histology without other risk factors.⁴⁹

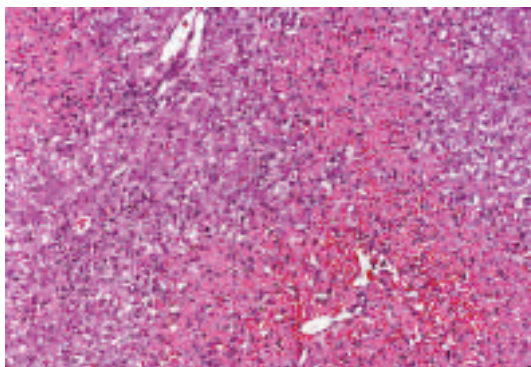


Figure 4 Acetaminophen toxicity. Marked hepatocellular necrosis is present in a zonal, centrilobular pattern, while the inflammatory infiltrate is minimal. Residual viable hepatocytes show some steatosis. H&E, $\times 100$. (Image courtesy of Dr Linda Ferrell, University of California, San Francisco, California, USA.)

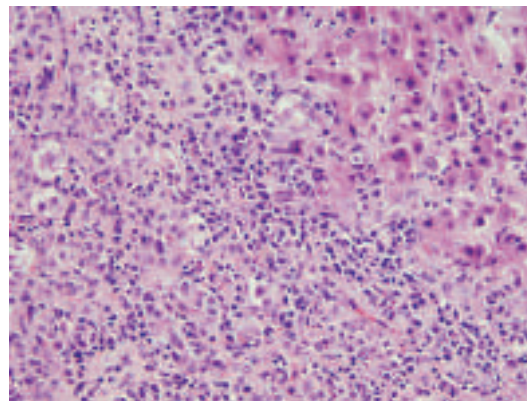


Figure 5 Minocycline-induced autoimmune hepatitis. Marked necroinflammatory activity with numerous plasma cells. H&E, $\times 200$.

Patients on long-term methotrexate need close monitoring. Liver biopsy is necessary in patients who develop deranged liver function following methotrexate therapy. A grading scheme has been proposed to assess toxicity (Roeningk classification^{50–52}; table 4).

ACUTE CHOLESTATIC INJURY

Drug-induced cholestatic injury can manifest clinically with jaundice, pruritus, dark urine and pale stools. Liver enzyme studies typically reveal elevation of alkaline phosphatase and γ -glutamyl transferase. Transaminases can be variably elevated. A Danish study of 1100 cases of drug-associated injury reported 16% with the acute cholestatic pattern.⁵³

The histological patterns of injury can be divided into two forms. (1) Pure (bland) cholestasis in which bile plugs are seen in hepatocytes or canaliculi and are most prominent in zone 3. Inflammation and hepatocellular injury are not observed. This pattern is typically observed with anabolic steroids (fig 7) and oral contraceptives. Other drugs that have been incriminated include prochlorperazine, thiabendazole⁵⁴ and warfarin. (2) Cholestatic hepatitis in which the cholestasis is accompanied by inflammation and hepatocellular injury. Bile ductular reaction may be present. This pattern also has been referred to as cholangiolitic or hypersensitivity cholestasis.⁵⁵ This pattern manifests as mixed-type injury on liver biochemical tests.

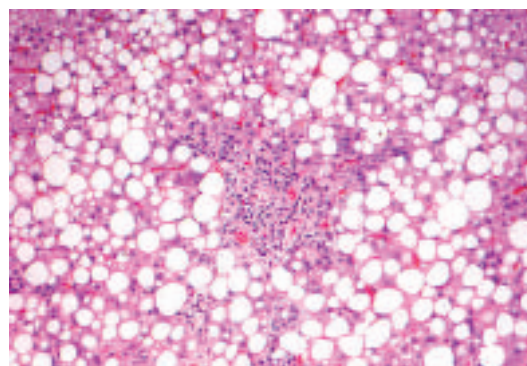


Figure 6 Methotrexate toxicity. Prominent macrovesicular steatosis and periportal fibrosis. H&E, $\times 100$. (Image courtesy of Dr Linda Ferrell, University of California, San Francisco, California, USA.)

Table 4 Roenigk classification system⁵¹

Roenigk grade	Fatty change	Nuclear pleomorphism	Necroinflammatory damage	Fibrosis
I	Mild or none	Mild or none	Mild or none	None
II	Moderate or severe	Moderate or severe	Moderate or severe portal inflammation	None
IIIa	With or without	With or without	With or without	Mild
IIIb	With or without	With or without	With or without	Moderate or severe
IV	With or without	With or without	With or without	Cirrhosis

A score of IIIb or IV is an indication to discontinue the drug. Early detection and discontinuation of the drug is associated with a favourable outcome.

Cholestatic hepatitis can result from a wide variety of drugs; it is the classic pattern seen with toxicity due to macrolide antibiotics such as erythromycin⁵⁶ (fig 8) and the antipsychotic agent chlorpromazine (see box 1).

Differential diagnosis

Drug-induced cholestatic injury can be histologically indistinguishable from obstructive biliary disease. While the latter typically results in portal tract oedema and ductular reaction with inflammation, cholestasis may be the only significant feature in early stages. Drug-induced cholestatic hepatitis also needs to be distinguished from autoimmune hepatitis and acute viral hepatitis.

Bland cholestasis can occur in several systemic disorders such as sepsis, cardiac failure and shock, and hence clinical information is necessary to establish the aetiology. In the appropriate clinical setting, benign recurrent intrahepatic cholestasis, post-operative cholestasis and intrahepatic cholestasis of pregnancy have to be considered. Benign recurrent intrahepatic cholestasis is a mild, non-progressive variant of bile transporter disorder characterised by intermittent episodes of cholestasis.⁵⁷ Intrahepatic cholestasis of pregnancy also is due to bile transporter gene variation, although it additionally appears affected by hormonal status, as twin pregnancies and patients on oral contraceptives are reported to be more susceptible to intrahepatic cholestasis of pregnancy.⁵⁸

Chronic biliary diseases such as primary biliary cirrhosis and primary sclerosing cholangitis do not show cholestasis on biopsy early in the course of the disease; serological tests such as antimitochondrial antibodies and cholangiography, respectively, can more definitely rule out these diagnoses.

CHRONIC CHOLESTASIS AND DUCTOPENIA

Cholestatic symptoms and biochemical findings usually resolve with cessation of the offending drug but may persist in some instances. Drugs causing prolonged cholestasis (defined as greater than 3 months in duration)^{1 59} and ductopenia include antibiotics such as amoxicillin–clavulanic acid^{60 61} and flucloxacillin,^{62 63} antifungals such as terbinafine⁶⁴ and, rarely, oral contraceptives.⁶⁵ Amiodarone can also cause prolonged disease.⁶⁶

Vanishing bile duct syndrome

Cholestasis with variable degree of inflammation, bile duct injury and hepatocellular damage is seen early in the course of the disease (fig 9). If the disease persists for a few months or beyond, loss of bile ducts and overt ductopenia may be observed, termed “vanishing bile duct syndrome”. Persistent inflammation and bile ductular reaction also may be present. Rare cases can progress to cirrhosis. Vanishing bile duct syndrome can be triggered by anticonvulsants such as carbamazepine⁶⁷ and zonisamide,⁶⁸ antipsychotics such as chlorpromazine⁶⁹ and sulpiride,⁷⁰ NSAIDs such as ibuprofen^{71 72} and tenoxicam,⁷³ and antibiotics such as amoxicillin,⁷⁴ flucloxacillin,⁷⁵ clindamycin and trimethoprim-sulfamethoxazole.⁷⁶ The histological picture can mimic primary biliary cirrhosis or obstructive biliary disease. Absence of antimitochondrial antibodies and normal imaging of the biliary tree help in establishing drug-related aetiology.

Other patterns

Biliary sclerosis can result from intra-arterial infusion of 5-fluorodeoxyuridine for treatment of hepatic metastasis of colorectal carcinoma.⁷⁷ Ischaemic injury to the large intrahepatic and extrahepatic bile ducts can lead to strictures that resemble

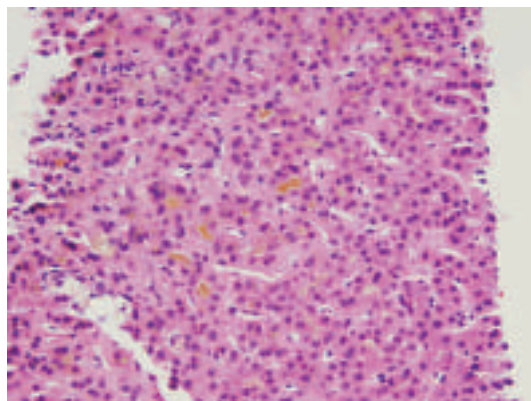


Figure 7 Anabolic-steroid-induced pure cholestasis. Prominent bile plugs are present in hepatocytes and canaliculi without inflammation or hepatocellular damage. H&E, $\times 200$.

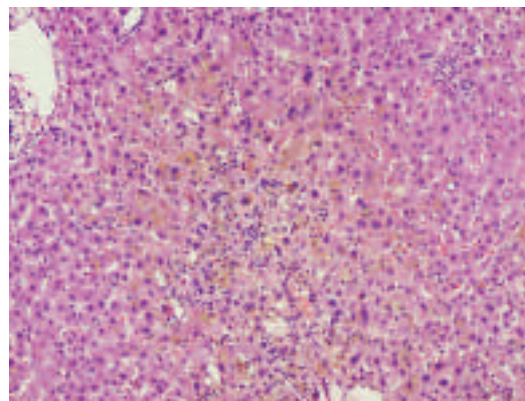


Figure 8 Erythromycin-related cholestatic hepatitis. Features similar to acute hepatitis are present, as well as bile plugs in hepatocytes and canaliculi. H&E, $\times 100$.

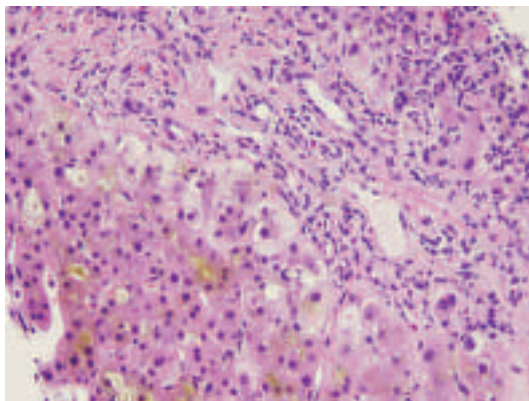


Figure 9 Prolonged cholestasis. Persistence of canalicular bile plugs accompanied by feathery degeneration of periportal hepatocytes (cholelathasis). H&E, $\times 200$.

primary sclerosing cholangitis radiologically and histologically. Similar injury can occur with other agents such as formaldehyde and sodium chloride injected into hydatid cysts.

GRANULOMATOUS HEPATITIS

The most common causes of granulomas in the liver are infections, sarcoidosis, primary biliary cirrhosis and drugs (box 2).

Granulomas are uncommon in hepatitis C but can occur in patients treated with interferon. Talc granulomas can occur in intravenous drug users and can be detected by viewing under polarised light. Other systemic granulomatous disease such as chronic metal toxicity (such as beryllium or copper) can also involve the liver.⁵⁵ Finally, a study of granulomatous hepatitis cases over a 13-year period identified 11% as idiopathic.⁷⁹ These cases can present with fever of unknown origin and generally respond favourably to steroids.

The granulomas can be present in the portal tracts or the parenchyma and lack necrosis. Unlike in primary biliary cirrhosis, the granulomas are not centred on the bile ducts. Granulomas also can occur with other patterns of liver injury such as acute hepatitis, cholestasis or steatosis.

The term fibrin-ring granuloma has been used for small granulomas that consist of a ring of fibrin arranged around a central fat vacuole (fig 10). Epithelioid histiocytes are present around the ring of fibrin. In atypical cases, the fibrin is

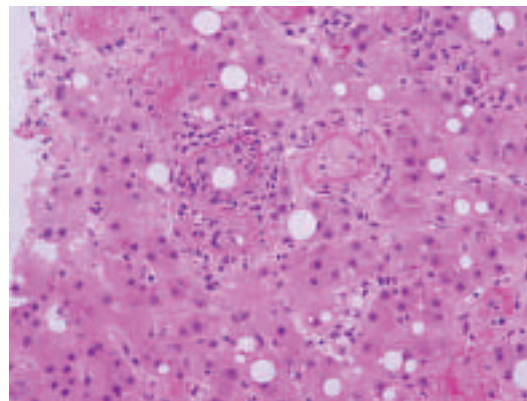


Figure 10 Fibrin-ring granulomas. Fat vacuole surrounded by a ring of fibrin deposition and epithelioid cells. H&E, $\times 200$.

intermixed with the histiocytes and does not form a well-defined ring. More typical granulomas without the fibrin ring generally are present in other areas of the biopsy. Fibrin-ring granulomas have been described with allopurinol, BCG vaccination and intravesical therapy for carcinoma. These granulomas were first described in the rickettsial disease Q fever (*Coxiella burnetii*) but also occur in boutonneuse fever (*Rickettsia conorii*), leishmaniasis, toxoplasmosis, cytomegalovirus infection and Hodgkin lymphoma.

STEATOSIS AND STEATOHEPATITIS

Macrovesicular steatosis

Macrovesicular steatosis includes large and small droplet fat. The term “large droplet fat” is used when at least half the hepatocyte cytoplasm is occupied by a single lipid vacuole, while multiple lipid vacuoles are seen in small droplet fat. The latter often is confused with true microvesicular steatosis which, unlike small droplet fat, affects the liver in a diffuse fashion (see below). Macrovesicular steatosis can be seen in association with steroids,⁸⁰ nitrofurantoin, gold, methotrexate, NSAIDs such as ibuprofen, indomethacin and sulindac, and antihypertensives such as metoprolol, chlorinated hydrocarbons such as carbon tetrachloride and chloroform,⁸¹ or chemotherapeutic agents such as 5-fluorouracil, cisplatin and tamoxifen.⁸²

Microvesicular steatosis

Exclusive or predominant microvesicular steatosis diffusely affecting the liver is a result of mitochondrial injury and often occurs as an adverse effect of drugs/toxins such as cocaine, tetracycline, valproic acid and zidovudine (fig 11). Acute exposure to alcohol (alcohol foamy liver degeneration)⁸³ and paediatric Reye syndrome also show diffuse microvesicular steatosis.⁸⁴ Other non-drug related aetiologies include acute fatty liver of pregnancy and genetic diseases such as carnitine deficiency.

Steatohepatitis

By definition, steatohepatitis is characterised by steatosis, lobular inflammation and hepatocellular injury in the form of hepatocellular ballooning (with or without acidophil bodies or Mallory hyaline) or pericellular fibrosis. A few drugs (notably amiodarone and irinotecan) play a direct aetiological role in steatohepatitis. Most other drugs exacerbate or precipitate steatohepatitis in the presence of other risk factors such as obesity and diabetes.

Box 2 Drugs implicated in granulomatous hepatitis

Antimicrobials

- ▶ Isoniazid, penicillin, sulfonamides, cephalixin, dapson, dicloxacillin, oxacillin, interferon

Anticonvulsants/antipsychotic agents

- ▶ Phenytoin, diazepam, chlorpropamide, chlorpromazine, procarbazine, carbamazepine

Others

- ▶ Allopurinol, gold, procainamide, quinidine, methyl dopa, diclofenac, diltiazem, BCG therapy for cancer, nitrofurantoin, mesalamine, phenylbutazone (veterinary use, use in humans limited due to side effect of aplastic anaemia)⁷⁸

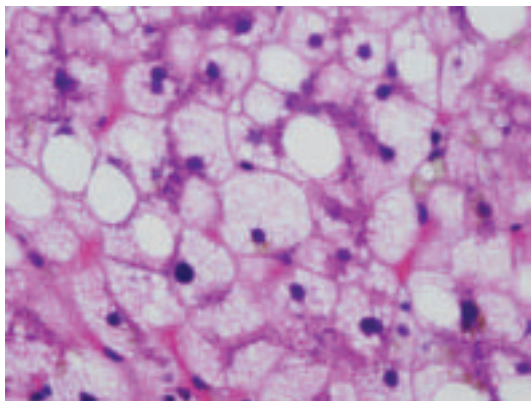


Figure 11 Microvesicular steatosis. Numerous small lipid droplets are present throughout the hepatocytic cytoplasm. H&E, $\times 400$.

Amiodarone

Amiodarone, a potent antiarrhythmic agent, causes elevated liver enzymes in up to 30% of patients^{85 86} and steatohepatitis in 1–2%⁸⁷ of patients. The majority of cases display liver enzyme abnormalities within 24 h of intravenous infusion.⁸⁸ Even low oral dosing (200 mg daily) may trigger steatohepatitis with cumulative use.⁸⁹ Occasionally, jaundice is the major clinical presentation. These cases often show hepatocellular necrosis and fibrosis, and have a poor prognosis.⁶⁶

Amiodarone steatohepatitis is characterised by prominent Mallory hyaline (occasionally in zone 1) and neutrophilic satellitosis, while steatosis is less conspicuous (fig 12). The findings can be similar to alcoholic steatohepatitis. Reversal of liver injury often occurs with discontinuation of the drug but may be delayed by weeks or months. In addition, amiodarone is also associated with a different type of lipid accumulation called “phospholipidosis” characterised by accumulation of drug in the lysosomes.^{90 91} This leads to “foamy” appearance of hepatocytes and Kupffer cells. The foamy areas show lamellar lysosomal inclusion bodies on electron microscopy⁹² (fig 13). Phospholipidosis is not always seen in amiodarone toxicity⁹⁰ and is independent of steatohepatitis.⁹³

Perhexiline maleate (Pexid), an antianginal drug, and diethylaminoethoxyhexestrol (Coralgil), a vasodilator, have been used extensively in Europe and Japan, respectively. Both drugs can cause steatohepatitis and phospholipidosis similar to amiodarone.^{94 95}

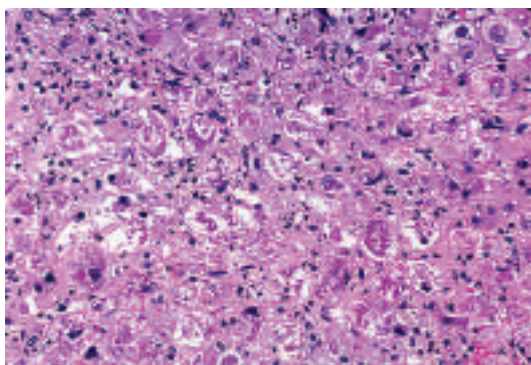


Figure 12 Amiodarone steatohepatitis. Marked hepatocyte ballooning, numerous Mallory hyaline and minimal steatosis. H&E, $\times 100$.

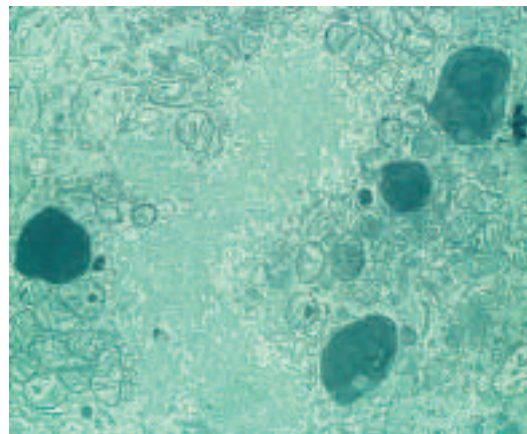


Figure 13 Phospholipidosis. Formation of lysosomal inclusion bodies due to accumulation of amiodarone. Electron micrograph. (Image courtesy of Dr Linda Ferrell, University of California, San Francisco, California, USA.)

Chemotherapy-induced steatohepatitis

Steatosis and steatohepatitis have been reported with chemotherapeutic agents. The latter especially is associated with irinotecan, a drug often used preoperatively in colorectal cancer with hepatic metastases. This has been referred to as chemotherapy-associated steatohepatitis in the oncology literature.^{82 96} Other chemotherapeutic agents such as oxaliplatin have been variably implicated.^{82 97}

Others

Drugs such as tamoxifen, steroids, oestrogen and diethylstilbestrol often lead to hepatic steatosis, but steatohepatitis is rare. These drugs may exacerbate or precipitate steatohepatitis in patients with risk factors for steatohepatitis rather than play an aetiological role. The evidence linking steatohepatitis and calcium channel blockers such as nifedipine also is anecdotal. Risk factors for steatohepatitis were present in many reported cases, creating uncertainty about the association of these drugs with steatohepatitic injury.⁹⁸

VASCULAR ABNORMALITIES

Several vascular patterns of injury are recognised, each with distinctive morphological features and drug associations.

Sinusoidal obstruction syndrome

Sinusoidal obstruction syndrome (SOS; veno-occlusive disease) is due to endothelial cell injury to small hepatic venules that manifests histologically as endothelial swelling and thrombosis (fig 14). The resultant venous outflow obstruction leads to sinusoidal dilatation, congestion, hepatocellular necrosis, and can result in centrilobular fibrosis.

Cytotoxic/chemotherapeutic drugs such as oxaliplatin (used in colorectal cancer) can cause injury to sinusoidal endothelial cells and hepatic stellate cells.^{97 99 100} SOS can also occur due to myeloablation before stem cell transplantation, chemotherapy for acute lymphocytic leukaemia, bone marrow transplantation¹⁰¹ and pyrrolizidine alkaloids.⁹⁷ Genetic polymorphisms in methylenetetrahydrofolate reductase have been implicated in SOS in post-transplant patients.¹⁰² Recently, defibrotide has been used with success to resolve cases of SOS,¹⁰³ although in some cases, transplantation can be required.¹⁰⁴

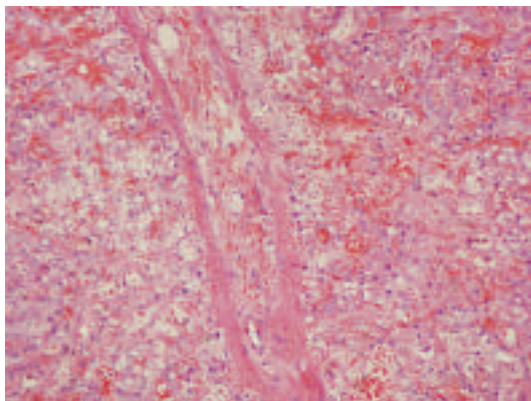


Figure 14 Sinusoidal obstruction syndrome. Endothelial injury in small hepatic venules leads to luminal occlusion due to endothelial swelling and thrombosis, and results in sinusoidal dilatation and congestion. H&E, $\times 100$.

Peliosis hepatis

Peliosis is characterised by blood-filled cavities without an endothelial lining in the hepatic parenchyma (fig 15). This phenomenon most commonly is associated with androgens¹⁰⁵ or contraceptive steroids.¹⁰⁶ Thiopurine-derived chemotherapeutic drugs also have been implicated.^{107–108} Peliosis also occurred with the intravenous contrast agent thorium dioxide (Thorotrast), which has been discontinued due to the high risk of angiosarcoma.^{109–110} Sinusoidal dilatation may accompany peliosis or may occur independently, particularly with androgenic or oestrogenic steroid use.¹¹¹

Hepatic vein thrombosis

Hepatic vein thrombosis is a rare complication of some drugs, including oral contraceptives^{112–113} and dacarbazine,¹¹⁴ and presents clinically as Budd-Chiari syndrome.

OTHER PATTERNS

Stellate cell lipidosis

Hepatic stellate cells (Ito cells) are modified fibroblasts that store lipids and vitamin A in the normal liver. They are located in the space of Disse between the sinusoidal endothelium and the hepatocytes but generally are not easily visible.¹¹⁵ In certain conditions, especially hypervitaminosis A, excessive lipid gets stored in the stellate cells (stellate cell lipidosis, fig 16). The nuclei of stellate cells are crescent shaped, dark staining, and

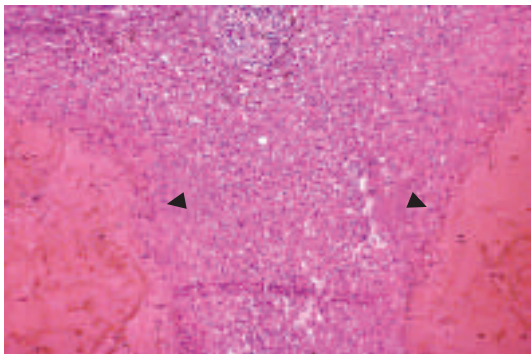


Figure 15 Peliosis. The hepatic parenchyma contains blood-filled cavities that lack an endothelial lining (arrows). H&E, $\times 66$. (Image courtesy of Dr Linda Ferrell, University of California, San Francisco, California, USA.)

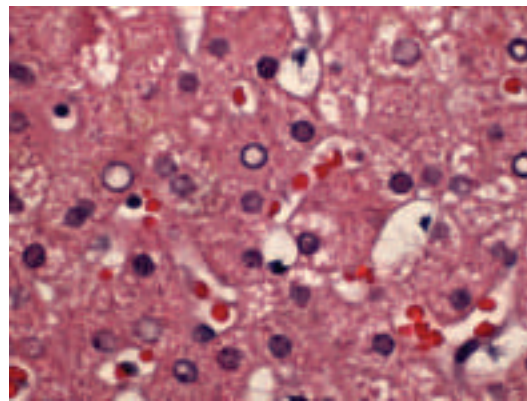


Figure 16 Stellate cell (Ito cell) lipidosis. Fat-laden stellate cells showing multiple lipid vacuoles with indentation of the nucleus. Note the location of Ito cells along the sinusoids in the space of Disse. H&E, $\times 400$.

indented by the lipid droplets. Thin strands of cytoplasm separate the lipid droplets. These lipid-laden cells easily can be mistaken for hepatocytes with steatosis. Their characteristic morphology and location along the sinusoids between the hepatic plates distinguishes them from steatotic hepatocytes.¹¹⁶

Hypervitaminosis A results from excess dietary/supplementary vitamin A intake or use of oral/topical retinoids (such as tretinoin for acne). Stellate cell lipidosis also has been reported with methotrexate, valproate and steroids, as well as in other clinical settings such as cholestasis, alcoholic liver disease and hepatitis C.

It is important to recognise this condition, as activation of stellate cells can lead to fibrosis, non-cirrhotic portal hypertension and, rarely, cirrhosis. One case of liver transplantation for subacute vitamin A toxicity has been reported.¹¹⁷ Early recognition can prompt reduced intake of vitamin A to avert progression and fibrosis. The contribution of stellate cell lipidosis to disease progression when present with other disease processes such as alcoholic liver disease and chronic hepatitis C is unknown.

Cytoplasmic inclusions

Ground glass change in the cytoplasm occurs in a minority of patients with hepatitis B and is characterised by pale eosinophilic

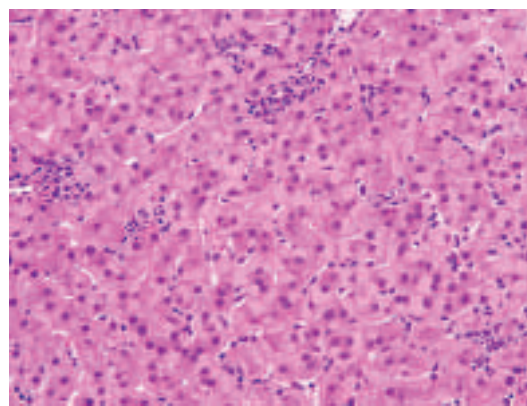


Figure 17 Ground-glass hepatocytes. This change can be seen with drugs such as cyanamide (used for treating alcohol abuse), diazepam and barbiturates, and in patients on insulin or intravenous glucose therapy. H&E, $\times 200$.

Review

Take-home messages

- ▶ Drug-induced liver injury can mimic any pattern of primary liver disease. A thorough clinical history, including exposure to herbal, over-the-counter agents and toxins, along with a systematic literature search, is critical to establish the diagnosis.
- ▶ Acute hepatitis, with or without cholestasis, is the most common histological pattern of drug-induced liver injury. Drugs such as acetaminophen are the most common cause of acute liver failure in the USA.
- ▶ Drug-induced chronic hepatitis is rare, but fibrosis and cirrhosis can occur with drugs such as methotrexate, while autoimmune hepatitis-like disease can result with drugs such as minocycline.
- ▶ In some instances, drug-related cholestatic injury can be prolonged and can lead to ductopenia.
- ▶ Drug-induced steatohepatitis is a rare phenomenon, but is well known to occur with amiodarone and irinotecan. Many drugs, such as tamoxifen, oestrogenic drugs and nifedipine, can precipitate or exacerbate steatohepatitis in the presence of other risk factors.

Interactive multiple choice questions

This JCP best practice article has an accompanying set of multiple choice questions (MCQs).

To access the questions, click on BMJ Learning: take this module on BMJ Learning from the content box at the top right and bottom left of the online article. For more information please go to: <http://jcp.bmj.com/education> Please note: the MCQs are hosted on BMJ Learning – the best available learning website for medical professionals from the BMJ Group.

If prompted, subscribers must sign into JCP with their journal's username and password. All users must also complete a one-time registration on BMJ Learning and subsequently log in (with a BMJ Learning username and password) on every visit.

cytoplasmic inclusions in hepatocytes. Similar changes (often termed "pseudo ground glass change", fig 17) can be seen with drugs such as cyanamide, a drug used in alcohol treatment programs.^{118–119} This phenomenon has also been described with other drugs such as barbiturates and diazepam, diabetic patients on insulin, and transplant patients on multiple immunosuppressive drugs such as steroids, tacrolimus and mycophenolate mofetil.^{119–120} Similar to hepatitis B, this change reflects hypertrophy of smooth endoplasmic reticulum with use of drugs such as barbiturates, while most other drug-induced cases are due to accumulation of abnormal glycogen.^{118–120} Rare metabolic disorders such as type IV glycogenosis, hypofibrinogenaemia, and Lafora disease can lead to the same morphological findings.

Pigments

Some drugs/toxins such as gold, titanium and thorium dioxide (Thorotrast) can be deposited as pigments in the liver. Drugs that cause prolonged cholestasis can lead to copper accumulation in periportal hepatocytes. Lipofuscin, a lysosomal pigment often seen in centrilobular hepatocytes, can be increased with

exposure to anticonvulsant drugs such as phenothiazine and phenacetin.

Hepar lobatum

This term generally refers to liver abnormalities in tertiary syphilis. In some instances, chemotherapy for metastatic liver cancer (especially from the breast) can lead to similar changes. The liver shows a lobulated contour with capsular indentations from which fibrous septa extend deep into the parenchyma.¹²¹ The fibrous septa can surround the degenerated centre of tumour nodules and may contain macrophages and residual tumour. Typical features of cirrhosis such as regenerative nodules are not observed. These features probably result from tissue collapse due to chemotherapy-related tumour regression that is followed by an organising phase of healing and scar contraction.¹²¹

Drug-related neoplasms

The association of oral contraceptives and hepatic adenomas is well recognised.¹²² Association with focal nodular hyperplasia and hepatocellular carcinoma also has been reported,^{123–124} but the link is less convincing. Other agents such as anabolic steroids used by sportsmen, clomiphene, danazol and carbamazepine have also been associated with hepatic adenoma.^{125–126}

Exposure to vinyl chloride (an industrial chemical) and thorium dioxide (a discontinued radiographic contrast agent) can lead to angiosarcoma, sometimes after long latent periods exceeding 20 years.¹²⁷ Hepatocellular carcinoma and cholangiocarcinoma also have been reported with thorium dioxide.¹²⁸

Competing interests: None.

REFERENCES

1. **Watkins PB**, Seeff LB. Drug-induced liver injury: summary of a single topic clinical research conference. *Hepatology* 2006;**43**:618–31.
2. **Teschke R**, Schwarzenboeck A, Hennermann KH. Kava hepatotoxicity: a clinical survey and critical analysis of 26 suspected cases. *Eur J Gastroenterol Hepatol* 2008;**20**:1182–93.
3. **Danan G**, Benichou C. Causality assessment of adverse reactions to drugs. I. A novel method based on the conclusions of international consensus meetings: application to drug-induced liver injuries. *J Clin Epidemiol* 1993;**46**:1323–30.
4. **Benichou C**, Danan G, Flahault A. Causality assessment of adverse reactions to drugs. II. An original model for validation of drug causality assessment methods: case reports with positive rechallenge. *J Clin Epidemiol* 1993;**46**:1331–6.
5. **Andrade RJ**, Lucena MI, Fernández MC, *et al*. Drug-induced liver injury: an analysis of 461 incidences submitted to the Spanish registry over a 10-year period. *Gastroenterology* 2005;**129**:512–21.
6. **Zimmerman HJ**. Drug-induced liver disease. *Clin Liver Dis* 2000;**4**:73–96.
7. **Björnsson E**, Olsson R. Suspected drug-induced liver fatalities reported to the WHO database. *Dig Liver Dis* 2006;**38**:33–8.
8. **Velayudham LS**, Farrell GC. Drug-induced cholestasis. *Expert Opin Drug Saf* 2003;**2**:287–304.
9. **Hartleb M**, Biernat L, Kochel A. Drug-induced liver damage – a three-year study of patients from one gastroenterological department. *Med Sci Monit* 2002;**8**:CR292–6.
10. **Memorial Sloan-Kettering Cancer Center**. About herbs, botanicals and other products. <http://www.mskcc.org/mskcc/html/58481.cfm> (accessed 18 February 2009).
11. **United States Department of Agriculture**. Natural Resources Conservation Service. PLANTS database. <http://plants.usda.gov/index.html> (accessed 18 February 2009).
12. **Batchelor WB**, Heathcote J, Wanless IR. Chaparral-induced hepatic injury. *Am J Gastroenterol* 1995;**90**:831–3.
13. **Savidou S**, Goulis J, Giavazis I, *et al*. Herb-induced hepatitis by *Teucrium polium* L.: report of two cases and review of the literature. *Eur J Gastroenterol Hepatol* 2007;**19**:507–11.
14. **Larrey D**, Vial T, Pauwels A, *et al*. Hepatitis after germander (*Teucrium chamaedrys*) administration: another instance of herbal medicine hepatotoxicity. *Ann Intern Med* 1992;**117**:129–32.
15. **Bakerink JA**, Gospe SM Jr, Dimand RJ, *et al*. Multiple organ failure after ingestion of pennyroyal oil from herbal tea in two infants. *Pediatrics* 1996;**98**:944–7.
16. **Stickel F**, Egerer G, Seitz HK. Hepatotoxicity of botanicals. *Public Health Nutr* 2000;**3**:113–24.

17. **Woolf GM**, Petrovic LM, Rojter SE, *et al*. Acute hepatitis associated with the Chinese herbal product jin bu huan. *Ann Intern Med* 1994;**121**:729–35.
18. **Brown AC**, Onopa J, Holck P, *et al*. Traditional kava beverage consumption and liver function tests in a predominantly Tongan population in Hawaii. *Clin Toxicol (Phila)* 2007;**45**:549–56.
19. **Harvey J**, Colin-Jones DG. Mistletoe hepatitis. *Br Med J (Clin Res Ed)* 1981;**282**:186–7.
20. **Li B**, Wang Z, Fang JJ, *et al*. Evaluation of prognostic markers in severe drug-induced liver disease. *World J Gastroenterol* 2007;**13**:628–32.
21. **Tilburt JC**, Kaptchuk TJ. Herbal medicine research and global health: an ethical analysis. *Bull World Health Organ* 2008;**86**:594–9.
22. **O'Sullivan HM**, Lum K. The poisoning of 'awa: the non-traditional use of an ancient remedy. *Pac Health Dialog* 2004;**11**:211–5.
23. **Ashar BH**, Rice TN, Sisson SD. Medical residents' knowledge of dietary supplements. *South Med J* 2008;**101**:996–1000.
24. **Lukita-Atmadja W**, Ito Y, Baker GL, *et al*. Effect of curcuminoids as anti-inflammatory agents on the hepatic microvascular response to endotoxin. *Shock* 2002;**17**:399–403.
25. **Martins F**, Suzan AJ, Cerutti SM, *et al*. Consumption of mate tea (*Ilex paraguariensis*) decreases the oxidation of unsaturated fatty acids in mouse liver. *Br J Nutr* 2008;**19**:1–6.
26. **Wai CT**, Tan BH, Chan CL, *et al*. Drug-induced liver injury at an Asian center: a prospective study. *Liver Int* 2007;**27**:465–74.
27. **Williams R**. Classification, etiology, and considerations of outcome in acute liver failure. *Semin Liver Dis* 1996;**16**:343–8.
28. **Lee WM**. Acute liver failure. *Clin Perspect Gastroenterol* 2001;**2**:101–10.
29. **Williams R**. Changing clinical patterns in acute liver failure. *J Hepatol* 2003;**39**:660–1.
30. **Hanje AJ**, Chalasani N. How common is chronic liver disease from acute drug-induced liver injury? *Gastroenterology* 2007;**132**:2067–8;discussion 2068–9.
31. **Russo MW**, Galanko JA, Shrestha R, *et al*. Liver transplantation for acute liver failure from drug induced liver injury in the United States. *Liver Transpl* 2004;**10**:1018–23.
32. **Saukkonen JJ**, Cohn DL, Jasmer RM, *et al*. An Official ATS Statement: Hepatotoxicity of Antituberculosis Therapy. *Am J Respir Crit Care Med* 2006;**174**:935–52.
33. **Larson AM**, Polson J, Fontana RJ, *et al*. Acetaminophen-induced acute liver failure: results of a United States multicenter, prospective study. *Hepatology* 2005;**42**:1364–72.
34. **Batts KP**, Ludwig J. Chronic hepatitis. An update on terminology and reporting. *Am J Surg Pathol* 1995;**19**:1409–17.
35. **Bénichou C**. Criteria of drug-induced liver disorders. Report of an international consensus meeting. *J Hepatol* 1990;**11**:272–6.
36. **Andrade RJ**, Lucena MI, Kaplowitz N, *et al*. Outcome of acute idiosyncratic drug-induced liver injury: Long-term follow-up in a hepatotoxicity registry. *Hepatology* 2006;**44**:1581–8.
37. **Roy AK**, Mahoney HC, Levine RA. Phenytoin-induced chronic hepatitis. *Dig Dis Sci* 1993;**38**:740–3.
38. **Picciocto A**, Campo N, Brizzolara R, *et al*. Chronic hepatitis induced by Jin Bu Huan. *J Hepatol* 1998;**28**:165–7.
39. **Saleh F**, Ko HH, Davis JE, *et al*. Fatal hepatitis C associated fibrosing cholestatic hepatitis as a complication of cyclophosphamide and corticosteroid treatment of active glomerulonephritis. *Ann Hepatol* 2007;**6**:186–9.
40. **Goldstein NS**, Bayati N, Silverman AL, *et al*. Minocycline as a cause of drug-induced autoimmune hepatitis. Report of four cases and comparison with autoimmune hepatitis. *Am J Clin Pathol* 2000;**114**:591–8.
41. **Ford TJ**, Dillon JF. Minocycline hepatitis. *Eur J Gastroenterol Hepatol* 2008;**20**:796–9.
42. **Amit G**, Cohen P, Ackerman Z. Nitrofurantoin-induced chronic active hepatitis. *Isr Med Assoc J* 2002;**4**:184–6.
43. **Stricker BH**, Blok AP, Claas FH, *et al*. Hepatic injury associated with the use of nitrofurans: a clinicopathological study of 52 reported cases. *Hepatology* 1988;**8**:599–606.
44. **Arranto AJ**, Sotaniemi EA. Histologic follow-up of α -methyl dopa-induced liver injury. *Scand J Gastroenterol* 1981;**16**:865–72.
45. **Islam S**, Mekhloufi F, Paul JM, *et al*. Characteristics of clometacin-induced hepatitis with special reference to the presence of anti-actin cable antibodies. *Autoimmunity* 1989;**2**:213–21.
46. **Mizutani T**, Shinoda M, Tanaka Y, *et al*. Autoantibodies against CYP2D6 and other drug-metabolizing enzymes in autoimmune hepatitis type 2. *Drug Metab Rev* 2005;**37**:235–52.
47. **Hytioglou P**, Tobias H, Saxena R, *et al*. The canals of hering might represent a target of methotrexate hepatic toxicity. *Am J Clin Pathol* 2004;**121**:324–9.
48. **Whiting-O'Keefe QE**, Fye KH, *et al*. Methotrexate and histologic hepatic abnormalities: a meta-analysis. *Am J Med* 1991;**90**:711–6.
49. **Langman G**, Hall PM, Todd G. Role of non-alcoholic steatohepatitis in methotrexate-induced liver injury. *J Gastroenterol Hepatol* 2001;**16**:1395–401.
50. **Roenigk HH Jr**, Auerbach R, Maibach HI, *et al*. Methotrexate in psoriasis: revised guidelines. *J Am Acad Dermatol* 1988;**19**:145–56.
51. **Roenigk HH Jr**, Auerbach R, Maibach H, *et al*. Methotrexate in psoriasis: consensus conference. *J Am Acad Dermatol* 1998;**38**:478–85.
52. **Berends MA**, van Oijen MG, Snoek J, *et al*. Reliability of the Roenigk classification of liver damage after methotrexate treatment for psoriasis: a clinicopathologic study of 160 liver biopsy specimens. *Arch Dermatol* 2007;**143**:1515–9.
53. **Friis H**, Andreassen PB. Drug-induced hepatic injury: an analysis of 1100 cases reported to the Danish Committee on Adverse Drug Reactions between 1978 and 1987. *J Int Med* 1992;**232**:133–8.
54. **Bion E**, Pariente EA, Maitre F. Severe cholestasis and sicca syndrome after thiabendazole. *J Hepatol* 1995;**23**:762–3.
55. **Ishak KG**, Zimmerman HJ. Drug-induced and toxic granulomatous hepatitis. *Baillieres Clin Gastroenterol* 1988;**2**:463–80.
56. **Karthik SV**, Casson D. Erythromycin-associated cholestatic hepatitis and liver dysfunction in children: the British experience. *J Clin Gastroenterol* 2005;**39**:743–4.
57. **Van Mil SW**, van der Woerd WL, van der Brugge G, *et al*. Benign recurrent intrahepatic cholestasis type 2 is caused by mutations in ABCB11. *Gastroenterology* 2004;**127**:379–84.
58. **Dixon PH**, van Mil S, Chambers J, *et al*. Contribution of variant alleles of ABCB11 to susceptibility to intrahepatic cholestasis of pregnancy. *Gut*. Published Online First: 5 November 2008. doi:10.1136/gut.2008.159541
59. **Degott C**, Feldmann G, Larrey D, *et al*. Drug-induced prolonged cholestasis in adults: a histological semiquantitative study demonstrating progressive ductopenia. *Hepatology* 1992;**15**:244–51.
60. **Pedro-Botet J**, Supervía A, Barranco C, *et al*. Intrahepatic cholestasis without hepatitis induced by amoxicillin/clavulanic acid. *J Clin Gastroenterol* 1996;**23**:137–8.
61. **Larrey D**, Vial T, Micallef A, *et al*. Hepatitis associated with amoxicillin-clavulanic acid combination: report of 15 cases. *Gut* 1992;**33**:368–71.
62. **Olsson R**, Wilholm BE, Sand C, *et al*. Liver damage from flucloxacillin, cloxacillin and dicloxacillin. *J Hepatol* 1992;**15**:154–61.
63. **Fairley CK**, McNeil JJ, Desmond P, *et al*. Risk factors for development of flucloxacillin associated jaundice. *BMJ* 1993;**306**:233–5.
64. **Mallat A**, Zafrani ES, Metreau JM, *et al*. Terbinafine-induced prolonged cholestasis with reduction of interlobular bile ducts. *Dig Dis Sci* 1997;**42**:1486–8.
65. **Wedén M**, Glaumann H, Einarsson K. Protracted cholestasis probably induced by oral contraceptive. *J Intern Med* 1992;**231**:561–5.
66. **Chang CC**, Petrelli M, Tomashefski JF Jr, *et al*. Severe intrahepatic cholestasis caused by amiodarone toxicity after withdrawal of the drug: a case report and review of the literature. *Arch Pathol Lab Med* 1999;**123**:251–6.
67. **Forbes GM**, Jeffrey GP, Shilkin KB, *et al*. Carbamazepine hepatotoxicity: another cause of the vanishing bile duct syndrome. *Gastroenterology* 1992;**102**:1385–8.
68. **Vuppalanchi R**, Chalasani N, Saxena R. Restoration of bile ducts in drug-induced vanishing bile duct syndrome due to zonisamide. *Am J Surg Pathol* 2006;**30**:1619–23.
69. **Moradpour D**, Altorfer J, Flury R, *et al*. Chlorpromazine-induced vanishing bile duct syndrome leading to biliary cirrhosis. *Hepatology* 1994;**20**:1437–41.
70. **Villari D**, Rubino F, Corica F, *et al*. Bile ductopenia following therapy with sulpiride. *Virchows Arch* 1995;**427**:223–6.
71. **Taghian M**, Tran TA, Bresson-Hadni S, *et al*. Acute vanishing bile duct syndrome after ibuprofen therapy in a child. *J Pediatr* 2004;**145**:273–6.
72. **Alam I**, Ferrell LD, Bass NM. Vanishing bile duct syndrome temporally associated with ibuprofen. *Am J Gastroenterol* 1996;**91**:1626–30.
73. **Trak-Smayra V**, Cazals-Hatem D, Asselah T, *et al*. Prolonged cholestasis and ductopenia associated with tenoxicam. *J Hepatol* 2003;**39**:125–8.
74. **Davies MH**, Harrison RF, Elias E, *et al*. Antibiotic-associated acute vanishing bile duct syndrome: a pattern associated with severe, prolonged, intrahepatic cholestasis. *J Hepatol* 1994;**20**:112–6.
75. **Eckstein RP**, Dowsett JF, Lunzer MR. Flucloxacillin induced liver disease: histopathological findings at biopsy and autopsy. *Pathology* 1993;**25**:223–8.
76. **Altraif I**, Lilly L, Wanless IR, *et al*. Cholestatic liver disease with ductopenia (vanishing bile duct syndrome) after administration of clindamycin and trimethoprim-sulfamethoxazole. *Am J Gastroenterol* 1994;**89**:1230–4.
77. **Alazami WM**, McHenry L, Watkins JL, *et al*. Chemotherapy-induced sclerosing cholangitis: long-term response to endoscopic therapy. *J Clin Gastroenterol* 2006;**40**:353–7.
78. **Benjamin SB**, Ishak KB, Zimmerman HJ, *et al*. Phenylbutazone liver injury: a clinical-pathologic survey of 23 cases and review of the literature. *Hepatology* 1981;**1**:255–63.
79. **McCluggage WG**, Sloan JM. Hepatic granulomas in Northern Ireland: a thirteen year review. *Histopathology* 1994;**25**:219–28.
80. **Paquot N**, Delwaide J. Fatty liver in the intensive care unit. *Curr Opin Clin Nutr Metab Care* 2005;**8**:183–7.
81. **Plaia GL**. Chlorinated methanes and liver injury: highlights of the past 50 years. *Annu Rev Pharmacol Toxicol* 2000;**40**:42–65.
82. **Zorzi D**, Laurent A, Pawlik TM, *et al*. Chemotherapy-associated hepatotoxicity and surgery for colorectal liver metastases. *Br J Surg* 2007;**94**:274–86.
83. **Uchida T**, Kao H, Quispe-Sjogren M, *et al*. Alcoholic foamy degeneration – a pattern of acute alcoholic injury of the liver. *Gastroenterology* 1983;**84**:683–92.
84. **Kimura S**, Kobayashi T, Tanaka Y, *et al*. Liver histopathology in clinical Reye syndrome. *Brain Dev* 1991;**13**:95–100.
85. **Vassallo P**, Trohman RG. Prescribing amiodarone: an evidence-based review of clinical indications. *JAMA* 2007;**298**:1312–22.
86. **Lewis JH**, Ranard RC, Caruso A, *et al*. Amiodarone hepatotoxicity: prevalence and clinicopathologic correlations among 104 patients. *Hepatology* 1996;**23**:679–85.
87. **Stravitz RT**, Sanyal AJ. Drug-induced steatohepatitis. *Clin Liver Dis* 2003;**7**:435–51.
88. **Rätz Bravo AE**, Drewe J, Schlienger RG, *et al*. Hepatotoxicity during rapid intravenous loading with amiodarone: Description of three cases and review of the literature. *Crit Care Med* 2005;**33**:128–34;discussion 245–6.
89. **Babany G**, Mallat A, Zafrani ES, *et al*. Chronic liver disease after low daily doses of amiodarone. Report of three cases. *J Hepatol* 1986;**3**:228–32.

Review

90. **Lewis JH**, Mullick F, Ishak KG, *et al*. Histopathologic analysis of suspected amiodarone hepatotoxicity. *Hum Pathol* 1990;**21**:59–67.
91. **Richert M**, Robert S. Fatal hepatotoxicity following oral administration of amiodarone. *Ann Pharmacother* 1995;**29**:582–6.
92. **Rigas B**, Rosenfeld LE, Barwick KW, *et al*. Amiodarone hepatotoxicity. A clinicopathologic study of five patients. *Ann Intern Med* 1986;**104**:348–51.
93. **Guigui B**, Perrot S, Berry JP, *et al*. Amiodarone-induced hepatic phospholipidosis: a morphological alteration independent of pseudoalcoholic liver disease. *Hepatology*;8:1063–8.
94. **Pessayre D**, Bichara M, Degott C, *et al*. Perhexiline maleate-induced cirrhosis. *Gastroenterology* 1979;**76**:170–7.
95. **Le Gall JY**. Perhexiline maleate toxicity on human liver cell lines. *Gut* 1980;**21**:977–84.
96. **Pawlik TM**, Olino K, Gleisner AL, *et al*. Preoperative chemotherapy for colorectal liver metastases: impact on hepatic histology and postoperative outcome. *J Gastrointest Surg* 2007;**11**:860–8.
97. **Kandutsch S**, Klinger M, Hacker S, *et al*. Patterns of hepatotoxicity after chemotherapy for colorectal cancer liver metastases. *Eur J Surg Oncol* 2008;**34**:1231–6.
98. **Bruno S**, Maisonneuve P, Castellana P, *et al*. Incidence and risk factors for non-alcoholic steatohepatitis: prospective study of 5408 women enrolled in Italian tamoxifen chemoprevention trial. *BMJ* 2005;**330**:932.
99. **Karoui M**, Penna C, Amin-Hashem M, *et al*. Influence of preoperative chemotherapy on the risk of major hepatectomy for colorectal liver metastases. *Ann Surg* 2006;**243**:1–7.
100. **Nordlinger B**, Benoist S. Benefits and risks of neoadjuvant therapy for liver metastases. *J Clin Oncol* 2006;**24**:4954–5.
101. **Kumar S**, DeLeve LD, Kamath PS, *et al*. Hepatic veno-occlusive disease (sinusoidal obstruction syndrome) after hematopoietic stem cell transplantation. *Mayo Clin Proc* 2003;**78**:589–98.
102. **Goekkurt E**, Stoehlmacher J, Stueber C, *et al*. Pharmacogenetic analysis of liver toxicity after busulfan/cyclophosphamide-based allogeneic hematopoietic stem cell transplantation. *Anticancer Res* 2007;**27**:4377–80.
103. **Ho VT**, Revta C, Richardson PG. Hepatic veno-occlusive disease after hematopoietic stem cell transplantation: update on defibrotide and other current investigational therapies. *Bone Marrow Transplant* 2008;**41**:229–37.
104. **Membreño FE**, Ortiz J, Foster PF, *et al*. Liver transplantation for sinusoidal obstructive syndrome (veno-occlusive disease): case report with review of the literature and the UNOS database. *Clin Transplant* 2008;**22**:397–404.
105. **Tsirigotis P**, Sella T, Shapira MY, *et al*. Peliosis hepatitis following treatment with androgen-steroids in patients with bone marrow failure syndromes. *Haematologica* 2007;**92**:e106–10.
106. **Perarnau JM**, Bacq Y. Hepatic vascular involvement related to pregnancy, oral contraceptives, and estrogen replacement therapy. *Semin Liver Dis* 2008;**28**:315–27.
107. **Elsing C**, Placke J, Herrman T. Alcohol binge cause peliosis hepatitis during azathioprine therapy in Crohn's disease. *World J Gastroenterol* 2007;**13**:4646–8.
108. **Gisbert JP**, González-Lama Y, Maté J. Thiopurine-induced liver injury in patients with inflammatory bowel disease: a systematic review. *Am J Gastroenterol* 2007;**102**:1518–27.
109. **Okuda K**, Omata M, Itoh Y, *et al*. Peliosis hepatitis as a late and fatal complication of thorotrast liver disease. Report of five cases. *Liver* 1981;**1**:110–22.
110. **Falk H**, Thomas LB, Popper H, *et al*. Hepatic angiosarcoma associated with androgenic-anabolic steroids. *Lancet* 1979;**2**:1120–3.
111. **Oligny LL**, Lough J. Hepatic sinusoidal ectasia. *Hum Pathol* 1992;**23**:953–6.
112. **Akbas T**, Imeryüz N, Bayalan F, *et al*. A case of Budd-Chiari syndrome with Behcet's disease and oral contraceptive usage. *Rheumatol Int* 2007;**28**:83–6.
113. **Srinivasan P**, Rela M, Prachalias A, *et al*. Liver transplantation for Budd-Chiari syndrome. *Transplantation* 2002;**73**:973–7.
114. **Herishanu Y**, Lishner M, Kitay-Cohen Y. The role of glucocorticoids in the treatment of fulminant hepatitis induced by dacarbazine. *Anticancer Drugs* 2002;**13**:177–9.
115. **Friedman SL**. Hepatic stellate cells: protean, multifunctional, and enigmatic cells of the liver. *Physiol Rev* 2008;**88**:125–72.
116. **Levine PH**, Delgado Y, Theise ND, *et al*. Stellate-cell lipidosis in liver biopsy specimens. Recognition and significance. *Am J Clin Pathol* 2003;**119**:254–8.
117. **Cheruvattath R**, Orrego M, Gautam M, *et al*. Vitamin A toxicity: when one a day doesn't keep the doctor away. *Liver Transpl* 2006;**12**:1888–91.
118. **Wisell J**, Boitnott J, Haas M, *et al*. Glycogen pseudoground glass change in hepatocytes. *Am J Surg Pathol* 2006;**30**:1085–90.
119. **Lefkowitz JH**, Lobritto SJ, Brown RS Jr, *et al*. Ground-glass, polyglucosan-like hepatocellular inclusions: A "new" diagnostic entity. *Gastroenterology* 2006;**131**:713–8.
120. **Alonso-Martí C**, Moreno A, Barat A, *et al*. Co-existence of hepatocyte ground-glass inclusions from several causes. *Histopathology* 1990;**16**:304–7.
121. **Gravel DH**, Bégin LR, Brisson ML, *et al*. Metastatic carcinoma resulting in hepar lobatum. *Am J Clin Pathol* 1996;**105**:621–7.
122. **Edmondson HA**, Henderson B, Benton B. Liver cell adenomas associated with use of oral contraceptives. *N Engl J Med* 1976;**294**:470–2.
123. **Tao L**. Oral contraceptive-associated liver cell adenoma and hepatocellular carcinoma: Cytomorphology and mechanism of malignant transformation. *Cancer* 1991;**68**:341–7.
124. **Laurent C**, Trillaud H, Lepreux S, *et al*. Association of adenoma and focal nodular hyperplasia: experience of a single French academic center. *Comp Hepatol* 2003;**2**:6.
125. **Bork K**, Pitton M, Harten P, *et al*. Hepatocellular adenomas in patients taking danazol for hereditary angio-oedema. *Lancet* 1999;**353**:1066–7.
126. **Tazawa K**, Yasuda M, Ohtani Y, *et al*. Multiple hepatocellular adenomas associated with long-term carbamazepine. *Histopathology* 1999;**35**:92–4.
127. **Lipshutz GS**, Brennan TV, Warren RS. Thorotrast-induced liver neoplasia: a collective review. *J Am Coll Surg* 2002;**195**:713–8.
128. **Mori T**, Fukutomi K, Kato Y, *et al*. 1998 results of the first series of follow-up studies on Japanese thorotrast patients and their relationships to an autopsy series. *Radiat Res* 1999;**152**:S72–80.

8. **Andersen RV**, Tybjaerg-Hansen A, Appleyard M, *et al*. Haemochromatosis mutations in the general population; iron overload progression rate. *Blood* 2004;**103**:2914–19.
9. **Olynyk JK**, Hagan SE, Cullen DJ, *et al*. Evolution of untreated hereditary haemochromatosis in the Busseton population; a 17 year study. *Mayo Clin Proc* 2004;**79**:309–13.
10. **Guyander D**, Jacquelinet C, Moirland R, *et al*. Non invasive prediction of fibrosis in C282Y homozygous haemochromatosis. *Gastroenterology* 1998;**115**:929–36.
11. **European Association for the Study of the Liver (EASL)**. EASL clinical practice guidelines for HFE haemochromatosis. *J Hepatol*. Published Online First: 18 April 2010. doi:10.1016/j.jhep.2010.03.001.

Corrections

Ramachandran R, Kakar S. Histological patterns in drug-induced liver disease. *J Clin Pathol* 2009;**62**:481–92. Table 4 in this article should read as below:

Table 4 Roenigk classification system⁵¹

Roenigk grade	Fatty change	Nuclear pleomorphism	Necroinflammatory damage	Fibrosis
I	Mild or none	Mild or none	Mild or none	None
II	Moderate or severe	Moderate or severe	Moderate or severe portal inflammation	Portal tract expansion
IIIa	With or without	With or without	With or without	Mild
IIIb	With or without	With or without	With or without	Moderate or severe
IV	With or without	With or without	With or without	Cirrhosis

J Clin Pathol 2010;**63**:1126. doi:10.1136/jcp.2010.058248corr1

Shih-Sung Chuang, Yung-Liang Liao, Sheng-Tsung Chang, *et al*. Hepatitis C virus infection is significantly associated with malignant lymphoma in Taiwan, particularly with nodal and splenic marginal zone lymphomas. *J Clin Pathol* 2010;**63**:595–8. Table 2 in this article should read as the following:

Table 2 HCV infection status among patients with lymphoma and healthy controls

Variable	Lymphoma cases (n=418)	Healthy controls (n=824)	p Value
Age (years) [†]	57.9±17.6	46.6±11.1	<0.001
Gender, male/female*	265 (63.4)/153 (36.6)	496 (60.2)/328 (39.8)	0.274
Anti-HCV negative*	308 (89.0)	809 (98.2)	<0.001
Anti-HCV positive*	38 (11.0)	15 (1.8)	

*² test.

[†]Student's test.

HCV, hepatitis C virus.

J Clin Pathol 2010;**63**:1126. doi:10.1136/jcp.2010.076810corr1

Craig S, Tait N. Multiple gastric calculi: a rare cause of gastric outlet obstruction. *J Clin Pathol* 2010;**63**:753–4. The author names Craig Steven and Tait Noel are incorrect. They should read as Steven Craig and Noel Tait.

J Clin Pathol 2010;**63**:1126. doi:10.1136/jcp.2010.077487corr1



Histological patterns in drug-induced liver disease

R Ramachandran and S Kakar

J Clin Pathol 2009 62: 481-492

doi: 10.1136/jcp.2008.058248

Updated information and services can be found at:

<http://jcp.bmj.com/content/62/6/481.full.html>

These include:

References

This article cites 123 articles, 12 of which can be accessed free at:

<http://jcp.bmj.com/content/62/6/481.full.html#ref-list-1>

Article cited in:

<http://jcp.bmj.com/content/62/6/481.full.html#related-urls>

Email alerting service

Receive free email alerts when new articles cite this article. Sign up in the box at the top right corner of the online article.

Topic Collections

Articles on similar topics can be found in the following collections

[Editor's choice](#) (91 articles)

Notes

To request permissions go to:

<http://group.bmj.com/group/rights-licensing/permissions>

To order reprints go to:

<http://journals.bmj.com/cgi/reprintform>

To subscribe to BMJ go to:

<http://group.bmj.com/subscribe/>