

New therapeutic advances in the management of progressive thyroid cancer

Jennifer A Woyach¹ and Manisha H Shah^{1,2}

¹Department of Internal Medicine and ²The Ohio State University Comprehensive Cancer Center, The Ohio State University, A438 Starling-Loving Hall, 320 West 10th Avenue, Columbus, Ohio 43210, USA

(Correspondence should be addressed to M H Shah at The Ohio State University Comprehensive Cancer Center, The Ohio State University; Email: manisha.shah@osumc.edu)

Abstract

The spectrum of thyroid cancers ranges from one of the most indolent to one of the most aggressive solid tumors identified. Conventional therapies for thyroid cancers are based on the histologic type of thyroid cancers such as papillary or follicular thyroid cancer (differentiated thyroid cancer (DTC)), medullary thyroid cancer (MTC), or anaplastic thyroid cancer (ATC). While surgery is one of the key treatments for all such types of thyroid cancers, additional therapies vary. Effective targeted therapy for DTC is a decades-old practice with systemic therapies of thyroid stimulating hormone suppression and radioactive iodine therapy. However, for the iodine-refractory DTC, MTC, and ATC there is no effective systemic standard of care treatment. Recent advances in understanding pathogenesis of DTC and development of molecular targeted therapy have dramatically transformed the field of clinical research in thyroid cancer. Over the last five years, incredible progress has been made and phases I–III clinical trials have been conducted in various types of thyroid cancers with some remarkable results that has made an impact on lives of patients with thyroid cancer. Such history-making events have boosted enthusiasm and interest among researchers, clinicians, patients, and sponsors and we anticipate ongoing efforts to develop more effective and safe therapies for thyroid cancer.

Endocrine-Related Cancer (2009) 16 715–731

Background

Thyroid cancer is the most common malignancy of the endocrine system, and a disease whose incidence has been increasing over the past 20 years (Davies & Welch 2006). This heterogeneous disease is classified into differentiated thyroid carcinoma (DTC), undifferentiated (anaplastic) thyroid carcinoma (ATC), poorly DTC, and medullary thyroid carcinoma (MTC). DTCs are by far the most common, and include the major subtypes of papillary and follicular as well as rare tumors derived from these subtypes. Most DTCs are indolent tumors, and, when identified at an early stage, are almost always cured through surgery and/or radioactive iodine therapy (¹³¹I). However, 5-year disease-specific survival of patients with DTC with distant metastases is <50% (Shaha *et al.* 1997, Hundahl *et al.* 1998). Current guidelines for treatment of progressive DTC include optimization of thyroid stimulating hormone (TSH) suppression, ¹³¹I, resection

of selected metastases, and bisphosphonates for bony metastases. While doxorubicin is the only cytotoxic chemotherapy currently approved through the Food and Drug Administration (FDA) of the USA, due to low short-lasting response rates and high toxicity profile, it is not routinely used in the management of thyroid cancers (Gottlieb & Hill 1974, Shimaoka *et al.* 1985, Williams *et al.* 1986, De Besi *et al.* 1991, Argiris *et al.* 2008).

Unlike DTC, MTC is derived from parafollicular C cells of the thyroid and can occur as part of the inherited syndromes such as multiple endocrine neoplasia (MEN)-2. Surgery is the only effective therapy, however, at the time of diagnosis 50–80% of patients have metastatic disease. Like DTC, patients with metastatic disease do poorly, with a 5 year survival of <50% (Hundahl *et al.* 1998). ATC are almost always aggressive and often not diagnosed until advanced stages (Kebebew *et al.* 2005). For ATC,

multimodality treatment including surgery, radiation, and chemotherapy is the standard of care. However, median survival of this group of patients is <1 year.

Novel insights in the pathogenesis of thyroid cancer

Cancer therapy has been revolutionized by the advent of therapies that selectively target cancer cells while sparing normal cells. Initial interest in this field grew with the successful development of the tyrosine kinase inhibitor imatinib for chronic myelogenous leukemia (Druker *et al.* 2001). Since this time, numerous small molecule tyrosine kinase inhibitors have been developed and tested in a variety of tumor types. The success of these inhibitors hinges on the discovery of appropriate targets so integral in tumorigenesis that their disruption is catastrophic for the tumor. The phenomenon called ‘oncogene addiction’, where the growth and survival of tumor can often be impaired by the inactivation of a single oncogene, has been described in a variety of tumors (Weinstein 2002, Weinstein & Joe 2008). In thyroid cancer, the targets that have been best described include the RET/papillary thyroid carcinoma (PTC), RAS, and BRAF. Non-overlapping rearrangement of RET/PTC, and mutations of RAS, BRAF, and neurotrophic tyrosine kinase receptor 1 (NTRK1) have been found in ~70% of PTC (Xing 2005).

With the juxtaposition of various genes to the RET gene, a chimeric protein, RET/PTC, is produced, whose constitutive expression has been implicated in the development of PTC (Viglietto *et al.* 1995, Jhiang *et al.* 1996). Similarly, germline mutations of RET are hallmark of the MEN-2 (Santoro *et al.* 1990), and these

mutations are seen in 26–48% of sporadic MTC (Shan *et al.* 1998, Uchino *et al.* 1999, Dvorakova *et al.* 2008, Elisei *et al.* 2008). Activating mutations of RAS occur in ~30% of follicular thyroid carcinoma (FTC). In 2002, Davies *et al.* (2002) reported a breakthrough discovery of activating mutations in BRAF gene in human cancer. Soon after discovery of BRAF as an oncogene for variety of human cancers, BRAF was found to be mutated (BRAF^{V600E}) in 28–69% of PTC (Cohen *et al.* 2003, Fukushima *et al.* 2003, Kimura *et al.* 2003, Namba *et al.* 2003, Nikiforova *et al.* 2003, Soares *et al.* 2003, Xu *et al.* 2003, Trovisco *et al.* 2004, Xing *et al.* 2004). BRAF is a non-receptor serine threonine kinase involved in the RAS/RAF/MAPK/ERK signaling cascade (Fig. 1). Targeted expression of BRAF^{V600E} in thyroid cells of transgenic mice induces goiter and invasive PTC, which transforms into poorly differentiated carcinomas (Knauf *et al.* 2005). Furthermore, a small inhibitory RNA construct targeting the expression of both wild-type BRAF and BRAF^{V600E} induced a comparable reduction of cancer cell viability. In addition to PTC, BRAF mutations also have been observed in 10–25% of ATC (Nikiforova *et al.* 2003, Santarpia *et al.* 2008). Like the RET/PTC, mutations in BRAF are thought to occur early in tumorigenesis (Nikiforova *et al.* 2003) and have been seen in aggressive thyroid cancers making this an attractive target for molecular therapies as well. Metalloproteinases (MMP) were shown to be induced by BRAF, particularly MMP3, MMP9, and MMP13 in an experimental model using rat thyroid PCCL3 cells (Mesa *et al.* 2006).

The phosphatidylinositol 3-kinase (PI3K)/Akt signaling pathway is an important regulator of many cellular events, including apoptosis, proliferation, and

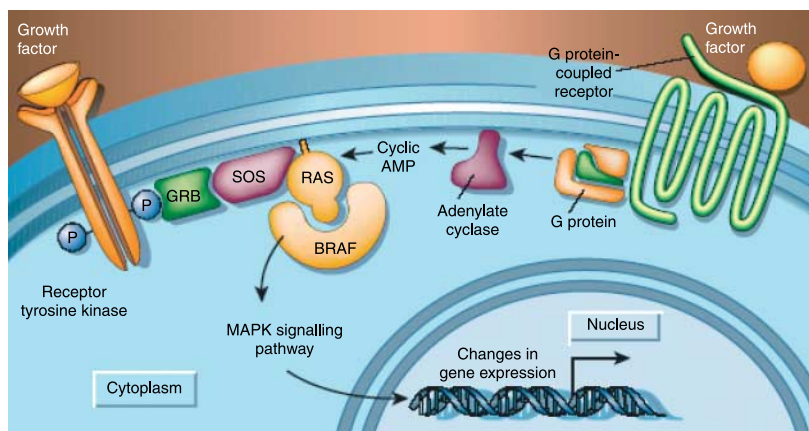


Figure 1 The RAS–RAF–MAP kinase signaling pathway. Reprinted by permission from Macmillan Publishers Ltd: Pollock PM & Meltzer PS 2002 *Nature* 417(6892) 906–907, copyright (2002).

motility. Aberrant activation of this pathway can occur through several mechanisms, such as inactivation of its negative regulator, phosphatase and tensin homolog deleted on chromosome 10, and activating mutations and gene amplification of the gene encoding the catalytic subunit of PI3K. These genetic abnormalities have been particularly associated with follicular adenoma, FTC, and ATC (Hou *et al.* 2007, Liu *et al.* 2008, Paes & Ringel 2008).

Another receptor tyrosine kinase that has gained interest in thyroid cancer in addition to other malignancies is c-Met, a proto-oncogene that is the high-affinity receptor for hepatocyte growth factor and is important for regulation of cell migration, proliferation, differentiation, and angiogenesis (Jiang *et al.* 1999). In PTC, overexpression of c-Met has been found in 70% of patients (Di Renzo *et al.* 1992), and ATC is associated with constitutively active c-Met as well (Bergstrom *et al.* 1999). In PTC, high levels of c-Met expression correlate inversely with the presence of distant metastasis (Belfiore *et al.* 1997). It has also been shown that the epidermal growth factor receptor (EGFR) is important in the regulation of c-Met (Bergstrom *et al.* 2000), and that RAS and RET upregulate c-Met (Ivan *et al.* 1997), identifying all as potential therapeutic targets.

The EGF and its receptor are attractive molecular targets for cancer therapy. EGF has shown to stimulate thyroid follicular cell proliferation (van der Laan *et al.* 1995) and increase the proliferation and invasion of DTC cells in culture and in nude mice (Hoelting *et al.* 1994).

Although it has been known for decades that angiogenesis is central to tumor development, we consider it relevant to mention its role in thyroid cancer pathogenesis (Lennard *et al.* 2001, Lewy-Trenda & Wierchniewska-Lawska 2002, Tanaka *et al.* 2002, Bauer *et al.* 2003, Lin *et al.* 2003) due to recent availability of potent and specific inhibitors of angiogenesis in the clinic. In order for tumors to grow and metastasize, they must acquire angiogenic capability (Gullino 1978) to provide their own blood supply. Vascular endothelial growth factor (VEGF) and platelet-derived growth factor (PDGF) are among the potent angiogenic factors that are implicated in pathogenesis of a variety of cancers including thyroid cancers (Fig. 2). VEGF binds to a family of membrane-bound receptor tyrosine kinases, VEGF receptors (VEGFRs) 1–4, resulting in subsequent down-stream signaling and release of angiogenic factors with subsequent new blood vessel formation.

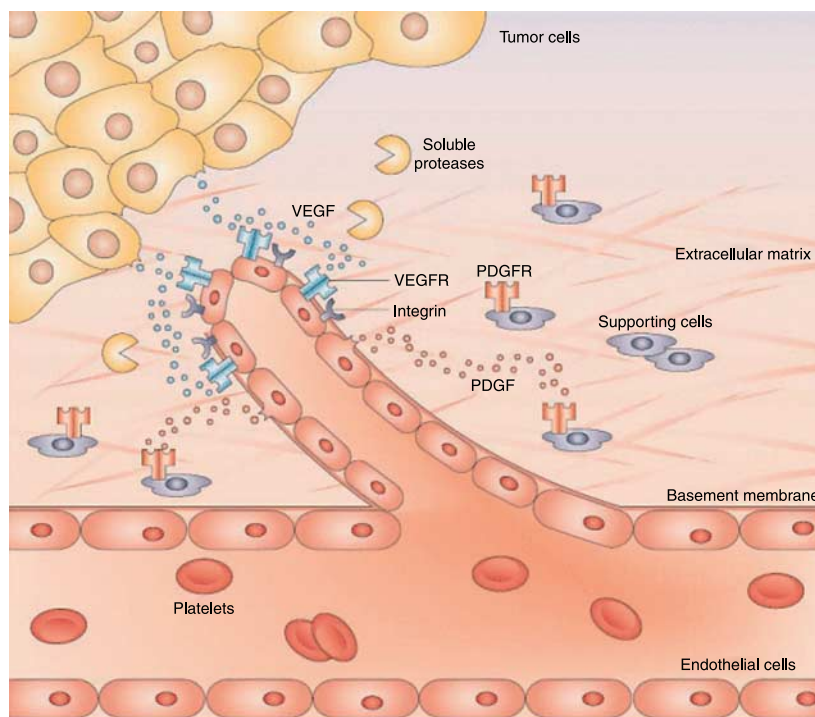


Figure 2 Tumor angiogenesis. Reprinted by permission from Macmillan Publishers Ltd: Cristofanilli M, Charnsangavej C & Hortobagyi GN 2002 *Nature Reviews. Drug Discovery* 1 415–426, copyright (2002).

Preclinical studies

Sorafenib (BAY 43-9006)

Sorafenib, a multi-kinase inhibitor targeting BRAF, VEGFR, PDGFR, and RET, was shown to suppress BRAF signaling and cell/tumor growth when tested *in vitro* and in xenograft models (Salvatore *et al.* 2006). Knockdown of BRAF by small inhibitory duplex RNA inhibited the MAP kinase signaling and the growth of ATC cells. Similar inhibition was achieved with sorafenib at half-maximal inhibitory concentrations (IC₅₀) of 0.5–1 mmol/l in thyroid carcinoma cells but not in normal thyrocytes. ATC xenografts were significantly smaller in nude mice treated with sorafenib than in control mice. This inhibition was associated with suppression of phospho-MAP kinase levels. Subsequently, RET kinase was reported to be a target in multi-kinase inhibitor spectrum of sorafenib based on its testing in pre-clinical models of RET mutated PTC and MTC (Carlomagno *et al.* 2006). Sorafenib inhibited oncogenic RET kinase activity at IC₅₀ of <50 nM in oncogenic RET-transfected NIH3T3 cells. It also arrested the growth of NIH3T3 and RAT1 fibroblasts transformed by oncogenic RET and of thyroid carcinoma cells, human TPC1 (PTC cell line), and TT (MTC cell line), that harbor spontaneous oncogenic RET alleles. After 3 weeks of treatment with oral sorafenib, the volume of TT cell xenografts was reduced from 72 to 44 mm³, whereas in vehicle-treated mice, mean tumor volume increased to 408 mm³ (*P*=0.02). This inhibition paralleled a decrease in RET phosphorylation. Another study targeting the BRAF expression using a small inhibitory RNA construct in thyroid cancer cell lines induced a comparable reduction of viability in both wild-type BRAF and BRAF^{V600E} mutant cancer cells (Mitsiades *et al.* 2007). Furthermore, AAL881, BRAF kinase inhibitors, inhibited MEK and ERK phosphorylation, and induced apoptosis preferentially in BRAF^{V600E}-harboring cells over wild-type cells.

Vandetanib (ZD 6474)

Vandetanib is an anilinoquinazoline multi-tyrosine kinase inhibitor targeting VEGFR and EGFR signaling. Like sorafenib, this drug also inhibits the RET oncoprotein making it an interesting targeted therapy for both PTC and MTC. It has been shown that vandetanib blocks the enzymatic activity of RET-derived oncoproteins at IC₅₀ of 100 nM (Carlomagno *et al.* 2002). Vandetanib also blocked *in vivo* phosphorylation and signaling of the RET/PTC3 and RET/MEN2B oncoproteins and of an EGF-activated

EGFR/RET chimeric receptor. Furthermore, vandetanib prevented the growth of two human PTC cell lines that carry spontaneous RET/PTC1 rearrangements and blocked the formation of tumors after injection of NIH-RET/PTC3 cells into nude mice.

Sunitinib

Sunitinib is another multi-tyrosine kinase inhibitor that targets VEGFR, PDGFR, and c-kit. It has also been shown to target RET/PTC, both blocking proliferation of TPC-1 cells that harbor RET/PTC1 rearrangement and causing morphologic reversal of transformed NIH-RET/PTC3 cells (Kim *et al.* 2006).

Gefitinib

Gefitinib is a tyrosine kinase inhibitor targeting an EGFR, which blocks its auto-phosphorylation and signal transduction. EGFR is overexpressed in ATC cell lines *in vitro* and *in vivo* as well as human ATC specimens (Schiff *et al.* 2004). Gefitinib inhibited cellular proliferation and induced apoptosis in ATC cell lines and slowed tumor growth in a nude mouse model of subcutaneous implant of ATC. This has been confirmed in another preclinical study, where gefitinib was combined with imatinib, a tyrosine kinase inhibitor targeting c-abl/PDGF-R (Kurebayashi *et al.* 2006). In this study, the combination therapy demonstrated enhanced apoptosis associated with the down-regulation of antiapoptotic proteins, Bcl-2 and Bcl-xL, and inhibited the growth of KTC-3 xenografts.

Combretastatin

Combretastatin is a microtubule inhibitor, which has been shown to destabilize vasculature, making it an attractive anti-tumor agent. Combretastatin displayed significant cytotoxicity in eight human ATC cell lines and in xenograft tumors from four ATC cell lines when injected in athymic nude mice (Dziba *et al.* 2002). Furthermore, it can also significantly enhance tumor response to both cisplatin and radiation (Chaplin *et al.* 1999). In a nude mouse xenograft model with ARO and KAT-4 cells, combretastatin and paclitaxel in combination with manumycin or carboplatin demonstrated significant antitumor activity (Yeung *et al.* 2007). Blebbing/budding of endothelial cells into capillary lumens and autophagy of tumor cells in combretastatin-treated xenografts confirms its vascular disrupting activity. Nelkin & Ball (2001) showed improvement in doubling time of MTC tumors in nude mice model from 12 to 29 days when treated with combretastatin and doxorubicin.

Bortezomib

In vitro, a proteasome inhibitor bortezomib alone or in combination with chemotherapy has been shown to induce apoptosis in MTC and ATC cells by inhibiting NF- κ B, increasing p53, p21, and jun expression, and inducing caspase-dependent apoptosis (Mitsiades *et al.* 2006).

17-AAG

17-AAG is a heat shock protein (Hsp) 90 inhibitor that has been identified as a potential therapeutic agent in thyroid cancer. Hsp 90 specifically has been found to be important to the signaling kinases Akt and RAF as well as formation of the PTC1 protein, which is the most common RET/PTC chimeric oncoprotein seen in PTC (Smida *et al.* 1999). In preclinical studies, 17-AAG was found to reduce RET/PTC1 protein levels, induce cell death and increase the uptake of radioactive iodine into thyroid cancer cells (Marsee *et al.* 2004). It has also been shown that levels of Hsp 90, rather than histologic subtype, determine the cytotoxic response to the agent in thyroid cancer cell lines (Braga-Basaria *et al.* 2004).

Histone deacetylase inhibitors

Depsipeptide (romidepsin, FK228) has been shown to increase sodium–iodine symporter expression and uptake of I¹²⁵ (Kitazono *et al.* 2001, Furuya *et al.* 2004). In the FTC and ATC cell lines, a very low concentration of depsipeptide increased histone acetylation and expression of both thyroglobulin (Tg) and the Na(+)/I(–) symporter (NIS) mRNAs (Kitazono *et al.* 2001).

In preclinical studies using thyroid cancer cell lines, suberoylanilide hydroxamic acid (SAHA) was found to induce growth arrest in ATC and MTC cell lines through p21-mediated inhibition of Rb phosphorylation (Mitsiades *et al.* 2005). In these studies, SAHA was also found to sensitize thyroid cancer cells to caspase-mediated death-receptor mediated cell death as well as to augment anti-tumor activity of doxorubicin.

DNA methylation inhibitors

Decitabine appears to work through inhibition of DNA methyltransferases, and causes reversible DNA damage to malignant cells (Palii *et al.* 2008). In preclinical studies, decitabine also has been shown to increase iodine uptake in ATC and poorly DTC cell lines (Provenzano *et al.* 2007). Thyroid carcinoma cell lines DRO and 2–7 had high levels

of DNA methylation (74 and 80%) compared with normal thyroid tissue (6%; $P < 0.05$). This finding correlated with low levels of NIS expression in the untreated thyroid carcinoma cell lines. Combination treatment with the epigenetic-modifying agents 5-aza-2'-deoxycytidine and sodium butyrate resulted in increases in NIS mRNA levels, global histone acetylation, and 8- to 9-fold increases in I¹²⁵ uptake for the DRO and 2–7 cells.

3-Phosphoinositide-dependent kinase-1 inhibitors

OSU-03012 (2-amino-*N*-{4-[5-(2-phenanthrenyl)-3-(trifluoromethyl)-1*H*-pyrazol-1-yl]-phenyl} acetamide) is a derivative of celecoxib, which was formulated to be a more potent inhibitor of 3-phosphoinositide-dependent kinase (PKD)-1. When exposed to OSU-03012, prostate cancer cells were shown to have dephosphorylation of Akt and subsequent apoptosis (Zhu *et al.* 2004). OSU-03012 was also found in thyroid cancer cells to directly inhibit p-21 activated kinases, downstream effectors of PKD-1, which are important in cell motility and proliferation (Porchia *et al.* 2007).

Peroxisome proliferator-activated receptor-gamma agonist

CS-7017, a thiazolidinedione class peroxisome proliferator-activated receptor (PPAR) gamma agonist, alone or in combination with paclitaxel inhibited the proliferation of the human ATC cell line DRO and inhibited the growth of the DRO in nude rats in a dose-dependent manner (Copland *et al.* 2006, Shimazaki *et al.* 2008).

Chemotherapeutic agents

Capecitabine is a tumor-activated fluoropyrimidine carbamate which is converted to 5-FU in target tissues by thymidine phosphorylase, causing high drug levels inside tumors while sparing normal tissues. 5-FU interferes with DNA synthesis by blocking thymidylate synthetase, and is inactivated by dihydropyrimidine dehydrogenase. Because of its mechanism of action, it is suspected that high levels of thymidine phosphorylase and low thymidylate synthetase and dihydropyrimidine dehydrogenase would predict response to capecitabine. In one study looking at immunohistochemistry of thyroid tumors, 43% of PTC and 25% of FTC had favorable characteristics (Patel *et al.* 2004).

Irinotecan, a topoisomerase I inhibitor, prevents the relaxation of DNA supercoiling during DNA replication

Table 1 Phases of clinical trials^a

Phase of clinical trial	Definition and goals of clinical trial
Phase I	The first of four phases of clinical trials, phase I studies are designed to establish the effects of a new drug in humans. These studies are usually conducted on small populations of healthy humans to specifically determine a drug's toxicity, absorption, distribution, metabolism, and maximum tolerated dose of the new drug
Phase II	After the successful completion of phase I trials, a drug is then tested for safety and efficacy in a slightly larger population of individuals who are afflicted with the disease or condition for which the drug was developed
Phase III	The third and last pre-approval round of testing of a drug is conducted on large populations of afflicted patients. Phase III studies usually test the new drug in comparison with the standard therapy currently being used for the disease in question. The results of these trials usually provide the information that is included in the package insert and labeling
Phase IV	After a drug has been approved by the FDA, phase IV studies are conducted to compare the drug to a competitor, explore additional patient populations, or to further study any adverse events

^aModified from the table in the website: <http://www.centerwatch.com/>

(Garcia-Carbonero & Supko 2002). A preclinical study in a mouse model of ATC showed that the combination of irinotecan and cetuximab, a chimeric monoclonal antibody to EGFR, inhibited tumor growth, invasion, and angiogenesis (Kim *et al.* 2006). In the same study, at the end of a 3 week treatment period, this combination decreased mean tumor volume by 97%, while doxorubicin decreased tumor volume by 7% (Kim *et al.* 2006). In a study using a mouse model of MTC, irinotecan was found to be highly effective (Strock *et al.* 2006).

Clinical trials in DTC

Clinical trials are studies designed to find new and better ways to treat patients with cancer. Through clinical trials, scientists and clinicians break new ground in the development of anti-cancer treatment. The definitions of phases of clinical trials and key

points in response criteria in solid tumors (RECIST) are described in Tables 1 and 2. In the last 5 years, dramatic advances have occurred in development of clinical trials for thyroid cancer (Table 3). Table 4 outlines summary of results of published phase II trials of kinase inhibitors, however, caution must be taken in comparing these results, as patient population tested was variable among these trials.

Sorafenib

Sorafenib has been approved through the FDA for patients with metastatic renal cell carcinoma and hepatocellular carcinoma, and is the first compound of its class to show promising anti-tumor activity in patients with advanced DTC (Kloos *et al.* 2005, 2008). Our group conducted a National Cancer Institute (NCI)-sponsored phase II trial of sorafenib that enrolled 58 patients with advanced non-MTCs (Kloos *et al.* 2005, 2008, Gupta-Abramson *et al.* 2008).

Table 2 Response evaluation criteria in solid tumors

Category	Definition per RECIST
Measurable lesions	Measurable lesions are defined as those that can be accurately measured in at least one dimension (longest diameter to be recorded) as >20 mm with conventional techniques (CT, MRI, X-ray) or as > 10 mm with spiral CT scan
Target lesions	All measurable lesions up to a maximum of five lesions per organ and ten lesions in total, representative of all involved organs, are identified as target lesions and recorded and measured at baseline
Measurement of the target lesions	A sum of the longest diameter (LD) for all target lesions is calculated and reported as the baseline sum LD. The baseline sum LD is used as the reference to characterize the objective tumor response
Response categories	Complete response (CR): disappearance of all target lesions Partial response (PR): at least a 30% decrease in the sum of the longest diameter (LD) of target lesions, taking as reference the baseline sum LD Progressive disease (PD): at least a 20% increase in the sum of the LD of target lesions, taking as reference the smallest sum LD recorded since the treatment started or the appearance of one or more new lesions Stable disease (SD): neither sufficient shrinkage to qualify for PR nor sufficient increase to qualify for PD, taking as reference the smallest sum LD since the treatment started

Table 3 Clinical trials for advanced differentiated thyroid cancer^a

Class of therapy	Putative targets of the therapy	Name of drugs	Status of phase II clinical trials
Anti-angiogenic drugs (oral kinase inhibitors)	VEGF-receptors, PDGF-receptors	Sorafenib (BAY 43-9006)	Completed, results published
		Axitinib (AG-013736)	Completed, results published
		Motesanib (AMG-706)	Completed, results published
		Pazopanib (GW786034)	Accrual ongoing, results pending
		Sunitinib (SU011248)	Accrual ongoing, results pending
		Vandetanib (ZD6474)	Accrual ongoing, results pending
Signaling pathway inhibitors	RAS–RAF–MEK signaling pathway	Sorafenib (BAY 43-9006)	Completed, results published
		AZD 6244	Accrual ongoing
Signaling pathway inhibitors	EGFR signaling pathway	Gefitinib	Completed, results published
Histone deacetylase inhibitors	Histone deacetylation	Vorinostat (SAHA)	Completed, results published
		Romidepsin (Depsipeptide)	Accrual completed, results pending
Demethylating agents	Methylation	Decitabine	Accrual ongoing
Cyclo-oxygenase (COX) inhibitor	COX-2	Celecoxib	Completed, results published
Immunomodulation	Inflammation, angiogenesis	Thalidomide	Completed, results published
		Lenalidomide	Accrual completed, results pending
Ansamycin antibiotic	Heat shock protein 90	17-AAG	Accrual ongoing
Proteasome inhibitor	Proteasome	Bortezomib (PS-341)	Accrual ongoing
Cytotoxic chemotherapy	DNA alkylating or antimetabolite	Irofulven and capecitabine	Completed, results presented in abstract

^aOngoing trials in MTC include single agent sorafenib, sunitinib, pazopanib, and 17-AAG. Ongoing trials in ATC include sorafenib, combretastatin and CS-7017. Please see www.clinicaltrials.gov for status update.

Sorafenib was administered at an initial dose of 400 mg orally twice each day, and was dose-reduced in 52% of patients. Of 33 cytotoxic chemo-naïve PTC patients, 5 patients had partial responses (PRs; 15%; 95% confidence interval (CI) 5–32) and 19 patients had stable disease (SD) lasting >6 months (57%). The Kaplan–Meier estimate of median progression free survival (PFS) was 16 months (95% CI, 8–27.5). Objective response was seen even in the eight patients who had previously received cytotoxic chemotherapy, with 13% PR and 50% SD >6 months duration. While no PRs were noted, SD >6 months was noted in 54 and 25% of patients in FTC/hurthle ($n=11$) or ATC ($n=4$) respectively. We noted dramatic sustained decreases in serum Tg levels in some patients with PRs and SDs, however, neither baseline Tg nor Tg response consistently correlated with degree or duration of objective response. Common (>10%) grade 3 adverse event (AEs) included hand–foot skin reaction, musculoskeletal pain, and fatigue. Rare events of keratoacanthoma, bowel perforation, and bleeding (hemoptysis in patients with central chest tumor lesions) were also observed. BRAF mutation (BRAF^{V600E} or BRAF^{K601E}) was detected in 17 of 22 (77%) patients with PTC. Four of

ten paired tumor biopsies from PTC patients performed pre-treatment and at 8 weeks on treatment showed a reduction in levels of pVEGFR, pERK and increase VEGF expression in response to sorafenib. Tumor perfusion was decreased with sorafenib as evaluated by dynamic contrast enhanced magnetic resonance imaging in 10 of 14 evaluable PTC patients. While decreases in SUV_{max} and metabolic volume had been observed in index lesions with sorafenib, no clear correlation was noted between fluorodeoxyglucose positron emission tomography (PET) response and objective response.

In a single center phase II study of sorafenib in 30 patients with advanced thyroid cancer, Gupta-Abramson *et al.* (2008) reported 7 (23%) PRs and 16 (53%) SDs and a median PFS of 19.7 months. A majority of these patients were PET scan positive (93%) and had either PTC ($n=18$) or FTC/Hurthle cell variant ($n=9$). Only 5 of 30 patients (17%) had received prior chemo- or investigational-therapy. While sorafenib was delivered at 400 mg orally twice daily in this study as well, dose reduction was required in 47% of the patients. Common treatment-related AEs included palmar-plantar erythema, rash,

Table 4 Results of phase II trials of kinase inhibitors in advanced thyroid cancer

Name of agent	Sorafenib	Sorafenib	Motesanib	Axitinib
Reference	Kloos <i>et al.</i> (2008)	Gupta-Abramson <i>et al.</i> (2008)	Sherman <i>et al.</i> (2008)	Cohen <i>et al.</i> (2008b)
Sites of phase II trial	Ohio State University	University of Pennsylvania	Multicenter, International	Multicenter, USA
Number of patients	56	30	93	60
Age (years)	61 (median)	63 (mean)	62 (median)	59 (median)
Histology (%)				
Papillary	70	60	61	50
Follicular/Hurthle cell	24	30	34	25
Medullary	0	3	0	18
Anaplastic	6	7	0	3
Other	0	0	4	3
Extent of disease (%)				
Locally advanced/recurrent	0	NR	1	50
Metastatic	100	NR	99	50
Performance status (%)				
ECOG 0–1	100	100	90	100
ECOG 2	0	0	10	0
Prior treatment (%)				
Surgery	100	100	100	87
Radioactive iodine	92	93	97	72
External beam radiation	46	37	57	82
Chemotherapy	19	10	17	15
Other	29	7	NR	25
Objective response (%)				
Intent to treat analysis	Yes	Yes	Yes	Yes
Assessable pts (%)	85	83	88	75
Complete response	0	0	0	0
Partial response	11	23	14	30
Stable disease	62	53	67	38
Stable disease > 6 months	53	NR	35	NR
Median duration of partial response (months)	9	4.5–21 (range)	8	Not yet reached
Median progression-free survival (months)	15 (PTC pts); 4.5 (non-PTC pts)	21 (DTC pts); 19.7 (all pts)	10	18.1
Serum thyroglobulin response compared with baseline	49% (11/23) PTC pts with >50% decrease	70% median decrease in 17 of 19 pts	45% (34/75) pts with >50% decrease	NR
Discontinuation due to adverse events (%)	25	20	13	13

NR, not reported.

musculoskeletal pain, pruritus, hypertension, diarrhea, fatigue, weight loss, stomatitis/mucositis, alopecia, abdominal bloating, and mood changes.

Objective response rates and median PFS in the above studies of sorafenib vary despite similar dosing schedule. While there is no clear explanation for such differences, it may be due to differences in patient characteristics such as prior therapy, overall tumor burden, and rate of progressive disease at the study entry, as well as tumor characteristics including BRAF mutation and tumor vascularity. Based on the promising data noted in these phase II studies, the authors recommend the use of sorafenib 400 mg orally twice daily under proper supervision in high-risk

patients with metastatic PTC who have progressed despite standard surgery and ¹³¹I and do not have the option to participate in clinical trials. In 2008, The National Comprehensive Cancer Network (NCCN; http://www.nccn.org/professionals/physician_gls/PDF/thyroid.pdf) also endorsed the use of sorafenib in the management of clinically progressive or symptomatic iodine-refractory PTC.

Axitinib (AG-013736)

Like sorafenib, axitinib is an oral multi-targeted tyrosine kinase inhibitor, but with a selectivity and potency against VEGFRs. Clinical responses have been

observed in renal cell carcinoma (Rixe *et al.* 2007). In a multicenter phase II study of 60 patients with advanced thyroid cancer using 5 mg daily dosing of axitinib, 18 (30%) PRs and 23 (38%) SD of >4 months duration were observed (Cohen *et al.* 2008b). Median PFS was 18 months (95% CI, 12.1 to not estimable). Among 30 PTC patients on this study, 8 (27%) achieved PRs and 12 (40%) experienced SD. While no definitive conclusions were made in serum Tg response in this study, significant decreases in mean serum VEGFR-2 and -3 concentrations were noted compared with baseline. The most common treatment-related AEs occurring in >20% of patients included fatigue, diarrhea, nausea, anorexia, hypertension, stomatitis, weight loss, and headache.

Motesanib (AMG-706)

Motesanib is a multi-targeted tyrosine kinase inhibitor that targets the VEGFRs, PDGFR, and c-kit (Polverino *et al.* 2006). In an open-label multicenter international phase II trial of motesanib in 93 patients with radioiodine-resistant, progressive DTC, motesanib was administered orally at a dose of 125 mg orally daily (Sherman *et al.* 2008). Objective response included 14% PRs, 67% SD and a 35% SD >6 months duration. The Kaplan–Meier estimate of the median duration of the response was 8 months (95% CI, 6–not estimable) and median PFS was 10 months (95% CI, 8–12.5). Among 75 patients in whom Tg analysis was performed, 81% had decreased serum Tg concentrations during treatment as compared with baseline, and significant correlation was noted between serum Tg response and RECIST response. The most common (>40%) treatment-related AEs were diarrhea, hypertension, fatigue, and weight loss. Grade 3 AEs occurred in 55% of patients that included diarrhea, hypertension, abdominal pain, anorexia, fatigue and rare gall bladder toxicity, hemorrhage, and thromboembolic events. Of note, hypothyroidism was noted in 12% of the patients. Of 25 patients with PTC, 10 had the mutant BRAF^{V600E} genotype, and 4 had mutations in RAS genes.

Sunitinib (SU 011248)

Sunitinib is approved through the FDA for patients with metastatic renal cell carcinoma or imatinib-refractory gastrointestinal stromal tumors. In an NCI-sponsored phase II study of sunitinib in 37 patients with iodine-refractory progressive DTC (Cohen *et al.* 2008a), treatment consisted of 6 week cycles of sunitinib malate 50 mg orally each day on a 4-week-on/2-week off schedule. Of 31

evaluable DTC patients who completed 12 weeks of treatment, the best response was PR in 13%, SD in 68%, and progressive disease in 10%, with 13% of patients not evaluable. The most common (>40%) drug related AEs included fatigue, diarrhea, palmar-plantar erythrodysesthesia, neutropenia, and hypertension. Results are awaited for other ongoing phase II trials of sunitinib in patients with iodine-refractory DTC and metastatic MTC (Goulart *et al.* 2008, Ravaud *et al.* 2008).

Gefitinib

Gefitinib is extensively studied in patients with non-small cell lung cancer. In a single institution phase II study in patients with advanced thyroid cancer, gefitinib was administered orally at dose of 250 mg daily in a total of 27 patients, 67% of whom had DTC (Pennell *et al.* 2008). No objective responses were observed, and five (18%) patients (2 PTC, 3 FTC) had SDs associated with minor (>10%) decrease in serum Tg compared with the baseline that was maintained for at least 3 months. Two of these patients had a >50% decline in the Tg levels. However, median PFS on the study was 4 months suggesting only limited potential benefit from the drug.

Vorinostat

Our group conducted NCI-sponsored phase II study to assess objective response to vorinostat (SAHA) in patients with advanced thyroid cancer (Woyach *et al.* 2008). Of the total of 19 patients, 16 had DTC that had progressed after standard therapy. Patients received oral vorinostat at a starting dose of 200 mg twice daily with dose adjustments allowed as necessary for toxicity. Patients were treated for 2 weeks followed by 1 week off therapy (3-week cycle) until disease progression or study withdrawal. No patient achieved a PR or CR. Grade 3 AEs consisted of fatigue, dehydration, ataxia, pneumonia, bruises, and deep vein thrombosis. Grade 3–4 thrombocytopenia was seen in seven patients and was associated with minor bleeding or bruises. This study shows that vorinostat at this dose/schedule is not an effective treatment for advanced thyroid cancer. Our study did not examine potential effect of vorinostat on re-expression of NIS gene.

Romidepsin

In a phase II clinical trial of romidepsin in patients with iodine-refractory, progressive, measurable DTC, romidepsin was administered at a dose of 13 mg/m² IV on day 1, 8, and 15, every 28 days (Su *et al.* 2006).

In preliminary report, 14 DTC patients out of a target accrual of 21 were enrolled. One grade 5 AE of sudden death was noted. Grade 3 AEs included fatigue, dysphagia, and dyspnea. No PR or CR was observed. Clinically, significant restoration of ^{131}I avidity was observed in one PTC patient who subsequently was given treatment-dose ^{131}I with a dramatic ^{131}I avidity by post-therapy whole body scan. Although this restoration of ^{131}I avidity is promising, the noted serious AE raises the question of safety of this drug.

A phase I trial of romidepsin using an alternate dosing schedule where romidepsin was administered on days 1, 3, and 5 was performed with a goal of enhancing gene expression and evaluating ^{131}I uptake in patients with ^{131}I -refractory DTC (Pierkarz *et al.* 2008). Twenty-six patients with solid tumors on this phase I study received doses ranging from 1 to 9 mg/m². Nine of 26 patients on this study had thyroid cancers and received a median of eight cycles (range 1–24). Hypoxia, nausea, and vomiting were considered as dose-limiting toxicities. Grade 3 AEs included cytopenias, anorexia, nausea, and vomiting. Six of nine patients with thyroid cancer had SDs for a median of 3 months. None of the four DTC patients who underwent the follow-up ^{131}I scans had increased ^{131}I uptake. Evaluation of histone acetylation in peripheral blood mononuclear cells (PBMCs) demonstrated a >2-fold increase.

Decitabine

Decitabine (5-aza-2'-deoxycytidine) is a demethylating agent that is approved through the FDA for myelodysplastic syndrome (MDS). An NCI-sponsored multi-institutional phase II study of decitabine is currently examining whether DNA demethylation can induce re-expression of the NIS, and thus ^{131}I avidity, in thyroid cancer. The study was designed in patients with iodine-refractory DTC whose tumor lesions were <1 cm, and iodine avidity is measured by diagnostic iodine scan after two cycles of decitabine. Twelve patients in the first stage of the two-arm study have been enrolled and currently results are being analyzed.

Celecoxib

Our group led a NCCN-sponsored two-center phase II trial of single agent celecoxib, a selective COX-2 inhibitor, in patients with progressive metastatic DTC (Mrozek *et al.* 2006). Patients were treated with celecoxib 400 mg orally twice a day for 12 months. The primary endpoint was PFS at 12 months using RECIST and/or serum Tg response. Twenty-three of 32 patients experienced progressive disease or stopped

therapy due to toxicity, thus fulfilling the intent-to-treat study endpoint for celecoxib failure. One patient achieved PR, and one patient completed 12 months of therapy progression-free. The study was terminated early due to lack of efficacy and new data regarding cardiotoxicity. Celecoxib failed to halt progressive metastatic DTC in most patients. COX-2 protein expression studies were performed in tumor tissue obtained from two responders and three randomly selected non-responder PTC patients. High COX-2 expression was observed in both responders with overall scores of +3. In two of the three non-responders examined, COX-2 expression was largely negative with overall scores of +1. However, the third non-responder patient had an overall score of +2 to +3.

Thalidomide and lenalidomide

Thalidomide and its analogue lenalidomide are potent anti-inflammatory, anti-angiogenic, and immunomodulatory drugs, successfully used for the treatment of multiple myeloma. Ain *et al.* (2007) studied the activity of both of these agents in a single institution phase II trials in patients with radioiodine-unresponsive progressive (tumor volumes increasing $\geq 30\%$ per year before entry assessed by radiographic studies) thyroid cancer. A phase II study to assess efficacy of thalidomide enrolled 29 patients with DTC and 7 patients with MTC. Daily thalidomide was administered at 200 mg, increasing over 6 weeks to 800 mg or maximum tolerated dose. Among 28 evaluable patients, five PRs (18%; 95% CI: 6–37) and nine SD (32%; 95% CI: 12–42) were observed. Median PR duration was 4 months (range, 2–6), and SD duration was 6 months (range, 2–14). Median survival was 23.5 months for responders (PR + SD) and 11 months for non-responders. Half of the patients with objective response discontinued thalidomide due to toxicity. Common AEs included fatigue, somnolence, peripheral neuropathy, constipation, dizziness, and infection. Pericardial effusion and pulmonary embolus were also seen as rare, but serious AEs.

An open-label phase II trial of single agent lenalidomide enrolled 21 patients with ^{131}I -unresponsive DTC (Ain *et al.* 2008). Lenalidomide was administered orally at a dose of 25 mg daily. Preliminary results show 22% PRs and 44% SDs in 18 evaluable patients. Treatment was well tolerated with myelosuppression responding to dose reduction being the most commonly reported AE. Of note, response criteria were based on tumor volume and not standard RECIST and response rate analysis was not done as intent-to-treat analysis in either of these studies.

Bortezomib (PS-341)

In an NCI-sponsored multicenter phase II trial of the bortezomib in patients with metastatic ^{131}I -refractory DTC, the drug was administered at a dose of 1.3 mg/m² i.v. on days 1, 4, 8, and 11 in a 3-week cycle (Brierley *et al.* 2006). At the time of preliminary report, ten patients had been enrolled. Among six evaluable patients, four (67%) patients had SDs as best response with one of these responses lasting more than 12 months. However, serum Tg levels increased in all four patients with SD by a median of 506%. Grade 3–4 AEs included pulmonary embolism ($n=1$) and motor neuropathy ($n=1$).

Cytotoxic chemotherapy

Irofulven, a novel DNA binding agent of the acylfulvene class, demonstrated anti-tumor activity in a variety of chemoresistant tumors. A phase I trial of an irofulven in combination with capecitabine conducted based on positive preclinical data in solid tumors showed PRs in two thyroid cancer patients (Alexandre *et al.* 2003). Subsequently, an international multicenter 2-stage, phase II trial was conducted to evaluate the objective response rate of combination cytotoxic chemotherapy in patients with advanced thyroid cancer (Droz *et al.* 2006). Patients were treated with irofulven at a dose of 0.4 mg/kg given over 30 min as an i.v. infusion on days 1 and 15 and capecitabine orally 2000 mg/m² daily from day 1 to 15 every 28 days. At the time of preliminary report, 23 patients (14 DTC, 5 MTC, and 4 ATC) had been treated. No objective responses were observed and SD was seen in 11 (79%) of DTC patients with a median duration of 4.8 months. Two of these patients had 14 and 19% decreases in tumor size respectively. The main AEs reported were thrombocytopenia, neutropenia, nausea, and asthenia.

Clinical trials in MTC

Vandetanib

A multicenter phase II trial of vandetanib was performed which included patients with unresectable, measurable, locally advanced, or metastatic hereditary MTC harboring a RET germline mutation (Wells *et al.* 2007). Thirty patients received initial treatment with vandetanib 300 mg orally daily and at the time of preliminary report, the median duration of treatment was 6 months. Six of 30 patients (20%) experienced a PR with duration of response ranging from 1.9 to 8.6 months and 9 patients (30%) had SD disease >6 months duration. In 19 patients, plasma

calcitonin levels showed a >50% decrease from baseline that was maintained for at least 6 weeks. Common AEs (>50%) included rash, diarrhea, fatigue, and nausea. QTc prolongation was uncommon (16%) and asymptomatic.

Another phase II clinical trial evaluated efficacy of vandetanib in patients with hereditary MTC when administered at 100 mg orally daily (Haddad *et al.* 2008). Patients were allowed to increase the dose to 300 mg orally daily at time of progression. Among 19 patients, 2 (10%) PRs and 6 (42%) SD >6 months have been noted.

Based on promising preliminary results of these small size phase II trials in hereditary MTC, an international phase III trial of vandetanib in sporadic and hereditary MTC was recently completed and the results are eagerly awaited.

Motesanib (AMG 706)

Motesanib is an oral multi-tyrosine kinase inhibitor targeting VEGF-R, PDGF-R, and c-kit, which has been studied in patients with DTC as well as MTC. In a multicenter international open label phase II trial of motesanib in MTC, patients with locally advanced or metastatic, progressive or symptomatic MTC received motesanib diphosphate 125 mg daily for up to 12 months or until unacceptable toxicity or disease progression (Schlumberger *et al.* 2007). Among 91 patients, 2 patients (2%) achieved PRs (95% CI, 0.3–7.7), and 43 (47%) had SDs of >6 months duration. The Kaplan–Meier estimate of median PFS was 12 months (95% CI, 10.7–14). The most common treatment-related AEs were diarrhea (41%), fatigue (41%), hypertension (27%), anorexia (27%), and nausea (26%). Interestingly, plasma motesanib trough concentrations were reduced compared with previous monotherapy studies at the same dose level, which may impact efficacy.

XL-184

XL-184 is an oral multi-kinase inhibitor targeting RET, MET and VEGFR2. In a phase I clinical trial of XL-184, 14 patients with MTC were enrolled (Salgia *et al.* 2008). Three PRs were noted among ten evaluable MTC patients, and 56–96% reductions in serum calcitonin and 5–80% reductions in serum CEA were noted in all ten evaluable MTC patients. Based on promising anti-tumor activity of XL-184 in MTC, this pilot trial was expanded to MTC cohort using a specific phase II dose of XL-184. An international phase 3 study of XL-184 versus placebo in patients with advanced MTC has recently begun.

Imatinib (STI-571)

Based on *in vitro* inhibition of RET receptor tyrosine kinase by imatinib, phase II open label trials using imatinib in metastatic MTC were conducted by two groups. In the first study, among nine MTC patients (one hereditary, eight sporadic) with unresectable, measurable, and progressive metastases, imatinib was administered at a dose of 600 mg orally daily (Frank-Raue *et al.* 2007). Best response was SD >6 months in five patients and >12 months in one patient. The median PFS was 6 months. Common AEs included mild–moderate nausea, edema, diarrhea, and skin rash. In another phase II study of imatinib using same dosing for up to 12 months, 4 of 15 metastatic MTC patients showed SD >2 years duration (de Groot *et al.* 2007). Serious AEs included hypothyroidism ($n=9$) and laryngeal edema in patients with history of recurrent laryngeal nerve palsy ($n=2$). Other AEs were fatigue, malaise, nausea, and skin rash. The absence of objective response and potential for serious toxicities possibly associated with imatinib do not justify its further use in patients with MTC.

Radioimmunotherapy

In radioimmunotherapy, a radionuclide is targeted to tumor sites using an antibody or antibody fragment. For less radiosensitive tumors, tumor tissue uptake can be enhanced by ‘pretargeting’, a two-step approach where the immune recognition of the tumor site and delivery of the therapeutic radionuclide occur sequentially. This approach has been studied in MTC in an attempt to take advantage of the CEA-positive nature of this type of tumor (Chatal *et al.* 2006, Martins *et al.* 2006). In a French Endocrine Oncology Group study, 29 patients with advanced, progressive MTC (serum calcitonin doubling times of <5 years) received an anti-CEA/anti-diethylenetriamine pentaacetic acid-indium bispecific monoclonal antibody, followed 4 days later by a ^{131}I -labeled bivalent hapten. When compared with 39 matched controls, overall survival was significantly longer in high risk treated patients than in untreated patients (110 vs 61 months; $P<0.030$). Toxicity was mainly hematologic and related to bone/bone-marrow tumor metastasis. Five (17%) patients had grade 4 thrombocytopenia, four (15%) experienced grade 4 neutropenia and one patient (3%) developed MDS. While a significant difference in overall survival is noted, this study is limited by the use of historic controls as a comparison group. Furthermore, prolonged duration of myelosuppression and occurrence of MDS make this treatment less attractive in patients with MTC.

Clinical trials in ATC

Conducting clinical trials in ATC poses several challenges due to the following factors: rare incidence; extremely aggressive clinical course in a vast majority of patients resulting in poor performance status and/or organ dysfunction; poor prognosis and short life expectancy; lack of knowledge about oncogenic targets; and lack of multi-disciplinary teams for care of ATC patients at most cancer centers. While these challenges have limited clinical trials in ATC in the past, the current era is very exciting due to the initiation of phase I-III clinical trials.

Combretastatin

Based on anti-tumor activity of combretastatin against ATC in pre-clinical studies and safety noted in a phase I trial, a phase II trial was conducted in 18 patients who had metastatic ATC, good performance status, and no prior therapy for disseminated disease (Cooney *et al.* 2006). Combretastatin at a dose of 45 mg/m² was administered as 10-min i.v. infusion on days 1, 8, and 15 every 28 days until progressive disease was noted. While therapy was well tolerated, no objective responses were seen. Six patients had SDs while rest of the patients progressed. Median PFS was 1.8 months (range, 0.5–21); with 28% of patients progression free >3 months. Median survival was ~5 months. Based on these results, an international phase III study of paclitaxel and carboplatin with or without combretastatin is ongoing.

Conclusions

With the development of targeted small molecule kinase inhibitors, the treatment of advanced thyroid cancer is changing dramatically. No longer is supportive care the standard, as there are clinical trials underway, which have the potential to revolutionize the field. Because of the well-described pathogenetic targets such as RET, RET/PTC, RAS, BRAF, c-Met, and VEGFR, this field will likely continue to see an explosion of new targeted agents. Besides these known targets, there still remains the opportunity to discover novel pathways important in the development of thyroid carcinoma. It also remains to be seen whether combinations of targeted therapies with other small molecular therapies, with chemo- or radio-therapy will improve response rates. The results of the clinical trials presented, as well as new agents in development, will likely greatly improve the lives of patients with advanced thyroid carcinoma.

Declaration of interest

Dr Manisha Shah had consultant role for Exelixis and BAYER pharmaceuticals in the past two years. Dr Jennifer Woyach has no conflict of interest.

Funding

This research did not receive any specific grant from any funding agency in the public, commercial or not-for-profit sector.

References

- Ain KB, Lee C & Williams KD 2007 Phase II trial of thalidomide for therapy of radioiodine-unresponsive and rapidly progressive thyroid carcinomas. *Thyroid* **17** 663–670.
- Ain KB, Lee C, Holbrook K, Dziba JM & Williams KD 2008 Phase II study of lenalidomide in distantly metastatic, rapidly progressive, and radioiodine-unresponsive thyroid carcinomas: preliminary results. *Journal of Clinical Oncology* **26** Supplement abstract 6027.
- Alexandre J, Berthault-Cvitkovic F, Hilgers W, Yovine A, Weems G & Herait P 2003 Phase I and pharmacokinetic (PK) study of iriflufen (IROF) and capecitabine (CAP) in combination using an intermittent schedule in advanced solid tumors. *Proceedings of the American Society of Clinical Oncology* **22** abstract 615.
- Argiris A, Agarwala SS, Karamouzis MV, Burmeister LA & Carty SE 2008 A phase II trial of doxorubicin and interferon alpha 2b in advanced, non-medullary thyroid cancer. *Investigational New Drugs* **26** 183–188.
- Bauer AJ, Patel A, Terrell R, Doniparthi K, Saji M, Ringel M, Tuttle RM & Francis GL 2003 Systemic administration of vascular endothelial growth factor monoclonal antibody reduces the growth of papillary thyroid carcinoma in a nude mouse model. *Annals of Clinical and Laboratory Science* **33** 192–199.
- Belfiore A, Gangemi P, Costantino A, Russo G, Santonocito GM, Ippolito O, Di Renzo MF, Comoglio P, Fiumara A & Vigneri R 1997 Negative/low expression of the Met/hepatocyte growth factor receptor identifies papillary thyroid carcinomas with high risk of distant metastases. *Journal of Clinical Endocrinology and Metabolism* **82** 2322–2328.
- Bergstrom JD, Hermansson A, Diaz de Stahl T & Heldin NE 1999 Non-autocrine, constitutive activation of Met in human anaplastic thyroid carcinoma cells in culture. *British Journal of Cancer* **80** 650–656.
- Bergstrom JD, Westermark B & Heldin NE 2000 Epidermal growth factor receptor signaling activates met in human anaplastic thyroid carcinoma cells. *Experimental Cell Research* **259** 293–299.
- Braga-Basaria M, Hardy E, Gottfried R, Burman KD, Saji M & Ringel MD 2004 17-Allylamino-17-demethoxygeldanamycin activity against thyroid cancer cell lines correlates with heat shock protein 90 levels. *Journal of Clinical Endocrinology and Metabolism* **89** 2982–2988.
- Brierley J, Tsang R, Glisson B, Kies M, Kane M, Haugen B, Litofsky D & Sherman S 2006 Bortezomib in patients with metastatic differentiated thyroid cancer: preliminary results of a multicenter phase II study. *Thyroid* **16** 858.
- Carlomagno F, Vitagliano D, Guida T, Ciardiello F, Tortora G, Vecchio G, Ryan AJ, Fontanini G, Fusco A & Santoro M 2002 ZD6474, an orally available inhibitor of KDR tyrosine kinase activity, efficiently blocks oncogenic RET kinases. *Cancer Research* **62** 7284–7290.
- Carlomagno F, Anaganti S, Guida T, Salvatore G, Troncone G, Wilhelm SM & Santoro M 2006 BAY 43-9006 inhibition of oncogenic RET mutants. *Journal of the National Cancer Institute* **98** 326–334.
- Chaplin DJ, Pettit GR & Hill SA 1999 Anti-vascular approaches to solid tumour therapy: evaluation of combretastatin A4 phosphate. *Anticancer Research* **19** 189–195.
- Chatal JF, Campion L, Kraeber-Bodere F, Bardet S, Vuillez JP, Charbonnel B, Rohmer V, Chang CH, Sharkey RM, Goldenberg DM *et al.* 2006 Survival improvement in patients with medullary thyroid carcinoma who undergo pretargeted anti-carcinoembryonic-antigen radioimmunotherapy: a collaborative study with the French Endocrine Tumor Group. *Journal of Clinical Oncology* **24** 1705–1711.
- Cohen Y, Xing M, Mambo E, Guo Z, Wu G, Trink B, Beller U, Westra WH, Ladenson PW & Sidransky D 2003 BRAF mutation in papillary thyroid carcinoma. *Journal of the National Cancer Institute* **95** 625–627.
- Cohen E, Needles B, Cullen K, Wong S, Wade J, Ivy S, Villafior V, Seiwert T, Nichols K & Vokes E 2008a Phase 2 study of sunitinib in refractory thyroid cancer. *Journal of Clinical Oncology* **26** Supplement abstract 6025.
- Cohen EE, Rosen LS, Vokes EE, Kies MS, Forastiere AA, Worden FP, Kane MA, Sherman E, Kim S, Bycott P *et al.* 2008b Axitinib is an active treatment for all histologic subtypes of advanced thyroid cancer: results from a phase II study. *Journal of Clinical Oncology* **26** 4708–4713.
- Cooney M, Savvides P, Agarwala S, Wang D, Flick S, Bergant S, Bhakta S, Lavertu P, Ortiz J & Remick S 2006 Phase II study of combretastatin A4 phosphate (CA4P) in patients with advanced anaplastic thyroid carcinoma (ATC). In *ASCO Annual Meeting*, p 5580.
- Copland JA, Marlow LA, Kurakata S, Fujiwara K, Wong AK, Kreinest PA, Williams SF, Haugen BR, Kloppner JP & Smallridge RC 2006 Novel high-affinity PPARgamma agonist alone and in combination with paclitaxel inhibits human anaplastic thyroid carcinoma tumor growth via p21WAF1/CIP1. *Oncogene* **25** 2304–2317.
- Davies L & Welch HG 2006 Increasing incidence of thyroid cancer in the United States, 1973–2002. *Journal of the American Medical Association* **295** 2164–2167.

- Davies H, Bignell GR, Cox C, Stephens P, Edkins S, Clegg S, Teague J, Woffendin H, Garnett MJ, Bottomley W *et al.* 2002 Mutations of the BRAF gene in human cancer. *Nature* **417** 949–954.
- De Besi P, Busnardo B, Toso S, Girelli ME, Nacamulli D, Simioni N, Casara D, Zorat P & Fiorentino MV 1991 Combined chemotherapy with bleomycin, adriamycin, and platinum in advanced thyroid cancer. *Journal of Endocrinological Investigation* **14** 475–480.
- Droz J, Baudin E, Medvedev V, Delord J, Kane M, Kloos R, Ringel M, Kahatt C, Weems G & Shah M 2006 Activity of irifolven (IROF) combined with capecitabine (CAPE) in patients (pts) with advanced thyroid carcinoma: phase II international multicenter study (preliminary results). *Journal of Clinical Oncology* **24** Supplement abstract 15511.
- Druker BJ, Sawyers CL, Kantarjian H, Resta DJ, Reese SF, Ford JM, Capdeville R & Talpaz M 2001 Activity of a specific inhibitor of the BCR-ABL tyrosine kinase in the blast crisis of chronic myeloid leukemia and acute lymphoblastic leukemia with the Philadelphia chromosome. *New England Journal of Medicine* **344** 1038–1042.
- Dvorakova S, Vaclavikova E, Sykorova V, Vcelak J, Novak Z, Duskova J, Ryska A, Laco J, Cap J, Kodetova D *et al.* 2008 Somatic mutations in the RET proto-oncogene in sporadic medullary thyroid carcinomas. *Molecular and Cellular Endocrinology* **284** 21–27.
- Dziba JM, Marcinek R, Venkataraman G, Robinson JA & Ain KB 2002 Combretastatin A4 phosphate has primary antineoplastic activity against human anaplastic thyroid carcinoma cell lines and xenograft tumors. *Thyroid* **12** 1063–1070.
- Elisei R, Cosci B, Romei C, Bottici V, Renzini G, Molinaro E, Agate L, Vivaldi A, Faviana P, Basolo F *et al.* 2008 Prognostic significance of somatic RET oncogene mutations in sporadic medullary thyroid cancer: a 10-year follow-up study. *Journal of Clinical Endocrinology and Metabolism* **93** 682–687.
- Frank-Raue K, Fabel M, Delorme S, Haberkorn U & Raue F 2007 Efficacy of imatinib mesylate in advanced medullary thyroid carcinoma. *European Journal of Endocrinology* **157** 215–220.
- Fukushima T, Suzuki S, Mashiko M, Ohtake T, Endo Y, Takebayashi Y, Sekikawa K, Hagiwara K & Takenoshita S 2003 BRAF mutations in papillary carcinomas of the thyroid. *Oncogene* **22** 6455–6457.
- Furuya F, Shimura H, Suzuki H, Taki K, Ohta K, Haraguchi K, Onaya T, Endo T & Kobayashi T 2004 Histone deacetylase inhibitors restore radioiodide uptake and retention in poorly differentiated and anaplastic thyroid cancer cells by expression of the sodium/iodide symporter thyroperoxidase and thyroglobulin. *Endocrinology* **145** 2865–2875.
- Garcia-Carbonero R & Supko JG 2002 Current perspectives on the clinical experience, pharmacology, and continued development of the camptothecins. *Clinical Cancer Research* **8** 641–661.
- Gottlieb JA & Hill CS Jr 1974 Chemotherapy of thyroid cancer with adriamycin. Experience with 30 patients. *New England Journal of Medicine* **290** 193–197.
- Goulart B, Carr L, Martins R, Eaton K, Kell E, Wallace S, Capell P & Mankoff D 2008 Phase II study of sunitinib in iodine refractory, well-differentiated thyroid cancer (WDTC) and metastatic medullary thyroid carcinoma (MTC). *Journal of Clinical Oncology* **26** Supplement abstract 6062.
- de Groot JW, Zonnenberg BA, van Ufford-Mannesse PQ, de Vries MM, Links TP, Lips CJ & Voest EE 2007 A trial of imatinib therapy for metastatic medullary thyroid carcinoma. *Journal of Clinical Endocrinology and Metabolism* **92** 3466–3469.
- Gullino PM 1978 Angiogenesis and oncogenesis. *Journal of the National Cancer Institute* **61** 639–643.
- Gupta-Abramson V, Troxel AB, Nellore A, Puttaswamy K, Redlinger M, Ransone K, Mandel SJ, Flaherty KT, Loevner LA, O'Dwyer PJ *et al.* 2008 Phase II trial of sorafenib in advanced thyroid cancer. *Journal of Clinical Oncology* **26** 4714–4719.
- Haddad RI, Krebs A, Vasselli J, Paz-Ares L & Robinson B 2008 A phase II open-label study of vandetanib in patients with locally advanced or metastatic hereditary medullary thyroid cancer. *Journal of Clinical Oncology* **26** Supplement abstract 6024.
- Hoelting T, Siperstein AE, Clark OH & Duh QY 1994 Epidermal growth factor enhances proliferation, migration, and invasion of follicular and papillary thyroid cancer *in vitro* and *in vivo*. *Journal of Clinical Endocrinology and Metabolism* **79** 401–408.
- Hou P, Liu D, Shan Y, Hu S, Studeman K, Condouris S, Wang Y, Trink A, El-Naggar AK, Tallini G *et al.* 2007 Genetic alterations and their relationship in the phosphatidylinositol 3-kinase/Akt pathway in thyroid cancer. *Clinical Cancer Research* **13** 1161–1170.
- Hundahl SA, Fleming ID, Fremgen AM & Menck HR 1998 A National Cancer Data Base report on 53,856 cases of thyroid carcinoma treated in the US, 1985–1995 (see comments). *Cancer* **83** 2638–2648.
- Ivan M, Bond JA, Prat M, Comoglio PM & Wynford-Thomas D 1997 Activated ras and ret oncogenes induce over-expression of c-met (hepatocyte growth factor receptor) in human thyroid epithelial cells. *Oncogene* **14** 2417–2423.
- Jhiang SM, Sagartz JE, Tong Q, Parker-Thornburg J, Capen CC, Cho JY, Xing S & Ledent C 1996 Targeted expression of the ret/PTC1 oncogene induces papillary thyroid carcinomas. *Endocrinology* **137** 375–378.
- Jiang W, Hiscox S, Matsumoto K & Nakamura T 1999 Hepatocyte growth factor/scatter factor, its molecular, cellular and clinical implications in cancer. *Critical Reviews in Oncology/Hematology* **29** 209–248.
- Kebebew E, Greenspan FS, Clark OH, Woeber KA & McMillan A 2005 Anaplastic thyroid carcinoma. Treatment outcome and prognostic factors. *Cancer* **103** 1330–1335.

- Kim DW, Jo YS, Jung HS, Chung HK, Song JH, Park KC, Park SH, Hwang JH, Rha SY, Kweon GR *et al.* 2006 An orally administered multitarget tyrosine kinase inhibitor, SU11248, is a novel potent inhibitor of thyroid oncogenic RET/papillary thyroid cancer kinases. *Journal of Clinical Endocrinology and Metabolism* **91** 4070–4076.
- Kimura ET, Nikiforova MN, Zhu Z, Knauf JA, Nikiforov YE & Fagin JA 2003 High prevalence of BRAF mutations in thyroid cancer: genetic evidence for constitutive activation of the RET/PTC-RAS-BRAF signaling pathway in papillary thyroid carcinoma. *Cancer Research* **63** 1454–1457.
- Kitazono M, Robey R, Zhan Z, Sarlis NJ, Skarulis MC, Aikou T, Bates S & Fojo T 2001 Low concentrations of the histone deacetylase inhibitor, depsipeptide (FR901228), increase expression of the Na(+)/I(-) symporter and iodine accumulation in poorly differentiated thyroid carcinoma cells. *Journal of Clinical Endocrinology and Metabolism* **86** 3430–3435.
- Kloos R, Ringel M, Knopp M, Heverhagen J, Hall N, Weldy L, Arbogast D, Collamore M & Shah M 2005 Preliminary results of phase II study of RAF/VEGF-R kinase inhibitor, BAY 43-9006 (sorafenib), in metastatic thyroid carcinoma. *13th International Thyroid Congress, Buenos Aires, Oct 30-Nov 4, 2005*.
- Kloos R, Ringel M, Knopp M, Hall N, King M, Stevens R, Liang J, Wakely P, Vasko V, Saji M *et al.* 2008 Phase II clinical trial of the multi-kinase inhibitor, Sorafenib, in metastatic thyroid cancer. *Journal of Clinical Oncology* **27** 1675–1684.
- Knauf JA, Ma X, Smith EP, Zhang L, Mitsutake N, Liao XH, Refetoff S, Nikiforov YE & Fagin JA 2005 Targeted expression of BRAF^{V600E} in thyroid cells of transgenic mice results in papillary thyroid cancers that undergo dedifferentiation. *Cancer Research* **65** 4238–4245.
- Kurebayashi J, Okubo S, Yamamoto Y, Ikeda M, Tanaka K, Otsuki T & Sonoo H 2006 Additive antitumor effects of gefitinib and imatinib on anaplastic thyroid cancer cells. *Cancer Chemotherapy and Pharmacology* **58** 460–470.
- van der Laan BF, Freeman JL & Asa SL 1995 Expression of growth factors and growth factor receptors in normal and tumorous human thyroid tissues. *Thyroid* **5** 67–73.
- Lennard CM, Patel A, Wilson J, Reinhardt B, Tuman C, Fenton C, Blair E, Francis GL & Tuttle RM 2001 Intensity of vascular endothelial growth factor expression is associated with increased risk of recurrence and decreased disease-free survival in papillary thyroid cancer. *Surgery* **129** 552–558.
- Lewy-Trenda I & Wierchniewska-Lawska A 2002 Expression of vascular endothelial growth factor (VEGF) in human thyroid tumors. *Polish Journal of Pathology* **53** 129–132.
- Lin SY, Wang YY & Sheu WH 2003 Preoperative plasma concentrations of vascular endothelial growth factor and matrix metalloproteinase 9 are associated with stage progression in papillary thyroid cancer. *Clinical Endocrinology* **58** 513–518.
- Liu Z, Hou P, Ji M, Guan H, Studeman K, Jensen K, Vasko V, El-Naggar AK & Xing M 2008 Highly prevalent genetic alterations in receptor tyrosine kinases and phosphatidylinositol 3-kinase/akt and mitogen-activated protein kinase pathways in anaplastic and follicular thyroid cancers. *Journal of Clinical Endocrinology and Metabolism* **93** 3106–3116.
- Marsee DK, Venkateswaran A, Tao H, Vadysirisack D, Zhang Z, Vandre DD & Jhiang SM 2004 Inhibition of heat shock protein 90, a novel RET/PTC1-associated protein, increases radioiodide accumulation in thyroid cells. *Journal of Biological Chemistry* **279** 43990–43997.
- Martins RG, Rajendran JG, Capell P, Byrd DR & Mankoff DA 2006 Medullary thyroid cancer: options for systemic therapy of metastatic disease? *Journal of Clinical Oncology* **24** 1653–1655.
- Mesa C Jr, Mirza M, Mitsutake N, Sartor M, Medvedovic M, Tomlinson C, Knauf JA, Weber GF & Fagin JA 2006 Conditional activation of RET/PTC3 and BRAFV600E in thyroid cells is associated with gene expression profiles that predict a preferential role of BRAF in extracellular matrix remodeling. *Cancer Research* **66** 6521–6529.
- Mitsiades CS, Poulaki V, McMullan C, Negri J, Fanourakis G, Goudopoulou A, Richon VM, Marks PA & Mitsiades N 2005 Novel histone deacetylase inhibitors in the treatment of thyroid cancer. *Clinical Cancer Research* **11** 3958–3965.
- Mitsiades CS, McMillin D, Kotoula V, Poulaki V, McMullan C, Negri J, Fanourakis G, Tseleni-Balafouta S, Ain KB & Mitsiades N 2006 Antitumor effects of the proteasome inhibitor bortezomib in medullary and anaplastic thyroid carcinoma cells *in vitro*. *Journal of Clinical Endocrinology and Metabolism* **91** 4013–4021.
- Mitsiades CS, Negri J, McMullan C, McMillin DW, Sozopoulos E, Fanourakis G, Voutsinas G, Tseleni-Balafouta S, Poulaki V, Batt D *et al.* 2007 Targeting BRAFV600E in thyroid carcinoma: therapeutic implications. *Molecular Cancer Therapeutics* **6** 1070–1078.
- Mrozek E, Kloos RT, Ringel MD, Kresty L, Snider P, Arbogast D, Kies M, Munden R, Busaidy N, Klein MJ *et al.* 2006 Phase II study of celecoxib in metastatic differentiated thyroid carcinoma. *Journal of Clinical Endocrinology and Metabolism* **91** 2201–2204.
- Namba H, Nakashima M, Hayashi T, Hayashida N, Maeda S, Rogounovitch TI, Ohtsuru A, Saenko VA, Kanematsu T & Yamashita S 2003 Clinical implication of hot spot BRAF mutation, V599E, in papillary thyroid cancers. *Journal of Clinical Endocrinology and Metabolism* **88** 4393–4397.
- Nelkin BD & Ball DW 2001 Combretastatin A-4 and doxorubicin combination treatment is effective in a preclinical model of human medullary thyroid carcinoma. *Oncology Reports* **8** 157–160.
- Nikiforova MN, Kimura ET, Gandhi M, Biddinger PW, Knauf JA, Basolo F, Zhu Z, Giannini R, Salvatore G, Fusco A *et al.* 2003 BRAF mutations in thyroid tumors are

- restricted to papillary carcinomas and anaplastic or poorly differentiated carcinomas arising from papillary carcinomas. *Journal of Clinical Endocrinology and Metabolism* **88** 5399–5404.
- Paes JE & Ringel MD 2008 Dysregulation of the phosphatidylinositol 3-kinase pathway in thyroid neoplasia. *Endocrinology and Metabolism Clinics of North America* **37** 375–387 (viii–ix).
- Palii SS, Van Emburgh BO, Sankpal UT, Brown KD & Robertson KD 2008 DNA methylation inhibitor 5-Aza-2'-deoxycytidine induces reversible genome-wide DNA damage that is distinctly influenced by DNA methyltransferases 1 and 3B. *Molecular and Cellular Biology* **28** 752–771.
- Patel A, Pluim T, Helms A, Bauer A, Tuttle RM & Francis GL 2004 Enzyme expression profiles suggest the novel tumor-activated fluoropyrimidine carbamate capecitabine (Xeloda) might be effective against papillary thyroid cancers of children and young adults. *Cancer Chemotherapy and Pharmacology* **53** 409–414.
- Pennell NA, Daniels GH, Haddad RI, Ross DS, Evans T, Wirth LJ, Fidiias PH, Temel JS, Gurubhagavatula S, Heist RS *et al.* 2008 A phase II study of gefitinib in patients with advanced thyroid cancer. *Thyroid* **18** 317–323.
- Pierkarz R, Luchenko V, Draper D, Wright J, Figg W, Fojo A & Bates S 2008 Phase I trial of romidepsin, a histone deacetylase inhibitor, given on days one, three and five in patients with thyroid and other advanced cancers. *Journal of Clinical Oncology* **26** Supplement abstract 3571.
- Polverino A, Coxon A, Starnes C, Diaz Z, DeMelfi T, Wang L, Bready J, Estrada J, Cattley R, Kaufman S *et al.* 2006 AMG 706, an oral, multikinase inhibitor that selectively targets vascular endothelial growth factor, platelet-derived growth factor, and kit receptors, potently inhibits angiogenesis and induces regression in tumor xenografts. *Cancer Research* **66** 8715–8721.
- Porchia LM, Guerra M, Wang YC, Zhang Y, Espinosa AV, Shinohara M, Kulp SK, Kirschner LS, Saji M, Chen CS *et al.* 2007 2-Amino-N-[4-[5-(2-phenanthrenyl)-3-(trifluoromethyl)-1H-pyrazol-1-yl]-phenyl] acetamide (OSU-03012), a celecoxib derivative, directly targets p21-activated kinase. *Molecular Pharmacology* **72** 1124–1131.
- Provenzano MJ, Fitzgerald MP, Krager K & Domann FE 2007 Increased iodine uptake in thyroid carcinoma after treatment with sodium butyrate and decitabine (5-Aza-dC). *Otolaryngology – Head and Neck Surgery* **137** 722–728.
- Ravaud A, de la Fouchardière C, Courbon F, Asselineau J, Klein M, Nicoli-Sire P, Bournaud C, Delord J, Weryha G & Catargi B 2008 Sunitinib in patients with refractory advanced thyroid cancer: the THYSU phase II trial. *Journal of Clinical Oncology* **26** Supplement abstract 6058.
- Di Renzo MF, Olivero M, Ferro S, Prat M, Bongarzone I, Pilotti S, Belfiore A, Costantino A, Vigneri R, Pierotti MA *et al.* 1992 Overexpression of the c-MET/HGF receptor gene in human thyroid carcinomas. *Oncogene* **7** 2549–2553.
- Rixe O, Bukowski RM, Michaelson MD, Wilding G, Hudes GR, Bolte O, Motzer RJ, Bycott P, Liao KF, Freddo J *et al.* 2007 Axitinib treatment in patients with cytokine-refractory metastatic renal-cell cancer: a phase II study. *Lancet Oncology* **8** 975–984.
- Salgia R, Sherman S, Hong D, Ng C, Frye J, Janisch L, Ratain M & Kurzrock R 2008 A phase I study of XL184, a RET, VEGFR2, and MET kinase inhibitor, in patients (pts) with advanced malignancies, including pts with medullary thyroid cancer (MTC). *Journal of Clinical Oncology* **26** Supplement abstract 3522.
- Salvatore G, De Falco V, Salerno P, Nappi TC, Pepe S, Troncone G, Carlomagno F, Melillo RM, Wilhelm SM & Santoro M 2006 BRAF is a therapeutic target in aggressive thyroid carcinoma. *Clinical Cancer Research* **12** 1623–1629.
- Santarpia L, El-Naggar AK, Cote GJ, Myers JN & Sherman SI 2008 Phosphatidylinositol 3-kinase/akt and ras/raf-mitogen-activated protein kinase pathway mutations in anaplastic thyroid cancer. *Journal of Clinical Endocrinology and Metabolism* **93** 278–284.
- Santoro M, Rosati R, Grieco M, Berlingieri MT, D'Amato GL, de Franciscis V & Fusco A 1990 The ret proto-oncogene is consistently expressed in human pheochromocytomas and thyroid medullary carcinomas. *Oncogene* **5** 1595–1598.
- Schiff BA, McMurphy AB, Jasser SA, Younes MN, Doan D, Yigitbasi OG, Kim S, Zhou G, Mandal M, Bekele BN *et al.* 2004 Epidermal growth factor receptor (EGFR) is overexpressed in anaplastic thyroid cancer, and the EGFR inhibitor gefitinib inhibits the growth of anaplastic thyroid cancer. *Clinical Cancer Research* **10** 8594–8602.
- Schlumberger M, Elisei R, Sherman S, Bastholt L, Wirth L, Martins R, Licitra L, Jarzab B, Pacini F, Daumerie C *et al.* 2007 Initial results from a phase II trial of motesanib diphosphate (AMG 706) in patients with medullary thyroid cancer. *89th Annual Meeting of the Endocrine Society (ENDO 07): Toronto, ON.*
- Shaha AR, Shah JP & Loree TR 1997 Differentiated thyroid cancer presenting initially with distant metastasis. *American Journal of Surgery* **174** 474–476.
- Shan L, Nakamura M, Nakamura Y, Utsunomiya H, Shou N, Jiang X, Jing X, Yokoi T & Kakudo K 1998 Somatic mutations in the RET protooncogene in Japanese and Chinese sporadic medullary thyroid carcinomas. *Japanese Journal of Cancer Research* **89** 883–886.
- Sherman SI, Wirth LJ, Droz JP, Hofmann M, Bastholt L, Martins RG, Licitra L, Eschenberg MJ, Sun YN, Juan T *et al.* 2008 Motesanib diphosphate in progressive differentiated thyroid cancer. *New England Journal of Medicine* **359** 31–42.

- Shimaoka K, Schoenfeld DA, DeWys WD, Creech RH & DeConti R 1985 A randomized trial of doxorubicin versus doxorubicin plus cisplatin in patients with advanced thyroid carcinoma. *Cancer* **56** 2155–2160.
- Shimazaki N, Togashi N, Hanai M, Isoyama T, Wada K, Fujita T, Fujiwara K & Kurakata S 2008 Anti-tumour activity of CS-7017, a selective peroxisome proliferator-activated receptor gamma agonist of thiazolidinedione class, in human tumour xenografts and a syngeneic tumour implant model. *European Journal of Cancer* **44** 1734–1743.
- Smida J, Salassidis K, Hieber L, Zitzelsberger H, Kellerer AM, Demidchik EP, Negele T, Spelsberg F, Lengfelder E, Werner M *et al.* 1999 Distinct frequency of ret rearrangements in papillary thyroid carcinomas of children and adults from Belarus. *International Journal of Cancer* **80** 32–38.
- Soares P, Trovisco V, Rocha AS, Lima J, Castro P, Preto A, Maximo V, Botelho T, Seruca R & Sobrinho-Simoes M 2003 BRAF mutations and RET/PTC rearrangements are alternative events in the etiopathogenesis of PTC. *Oncogene* **22** 4578–4580.
- Strock CJ, Park JI, Rosen DM, Ruggeri B, Denmeade SR, Ball DW & Nelkin BD 2006 Activity of irinotecan and the tyrosine kinase inhibitor CEP-751 in medullary thyroid cancer. *Journal of Clinical Endocrinology and Metabolism* **91** 79–84.
- Su Y, Tuttle R, Fury M, Ghossein R, Singh B, Herman K, Venkatraman E, Stambuk H, Robbins R & Pfister D 2006 A phase II study of single agent depsipeptide (DEP) in patients (pts) with radioactive iodine (RAI)-refractory, metastatic, thyroid carcinoma: preliminary toxicity and efficacy experience. *Journal of Clinical Oncology* **24** Supplement abstract 5554.
- Tanaka K, Kurebayashi J, Sonoo H, Otsuki T, Yamamoto Y, Ohkubo S, Yamamoto S & Shimozuma K 2002 Expression of vascular endothelial growth factor family messenger RNA in diseased thyroid tissues. *Surgery Today* **32** 761–768.
- Trovisco V, Vieira de Castro I, Soares P, Maximo V, Silva P, Magalhaes J, Abrosimov A, Guiu XM & Sobrinho-Simoes M 2004 BRAF mutations are associated with some histological types of papillary thyroid carcinoma. *Journal of Pathology* **202** 247–251.
- Uchino S, Noguchi S, Yamashita H, Sato M, Adachi M, Yamashita H, Watanabe S, Ohshima A, Mitsuyama S, Iwashita T *et al.* 1999 Somatic mutations in RET exons 12 and 15 in sporadic medullary thyroid carcinomas: different spectrum of mutations in sporadic type from hereditary type. *Japanese Journal of Cancer Research* **90** 1231–1237.
- Viglietto G, Chiappetta G, Martinez-Tello FJ, Fukunaga FH, Tallini G, Rigopoulou D, Visconti R, Mastro A, Santoro M & Fusco A 1995 RET/PTC oncogene activation is an early event in thyroid carcinogenesis. *Oncogene* **11** 1207–1210.
- Weinstein IB 2002 Cancer. Addiction to oncogenes – the Achilles heel of cancer. *Science* **297** 63–64.
- Weinstein IB & Joe A 2008 Oncogene addiction. *Cancer Research* **68** 3077–3080 (discussion 3080).
- Wells S, Gosnell J, Gagel R, Moley J, Pfister D, Sosa J, Skinner M, Krebs A, Hou J & Schlumberger M 2007 Vandetanib in metastatic hereditary medullary thyroid cancer: follow-up results of an open-label phase II trial. In *2007 ASCO Annual Meeting*, Abst no. 6018.
- Williams SD, Birch R & Einhorn LH 1986 Phase II evaluation of doxorubicin plus cisplatin in advanced thyroid cancer: a Southeastern Cancer Study Group Trial. *Cancer Treatment Reports* **70** 405–407.
- Woyach J, Kloos R, Ringel M, Arbogast D, Collamore M, Zwiebel J, Grever M, Villalona-Calero M & Shah M 2008 Lack of therapeutic effect of the histone deacetylase inhibitor vorinostat in patients with metastatic radioiodine-refractory thyroid carcinoma. *Journal of Clinical Endocrinology and Metabolism* **94** 164–170.
- Xing M 2005 BRAF mutation in thyroid cancer. *Endocrine-Related Cancer* **12** 245–262.
- Xing M, Vasko V, Tallini G, Larin A, Wu G, Udelsman R, Ringel MD, Ladenson PW & Sidransky D 2004 BRAF T1796A transversion mutation in various thyroid neoplasms. *Journal of Clinical Endocrinology and Metabolism* **89** 1365–1368.
- Xu X, Quiros RM, Gattuso P, Ain KB & Prinz RA 2003 High prevalence of BRAF gene mutation in papillary thyroid carcinomas and thyroid tumor cell lines. *Cancer Research* **63** 4561–4567.
- Yeung SC, She M, Yang H, Pan J, Sun L & Chaplin D 2007 Combination chemotherapy including combretastatin A4 phosphate and paclitaxel is effective against anaplastic thyroid cancer in a nude mouse xenograft model. *Journal of Clinical Endocrinology and Metabolism* **92** 2902–2909.
- Zhu J, Huang JW, Tseng PH, Yang YT, Fowble J, Shiau CW, Shaw YJ, Kulp SK & Chen CS 2004 From the cyclooxygenase-2 inhibitor celecoxib to a novel class of 3-phosphoinositide-dependent protein kinase-1 inhibitors. *Cancer Research* **64** 4309–4318.