

EDITORIAL

## Safety and clinical efficacy of granulocyte and monocyte adsorptive apheresis therapy for ulcerative colitis

Takayuki Yamamoto, Satoru Umegae, Koichi Matsumoto

Takayuki Yamamoto, Satoru Umegae, Koichi Matsumoto, Inflammatory Bowel Disease Center, Yokkaichi Social Insurance Hospital, 10-8 Hazuyamacho, Yokkaichi, Mie 510-0016, Japan  
Correspondence to: Takayuki Yamamoto, MD, Inflammatory Bowel Disease Center, Yokkaichi Social Insurance Hospital, 10-8 Hazuyamacho, Yokkaichi, Mie 510-0016, Japan. nao-taka@sannet.ne.jp  
Telephone: +81-593-31-2000 Fax: +81-593-31-0354  
Received: 2005-07-18 Accepted: 2005-08-03

### Abstract

Active ulcerative colitis (UC) is frequently associated with infiltration of a large number of leukocytes into the bowel mucosa. Therefore, removal of activated circulating leukocytes by apheresis has the potential for improving UC. In Japan, since April 2000, leukocytapheresis using Adacolumn has been approved as the treatment for active UC by the Ministry of Health and Welfare. The Adacolumn is an extracorporeal leukocyte apheresis device filled with cellulose acetate beads, and selectively adsorbs granulocytes and monocytes/macrophages. To assess the safety and clinical efficacy of granulocyte and monocyte adsorptive apheresis (GMCAP) for UC, we reviewed 10 open trials of the use of GMCAP to treat UC. One apheresis session (session time, 60 min) per week for five consecutive weeks (a total of five apheresis sessions) has been a standard protocol. Several studies used modified protocols with two sessions per week, with 90-min session, or with a total of 10 apheresis sessions. Typical adverse reactions were dizziness, nausea, headache, flushing, and fever. No serious adverse effects were reported during and after GMCAP therapy, and almost all the patients could complete the treatment course. GMCAP is safe and well-tolerated. In the majority of patients, GMCAP therapy achieved clinical remission or improvement. GMCAP is a useful alternative therapy for patients with steroid-refractory or -dependent UC. GMCAP should have the potential to allow tapering the dose of steroids, and is useful for shortening the time to remission and avoiding re-administration of steroids at the time of relapse. Furthermore, GMCAP may have efficacy as the first-line therapy for steroid-naïve patients or patients who have the first attack of UC. However, most of the previous studies were uncontrolled trials. To assess a definite efficacy of GMCAP, randomized, double-blind, sham-controlled trials are necessary. A serious problem with GMCAP is cost; a single session costs ¥145 000 (\$1 300). However, if this treatment prevents hospital admission, re-administration of steroids and

surgery, and improves a quality of life of the patients, GMCAP may prove to be cost-effective.

© 2006 The WJG Press. All rights reserved.

**Key words:** Clinical efficacy; Granulocyte and monocyte adsorptive apheresis; Leukocytapheresis; Safety; Ulcerative colitis

Yamamoto T, Umegae S, Matsumoto K. Safety and clinical efficacy of granulocyte and monocyte adsorptive apheresis therapy for ulcerative colitis. *World J Gastroenterol* 2006; 12(4): 520-525

<http://www.wjgnet.com/1007-9327/12/520.asp>

### INTRODUCTION

Ulcerative colitis (UC) is an inflammatory bowel disease of unknown etiology that involves colon and rectum. Active UC is frequently associated with infiltration of large number of leukocytes into the bowel mucosa<sup>[1,2]</sup>. The infiltrated leukocytes can cause extensive mucosal tissue injury by releasing a large number of inflammatory mediators such as prostaglandins, leukotrienes, platelet activating factor, thromboxanes, oxygen radicals, proteases, and cytokines<sup>[3]</sup>. Therefore, removal of activated circulating leukocytes by apheresis has the potential for improving the bowel inflammation and patient status in UC. Recently, leukocytapheresis has been tried as a novel approach for UC<sup>[4,5]</sup>.

Clinical efficacy and safety of leukocytapheresis for UC were initially investigated in a multicenter study in Japan, and the results were published in 1999<sup>[5]</sup>. In that study, 120 patients were randomly divided into two groups; one group received leukocytapheresis and the other group conventional drugs (corticosteroids and/or sulfasalazine/mesalazine). Clinical efficacy was observed in 58% of patients in the leukocytapheresis group compared with 44% in the drug group. Adverse effects were noted in 8% of patients in the leukocytapheresis group compared with 43% in the drug group. From these data, leukocytapheresis seemed to be superior to conventional drugs, and this was more striking in patients with severe and intractable diseases<sup>[5]</sup>. In Japan, since April 2000, leukocytapheresis using Adacolumn (Japan Immunoresearch Laboratories, Takasaki, Japan)<sup>[6]</sup> has been approved as the treatment of patients with active UC by the Ministry of Health and

**Table 1** Summary of trials of GMCAP therapy using Adacolumn for patients with active UC

Authors (yr)	Indications for GMCAP	n	Apheresis protocol	Adverse effects (% of patients)	Efficacy (%)
Shimoyama <i>et al</i> <sup>[9]</sup> (2001)	Refractory to conventional drugs	53	Standard <sup>1</sup>	9%	Remission: 21% Improvement: 37%
Tomomasa <i>et al</i> <sup>[10]</sup> (2003)	Steroid-refractory children	12	1 session/wk for 5-10 wk	9%	Improvement: 67%
Hanai <i>et al</i> <sup>[11]</sup> (2003)	Steroid-refractory Steroid-naive	31 8	10 or 11 sessions over 11 wk	18%	Remission: Steroid-refractory 81% Steroid-naive 88%
Suzuki <i>et al</i> <sup>[12]</sup> (2004)	Steroid-naive	20	2 sessions/wk for 3-5 wk	10%	Improvement: Steroid-refractory 6% Steroid-naive 12%
Naganuma <i>et al</i> <sup>[13]</sup> (2004)	Steroid-refractory Steroid-dependent	44	Standard <sup>1</sup>	5%	Remission: 55% Improvement: 20%
Hanai <sup>[14]</sup> (2004) <sup>2</sup>	Steroid-dependent	46	11 sessions over 10 wk	22%	Remission: 83%
Yamamoto <i>et al</i> <sup>[15]</sup> (2004)	Mild-to-moderate active distal disease	30	Standard <sup>1</sup>	27%	Remission: 70% Improvement: 17%
Domenech <i>et al</i> <sup>[16]</sup> (2004) <sup>3</sup>	Steroid-dependent	14	Standard <sup>1</sup>	15%	Remission: 62% Improvement: 14%
Kanke <i>et al</i> <sup>[17]</sup> (2004)	Mild-to-severe disease	60	10 sessions over 12 wk <sup>4</sup>	18%	Remission: 23% Improvement: 60%
Kim <i>et al</i> <sup>[18]</sup> (2005)	Refractory to conventional drugs	27	Standard <sup>1</sup>	11%	Improvement: 70%

GMCAP, granulocyte and monocyte/macrophage adsorptive apheresis; UC, ulcerative colitis.

<sup>1</sup>Five apheresis sessions for five consecutive weeks; session time, 60 min; blood flow rate, 30 mL/min.

<sup>2</sup>This study was a randomized controlled trial comparing efficacy of GMCAP and prednisolone.

<sup>3</sup>This study also included 12 patients with Crohn's disease.

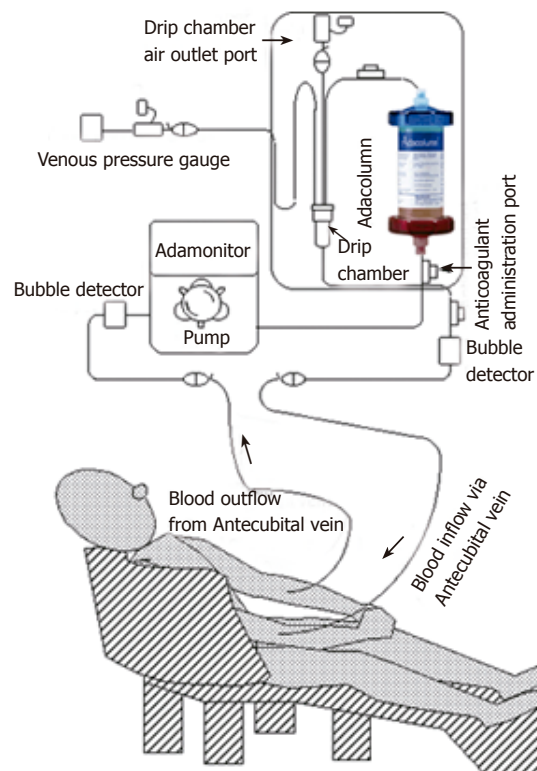
<sup>4</sup>One or two sessions per week; session time, 60 or 90 min.

Welfare. Hence, currently the Adacolumn is available in the market throughout Japan and is being used for treating UC. The Adacolumn is an extracorporeal leukocyte apheresis device filled with cellulose acetate beads, and selectively adsorbs granulocytes and monocytes/macrophages; lymphocytes are not significantly adsorbed<sup>[7]</sup>. Thus, the Adacolumn is for selective granulocyte and monocyte/macrophage adsorptive apheresis (GMCAP). As leukocytapheresis therapy, Cellsorba (Asahi Kasei Medical Co., Ltd, Tokyo, Japan)<sup>[8]</sup> is also available in Japan. The Cellsorba is filled with very fine polyester fiber as adsorptive carriers, and removes lymphocytes in addition to granulocytes and monocytes.

In this paper, we have discussed safety and efficacy of GMCAP using the Adacolumn, which has been used as leukocytapheresis therapy in our institution. Since 2000, there have been 10 open trials of the use of GMCAP to treat UC (Table 1)<sup>[9-18]</sup>. Eight of the ten trials were performed in Japan. We mainly reviewed these trials to assess clinical efficacy and safety of GMCAP for UC. Finally, we discussed possible future role of GMCAP in the management of UC.

### GMCAP procedures

The Adacolumn<sup>[6]</sup> is a single use adsorptive type apheresis column, with a volume of 335 mL, filled with 220 g of cellulose acetate beads of 2 mm diameter as the column adsorptive carriers. An outline of GMCAP procedures using the Adacolumn is shown in Figure 1. GMCAP was



**Figure 1** An outline of GMCAP procedures using the Adacolumn. Blood is drawn into the column from the antecubital vein of one hand, and returned to the patient via antecubital vein of the contralateral hand. GMCAP, granulocyte and monocyte/macrophage adsorptive apheresis.

performed in out-patient clinic for patients with mild symptoms, and patients with severe symptoms were hospitalized for GMCAP. The process of performing GMCAP is relatively simple. Prior to apheresis, the system is primed by saline-containing anticoagulant, nafamostat mesilate or heparin, and during apheresis saline containing those anticoagulants is continuously administered into the column. Blood is drawn into the column from the antecubital vein of one hand, and returned to the patient via antecubital vein of the contralateral hand, without using a shunt. The commonly used apheresis time and blood flow rate are 60 min and 30 mL/min, respectively. During these procedures, the carriers adsorb about 65% of granulocytes, 55% of monocytes and 2% of lymphocytes from the blood in the column<sup>[7]</sup>. After completion of each apheresis session, the residual blood in the column and circuit lines is returned to the patient by infusing physiological saline at the blood inflow line. Vital signs are continuously monitored during the apheresis by dialysis staff. One apheresis session (session time, 60 min; blood flow rate, 30 mL/min) per week for five consecutive weeks (a total of five apheresis sessions) has been a standard protocol. Recently, other protocols with two sessions per week or a total of 10 apheresis sessions have been used for patients with severe UC. Furthermore, apheresis sessions longer than 60 min and apheresis with a higher blood flow rate have been tried for severe diseases. In several institutions, the efficacy of the protocol with a longer session time and higher blood flow rate is being compared with that of the standard protocol<sup>[17]</sup>.

### Indications for GMCAP

According to the Guidelines of the Investigation and Research Committee of Inflammatory Bowel Disease of the Ministry of Health and Welfare of Japan, GMCAP has been mainly used for patients with steroid-refractory (no or little improvement after high dose steroid therapy) and steroid-dependent (inability to decrease the steroid dosage) moderate-to-severe UC. For the majority of patients, corticosteroids were given during GMCAP therapy as concomitant medications. In contrast, steroid-naïve patients with milder UC were also treated with GMCAP<sup>[11,12,15]</sup>.

### Adverse effects

No serious adverse effects were reported during and after GMCAP therapy, and almost all patients could complete the treatment course. From the data in the previous trials<sup>[9-18]</sup>, adverse effects were observed in 5%-27% of patients (Table 1). Typical adverse reactions were dizziness, nausea, headache, flushing, and fever. These symptoms lasted from only a couple of minutes to a couple of hours. Fever could be treated with antifebrile, and headache could be prevented with painkillers before the apheresis. Infectious problems due to GMCAP were rarely reported<sup>[16]</sup>. In our study, one patient developed a mild liver dysfunction probably due to an anticoagulant, nafamostat mesilate<sup>[15]</sup>. Thereafter, heparin was used instead. The liver dysfunction normalized without any special treatment.

### Clinical efficacy

Patients were followed up regularly during and after GMCAP therapy, and the final efficacy assessment was performed at one or two weeks after the last apheresis session<sup>[9-18]</sup>. The efficacy of GMCAP was evaluated using clinical activity index or disease activity index scores<sup>[19-21]</sup>. In a prospective multicenter trial in Japan<sup>[9]</sup>, 53 patients refractory to conventional drug therapy were treated with the standard GMCAP protocol (five apheresis sessions for five consecutive weeks; session time, 60 min; blood flow rate, 30 mL/min) in combination with prednisolone. After the treatment, 21% and 37% of patients achieved remission and improvement (without remission), respectively, and the mean daily dose of prednisolone per patient was reduced from 24.4 mg at enrollment to 14.2 mg after GMCAP therapy. In another prospective multicenter study in Korea<sup>[18]</sup>, 27 patients with moderate-to-severe active UC refractory to conventional drugs were treated with the standard GMCAP protocol. Clinical improvement was observed in 70% of patients (44% markedly improved), and tapering down or discontinuation of steroids was possible in 56% of concomitant steroid users. Naganuma *et al*<sup>[13]</sup> treated 44 steroid-refractory or -dependent patients with the standard GMCAP protocol. Twenty-four patients (55%) obtained remission, 9 (20%) showed a clinical response (without remission), and 11 (25%) remained unchanged. Only 20% of patients with severe steroid-refractory UC achieved remission, whereas 70% of patients with moderate steroid-refractory UC achieved remission. In 90% of patients with steroid-dependent UC, the daily dose of corticosteroids could be tapered during GMCAP therapy. In the long-term, 61% of patients who achieved clinical improvement or remission maintained remission, whereas 39% had relapsed. Approximately half of the relapsed patients were successfully treated with repeat GMCAP therapy. The Spanish Group for the Study of Crohn's Disease and Ulcerative Colitis (GETECCU)<sup>[16]</sup> conducted a prospective, open, pilot study including 26 patients with steroid-dependent inflammatory bowel disease (UC, 14; Crohn's disease, 12). Patients were started on 60 mg/d of prednisone; after one week, GMCAP therapy with the standard protocol was started. The steroid dose was tapered weekly if there was clinical improvement. Remission was achieved in 62% and 70% of patients with UC and Crohn's disease, respectively. During a median follow-up of 12.6 mo, 6 of 8 UC patients maintained their clinical remission; however, only one Crohn's disease patient remained in remission after the first 6 mo of follow-up.

Higher remission or improvement rates have been reported using the modified GMCAP protocols. Hanai *et al*<sup>[11]</sup> examined 31 patients with steroid-refractory UC and eight steroid-naïve patients who were treated with a total of 10 or 11 GMCAP sessions (session time, 60 min; blood flow rate, 30 mL/min); for patients with severe diseases, two sessions per week for the first three weeks and then weekly session for five weeks; for the other patients, weekly session for the first five weeks and after an interval of one week, weekly session for another five weeks. After the treatment, 81% of steroid-refractory and 88% of

steroid-naïve patients achieved remission, and 79% of patients maintained their remission during 12 mo. The same research group<sup>[14]</sup> conducted a randomized controlled trial comparing the efficacy of GMCAP and prednisolone. Sixty-nine steroid-dependent patients were randomly assigned to two groups; 46 patients were given 11 GMCAP sessions (session time, 60 min; flow rate, 30 mL/min) over 10 wk in combination with prednisolone (GMCAP group), and the other 23 patients were treated with 30 mg/d of prednisolone (prednisolone group). Prednisolone was tapered or discontinued with improvement of disease in both the groups. At 12 wk after the treatment, 83% of patients in the GMCAP group and 65% in the prednisolone group achieved remission and the difference was not statistically significant. During the 12 wk of the treatment, the cumulative amount of prednisolone received per patient was 1 157 mg in the GMCAP group, which was significantly lower than 1 938 mg in the prednisolone group. Kanke *et al.*<sup>[17]</sup> treated 60 patients with active UC with 10 GMCAP sessions with different duration (60 or 90 min) and frequency (one or two sessions per week) of apheresis. There was an association between the final disease activity and the duration of apheresis, and twice a week was superior to one session per week for the improvement of disease activity. Furthermore, twice a week or 90 min was superior to one session per week or 60 min for improvement of clinical symptoms such as diarrhea, abdominal pain, and bloody stools.

GMCAP has been also used for steroid-naïve patients or patients with milder UC<sup>[12,15]</sup>. Suzuki *et al.*<sup>[12]</sup> treated 20 steroid-naïve patients with active UC with 6-10 GMCAP sessions (two sessions per week; session time, 60 min; blood flow rate, 30 mL/min). Seventeen patients (85%) achieved remission, and 60% had maintained their remission during eight months. In our study<sup>[15]</sup>, GMCAP therapy with the standard protocol (no concomitant steroid medications) was performed for 30 patients with mild-to-moderately active distal UC. Clinical symptoms significantly improved after the third apheresis session. Clinical remission was achieved in 21 patients (70%), and clinical improvement (without remission) was recognized in 5 patients (17%). In 4 patients (13%), clinical response was not recognized. GMCAP was not effective for patients with long disease duration and those who had been treated with high-dose steroids. All of the 21 patients who achieved clinical remission were able to maintain remission during the 12-wk follow-up after GMCAP. The efficacy of GMCAP for pediatric UC has been reported. Tomomasa *et al.*<sup>[10]</sup> retrospectively reviewed 12 steroid-refractory children who were treated with weekly GMCAP for 5-10 consecutive weeks. In eight patients, clinical symptoms improved after two apheresis sessions. The dose of steroid was tapered during GMCAP therapy by 50%. Four of the eight patients relapsed 3.5 mo after the last apheresis session, the other four patients remained in remission up to 22.8 mo.

## DISCUSSION

A lot of research is going on to clarify the detailed mechanism of GMCAP on UC<sup>[7,22-29]</sup>. Although during GMCAP,

the carriers adsorb 65% of granulocytes, 55% of monocytes and 2% of lymphocytes from the blood in the column, the number of these leukocytes in the systemic circulation did not fall immediately after the apheresis<sup>[7]</sup>. This can be explained by an influx of new leukocytes into the systemic circulation from the marginal pools, principally the bone marrow during apheresis. Thus, the efficacy of GMCAP cannot be fully explained on the basis of reducing leukocytes. Rembacken *et al.*<sup>[4]</sup> found that the markedly increased expression of  $\alpha(m)$  integrin/Mac-1 and low L-selectin expression alter the capability of granulocytes to migrate to inflammatory sites. Kashiwagi *et al.*<sup>[23]</sup> found a significant suppression of proinflammatory cytokines (interleukin [IL]-1 $\beta$ , IL-6, IL-8 and tumor necrosis factor [TNF]- $\alpha$  production) by leukocytes, neutrophils chemotaxis, down-regulation of leukocyte adhesion molecule (L-selectin) and neutrophil adhesion to IL-1 $\beta$ -activated endothelial cells after GMCAP for UC. Furthermore, the number of CD10-negative premature granulocytes increased, indicating increased turnover of these cells in the systemic circulation. Takeda *et al.*<sup>[27]</sup> found that granulocyte adsorption to cellulose acetate beads required plasma IgG, the complement C3 and was inhibited by an antibody to leukocytes CD18. Furthermore, hepatocyte growth factor and IL-1 receptor antagonist (IL-1ra) which have strong anti-inflammatory actions were released by granulocytes that adhered to cellulose acetate beads. Hanai *et al.*<sup>[28]</sup> found that TNF- $\alpha$  receptors I and II were significantly increased in the peripheral blood after apheresis. These observations suggest that selective granulocyte and monocyte adsorption is associated with modified peripheral blood leukocyte function favorable to patients with UC which reflect leukocyte hyperactivity. Further investigations are necessary to explain the precise mechanism of GMCAP.

No serious adverse effects were reported during and after GMCAP therapy, and almost all patients could complete the treatment course<sup>[9-18]</sup>. GMCAP is fairly safe and well tolerated. The clinical remission and improvement rates were different among the studies because many factors such as the indications of GMCAP, disease activity before GMCAP, protocol of GMCAP (frequency, duration and a total number of apheresis), concomitant medications, and the method of efficacy assessment were different. However, the data from the previous trials suggest that GMCAP is a useful alternative therapy for patients with steroid-refractory or -dependent UC. GMCAP should have the potential to allow tapering the dose of steroids, and is useful for shortening the time to remission and avoiding re-administration of steroids at the time of relapse. Furthermore, GMCAP may have efficacy as the first-line therapy for steroid-naïve patients or patients who have the first attack of UC.

The modified apheresis protocols with two sessions per week, with 90-min session, or a total of 10 apheresis sessions seem to be more effective than the standard protocol (weekly, 60-min apheresis and a total of five sessions). The modified protocol should be used for patients with more severe diseases, and patients with milder diseases can be treated with the standard protocol. However, the most appropriate frequency and duration of apheresis, and number of apheresis sessions still remain

unknown. Although several patients maintained their remission after GMCAP therapy, the long-term efficacy of GMCAP should be assessed in future. Furthermore, whether GMCAP is useful as maintenance therapy during remission needs to be assessed. Most of the previous studies were uncontrolled trials; only one study was a randomized, open-labeled, controlled trial comparing GMCAP and prednisolone<sup>[14]</sup>. To assess a definite efficacy of GMCAP, well-designed randomized controlled trials are necessary. In the United States and Canada, a randomized, prospective, double-blinded, placebo-controlled (sham-controlled) study to evaluate the safety and effectiveness of the Adacolumn apheresis system for the treatment of moderate-to-severe UC is being conducted<sup>[30]</sup>.

There have been few studies which examined the efficacy of GMCAP for Crohn's disease<sup>[16,31-34]</sup>. One study reported that a five-session protocol of GMCAP seemed to be efficient in the treatment of steroid-dependent UC, but not in Crohn's disease<sup>[16]</sup>. In contrast, several studies reported that GMCAP was useful to decrease the disease activity in patients with Crohn's disease<sup>[31-34]</sup>. Kusaka *et al*<sup>[33]</sup> treated six patients with active Crohn's disease unresponsive to conventional medications with GMCAP (five apheresis sessions for five consecutive weeks). The Crohn's disease activity index (CDAI) significantly decreased after GMCAP therapy. Three of the six patients responded to the therapy, and one patient could be induced to remission. Fukuda *et al*<sup>[34]</sup> treated 21 patients with a CDAI of >200 and unresponsive to standard medication with GMCAP (five apheresis sessions for five consecutive weeks). After GMCAP therapy, significant improvements in CDAI scores were observed. GMCAP could be effective for inducing remission and improving the quality of life in patients with active Crohn's disease that is refractory to conventional therapy. However, further clinical studies are necessary to assess the efficacy of leukocytapheresis for Crohn's disease because the number of patients included in the previous studies was quite small.

A serious problem with GMCAP is cost; a single session of GMCAP costs ¥145 000 (\$1 300). Because of high cost, GMCAP therapy may not be favorable as a first-line alternative to steroids in patients with active UC. Up to now, the most common medication for UC has been steroids<sup>[35,36]</sup>. When the patient does not respond to steroids and the disease is progressing, surgery is implemented as the last option. Most patients experience adverse effects associated with high dose and long-term administration of steroids and hence, they could have a poor quality of life<sup>[35,36]</sup>. Patients with active UC can be successfully treated with leukocytapheresis, without the usage of corticosteroids, which is good news for both patients and physicians because the prolonged use of steroids may be limited and patient compliance diminished by potential adverse effects. If GMCAP prevents hospital admission, re-administration of steroids and surgery, and it improves and maintains a quality of life of the patients, GMCAP may prove to be cost-effective. The future of GMCAP in the treatment of UC requires further evaluation.

## REFERENCES

- 1 Grisham MB, Kvietys PR. Role of neutrophils in the pathogenesis of inflammatory bowel disease. In: Allan, RN, Rhodes, JM, Hanauer, SB, Keighley, MRB, Alexander-Williams, J, Fazio, VW, eds. *Inflammatory Bowel Diseases*, 3rd ed. New York: Churchill Livingstone 1997: 73-80
- 2 Mahida YR. Monocytes and macrophages in inflammatory bowel disease. In: Allan, RN, Rhodes, JM, Hanauer, SB, Keighley, MRB, Alexander-Williams, J, Fazio, VW, eds. *Inflammatory Bowel Diseases*, 3rd ed. New York: Churchill Livingstone 1997: 81-85
- 3 Rampton DS. Inflammatory mediators. In: Allan, RN, Rhodes, JM, Hanauer, SB, Keighley, MRB, Alexander-Williams, J, Fazio, VW, eds. *Inflammatory Bowel Diseases*, 3rd ed. New York: Churchill Livingstone 1997: 107-116
- 4 Rembacken BJ, Newbould HE, Richards SJ, Misbah SA, Dixon ME, Chalmers DM, Axon AT. Granulocyte apheresis in inflammatory bowel disease: possible mechanisms of effect. *Ther Apher* 1998; **2**: 93-96
- 5 Shimoyama T, Sawada K, Tanaka T, Saito Y, Munakata A, Toyota T, Hiwatahi N, Kasukawa R, Ohara M, Asakura H, Honma T, Kimura K, Koizumi H, Saito Y, Suzuki Y, Nagamachi Y, Koitabashi H, Muto T, Nagawa H, Umeda N, Matsueda K, Hayashi N, Iizuka B, Baba S, Nakamura T, Nasu M, Murakami K, Sawada T, Kataoka T. Granulocyte and monocyte apheresis with the G-1 column in the treatment of patients with active ulcerative colitis. *Jpn J Apher* 1999; **18**: 117-131  
<http://www.adacolumn.com/index.htm>
- 6 Saniabadi AR, Hanai H, Takeuchi K, Umemura K, Nakashima M, Adachi T, Shima C, Bjarnason I, Lofberg R. Adacolumn, an adsorptive carrier based granulocyte and monocyte apheresis device for the treatment of inflammatory and refractory diseases associated with leukocytes. *Ther Apher Dial* 2003; **7**: 48-59  
<http://www.asahi-kasei.co.jp/medical/en/product/leukocytapheresis/cellsorba.htm>
- 7 Shimoyama T, Sawada K, Hiwatahi N, Sawada T, Matsueda K, Munakata A, Asakura H, Tanaka T, Kasukawa R, Kimura K, Suzuki Y, Nagamachi Y, Muto T, Nagawa H, Iizuka B, Baba S, Nasu M, Kataoka T, Kashiwagi N, Saniabadi AR. Safety and efficacy of granulocyte and monocyte adsorption apheresis in patients with active ulcerative colitis: a multicenter study. *J Clin Apher* 2001; **16**: 1-9
- 8 Tomomasa T, Kobayashi A, Kaneko H, Mika S, Maisawa S, Chino Y, Syou H, Yoden A, Fujino J, Tanikawa M, Yamashita T, Kimura S, Kanoh M, Sawada K, Morikawa A. Granulocyte adsorptive apheresis for pediatric patients with ulcerative colitis. *Dig Dis Sci* 2003; **48**: 750-754
- 9 Hanai H, Watanabe F, Takeuchi K, Iida T, Yamada M, Iwaoka Y, Saniabadi A, Matsushita I, Sato Y, Tozawa K, Arai H, Furuta T, Sugimoto K, Bjarnason I. Leukocyte adsorptive apheresis for the treatment of active ulcerative colitis: a prospective, uncontrolled, pilot study. *Clin Gastroenterol Hepatol* 2003; **1**: 28-35
- 10 Suzuki Y, Yoshimura N, Saniabadi AR, Saito Y. Selective granulocyte and monocyte adsorptive apheresis as a first-line treatment for steroid naive patients with active ulcerative colitis: a prospective uncontrolled study. *Dig Dis Sci* 2004; **49**: 565-571
- 11 Naganuma M, Funakoshi S, Sakuraba A, Takagi H, Inoue N, Ogata H, Iwao Y, Ishi H, Hibi T. Granulocytapheresis is useful as an alternative therapy in patients with steroid-refractory or -dependent ulcerative colitis. *Inflamm Bowel Dis* 2004; **10**: 251-257
- 12 Hanai H, Watanabe F, Yamada M, Sato Y, Takeuchi K, Iida T, Tozawa K, Tanaka T, Maruyama Y, Matsushita I, Iwaoka Y, Kikuch K, Saniabadi AR. Adsorptive granulocyte and monocyte apheresis versus prednisolone in patients with corticosteroid-dependent moderately severe ulcerative colitis. *Digestion* 2004; **70**: 36-44
- 13 Yamamoto T, Umegae S, Kitagawa T, Yasuda Y, Yamada Y, Takahashi D, Mukumoto M, Nishimura N, Yasue K, Matsumoto K. Granulocyte and monocyte adsorptive apheresis in the treatment of active distal ulcerative colitis: a prospective, pilot study. *Aliment Pharmacol Ther* 2004; **20**: 783-792
- 14 Domenech E, Hinojosa J, Esteve-Comas M, Gomollon F, Herrera JM, Bastida G, Obrador A, Ruiz R, Saro C, Gassull MA.

- Granulocyteapheresis in steroid-dependent inflammatory bowel disease: a prospective, open, pilot study. *Aliment Pharmacol Ther* 2004; **20**: 1347-1352
- 17 **Kanke K**, Nakano M, Hiraishi H, Terano A. Clinical evaluation of granulocyte/monocyte apheresis therapy for active ulcerative colitis. *Dig Liver Dis* 2004; **36**: 811-817
- 18 **Kim HJ**, Kim JS, Han DS, Yang SK, Hahm KB, Lee WI, Kwon SW, Choi JH, Kim WH, Choi KY, Song IS. Granulocyte and monocyte adsorption apheresis in Korean conventional treatment-refractory patients with active ulcerative colitis: a prospective open-label multicenter study. *Korean J Gastroenterol* 2005; **45**: 34-44
- 19 **Lichtiger S**, Present DH, Kornbluth A, Gelernt I, Bauer J, Galler G, Michelassi F, Hanauer S. Cyclosporine in severe ulcerative colitis refractory to steroid therapy. *N Engl J Med* 1994; **330**: 1841-1845
- 20 **Sutherland LR**, Martin F, Greer S, Robinson M, Greenberger N, Saibil F, Martin T, Sparr J, Prokipchuk E, Borgen L. 5-Aminosalicylic acid enema in the treatment of distal ulcerative colitis, proctosigmoiditis, and proctitis. *Gastroenterology* 1987; **92**: 1894-1898
- 21 **Seo M**, Okada M, Yao T, Ueki M, Arima S, Okumura M. An index of disease activity in patients with ulcerative colitis. *Am J Gastroenterol* 1992; **87**: 971-976
- 22 **Noguchi M**, Hiwatashi N, Hayakawa T, Toyota T. Leukocyte removal filter-passed lymphocytes produce large amounts of interleukin-4 in immunotherapy for inflammatory bowel disease: role of bystander suppression. *Ther Apher* 1998; **2**: 109-114
- 23 **Kashiwagi N**, Sugimura K, Koiwai H, Yamamoto H, Yoshikawa T, Saniabadi AR, Adachi M, Shimoyama T. Immunomodulatory effects of granulocyte and monocyte adsorption apheresis as a treatment for patients with ulcerative colitis. *Dig Dis Sci* 2002; **47**: 1334-1341
- 24 **Tsukada Y**, Nakamura T, Iimura M, Iizuka BE, Hayashi N. Cytokine profile in colonic mucosa of ulcerative colitis correlates with disease activity and response to granulocytapheresis. *Am J Gastroenterol* 2002; **97**: 2820-2828
- 25 **Takeda Y**, Hiraishi K, Takeda H, Shiobara N, Shibusawa H, Saniabadi AR, Adachi M, Kawata S. Cellulose acetate beads induce release of interleukin-1 receptor antagonist, but not tumour necrosis factor-alpha or interleukin-1beta in human peripheral blood. *Inflamm Res* 2003; **52**: 287-290
- 26 **Hiraishi K**, Takeda Y, Shiobara N, Shibusawa H, Jimma F, Kashiwagi N, Saniabadi AR, Adachi M. Studies on the mechanisms of leukocyte adhesion to cellulose acetate beads: an in vitro model to assess the efficacy of cellulose acetate carrier-based granulocyte and monocyte adsorptive apheresis. *Ther Apher Dial* 2003; **7**: 334-340
- 27 **Takeda Y**, Shiobara N, Saniabadi AR, Adachi M, Hiraishi K. Adhesion dependent release of hepatocyte growth factor and interleukin-1 receptor antagonist from human blood granulocytes and monocytes: evidence for the involvement of plasma IgG, complement C3 and beta2 integrin. *Inflamm Res* 2004; **53**: 277-283
- 28 **Hanai H**, Watanabe F, Yamada M, Sato Y, Takeuchi K, Iida T, Tozawa K, Tanaka T, Maruyama Y, Matsushita I, Iwaoka Y, Saniabadi A. Correlation of serum soluble TNF-alpha receptors I and II levels with disease activity in patients with ulcerative colitis. *Am J Gastroenterol* 2004; **99**: 1532-1538
- 29 **Andoh A**, Tsujikawa T, Inatomi O, Deguchi Y, Hata K, Kitoh K, Sasaki M, Mitsuyama K, Fujiyama Y. Suppression of inflammatory cytokine secretion by granulocyte/monocyte adsorptive apheresis in active ulcerative colitis. *Ther Apher Dial* 2005; **9**: 123-127
- 30 <http://www.clinicaltrials.gov/ct/gui/show/NCT00102193>
- 31 **Matsui T**, Nishimura T, Matake H, Ohta T, Sakurai T, Yao T. Granulocytapheresis for Crohn's disease: a report on seven refractory patients. *Am J Gastroenterol* 2003; **98**: 511-512
- 32 **Cuenca F**, Garcia Paredes J, Mendoza JL, Cruz DM, Herrero A, Diaz-Rubio M. Experience with granulocytapheresis in Crohn's disease. *Rev Esp Enferm Dig* 2004; **96**: 501-503, 504-506
- 33 **Kusaka T**, Fukunaga K, Ohnishi K, Kosaka T, Tomita T, Yokoyama Y, Sawada K, Fukuda Y, Miwa H, Matsumoto T. Adsorptive Monocyte-granulocytapheresis (M-GCAP) for refractory Crohn's disease. *J Clin Apher* 2004; **19**: 168-173
- 34 **Fukuda Y**, Matsui T, Suzuki Y, Kanke K, Matsumoto T, Takazoe M, Matsumoto T, Motoya S, Honma T, Sawada K, Yao T, Shimoyama T, Hibi T. Adsorptive granulocyte and monocyte apheresis for refractory Crohn's disease: an open multicenter prospective study. *J Gastroenterol* 2004; **39**: 1158-1164
- 35 **Truelove SC**, Jewell DP. Intensive intravenous regimen for severe attacks of ulcerative colitis. *Lancet* 1974; **1**: 1067-1070
- 36 **Hanauer SB**. Inflammatory bowel disease. *N Engl J Med* 1996; **334**: 841-848

S- Editor Guo SY L- Editor Elsevier HK E- Editor Bi L