

Advanced Developments in Neck Dissection Technique: Perspectives in Minimally Invasive Surgery

Jandee Lee and Woong Youn Chung
*Department of Surgery, Yonsei University College of Medicine
 South Korea*

1. Introduction

Over the last decade, surgeons have experienced dramatic changes in operative procedures as a result of the development of remarkable new technological tools that have enabled significant advances in minimally invasive surgical techniques and instruments. These advances have led to the increased application of minimally invasive techniques for “non-conventional” procedures. The potential benefits of minimally invasive surgery have included reduced levels of trauma to the tissues, decreased postoperative pain, reduced length of hospital stay, and better cosmetic outcomes. Various types of minimally invasive operative techniques have been introduced, including mini-incision, video-assisted, endoscopic, robotic, laparoendoscopic single-site surgery (LESS), and natural orifice trans-luminal endoscopic surgery (NOTESTM). In head and neck surgery, where vital structures are in close proximity to each other, and the operative field is a deep and narrow space, these minimally invasive approaches can be especially challenging. Minimally invasive surgery is not minimum surgery, and the principle of complete tumor resection must still be followed. Therefore, head and neck surgeons have often avoided minimally invasive techniques due to concerns about visualization, damage to vital structures, and limited availability of instruments specific to the delicate tasks required of the head and neck surgeon.

Minimally invasive neck surgery through totally endoscopic or video-assisted techniques, which are currently being used around the globe for thyroid and parathyroid surgeries, enables a smaller wound size or allows for the positioning of the wound in areas of cosmetic benefit. Since Michel Gagner first described endoscopic neck surgery in 1996, endoscopic procedures based on various approaches have been widely applied. In addition to minimized scarring and improved cosmetic results, the adoption of endoscopic procedures has offered several extra advantages, such as diminished postoperative hyperesthesia or paresthesia of the anterior neck and less patient discomfort during swallowing, which may sometimes result from the conventional transverse cervical incision. However even with these potential advantages, the technical limitations of endoscopic neck surgery, which are shared by many other types of minimally invasive surgery, have remained a significant consideration. The skills required in using straight, rigid endoscopic instruments without articulations and a two-dimensional (2D) view are radically different from those applied in

the 3D milieu of conventional surgery performed directly by the surgeon's expert hands. Furthermore, particularly in the head and neck area, the workspace during endoscopic surgery is narrow and restrictive. Although several minimally invasive techniques have been adopted in the attempt to avoid long cervical scars, purely endoscopic methods have been technically limited when procedures are complex.

In many fields, surgeons have introduced robotic techniques to minimally invasive procedures and have gradually overcome such limitations. The new da Vinci S surgical robot system (Intuitive, Inc., Sunnyvale, CA) is increasingly available, and because of the complexities of certain laparoscopic procedures, the extended capabilities offered by this robotic technology are gaining wide acceptance. The da Vinci S system allows operations to be performed more safely and meticulously than conventional endoscopic procedures by providing a 3D, magnified, and stable operative view. Head and neck surgeons have begun to incorporate surgical robotics in minimally invasive neck surgery to overcome the constraints observed during endoscopic surgery. In head and neck surgery, robotic techniques permit better visualization and a wider range of manipulations that can fit in a deep and narrow space. The authors have recently reported our initial experience with 33 patients who underwent modified radical neck dissection using robotic techniques. The results seem promising, with greater surgical scope and no serious complications.

In this chapter, we introduce the newly developed technologies in neck surgery and evaluate how some of these developments might improve surgical outcomes. These advanced technologies include the development of various endoscopic techniques, and the da Vinci robot surgical system.

2. Minimally invasive neck dissection

2.1 History of neck dissection

The first documented neck dissection was performed in 1888 by Franciszek Jawdyski, but the first description of neck dissection technique was presented by George Crile in 1906. Since then, neck dissection has evolved into a more refined set of procedures that allow for a greater degree of conservation and reduced morbidity. This modern technique, radical block dissection of all the deep lymphatic structures in the neck, has been described in detail (Rinaldo et al, 2008). Radical neck dissection in a series of 132 patients was found to have a mortality rate of 8% and a 3-year survival rate of 38% (Kazi, 2003); however 86 of these 132 patients underwent types of dissection that likely corresponded to modern selective neck dissections rather than en bloc radical neck dissection. Following a report showing the results of 665 operations in 599 patients by Martin et al. (1951), the technique of Martin, similar in most respects to that of Crile, became the standard "radical neck dissection", and for many years was considered the only truly curative procedure for regional lymph node disease in patients with head and neck cancer. This operation involved the removal of all lymphatic and non-lymphatic structures from the mandible to the clavicle and between the platysma and the prevertebral fascia, except for the carotid arteries; hypoglossal, lingual, vagus and phrenic nerves; and brachial plexus. The lateral boundary of the dissection was the anterior border of the trapezius muscle, and the medial border was the midline of the neck, superficial to the infrahyoid muscles, and the opposite digastric muscle superficial to the suprahyoid (mylohyoid) muscle (Ferlito et al, 2009). A standard selective neck dissection that spares the spinal accessory nerve was also described (Ward & Robben, 1951). At that time, the technique of neck dissection included the en-bloc resection of the spinal accessory

nerve, the jugular vein and the sternocleidomastoid muscle, and in some cases, the resection of the vagus nerve. This method, however, was not widely accepted until the 1980s, when studies comparing radical and modified radical neck dissections revealed similar oncologic results but more compromised function and greater shoulder pain for patients who underwent radical neck procedures. This change in extent of surgery had an important impact on elective neck dissection, maximizing the use of a preventive treatment that is less invasive but that does not diminish oncologic results (Kowalski & Sanabria, 2007).

2.2 Classification of neck dissection

2.2.1 Neck node nomenclature and classification

Over the past decade, the nomenclature and classification of neck dissection have not changed; if anything, they have become more simplified and standardized. According to the revised neck dissection classification proposed by the American Head and Neck Society and the American Academy of Otolaryngology–Head and Neck Surgery (AAO-HNS), the lymph nodes of the neck are divided into six levels (I–VI) (Robbins et al, 2001) (Table 1) (Figure 1).

In 2008, the Committee for Neck Dissection Classification of the AHNS prepared a contemporary revision, to keep classifications consistent with current practice (Robbins et al, 2008). Now that imaging modalities are used in staging the neck, radiologic landmarks are needed to define the boundaries between lymph node levels. This classification system, however, has given rise to several concerns (Ferlito et al, 2008). First, the boundary that separates sublevels IB and IIA is currently defined as the border of the stylohyoid muscle.

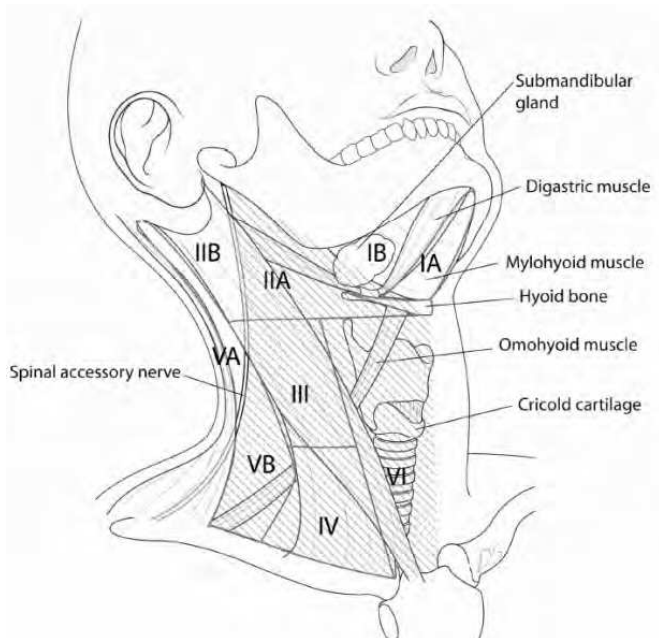


Fig. 1. Anatomic landmarks used to divide the lateral and central lymph node compartments into levels I–VI; the area with a peculiar fold line is where lymph node dissection is made during radical neck dissection (Kang et al, 2011).

Neck node level	Superior boundary	Inferior boundary	Anteromedial boundary	Posterolateral boundary
IA (submental)	Symphysis of mandible	Body of hyoid	Anterior belly of contralateral digastric muscle	Anterior belly of ipsilateral digastric muscle
IB (submandibular)	Body of mandible	Posterior belly of digastric muscle	Anterior belly of digastric muscle	Stylohyoid muscle
IIA (upper jugular)	Skull base	Horizontal plane defined by the inferior body of the hyoid bone	Stylohyoid muscle	Vertical plane defined by the spinal accessory nerve
IIB (upper jugular)	Skull base	Horizontal plane defined by the inferior body of the hyoid bone	Vertical plane defined by the spinal accessory nerve	Lateral border of the sternocleidomastoid muscle
III (middle jugular)	Horizontal plane defined by the inferior body of the hyoid bone	Horizontal plane defined by the inferior border of the cricoid cartilage	Lateral border of the sternohyoid muscle	Lateral border of the sternocleidomastoid muscle
IV (lower jugular)	Horizontal plane defined by the inferior border of the cricoid cartilage	Clavicle	Lateral border of the sternohyoid muscle	Lateral border of the sternocleidomastoid muscle
VA (posterior triangle)	Apex of convergence of the sternocleidomastoid and trapezius muscle	Horizontal plane defined by the inferior border of the cricoid cartilage	Posterior border of the sternocleidomastoid muscle	Anterior border of the trapezius muscle
VB (posterior triangle)	Horizontal plane defined by the inferior border of the cricoid cartilage	Clavicle	Posterior border of the sternocleidomastoid muscle	Anterior border of the trapezius muscle
VI (anterior compartment)	Hyoid bone	Suprasternal	Common carotid artery	Common carotid artery

Table 1. Lymph node nomenclature and classification in neck dissection (Robbins et al, 2002)

While this anatomical landmark can be recognized during neck dissection, it is difficult to determine during physical examination or on imaging modalities. Therefore, the Committee proposed that the border between levels I and II be the vertical plane defined by the

posterior edge of the submandibular gland, that the boundary between levels II and III be the hyoid bone, and the boundary between levels III and IV be the cricoid cartilage. Level VI is currently defined as lying below the body of the hyoid bone, above the top of the manubrium, and between the lateral borders of the sternohyoid muscles, which separate level VI from levels II and III. However, the sternohyoid muscles are not easy to define radiologically. Thus, the Committee proposed that the lateral borders of level VI be defined as the inner margins of the carotid arteries, which in most patients can be easily palpated as well as viewed radiologically (Ferlito et al, 2008).

According to the neck node classification of the AHNS, both lymph nodes of the superior mediastinum (often referred to as level VII) and lymph nodes outside the neck groupings (i.e. the retropharyngeal, periparotid, and buccinator nodes) are not included in this classification, but are designated by their specific group. Although the superior mediastinal lymph nodes have been referred to as “level VII,” the Neck Dissection Classification Committee of the AHNS does not recommend use of this term, as it defines a region outside the typical boundaries of the neck. The Committee has sought to prevent the establishment of new levels defining other lymph node groups, thus avoiding a more complex numbering system (Ferlito et al, 2008). However, the term level VII continues to be employed in many publications to represent the lymph nodes in the superior mediastinal group. Thus, the new Committee recommends that level VII refer to the extension of the chain of paratracheal nodes below the suprasternal notch (the dividing line between levels VI and VII) to the level of the innominate artery only. As an alternative to naming this group level VII, these nodes may be designated as “the superior mediastinal lymph nodes, above the level of the innominate artery.” This level is defined by the sternal notch superiorly and the innominate artery inferiorly, landmarks that are readily identifiable on imaging modalities. The Committee noted that nodes in level VII are usually accessible through the cervical incision. Mediastinal lymph nodes inferior to the innominate artery require sternotomy for access, and are not included in level VII (Robbins et al, 2008).

2.2.2 Neck dissection classification

The updated American Joint Committee on Cancer (AJCC) staging system has highlighted the significance of the biology of lymph node metastases and has refined selective neck dissection procedures by correlating surgical with radiologic landmarks, thus facilitating multidisciplinary cooperation among surgeons, radiologists and oncologists. The currently employed definitions of neck dissection terminology and definitions and indications for types of selective node dissection are shown in Table 2 (Ferlito et al, 2009).

Several types of neck dissection have been described. Radical neck dissection consists of levels I-V with the associated sternocleidomastoid muscle, jugular vein and spinal accessory nerve. Modified radical neck dissection consists of levels I-V without any of the aforementioned non-lymphatic structures. Selective neck dissection consists of any dissection that excludes one or more lymph node levels included in a radical neck dissection (i.e. levels II-IV). Extended neck dissection includes one or more additional lymph node groups or nonlymphatic structures in addition to those of a radical neck dissection, including periparotid lymph nodes and parotidectomy or superior mediastinal nodes and level VI.

The purpose of neck dissection may be therapeutic, to treat lymph node metastases found during a physical or imaging examination; opportune, when the approach for exposure and

Terminology	Extent of neck dissection
Radical neck dissection	Removal of lymph nodes levels I-V sternocleidomastoid muscle, spinal accessory nerve, and internal jugular vein.
Modified neck dissection	Removal of lymph nodes levels I-M (as in radical neck dissection), but preservation of at least one of the non-lymphatic structures (sternocleidomastoid muscle, spinal accessory nerve, and internal jugular vein). Each non-lymphatic structure that is removed should be named.
Selective neck dissection	Preservation of one or more lymph node levels relative to a radical neck dissection.
Extended neck dissection	Removal of an additional lymph node level or group or a non-lymphatic structure relative to a radical neck dissection (muscle, blood vessel, nerve). An example of other lymph node groups can be – superior mediastinal, parapharyngeal, retropharyngeal, peri-parotid, postauricular, suboccipital, or buccinators. An example of other non-lymphatic structure can be external carotid artery, hypoglossal or vagus nerves.

Table 2. Definitions of neck dissection (Ferlito et al, 2009)

resection of a malignant primary tumor is through the neck; or elective, when lymph node compromise is not found clinically or by imaging, but the risk of microscopic metastases is higher than the risk associated with an additional surgical procedure and its attendant morbidity. In principle, indications for neck dissection in oral cancer patients must include a risk-benefit analysis, balancing the probabilities of neck metastases, complications associated with neck dissection and the possible prognostic influence of late diagnosis of metastasis during follow-up. If the probability of neck metastases is high, neck dissection with its intrinsic morbidity has the same effect as therapeutic dissection, decreasing the risk of regional recurrence. However, if the probability of neck metastases is low or nil, neck dissection is an overtreatment, with morbidities arising from the neck procedure possibly resulting in a reduced quality of life and increased functional deficits. Although this risk-benefit analysis would yield better results if it were possible to predict the risk of neck metastases, this type of prediction is difficult to introduce and apply in clinical practice (Kowalski & Sanabria, 2007).

Due to the development of a variety of surgical procedures for managing regional disease in head and neck cancer, a system of classification has evolved. Once it was demonstrated that standard radical neck dissection was not necessary for effective management of cervical metastatic disease in all patients, the procedures were modified and the extent and location of dissection altered to conform to the proven or surmised lymph node levels at risk. This has resulted in a plethora of procedures that have become increasingly difficult to name and classify. The currently employed classification system has built on previous definitions of node levels and types of neck dissection. Nevertheless, the many permutations of possible levels and structures removed have made it difficult to describe the type of resection in each patient. This system, however, has the advantages of familiar terminology and definitions, thus facilitating its employment (Ferlito et al, 2009).

2.3 Distribution of neck metastasis from various primary sites and extent of neck dissection

Neck node metastasis is the most important prognostic factor in patients with several types of head and neck carcinoma, making the management of neck metastases in head and neck cancer one of the most important aspects of treatment. Although therapeutic neck dissection has been found to affect the prognosis of head and neck cancer patients, the role of elective neck dissection remains unclear. Of head and neck malignancies, oral cancer has been the most widely assessed using elective neck dissection. However, the amount and quality of information currently available cannot definitively determine the prognostic effects of elective neck dissection. Furthermore, the recent introduction of sentinel lymph node biopsy in the diagnosis and treatment of head and neck cancer has suggested that elective neck dissection may not be clinically useful (Kowalski & Sanabria, 2007).

The idea of removing individual node levels immediately draining the primary cancer site originated during the 19th century. Supraomohyoid neck dissection (node levels I-III) for oral and oropharyngeal cancer, jugular chain neck dissection (levels II-IV) for laryngeal cancer, and central compartment node dissection (level VI) for thyroid cancer were performed later, mostly in patients with clinically negative necks, but these procedures were considered to be of benefit mainly for staging purposes (Ferlito et al, 2009). The major therapeutic advance in the past two decades has been the refinement of the various selective neck dissections to achieve oncologic control and minimize morbidity. These selective dissections can be tailored to individual patients to some extent since there is now an awareness of the pattern of spread for each head and neck site. Table 3 summarizes the lymph node levels likely to be involved (and thus included in a selective dissection) based on site (Seethala et al, 2009).

Primary tumor site	Lymphatic drainage pattern
Oral cavity	Level I – III (sometimes IV)
Oropharynx, hypopharynx, larynx	Levels II-IV (IIA only for some Squamous cell carcinoma of larynx and hypopharynx)
Larynx with subglottic involvement	Levels IV-VI
Thyroid	Level VI (level II-V if level V is clinically +)

Table 3. Common drainage patterns for tumors of various head and neck sites (Robbins et al, 2002)

2.4 Minimally invasive neck dissection

2.4.1 Minimally invasive video-assisted neck dissection

There have been only a few reports on a minimally invasive approach for neck dissection. During thyroid surgery, modified radical neck dissection is usually performed through a large transverse incision (extended collar incision). In some patients, an additional McFee incision may be necessary to clear neck level II. Video assisted thyroidectomy therefore became a valid option for patients with thyroid nodules and low risk papillary thyroid carcinomas. In addition, video assisted central neck lymph node dissection was shown to be feasible in patients with papillary thyroid carcinoma (Bellantone et al, 2002), resulting in the development of a minimally invasive video-assisted lateral neck dissection approach

(VALNED) (Lombardi et al, 2007). This type of surgery begins by making a 4 cm cervical incision between the cricoid cartilage and sternal notch. A 30° endoscope (5 mm) is used for better vision and the operating field is exposed by retractors. Under visual control the neck dissection is performed with conventional instruments, although use of a harmonic scalpel is preferred. The mean number of nodes removed per side was 25. The cosmetic results of the 4 cm horizontal incision were superior to those of conventional approaches. Although VALNED is a safe and feasible technique, additional studies are needed to show that the completeness of resection is similar to that of conventional open approaches.

2.4.2 Endoscopic neck dissection

The outcomes of minimally invasive video assisted thyroidectomies have suggested that endoscopic techniques have advantages for other types of head and neck surgery. The relatively longer operation time using this approach is likely due to the narrower operative field and the presence of many vital structures in the neck. Although endoscopic operations were initially limited to regions with natural cavities such as the peritoneum and pleura, the use of endoscopic approaches for head and neck surgery has extended their indications to regions without a natural cavity. All validated methods try to reduce the extent of surgical trauma and its associated morbidity (Muenscher et al, 2011). The main reasons for the development of endoscopic neck surgery are the unpredictable risks of unsatisfactory cosmetic results. For patients with benign neck lesions, this would mean replacing one deformity with another. Further, use of endoscopic methods results in faster wound healing and reduced morbidity due to complications.

Ten endoscopic neck dissections on five human cadavers showed that the majority of neck lymph nodes could be removed by this approach (Dulguerov et al, 2001). Endoscopic selective neck dissection has been utilized in a porcine model (Terris et al, 2003), and endoscopic neck surgery with lymph node dissection has been performed on patients with thyroid neoplasms (Kitagawa et al, 2003; Miccoli & Materazzi, 2004). Gasless skin lifting techniques, approaching lateral neck levels during thyroidectomy, have also been performed (Kitagawa et al, 2003). The results of endoscopic lymph node excisions in patients with squamous cell carcinomas of the upper aerodigestive tract located at different sites (uvula, epiglottis and glottis), as well as those of endoscopic sentinel lymphadenectomy for diagnosis of the N0 neck, were presented in 2004 (Werner et al, 2004). It is unclear whether the N0 neck in surgically treated head and neck carcinomas should be accessed by neck dissection or regular clinical follow up, although an endoscopic approach may be an alternative to tracer uptake by sentinel lymph nodes. A small skin incision chosen for endoscopy may be extended for standard neck dissection. In this method, a rigid endoscope is introduced through a specially designed tube, allowing the labeled lymph node to be dissected after removing subcutaneous adipose tissue. The sentinel node concept combines endoscopic lymph node dissection with frozen section analysis to explore the N0 neck. Alternatively, an approach called stealth surgery can be used for transaxillary subcutaneous endoscopic excision of benign neck lesions (Dutta et al, 2008). This endoscopic method may reduce the degree of invasiveness frequently associated with sentinel lymphadenectomy. A recent editorial concluded that "It will take a lot of work before we know if endoscopic neck dissection is a good, oncologic operation, but the trip to learn such a truth should be interesting" (Richtsmeier, 2003). At present, however, this procedure has not achieved widespread acceptance in clinical practice (Ferlito et al, 2006).

2.4.3 Characteristics of endoscopic approaches for neck surgery

In general, it is important to distinguish between two approaches for neck dissection. In one, a pure endoscopic approach is used to insert ports and to achieve a working space correlating with visceral or non-visceral organs by insufflating gas/air. The instruments are inserted through special trocars. In the second, minimally invasive approach, such as video-assisted approaches, skin incisions are larger, and the working space is maintained by external retraction of the skin. In these approaches, the endoscope is a means to improve the view through a small opening. In both approaches, dissection is usually performed "conventionally", often by using a harmonic scalpel. All of these procedures are designed to reduce the extent of surgical trauma and morbidity and were established during surgery for complete removal of involved organs. However, there have been few descriptions of neck dissections and standard procedures have not yet been established.

Typically, neck lesions are removed through skin incisions. Some horizontal incisions may be made to blend with skin creases. However, other surgical scars on the face and neck may become hypertrophic or keloid scars, having a lifelong impact on patients. Endoscopic approaches may produce smaller scars, by making small incisions in areas easy to hide (e.g. the axilla). Video assisted or gasless axillary procedures still require larger skin incisions, but the retraction and improved overview provided by the endoscope can significantly reduce incision size, while allowing easy extension of these incisions in patients switched to open procedures. The major disadvantage of these techniques is prolonged operation time, which, however, can be shortened as surgeons become more experienced. Table 4 describes the advantages and disadvantages of endoscopic and video-assisted approaches with or without gas.

Gas insufflation technique	
Advantages	Smallest incisions (Ports) Best cosmetic results Shorter time in hospital
Disadvantages	Arterial injury Venous injury Embolism Pneumothorax Pneumomediastinum Subcutaneous emphysema Special training Special equipment Prolonged operation time
Gasless technique (flap retraction technique)	
Advantages	Single incisions Magnified operating field Good cosmetic results Short time in hospital Easy to convert approach Possibility use of microscope
Disadvantages	Limited tumor size Retraction affects wounds Prolonged operation time

Table 4. Advantages and disadvantages of various endoscopic techniques. (Muenscher et al, 2011)

Furthermore, endoscopic and minimally invasive/video assisted dissections require special instruments and are more costly and time consuming. Although complication rates are low after endoscopic neck surgery, several morbidities, such as injuries to arteries and veins, embolism, subcutaneous emphysema, pneumothorax and pneumomediastinum, were described in early reports on the use of these methods in thyroid surgery. Many of these complications, however, may have been due to gas insufflation to enhance working space. Moreover, as in any other type of endoscopic surgery, common surgical complications, such as nerve injury and wound infection, can occur. These complications depend on patient selection, especially since indications for minimally invasive approaches have not been determined. Conversion to open procedures is common in oncologic settings such as proven N+ status in patients with head and neck carcinomas. To date, there have been no prospective randomized clinical trials comparing open with endoscopic or video assisted surgery, especially regarding the extent of resection. Minimally invasive approaches are advantageous for patients with benign neck lesions, thyroid disease, and selective/sentinel lymph node dissections, due to better cosmetic results and shorter wound healing times. Surgeons tend to favor video assisted minimally invasive techniques or endoscopic surgery using a gasless transaxillary approach, creating the working space by retraction, because the gas filling procedures, especially at level IV, bear some risks (Muenscher et al, 2011).

2.5 Robot technique for head and neck cancer

The endoscopic technique represents a considerable technologic advance and has recently been applied to head and neck surgery. Several trials of endoscopic neck surgery plus radical node dissection in patients with head and neck as well as thyroid cancer have shown that the endoscopic approach to neck dissection eliminates the long cervical scar. Furthermore, to overcome displeasing cosmetic outcomes, several endoscopic approaches to neck dissection have been conducted using remote skin incision. However, endoscopic surgery is more demanding and requires more time than open surgery, primarily because of instrumental and anatomical limitations. The instruments used to perform these minimally invasive endoscopic surgeries have definite limitations such as a 2-dimensional flat monitor, rigid and straight endoscopic instruments, and no tactile sense. Endoscopic surgery is particularly problematic for complex and difficult procedures such as radical neck dissection for head and neck cancer, in keeping with the principles of oncologic safety. The da Vinci surgical robot system (Intuitive Surgical, Sunnyvale, CA, USA) was developed to overcome these limitations (Chung et al, 2011). This surgical robot system promises more precise, improved endoscopic techniques and enables compartment-oriented anatomical neck dissection. Moreover, the robotic technique for minimally invasive surgery has other advantages, including the increased dexterity of the instrumentation used. Use of the robot system in head and neck surgery eliminates some of the technical pitfalls and limitations of endoscopic surgery. Furthermore, advances in robotic techniques, such as a steady camera platform, a 3-dimensional magnified operative view, 7 degrees of freedom, scaled and tremor-filtered movements, and a multi-articulated endo-wrist, allow precise and complex endoscopic procedures to be performed. Accordingly, the meticulous and precise motions of modern robotic instruments have introduced new levels of technical safety and feasibility to robotic thyroidectomy.

We recently described 33 patients who underwent robotic modified radical neck dissection using a gasless transaxillary approach, and provided details of operative techniques and

short-term operative outcomes (Kang et al, 2011). To our knowledge, this was the first report of robotic radical neck dissection technique in head and neck surgery. We found that the short-term operative outcomes were satisfactory, with no serious postoperative complications. This technique allowed precise manipulation of robotic instruments and complete compartment-oriented dissection without injuring major vessels or nerves or compromising surgical oncologic principles. Moreover, esthetic outcomes were maximized by using a remote axillary incision site, allowing the incision scar in the axilla to be completely concealed when the arm is down in its natural position, with the small anterior chest wall incision scar becoming almost inconspicuous over time (see Figure 2 & 3).

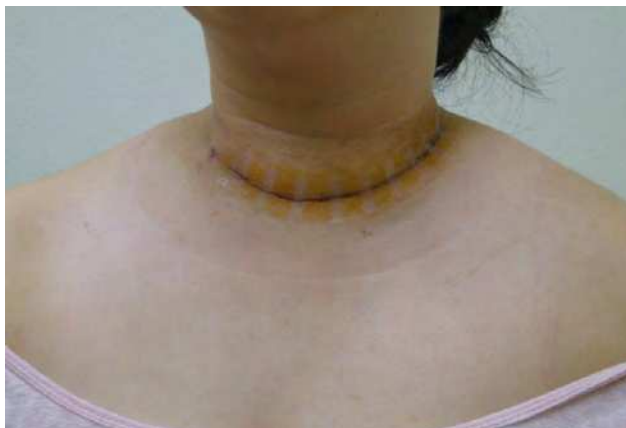

Fig. 2. Photograph of a postoperative scar with an extended long collar incision after conventional open modified radical neck dissection.

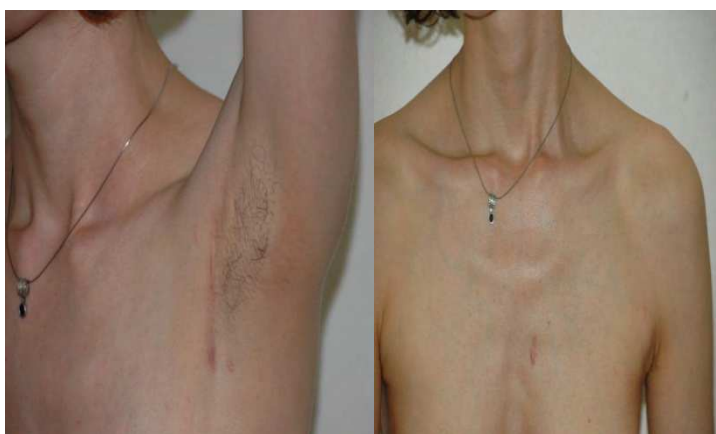

Fig. 3. Excellent cosmetic outcomes after robotic modified radical neck dissection. The long axillary scar is concealed when the patient's arm is by her side in the normal position, and most of the small anterior chest wall scar eventually becomes inconspicuous several months after the operation.

However, robotic neck dissection for patients with head-and-neck cancer remains at an early stage, and many unanswered questions remain; the benefits afforded by the technique require further evaluation.

2.6 Robotic neck dissection technique

In robotic modified radical neck dissection technique, the complete anatomical neck lymph node dissection, matching that of the open method, was found to be possible using excellent robotic instruments, such as magnified and 3-dimensional operative field, a stable camera platform, multi-articulated and tremor filtering system, and three accessible robotic arms. We briefly introduced our robotic modified radical neck dissection technique (Kang et al, 2011).

2.6.1 Operative set-up and creation of working space

With the patient in the supine positions and under general anesthesia, the neck is extended slightly by inserting a soft pillow under the shoulder and the face is turned away from the lesion. The lesion side arm is abducted to expose axilla and lateral neck, and the head is tilted and rotated to face the non-lesion side (Fig. 4).

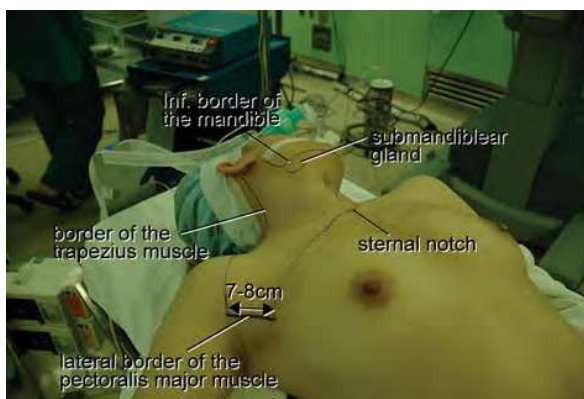

Fig. 4. Patient position for robotic modified radical neck dissection using a gasless transaxillary approach (Chung et al, 2011).

The landmarks for flap dissection are bounded by the sternal notch and the midline of the anterior neck medially, the anterior border of the trapezius muscle laterally, and the submandibular gland superiorly.

A 7-8cm vertical skin incision is placed in the axilla along the anterior axillary fold and the lateral border of the pectoralis major muscle. The subcutaneous flap from the axilla to the midline of the anterior neck is dissected over the anterior surface of the pectoralis major muscle and clavicle by electrical cautery under direct vision. After exposing the clavicle, subplatysmal flap dissection proceeds to the midline of the anterior neck medially, to the upper point where the external jugular vein and greater auricular nerve cross the lateral border of the sternocleidomastoid (SCM) muscle superiorly. The external jugular vein is ligated at the crossing point of the SCM muscle. Laterally the trapezius muscle is identified and dissected upwards along its anterior border. During the flap dissection in the posterior

neck area, the spinal accessory nerve is identified and exposed along its course. After subplatysmal flap dissection, the clavicular head of the SCM is divided at the level of its attachment to the clavicle to expose the junction area between the internal jugular vein and the subclavian vein), and the dissection proceeds upwards along with the posterior surface of the SCM to expose the submandibular gland and the posterior belly of the digastric muscle. After flap dissection, the patient's head is returned to the neutral position. A spatula-shaped wide external retractor (Chung's retractor) is then used to raise and tent the skin flap at the anterior chest wall, the SCM, and the strap muscles to create a working space. The entire neck levels (level IIa, III, IV, Vb, and VI areas) are fully exposed by elevating the SCM muscle and the strap muscles. A second skin incision (0.8cm long) is then made on the medial side of the anterior chest wall to allow the fourth robotic arm to be inserted (2cm superiorly and 6-8cm medially from the nipple) (Fig. 5).

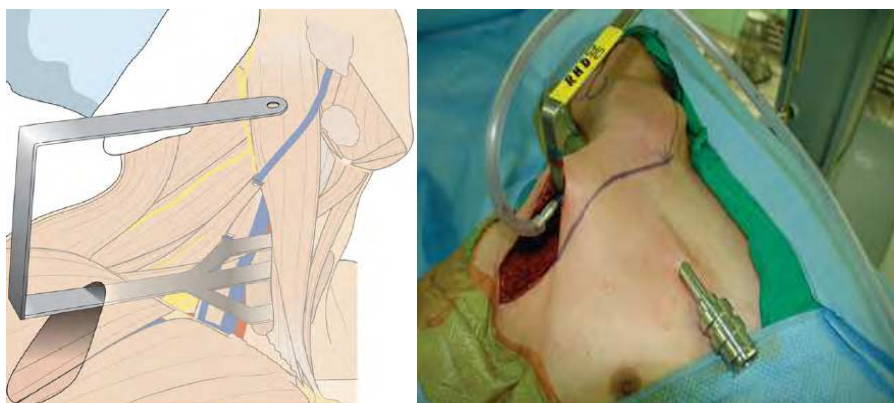


Fig. 5. Initial position of the external retractor during robotic modified radical neck dissection of levels III, IV, and Vb. The external retractor was placed between the thyroid and the strap muscle, with the direction of the blade from the axilla to the anterior neck (Kang et al, 2011).

2.6.2 Robot docking stage

The robotic column is placed on the lateral side of the patient contralateral to the main lesion, and the operative table is positioned slightly obliquely with respect to the direction of the robotic column to allow direct alignment between the axis of the robotic camera arm and the operative approach. Proper introduction angles are important to prevent collisions between robotic arms. Four robotic arms are used during the operation. Three arms are inserted through the axillary incision: a 30° degree dual channel camera is placed on the central camera arm through a 12-mm trocar. In particular, the camera arm should be placed in the center of the axillary skin incision. This arm is inserted to face upward. The 5-mm Maryland dissector is installed on the left side of the camera and the Harmonic curved shears on the right side through 8-mm trocar. A Prograsp forceps is placed on the fourth arm and inserted through the 8-mm anterior chest trocar. The Harmonic curved shear and the Maryland dissector arms should be inserted in the opposite manner to the camera arm (to face downward). Finally, the external three joints of the robotic arms should form an inverted triangle (Figure 6).

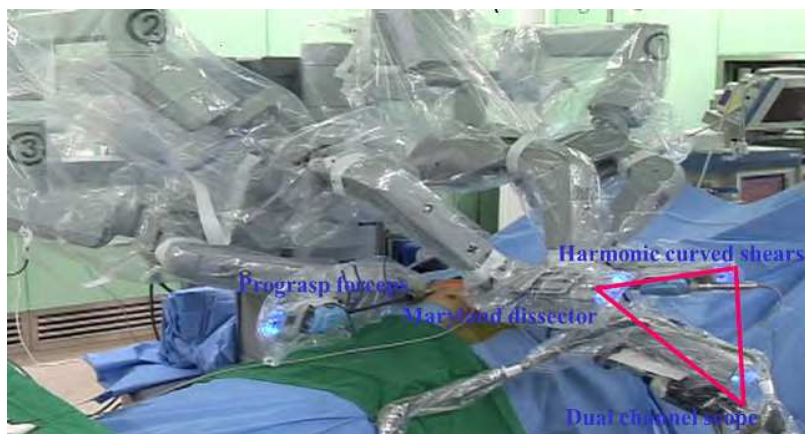

Fig. 6. Following the insertion of all robotic instruments through the axillary and anterior chest skin incisions, the three external joints of the robotic arms should form an inverted triangle.

2.6.3 Console stage

Actually, the robotic modified radical neck dissection procedure is similar to conventional open technique. Lateral neck dissection is initiated from the level III and IV area around the internal jugular vein (IJV). A careful dissection is needed during the detachment of the lymph node from the posterior aspect of the IJV to avoid injury to the common carotid artery and the vagus nerve. Smooth, sweeping, lateral movements of a Harmonic curved shears can establish a proper plane and allow vascular structures to be differentiated from specimen tissues. The dissection of the IJV is progressed upward from level IV to the upper level III area. During this procedure, the superior belly of the omohyoid muscle is cut at the thyroid cartilage level. Packets of LNs are then drawn superiorly using the ProGrasp forceps, and the LNs are meticulously detached from the junction of the IJV and subclavian vein. In general, the transverse cervical artery courses laterally across the anterior scalene muscle, anterior to the phrenic nerve. Using this anatomic landmark, the phrenic nerve and transverse cervical artery can be preserved without injury or ligation. Further dissection is followed along the subclavian vein laterally. The inferior belly of omohyoid muscle is cut where it meets the trapezius muscle. The distal external jugular vein is then clipped and divided at its connection with the subclavian vein. Level VB dissection in the posterior neck area proceeds along the spinal accessory nerve in the superomedial direction, and is followed by level IV dissection, while preserving the brachial nerve plexus, the phrenic nerve, and the thoracic duct. The dissection proceeds by making turns at levels VB, IV, and III, and then by proceeding upward to the level IIA area. The individual nerves of the cervical plexus are sensory nerves, and when encountered during dissection they are sacrificed to ensure complete node dissection, while preserving the phrenic nerve and ansa cervicalis.

After performing the level III, IV and VB node dissection, re-docking is needed for a better operating view to dissect the level II lymph node. The external retractor is then reinserted through the axillary incision and directed toward the submandibular gland (Fig 7).

The operating table should also be repositioned more obliquely with respect to the direction of the robotic column to allow the same alignment between the axis of the robotic camera arm and the direction of retractor blade insertion. Drawing the specimen tissue inferolaterally, soft tissues and LNs are detached from the lateral border of the sternohyoid

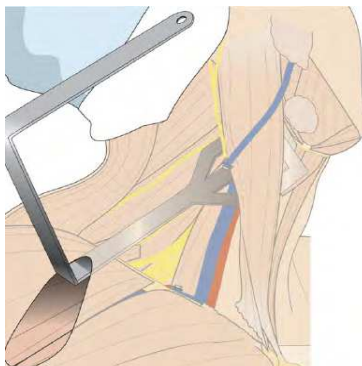


Fig. 7. Re-positioning of the external retractor during robotic modified radical neck dissection. For level II dissection, the blade of the external retractor is re-inserted toward the submandibular gland. (Kang et al, 2011).

muscle, the submandibular gland, and the anterior surfaces of the carotid artery and the IJV. Level IIA dissection is advanced until the posterior belly of the digastric muscle is exposed superiorly. After removing the specimen, fibrin glue is sprayed around the area of the thoracic duct and minor lymphatics, and a 3-mm closed suction drain is inserted just under the axillary skin incision. Wounds are closed cosmetically. The incision scar in the axilla is completely covered when the arm is in its neutral position.

3. Conclusion

A long journey has been traversed from the initial studies of lymphatic drainage of the neck, to determination of effective surgical extent and the development of effective surgical techniques for managing cervical nodal metastases in patients with head and neck cancers. Various neck dissection techniques have been utilized as a fundamental tool in the management of patients with head and neck cancer. The recently developed advanced robotic technique in head and neck surgery has been shown to be both safe and feasible in selected patients, yielding excellent cosmetic outcomes. Moreover, this technique may facilitate radical neck dissection during surgery for thyroid cancer. However, use of a robot for neck dissection of patients with head-and-neck cancer remains at an early stage, and prospective randomized studies are required to evaluate the real benefits afforded by this technique.

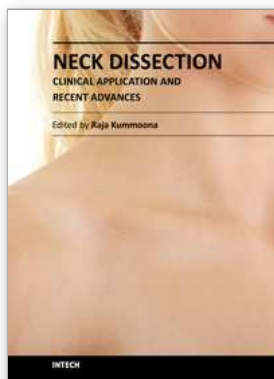
4. Acknowledgment

All authors including Drs. Lee, and Chung have no conflicts of interest or financial ties to disclose.

5. References

- Bellantone, R.; Lombardi, CP. & Raffaelli, M. (2002) Central neck lymph node removal during minimally invasive video-assisted thyroidectomy for thyroid carcinoma: a feasible and safe procedure. *J Laproendosc Adv Surg Tech A*, Vol.12, No.3, pp. 181-185
- Chung, WY. (2011) The evolution of robotic thyroidectomy: from inception to neck dissection. *J Robotic Surg*, Vol.5 pp.17-23

- Dulquerov, P.; Leuchter, I. & Szalay-Quinodoz, I. (2001) Endoscopic neck dissection in human cadavers. *Laryngoscope*, Vol.111, No.12, pp.2135-2139
- Dutta, S.; Slater, B. & Butler M. (2008) "Stealth surgery": transaxillary subcutaneous endoscopic excision of benign neck lesions. *J Pediatr Surg*, Vol.43, No.11, pp.2070-2074
- Ferlito, A.; Rinaldo, A. & Siver, CE. (2006) Neck dissection: then and now. *Auris Nasus Larynx*, Vol.33, No.4, pp.365-374
- Ferlito, A.; Siver, CE. & Rinaldo, A. (2008) Neck dissection: present and future? *Eur Arch Otorhinolaryngol*, Vol.265, No.6, pp.621-626
- Ferlito, A.; Robbins, KT. & Silver, CE. (2009) Classification of neck dissections: an evolving sytem. *Auris Nasus Larynx*, Vol.36, No.2, pp.127-134
- Kang, SW.; Lee, SH. & Ryu, HR. (2010) Initial experience with robot-assisted modified radical neck dissection for the management of thyroid carcinoma with lateral neck node metastasis. *Surgery*, Vol.148, No.6, pp.1214-1221
- Kazi, RA. (2003) The life and times of George Washinton Crile. *J Postgrad Med*, Vol.49, pp.289-290
- Kitagawa, W.; Shimizu, K. & Akasu, H. (2003) Endoscopic neck surgery with lymph node dissection for papillary carcinoma of the thyroid using a totally gasless anterior neck skin lifting method, *J Am Coll Surg*, Vol.196, No.6, pp.990-994
- Kowalski, LP. & Sanabria, A. (2007) Elective neck dissection in oral carcinoma: a critical review of the evidence. *Acta Otorhinolaryngol Ital*, Vol.27, No.3, pp.113-117
- Lombardi, CP.; Raffaelli, M. & Princi, P. (2007) Minimally invasive video-assisted functional lateral neck dissection for metastatic papillary thyroid carcinoma. *Am J Surg*, Vol.193, No.1, pp. 114-118
- Martin, H; Del Valle, B. & Ehrlich, H. (1951) Neck dissection. *Cancer*, Vol.4, No.3, pp.441-499
- Miccoli, P. & Materazzi G. (2004) Update on endoscopic cervical surgery. *Semin Laparosc Surg*, Vol.11, No.3, pp.139-145
- Muenschler, A.; Dalchow, C. & Kutta, H. (2011) The endoscopic approach to the neck: a review of the literature, and overview of the various techniques. *Surg Endosc*, Vol.25, No.5, pp.1358-1363
- Richtsmeier, WJ. (2003) Dissecting the "endoscopic neck". *Arch Otolaryngol Head Neck Surg*, Vol.129, No.6, pp.612
- Rinaldo, A.; Ferlito, A. & Silver, CE. (2008) Early history of neck dissection. *Eur Arch Otorhinolaryngol*, Vol.265, No.12, pp.1535-1538
- Robbins, KT.; Clayman, G. & Levine, PA. (2002) Neck dissection classification update: revisions proposed by the American Head and Neck Society and the American Academy of Otolaryngology-Head and Neck Surgery. *Arch Otolaryngol Head neck Surg*, Vol.128, No.7, pp.751-758
- Robbins, KT; Shaha, AR. & Medina, JE. (2008) Consensus statement on the classification and terminology of neck dissection. *Arch Otolaryngol Head Neck Surg*, Vol.134, No.5, pp.536-538
- Seethala, RR. (2009) Current state of neck dissection in the United States. *Am J Surg Pathol*, Vol.34, No.8, pp.1106-1121
- Terris, DJ.; Monfared, A. & Thomas, A. (2003) Endoscopic selective neck dissection in a porcine model. *Arch Otolaryngol Head Neck Surg*, Vol.129, No.6, pp.613-617
- Ward, GE. & Robben, JO. (1951) A composite operation for radical neck dissection and removal of cancer of the mouth. *Cancer*, Vol.4, No.1, pp.98-109
- Werner, JA.; Sapundzhiev, NR. & Teymoortash, A. (2004) Endoscopic sentinel lymphadenectomy as a new diagnostic approach in the N0 neck. *Eur Arch Otorhinolaryngol*, Vol.261, No.9, pp.463-468



Neck Dissection - Clinical Application and Recent Advances

Edited by Prof. Raja Kummoona

ISBN 978-953-51-0104-8

Hard cover, 164 pages

Publisher InTech

Published online 22, February, 2012

Published in print edition February, 2012

Neck Dissection - Clinical Application and Recent Advances is a leading book in neck surgery and represents the recent work and experiences of a number of top international scientists. The book covers all techniques of neck dissection and the most recent advances in neck dissection by advocating better access to all techniques of neck dissection; e.g. Robotic surgery (de Venice) system, a technique for detection of lymph node metastasis by ultra sonography and CT scan, and a technique of therapeutic selective neck dissection in multidisciplinary treatment. This book is essential to any surgeon specializing or practicing neck surgery, including Head Neck Surgeons, Maxillofacial Surgeons, ENT Surgeons, Plastic and Reconstructive Surgeons, Craniofacial Surgeons and also to all postgraduate Medical & Dental candidates in the field.

How to reference

In order to correctly reference this scholarly work, feel free to copy and paste the following:

Jandee Lee and Woong Youn Chung (2012). Advanced Developments in Neck Dissection Technique: Perspectives in Minimally Invasive Surgery, Neck Dissection - Clinical Application and Recent Advances, Prof. Raja Kummoona (Ed.), ISBN: 978-953-51-0104-8, InTech, Available from:
<http://www.intechopen.com/books/neck-dissection-clinical-application-and-recent-advances/advanced-developments-in-neck-dissection-technique-perspectives-in-minimally-invasive-surgery>

INTech

open science | open minds

InTech Europe

University Campus STeP Ri
Slavka Krautzeka 83/A
51000 Rijeka, Croatia
Phone: +385 (51) 770 447
Fax: +385 (51) 686 166
www.intechopen.com

InTech China

Unit 405, Office Block, Hotel Equatorial Shanghai
No.65, Yan An Road (West), Shanghai, 200040, China
中国上海市延安西路65号上海国际贵都大饭店办公楼405单元
Phone: +86-21-62489820
Fax: +86-21-62489821

© 2012 The Author(s). Licensee IntechOpen. This is an open access article distributed under the terms of the [Creative Commons Attribution 3.0 License](#), which permits unrestricted use, distribution, and reproduction in any medium, provided the original work is properly cited.