

Phantom-limb pain: characteristics, causes, and treatment

Herta Flor

Phantom-limb pain is a common sequela of amputation, occurring in up to 80% of people who undergo the procedure. It must be differentiated from non-painful phantom phenomena, residual-limb pain, and non-painful residual-limb phenomena. Central changes seem to be a major determinant of phantom-limb pain; however, peripheral and psychological factors may contribute to it. A comprehensive model of phantom-limb pain is presented that assigns major roles to pain occurring before the amputation and to central as well as peripheral changes related to it. So far, few mechanism-based treatments for phantom-limb pain have been proposed. Most published reports are based on anecdotal evidence. Interventions targeting central changes seem promising. The prevention of phantom-limb pain by peripheral analgesia has not yielded consistent results. Additional measures that reverse or prevent the formation of central memory processes might be more effective.

Lancet Neurology 2002; 1: 182–89

The amputation of a limb is commonly followed by the sensation that the deafferented body part is still present. These non-painful phantom sensations may include a specific position, shape, or movement of the phantom, feelings of warmth or cold, itching, tingling, or electric sensations, and other paraesthesias.¹ Pain in the body part that is no longer present occurs in 50–80% of all amputees.² The term phantom-limb pain was coined for this sensation by Mitchell in 1872.³ Ambroise Paré had postulated in 1552 that peripheral factors as well as a central pain memory might be causing phantom-limb pain and was the first to describe the phenomenon.⁴ Pain may be related to a certain position or movement of the phantom and may be elicited or exacerbated by a range of physical factors (eg, changes in weather or pressure on the residual limb) and psychological factors (eg, emotional stress). It seems to be more intense in the distal portions of the phantom and can have several different qualities, such as stabbing, throbbing, burning, or cramping. Although older studies cited smaller prevalence rates, they probably did not assess the true occurrence of the sensation, because patients can be reluctant to admit pain in a part of the body that is no longer present for fear of being thought mentally disturbed.

Phantom-limb pain is commonly confused with pain in the area adjacent to the amputated body part.⁵ Such pain is referred to as residual-limb or stump pain, and it is positively associated with phantom-limb pain in most cases.⁶ The residual limb may also be the site of non-painful

phenomena, such as tingling, itching, cramping, or involuntary movements. Furthermore, post-amputation pain at the site of the wound must be distinguished from pain in the residual limb and in the phantom limb, which may all occur together in the early phase after amputation. Finally, assessment of acute and chronic pain before amputation may be useful; these symptoms are related to the frequency, type, and severity of phantom-limb pain in the phase after amputation in varying proportions of the amputee population.⁷

Clinical characteristics

Phantom-limb pain is commonly classified as neuropathic, and it is assumed to be related to damage of central or peripheral neurons. Although such pain is most common after the amputation of an arm or leg, it can also occur after the surgical removal of other body parts such as breast, rectum, penis, testicles, eye, tongue, or teeth. Lesions of the peripheral nerves or the central nervous system (eg, brachial-plexus avulsion or paraplegia) can also cause phantom-limb pain. It seems to be more likely if the individual had chronic pain before the amputation and is less likely if the amputation was done when the individual was very young. Older children have been reported to have a high frequency of phantom-limb pain,^{8,9} but studies based on questionnaire data are especially difficult in children. Although phantom sensations seem to occur in individuals born without a limb, pain in the missing limb seems to be very rare in these circumstances.^{10,11} The long-term course of phantom-limb pain is unclear. Some researchers have reported a slight decline in the proportion of patients affected over the course of several years after surgery,⁷ but others have described high rates also in long-term amputees.¹ Commonly, the pain in the phantom is similar to the pain felt in the limb before amputation.^{7,12} The reported proportion ranges from 10% to 79%,^{7,12} depending on the type and time of assessment. As Nikolajsen and colleagues have pointed out,¹³ the type of assessment and potential errors in retrospective reports are important determinants of the frequency of these “pain memories”. There have been some reports that phantom-limb pain is more frequent in

HF is at the Department of Clinical and Cognitive Neuroscience, University of Heidelberg, Central Institute of Mental Health, Mannheim, Germany.

Correspondence: Prof Herta Flor, Department of Clinical and Cognitive Neuroscience, University of Heidelberg, Central Institute of Mental Health, J5, D-68159 Mannheim, Germany.
Tel +49 621 170322; fax +49 621 1703932;
email flor@zi-mannheim.de

female than male amputees, but other studies did not confirm these findings.^{11,14} The small sample sizes of some studies preclude the detection of significant differences between groups.

About 30% of people with amputations report the feeling of telescoping—ie, the retraction of the phantom towards the residual limb and in many cases the disappearance of the phantom into the limb, which may be accompanied by a shrinking of the limb. Telescoping was long assumed to be an adaptive process negatively associated with phantom-limb pain, and as such an expression of changes in the central nervous system that were beneficial.^{15,16} However, recent evidence suggests that central changes, phantom-limb pain, and telescoping are positively related^{6,17}—ie, that telescoping is associated with more rather than less phantom-limb pain. Many patients with phantom-limb pain also report sensations that are referred to the phantom when skin areas adjacent to, but also far removed from, the amputated limb are stimulated, with a point-to-point correspondence between stimulation sites and sensations in the phantom.¹⁸ However, in most cases, referred sensations lack this topographic correspondence.^{17,19} Previous studies have also reported increased perceptual acuity of the residual limb as assessed by two-point discrimination, and lower perception and pain thresholds than in the contralateral limb.²⁰ These changes in sensory perception were also thought to be positively related to the feeling of telescoping. More recent studies, however, could not confirm this relation and have questioned the assumption that stump perceptual acuity is a correlate of central changes related to the experience of a phantom.^{17,21}

Aetiology of phantom-limb pain

Both peripheral and central factors have been discussed as determinants of phantom-limb pain. Psychological factors do not seem to contribute to the causation but may instead affect the course and the severity of the pain.^{5,22} The general view now is that many changes along the neuraxis contribute to the experience of phantom-limb pain.

Central factors

Anecdotal evidence in human amputees suggests that spinal mechanisms have a role in phantom-limb pain. For example, during spinal anaesthesia, phantom pains have been reported by patients who have never experienced phantom pain.² Experimental data in human amputees are lacking, however, and most of the evidence in animals is based on models of partial nerve injury. Increased activity of peripheral nociceptors leads to a permanent change in the synaptic structure of the dorsal horn in the spinal cord, a process called central sensitisation.²³ This process is characterised by increased excitability of the dorsal-horn neurons, reduction of inhibitory processes, and structural changes at the central nerve endings of the primary sensory neurons, the interneurons, and the projection neurons. This central sensitisation is mediated by the NMDA receptor and its transmitter glutamate.²⁴ Possible mechanisms are that low-threshold afferents become functionally connected to ascending spinal projection neurons that carry nociceptive

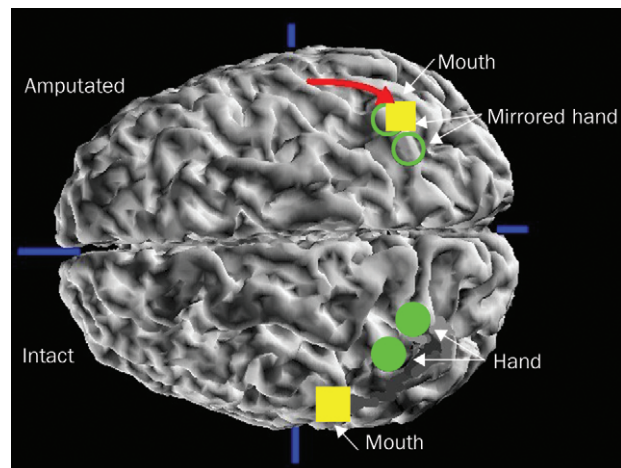


Figure 1. Assessment of reorganisation of the primary somatosensory cortex in an individual with amputation of the arm and phantom-limb pain. Neuromagnetic source imaging was used to define the localisation of the hand and mouth regions on the cortical hemisphere contralateral to the intact side and of the mouth region on the hemisphere contralateral to the amputation side. Magnetic fields evoked by pneumatic stimulation of the fingers of the intact side and the corner of the mouth on both sides were integrated with structural magnetic resonance images. The localisation of the intact hand was then transposed to the side contralateral to the amputation (with the assumption of a symmetrical localisation of the somatosensory homunculus) to assess where the former hand region was localised. The mouth representation on the amputated side has completely invaded the hand region. The amount of shift can be identified by calculating the Euclidean distance between the mouth and the hand region. The larger this distance (red arrow) the greater the cortical reorganisation.

information, or inhibitory interneurons may be destroyed by rapid discharge from injured tissue leading to a hyperexcitable spinal cord. Peripheral-nerve injury can lead to degeneration of C-fibre terminals in lamina II, which may induce sprouting of A-fibre terminals into this area, where they are normally not represented (they normally terminate in laminae III and IV).²⁵ The incoming A-fibre input might then be interpreted as noxious and could be the anatomical substrate of allodynia. The loss of input related to deafferentation might also lead to a general disinhibition of the spinal cord with a reduction in GABAergic activity and a downregulation of opioid receptors. In addition, cholecystokinin, an endogenous inhibitor of the opioid receptor, is upregulated in injured tissue.²⁶ A mechanism of special relevance to phantom phenomena may be the invasion of regions of the spinal cord where the deafferented limb was previously represented. In nerve-constriction injury, a commonly used animal model for neuropathic pain, expansion of receptive fields and a shift in activity from adjacent neurons into the deafferented zone have been observed.²⁷ These processes may be due to unmasking of previously silent connections or the sprouting of new connections. A further observed mechanism is a “phenotypic switch” in the expression of neuropeptides (such as substance P). They are normally expressed by nociceptor primary afferent A δ and C fibres but become expressed by A β fibres after peripheral-nerve injury. Thus, A β afferents can create the hyperexcitability of the spinal cord that is usually associated with noxious input.²⁶

Supraspinal changes related to phantom-limb pain involve the brainstem, the thalamus, and the cortex.²⁸ Melzack²⁹ suggested that there is a neuromatrix—ie, a network of neurons in several brain areas including the thalamus and somatosensory cortex, the reticular formation, the limbic system, and the posterior parietal cortex—that are the anatomical substrate of the self. The output from this system forms a neurosignature, which is specific for an individual and provides information about the body and its sensations. This neuromatrix is thought to be genetically determined but also modified by experience. An amputation would create abnormal input into the neuromatrix owing to a lack of normal sensory activity or overactivity related to the abnormal firing pattern of damaged nerves. This input would lead to an altered neurosignature and the experience of a phantom. The neuromatrix theory is difficult to test because it involves many brain areas and is not specific. It also does not explain why some individuals with amputations develop phantom-limb pain whereas others remain free of pain. Nevertheless, the brain areas cited as part of the neuromatrix are importantly involved in the experience of phantom limbs and phantom-limb pain.

New insights into phantom-limb pain have come from studies that showed changes in the functional and structural architecture of primary somatosensory cortex after amputation and deafferentation in adult monkeys. Changes in the sensory and motor maps were previously thought to occur only during a limited time during the development of the organism. In these studies, the amputation of digits of an adult owl monkey led to an invasion of adjacent areas into the representation zone of the deafferented fingers.³⁰ Whereas this type of reorganisational change spanned a distance of several millimetres, recordings from the somatosensory cortex of monkeys who had undergone dorsal rhizotomy 12 years earlier showed reorganisational changes (invasion of the mouth and chin area into the deafferented arm and hand area) on a scale of several centimetres.³¹ Subsequently, Ramachandran and co-workers¹⁸ noted that, in people with arm or hand amputations, sensations in the phantom could be elicited by stimulating the face ipsilateral to the amputation with a point-to-point correspondence between stimulation sites on the face and phantom sensations. They postulated that reorganisation of the somatosensory cortex might be the basis of this process. Several imaging studies^{18,32,33} have reported that people with arm or hand amputations actually show a shift of the mouth into the hand representation in primary somatosensory cortex (figure 1). We provided evidence that these cortical changes are related less to referred sensations but have a close association with phantom-limb pain.³² The larger the shift of the mouth representation into the zone that formerly represented the amputated hand and arm, the greater the phantom-limb pain.

These cortical changes can be reversed by the elimination of peripheral input from the amputation stump by means of brachial-plexus anaesthesia. Peripheral anaesthesia completely eliminated cortical reorganisation and phantom-limb pain in three of six patients in one study;

in the remaining three, both cortical reorganisation and phantom-limb pain remained unchanged.³³ This result suggests that in some individuals cortical reorganisation and phantom-limb pain may be maintained by peripheral input, whereas in others central, possibly intracortical, changes seem to be more important. The extent to which spinal changes contribute to these supraspinal alterations is so far not known. Axonal sprouting in the cortex underlies the reorganisational changes observed in amputated monkeys,³⁴ whereas thalamic reorganisation occurs after lesions close to the dorsal horn and is then relayed to the cortex.³⁵ This type of cortical reorganisation is present in both the somatosensory and the motor cortex.^{36,37} For example, lip movements led to activation of the area where the amputated hand and arm were formerly represented in patients with phantom-limb pain but not in amputees without pain (figure 2). However, reorganisation of the motor system was limited to the cortex; spinal changes were not observed.³⁸

Thalamic stimulation and recordings in human amputees have shown that reorganisational changes also occur at the thalamic level and are closely related to the perception of phantom limbs and phantom-limb pain.³⁹ Studies in animals have shown that these changes can be relayed from the spinal and brainstem level,²⁸ but changes on the subcortical levels may also originate in the cortex, which has strong efferent connections to the thalamus and lower structures.⁴⁰

Peripheral factors

Peripheral changes, such as nociceptive input from the residual limb, have been viewed as an important determinant of phantom-limb pain. This idea is supported by the moderately high correlation between residual-limb and phantom-limb pain. Ectopic discharge from a stump neuroma has been postulated as one important peripheral mechanism.⁴¹ When peripheral nerves are cut or injured, regenerative sprouting of the injured axon occurs. In this process, a neuroma in the residual limb may be formed—ie, enlarged and disorganised endings of C fibres and demyelinated A fibres that show an increased rate of spontaneous activity. Mechanical and chemical stimulation

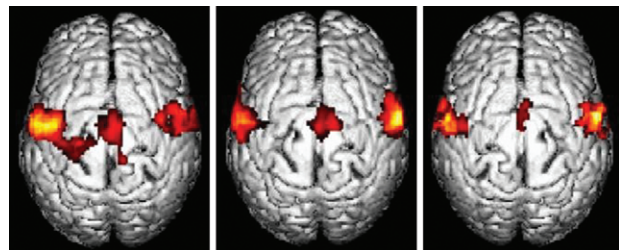


Figure 2. Reorganisation in primary somatosensory and motor cortex in patients who had had unilateral arm amputation with phantom-limb pain (left) and without phantom-limb pain (middle), and in a healthy control. The participants had to pucker their lips at a metronome-paced speed while functional magnetic resonance images were taken. Only in amputees with phantom-limb pain did a shift of the mouth representation into the hand representation occur; those without pain and the healthy control do not display a similar shift.

further increase the rate of discharge, which seems to be mainly related to ectopia (neuronal discharge that is generated along the axon or in the soma). These ectopic discharges have been related to stimulation of the stump (by pressure or cold), but they can also occur spontaneously as a consequence of nerve injury and seem to be a result of the upregulation or novel expression of sodium channels.⁴² In addition, non-functional connections between axons (ephapses) may contribute to this spontaneous activity. However, phantom-limb pain is present in many patients immediately after amputation before a neuroma could have formed. Moreover, local anaesthesia of the stump does not eliminate phantom-limb pain in all cases.³³

Computer models of deafferentation and related processes have suggested that peripheral factors can increase central reorganisation of neuronal networks. Thus, abnormal noise-like input that might originate from a neuroma in the residual limb greatly increases the amount of central map reorganisation,⁴³ thus indicating that peripheral and central factors may interact to create the experience of phantom-limb pain.

A further site of ectopic discharge may be the dorsal root ganglion (DRG). Ectopia in the DRG can amplify discharge coming from the residual limb or can lead to cross-excitation and instigate the depolarisation of neighbouring neurons.⁴⁴ In human beings, an anaesthetic block of a neuroma eliminated nerve activity related to the stimulation of the stump but not spontaneous activity, which may be originating in the DRG (figure 3).⁴⁵ Sympathetic discharge, which can also be caused by emotional distress, may lead to increased amounts of circulating epinephrine, which can trigger and exacerbate neuronal activity from neuroma.⁴⁶ If a phantom-pain-eliciting neuroma develops, the pain depends on the nerve that is involved, where it was cut, and the state of the neuron after injury. In addition, factors such as temperature, oxygenation, and local inflammation may have roles.⁴⁵ There is also evidence for genetic factors in the predisposition to neuropathic pain. For example, Seltzer and colleagues⁴⁷ suggested several candidate genes on chromosome 15 that could be involved in the autotomy that follows peripheral neurectomy in rodents, which has long been considered a valid animal model for phantom-limb pain.⁴⁸ In human beings, however, anecdotal evidence from a family of amputees showed very diverse phantom phenomena despite a close familial relationship.⁴⁹

The role of the sympathetic nervous system in animal models of neuropathic pain such as constriction injury or autotomy has been well documented,⁴⁴ but research on its role in phantom-limb pain is scarce. The mechanisms that have been discussed are sympathetically triggered ephaptic transmission, sympathetic activation of nociceptors, and activation of low-threshold mechanoreceptors that trigger sensitised spinal-cord neurons. In addition to sympathetic-sensory coupling in the periphery (neuroma), sympathetic-sensory coupling also occurs at the DRG.

The sympathetic maintenance of some types of phantom-limb pain has been supported by evidence that β -adrenergic blocking agents or temporary or surgical blockade of sympathetic activation can reduce phantom-

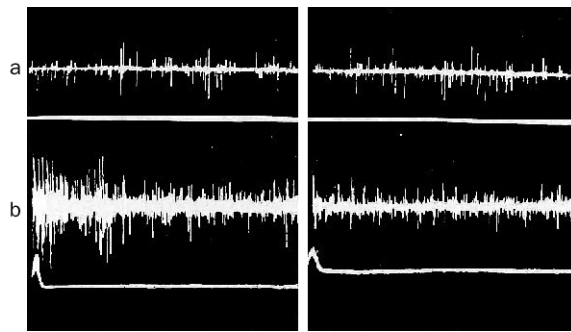


Figure 3. A microelectrode recording from a skin nerve fascicle (in the median nerve at the wrist) in a patient with phantom pain in the hand and fingers after hand amputation. Taps on the stump neuroma could increase phantom pain. (a) shows spontaneous impulse activity in the nerve fascicle before (left) and after (right) lidocaine block. Spontaneous phantom-limb pain was also uninfluenced. (b) shows the effects of lidocaine on neural impulses evoked by taps on the neuroma before (left) and after (right) lidocaine block. Both tap-evoked activity and the associated increase in phantom pain were eliminated after the block (right). Reproduced with the permission of Elsevier Science.⁴⁵

limb pain. Injections of epinephrine lead to an increase in phantom-limb pain and paraesthesias in some amputees.⁵⁰

Although sympathetically maintained pain does not necessarily covary with regional sympathetic abnormalities, sympathetic dysregulation in the residual limb is apparent in some patients. Reduced near-surface blood flow to a limb has been implicated as a predictive physiological correlate of burning phantom-limb pain.⁵¹ Onset and intensity of cramping and squeezing descriptions of phantom pain have been related to muscle tension in the residual limb. Changes in surface electromyographic representations of muscle tension in the residual limb precede changes in cramping and squeezing phantom pain by up to a few seconds.⁵² This relation seems not to hold for any other descriptions of phantom pain.

Peripheral factors alone cannot, however, be the primary factor in the occurrence of phantom-limb pain. Pain is present even if there are no pathological features in the residual limb. It commonly starts immediately after the amputation, and anaesthetic blocks do not uniformly eliminate phantom-limb pain or they eliminate it for a period that clearly exceeds the time the block can be active. These findings suggest that peripheral factors may be of varying importance in the causation and modulation of phantom-limb pain, and that central factors must also play a part. Furthermore, there are also likely to be subgroups of patients with distinct and differentiable abnormalities.⁵³

Psychological factors

There has been an assumption that phantom limbs and pain are related to unresolved grief over the loss of the limb and may be a psychosomatic manifestation of a premorbid personality. The idea that phantom-limb pain “is just in the head” of the patient is still prevalent and may contribute to the large divergence in reported incidence and prevalence. Empirical studies on psychological characteristics of patients who have phantom-limb pain and controls show that these patients tend to have normal psychological profiles.²²

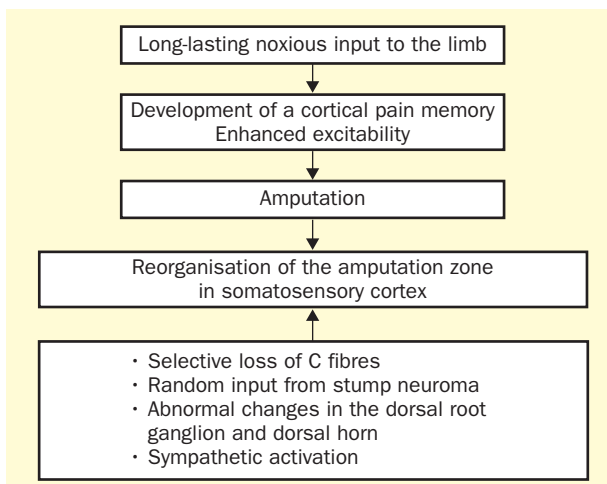


Figure 4. Schematic diagram incorporating the main factors thought to be relevant for the development of phantom-limb pain.

Phantom-limb pain is, however, triggered and exacerbated by psychological factors. Longitudinal diary studies showed that there is a significant relation between stress and the onset and exacerbation of episodes of phantom-limb pain, probably mediated by activity in the sympathetic nervous system and increases in muscle tension.⁵⁴ Cognitive factors also play a part in the modulation of phantom-limb pain; patients who lack coping strategies and fear the worst when confronted with episodes of pain are more affected by the pain and report more interference than patients who cope well with their problem.⁵⁵ Psychological variables before the amputation are also predictive of phantom-limb pain. Patients who received less support before the amputation tend to report more phantom-limb pain.⁵⁶

A model of phantom-limb pain

The determinants of phantom-limb pain include both peripheral and central factors, and we can assume that pain memories established before the amputation are powerful elicitors of phantom-limb pain. The original assumption of a somatosensory pain memory, as noted by Katz and Melzack,¹² was based on findings that many amputees report pain similar in both quality and location to that experienced before the amputation. However, Jensen and colleagues^{2,7,13} have noted that these explicit memories of preamputation pain are rare and of less importance in chronic phantom-limb pain. Pain memories are, however, more likely to be implicit and not readily accessible to conscious recollection. The term implicit pain memory refers to central changes related to nociceptive input that lead to subsequent altered processing of the somatosensory system and do not require changes in conscious processing of the pain experience.

In patients with chronic back pain, increasing duration of pain is correlated with an increase of the representation zone of the back in primary somatosensory cortex;⁵⁷ the experience of acute pain alters the map in the primary somatosensory cortex.⁵⁸ These findings suggest that long-lasting noxious input may lead to long-term changes at the central level, and especially at the cortical level. The primary

somatosensory cortex is known to be involved in the processing of pain, and it may be important for the sensory-discriminative features of the pain experience.⁵⁹ There have also been reports that phantom-limb pain was abolished after the surgical removal of parts of the primary somatosensory cortex and that stimulation of somatosensory cortex evoked phantom-limb pain.^{60,61} If a somatosensory pain memory has been established with an important neural correlate in spinal and supraspinal structures, such as in primary somatosensory cortex, subsequent deafferentation and an invasion of the amputation zone by neighbouring input may preferentially activate cortical neurons coding for pain. Since the cortical area coding input from the periphery seems to stay assigned to the original zone of input, the activation in the cortical zone representing the amputated limb is referred to this limb and the activation is interpreted as phantom sensation and phantom-limb pain. Figure 4 summarises these changes assumed to take place in patients with phantom-limb pain. A likely scenario is not only that the areas involved in sensory-discriminative features of pain reorganise but also that those areas mediating affective-motivational features of pain, such as the insula and the anterior cingulate cortex, undergo plastic changes that contribute to the experience of phantom pain.⁶² The importance of sensitisation before amputation was confirmed by Nikolajsen and colleagues,⁶³ who reported a close association between mechanical sensitivity before amputation and early phantom-limb pain. However, the researchers tested only thresholds and not sensitisation. Further research is needed to clarify these relations.

Treatment of phantom-limb pain

Several studies, including large surveys of patients with amputations, have shown that most treatments for phantom-limb pain are ineffective and do not take account of the mechanisms underlying the production of the pain.⁶⁴ Most studies have been uncontrolled short-term assessments of small samples of patients. A maximum benefit of about 30% has been reported from treatments such as local anaesthesia, sympathectomy, dorsal-root entry-zone lesions, cordotomy and rhizotomy, neurostimulation methods, or pharmacological interventions such as anticonvulsants, barbiturates, antidepressants, neuroleptics, and muscle relaxants.^{53,64} This proportion does not exceed the placebo effect reported in other studies. The panel summarises currently available treatments for phantom-limb pain and indicates the extent to which controlled studies have been done.

Many pharmacological interventions have been tried. Although tricyclic antidepressants and sodium-channel blockers are treatments of choice for neuropathic pain,⁶⁵ there have been no controlled studies of these agents for phantom-limb pain. Controlled studies have been done only for opioids,⁶⁶ calcitonin,⁶⁷ and ketamine,⁶⁸ all effectively reduce phantom-limb pain. Memantine, another NMDA-receptor antagonist, was not effective, however,⁶⁹ despite the finding from animal studies that cortical reorganisation can be prevented and reversed by the use of such agents or

GABA agonists.⁷⁰ In one controlled study, transcutaneous nerve stimulation (TENS) had a small effect on phantom-limb pain.⁷¹

Mechanism-based treatments are rare, but a few small and mostly uncontrolled studies have shown they are effective. Lidocaine decreased phantom-limb pain of patients with neuromas in two small controlled studies.^{72,73} Biofeedback treatments resulting in vasodilatation or decreased muscle tension in the residual limb help to reduce phantom-limb pain and seem promising in patients in whom peripheral factors contribute to the pain.⁷⁴ Findings from neuroelectric and neuromagnetic source imaging suggest that changes in cortical reorganisation might influence phantom-limb pain. Animal work on stimulation-induced plasticity suggests that extensive behaviourally relevant (but not passive) stimulation of a body part leads to an expansion of its representation zone.⁷⁵ Thus, the use of a myoelectric prosthesis might be one way to influence phantom-limb pain. Intensive use of a myoelectric prosthesis was positively associated with both less phantom-limb pain and less cortical

reorganisation.³⁷ When cortical reorganisation was controlled for, the relation between prosthesis use and decreased phantom-limb pain was no longer significant; thus, cortical reorganisation seems to mediate this association. Another approach in patients for whom prosthesis use is not practicable is the use of behaviourally relevant stimulation. A 2-week training course that consisted of discrimination training of electric stimuli to the stump for 2 h per day led to significant improvements in phantom-limb pain and a significant reversal of cortical reorganisation.⁷⁶ A control group of patients who received standard medical treatment and general psychological counselling during this period did not show these changes in cortical reorganisation or phantom-limb pain (figure 5). The basic idea of the treatment was to provide input into the amputation zone and thus undo the reorganisational changes that occurred after the amputation. A recent study has confirmed these findings with a similar protocol.⁷⁷ Ramachandran and Rogers-Ramachandran⁷⁸ described another behaviourally oriented approach: a mirror was placed in a box, and the patient inserted his or her intact arm and the residual limb. He or she was then asked to look at the mirror image of the intact arm, which is perceived as an intact hand where the phantom used to be, and to make symmetrical movements with both hands, thus suggesting real movement from the lost arm to the brain. This procedure seems to re-establish control over the phantom limb and to alleviate pain in some patients, although controlled data are lacking.

Owing to the paucity of controlled studies, a reasonable approach is to base the treatment of phantom pain on recommendations for neuropathic pain in general, such as antidepressant medication and calcium-channel blockers including carbamazepine.⁶⁵ Opioids, calcitonin, ketamine, TENS, and sensory discrimination training can also be used.

Prevention of phantom-limb pain

Katz and Melzack¹² emphasised that there are somatosensory pain memories that may be revived after an amputation and lead to phantom-limb pain. They also noted that implicit and explicit memory components can be differentiated, and that both contribute to the experience of phantom limbs and phantom-limb pain. They therefore suggested that both memory components need to be targeted in trials of analgesic treatment aiming to prevent the onset of phantom-limb pain—ie, that both general and spinal anaesthesia are needed.

Pre-emptive analgesia refers to the attempt to prevent chronic pain by early intervention before acute pain occurs, for example before and during surgery. Findings on sensitisation of spinal neurons by afferent barrage have suggested that general anaesthesia should be complemented by peripheral anaesthesia, thus preventing peripheral nociceptive input from reaching the spinal cord and higher centres. However, pre-emptive analgesia that included both general and spinal anaesthesia has not been consistently effective in preventing the onset of phantom-limb pain. Whereas several studies have reported a reduction of the proportion of patients with phantom-limb pain when additional epidural anaesthesia was used before and during

Commonly used treatments for phantom-limb pain

Pharmacological

Conventional analgesics
Opioids*
β-blockers
Neuroleptics
Anticonvulsants
NMDA-receptor antagonists
Ketamine*
Memantine†
Antidepressants
Barbiturates
Muscle relaxants

Surgical

Stump revision
Neurectomy
Sympathectomy
Rhizotomy
Cordotomy
Tractotomy
Dorsal column stimulation
Deep brain stimulation

Anaesthetic

Nerve blocks
Epidural blockade
Sympathetic block
Local anaesthesia
Lidocaine*

Psychological

Electromyographic biofeedback
Temperature biofeedback
Cognitive-behavioural pain management
Sensory discrimination training*
Hypnosis

Other

Transcutaneous nerve stimulation (TENS)*
Acupuncture
Physiotherapy
Ultrasound
Manipulation
Prosthesis training

*At least one controlled study with a positive effect on phantom-limb pain has been done. †A controlled study with a negative effect on phantom-limb pain has been done.

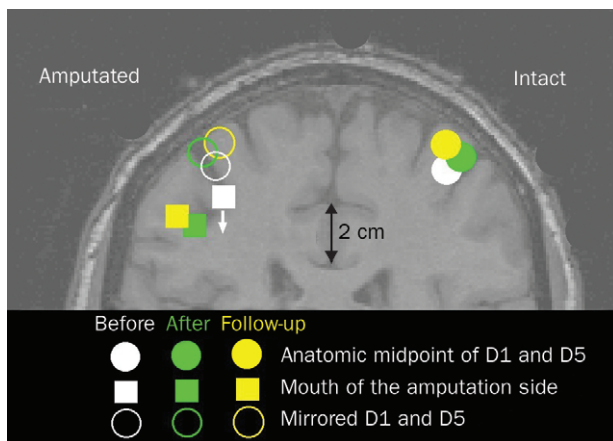


Figure 5. Change in cortical reorganisation after training in sensory discrimination in a group of patients with arm or hand amputations. On the right, the representation of the hand of the intact side is shown for the measurement points before and after training and at 3-month follow-up. On the left, the mirror image of the hand representation is shown in the upper part of the figure. The lower part shows the change of the mouth representation of the amputation side. After training the reorganisation was reversed—ie, the mouth has shifted toward its original more inferior and lateral position. At 3-month follow-up (no training in between) the original reorganisation is again approached.

surgery, one recent controlled study found no beneficial effect on phantom-limb pain.⁷⁹ A pre-existing pain memory that has already led to central and especially cortical changes would not necessarily be affected by a short-term elimination of afferent barrage. Thus, peripheral analgesia might be able to eliminate new but not pre-existing central changes in the perioperative phase. Here, NMDA antagonists and GABA agonists might be beneficial to prevent both central reorganisation and phantom-limb pain. In a recent study, the NMDA-receptor antagonist memantine was compared with placebo in addition to

Search strategy and selection criteria

Published data for this review were identified by searches of Medline, Current Contents, and PsycLit. The search term “phantom-limb pain” was used. Additional references were obtained from books relevant to the topic and from references of the relevant articles. Articles published in English, French, Italian, or German were included. Abstracts and reports from meetings were not considered.

brachial-plexus anaesthesia in patients undergoing traumatic amputations of individual fingers or a hand.⁸⁰ In this placebo-controlled double-blind randomised study, the incidence of phantom limb pain was significantly reduced in the memantine group (20%) compared with the placebo group (72%) at 1 year after surgery.

Future developments

Both peripheral and central factors and their interaction need to be examined more closely in animal models of amputation-related pain and in human beings with amputations. The role of spinal mechanisms has so far been insufficiently elucidated. The detection of genes relevant for the development of phantom-pain-like behaviours in animals is an important step and may aid in the identification of predisposing factors for phantom-limb pain as well as the development of new interventions. The development of more powerful treatments for phantom-limb pain needs controlled treatment outcome, prospective, and double-blind placebo-controlled trials.

Conflict of interest

I have no conflict of interest.

Role of the funding source

HF acknowledges the support of the Deutsche Forschungsgemeinschaft. This funding body had no role in the preparation of the review, or in the decision to submit it for publication.

References

- Kooijman CM, Dijkstra PU, Geertzen JHB, Elzinga A, van der Schans CP. Phantom pain and phantom sensations in upper limb amputees: an epidemiological study. *Pain* 2000; 87: 33–41.
- Jensen TS, Nikolajsen L. Phantom pain and other phenomena after amputation. In: Wall PD, Melzack RA, eds. *Textbook of pain*, 4th edn. Edinburgh: Churchill Livingstone, 1999: 799–814.
- Mitchell SW. Injuries of nerves and their consequences. Philadelphia: Lippincott, 1872.
- Keil G. So-called initial description of phantom pain by Ambrose Pare. “Chose digne d’admiration et quasi incroyable”; the “douleur es parties mortes et amputees”. *Fortschr Med* 1990; 108: 62–66.
- Hill A. Phantom limb pain: a review of the literature on attributes and potential mechanisms. *J Pain Symptom Manage* 1999; 17: 125–42.
- Montoya P, Larbig W, Grulke N, Flor H, Taub E, Birbaumer N. The relationship of phantom pain to other phantom limb phenomena in upper extremity amputees. *Pain* 1997; 72: 87–93.
- Jensen TS, Krebs B, Nielsen J, Rasmussen P. Immediate and long-term phantom limb pain in amputees: incidence, clinical characteristics and relationship to pre-amputation pain. *Pain* 1985; 21: 267–78.
- Krane EJ, Heller LB. The prevalence of phantom sensation and pain in pediatric amputees. *J Pain Symptom Manage* 1995; 10: 21–29.
- Wilkins KL, McGrath PJ, Finley GA, Katz J. Phantom limb sensations and phantom limb pain in child and adolescent amputees. *Pain* 1998; 78: 7–12.
- Melzack RA, Israel R, Lacroix R, Schultz G. Phantom limbs in people with congenital limb deficiency or amputation in early childhood. *Brain* 1997; 120: 1603–20.
- Flor H, Elbert T, Mühlhnickel W, Pantev C, Wienbruch C, Taub E. Cortical reorganization and phantom phenomena in congenital and traumatic upper-extremity amputees. *Exp Brain Res* 1998; 119: 205–12.
- Katz J, Melzack R. Pain ‘memories’ in phantom limbs: review and clinical observations. *Pain* 1990; 43: 319–36.
- Nikolajsen L, Ilkjaer S, Kroner K, Christensen JH, Jensen TS. The influence of preamputation pain on postamputation stump and phantom pain. *Pain* 1997; 72: 393–405.
- Ehde DM, Czerniecki JM, Smith DG, et al. Chronic phantom sensations, phantom pain, residual limb pain, and other regional pain after lower limb amputation. *Arch Phys Med Rehabil* 2000; 81: 1039–44.
- Cronholm B. Phantom limbs in amputees: a study of changes in the integration of centripetal impulses with special reference to referred sensations. *Acta Psychiatr Neurol Scand Suppl* 1951; 72: 1–310.
- Katz J. Psychophysiological contributions to phantom limbs. *Can J Psychiatry* 1992; 37: 282–98.
- Grüsser SM, Winter C, Mühlhnickel W, et al. The relationship of perceptual phenomena and cortical reorganization in upper extremity amputees. *Neuroscience* 2001; 102: 263–72.
- Ramachandran VS, Rogers-Ramachandran DC, Stewart M. Perceptual correlates of massive cortical reorganization. *Science* 1992; 258: 1159–60.
- Knecht S, Henningsen H, Höhling C, et al. Plasticity of plasticity? Changes in the pattern of perceptual correlates of reorganization after amputation. *Brain* 1998; 121: 717–24.
- Haber WB. Effects of loss of limb on sensory functions. *J Psychol* 1955; 40: 115–23.
- Braune S, Schady W. Changes in sensation after nerve injury or amputation: the role of central factors. *J Neurol Neurosurg Psychiatry* 1993; 56: 393–99.
- Sherman RA, Sherman CJ, Bruno GM. Psychological factors influencing chronic phantom limb pain: an analysis of the literature. *Pain* 1987; 28: 285–95.
- Doubell TP, Mannion RJ, Woolf CJ. The dorsal horn: state-dependent sensory processing, plasticity and the generation of pain. In: Wall PD, Melzack RA, eds. *Textbook of pain*, 4th edn. Edinburgh: Churchill Livingstone, 1999: 165–81.
- Sandkühler J. Learning and memory in pain pathways. *Pain* 2000; 88: 113–18.
- Woolf CJ, Shortland P, Coggeshall RE. Peripheral nerve injury triggers central sprouting of myelinated afferents. *Nature* 1992; 355: 75–78.
- Woolf CJ, Mannion RJ. Neuropathic pain: aetiology, symptoms, and treatment. *Lancet* 1999; 353: 1959–64.
- Cook AJ, Woolf CJ, Wall PD, McMahon SB. Dynamic receptive field plasticity in rat spinal cord following C-primary afferent input. *Nature* 1987; 325: 151–53.
- Florence SL, Kaas JH. Large-scale reorganization at multiple levels of the somatosensory pathway following therapeutic amputation of the hand in monkey. *J Neurosci* 1995; 15: 8083–95.

- 29 Melzack RA. Phantom limbs and the concept of a neuromatrix. *Trends Neurosci* 1990; 13: 88–92.
- 30 Merzenich MM, Nelson RJ, Stryker MP, Cynader MS, Schoppmann A, Zook JM. Somatosensory cortical map changes following digit amputation in adult monkeys. *J Comp Neurol* 1984; 224: 591–605.
- 31 Pons TP, Garrahy PE, Ommaya AK, Kaas JH, Taub E, Mishkin M. Massive cortical reorganization after sensory deafferentation in adult macaques. *Science* 1991; 252: 1857–50.
- 32 Flor H, Elbert T, Knecht S, et al. Phantom limb pain as a perceptual correlate of cortical reorganization following arm amputation. *Nature* 1995; 357: 482–84.
- 33 Birbaumer N, Lutzenberger W, Montoya P, et al. Effects of regional anesthesia on phantom limb pain are mirrored in changes in cortical reorganization. *J Neurosci* 1997; 17: 5503–08.
- 34 Florence SL, Taub HB, Kaas JH. Large-scale sprouting of cortical connections after peripheral injury in adult macaque monkeys. *Science* 1999; 282: 1117–20.
- 35 Jones EG, Pons TP. Thalamic and brainstem contributions to large-scale plasticity of primate somatosensory cortex. *Science* 1998; 282: 1121–25.
- 36 Wu CWH, Kaas JH. Reorganization in primary motor cortex of primates with long-standing therapeutic amputations. *J Neurosci* 1999; 19: 7679–97.
- 37 Lotze M, Flor H, Grodd W, Larbig W, Birbaumer N. Phantom movements and pain: an fMRI study in upper limb amputees. *Brain* 2001; 124: 2268–77.
- 38 Chen R, Corwell B, Yaseen Z, Hallett M, Cohen LG. Mechanisms of cortical reorganization in lower-limb amputees. *J Neurosci* 1998; 18: 3443–50.
- 39 Davis KD, Kiss ZHT, Luo L, Tasker RR, Lozano AM, Dostrovsky JO. Phantom sensations generated by thalamic microstimulation. *Nature* 1998; 391: 385–87.
- 40 Ergenzinger ER, Glasier MM, Hahn JO, Pons TP. Cortically induced thalamic plasticity in the primate somatosensory system. *Nat Neurosci* 1998; 1: 226–29.
- 41 Wall PD, Gutnick M. Ongoing activity in peripheral nerves: the physiology and pharmacology of impulses originating from a neuroma. *Exp Neurol* 1974; 43: 580–93.
- 42 Devor M, Govrin-Lippman R, Angelides K. Na⁺ channels immunolocalization in peripheral mammalian axons and changes following nerve injury and neuroma formation. *J Neurosci* 1993; 13: 1976–92.
- 43 Spitzer M, Bohler P, Weisbrod M, Kischka U. A neural network model of phantom limbs. *Biol Cybern* 1995; 72: 197–206.
- 44 Devor M, Seltzer Z. Pathophysiology of damaged nerves in relation to chronic pain. In: Wall PD, Melzack RA, eds. *Textbook of pain*, 4th edn. New York: Churchill-Livingstone; 1999, 128–64.
- 45 Nystrom B, Hagbarth KE. Microelectrode recordings from transected nerves in amputees with phantom limb pain. *Neurosci Lett* 1981; 27: 211–16.
- 46 Devor M, Jänig W, Michaelis M. Modulation of activity in dorsal root ganglion neurones by sympathetic activation in nerve-injured rats. *J Neurophysiol* 1994; 71: 38–47.
- 47 Seltzer Z, Wu T, Max MB, Diehl SR. Mapping a gene for neuropathic pain-related behavior following peripheral neurectomy in the mouse. *Pain* 2001; 93: 101–06.
- 48 Inbal R, Devor M, Tuchendler O, Lieblich I. Autotomy following nerve injury: genetic factors in the development of chronic pain. *Pain* 1980; 3: 327–37.
- 49 Schott GD. Pain and its absence in an unfortunate family of amputees. *Pain* 1986; 25: 229–31.
- 50 Torebjörk E, Wahren L, Wallin G, Koltzenburg M. Noradrenaline-evoked pain in neuralgia. *Pain* 1995; 63: 11–20.
- 51 Sherman RA, Bruno GM. Concurrent variation of burning phantom limb and stump pain with near surface blood flow in the stump. *Orthopedics* 1987; 10: 1395–402.
- 52 Sherman RA, Griffin VD, Evans CB, Grana AS. Temporal relationships between changes in phantom limb pain intensity and changes in surface electromyogram of the residual limb. *Int J Psychophysiol* 1992; 13: 71–77.
- 53 Sherman RA. Phantom limb pain. New York: Plenum, 1997.
- 54 Arena JG, Sherman RA, Bruno GM, Smith JD. The relationship between situational stress and phantom limb pain: cross-lagged correlational data from six-month pain logs. *J Psychosom Med* 1990; 34: 71–77.
- 55 Hill A, Niven CA, Knussen C. The role of coping in adjustment to phantom limb pain. *Pain* 1995; 62: 79–86.
- 56 Gallagher P, Allen D, MacLachlan M. Phantom limb pain and residual limb pain following lower limb amputation: a descriptive analysis. *Disabil Rehab* 2001; 23: 522–30.
- 57 Flor H, Braun C, Elbert T, Birbaumer N. Extensive reorganization of primary somatosensory cortex in chronic back pain patients. *Neurosci Lett* 1997; 224: 5–8.
- 58 Soros P, Knecht S, Bantel C et al. Functional reorganization of the human primary somatosensory cortex after acute pain demonstrated by magnetoencephalography. *Neurosci Lett* 2001; 298: 195–98.
- 59 Treede RD, Kenshalo DR, Gracely RH, Jones AK. The cortical representation of pain. *Pain* 1999; 79: 105–11.
- 60 Woolsey CN, Erickson TC, Gilson WE. Localization in somatic sensory and motor areas of human cerebral cortex as determined by direct recording of evoked potentials and electrical stimulation. *J Neurosurg* 1979; 51: 476–506.
- 61 Appenzeller O, Bicknell JM. Effects of nervous system lesion on phantom experience in amputees. *Neurology* 1969; 19: 141–46.
- 62 Wei F, Li P, Zhuo M. Loss of synaptic depression in mammalian anterior cingulate cortex after amputation. *J Neurosci* 1999; 19: 9346–54.
- 63 Nikolajsen L, Ilkjaer S, Jensen TS. Relationship between mechanical sensitivity and post-amputation pain: a perspective study. *Eur J Pain* 2000; 4: 327–34.
- 64 Sherman RA, Sherman CJ, Gall NG. A survey of current phantom limb pain treatment in the United States. *Pain* 1980; 8: 85–99.
- 65 Sindrup SH, Jensen TS. Efficacy of pharmacological treatments of neuropathic pain: an update and effect related to mechanism of drug action. *Pain* 1999; 83: 389–400.
- 66 Huse E, Larbig W, Flor H, Birbaumer N. The effect of opioids on phantom limb pain and cortical reorganization. *Pain* 2001; 90: 47–55.
- 67 Jaeger H, Maier C. Calcitonin in phantom limb pain: a double-blind study. *Pain* 1992; 48: 21–27.
- 68 Nikolajsen L, Hansen CL, Nielsen J, Keller J, Arendt-Nielsen L, Jensen TS. The effect of ketamine on phantom limb pain: a central neuropathic disorder maintained by peripheral input. *Pain* 1996; 67: 69–77.
- 69 Nikolajsen L, Gottrup H, Kristensen AGD, Jensen TS. Memantine (a N-methyl D-aspartate receptor antagonist) in the treatment of neuropathic pain following amputation or surgery: a randomised, double-blind, cross-over study. *Anesth Analg* 2000; 91: 960–66.
- 70 Jones EG. Cortical and subcortical contributions to activity-dependent plasticity in primate somatosensory cortex. *Annu Rev Neurosci* 2000; 23: 1–37.
- 71 Katz J, Melzack RA. Auricular transcutaneous electrical nerve stimulation (TENS) reduces phantom limb pain. *J Pain Symptom Manage* 1991; 6: 77–83.
- 72 Chabal C, Jacobson L, Russell LC, Burchiel KJ. Pain response to perineuromal injection of normal saline, epinephrine, and lidocaine in humans. *Pain* 1992; 49: 9–12.
- 73 Chabal C, Jacobson L, Russell LC, Burchiel KJ. Pain responses to perineuromal injection of normal saline, gallamine, and lidocaine in humans. *Pain* 1989; 36: 321–25.
- 74 Sherman RA. Stump and phantom limb pain. *Neurol Clin* 1989; 7: 249–64.
- 75 Jenkins WM, Merzenich MM, Ochs MT, Allard T, Guic-Robles E. Functional reorganization of primary somatosensory cortex in adult owl monkeys after behaviorally controlled tactile stimulation. *J Neurophysiol* 1990; 63: 82–104.
- 76 Flor H, Denke C, Schaefer M, Grüsser M. Sensory discrimination training alters both cortical reorganisation and phantom limb pain. *Lancet* 2001; 357: 1763–64.
- 77 Huse E, Preissl H, Larbig W, Birbaumer N. Phantom limb pain. *Lancet* 2001; 358: 1015.
- 78 Ramachandran VS, Rogers-Ramachandran D. Synaesthesia in phantom limbs induced with mirrors. *Proc R Soc Lond B Biol Sci* 1996; 263: 377–86.
- 79 Nikolajsen L, Ilkjaer S, Christensen JH, Kroner K, Jensen TS. Randomised trials of epidural bupivacaine and morphine in prevention of stump and phantom pain in lower-limb amputation. *Lancet* 1997; 350: 1353–57.
- 80 Wiech K, Preissl H, Kiefer T, et al. Prevention of phantom limb pain and cortical reorganization in the early phase after amputation in humans. *Soc Neurosci Abstr* 2001; 28: 163.9.