

Multimodal responses induced by cortical stimulation of the parietal lobe: a stereo-electroencephalography study

Simona Balestrini,¹ Stefano Francione,² Roberto Mai,² Laura Castana,² Giuseppe Casaceli,² Daniela Marino,³ Leandro Provinciali,¹ Francesco Cardinale² and Laura Tassi²

The functional complexity of the parietal lobe still represents a challenge for neurophysiological and functional neuroimaging studies. While the somatosensory functions of the anterior parietal cortex are well established, the posterior parietal cortex has a relevant role in processing the sensory information, including visuo-spatial perception, visual attention, visuo-motor transformations and other complex and not completely understood functions. We retrospectively analysed all the clinical manifestations induced by intracerebral bipolar electrical stimulation in 172 patients suffering from drug-resistant focal epilepsy (mean age 25.6, standard deviation 11.6; 44% females and 56% males) with at least one electrode stereotactically implanted in the parietal cortex. A total of 1186 electrical stimulations were included in the analysis, of which 88 were subsequently excluded because of eliciting pathological electric activity or inducing ictal symptomatology. In the dominant parietal lobe, clinical responses were observed for 56 (25%) of the low-frequency stimulations and for 76 (50%) of the high-frequency stimulations. In the non-dominant parietal lobe, 111 (27%) low-frequency and 176 (55%) high-frequency stimulations were associated with a clinical response. Body scheme alteration was the only clinical effect showing a lateralization, as they were evoked only in the non-dominant hemisphere. The occurrence of somatosensory sensations, motor symptoms, dysarthria and multimodal responses were significantly associated with stimulation of the postcentral gyrus (odds ratio: 5.83, $P < 0.001$; odds ratio: 8.77, $P < 0.001$; odds ratio: 5.44, $P = 0.011$; odds ratio: 8.33, $P = 0.006$; respectively). Stimulation of the intraparietal sulcus was associated with the occurrence of sensory illusions or hallucinations (odds ratio: 8.68, $P < 0.001$) and eyeball/eyelid movements or sensations (odds ratio: 4.35, $P = 0.047$). To our knowledge, this is the only currently available complete revision of electrical stimulation of the entire parietal cortex with the aim to evaluate the neurophysiology of this relevant brain region. Our analysis offers a general overview of the multiple roles of the parietal cortex and supports its crucial involvement in different networks related to complex integrative functions.

1 Neurological Clinic, Department of Experimental and Clinical Medicine, Marche Polytechnic University, Ancona, Italy

2 'Claudio Munari' Epilepsy Surgery Centre, Niguarda Hospital, Milan, Italy

3 Department of Neurological and Sensorial Sciences, University of Siena, Italy

Correspondence to: Simona Balestrini,
Neurological Clinic,
Department of Experimental and Clinical Medicine,
Marche Polytechnic University,
via Conca 71, 60100 Ancona, Italy
E-mail: s.balestrini@ucl.ac.uk

Keywords: stereo-EEG; parietal lobe; clinical neurophysiology; associational areas; sensory systems

Introduction

The parietal lobe is located posterior to the central sulcus and superior to the occipital lobe, constituting ~20% of the human brain (Siegel *et al.*, 2003). Its functions include the somatosensory functions of the anterior parietal cortex in the detection of and discrimination between somatosensory stimuli, multiple roles of the posterior parietal cortex in processing sensory information, including visuo-spatial perception, visual attention, visuo-motor transformations and other complex and not completely understood functions. Critchley, in his monograph of 1953, already expressed the concept of the parietal lobe as an ‘ordering principle’ of several areas in distributed systems involving other cortical and subcortical structures (Critchley, 1953). This complexity of functions indeed still represents a challenge for neurophysiological and functional neuroimaging studies and a discrete amount of the current available knowledge derives from extrapolations of experimental studies on monkeys (Rizzolatti *et al.*, 1997). Since the first descriptions of the functional organization of the sensory-motor strip by W. Penfield (Penfield and Boldrey, 1937), direct electrical stimulation has been used to obtain a cortical map of human cortical functions (Penfield and Rasmussen, 1957). The use of electrical stimulation allows for the definition of eloquent areas (Lachhwani and Dinner, 2004), where the stimulation leads to a reproducibly demonstrable change in neurological function, including positive or negative phenomena. Primary sensory, secondary sensory and supplementary sensorimotor areas have been extensively studied in electrical stimulation studies, showing relatively stable and reproducible positive responses (Penfield and Boldrey, 1937; Lim *et al.*, 1994). On the other hand, few and heterogeneous data are available on the results of electrical stimulation of the posterior parietal cortex. In humans, electrical stimulation of the lateral and medial superior parietal area has been associated with sensorimotor, vestibular and visual responses. By comparison, electrical stimulation of the inferior parietal area has generated body scheme alteration, somatosensory and vestibular responses, language and cognitive disturbances, with some difference between the dominant and non-dominant hemispheres (Morris *et al.*, 1984; Richer *et al.*, 1991; Kahane *et al.*, 2003; Laff *et al.*, 2003; Matsushashi *et al.*, 2004; Selimbeyoglu and Parvizi, 2010). There is now consensus on the role of posterior parietal cortex in sensorimotor integration and coordinate transformations, but there are still outstanding questions regarding functional localization along the sensorimotor continuum (Colby and Goldberg, 1999; Andersen and Buneo, 2002). Furthermore, cortical stimulation studies have not addressed the issue of hemispheric lateralization so far.

The main purpose of the current study was to explore the functional organization of the dominant and non-dominant parietal cortices using electrical stimulation, with a specific emphasis on hemispheric lateralization. We thus reviewed

the results of electrical stimulation performed into the parietal lobe as a routine procedure in 172 patients with drug-resistant focal epilepsy who underwent stereo-EEG.

Materials and methods

Patients

Two hundred and seventy-four consecutive patients with focal epilepsy underwent stereo-EEG for refractory focal epilepsy over the 109-month period between January 2005 and January 2014, at the ‘Claudio Munari’ Epilepsy Surgery Centre of Niguarda Hospital, Milan (Italy). Each implantation schema of the 274 consecutive cases was carefully reviewed by means of the stereotactic planning software Voxim (IVS) (for cases before January 2009) or Slicer 3D (<http://www.slicer.org>) (for cases after December 2008) by two different epileptologists and one neurosurgeon. Patients with at least one intracerebral electrode implanted in the parietal lobe were included in the study. All patients underwent psychiatric and psychometric assessment as part of the routine presurgical work-up. Subjects with a diagnosis of psychiatric disturbances or any degree of learning disability were excluded because these conditions might affect the evoked subjective perceptual and behavioural phenomena resulting in 172 patients being selected [76 females, 96 males; mean age 25.6, standard deviation (SD) 11.6 years]. The hemispheric dominance for language was determined by functional MRI or electrical stimulation results.

All patients were fully informed of the aims of the stereo-EEG recording and stimulation procedures and gave their written informed consent in agreement with the Declaration of Helsinki. The study was approved by the local Ethics Committee (protocol number 939, ‘Retrospective study of the analysis of the neurophysiological data obtained during video-stereo EEG monitoring as part of the diagnostic presurgical work-up’, approved on the 12 December 2013).

Intracerebral electrode implantation

The stereotactic implantation procedure is detailed in Cardinale *et al.* (2013). All patients were chronically implanted with semi-rigid platinum/iridium intracerebral electrodes (0.8 mm in diameter; DIXI). The electrodes had between five and 18 recording contacts, depending on their length. Contacts were 2-mm long and separated from one another by 1.5 mm. Ninety-six implantations were on the right side (56%), 57 on the left side (33%) and 19 bilateral (11%), with four to 18 electrodes implanted in each case. The number of electrodes and the sites of implantation were established according to the available non-invasive anatomical, electrical, and clinical data, collected during an earlier phase of the investigation, to plan a tailored strategy of exploration consistent with the hypothetical localization of the epileptogenic zone (Talairach and Bancaud, 1973) specific to each patient. Each implantation had arbitrarily chosen electrode labels that were not specific to their anatomical localization. The application accuracy of the stereo-EEG methodology has already been analysed *in vivo* showing a median target point localization error of 1.77 mm (interquartile range, 1.25–2.51 mm; P -value $< 2.2 \times 10^{-16}$) (Cardinale *et al.*, 2013).

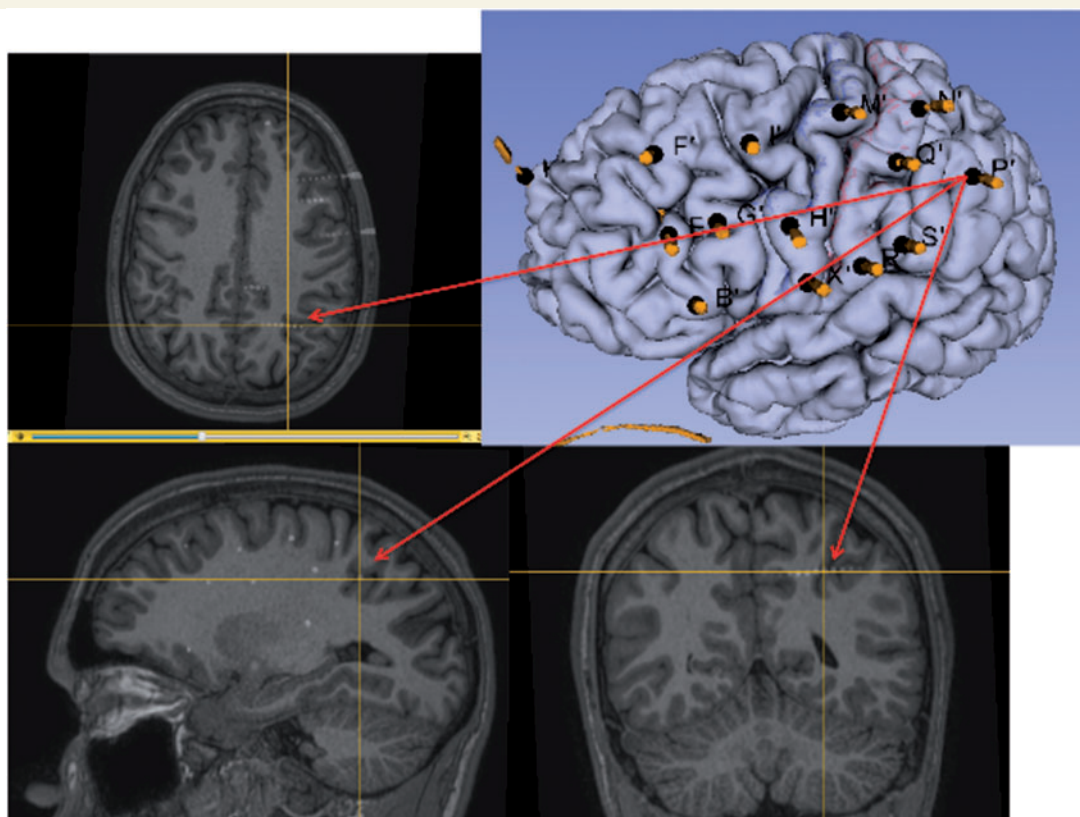


Figure 1 Example of a fronto-centro-parietal left-side implantation with five electrodes sited in the parietal cortex. The following electrodes were implanted in the parietal lobe: N, Q and R = primary sensory area in the postcentral gyrus; S = sovramarginal gyrus; P = angular gyrus with the lateral contacts, intraparietal sulcus in the intermediate part, as shown in the multiplanar magnetic resonance image, and parietal cingulate gyrus with the mesial leads. All other electrodes are sited in the frontal lobe.

Figure 1 illustrates an example of left-side implantation exploring frontal and anterior parietal lobes.

Electrical stimulation paradigm

Electrical bipolar stimulations of two adjacent contacts were carried out at low-frequencies (1 Hz, pulse width 1–3 ms, 30 s) and high-frequencies (50 Hz, pulse width 1 ms, 5 s), to map functionally eloquent regions and reproduce ictal manifestations. These parameters were used to avoid any tissue injury (charge density per square pulse <55 IC/cm²) (Gordon *et al.*, 1990). Electrical stimulations were performed by delivering monophasic rectangular electrical stimuli of alternating polarity (IRES 600 CH electrical stimulator, Micromed or OSIRIS NeuroStimulator, Inomed). According to previous studies (Rank, 1975), the current spread linked to a stimulation intensity of 3 mA is able to stimulate excitable nervous elements up to a maximum distance of 5 mm. Square pulses of current were applied between two adjacent contacts (bipolar stimulation). This type of stimulation involves a smaller cortical volume than monopolar stimulation, allowing functional localization within ~ 5 mm of the stimulated pair of electrodes (Nathan *et al.*, 1993). For the low-frequency tests all adjacent contact pairs were stimulated.

For the purpose of this analysis, we excluded electrical stimulations performed in electrodes sited in any type of parietal lobe lesions visible on MRI or revealed by

neuropathological examination in the operated patients, and those eliciting pathological electric activity (defined as after-discharges both local or spreading out of the stimulation site) or inducing part or the entire habitual ictal symptomatology. We also excluded all electrical stimulations performed at contact pairs located in white matter tracts.

During the all stimulation session, patients were sitting in bed and asked to relax. During each stimulation, the subject underwent a number of tests chosen depending on the site of the stimulation from the following battery: language (including comprehension, expression and reading tasks); memory; calculus; visual (including visual recognition and visual field assessment); sensori-motor. For the latter patients were requested, following a 5-s period at rest, to maintain the relevant body parts in the anti-gravity position, to highlight the presence of positive and particularly negative motor phenomena. They were asked to report any symptom or clinical change, however subtle, and were immediately questioned on these symptoms. They were not aware of when, where, or whether, stimulation was applied.

Data collection and analysis

Analysis of the electrical stimulation clinical responses was performed using the videotaped recordings of stimulation sessions and the simultaneous EEG traces (Nihon Kohden System, Japan) by three epileptologists. The electrical

stimulation responses were classified into the following semiological categories: (i) somatosensory sensation (including anaesthesia, paraesthesia or thermic dysperception); (ii) visual, auditory, gustatory or multisensory illusion/hallucination; (iii) vertigo; (iv) body scheme alteration (including altered subjective perception of body image or movement); (v) dysarthria; (vi) speech arrest; (vii) neurovegetative symptom (including all types of autonomic symptoms); (viii) pain; (ix) eyeball/eyelid movement or sensation; (x) motor symptom (including clonic or tonic movements, atonia); (xi) psychic phenomenon (including derealization); (xii) multimodal response (including complex symptom belonging to more than one of the above categories); and (xiii) unclassified response (when the effect was not possible to include in any of the above categories).

Examples of symptoms classification are reported in Supplementary Table 1.

The parietal lobes were divided in the following substructures (Duvernois, 1999; Nieuwenhuys *et al.*, 2008) (Fig. 2): (i) postcentral gyrus, posterior part of paracentral lobule and parietal operculum; (ii) posterior cingulum; (iii) precuneus; (iv) intraparietal sulcus; (v) superior parietal lobule; and (vi) inferior parietal lobule.

The electrode contacts were localized in relation to the above substructures. In each substructure, electrical stimulations determining analogous clinical responses in the same patient were considered once.

To overview all the effective electrical stimulations, the post-implant data set (3D-CT or 3D-T₁-weighted MRI scan) was registered to the pre-implant 3D-T₁-weighted MRI scan using FLIRT (Oxford Centre for Functional MRI of the Brain-FMRIB's Linear Image Registration Tool) (Jenkinson and Smith, 2001), a software tool for linear registrations provided by FMRIB's Software Library (FSL) (Jenkinson *et al.*, 2012). Registration parameters were six degrees of freedom, mutual information and trilinear interpolation. All 3D-T₁-weighted MRI scans were non-linearly registered to 'fsaverage', the template space provided by FreeSurfer package (Fischl, 2012), using FNIRT (Oxford Centre for Functional MRI of the Brain-FMRIB's Non-linear Image Registration Tool). After the concatenation of the two transformation matrices, the

original position of the electrodes implanted in each patient was moved to the template space. Finally, both the registered data sets and the 3D reconstruction of the template pial surface were loaded in a scene, created with 3D Slicer (Gering *et al.*, 1999). A dot representing the position of the point halfway between each pair of adjacent stimulation leads was manually located for each effective electrical stimulation. A map with all effective electrical stimulations was thus obtained for the dominant and non-dominant hemispheres (Fig. 3).

The Kruskal-Wallis rank test was used to compare the distribution of clinical responses in each parietal lobe substructure, considering both dominant and non-dominant hemispheres together, separately for the low- and high-frequencies. The Wilcoxon signed-rank test was performed to compare the distribution of clinical effects in each substructure between the two hemispheres and across the various substructures, considering both dominant and non-dominant sides. Odds ratios (ORs) were calculated using multivariate logistic regression to quantify associations between the occurrence of positive symptoms in each semiological category (considered as the dependent variable) and epilepsy duration, presumed location of the epileptogenic zone in the parietal lobe, hemispheric dominance, electrical stimulation frequency, electrical stimulation site, presence of any parietal structural lesion on brain MRI scan. Univariate associations with a *P*-value <0.20 were used to build a multivariate model. For the electrical stimulation site, considered as categorical variable, the subregion with the largest sample size was chosen as a reference factor. Regression analysis was not carried out for the clinical categories with <10 positive responses (neurovegetative symptoms, pain, psychic phenomena, speech arrest). Significant values were retained for *P*-values <0.05. Data analysis was performed using the Stata/IC 11.1 Statistical package.

Results

All 172 patients included had a diagnosis of drug-resistant focal epilepsy. Demographic and clinical characteristics are summarized in Table 1. Following stereo-EEG, 113 patients

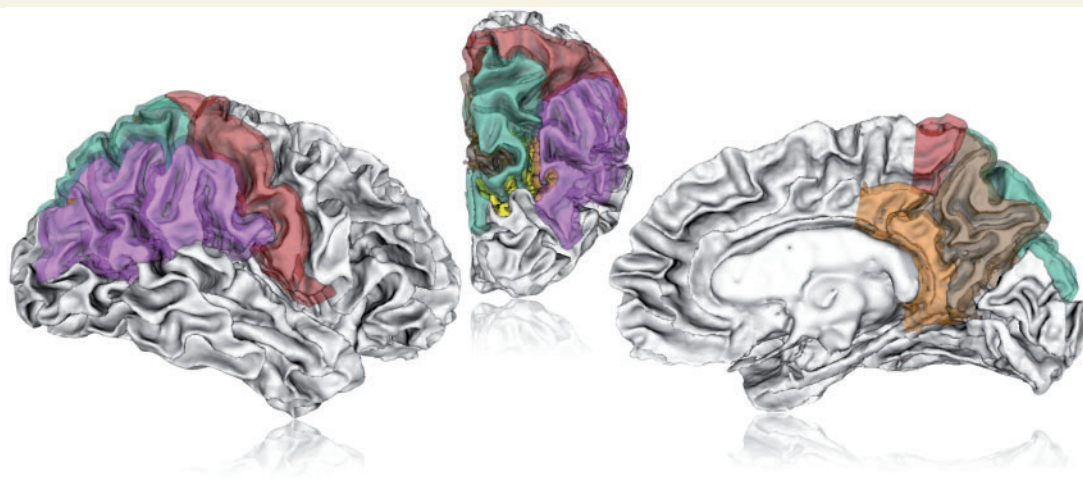

Figure 2 Lateral, posterior and mesial aspect of the right hemisphere. Postcentral gyrus in red; inferior parietal lobule in purple; superior parietal lobule in green; intraparietal sulcus in yellow; precuneus in brown; posterior cingulum in orange.

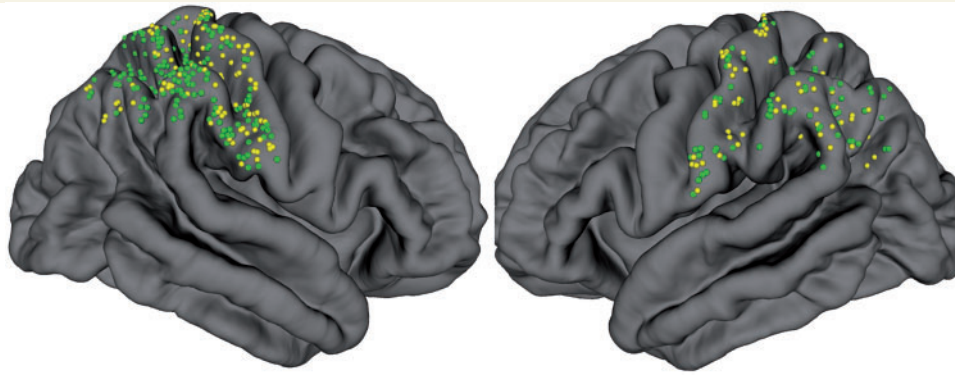


Figure 3 The effective electrical stimulations are showed into the dominant hemisphere (right side) and in the non-dominant (left side). Low frequency sites are depicted in yellow, high frequency in green. Fifty-six low-frequency and 76 high-frequency stimulations are shown in the dominant hemisphere; 111 low-frequency and 176 high-frequency stimulations are displayed in the non-dominant side.

underwent surgical treatment. Details of surgical resection and outcome are showed in Supplementary Table 2. Overall, 648 low-frequency and 538 high-frequency stimulations were collected and analysed. Of these, 88 were excluded because eliciting pathological electric activity or inducing part or the entire habitual ictal symptomatology. Five patients had the right hemisphere dominant for language. All stimulations included in the analysis are detailed in Supplementary Table 3.

Low- and high-frequency stimulation

In the dominant parietal lobe, 222 low-frequency and 152 high-frequency stimulations were included in the analysis. A clinical response was obtained from 56 (25%) of the low-frequency stimulations and from 76 (50%) of the high-frequency stimulations. In the non-dominant parietal lobe, 406 low-frequency and 318 high-frequency stimulations were analysed. Of these, 111 (27%) low-frequency and 176 (55%) high-frequency stimulations were associated with a clinical response. The clinical responses obtained in each substructure with low and high-frequency stimulation, for each hemisphere, are shown in Fig. 4. When considering both hemispheres together, the analysis of the distribution of the clinical responses in each parietal lobe substructure showed a slightly significantly different per cent distribution of the responses in the postcentral gyrus ($P = 0.049$) and intraparietal sulcus ($P = 0.049$), for the low frequency electrical stimulations, and a significant difference in the per cent distribution of the clinical symptoms only in the postcentral gyrus ($P = 0.039$), for the high frequency electrical stimulations (Kruskal-Wallis rank test).

Clinical responses from electrical stimulations

After analysing all the clinical responses from both low- and high-frequency stimulations, in each parietal

Table 1 Demographic and clinical characteristics

General characteristics	Number of patients (n = 172)
Gender	
Females, n (%)	76 (44)
Males, n (%)	96 (56)
Neurological examination	
Abnormal, n (%)	29 (17)
Normal, n (%)	143 (83)
Age at onset of epilepsy in years, mean (SD)	8.6 (11.1)
Duration of epilepsy in years, mean (SD)	16.9 (12.3)
Age at stereo-EEG in years, mean (SD)	25.6 (11.6)
Side of stereo-EEG exploration	
Right, n (%)	96 (56)
Left, n (%)	57 (33)
Bilateral, n (%)	19 (11)
Side of epileptogenic area	
Right, n (%)	106 (62)
Left, n (%)	59 (34)
Bilateral, n (%)	4 (2)
Not determined, n (%)	3 (2)
Involvement of parietal lobe in the epileptogenic area, n (%)	50 (29)
Presence of parietal structural lesion on brain MRI scan, n (%)	26 (15)

substructure of the dominant and non-dominant hemisphere, we obtained the following prevalent clinical symptoms.

Post-central gyrus

In the postcentral gyrus, 174 effective electrical stimulations were analysed. In both hemispheres, motor symptoms (22 of 56, 39%, for the dominant hemisphere; 56 of 118, 48%, for the non-dominant hemisphere) were the most common elicited clinical responses, followed by somatosensory sensations (20 of 56, 36%, for the dominant hemisphere; 37 of 118, 31%, for the non-dominant hemisphere).

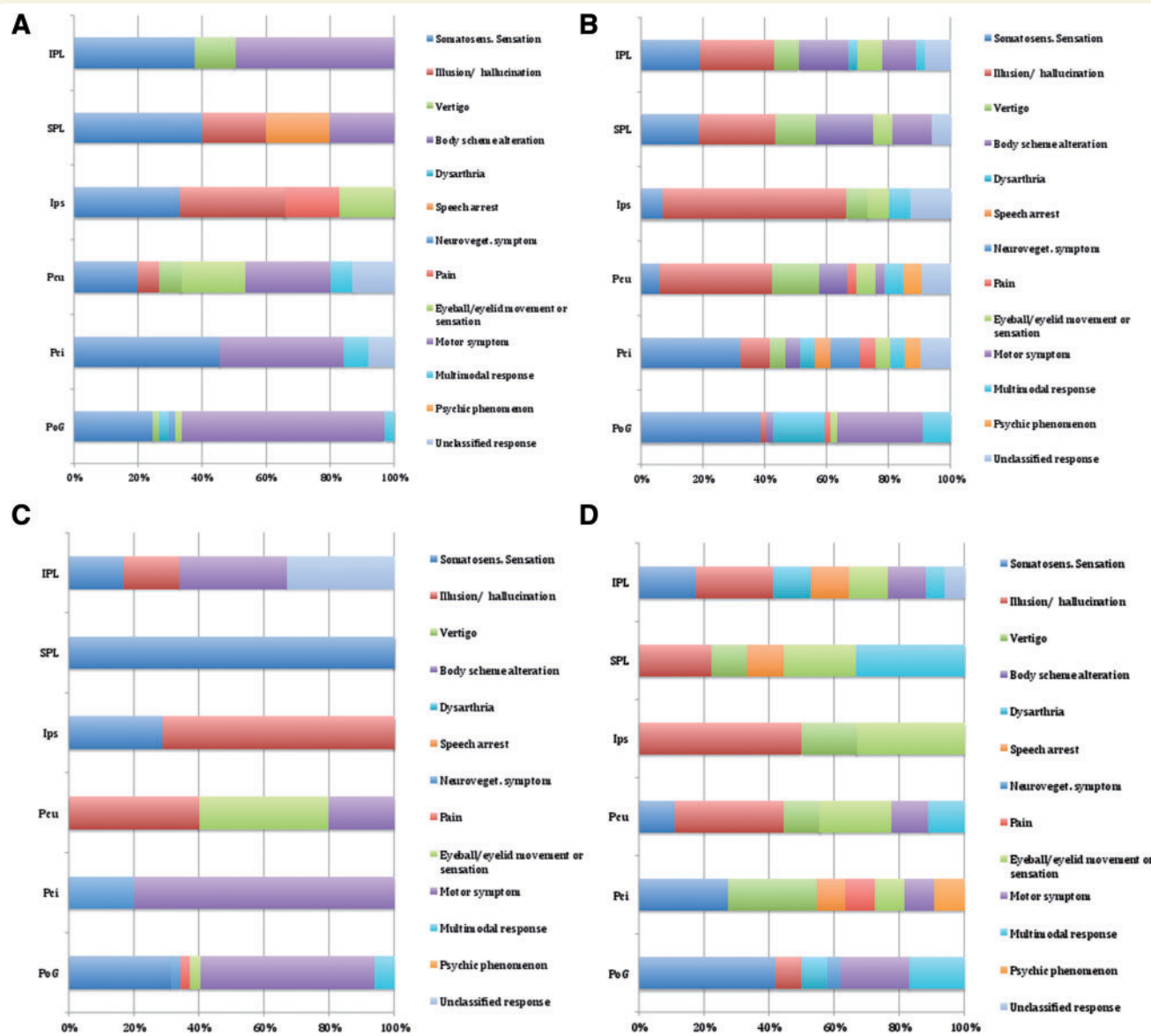


Figure 4 Summary of clinical responses obtained in each substructure with low and high-frequency stimulation, for each hemisphere. Clinical responses associated with: (A) low-frequency stimulation in the non-dominant hemisphere; (B) high-frequency stimulation in the non-dominant hemisphere; (C) low-frequency stimulation in the dominant hemisphere; and (D) high-frequency stimulation in the dominant hemisphere.

Posterior cingulum

In the posterior cingulum, 50 effective electrical stimulations were analysed. The prevalent provoked responses in the dominant hemisphere were motor symptoms (5 of 16, 31%), followed by somatosensory sensations and vertigo (both 3 of 16, 19%). On the non-dominant side, the highest number of responses were somatosensory (13 of 34, 38%), followed by motor symptoms (5 of 34, 15%).

Precuneus

In the precuneus, 62 effective electrical stimulations were analysed. Visual illusion/hallucinations were bilaterally the prevalent responses (5 of 14, 36%, in the dominant

hemisphere, and 13 of 48, 27%, in the non-dominant hemisphere). On the dominant side, the second most prevalent responses were eyeball/eyelid movements or sensations (4 of 14, 29%), and vertigo on the non-dominant side (6 of 48, 13%).

Intraparietal sulcus

In the intraparietal sulcus, 34 effective electrical stimulations were analysed. Similarly, in this region visual illusion/hallucinations were the prevalent response (8 of 13, 62%, for the dominant hemisphere, and 11 of 21, 52%, for the non-dominant hemisphere), followed by somatosensory sensations (2 of 13, 15%, in the dominant hemisphere

and 3 of 21, 14%, in the non-dominant hemisphere) on both sides. In the dominant hemisphere, the second highest prevalence of clinical symptoms was also eyeball/eyelid movements or sensations (2 of 13, 15%).

Superior parietal lobule

In the superior parietal lobule, 31 effective electrical stimulations were analysed. In the dominant hemisphere, the most frequently evoked clinical symptoms were of the multimodal category (3 of 10, 30%), followed by visual illusions and eye movements/sensations (both 2 of 10, 20%). In the non-dominant hemisphere, somatosensory sensations and sensory illusion/hallucinations were the most frequent (both 5 of 21, 24%), followed by body scheme alteration and motor symptoms (both 3 of 21, 14%).

Inferior parietal lobule

In the inferior parietal lobule, 68 effective electrical stimulations were analysed. In the dominant hemisphere the most frequently elicited responses were sensory illusion/hallucinations (5 of 23, 22%), followed by somatosensory sensations and motor symptoms (both 4 of 23, 17%). On the non-dominant side, the greatest number of responses were somatosensory (10 of 45, 22%), followed by sensory illusion/hallucinations (9 of 45, 20%).

Clinical responses summary

Comparison of the distribution of clinical effects between the two hemispheres showed no difference in any of the explored substructures. Body scheme alterations were the only lateralized clinical effects, being exclusively evoked in the non-dominant hemisphere. When considering dominant and non-dominant lobes together, the distributions of each clinical effect did not vary significantly across the various substructures.

One thousand and ninety-eight electrical stimulations were analysed by logistic regression. We chose the inferior parietal lobule as reference factor for the electrical stimulation site, considered as the categorical variable. Results of all univariate and multivariate analyses for each semiological category are shown in Supplementary Table 4.

The occurrence of somatosensory sensations, motor symptoms and dysarthria were significantly associated with electrical stimulation in the postcentral gyrus (OR 5.83, $P < 0.001$; OR 8.77, $P < 0.001$; OR 5.44, $P = 0.011$, respectively) and electrical stimulation frequency (somatosensory sensations and dysarthria were more likely to occur with high-frequency stimulation, OR 1.78, $P = 0.008$ and OR 12.09, $P = 0.001$, whereas motor symptoms were more likely to be evoked by low-frequency stimulation, OR 0.52, $P = 0.006$).

The probability of evoked sensory illusions or hallucinations was highest in the intraparietal sulcus (OR 8.68, $P < 0.001$), followed by the precuneus (OR 2.14, $P = 0.042$), after controlling for electrical stimulation frequency (more likely to occur with high-frequency

stimulation, OR 7.39, $P < 0.001$). The postcentral gyrus (OR 0.24, $P = 0.029$) and the posterior cingulum (OR 0.16, $P = 0.016$) were negatively associated with the occurrence of sensory illusions or hallucinations.

The occurrence of vertigo was significantly associated only with electrical stimulation frequency (more likely to occur with high-frequency stimulation, OR 8.06, $P = 0.001$).

We did not find any relevant association with the occurrence of body scheme alteration.

We found a significant probability to obtain eyeball/eyelid movements or sensations when stimulating the intraparietal sulcus (OR 4.35, $P = 0.047$), after controlling for electrical stimulation frequency (more likely to occur with high-frequency stimulation, OR 2.88, $P = 0.019$) and for the presumed location of the epileptogenic zone in the parietal lobe (OR 4.03, $P = 0.005$).

Finally multimodal responses were more likely to occur in the postcentral gyrus (OR 8.33, $P = 0.006$), after controlling for epilepsy duration (OR 1.04, $P = 0.026$) and electrical stimulation frequency (more likely to occur with high-frequency stimulation, OR 4.98, $P = 0.001$).

Hemispheric dominance and the presence of parietal structural lesion on brain MRI scan were not associated with any type of clinical response.

Discussion

The current study offers a complete overview of the physiologic and 'paraphysiologic' responses evoked by low- and high-frequency electrical stimulation of the parietal cortex in a consecutive series of patients with drug-resistant focal epilepsy who underwent stereo-EEG recordings as part of the presurgical work-up. From a methodological standpoint, our results confirm expectations: low-frequency stimulations had an average efficiency rate of 26%, whereas high-frequency stimulations reached ~50%, regardless of parietal cortex involvement in the epileptogenic area. Furthermore, the use of the stereotactic planning software, to analyse the post-implantation images, allowed a highly precise anatomical localization of each recording contact of the implanted electrodes (Cardinale *et al.*, 2013, 2015).

There are limitations of our study that need to be considered. Electrical stimulations have been performed in the context of a clinical protocol aimed to delineate the epileptogenic zone and mapping the eloquent regions in a cohort of patients with epilepsy, undergoing the presurgical work-up, evaluating elementary clinical responses. Thus our retrospective analysis cannot guarantee the complete seeking of all negative and positive symptoms potentially expected in each specific region. Furthermore, we cannot guarantee a complete and unequivocal reliability of the subjective symptoms, as there is an unavoidable degree of difference in age, psychometric and cultural profile of every patient. Finally, electrical stimulation permitting to

stimulate the patient only during a few seconds, may not be the best tool to explore integrated superior functions, necessitating probably a longer time to evaluate these complex integrate skills.

To our knowledge, no other published studies report the evoked clinical responses from electrical stimulation over as large an extent and in as much detail, of the parietal cortex as ours. However, the functional architecture of the parietal cortex has been widely explored and it is well known that very heterogeneous stimuli and tasks produce parietal activation in the brain (Sack, 2009). A number of studies have demonstrated the role of the parietal cortex as a fundamental associative structure in the processes of sensory-motor integration, with the different subregions involved in different functions related to processing of sensory data, memory, attention and motor anticipation (Nachev and Husain, 2006; Cabeza *et al.*, 2008). Our analysis confirmed the multiplicity of functions of the parietal cortex in all the explored subregions in both hemispheres.

Postcentral gyrus, posterior part of paracentral lobule and parietal operculum

In this subregion, we found a significant association with the occurrence of somatosensory sensations, motor symptoms, dysarthria and multimodal responses. The postcentral gyrus is a primary sensory area, defined by Penfield as one of the ‘essential eloquent cortices’ (Penfield and Jasper, 1954), easy to functionally map with electrical stimulation and with a well-defined contralateral somatotopic response (Selimbeyoglu and Parvizi, 2010). The parietal operculum represents a secondary somatosensory area. The occurrence of somatosensory responses is considered obvious. Regarding the motor responses, these can occur after stimulations not only of the primary motor area, localized in the precentral gyrus, but up to 2 cm behind the central sulcus (Uematsu *et al.*, 1992). The elicitation of dysarthria might be explained by the somatotopic sensory over-representation of the lips, jaw and tongue in the parietal operculum (Nelson *et al.*, 1980). A recent functional MRI study investigated the organization of oro-facial articulators and showed the left parietal operculum as part of a network of overlapping brain areas involved in the laryngeal and supralaryngeal motor control (Grabski *et al.*, 2012). The dual-stream model of speech processing by Hickok and Poeppel postulates the existence of a ventral stream that is largely bilaterally organized and processes speech signals for comprehension and a dorsal stream that is strongly left-hemisphere dominant and maps acoustic speech signals to frontal lobe articulatory networks. They showed that the dorsal stream projects dorso-posteriorly toward inferior parietal (including the operculum) and posterior frontal lobe regions and is involved in auditory-motor integration by mapping acoustic speech sounds to articulatory representations (Poeppel and Hickok, 2004; Hickok and

Poeppel, 2007). A previous study found a lower prevalence (6%) of transitory speech disturbances after electrical stimulation of the secondary somatosensory area, in a cohort of 14 patients (Mazzola *et al.*, 2006). Consequently the occurrence of multimodal responses demonstrates that the postcentral gyrus has a significant level of sensory-motor integration, though being a primary cortex (Rothwell, 1994).

Posterior cingulum

Previous studies showed motor and neurovegetative symptoms after stimulating this area (Fink *et al.*, 1997; Vogt, 2005). The established functions of this region include the integration of visual information (Vogt *et al.*, 2006) and the spatial orientation and spatial memory (Sutherland *et al.*, 1988; Harker and Whishaw, 2004). Our data and analysis do not provide evidence regarding these complex roles. However, electrical stimulation of this area in our study provoked a heterogeneous number of clinical responses and this is likely related to its highly integrative function. After somatosensory and motor symptoms, the next most frequent symptoms were vertigo and neurovegetative. The anterior cingulum has been shown to have a role in pain mechanisms (Maarrawi *et al.*, 2007), in parasympathetic control of heart rhythm (Lane *et al.*, 2013) and overall in autonomic responses (Critchley *et al.*, 2003). There seems to be much less evidence for the involvement of the posterior cingulum in the neurovegetative functions. Future studies may investigate the function of this area in modulating the autonomic nervous system and examine potential differences with the function of the anterior cingulum. In the posterior cingulum, we also obtained two psychic phenomena, one in each hemisphere, including feelings of ‘being like in a parallel world’ as well as depersonalization or derealization. We considered these symptoms as part of the spectrum of the out-of-body experiences or rather complex visuo-spatial perception with location of the own body in extra-personal space (Blanke and Mohr, 2005).

Precuneus

This brain region is one of the less accurately mapped of the entire cortex, most likely due to its deep anatomical location and the low number of focal lesions described in this area. However, its strategic position and widespread connections suggest how the precuneus represents an associative area with various relevant functions. Neuroimaging studies demonstrated a central role of this region in a wide spectrum of highly integrated tasks, including visuo-spatial imagery, episodic memory retrieval and self-processing operations (Kircher *et al.*, 2000; Hanakawa *et al.*, 2003; Cavanna and Trimble, 2006). In both hemispheres the prevalent clinical responses of electrical stimulations were visual illusion or hallucinations, in line with a previous study (Richer *et al.*, 1991), supporting the role in complex and integrated tasks. Here we also obtained a high number

of eye/eyelid movements or sensations (nine overall). Thier and Andersen (1998) elicited saccades by electrical micro-stimulation of the posterior medial parietal cortex of monkey, postulating the hypothesis of a ‘medial parietal eye field’, in addition to the already known ‘lateral parietal eye field’, located in the parietal bank of the intraparietal sulcus (Andersen *et al.*, 1990). Another relatively frequent response in the precuneus (six in the non-dominant and one in the dominant) was vertigo. Kahane *et al.* (2003) mapped the human vestibular cortex by electrical stimulation in 260 patients with partial epilepsy and four vestibular symptoms were electrically induced in the precuneus (three in the right side, one in the left side). A case of a patient with a circumscribed ependymoma in the right paramedian precuneus was reported, describing vestibular symptoms reproduced by electrical stimulation of the lesional area (Wiest *et al.*, 2004). The vestibular responses of this region may be likely related to its role in the processing of spatial information relative to the position of the subject, allowing the control of body movements. In the non-dominant precuneus we also obtained two psychic phenomena (see above for the interpretation).

Intraparietal sulcus

The intraparietal sulcus is an anatomically constant sulcus in humans, larger and more expanded than in monkeys, though most of the anatomo-functional studies in this area have been performed on macaques. The intraparietal sulcus has a functional relevance in the integration of information such as spatial coordinates of objects, the position of body parts in space, eye movement data, or geometrical properties of objects such as shape, size and orientation, with the aim to guide and control action in space (Duhamel *et al.*, 1992; Colby *et al.*, 1993; Sakata *et al.*, 1995; Rizzolatti *et al.*, 1998; Grefkes and Fink, 2005). It is also involved in cognitive functions such as spatial orientation and local/global processing (Fink *et al.*, 1999; Thiel *et al.*, 2004). We found a significant association with the occurrence of illusions/hallucinations and eyeball/eyelid movements or sensations, proving the involvement of this region in visuo-motor tasks and in integrating neural signals from different sensory modalities. Swisher *et al.* (2007) also obtained a number of visual illusions/hallucinations during the mapping of the human intraparietal sulcus by direct visual stimulation during a functional neuroimaging study.

Superior parietal lobule

The multiple types of clinical responses obtained in our analysis support the integrative function of the superior parietal lobule, in agreement with published data. Previous studies suggested the involvement of this region in the attention towards visual and tactile stimuli (Pardo *et al.*, 1991; Corbetta *et al.*, 1993), in integration of visual stimuli (Corbetta *et al.*, 1995), in visually guided

reaching (Clower *et al.*, 1996; Rizzolatti *et al.*, 1997), and in sensori-motor integration even in relation to body image representation (Wolpert *et al.*, 1998; Sirigu and Duhamel, 2001). Indeed, our data reveal a spectrum of responses including somatosensory sensations, visual illusions, body scheme alterations, motor symptoms, eye movements/sensations and multimodal responses.

Inferior parietal lobule

We found heterogeneous responses also in this region, mostly somatosensory sensations, sensory illusions/hallucinations and motor symptoms; we even found vertigo, body scheme alterations and multimodal response. Previous electrical stimulation studies of the inferior parietal lobule in humans showed body scheme alterations (‘urge to move’ body parts or illusions of such movements), out of body experiences, somatosensory sensations, vertigo, anomia in both hemispheres. Hemi-spatial neglect was reported only in the non-dominant hemisphere, while speech arrest, conduction aphasia, finger agnosia and acalculia were induced only in the dominant hemisphere (Selimbeyoglu and Parvizi, 2010). In the dominant inferior parietal lobule we evoked two speech arrests; this is in line with the dominant inferior parietal lobule being part of the cortical network for expressive language function (Lehericy *et al.*, 2000). In the non-dominant inferior parietal lobule we observed the highest number of body scheme alterations. This type of response was evoked only by high-frequency electrical stimulation and only in the non-dominant hemisphere. This was the only clinical effect that showed a significant hemispheric lateralization. Previous studies showed a distinction between body scheme alterations following dominant posterior parietal cortex damage such as autotopagnosia (a disorder of body awareness, where patients are not able to localize and orient parts of their body when asked by examiners), finger agnosia and left-right confusion compared with lesions in the non-dominant posterior parietal cortex as left hemisomatognosia (Cutting, 1991; Aglioti *et al.*, 1996). In the dominant hemisphere, these disturbances are thought to be related to an altered representation of the concept of body scheme, mainly associated with language. In the non-dominant hemisphere the autoscopic phenomena are prevalent such as sense of disembodiment or active hatred of the paralysed limb (misoplegia) (Moss and Turnbull, 1996). These symptoms could originate from a disturbance of sensorimotor integration in the right temporo-parietal cortex and in the vestibular representation of the posterior insula (Blanke and Metzinger, 2009).

The inferior parietal lobule is a neocortical area, belonging to the heteromodal association cortex (HASC), which also includes the temporal planum, the dorsolateral prefrontal cortex and the inferior prefrontal cortex. These cortical areas are ‘epicentres of a large-scale distributed network, where each epicentre potentially belongs to multiple networks which intersect each other’ (Mesulam,

1998). The inferior parietal lobule also has a role in processing data from visual, auditory and somatosensory association cortices (Geschwind, 1964), in selective attention (Heilman *et al.*, 1993) and in visuo-spatial processing (Petersen *et al.*, 1989).

Conclusions

The multiple and multimodal functions of the human brain are not yet completely understood and defined, despite the relevant advancement of neurophysiologic and functional neuroradiological techniques. A significant amount of evidence suggests the crucial role of the parietal lobes in different networks involved in complex integrative functions.

In summary, in the postcentral gyrus we found a significant probability to evoke somatosensory sensations, motor symptoms, dysarthria and multimodal responses. When we relate these findings to the results of a stereo-EEG study analysing clinical manifestations of parietal lobe seizures (Bartolomei *et al.*, 2011), we note that somatosensory symptoms were one of the most frequent subjective symptoms of seizures arising from the parietal operculum as well as motor manifestations (i.e. hyperkinetic behaviour) were quite frequent in seizures from the inferior parietal lobule or the parietal operculum. In the intraparietal sulcus and precuneus we obtained a relevant occurrence of sensory illusions or hallucinations. This subjective manifestation has been described also in seizures originating from the precuneus (Bartolomei *et al.*, 2011). In the intraparietal sulcus a significant probability to obtain eyeball/eyelid movements or sensations was also detected. This was the only symptom associated with the presumed location of the epileptogenic zone in the parietal lobe; we cannot therefore exclude an interaction of the epileptogenic network for the occurrence of this response. Versive phenomena of the head and eyes are frequent symptoms of seizures affecting regions close to or within the intraparietal sulcus (Bartolomei *et al.*, 2011).

We believe our study to be the only currently available complete revision of electrical stimulation in the entire parietal lobe with the aim to evaluate the neurophysiology of this relevant brain region. By providing a general overview of the polyhedral function of the parietal cortex it can form a strong basis for the formulation of novel hypotheses focused on specific subregions of the parietal lobe perhaps using more specific and complex tasks.

Acknowledgement

We thank Ms Kristin Heggeli for the linguistic revision.

Supplementary material

Supplementary material is available at *Brain* online.

Web resource

3D Slicer. <http://www.slicer.org>.

References

- Andersen RA, Bracewell RM, Barash S, Gnadt JW, Fogassi L. Eye position effects on visual, memory, and saccade-related activity in areas LIP and 7a in the macaque. *J Neurosci* 1990; 10: 1176–96.
- Andersen RA, Buneo CA. Intentional maps in posterior parietal cortex. *Annu Rev Neurosci* 2002; 25: 189–220.
- Aglioti S, Smania N, Manfredi M, Berlucchi G. Disownership of left hand and objects related to it in a patient with right brain damage. *Neuroreport* 1996; 8: 293–6.
- Bartolomei F, Gavaret M, Hewett R, Valton L, Aubert S, Régis J, et al. Neural networks underlying parietal lobe seizures: a quantified study from intracerebral recordings. *Epilepsy Res* 2011; 93: 164–76.
- Blanke O, Metzinger T. Full-body illusions and minimal phenomenal selfhood. *Trends Cogn Sci* 2009; 13: 7–13.
- Blanke O, Mohr C. Out-of-body experience, heautoscopy, and autoscopic hallucination of neurological origin. Implications for neurocognitive mechanisms of corporeal awareness and self-consciousness. *Brain Res Brain Res Rev* 2005; 50: 184–99.
- Cabeza R, Ciaramelli E, Olson IR, Moscovitch M. The parietal cortex and episodic memory: an attentional account. *Nat Rev Neurosci* 2008; 9: 613–25.
- Cardinale F, Cossu M, Castana L, Casaceli G, Schiariti MP, Miserocchi A, et al. Stereoelectroencephalography: surgical methodology, safety, and stereotactic application accuracy in 500 procedures. *Neurosurgery* 2013; 72: 353–66.
- Cardinale F, Pero G, Quilici L, Piano M, Colombo P, Moscato A, et al. Cerebral angiography for multimodal surgical planning in epilepsy surgery: description of a new three-dimensional technique and literature review. *World Neurosurg* 2015. Advance Access published on March 25, 2015, doi: 10.1016/j.wneu.2015.03.028.
- Cavanna AE, Trimble MR. The precuneus: a review of its functional anatomy and behavioural correlates. *Brain* 2006; 129: 564–83.
- Clower DM, Hoffman JM, Votaw JR, Faber TL, Woods RP, Alexander GE. Role of posterior parietal cortex in the recalibration of visually guided reaching. *Nature* 1996; 383: 618–21.
- Colby CL, Duhamel JR, Goldberg ME. Ventral intraparietal area of the macaque: anatomic location and visual response properties. *J Neurophysiol* 1993; 69: 902–14.
- Colby CL, Goldberg ME. Space and attention in parietal cortex. *Annu Rev Neurosci* 1999; 22: 319–49.
- Corbetta M, Miezin FM, Shulman GL, Petersen SE. A PET study of visuospatial attention. *J Neurosci* 1993; 13: 1202–26.
- Corbetta M, Shulman GL, Miezin FM, Petersen SE. Superior parietal cortex activation during spatial attention shifts and visual feature conjunction. *Science* 1995; 270: 802–5.
- Critchley M. *The parietal lobes, 1953*. London: Arnold. Reprint, New York, NY: Habner, 1969.
- Critchley HD, Mathias CJ, Josephs O, O'Doherty J, Zanini S, Dewar BK, et al. Human cingulate cortex and autonomic control: converging neuroimaging and clinical evidence. *Brain* 2003; 126: 2139–52.
- Cutting J. Delusional misidentification and the role of the right hemisphere in the appreciation of identity. *Br J Psychiat* 1991; (Suppl): 70–5.
- Duhamel JR, Colby CL, Goldberg ME. The updating of the representation of visual space in parietal cortex by intended eye movements. *Science* 1992; 255: 90–2.
- Duvernoys HM, editor. *The human brain surface, blood supply, and three-dimensional sectional anatomy*. New York: Springer Wien New York; 1999.

- Fink GR, Frackowiak RS, Pietrzyk U, Passingham RE. Multiple non-primary motor areas in the human cortex. *J Neurophysiol* 1997; 77: 2164–74.
- Fink GR, Marshall JC, Halligan PW, Dolan RJ. Hemispheric asymmetries in global/local processing are modulated by perceptual salience. *Neuropsychologia* 1999; 37: 31–40.
- Fischl B. *FreeSurfer*. *Neuroimage* 2012; 62: 774–81.
- Gering DT, Nabavi A, Kikinis R, Grimson WEL, Hata N, Everett P, et al. An integrated visualization system for surgical planning and guidance using image fusion and interventional imaging. In: Taylor C, Colchester A, editors. *Proceedings from the Second International Conference on Medical Image Computing and Computer-Assisted Intervention*. Cambridge: Springer-Verlag; 1999. p 809–819.
- Geschwind N. The development of the brain and the evolution of language. In: Stuart CIJM, editor. *Report of the 15th annual RTM on linguistic and language studies*. Washington, DC: Georgetown University Press; 1964. pp. 155–69.
- Gordon B, Lesser RP, Rance NE, Hart J Jr, Webber R, Uematsu S, et al. Parameters for direct cortical electrical stimulation in the human: histopathologic confirmation. *Electroencephalogr Clin Neurophysiol* 1990; 75: 371–77.
- Grabski K, Lamalle L, Vilain C, Schwartz JL, Vallée N, Tropes I, et al. Functional MRI assessment of orofacial articulators: neural correlates of lip, jaw, larynx, and tongue movements. *Hum Brain Mapp* 2012; 33: 2306–21.
- Grefkes C, Fink GR. The functional organisation of the intraparietal sulcus in humans and monkeys. *J Anat* 2005; 207: 3–17.
- Hanakawa T, Immisch I, Toma K, Dimyan MA, Van Gelderen P, Hallett M. Functional properties of brain areas associated with motor execution and imagery. *J Neurophysiol* 2003; 89: 989–1002.
- Harker KT, Whishaw IQ. A reaffirmation of the retrosplenial contribution to rodent navigation: reviewing the influences of lesion, strain, and task. *Neurosci Biobehav Rev* 2004; 28: 485–96.
- Heilman KM, Watson RT, Valenstein E, Damasio AR. Localization of lesions in neglect. In: Kertesz A, editor. *Localization in neuropsychology*. New York, NY: Academic Books; 1993. pp. 471–92.
- Hickok G, Poeppel D. The cortical organization of speech processing. *Nat Rev Neurosci* 2007; 8: 393–402.
- Jenkinson M, Beckmann CF, Behrens TEJ, Woolrich MW, Smith SM. *FSL*. *Neuroimage* 2012; 62: 782–90.
- Jenkinson M, Smith SM. A global optimisation method for robust affine registration of brain images. *Med Image Anal* 2001; 5: 143–56.
- Kahane P, Hoffmann D, Minotti L, Berthoz A. Reappraisal of the human vestibular cortex by cortical electrical stimulation study. *Ann Neurol* 2003; 54: 615–24.
- Kircher TT, Senior C, Phillips ML, Benson PJ, Bullmore ET, Brammer M, et al. Towards a functional neuroanatomy of self-processing: effects of faces and words. *Cogn Brain Res* 2000; 10: 133–44.
- Lachhwani D, Dinner DS. *Cortical stimulation in the definition of eloquent cortical areas*. Amsterdam, The Netherlands: Elsevier; 2004.
- Laff R, Mesad S, Devinski O. Epileptic kinetopsia: ictal illusory motion perception. *Neurology* 2003; 61: 1262–4.
- Lane RD, Weidenbacher H, Smith R, Fort C, Thayer JF, Allen JJ. Subgenual anterior cingulate cortex activity covariation with cardiac vagal control is altered in depression. *J Affect Disord* 2013; 150: 565–70.
- Lehericy S, Cohen L, Bazin B, Samson S, Giacomini E, Rougetet R, et al. Functional MR evaluation of temporal and frontal language dominance compared with the Wada test. *Neurology* 2000; 54: 1625–33.
- Lim SH, Dinner DS, Pillay PK, Lüders H, Morris HH, Klem G, et al. Functional anatomy of the human supplementary sensorimotor area: results of extraoperative electrical stimulation. *Electroencephalogr Clin Neurophysiol* 1994; 91: 179–93.
- Maarrawi J, Peyron R, Mertens P, Costes N, Magnin M, Sindou M, et al. Motor cortex stimulation for pain control induces changes in the endogenous opioid system. *Neurology* 2007; 69: 827–34.
- Matsushashi M, Ikeda A, Ohara S, Matsumoto R, Yamamoto J, Takayama M, et al. Multisensory convergence at human temporo-parietal junction – epicortical recording of evoked responses. *Clin Neurophysiol* 2004; 115: 1145–60.
- Mazzola L, Isnard J, Manguiere F. Somatosensory and pain responses to stimulation of the second somatosensory area (SII) in humans. A comparison with SI and insular responses. *Cerebral Cortex* 2006; 16: 960–8.
- Mesulam MM. From sensation to cognition. *Brain* 1998; 121: 1013–52.
- Morris HH, Lüders H, Lesser RP, Dinner DS, Hahn J. Transient neuropsychological abnormalities (including Gerstmann’s syndrome) during cortical stimulation. *Neurology* 1984; 34: 877–83.
- Moss AD, Turnbull OH. Hatred of the hemiparetic limbs (misoplegia) in a 10 year old child. *J Neurol Neurosurg Psychiatry* 1996; 61: 210–1.
- Nathan SS, Sinha SR, Gordon B, Lesser RP, Thakor NV. Determination of current density distributions generated by electrical stimulation of the human cerebral cortex. *Electroencephalogr Clin Neurophysiol* 1993; 86: 183–92.
- Nelson RJ, Sur M, Felleman DJ, Kaas JH. Representations of the body surface in postcentral parietal cortex of *Macaca Fascicularis*. *J Comp Neurol* 1980; 192: 611–43.
- Nachev P, Husain M. Disorders of visual attention and the posterior parietal cortex. *Cortex* 2006; 42: 766–73.
- Nieuwenhuys R, Voogd J, van Huijzen C. *The human central nervous system*. Berlin, Heidelberg, New York, NY: Springer-Verlag; 2008.
- Pardo JV, Fox PT, Raichle ME. Localization of a human system for sustained attention by positron emission tomography. *Nature* 1991; 349: 61–4.
- Penfield W, Boldrey E. Somatic motor and sensory representations in the cerebral cortex of man as studied by electrical stimulation. *Brain* 1937; 60: 389–443.
- Penfield W, Jasper H. *Epilepsy and the functional anatomy of the human brain*. London: Churchill; 1954. p. 773.
- Penfield W, Rasmussen T. *The cerebral cortex of man. A clinical study of localization of function*. New York, NY: Macmillan; 1957.
- Petersen SE, Robinson DL, Currie JN. Influences of lesions of parietal cortex on visual spatial attention in humans. *Exp Brain Res* 1989; 76: 267–80.
- Poeppel D, Hickok G. Towards a new functional anatomy of language. *Cognition* 2004; 92: 1–12.
- Rank JB. Which elements are excited in electrical stimulation of mammalian central nervous system: a review. *Brain Res* 1975; 98: 417–40.
- Richer F, Martinez M, Cohen H, Saint-Hilaire JM. Visual motion perception from stimulation of the human medial parieto-occipital cortex. *Exp Brain Res* 1991; 87: 649–52.
- Rizzolatti G, Fogassi L, Gallese V. Parietal cortex: from sight to action. *Curr Opin Neurobiol* 1997; 7: 562–67.
- Rizzolatti G, Luppino G, Matelli M. The organization of the cortical motor system: new concepts. *Electroencephalogr Clin Neurophysiol* 1998; 106: 283–96.
- Rothwell J. *Control of human voluntary movement*. London: Chapman & Hall; 1994.
- Sack AT. Parietal cortex and spatial cognition. *Behav Brain Res* 2009; 202: 153–61.
- Sakata H, Taira M, Murata A, Mine S. Neural mechanisms of visual guidance of hand action in the parietal cortex of the monkey. *Cereb Cortex* 1995; 5: 429–38.
- Selimbeyoglu A, Parvizi J. Electrical stimulation of the human brain: perceptual and behavioral phenomena reported in the old and new literature. *Front Hum Neurosci* 2010; 4: 46.

- Siegel AM, Andersen RA, Freund H-J, Spencer DD. The parietal lobes. *Advances in neurology*, volume 93. Philadelphia : Lippincott Williams & Wilkins; 2003, p. 372.
- Sirigu A, Duhamel JR. Motor and visual imagery as two complementary but neurally dissociable mental processes. *J Cogn Neurosci* 2001; 13: 910–19.
- Sutherland RJ, Wishaw IQ, Kolb B. Contributions of cingulate cortex to two forms of spatial learning and memory. *J Neurosci* 1988; 8: 1863–72.
- Swisher JD, Halko MA, Merabet LB, McMains SA, Somers DC. Visual topography of human intraparietal sulcus. *J Neurosci* 2007; 27: 5326–37.
- Talairach J, Bancaud J. Stereotaxic approach to epilepsy: methodology of anatomo-functional stereotactic investigations. *Prog Neurol Surg* 1973; 5: 297–354.
- Thiel CM, Zilles K, Fink GR. Cerebral correlates of alerting, orienting and reorienting of visuospatial attention: an event-related fMRI study. *Neuroimage* 2004; 21: 318–28.
- Thier P, Andersen RA. Electrical microstimulation distinguishes distinct saccade-related areas in the posterior parietal cortex. *J Neurophysiol* 1998; 80: 1713–35.
- Uematsu S, Lesser R, Fisher RS, Gordon B, Hara K, Krauss GL, et al. Motor and sensory cortex in humans: topography studied with chronic subdural stimulation. *Neurosurgery* 1992; 31: 59–72.
- Vogt BA. Pain and emotion interactions in subregions of the cingulate gyrus. *Nat Rev Neurosci* 2005; 6: 533–44.
- Vogt BA, Vogt L, Laureys S. Cytology and functionally correlated circuits of human posterior cingulate areas. *Neuroimage* 2006; 29: 452–66.
- Wiest G, Zimprich F, Prayer D, Czech T, Serles W, Baumgartner C. Vestibular processing in human paramedian precuneus as shown by electrical cortical stimulation. *Neurology* 2004; 62: 473–5.
- Wolpert DM, Goodbody SJ, Husain M. Maintaining internal representations: the role of the human superior parietal lobe. *Nat Neurosci* 1998; 1: 529–33.