

Pharmacological and environmental factors in primary angle-closure glaucoma

Ian Subak-Sharpe[†], Sancy Low^{†‡}, Winifred Nolan[§], and Paul J. Foster^{*†‡}

[†]Moorfields Eye Hospital, London, UK; [‡]UCL Institute of Ophthalmology, London, UK, and [§]Birmingham and Midland Eye Centre, Birmingham, UK

Introduction or background: A large number of drug classes have now been reported to provoke angle closure in high-risk individuals. The mechanism of action can be generalized into three main categories: sympathomimetic, parasympatholytic and idiosyncratic reactions.

Sources of data: This review of the ophthalmic literature provides a clinical summary of primary angle-closure glaucoma (PACG) and its management.

Areas of agreement: External stimuli (pharmacological and environmental) may induce acute, and more often, asymptomatic angle closure, which carries a significant risk of glaucoma.

Growing points: Whenever in doubt, patients at risk of PACG who are starting on drug therapy known to provoke angle closure or aggravate the condition should be referred for detailed gonioscopic examination of the anterior chamber by an ophthalmologist.

Areas for developing research: The use of new imaging methods such as anterior segment optical coherence tomography to assess the presence or risk of angle closure is gaining popularity, and may offer a more rapid method of identifying people who are at risk of sight loss from angle-closure glaucoma precipitated by non-ophthalmological medication.

Keywords: angle-closure/glaucoma/drugs/environment

Background

Accepted: October 13,
2009

*Correspondence to:
P. Foster, Department of
Epidemiology and
Molecular Genetics, UCL
Institute of
Ophthalmology, 11-43
Bath Street, London EC1V
9EL, UK. E-mail: p.foster@
ucl.ac.uk

Glaucoma is the world's commonest cause of irreversible blindness, currently affecting 60 million people with 8.4 million blind, and projected to rise to 80 million by 2020 with 11.2 million blind.¹ It is an optic neuropathy associated with characteristic cupping of the optic disc and progressive visual field loss. In the disease, the retinal ganglion cell axons are damaged as they enter and transit through the optic disc. The pathophysiology of the condition is attributed to either direct pressure, causing a block of axoplasmic flow, or indirect reduction in

optic nerve head blood flow, caused by a lowering of the vascular perfusion pressure.² However, the balance between these two mechanisms is often unclear.

For clinical purposes, glaucoma is normally classified according to the presence or absence of obstruction by the iris to the outflow pathway of aqueous humour at the level of the proximal trabecular meshwork in the anterior chamber drainage angle (the angle between the peripheral cornea and the iris). Such cases are referred to as angle-closure glaucoma and open-angle glaucoma, respectively. While the prevalence of primary open-angle glaucoma is greater than primary angle-closure glaucoma (PACG) in the Western world, the primary angle closure accounts for 50% of global glaucoma blindness.¹

There are three conceptual stages in the natural history of PACG. Initially, contact between the peripheral iris and the trabecular meshwork occurs with no clinically discernable impact on the intraocular pressure (IOP) or the tissues of the trabecular meshwork. These cases are termed 'anatomically narrow angle' or 'primary angle-closure suspects'. In many cases, this progresses to the formation of adhesions between iris and trabecular meshwork, or an increase in the IOP. This stage is termed 'primary angle closure' and denotes an established disease. Unless promptly and effectively managed, the condition may progress to cause glaucomatous optic neuropathy, or 'PACG', which causes significant functional impairment of the vision.³

The clinical course through these conceptual stages can be 'acute' (indicating a rapid onset of extremely high IOP causing symptoms of pain, redness and reduced vision) or 'chronic' (indicating an asymptomatic course). Most textbooks and review articles that accounts for PACG emphasize the presence of symptoms as a defining feature of acute angle closure (AAC). When treated promptly and effectively, acute cases (Fig. 1) can usually be prevented from developing glaucomatous optic neuropathy or significant visual deficits³ However, angle closure often follows an asymptomatic course, referred to as 'chronic' angle closure. Eyes with the asymptomatic ('chronic') form of the disease typically present late to medical services often with advanced glaucomatous damage and visual field loss. From population-based research in the high-risk populations of Asia, it appears that more than 50% of cases of angle-closure glaucoma remain asymptomatic until there is profound loss of vision in the later stages.⁴⁻⁷ Despite early treatment, some patients who initially present with acute symptoms, will progress to develop chronic angle-closure glaucoma. Hence, long-term follow-up may be required for some patients after AAC.

Angle closure in Europe is less common. In the AAC register at Moorfields Eye Hospital serving Greater London, an average of one case per week presents to eye casualty with the condition (personal

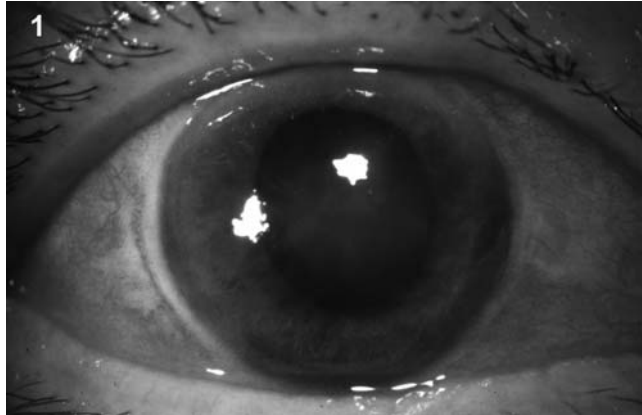


Fig. 1 An eye with AAC, with clinical signs of a mid-dilated pupil, hazy cornea and injected blood vessels (courtesy of medical illustrations, Moorfields Eye Hospital).

communication, D. Siriwardena). In the Rotterdam eye study, 2% of an unselected population aged 55 years and over had a narrow anterior chamber angle at risk of closure on examination of the limbal chamber depth. This was twice as high in women as men.⁸ In the Egna-Neumarkt study in Northern Italy, angle-closure glaucoma was found in 0.6% of the population, accounting for a quarter of all the glaucoma cases.

Drugs and poisons, both therapeutic and recreational, as well as environmental factors have been linked to the development of angle closure in susceptible patients. These often present with symptoms, but may have a ‘chronic’ insidious course leading to PACG. Best current evidence does not support the use of a classification system focused on symptomatology to describe PACG.⁹ This review is focused on the drug and environmental mechanisms that may trigger angle closure and lead to glaucomatous optic neuropathy if left untreated. It will allow the reader to identify patients at risk and understand the rationale behind the treatment of these cases.¹⁰

Diagnostic provocation of the occludable angle

The use of eye drops (pilocarpine and phenylephrine together) to assess a narrow angle that may be at risk of occluding and predispose a patient to PACG is known as the ‘Mapstone provocative test’.¹¹ The rationale of the Mapstone test is that simultaneous contraction of the sphincter and dilator muscles of the iris in opposite directions leads to pupil-block angle closure (Fig. 2), triggering elevated IOP in an at-risk eye. Alternatively, more physiological stimuli may be used: the

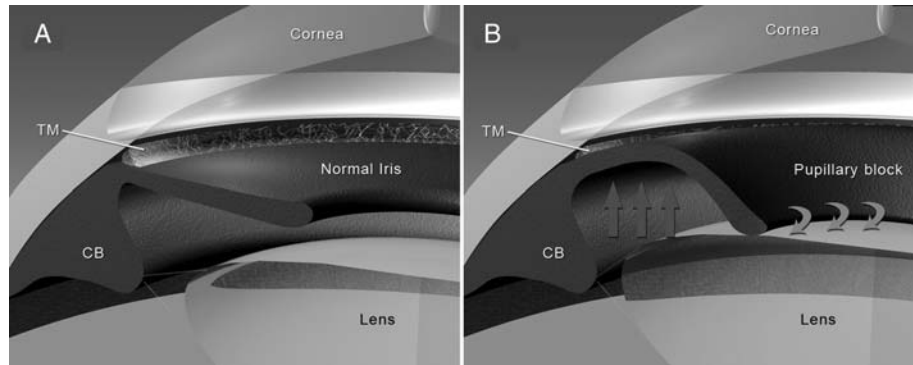


Fig. 2 (A) Normal anterior chamber angle anatomy: the trabecular meshwork (TM) is found at the angle between the iris and the cornea, and constitutes the main drainage structure that removes aqueous humour (AH) from the eye. AH is produced by the ciliary body (CB), passing through the space between the iris and the lens into the anterior chamber, finally draining out of the eye from the TM. (B) In pupil-block angle closure, AH is unable to pass through the anterior chamber due to the pupillary sphincter being adherent to the anterior lens (curved arrows). A positive force in the posterior chamber due to AH build-up (vertical arrows) leads to a rise in IOP, and blockage of the TM and anterior chamber angle (illustrations for Figs 2–4 are courtesy of Mr Alan Lacey).

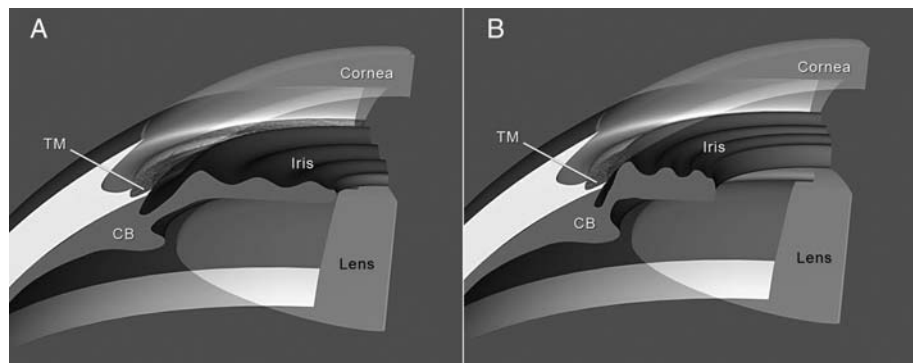


Fig. 3 (A) This figure demonstrates a normal but narrow angle before pupil dilation. The peripheral iris is thick but the trabecular meshwork (TM) is visible for the sector of the eye in this illustration. (B) After pupillary dilation, there is marked crowding of the peripheral iris and occlusion of the drainage angle.

darkroom test¹² or prone-position test¹³ may be performed by either placing the patient in a darkroom or a prone-position for 60–90 min. If the peripheral iris obstructs the trabecular meshwork and leads to IOP elevation of 8 mmHg or more, this is considered a positive result. These two tests can be combined in the darkroom prone-position test.^{14,15}

Pharmacological mydriasis/dilation of the pupil with topical phenylephrine (sympathomimetic), atropine and cyclopentolate (both anticholinergic parasympatholytics) can precipitate angle closure due to crowding of the peripheral iris in the fully dilated state (Fig. 3). There may be a lag

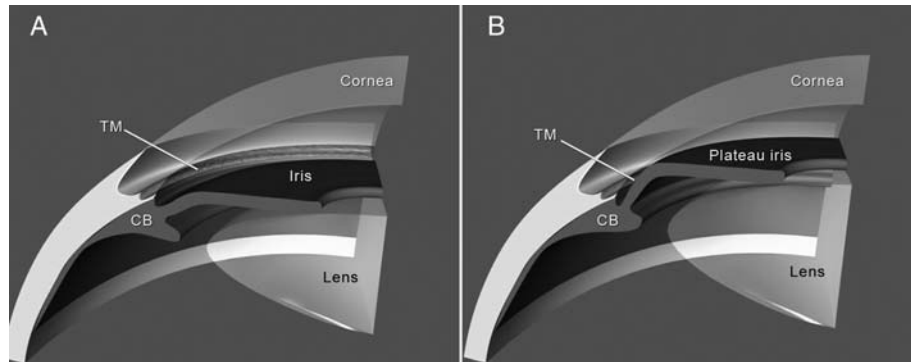


Fig. 4 (A) This figure demonstrates a normal and wide-open angle. (B) In contrast to (A), this diagram shows a particular iris configuration known as plateau iris, which occurs in younger patients, where the peripheral iris makes a sharp angulation at the drainage angle, causing it to be blocked. The central iris profile is flat, compared with the mechanism illustrated in Fig. 2b.

of 1–4 h before the onset of symptoms secondary to significantly raised IOP. Resolution of pharmacological dilation can also precipitate AAC through pupil-block in a similar way to the Mapstone provocative test mentioned above (Fig. 2).

Apart from topical sympathomimetic or anticholinergic eye drops, angle closure has now been reported in many classes of drugs, some of which affect autonomic function and may result in permanent visual loss and glaucomatous optic neuropathy. The patients most at risk of developing angle closure are typically older, female patients with shallow anterior chambers. They are often, but not invariably, hypermetropic and have bulky crystalline lenses. In younger people, an anatomical predisposition known as ‘plateau iris’ may be present¹⁶ (Fig. 4). Plateau iris may be associated with multiple ciliary body cysts.¹⁷ Clinical features to look out for in the high-risk eye are presented in Table 1.

Mechanisms of drug-induced angle closure

There are several different mechanisms that may cause iridotrabecular contact, and result in pathological angle closure. These mechanisms are typically described as acting at four distinct anatomical locations, each progressively more posterior: the pupil margin, the peripheral iris, the cilio-lenticular space and retro-lenticular potential space. Pupil-block (Fig. 2) occurs as a result of a differential pressure gradient from the posterior segment where the aqueous humour is formed and the anterior chamber where the fluid is drained. Pupil-block may also occur in the presence of peripheral iris crowding or plateau iris.

Table 1: The high-risk eye.

Individual risk factors	
Age	Age of 60 years or older is a major risk factor for AAC, relative risk 9.1 in Singapore.
Gender	AAC affects women two to four times as often as men, irrespective of race.
Cataracts	Bulky cataracts are associated with pupil-block and peripheral iris crowding.
Race	Chinese race found to be a relative risk of 2–2.8 in Singapore; 11.8% of Alaskan Eskimo women over 60 years was found to have occludable angles.
Family history	A positive family history has been observed in cases of PACG.
Ocular risk factors	
Refraction	Patients with angle closure are more likely to be hypermetropic than myopic.
Axial biometry	Shorter anterior chamber depths and axial length are demonstrated in patients with occludable angles than in normal controls.
Plateau iris	Approximately 50% of patients under 40 years had plateau iris.

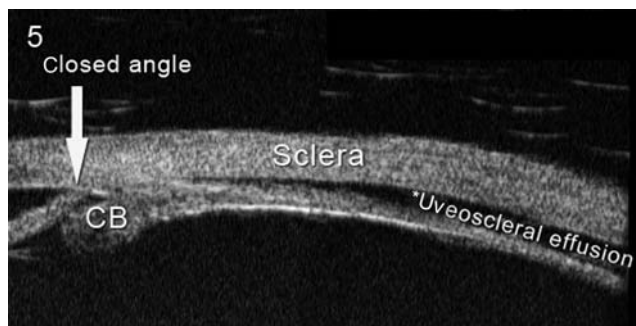

Fig. 5 This is an UBM image of a patient with drug-induced angle closure, the iris is pressed against the anterior chamber angle and the CB is rotated anteriorly. The uveoscleral effusion (*) seen here is typical of the idiosyncratic mechanism of adverse reactions that precipitate AAC (courtesy of Mr Gus Gazzard).

The latter two can lead directly to iris obstruction of the trabecular meshwork and subsequent angle closure.

Drug-induced angle closure is the result of: (1) crowding of the anterior chamber angle as a result of pupillary dilation, (2) pupil-block as the dilated pupil constricts or (3) idiosyncratic drug reactions that change the irido-corneal angle by formation of cilio-choroidal effusions (Fig. 5). Table 2 gives a list of the drug classes and mechanisms of action. The important drug classes that have been associated with angle closure are now discussed individually.

Bronchodilators

Asthma and chronic obstructive airway disease are frequently treated with bronchodilator medications. These are usually either α_2 -adrenergic agonists or anticholinergics. Nebulized forms of ipratropium bromide,^{18,19} atropine²⁰ and salbutamol (albuterol)²¹ used on their own

Table 2: Drug provoked angle closure by mechanisms of action and drug classes.

Sympathomimetic activity	
β ₂ -Agonists	Salbutamol (albuterol), ritodrine
α-Agonists	Phenylephrine
Nasal decongestants	Phenylpropanolamine
Cocaine	
Anticholinergic activity	
TCA	Imipramine, clomipramine, trazadone
SSRIs	Paroxetine, citalopram, fluvoxamine, venlafaxine
Muscarinic antagonists	Oxybutynin, atropine, botulinum toxin A, tropicamide
Other drug classes (idiosyncratic reactions)	
Antihistamine	Promethazine
Amphetamines	Ecstasy
Sulpha-containing drugs	Sulphamethoxazole, trimethoprim, acetazolamide
Thiazide diuretic	Hydrochlorothiazide
Antiepileptic	Topiramate
Antidepressant	Escitalopram

have each provoked AAC. However, most patients suffering an acute asthma attack receive combinations of these medications often in high doses, as nebulized preparations. AAC has been reported on a number of occasions for the combination of nebulized ipratropium bromide with salbutamol.^{22–25} The route of absorption of these agents into the eye is unclear. However, it has been suggested that nebulized administration of these medications allows a significant dose to be absorbed over the conjunctiva and cornea. To avoid this, it has been suggested that patients could be fitted with goggles, or the holes in the sides of mask, which discharge vapour across the cornea, could be occluded.

Antidepressants

The major classes of antidepressants that cause angle closure are tricyclic antidepressants (TCAs) and serotonin-specific reuptake inhibitors (SSRIs).^{26–28} TCAs have historically been associated with a high incidence of anticholinergic (muscarinic) side-effects such as dry mouth and constipation. Newer tricyclic-related drugs such as trazodone have a lesser side-effect profile. AAC has been widely reported among patients using clomipramine²⁹ and imipramine, a less sedative tricyclic.³⁰ Although trazodone has less anticholinergic (muscarinic) side-effects than the older tricyclics, chronic low dose use in a patient known to have PACG resulted in poor IOP control during trazodone use.³¹

SSRI were originally developed and promoted for their lack of sedation or systemic antimuscarinic side-effects. They are now the most widely used antidepressants in the UK. However, they do have

anticholinergic properties and several of the SSRIs have been shown to have the potential to provoke symptomatic AAC either at therapeutic dosage or in overdose. Paroxetine has been the SSRI most frequently reported in this context^{32–35} with patients ranging widely in age and duration of time from initiating treatment to onset of angle-closure symptoms.

Of the other SSRIs, both citalopram³⁶ and escitalopram³⁷ have been reported to be associated with AAC. The mechanism of angle closure for escitalopram was through production of a ciliochoroidal effusion (Fig. 5), ciliary body detachment and rotation of the iris and anterior chamber angle.³⁷ This was diagnosed before any glaucomatous disc damage and resolved after topical cycloplegics and discontinuation of the escitalopram. Fluvoxamine, another SSRI has been implicated in provoking AAC in a patient known to have narrow angles and glaucoma. The patient's symptoms were reversed upon stopping the medication.³⁸

Venlafaxine is a serotonin and noradrenaline re-uptake inhibitor, widely used for depression as it is thought to have less sedative and antimuscarinic effects than the tricyclics. It is also used to treat irritable bowel syndrome, where it is thought to act both by modulating central and peripheral sensory mechanisms and by reducing associated depression. However, there have now been several reports of AAC with venlafaxine via an idiosyncratic mechanism with supraciliary effusions.^{39–41} It remains unclear whether this is due to serotonergic effects, anticholinergic effects or weak adrenergic effects.

Serotonergic agents are also used as appetite suppressants and dexfenfluramine prescribed for this has been associated with AAC by inducing pupil-block.⁴²

Anticholinergics given for urinary incontinence and as antispasmodics

Over active bladder (OAB) and detrusor instability are extremely common conditions, affecting one in three of those over 75 years old.⁴³ The involuntary bladder contractions, mediated by muscarinic receptors in the detrusor muscle, occur during the bladder filling phase. The mainstay of treatment for OAB is anticholinergic medication. Symptomatic AAC has been reported in an 80-year-old hypermetrope taking oxybutynin for urge incontinence.⁴⁴ The British National Formulary lists 'glaucoma' as a contraindication to use of anticholinergics for these conditions, although it makes no distinction between open-angle glaucoma and angle-closure glaucoma, nor between patients who have had previous laser treatment for their occludable anterior chamber angles. The risk of angle closure is reduced but not

eradicated by laser iridotomy. These patients are therefore considered to be at lower (but not negligible) risk.⁴⁵

General anaesthetics

Patients undergoing general anaesthesia procedures are often given intravenous anticholinergic medications such as atropine to prevent side-effects from neostigmine, a reversible cholinesterase inhibitor used at the end of operation to reverse non-depolarizing muscle relaxants. Although small doses of parenteral atropine were found not to produce mydriasis, larger doses did, especially in lightly pigmented eyes.⁴⁶ There have been several case series of patients suffering AAC after general anaesthesia^{47,48} and have resulted in permanent visual loss from glaucomatous optic neuropathy. Atropine is sometimes used after coronary angioplasty, and a case of AAC after this has been recorded.⁴⁹

Over-the-counter medicines and cough suppressants

Phenylephrine has marked α_1 -adrenergic properties and is frequently used by eye care professionals to produce mydriasis (pupil dilation) for diagnostic and therapeutic purposes. It is also a common constituent of many over-the-counter cold remedies and is also used to treat epistaxis, by direct intranasal application to produce vasoconstriction, usually prior to nasal packing or cautery. Its use has been associated with AAC, when given nasally for epistaxis,⁵⁰ and as part of an over-the-counter medicine Fenox nasal drops (Phenylephrine Hydrochloride BP 0.5% w/v with Cetrime Ph Eur, Glycerin Ph Eur, Methylhydroxybenzoate Ph Eur).⁵¹ The phenomenon of phenylephrine-induced angle closure is not infrequently seen in ophthalmology clinics after topical (eyedrop) application, for fundal examination. Mydriatic-induced angle closure is used in glaucoma clinics, after peripheral iridotomy, as a test to assess safety and determine if there is a need of long-term pilocarpine prophylaxis.

Many over-the-counter cold and cough remedies contain constituents, included as antihistamines or decongestants, which also have marked sympathomimetic or anticholinergic effects. AAC has been reported in a patient after taking the recommended dose of Night Nurse, which contains the antihistamine promethazine, and Day Nurse (Glaxo Smithkline) which contains the decongestant phenylpropanolamine.⁵²

These ingredients are far from unique to these products though: promethazine is a component of Medised, Phenergan, Tixylix Night-time,

Avomine, Pamergan, Sominex, Ronpiron, Phensedyl, Phenhalal and Q Mazine: Phenylpropanolamine is also found in Contac 400, Vicks Coldcare, Mu-cron, Benylin Day and Night, Allereze, Dimotapp, Nirolex prolonged release, Sinutab, Triogesic and Triominic.⁵² In a study from Hong Kong, up to 25% of cases that present with AAC had recently taken antitussive medication that precipitated the event.⁵³

Recreational drugs

Cocaine hydrochloride causes pupil dilation due to its adrenergic properties. It is often given medically to reduce bleeding, particularly from the nasal mucosa. Acute angle closure has been reported after cocaine application intranasally during dacryocystorhinostomy surgery⁵⁴ and after elective antral washout.⁵⁵ AAC has also been reported after ipsilateral intranasal cocaine abuse.⁵⁶

In contrast to cocaine, methylenedioxymethamphetamine (ecstasy) is only used recreationally. Bilateral AAC was reported in a young woman who used ecstasy and marijuana.⁵⁷ No choroidal effusions were found. However in another case report of a young man who noticed progressive decrease in vision after taking ecstasy for 2 weeks was found to have choroidal effusions and transient myopia which resolved upon cessation of the drug.⁵⁸

Botulinum toxin

Botulinum toxin inhibits the release of acetylcholine and could theoretically cause mydriasis. A case of AAC has been recorded shortly after treatment of blepharospasm with botulinum toxin.⁵⁹

Other sympathomimetics

Ritodrine is a direct acting sympathomimetic drug, predominantly a β_2 -agonist, which is used to reduce uterine contractions and stop premature labour. It is usually given by intravenous infusion. Bilateral AAC has been reported 8 h after starting a ritodrine infusion for premature labour.⁶⁰ However, labour itself has also been implicated in triggering AAC.⁶¹

There has been a case report of angle closure developing a few hours after ingestion of sildenafil (Viagra).⁶² However, angle closure has also been associated with sexual activity⁶³ and the drug may not actually be the association in this case.⁶⁴

Poisons

Belladonna (*atropa belladonna*) is a mixture of alkaloids, principally atropine, hyoscyamine and scopolamine. It is derived from the deadly nightshade plant. Up until the 1950s it was in common usage both as a tincture and an extract. There have been case reports of AAC precipitated in hypermetropes who had recently been commenced on extract of belladonna, a few days previously.⁶⁵

Bilateral AAC has been reported in two patients following snake-bite.⁶⁶ Snake venoms are often complex multicomponent poisons.

Idiosyncratic reaction to systemic medications

Topiramate is a relatively new sulpha-containing anticonvulsant that can be used in both children and adults. It is also increasingly used for migraine prophylaxis. It has been associated with acute myopia, suprachoroidal effusion and acute angle closure.⁶⁷⁻⁷¹ This is an idiosyncratic response, which is neither dose dependant nor is it related to pre-existing patient refractive error. Topiramate-induced angle closure is caused by suprachoroidal effusion and ciliary body oedema, which produce forward rotation of the ciliary body, in turn displacing the iris forward to close the anterior chamber angle (Fig. 6).

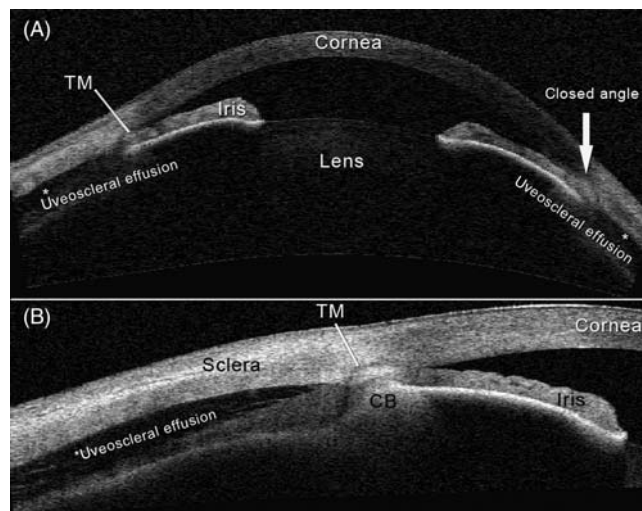


Fig. 6 (A) This is an anterior segment OCT (ASOCT) scan of a uveoscleral effusion (*) in cross section. The anterior chamber is shallow. The patient was on topiramate and all clinical signs resolved within 2 weeks of cessation of the drug. The ASOCT scan differs from the UBM (Fig. 5) in that the ciliary body (CB) is less well demarcated on ASOCT. (B) However, on the high-resolution ASOCT scan on eccentric gaze, the TM was clearly visible and one can see the CB rotation, and a completely closed angle from this adverse drug reaction.

Because of the high frequency of this severe ocular side-effect, patients and the parents of paediatric patients should be warned to attend their local eye casualty if they experience blurring of vision or eye pain, after starting topiramate. The ophthalmologists treating these patients should stop the topiramate, substituting another anticonvulsant, and commence atropine cycloplegia, to displace the iris-lens plane posteriorly, together with topical ocular hypotensive medications and acetazolamide.

Other sulpha-containing drugs^{72–76} such as hydrochlorothiazide, a thiazide diuretic used to treat hypertension⁷⁷ may also be accompanied by suprachoroidal effusions, anterior rotation of the ciliary body and shallowing of the anterior chamber.^{73,74} These patients are unlikely to have pre-existing risk of angle closure, and after withdrawal of the medication usually revert to a normal deep anterior chamber, with open drainage angle.^{67,69}

Environmental factors in angle closure

Light, season and temperature

In non-tropical countries there is often a wide variation in the number of day–light hours, according to the season. In Finland using meteorological data and hospital discharge registers, the incidence of AAC was found to be positively associated with the number of hours without sunshine, and was more common in winter and autumn than summer or spring.^{78,79} In Croatia, a similar retrospective study also found more cases of AAC during winter, and on days with less sunshine.⁸⁰ A similar seasonal incidence was seen in Birmingham and in Canterbury in the UK.^{81,82} In Israel, a statistically significant preponderance of attacks were found in summer and winter, times of more extreme weather than in spring or autumn.⁸³

In Singapore, a prospective island-wide incidence study, found AAC to be more frequent on hotter days.⁸⁴ In Switzerland⁸⁵ found that the majority of AAC cases presented during a particular pattern of adverse weather with advection of cold maritime air behind a low-pressure system. A common factor for all these environmental factors is thought to be that during adverse weather conditions people tend to stay indoors. The darker conditions are associated with pupil dilation and increased frequency of AAC.

Sunspots

Incidence of AAC, in the UK, appears to be inversely related to sunspot activity, both on the day of presentation and in the immediately

preceding period.⁸¹ In Singapore,⁸⁴ there was a direct relationship between symptomatic angle closure and both number of sunspots and mean solar radio flux. Increased sunspot activity is associated with a small increase in solar radiation, terrestrial geomagnetic storms and heating of the Earth's outer atmosphere.⁸⁴ It remains unclear whether sunspot activity is truly associated with AAC.

Adrenaline and stress

Two 73-year old sisters presented with simultaneous AAC after having been involved in a fight with each other.⁸⁶ The release of adrenaline during the squabble, and associated mydriasis, was thought to be the causative factor.

AAC has been reported a number of times after eyelid surgery, in particular blepharoplasty.⁸⁷⁻⁸⁹ These cases were thought to have been caused by adrenaline-induced angle closure (several millilitres of local anaesthetic-containing adrenaline is injected for haemostasis) in eyes with coexistent occludable anterior chamber angles.

Identification of cases and management

The current reference-standard of angle width assessment is gonioscopy, in which the anterior chamber angle is examined using a diagnostic contact lens. Other screening techniques include the oblique flashlight test, van Herick technique at the slit lamp microscope and newer imaging techniques including high-resolution ultrasound biomicroscopy (UBM) and optical coherence tomography (OCT) of the anterior segment. Some of these imaging techniques are not widely available (see also Figs 5 and 6).

Management of angle closure

Laser iridotomy

The creation of a full thickness hole in the peripheral iris using laser (previously argon laser but now superseded by either combined argon and Nd:YAG laser, or YAG laser alone) is termed an iridotomy.^{90,91} Prior to the development of laser technology this hole was made by surgical means (surgical iridectomy). The iridotomy allows the aqueous humor to bypass the pupil to eliminate any pupil-block mechanism of angle closure. Iridotomy is implemented at diagnosis in all patients with acute or established primary angle closure. It is often used as

a preventive treatment in patients with iridotrabecular contact, particularly in cases that need frequent pupil dilation for retinal examinations (e.g. diabetics). It is, however, less effective where extensive areas of peripheral anterior synechiae already exist causing permanent angle closure.

Iridoplasty

Peripheral iridotomy is the usual first-line treatment of patients with AAC. A significant number of patients have evidence of residual appositional angle-closure post-iridotomy. In some of these cases low-power Argon laser burns are applied to the peripheral iris to contract it away from the trabecular meshwork thereby opening the angle.^{92–94} Iridoplasty may also be used as initial treatment for patients in AAC. Once angle closure has been overcome, a peripheral laser iridotomy is performed.

Lens extraction

For patients with a co-existing cataract and angle closure, removing the lens by surgical means will also have a therapeutic effect on the angle-closure process.⁹⁵ In many patients with chronic angle closure, this achieves adequate control of the IOP.⁹⁶

Medical treatment

Cholinergic agents, such as pilocarpine, can be delivered as eye drops. These cause constriction of the pupil and thus pull the peripheral iris away from the trabecular meshwork, opening the drainage angle. Other topical and systemic IOP lowering medications are usually given to help control IOP in AAC and may help control IOP in chronic angle closure.

Discussion and conclusion

Most cases of primary angle closure probably occur in patients for whom there are no identifiable, exogenous causative agents. However, environmental and pharmacological factors (both systemic and topical) can cause angle closure and glaucomatous optic neuropathy if left untreated. This review draws from a very large number of case reports. The message is that patients do not always have typical textbook accounts of ‘acute’ symptomatic or ‘chronic’ asymptomatic presentations of angle closure. All healthcare professionals should be aware of the risks of angle closure from certain systemic medications, in predisposed individuals. Referral to an ophthalmologist for gonioscopy should be arranged whenever there is any doubt.

It seems anomalous that current drug guidelines potentially deprive all glaucoma patients of beneficial medications, when most have a type of glaucoma (either open-angle or treated angle closure) which will not be aggravated by their use. There remains a lack of understanding about the difference between angle-closure and open-angle glaucoma.⁹⁷ Instead of using a blanket recommendation contraindicating the use of these medications for all glaucoma patients, one option is to assess them for closable angles prior to giving medications that might produce angle closure. Ideally, patients that have been identified to be at high risk (see Table 1) should be assessed prior to starting treatment. However, this may not be practical to implement, even in populations with high prevalence of angle closure.

Clinicians should ensure that all patients understand that they need to seek urgent ophthalmic attention should they develop blurred vision, or a red or painful eye, after starting any one of these medications. All patients over the age of 40 years, and those with a positive family history of glaucoma should undergo regular examination by an optometrist or ophthalmologist.

Acknowledgements

The views expressed in this publication are those of the authors and not necessarily those of the Department of Health.

Funding

The authors acknowledge (a proportion of their) financial support from the Department of Health through the award made by the National Institute for Health Research to Moorfields Eye Hospital NHS Foundation Trust and UCL Institute of Ophthalmology for a Specialist Biomedical Research Centre for Ophthalmology.

References

- 1 Quigley HA, Broman AT (2006) The number of people with glaucoma worldwide in 2010 and 2020. *Br J Ophthalmol*, **90**, 262–267.
- 2 Weinreb RN, Khaw PT (2004) Primary open-angle glaucoma. *Lancet*, **363**, 1711–1720.
- 3 Ang LP, Aung T, Chua WH *et al.* (2004) Visual field loss from primary angle-closure glaucoma: a comparative study of symptomatic and asymptomatic disease. *Ophthalmology*, **111**, 1636–1640.
- 4 Foster PJ, Baasanhu J, Alsbirk PH *et al.* (1996) Glaucoma in Mongolia. A population-based survey in Hovsgol province, northern Mongolia. *Arch Ophthalmol*, **114**, 1235–1241.

- 5 Foster PJ, Oen FT, Machin D *et al.* (2000) The prevalence of glaucoma in Chinese residents of Singapore: a cross-sectional population survey of the Tanjong Pagar district. *Arch Ophthalmol*, **118**, 1105–1111.
- 6 Bourne RR, Sukudom P, Foster PJ *et al.* (2003) Prevalence of glaucoma in Thailand: a population based survey in Rom Klao District, Bangkok. *Br J Ophthalmol*, **87**, 1069–1074.
- 7 He M, Foster PJ, Ge J *et al.* (2006) Prevalence and clinical characteristics of glaucoma in adult Chinese: a population-based study in Liwan District, Guangzhou. *Invest Ophthalmol Vis Sci*, **47**, 2782–2788.
- 8 Wolfs RC, Grobbee DE, Hofman A, de Jong PT (1997) Risk of acute angle-closure glaucoma after diagnostic mydriasis in nonselected subjects: the Rotterdam study. *Invest Ophthalmol Vis Sci*, **38**, 2683–2687.
- 9 Ong EL, Baasanhu J, Nolan W *et al.* (2008) The utility of symptoms in identification of primary angle-closure in a high-risk population. *Ophthalmology*, **115**, 2024–2029.
- 10 Amerasinghe N, Aung T (2008) Angle-closure: risk factors, diagnosis and treatment. *Prog Brain Res*, **173**, 31–45.
- 11 Mapstone R (1976) Provocative tests in closed-angle glaucoma. *Br J Ophthalmol*, **60**, 115–119.
- 12 Gloster J, Poinosawmy D (1973) Changes in intraocular pressure during and after the dark-room test. *Br J Ophthalmol*, **57**, 170–178.
- 13 Hung PT, Chou LH (1979) Provocation and mechanism of angle-closure glaucoma after iridectomy. *Arch Ophthalmol*, **97**, 1862–1864.
- 14 Kim TW, Park KH, Hong C (2007) Dark-room prone-position test for intermittent angle closure. *Korean J Ophthalmol*, **21**, 151–154.
- 15 Sihota R, Mohan S, Dada T *et al.* (2007) An evaluation of the darkroom prone provocative test in family members of primary angle closure glaucoma patients. *Eye*, **21**, 984–989.
- 16 Ritch R, Dorairaj S (2007) Plateau iris syndrome in younger patients. *Clin Exp Ophthalmol*, **35**, 399–400.
- 17 Azuara-Blanco A, Spaeth GL, Araujo SV *et al.* (1996) Plateau iris syndrome associated with multiple ciliary body cysts. Report of three cases. *Arch Ophthalmol*, **114**, 666–668.
- 18 Malani JT, Robinson GM, Seneviratne EL (1982) Ipratropium bromide induced angle closure glaucoma. *N Z Med J*, **95**, 749.
- 19 Ortiz RJ, Hidalgo Mora JJ, Gascon RG, Navarro AB (2005) Acute angle-closure glaucoma and ipratropium bromide. *Med Clin (Barc)*, **124**, 795.
- 20 Berdy GJ, Berdy SS, Odin LS, Hirst LW (1991) Angle closure glaucoma precipitated by aerosolized atropine. *Arch Intern Med*, **151**, 1658–1660.
- 21 Rho DS (2000) Acute angle-closure glaucoma after albuterol nebulizer treatment. *Am J Ophthalmol*, **130**, 123–124.
- 22 Shah P, Dhurjon L, Metcalfe T, Gibson JM (1992) Acute angle closure glaucoma associated with nebulised ipratropium bromide and salbutamol. *BMJ*, **304**, 40–41.
- 23 Reuser T, Flanagan DW, Borland C, Bannerjee DK (1992) Acute angle closure glaucoma occurring after nebulized bronchodilator treatment with ipratropium bromide and salbutamol. *J R Soc Med*, **85**, 499–500.
- 24 Mulpeter KM, Walsh JB, O'Connor M *et al.* (1992) Ocular hazards of nebulized bronchodilators. *Postgrad Med J*, **68**, 132–133.
- 25 De Saint JM, Bourcier T, Borderie V *et al.* (2000) Acute closure-angle glaucoma after treatment with ipratropium bromide and salbutamol aerosols. *J Fr Ophthalmol*, **23**, 603–605.
- 26 Costagliola C, Mastropasqua L, Capone D *et al.* (2000) Effect of fluoxetine on intraocular pressure in the rabbit. *Exp Eye Res*, **70**, 551–555.
- 27 Costagliola C, Parmeggiani F, Sebastiani A (2004) SSRIs and intraocular pressure modifications: evidence, therapeutic implications and possible mechanisms. *CNS Drugs*, **18**, 475–484.
- 28 Rennie IG (1993) Clinically important ocular reactions to systemic drug therapy. *Drug Saf*, **9**, 196–211.
- 29 Schlingemann RO, Smit AA, Lunel HF, Hijdra A (1996) Amaurosis fugax on standing and angle-closure glaucoma with clomipramine. *Lancet*, **347**, 465.
- 30 Ritch R, Krupin T, Henry C, Kurata F (1994) Oral imipramine and acute angle closure glaucoma. *Arch Ophthalmol*, **112**, 67–68.

- 31 Pae CU, Lee CU, Lee SJ *et al.* (2003) Association of low dose trazodone treatment with aggravated angle-closure glaucoma. *Psychiatry Clin Neurosci*, **57**, 127–128.
- 32 Kirwan JF, Subak-Sharpe I, Teimory M (1997) Bilateral acute angle closure glaucoma after administration of paroxetine. *Br J Ophthalmol*, **81**, 252.
- 33 Eke T, Bates AK (1997) Acute angle closure glaucoma associated with paroxetine. *BMJ*, **314**, 1387.
- 34 Lewis CF, DeQuardo JR, DuBose C, Tandon R (1997) Acute angle-closure glaucoma and paroxetine. *J Clin Psychiatry*, **58**, 123–124.
- 35 Browning AC, Reck AC, Chisholm IH, Nischal KK (2000) Acute angle closure glaucoma presenting in a young patient after administration of paroxetine. *Eye*, **14**, 406–408.
- 36 Croos R, Thirumalai S, Hassan S, Davis JR (2005) Citalopram associated with acute angle-closure glaucoma: case report. *BMC Ophthalmol*, **5**, 23.
- 37 Zelefsky JR, Fine HF, Rubinstein VJ *et al.* (2006) Escitalopram-induced uveal effusions and bilateral angle closure glaucoma. *Am J Ophthalmol*, **141**, 1144–1147.
- 38 Jimenez-Jimenez FJ, Orti-Pareja M, Zurdo JM (2001) Aggravation of glaucoma with fluvoxamine. *Ann Pharmacother*, **35**, 1565–1566.
- 39 Ng B, Sanbrook GM, Malouf AJ, Agarwal SA (2002) Venlafaxine and bilateral acute angle closure glaucoma. *Med J Aust*, **176**, 241.
- 40 de Guzman MH, Thiagalingam S, Ong PY, Goldberg I (2005) Bilateral acute angle closure caused by supraciliary effusions associated with venlafaxine intake. *Med J Aust*, **182**, 121–123.
- 41 Ezra DG, Storoni M, Whitefield LA (2006) Simultaneous bilateral acute angle closure glaucoma following venlafaxine treatment. *Eye*, **20**, 128–129.
- 42 Denis P, Charpentier D, Berros P, Touameur S (1995) Bilateral acute angle-closure glaucoma after dexfenfluramine treatment. *Ophthalmologica*, **209**, 223–224.
- 43 Milsom I, Abrams P, Cardozo L *et al.* (2001) How widespread are the symptoms of an overactive bladder and how are they managed? A population-based prevalence study. *BJU Int*, **87**, 760–766.
- 44 Sung VC, Corridan PG (1998) Acute-angle closure glaucoma as a side-effect of oxybutynin. *Br J Urol*, **81**, 634–635.
- 45 Goh D, Chan J, Vasudevan S *et al.* (2005) Managing patients with an overactive bladder and glaucoma: a questionnaire survey of Japanese urologists on the use of anticholinergics. *BJU Int*, **96**, 192–193.
- 46 Schwartz H, Apt L (1979) Mydriatic effect of anticholinergic drugs used during reversal of nondepolarizing muscle relaxants. *Am J Ophthalmol*, **88**, 609–612.
- 47 Fazio DT, Bateman JB, Christensen RE (1985) Acute angle-closure glaucoma associated with surgical anesthesia. *Arch Ophthalmol*, **103**, 360–362.
- 48 Ates H, Kayikcioglu O, Andac K (1999) Bilateral angle closure glaucoma following general anesthesia. *Int Ophthalmol*, **23**, 129–130.
- 49 Mandak JS, Minerva P, Wilson TW, Smith EK (1996) Angle closure glaucoma complicating systemic atropine use in the cardiac catheterization laboratory. *Cathet Cardiovasc Diagn*, **39**, 262–264.
- 50 Zenzen CT, Elliott D, Balok EM *et al.* (2004) Acute angle-closure glaucoma associated with intranasal phenylephrine to treat epistaxis. *Arch Ophthalmol*, **122**, 655–656.
- 51 Khan MA, Watt LL, Hugkulstone CE (2002) Bilateral acute angle-closure glaucoma after use of Fenox nasal drops. *Eye*, **16**, 662–663.
- 52 Barrett V, Jordan T (2001) Angle closure risk from proprietary medicines. *Eye*, **15**, 248–249.
- 53 Lai JS, Liu DT, Tham CC *et al.* (2001) Epidemiology of acute primary angle-closure glaucoma in the Hong Kong Chinese population: prospective study. *Hong Kong Med J*, **7**, 118–123.
- 54 Wilcsek GA, Vose MJ, Francis IC *et al.* (2002) Acute angle closure glaucoma following the use of intranasal cocaine during dacryocystorhinostomy. *Br J Ophthalmol*, **86**, 1312.
- 55 Hari CK, Roblin DG, Clayton MI, Nair RG (1999) Acute angle closure glaucoma precipitated by intranasal application of cocaine. *J Laryngol Otol*, **113**, 250–251.
- 56 Mitchell JD, Schwartz AL (1996) Acute angle-closure glaucoma associated with intranasal cocaine abuse. *Am J Ophthalmol*, **122**, 425–426.

- 57 Trittibach P, Frueh BE, Goldblum D (2005) Bilateral angle-closure glaucoma after combined consumption of 'ecstasy' and marijuana. *Am J Emerg Med*, **23**, 813–814.
- 58 Kumar RS, Grigg J, Farinelli AC (2007) Ecstasy induced acute bilateral angle closure and transient myopia. *Br J Ophthalmol*, **91**, 693–695.
- 59 Corridan P, Nightingale S, Mashoudi N, Williams AC (1990) Acute angle-closure glaucoma following botulinum toxin injection for blepharospasm. *Br J Ophthalmol*, **74**, 309–310.
- 60 Guvendag Guven ES, Guven S, Coskun F *et al.* (2005) Angle closure glaucoma induced by ritodrine. *Acta Obstet Gynecol Scand*, **84**, 489–490.
- 61 Kearns PP, Dhillon BJ (1990) Angle closure glaucoma precipitated by labour. *Acta Ophthalmol (Copenh)*, **68**, 225–226.
- 62 Ramasamy B, Rowe F, Nayak H *et al.* (2007) Acute angle-closure glaucoma following sildenafil citrate-aided sexual intercourse. *Acta Ophthalmol Scand*, **85**, 229–230.
- 63 Ritch R, Dorairaj SK, Liebmann JM (2007) Angle-closure triggered by orgasm: a new provocative test? *Eye*, **21**, 872–874.
- 64 Markovits AS (1996) Sudden visual loss associated with sexual activity. *Arch Ophthalmol*, **114**, 106.
- 65 Ullman EV, Mossman FD (1950) Glaucoma and orally administered belladonna. *Am J Ophthalmol*, **33**, 757–762.
- 66 Srinivasan R, Kaliaperumal S, Dutta TK (2005) Bilateral angle closure glaucoma following snake bite. *J Assoc Physicians India*, **53**, 46–48.
- 67 Banta JT, Hoffman K, Budenz DL *et al.* (2001) Presumed topiramate-induced bilateral acute angle-closure glaucoma. *Am J Ophthalmol*, **132**, 112–114.
- 68 Rhee DJ, Goldberg MJ, Parrish RK (2001) Bilateral angle-closure glaucoma and ciliary body swelling from topiramate. *Arch Ophthalmol*, **119**, 1721–1723.
- 69 Chen TC, Chao CW, Sorkin JA (2003) Topiramate induced myopic shift and angle closure glaucoma. *Br J Ophthalmol*, **87**, 648–649.
- 70 Fraunfelder FW, Fraunfelder FT, Keates EU (2004) Topiramate-associated acute, bilateral, secondary angle-closure glaucoma. *Ophthalmology*, **111**, 109–111.
- 71 Thambi L, Kapcala LP, Chambers W *et al.* (2002) Topiramate-associated secondary angle-closure glaucoma: a case series. *Arch Ophthalmol*, **120**, 1108.
- 72 Maddalena MA (1968) Transient myopia associated with acute glaucoma and retinal edema following vaginal administration of sulfanilamide. *Arch Ophthalmol*, **80**, 186–188.
- 73 Bovino JA, Marcus DF (1982) The mechanism of transient myopia induced by sulfonamide therapy. *Am J Ophthalmol*, **94**, 99–102.
- 74 Hook SR, Holladay JT, Prager TC, Goosey JD (1986) Transient myopia induced by sulfonamides. *Am J Ophthalmol*, **101**, 495–496.
- 75 Fan JT, Johnson DH, Burk RR (1993) Transient myopia, angle-closure glaucoma, and choroidal detachment after oral acetazolamide. *Am J Ophthalmol*, **115**, 813–814.
- 76 Postel EA, Assalian A, Epstein DL (1996) Drug-induced transient myopia and angle-closure glaucoma associated with supraciliary choroidal effusion. *Am J Ophthalmol*, **122**, 110–112.
- 77 Geanon JD, Perkins TW (1995) Bilateral acute angle-closure glaucoma associated with drug sensitivity to hydrochlorothiazide. *Arch Ophthalmol*, **113**, 1231–1232.
- 78 Teikari J, Raivio I, Nurminen M (1987) Incidence of acute glaucoma in Finland from 1973 to 1982. *Graefes Arch Clin Exp Ophthalmol*, **225**, 357–360.
- 79 Teikari JM, O'Donnell J, Nurminen M, Raivio I (1991) Acute closed angle glaucoma and sunshine. *J Epidemiol Community Health*, **45**, 291–293.
- 80 Bojic L, Vojnikovic B, Karelovic D, Jukic-Lesina T (2001) Acute angle-closed glaucoma and meteorological factors in Split, Croatia. *Coll Antropol*, **25**(Suppl.), 105–109.
- 81 Hillman JS, Turner JD (1977) Association between acute glaucoma and the weather and sunspot activity. *Br J Ophthalmol*, **61**, 512–516.
- 82 Edwards RS (1987) Ophthalmic emergencies in a district general hospital casualty department. *Br J Ophthalmol*, **71**, 938–942.
- 83 David R, Tessler Z, Yassar Y (1985) Epidemiology of acute angle-closure glaucoma: incidence and seasonal variations. *Ophthalmologica*, **191**, 4–7.
- 84 Seah SK, Foster PJ, Chew PT *et al.* (1997) Incidence of acute primary angle-closure glaucoma in Singapore. An island-wide survey. *Arch Ophthalmol*, **115**, 1436–1440.

- 85 Tupling MR, Junet EJ (1977) Meteorological triggering of acute glaucoma attacks. *Trans Ophthalmol Soc U K*, **97**, 185–188.
- 86 Talluto D, Feith M, Allee S (1998) Simultaneous angle closure in twins. *J Glaucoma*, **7**, 68–69.
- 87 Green MF, Kadri SW (1974) Acute closed-angle glaucoma, a complication of blepharoplasty: report of a case. *Br J Plast Surg*, **27**, 25–27.
- 88 Gayton JL, Ledford JK (1992) Angle closure glaucoma following a combined blepharoplasty and ectropion repair. *Ophthal Plast Reconstr Surg*, **8**, 176–177.
- 89 Wride NK, Sanders R (2004) Blindness from acute angle-closure glaucoma after blepharoplasty. *Ophthal Plast Reconstr Surg*, **20**, 476–478.
- 90 Robin AL, Pollack IP (1984) A comparison of neodymium: YAG and argon laser iridotomies. *Ophthalmology*, **91**, 1011–1016.
- 91 Pollack IP, Robin AL, Dragon DM *et al.* (1984) Use of the neodymium: YAG laser to create iridotomies in monkeys and humans. *Trans Am Ophthalmol Soc*, **82**, 307–328.
- 92 Ritch R, Tham CC, Lam DS (2004) Long-term success of argon laser peripheral iridoplasty in the management of plateau iris syndrome. *Ophthalmology*, **111**, 104–108.
- 93 Ritch R, Liebmann JM (1996) Argon laser peripheral iridoplasty. *Ophthalmic Surg Lasers*, **27**, 289–300.
- 94 Ritch R (1982) Argon laser treatment for medically unresponsive attacks of angle-closure glaucoma. *Am J Ophthalmol*, **94**, 197–204.
- 95 Lam DS, Leung DY, Tham CC *et al.* (2008) Randomized trial of early phacoemulsification versus peripheral iridotomy to prevent intraocular pressure rise after acute primary angle closure. *Ophthalmology*, **115**, 1134–1140.
- 96 Roberts TV, Francis IC, Lertusumitkul S *et al.* (2000) Primary phacoemulsification for uncontrolled angle-closure glaucoma. *J Cataract Refract Surg*, **26**, 1012–1016.
- 97 Kato K, Yoshida K, Suzuki K *et al.* (2005) Managing patients with an overactive bladder and glaucoma: a questionnaire survey of Japanese urologists on the use of anticholinergics. *BJU Int*, **95**, 98–101.