

# Impetigo Herpetiformis during Pregnancy: A Case Report and Literature Review

Qian-Qian Gao Ming-Rong Xi Qiang Yao

West China Second University Hospital, Sichuan University, Chengdu, Sichuan, PR China

## Key Words

Impetigo herpetiformis · Pregnancy · Acitretin

## Abstract

**Background:** Impetigo herpetiformis (IH) is a rare pustular dermatosis that typically occurs in pregnant women with unknown etiology. **Case Report:** We report an 18-year-old primigravida who presented with IH at nearly 30 weeks' gestation and was the first patient reported in mainland China. The patient's condition deteriorated rapidly in spite of treatment with corticosteroids and antibiotics, so we decided to terminate the pregnancy by induction of labor. After vaginal delivery she developed fever and her skin lesions did not disappear naturally. Fortunately her symptoms were resolved with the treatment of antibiotics and acitretin, and at day 60 postpartum her skin lesions had completely disappeared. **Conclusion:** Although IH is associated with high mortality and morbidity in both fetus and mother, a better prognosis could be achieved with an immediate diagnosis and proper treatment. The etiology of IH needs to be further explored and the process of diagnosis and therapy should be standardized.

Copyright © 2013 S. Karger AG, Basel

## Introduction

Impetigo herpetiformis (IH), firstly introduced by von Hebra [1] in 1872, is characterized as an acute pustular eruption that mainly occurs in the last trimester of pregnancy with a serious risk to the mother and the fetus [2]. According to the literature, although the causes of impetigo herpetiformis are still unknown [3, 4], complications like hypoparathyroidism and hypocalcemia are common in patients [5–8]. Generally the patients recover after delivery, but IH frequently recurs in subsequent pregnancy [2, 7–10]. Early diagnosis and treatment is important in order to get a better prognosis for both the mother and fetus.

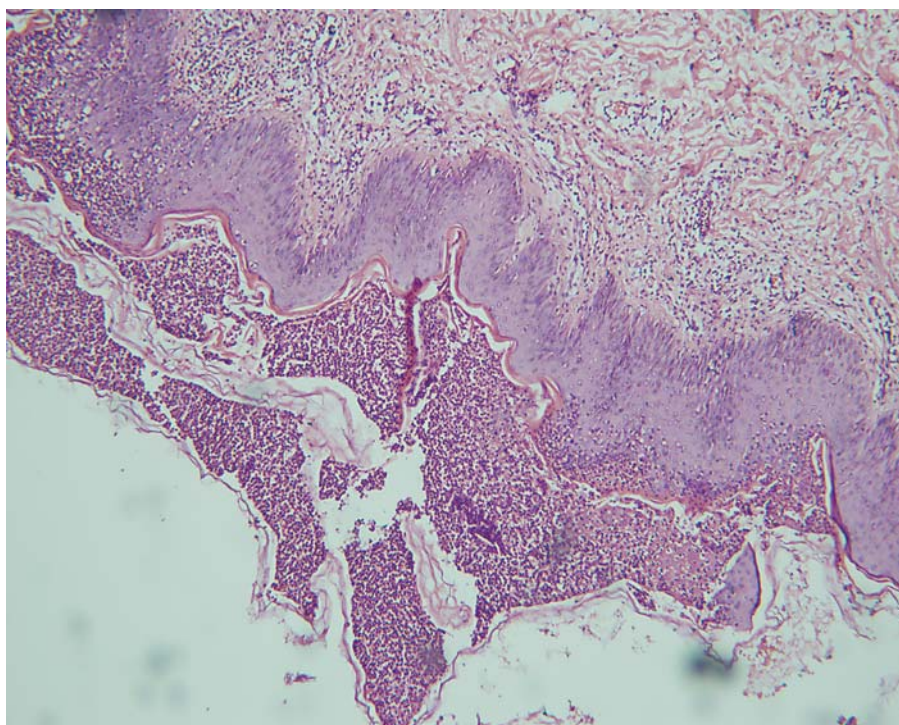
We report a case of IH during the third trimester that did not respond to corticosteroids and antibiotics. It is the first case reported in mainland China. The condition of the patient worsened so we decided to terminate the pregnancy by induction of labor at 35 weeks' gestation, and a healthy female baby (weight 1.8 kg; Apgar score 10 at 1 min) was delivered vaginally. After delivery the condition of the patient did not improve. Fortunately, with the treatment of antibiotics, antiallergic agent and acitretin, as well as correction of electrolyte imbalance, the patient recovered at day 60 postpartum.

## Case Report

An 18-year-old Han Chinese primigravida was admitted to our hospital because of pustular lesions in the third trimester. She did not have regular prenatal visits. She denied hypertension, diabetes mellitus and any other diseases. She also denied taking any drugs including indomethacin, lithium, beta-blockers and smoking, which could be risk factors for pustular psoriasis. She and her family had no history of any dermatosis or other diseases.

She had got pustular lesions at nearly 30 weeks' gestation and accepted treatment of penicillin intravenously at a local clinic, which was unsuccessful. Firstly, she had erythema around the pustular lesions in the vicinity of her retroauricular, hypogastric and inguinal regions without pruritus or pain. Gradually, the skin lesions covered her entire body (except the scalp, oral mucosa and palmoplantar regions), with pruritus and pain, and at 33 weeks' gestation and she was sent to a local hospital.

Her body temperature was 37.5 °C, pulse rate 110 beats/min and blood pressure 105/75 mm Hg. Significant laboratory findings were as follows: WBC count of  $9.9 \times 10^9/l$  (range 4–10  $\times 10^9/l$ ); neutral polymorphonuclear cell percentage of 83.3% (range 50–70%); hemoglobin of



**Fig. 1.** Parakeratosis and irregular acanthosis with subcorneal, intraepidermal neutrophils and microabscesses. HE.  $\times 100$ .

91 g/l (range 115–135 g/l); serum calcium of 2.06 mmol/l (range 2.1–2.7 mmol/l), and serum potassium of 3.15 mmol/l (range 3.5–5 mmol/l). A punch skin biopsy from a pustule on her trunk revealed epidermal parakeratosis, acanthosis with irregular hypertrophy and subcorneal microabscesses (fig. 1), dermal papilla edema, vascular dilatation and congestion surrounded by infiltration of lymphocytes, neutrophils and rare eosinophils (fig. 2). Pathological diagnosis and clinical manifestations demonstrated that the patient suffered from IH, and she was treated with methylprednisolone at a dose of 40 mg/day intravenously combined with prednisone 20 mg/day orally for 5 days, but the condition of the patient did not improve. The skin lesions on her trunk and arms increased more and more and the pruritus and pain remained.

The patient was, therefore, admitted to our hospital at gestation of 34 weeks and 2 days with widespread erythema, crusta and decrustation over the whole body including the face, trunk (fig. 3), arms, legs (fig. 4) and vulva. Her body temperature was 36.4°C, pulse rate 118 beats/min and blood pressure 94/51 mm Hg. Abnormal values were shown in some laboratory tests, such as: WBC count of  $26.3 \times 10^9/l$  (range 4–10

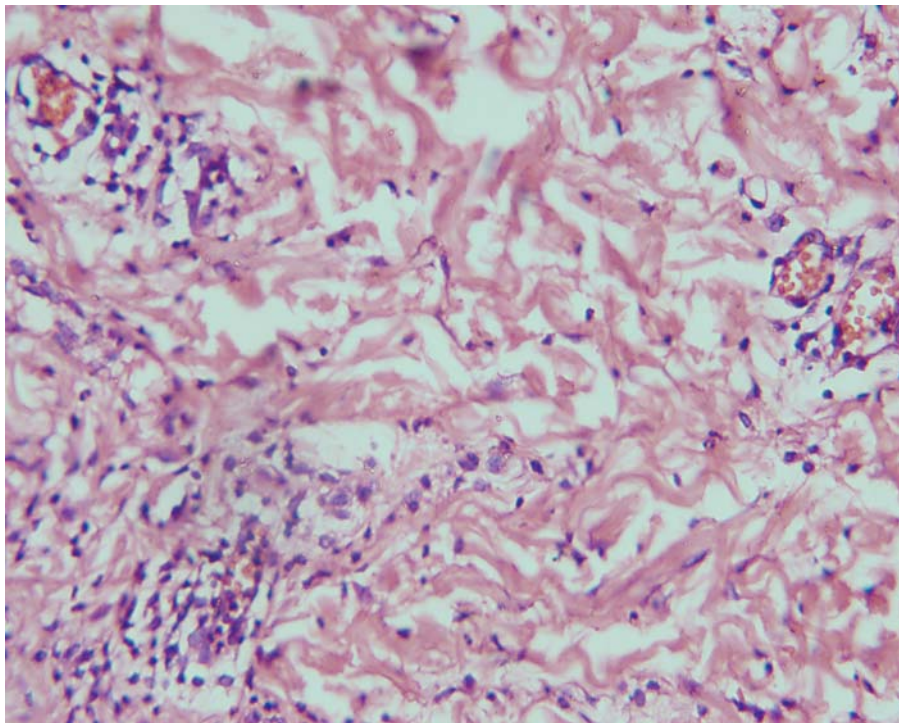
$\times 10^9/l$ ), hemoglobin of 96 g/l (range 115–135 g/l) and albumin of 27.2 g/l (range 35–55 g/l). The tests of renal and thyroid function were normal. The pharyngeal and urine cultures were negative. The obstetric ultrasound scan showed normal fetal growth. Electronic fetal monitoring tracings every day were reactive. After expectant treatment for 4 days, the skin lesions did not disappear and the patient still felt pain and pruritus. Furthermore, she had low-grade fever. After a group consultation we decided to induce labor to improve the maternal condition. Finally, a female baby (weight 1.8 kg; Apgar score 10 at 1 min) with no pustular or other erythema was delivered vaginally at 35 weeks' gestation (fig. 5). The baby was sent to the neonate intensive care unit because of preterm birth. Although the pruritus was relieved and the erythema on her face disappeared, the patient still had low-grade fever after vaginal delivery. She was transferred to the dermatological department for further treatment. Her body temperature gradually rose from 38.1 to 39.7°C, and new erythema and pustules occurred. Fortunately her symptoms were resolved with the treatment of antibiotics and antipyretic and antiallergic agent. Then acitretin (with a dosage of 10 mg 3 times a day orally for nearly

60 days) was used and by day 60 postpartum her skin lesions had completely disappeared (fig. 6 shows exfoliation of the patient's back at 2 weeks postpartum). We also encouraged the patient to establish faith of recovery during the whole process; psychological therapy was obviously very helpful to this patient.

## Discussion

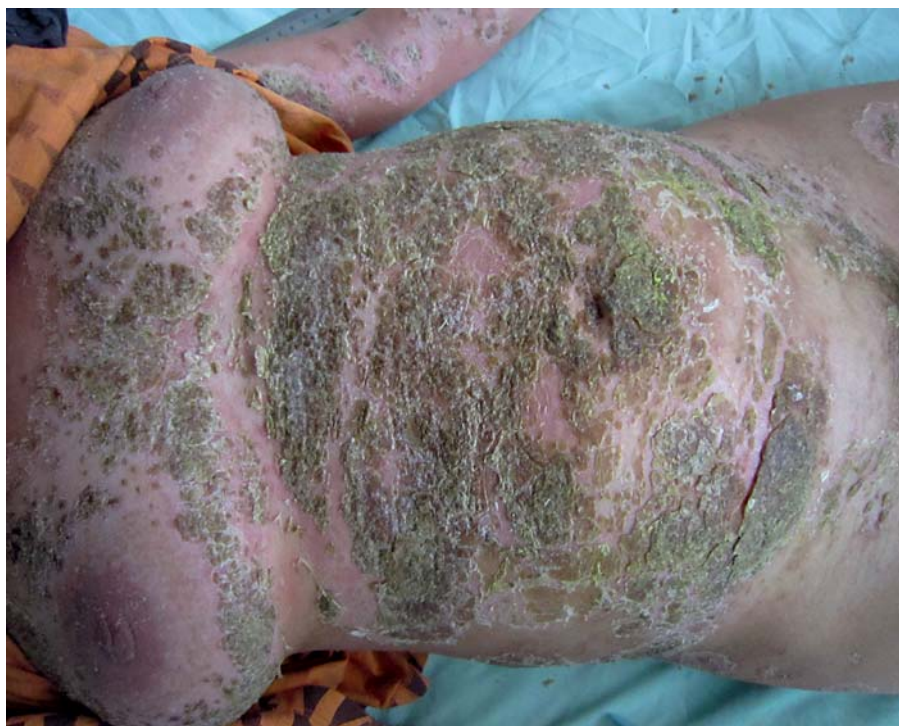IH is a rare pustular dermatosis which was first introduced by von Hebra [1] in 1872. In our literature review, it is confirmed that IH is a notorious skin disorder of pregnancy with increased morbidity and mortality that affects both the mother and the fetus [1, 2]. IH mainly afflicts pregnant women during the third trimester of pregnancy but it may also occur in the first trimester of pregnancy, puerperium or menstrual period, and it may even occur in men [8, 11–14]. In patients who suffered from IH before, the disease recurs at an earlier gestational age during a subsequent pregnancy [7, 9, 10]. Although genetic background is not considered in our literature review, several familial cases have been reported [15, 16]. Therefore, IH might be a genetic disease, but the genetic background is unknown as yet.





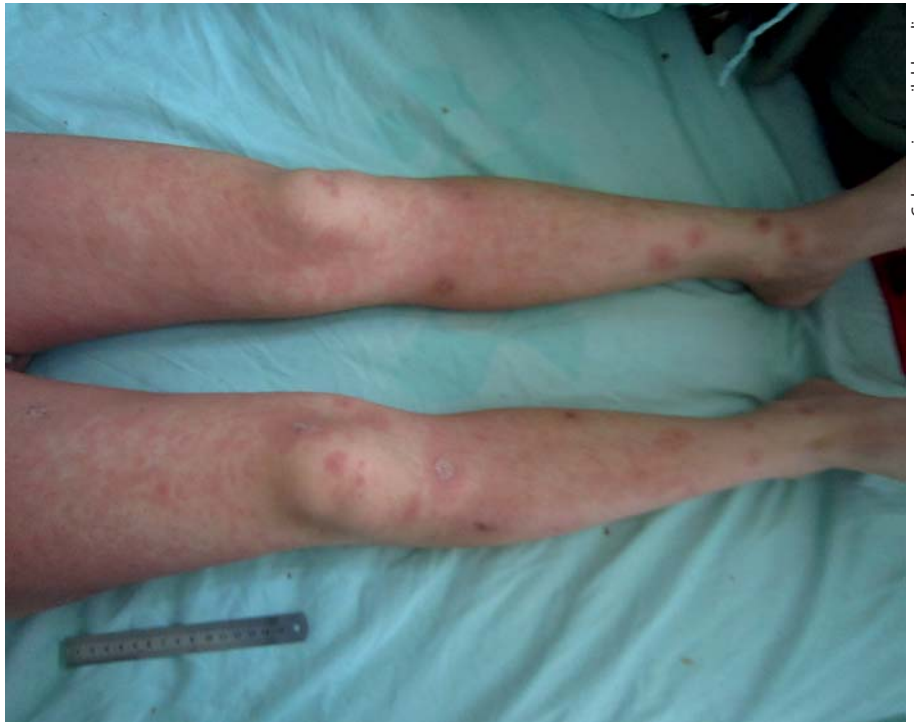Color version available online

**Fig. 2.** Dilated capillary loops surrounded by lymphocytes, neutrophils and rare eosinophils. HE.  $\times 400$ .



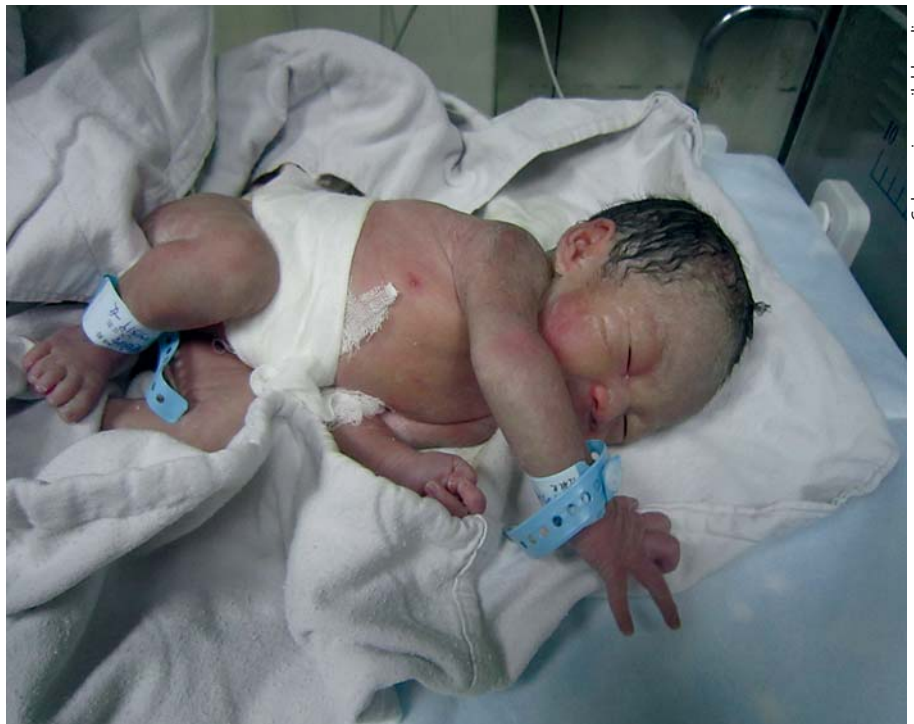Color version available online

**Fig. 3.** Crusting and decrustation on the patient's abdomen.



Color version available online

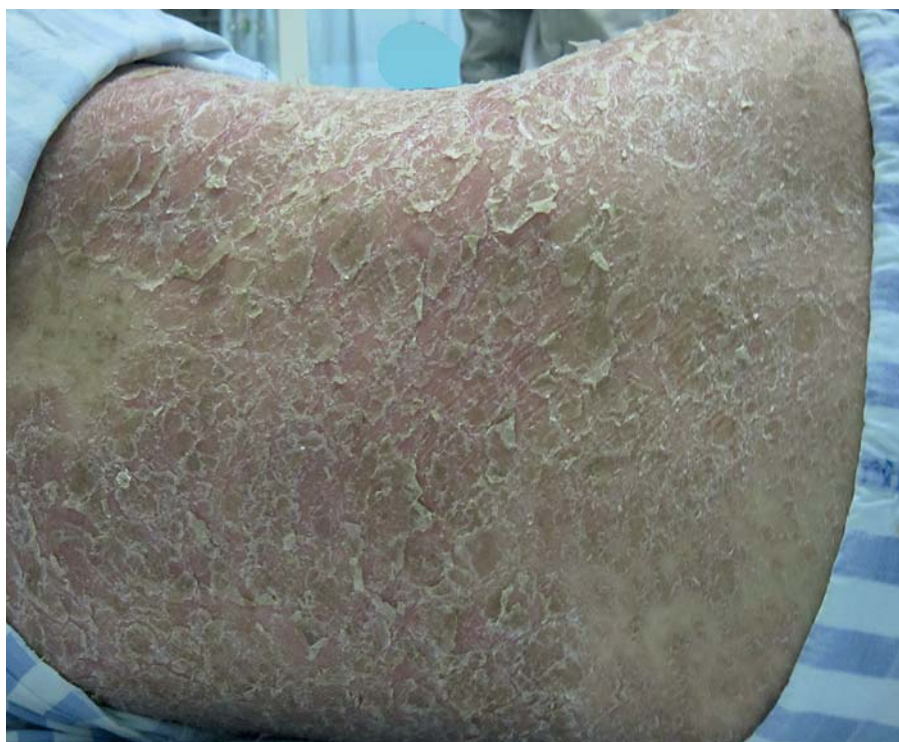**Fig. 4.** Erythema spread all over the patient's legs.



Color version available online

**Fig. 5.** Female baby (35 weeks' gestation age) with no pustular or other erythema (weight 1.8 kg).





**Fig. 6.** Exfoliation of the patient's back (2 weeks postpartum).

There are considerable debates on the classification of IH [2, 11, 12, 17, 18]. Some authorities consider the disease as an acute pustular phase of psoriasis, and it may also be a rare form of generalized pustular psoriasis (GPP) in pregnancy. Other observers have defined IH as a distinct entity. Baker and Ryan [19] have reviewed 104 cases of GPP. This disease, which predominantly comes on in the second half of life, affects both sexes and can be provoked by the withdrawal of systemic corticosteroid therapy, pregnancy and infection. Compared with IH, GPP is a rare and yet potentially lethal clinical variant of psoriasis, which is characterized by the formation of sterile cutaneous pustules, neutrophilia, fever and features of systemic inflammation [20]. Only by clarifying the pathogenesis of IH can we distinguish IH from psoriasis.

Although genetic study of IH is rare, some scientific studies of GPP have been carried out by researchers like Onoufriadis et al. [20]. It was found that the function loss of IL-36RN (previously known as IL-1F5) implicates that GPP is caused by innate immune dysregulation in this severe episodic inflammatory disease. Therefore, taking IL-1 as a potential target for therapeutic intervention might cure the disease [20, 21]. In order to find a better treatment

for IH, more work should be continuously done to find the gene mutation of IH.

The diagnosis of IH is mainly based on typical clinical findings in the third trimester of pregnancy: a disseminated spread of sterile pustules is often complicated by major general symptoms such as fever, nausea and hypocalcemic tetany [2]. Some cases report that IH may be complicated by gestational hypertension, fetal distress because of placental insufficiency, hypoparathyroidism, hyperparathyroidism, diabetes or hypoalbuminemia [8, 9, 11, 22, 23].

Even though there was no sign of infection, laboratory findings indicate that leukocytosis, in particular, increased neutrophils and created an elevated erythrocyte sedimentation rate. Cases of IH associated with hypocalcemia, hypoalbuminemia and low serum levels of vitamin D have been reported [2, 8, 9], but the contribution of these abnormalities is still uncertain. Some authors infer that IH may be an autoimmune disease. Although the significance of histopathological examination of skin and placenta is not specified clearly, it can help the doctor to diagnose IH.

There are no guidelines for standard treatments of IH. According to the literature review, the treatments of IH mainly include systemic corticosteroids (predni-

sone), cyclosporine, antibiotic, methotrexate, ultraviolet A (PUVA), system retinoids and clofazimine [2, 7–12, 17, 18, 22–24]. At the beginning of IH or in mild cases, corticosteroids are usually efficacious at a low dose of 15–30 mg a day. In some severe cases, it is necessary to increase the dose to 40–60 mg a day to control the symptoms [2, 22]. However, some cases reported that the patients were unresponsive to corticosteroid therapy [10, 17, 22]. In progressive cases, oral cyclosporine is the second-line therapy for IH and antibiotics should be administered to treat or prevent secondary infection [2, 9, 17, 22]. Furthermore, it is reported that taking parenteral calcium, vitamin D, infliximab and pyridoxine in high doses, as well as chorionic gonadotropin, is effective for IH during pregnancy. Moreover, taking methotrexate, retinoid (such as isotretinoin, acitretin) and PUVA is helpful for curing IH after delivery [2, 10, 23–26]. According to the United States Food and Drug Administration pregnancy safety index, prednisolone and cyclosporine classified into 'C' category are safer alternatives in pregnancy than methotrexate and retinoid classified into 'X' category [24]. In addition, because of its long half-life, it is not sure whether a baby can be exposed to acitretin through the mother's

milk; therefore breastfeeding should be a carefully considered option when the mother is taking acitretin.

It is necessary to find the causes of IH and better treatment for prognosis, as there is no guideline to direct the time, dosage and type of drugs for therapy due to the rarity of IH cases. Considering the risk of treating IH, it is important to warn the patient of the side effects of special medicine with a signed informed consent. IH induces a high risk of infection, massive body fluid loss and electrolyte imbalance. Fluid and electrolytes, especially serum calcium, need to be closely monitored. In addition, maternal cardiac and renal functions should also be monitored [2, 22], as they can quickly deteriorate with disease progression. Besides close monitoring and aggressively controlling maternal symptoms, electronic fetal monitoring and uterine artery Doppler ul-

trasound are useful as screening tools to detect placental insufficiency. The final step in the treatment of resistant cases should be the early delivery of the fetus.

In summary, this case we reported was unresponsive to corticosteroid therapy. Correction of electrolyte imbalance, prevention from infection, psychological support and other symptomatic treatment were the mainstay of treatment during the antepartum period. After delivery, acitretin therapy and systemic support treatment were the suitable choice.

### Conclusions

The pathogenesis of IH is still unknown. IH is associated with high mortality and morbidity in both fetus and mother, but with early diagnosis, close monitoring and

proper treatment a better prognosis could be achieved. In spite of many therapies, the effective treatments of IH are still not specified and the process of diagnosis and therapy should be standardized. Multidisciplinary cooperation is important in the treatment of IH.

### Acknowledgements

The authors wish to thank the Fourth People's Hospital of Zigong City, Sichuan, China, for providing pathological sections.

### Disclosure Statement

The publication of this paper has no financial interest for the editors, their relatives, or their institution.

### References

- 1 von Hebra F: Ueber einzelne während Schwangerschaft, des Wochenbettes und bei Uterinalkrankheiten der Frauen zu beobachtende Hautkrankheiten. *Wien Med Wochenschr* 1872;22:1197–1202.
- 2 Oumeish OY, Parish JL: Impetigo herpeticiformis. *Clin Dermatol* 2006;24:101–104.
- 3 Sauer GC, Geha BJ: Impetigo herpeticiformis. *Arch Dermatol* 1961;83:173–180.
- 4 Henson TH, Tuli M, Bushore D, Talanin NY: Recurrent pustular rash in a pregnant woman. *Arch Dermatol* 2000;136:1055–1060.
- 5 Baker H, Ryan TJ: Generalized pustular psoriasis. A clinical and epidemiological study of 104 cases. *Br J Dermatol* 1968;80:771–793.
- 6 Bajaj AK, Swarup V, Gupta OP, Gupta SC: Impetigo herpeticiformis. *Dermatologica* 1977; 155:292–295.
- 7 Sahin HG, Sahin HA, Metin A, Zeteroglu S, Ugras S: Recurrent impetigo herpeticiformis in a pregnant adolescent: case report. *Eur J Obstet Gyn Reprod Biol* 2002;101:201–203.
- 8 Sardy M, Preisz K, Berecz M, Horvath C, Karpatis S, Horvath A: Methotrexate treatment of recurrent impetigo herpeticiformis with hypoparathyroidism. *J Eur Acad Dermatol Venereol* 2006;20:742–743.
- 9 Lakshmi C, Srinivas CR, Paul S, Chitra TV, Kanchanamalai K, Somasundaram LS: Recurrent impetigo herpeticiformis with diabetes and hypocalcaemia successfully treated with cyclosporine, albumin, insulin and metformin. *Indian J Dermatol* 2010;55:181–184.
- 10 Cravo M, Ieira R, Tellechea O, Figueiredo A: Recurrent impetigo herpeticiformis successfully treated with methotrexate. *J Eur Acad Dermatol Venereol* 2009;23:336–337.
- 11 Fouda UM, Foud RM, Ammar HM, Salem M, Darouti MEI: Impetigo herpeticiformis during the puerperium triggered by secondary hypoparathyroidism: a case report. *Cases J* 2009;2: 9338.
- 12 Chaidemenos G, Lefaki I, Tsakiri A, Mourelou O: Impetigo herpeticiformis: menstrual exacerbations for 7 years postpartum. *J Eur Acad Dermatol Venereol* 2005;19:466–469.
- 13 Moynihan GD, Ruppe JP Jr: Impetigo herpeticiformis and hypoparathyroidism. *Arch Dermatol* 1985;121:1330–1331.
- 14 Holm AL, Goldsmith LA: Impetigo herpeticiformis associated with hypocalcaemia. *Arch Dermatol* 1991;127:91–95.
- 15 Vicdan K, Gokay Z, Var T, Danisman N, Gokmen O: Twin sisters with impetigo herpeticiformis. *Eur J Obstet Gyn Reprod Biol* 1995;63: 195–196.
- 16 Erbagci Z, Erkilic S: A case of recurrent impetigo herpeticiformis with a positive family history. *Int J Clin Pract* 2000;54:619–620.
- 17 Arslanpence I, Dede FS, Gokcu M, Gelisen O: Impetigo herpeticiformis unresponsive to therapy in a pregnant adolescent. *J Pediatr Adolesc Gynecol* 2003;16:129–132.
- 18 Oumeish OY, Al-Fouzani AW: Miscellaneous diseases affected by pregnancy. *Clin Dermatol* 2006;24:113–117.
- 19 Baker H, Ryan TJ: Generalized pustular psoriasis: a clinical and epidemiological study of 104 cases. *Brit J Dermatol* 1968;80:77.
- 20 Onoufriadis A, Simpson MA, Pink AE, Meglio PD, Smith CH, Pullabhatla V, Knight J, Spain SL, Nestle FO, Burden AD, Capon F, Trembath RC, Barker JN: Mutations in IL-36RN/IL1F5 are associated with the severe episodic inflammatory skin disease known as generalized pustular psoriasis. *Am J Hum Genet* 2011;89:432–437.
- 21 Abbas O, Itani S, Ghosn S, Kibbi AG, Fidawi G, Farooq M, Shimomura Y, Kurban M: Acrodermatitis continua of Hallopeau is a clinical phenotype of DITRA: evidence that it is a variant of pustular psoriasis. *Dermatology* DOI: 10.1159/000346572.
- 22 Huang YH, Chen YP, Liang CC, Chang YL, Hsieh CC: Impetigo herpeticiformis with gestational hypertension: a case report and literature review. *Dermatology* 2011;222:221–224.
- 23 Wolf R, Tartler U, Stege H, Megahed M, Ruzicka T: Impetigo herpeticiformis with hyperparathyroidism. *J Eur Acad Dermatol Venereol* 2005;19:743–746.
- 24 Lim KS, Tang MBY, Ng PPL: Impetigo herpeticiformis – a rare dermatosis of pregnancy associated with prenatal complications. *Ann Acad Med Singapore* 2005;34:565–568.
- 25 Masmoudi A, Abdelmaksoud W, Ghorbel S, Amouri H, Mseddi M, Bouassida S, Zahaf A, Guermazi M, Boudaya S, Turki H: Impetigo herpeticiformis (two cases). *J Gynecol Obstet Biol Reprod* 2008;37:804–807.
- 26 Doebelin B, Estival JL, Nau A, Dupin M, Combemale P: Impetigo herpeticiformis and Ondine curse. *Ann Dermatol Venereol* 2005; 132:559–561.