

Long-Term Follow-up of Shoulder Hemiarthroplasty for Glenohumeral Osteoarthritis

William N. Levine, MD, Charla R. Fischer, MD, Duong Nguyen, MD, Evan L. Flatow, MD,
Christopher S. Ahmad, MD, and Louis U. Bigliani, MD

Investigation performed at the Center for Shoulder, Elbow and Sports Medicine, Columbia University Medical Center, New York, NY

Background: There is major controversy surrounding the use of hemiarthroplasty as compared with total shoulder arthroplasty for glenohumeral osteoarthritis, and long-term clinical outcomes of hemiarthroplasty are lacking.

Methods: Of a cohort of thirty patients (thirty-one shoulders) who were treated with hemiarthroplasty for glenohumeral osteoarthritis and followed longitudinally at our institution, twenty-five were available for long-term follow-up; five died, and one refused to participate. Three of the five patients who died had revision arthroplasty before death, and the data from those three were therefore included in the final follow-up (final follow-up data therefore included twenty-seven patients and twenty-eight shoulders). Follow-up through phone conversations and postal mail surveys included the following: Short Form-36, American Shoulder and Elbow Surgeons (ASES) shoulder outcome score, EuroQol, Simple Shoulder Test, modified Neer Score, and a unique, validated self-administered range-of-motion questionnaire. Correlations between clinical outcome and age, type of glenoid wear, and cause of osteoarthritis were determined.

Results: The average follow-up was 17.2 years (range, thirteen to twenty-one years). There were eight revisions (three of fifteen shoulders with concentric glenoids, and five of sixteen shoulders with eccentric glenoids). For those shoulders not revised, the average ASES score was 70.54 (range, 36.67 to 91.67). Overall, active shoulder forward elevation and external rotation with the arm at 90° of abduction increased from 104° preoperatively to 141.8° (range, 45° to 180°) and 20.7° to 61.0° (range, 30° to 90°), respectively ($p < 0.05$), at the time of final follow-up. Of those who required revision arthroplasty, the average patient age at the time of the index procedure was 51.0 years (range, twenty-six to eighty-one years), while those not requiring revision averaged 57.1 years (range, twenty-seven to sixty-three years). The overall Neer satisfaction rating was 25%. The average Neer score and Neer rating for unrevised cases were significantly higher for concentric glenoid wear compared with eccentric glenoid wear ($p = 0.015$ and $p = 0.001$, respectively). Patients who had concentric glenoid wear had higher EuroQol scores ($p = 0.020$). The average Neer scores were 65.29 (range, forty-seven to seventy-eight) for primary osteoarthritis and 54.46 (range, forty to seventy-seven) for secondary osteoarthritis ($p = 0.036$).

Conclusions: Only 25% of patients with glenohumeral osteoarthritis treated with shoulder hemiarthroplasty are satisfied with their outcome at an average of seventeen years after the operation. Patients with concentric glenoid wear and primary osteoarthritis have better outcomes than those with eccentric glenoid wear and secondary osteoarthritis do, but patients in both groups experienced deterioration of results over time.

Level of Evidence: Therapeutic Level IV. See Instructions for Authors for a complete description of levels of evidence.

Osteoarthritis of the glenohumeral joint is a life-altering disease, the treatment for which was dramatically changed in the 1970s with the introduction of shoulder arthroplasty. Initially, humeral head replacement alone was in-

troduced for the treatment of glenohumeral osteoarthritis. Good results were reported, with most patients experiencing pain relief and return of shoulder function¹. Yet some patients had a slow recovery of strength and had continuing shoulder fatigability.

Disclosure: None of the authors received payments or services, either directly or indirectly (i.e., via his or her institution), from a third party in support of any aspect of this work. One or more of the authors, or his or her institution, has had a financial relationship, in the thirty-six months prior to submission of this work, with an entity in the biomedical arena that could be perceived to influence or have the potential to influence what is written in this work. No author has had any other relationships, or has engaged in any other activities, that could be perceived to influence or have the potential to influence what is written in this work. The complete **Disclosures of Potential Conflicts of Interest** submitted by authors are always provided with the online version of the article.

Glenoid resurfacing was later introduced by Neer, who found that patients had superior pain relief and greater patient satisfaction compared with humeral head replacement alone². Indications for humeral head replacement alone were questioned³⁻¹¹. Studies showed that, in comparison with total shoulder replacement, humeral head replacement led to better outcomes in patients with severe rotator cuff disease, persistent instability, and lack of glenoid bone stock^{12,13}, in part due to the early loosening and failure of the glenoid component that occurred after total shoulder replacement^{6,14-17}.

Glenoid component failure has been a major concern in shoulder arthroplasty. Progressive radiolucent lines are commonly found on postoperative radiographs of patients who have undergone glenoid resurfacing; however, the mere presence of these radiolucent lines is not always indicative of glenoid component failure requiring revision^{6,8,14,16}. Torchia et al.¹⁸ showed that glenoid loosening was associated with pain, yet Boyd et al. found no association with progressive glenoid loosening and pain⁶. The condition of the glenoid is one of many factors influencing the decision-making to resurface the glenoid during shoulder arthroplasty. Other critical factors include patient age, the condition and integrity of the rotator cuff, and the presence of inflammatory arthritis. There is no formula to determine which patients should receive a hemiarthroplasty and which should receive a total shoulder arthroplasty. These factors have to be counterbalanced with the concern that exists regarding the durability of shoulder hemiarthroplasty. Other alternatives that have been used to avoid prosthetic glenoid implantation include biologic resurfacing of the glenoid with interpositional graft (fascia lata, capsule, or Achilles tendon)¹⁹, arthroscopic glenoplasty²⁰, and glenoid reaming ("ream and run")²¹. There are risks associated with all of these, and, although limited short-term success has been reported, none has demonstrated long-term durability.

The radiographic appearance and clinical features of the glenoid are critical in determining whether humeral head replacement alone will be successful. We previously reported that patients with concentric glenoids had better outcomes than those with eccentric glenoids²². This finding suggested that eccentric glenoid wear may be a relative contraindication for isolated humeral head replacement. Later studies further validated these results, including the study by Iannotti and Norris, which showed that patients with eccentric glenoid wear had better results with total shoulder arthroplasty than they did with humeral head replacement²³.

The purpose of the current study was to report on the long-term outcomes of patients treated with hemiarthroplasty for glenohumeral osteoarthritis and to compare the results with those from our previous study, which had much shorter follow-up²². The hypothesis was that, irrespective of glenoid type, the outcomes of hemiarthroplasty would deteriorate over time and patients with eccentric glenoid wear would fare worse.

Materials and Methods

In this retrospective study, we reviewed the forty-two patients with glenohumeral osteoarthritis who had been treated with shoulder hemiarthroplasty at our institution between June 1990 and December 1994. In our previously

reported series²², thirty (thirty-one shoulders) of those forty-two patients were available for midterm follow-up at 7.9 years. From this original cohort, twenty-seven patients (twenty-eight shoulders) were available for the current follow-up at 17.2 years after the initial hemiarthroplasty. Five of the original patients had died, but three had undergone revision arthroplasty prior to death and were included in our follow-up data. One patient refused to participate in follow-up due to continued pain. We obtained informed consent from participating patients, and our institutional review board approved this study.

There were fifteen men and fifteen women. Nine patients (ten shoulders) were treated for primary osteoarthritis, including seven men (one received bilateral treatment) and two women. Twenty-one patients (twenty-one shoulders) were treated for secondary osteoarthritis, including eight men and thirteen women. Of the patients with secondary osteoarthritis, seven had osteoarthritis as a result of prior trauma, four had osteoarthritis caused by a prior glenohumeral instability repair (three Putti-Platt and one Magnuson-Stack), seven had osteonecrosis of the humeral head, and three developed chronic arthritis as a result of other reasons (e.g., neonatal septic arthritis).

All surgical procedures were done through a standard deltopectoral approach and with use of anterior and inferior capsular release to allow for stable external rotation after repair of the subscapularis tendon. There was no intraoperative evidence of posterior glenohumeral subluxation. Four subacromial decompressions were performed, and no rotator cuff tears were present. All patients received a Neer II prosthesis (3M, St. Paul, Minnesota), and all patients followed a standard rehabilitation program starting immediately after the operation.

The condition of the glenohumeral joint was evaluated preoperatively on axillary radiographs and then confirmed at the time of surgery for the type of glenoid wear. At the time of this study, advanced imaging studies such as computed tomography (CT) and/or magnetic resonance imaging (MRI) were not routinely ordered prior to performing shoulder arthroplasty. We now routinely perform preoperative CT on all shoulder arthroplasty patients to better assess the glenoid wear, as axillary radiographs can be misleading. Additional intraoperative factors were noted, such as presence of scarring causing contractures, the presence of humeral osteophytes, and the presence of intra-articular loose bodies. Although no patients had rotator cuff tears, fraying of the tendons was evaluated. The type of glenoid wear was categorized as either type I or type II, consistent with categories used in our initial study. Type-I glenoids had a concentric cartilage degeneration pattern that created a concentric osseous surface without flattening or significant bone loss. Type-II glenoids were no longer concentric as a result of uneven bone loss in addition to the cartilage surface loss²².

At the time of follow-up examination, patients were evaluated with a variety of outcome tools, including the Short-Form 36 (SF-36), the EuroQol, the modified Neer score, the American Shoulder and Elbow Surgeons (ASES) data sheet, the Simple Shoulder Test, a visual analog scale (VAS) for pain, an assessment of subjective satisfaction, and a validated, patient self-assessment range-of-motion questionnaire²⁴. (Please see the Appendix for a description of the modified Neer rating scale, the EuroQol, and the patient self-assessment range-of-motion questionnaire.) The range-of-motion questionnaire is a validated self-reporting tool that allows patients to accurately determine their range of motion. This had been proven to be highly effective and accurate. Regarding the Neer rating scale, excellent and good were included in the satisfactory group, and fair and poor were included in the unsatisfactory group. Subjective satisfaction was evaluated on a scale of very satisfied, satisfied, or dissatisfied.

Statistical Methods

While the purpose of our study was to report the long-term results after humeral hemiarthroplasty, we also analyzed the effect of glenoid wear pattern and surgical indication. One null hypothesis stated that there is no difference in long-term outcomes of shoulder hemiarthroplasty in patients with concentric and eccentric glenoid wear. The second null hypothesis was that patients with primary osteoarthritis have similar long-term outcomes after shoulder hemiarthroplasty as patients whose osteoarthritis is secondary to trauma. We performed Student t tests to determine the significance of the differences seen in each group.

TABLE I Patient Demographics by Subgroup

	Primary Osteoarthritis	Secondary Osteoarthritis
Male patients (no. of shoulders)	7 (8)	8 (8)
Female patients (no. of shoulders)	2 (2)	13 (13)
Age at surgery (yr)	58.8	53.9
Length of follow-up (yr)	17.43	17.03
Revisions	2	6
Concentric glenoid (type I)	7	8
Eccentric glenoid (type II)	3	13
Indications for hemiarthroplasty		
Osteoarthritis cause by instability repair		4
Posttraumatic osteoarthritis		7
Osteonecrosis of the humeral head		7
Other causes of osteoarthritis		3

Source of Funding

There were no external sources of funding provided for this study.

Results

The loss of patients between the short-term (i.e., twenty-nine months) follow-up of thirty-one shoulders and the long-term (i.e., 17.2 years) follow-up of twenty-eight shoulders did not produce differences in the patient demographics.

The average length of follow-up of these patients was 17.2 years (range, thirteen to twenty-one years). The average age of the patients at the time of initial hemiarthroplasty was 55.5 years (range, twenty-six to eighty-one years; standard deviation, 12.7). The average age at the time of the most recent follow-up of 17.2 years was 71.46 years (range, 42.69 to eighty-five years).

The pertinent demographic data is listed in Table I.

The overall Neer scores showed 25% (seven of twenty-eight) satisfactory results and 75% (twenty-one of twenty-eight) unsatisfactory results. Eight shoulders (29%) had undergone revision arthroplasty and were considered as having a poor outcome. In total, there were four (14%) excellent results, three (11%) good results, three (11%) fair results, and eighteen (64%) poor results. Of the twelve shoulders with type-I glenoid wear, five (42%) had satisfactory results and seven (58%) had unsatisfactory results. Of the sixteen shoulders with type-II glenoid wear, two (13%) had satisfactory results and fourteen (88%) had unsatisfactory results. The outcomes were considered satisfactory in four (44%) of the nine shoulders with primary osteoarthritis and three (16%) of the nineteen shoulders with secondary osteoarthritis. The results are summarized in Table II along with the published results from the 2.4-year follow-up and the unpublished results from the midrange 7.9-year follow-up.

While the overall results were poor, a comparison of the Neer scores according to glenoid wear type and osteoarthritis type showed significant differences. The average modified Neer score, Neer rating, and Neer satisfaction for type-I glenoids were significantly better than they were for type-II glenoids

($p = 0.015, 0.001, \text{ and } 0.045$, respectively) (Table III). Only the Neer score was significantly better for patients with primary osteoarthritis than it was for patients with secondary osteoarthritis (65.29 [range, forty-seven to seventy-eight] compared with 54.46 [range, forty to seventy-seven], respectively; $p = 0.036$) (Table III).

Overall, shoulder motion was significantly improved from baseline. Both active forward elevation and external rotation with the arm in 90° of abduction improved significantly (104° to 141.8° [range, 45° to 180°] and 20.7° to 61.0° [range, 30° to 90°], respectively; $p < 0.05$) from the time that the preoperative baseline measurements were made until the time of final follow-up. The average level of active internal rotation did not improve significantly. Shoulder motion was obtained at the latest follow-up with a validated self-assessment form that was not available at the time of the initial surgery. At the time of long-term follow-up, the overall pain scores remained low at 2.20 (range, 0 to 8). The shoulder motion and pain outcomes showed more improvement for patients with type-I glenoids than for patients with type-II glenoids. The average forward elevation, external rotation with the arm in 90° of abduction,

TABLE II Patient Satisfaction According to the Neer Criteria

	Patient Satisfaction		
	At 2.4 Years	At 7.9 Years*	At 17.2 Years
Overall	74%	61%	25%
Concentric glenoid (type I)	84%	67%	42%
Eccentric glenoid (type II)	63%	56%	12%
Primary osteoarthritis	80%	NA	44%
Secondary osteoarthritis	71%	NA	16%

*NA = not available.

TABLE III Average Modified Neer Scores by Patient Subgroup

	Concentric Glenoid (Type I)	Eccentric Glenoid (Type II)	P Value	Primary Osteoarthritis	Secondary Osteoarthritis	P Value
Neer score (range)	64.89	51.09	0.015	65.29 (47 to 78)	54.46 (40 to 77)	0.036
Neer rating	Good	Poor	0.001	Fair	Poor	0.086
Neer satisfaction	Satisfied	Unsatisfied	0.045	Satisfied	Unsatisfied	0.071

TABLE IV Average Range of Motion and Pain by Patient Subgroup

	Concentric Glenoid (Type I)	Eccentric Glenoid (Type II)	P Value	Primary Osteoarthritis	Secondary Osteoarthritis	P Value
Forward elevation	155°	130.9°	0.115	171°	126°	0.013
External rotation with arm in 90° of abduction	65.56°	57.27°	0.247	80.71°	50.38°	0.004
Internal rotation	L5 level	L5 level	0.415	L5 level	L5 level	0.411
Visual analog scale pain score	2.0	2.36	0.390	1.0	2.84	0.081

TABLE V Average Subjective Outcome Scores by Subgroup*

	Concentric Glenoid (Type I)	Eccentric Glenoid (Type II)	P Value	Primary Osteoarthritis	Secondary Osteoarthritis	P Value
ASES	77.04	65.23	0.11	81.67	64.55	0.04
SF-36	69.67	69.64	0.50	68.57	70.23	0.423
EuroQol	0.676	0.446	0.020	0.546	0.551	0.482
Simple Shoulder Test	9.22	7.27	0.075	10.29	7.00	0.007
Patient-reported satisfaction	Very satisfied	Satisfied	0.240	Very satisfied	Satisfied	0.139

*ASES = American Shoulder and Elbow Surgeons shoulder outcome score, SF-36 = Short-Form 36.

and internal rotation were better for patients with type-I glenoids, but the difference was not significant. The average active internal rotation was to the 5th lumbar vertebra for both type-I and type-II glenoids. Pain scores were also very similar between the two groups (Table IV). Shoulder motion outcomes with regard to forward elevation and external rotation with the arm in 90° of abduction were significantly better for patients with primary osteoarthritis than for patients with secondary osteoarthritis ($p = 0.013$ and 0.004 , respectively) (Table IV).

The long-term patient-centered outcome scores for the patients with nonrevised shoulders were compared with the preoperative and short-term scores of patients from the same cohort. The average ASES scores for the nonrevised shoulders at the time of long-term follow-up showed improvement over the short-term follow-up scores. The overall outcome scores for the twenty nonrevised shoulders at the time of long-term follow-up were as follows: ASES score, 70.54 (range, 36.67 to 91.67); SF-36 score, 69.65 (range, 30 to 98.33); EuroQol score, 0.549 (range, 0.113 to 0.841); and the Simple Shoulder Test

score, 8.15 (range, 4 to 12). Although the outcome measures were greater for patients with type-I glenoids than for those with type-II glenoids, there was a significant difference only for the EuroQol score ($p = 0.020$).

Subjective patient satisfaction varied according to glenoid type, with type-I glenoids associated with an average rating of “very satisfied” and type-II glenoids associated with an average rating of “satisfied” (Table V). Patients who had primary osteoarthritis also fared better with regard to outcome scores and patient satisfaction than did patients who had secondary osteoarthritis (Table V).

The overall revision rate was 29% (eight of twenty-eight shoulders). Shoulders with a type-I glenoid were revised at a rate of 25% (three of twelve shoulders), and shoulders with a type-II glenoid were revised at a rate of 31% (five of sixteen shoulders) (Fig. 1). Patients who underwent revision had an average age of 51.0 years (range, twenty-six to eighty-one years) at the time of the index procedure. The patients who did not undergo revision had an average age of 57.1 years (range,

Survivorship

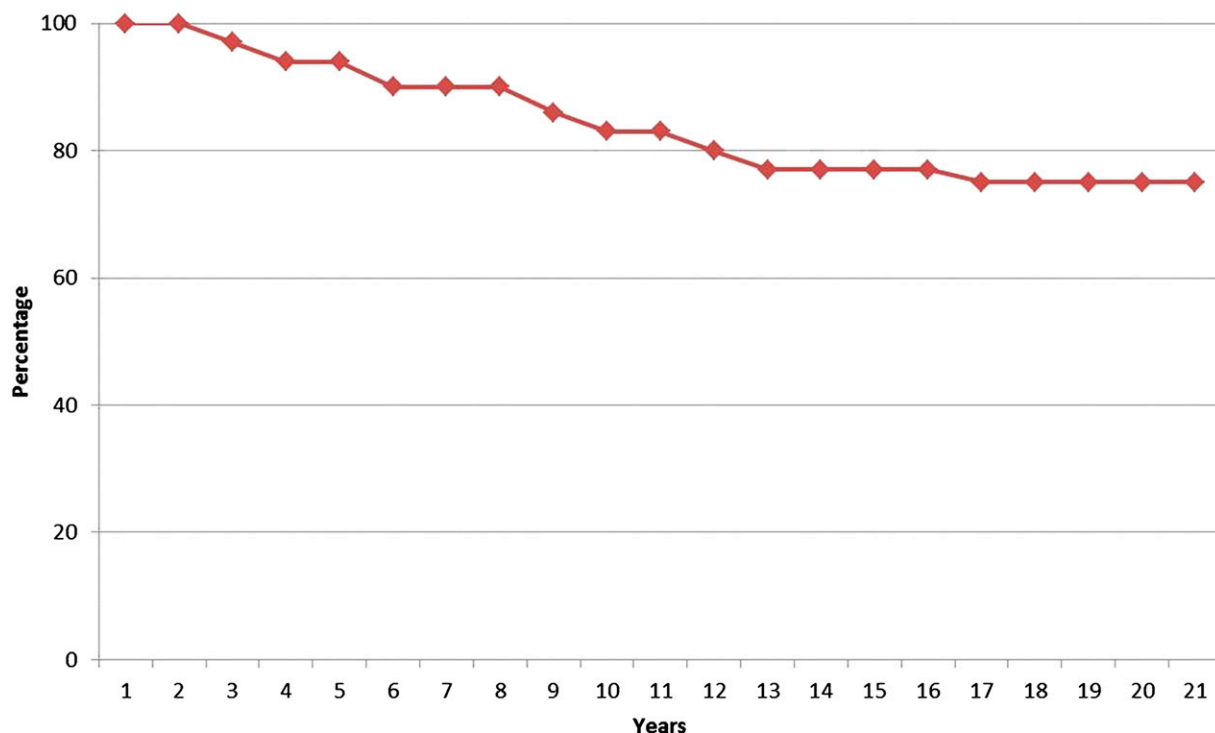


Fig. 1
Survivorship of hemiarthroplasty implants over time.

twenty-seven to sixty-three years) at the time of surgery. Seven patients (eight shoulders) underwent revision. Of these seven, one patient who had undergone bilateral hemiarthroplasties for the treatment of primary osteoarthritis underwent revision procedures and received a total shoulder replacement for the right shoulder at four years and for the left shoulder at twelve years. Arthroscopic debridement of the glenohumeral joint was performed in the right shoulder two years after the initial surgery, and the hemiarthroplasty implant was converted to a total shoulder prosthesis two years later. The indication for both revisions was a painful hemiarthroplasty. Another hemiarthroplasty patient who had undergone prior glenohumeral instability repair with a Putti-Platt procedure underwent revision to a total shoulder prosthesis three years after the hemiarthroplasty procedure. One patient who initially had humeral head osteonecrosis underwent revision to a total shoulder prosthesis ten years after the hemiarthroplasty. A patient who had instability after trauma underwent revision to a total shoulder replacement at two years and then underwent total shoulder revision arthroplasty eleven years after the hemiarthroplasty. One patient who initially had osteonecrosis underwent revision hemiarthroplasty for a superiorly subluxating humeral head at nine years after the hemiarthroplasty. Another patient had pain and underwent revision prior to his death six years after the initial hemiarthroplasty. The final patient underwent revision to a total shoulder arthroplasty seventeen years after the original hemiarthroplasty.

Discussion

The controversy regarding choice of arthroplasty for the treatment of glenohumeral osteoarthritis continues. Long-term follow-up results of our original cohort of patients show deteriorating outcomes for shoulders that undergo humeral head replacement for the treatment of primary and secondary glenohumeral arthritis. Overall patient function decreased in all patients, regardless of glenoid type or presenting diagnosis. The Neer satisfaction score decreased from 74% at 2.4 years, to 61% at 7.9 years, and ultimately to 25% at 17.2 years of follow-up.

There have been several studies that have reported on the long-term results after humeral head replacement. Rispoli et al. followed forty-nine patients and fifty-one humeral head replacements with an average follow-up of 11.3 years¹². They found a revision rate of 25%, which is consistent with our revision rate of 29%. Fifty-eight percent of patients in this study had a satisfactory or excellent result according to a modified Neer rating system. Wirth et al. followed forty-three patients at an average of 7.5 years after hemiarthroplasty¹³. All parameters measured were better at the two-year postoperative evaluation. However, only the Simple Shoulder Test showed a significant retained high value at two and seven years. This study confirms our findings that shoulder function improves in the first few years after hemiarthroplasty but then steadily declines with long-term follow-up.

There are many studies that report the superior midterm to long-term results of total shoulder arthroplasty compared with humeral head replacement for glenohumeral osteoarthritis^{3,6-10,16,25}. Edwards et al. reported on the largest series to date (601 total shoulder arthroplasties and eighty-nine humeral head replacements) and noted that total shoulder arthroplasty had significantly better results than humeral head replacement across all parameters⁸. Orfaly et al. followed patients with humeral head replacement and total shoulder arthroplasty for an average of 4.3 years¹⁰ and found that while pain scores between the hemiarthroplasty and total shoulder arthroplasty groups were similar, total shoulder arthroplasty led to a greater preoperative to postoperative increase in ASES scores. Sperling et al. reported their results at an average of 16.8 years of follow-up after humeral head replacement and total shoulder arthroplasty³. Patients who had undergone humeral head replacement had 60% unsatisfactory results and a revision rate of 18% at ten years and 25% at twenty years. The revision rates following total shoulder arthroplasty were much lower, with 3% at ten years and 16% at twenty years.

Some authors have postulated that a benefit of humeral head replacement in young patients is that it allows for a simple conversion to total shoulder arthroplasty if that procedure becomes necessary in the future. One of our study patients exemplified how difficult conversion can be: first he underwent a humeral head replacement that failed; then he required a complex conversion to total shoulder arthroplasty, which also failed; and finally he underwent a re-revision total shoulder arthroplasty less than two years later. In addition to anecdotal evidence, several studies have shown the difficulty of predicting outcomes following revision conversion arthroplasty. Sperling and Cofield followed eighteen patients who had undergone conversion of humeral head replacement to total shoulder replacement²⁶. At an average follow-up of 5.5 years, they demonstrated a reduction in pain and an improvement in function after conversion to total shoulder arthroplasty, but seven patients continued to have unsatisfactory results. In another study, Carroll et al.⁷ also showed similar results. Sixteen consecutive patients underwent revision to total shoulder arthroplasty at an average of 3.5 years after initial humeral head replacement. At an average of 5.5 years of follow-up, 47% of patients had an unsatisfactory outcome. These two studies illustrate that conversion of a humeral hemiarthroplasty to total shoulder arthroplasty is not straightforward and can result in limited improvement.

After our initial study with an average of 2.4 years of follow-up²², other studies confirmed that patients with concentric glenoids have better outcomes than patients with eccentric glenoids after humeral head replacement. Iannotti and Norris investigated preoperative characteristics that predicted a better postoperative outcome in both humeral hemiarthroplasty and in total shoulder arthroplasty²³. Their cohort included 128 patients, twenty-nine of whom had eccentric glenoids. When compared with patients with eccentric glenoids who had humeral head replacement, patients with eccentric glenoids who underwent total shoulder arthroplasty had better results with regard to pain, satisfaction, quality of life, and ASES

scores. Hettrich et al. reported similar results in seventy-one shoulders in sixty-eight patients at an average follow-up of forty-nine months, showing that, for shoulders without glenoid erosion, patient outcomes as measured by SF-36 and the Simple Shoulder Test were better¹⁷. Hasan et al. examined preoperative characteristics that led to the failure of sixty-four hemiarthroplasties and seventy-four total shoulder arthroplasties¹⁶, finding that 42% of patients with failed hemiarthroplasties had substantial glenoid erosion. Our current study confirms these results with regard to decreased satisfaction in patients with eccentric glenoid wear.

The current study has several limitations. It is a retrospective cohort study and does not have control groups, randomization, or blinding. The small patient cohort is another limitation. We may have been able to detect more significant differences in patient outcome if we had started with a larger sample size. Lastly, because many of the patients had secondary osteoarthritis, the findings of this study cannot be compared with the findings of previous studies that evaluated only primary glenohumeral osteoarthritis or randomized clinical trials that compared humeral head replacement with total shoulder replacement. In addition, univariate analysis does not allow definitive interpretation of the relationship between glenoid morphology and the etiology of osteoarthritis as they are not independent variables.

Despite these limitations, the major strength of this study was the ability to longitudinally follow the original cohort for almost two decades. Our data is in accordance with the literature that questions the use of humeral head replacement as the index procedure of choice for the treatment of glenohumeral arthritis. In addition to our results, many studies have shown poor results in long-term follow-up of humeral head replacement. When comparing total shoulder arthroplasty with humeral head replacement, the results favor the long-term results for total shoulder replacement. Many authors have cited the ability of converting humeral head replacements to total shoulder replacement as an indication for hemiarthroplasty as first-line treatment for younger patients. However, the results of conversions are poor, and the long-term outcomes following total shoulder replacement are superior.

In summary, hemiarthroplasty for glenohumeral osteoarthritis is associated with poor durability and decreasing survivorship with long-term follow-up. Patients with concentric glenoid wear and patients with eccentric glenoid wear both demonstrated lower patient outcomes over time. However, patients with eccentric glenoids had even poorer results than those with concentric glenoids with longer-term follow-up. Based on our experience, we prefer total shoulder replacement to hemiarthroplasty for the surgical management of glenohumeral osteoarthritis in shoulders with an intact rotator cuff.

Appendix

eA A description of the modified Neer rating scale, the EuroQol, and the patient self-assessment range-of-motion questionnaire is available with the online version of this article as a data supplement at jbj.org. ■

William N. Levine, MD
Charla R. Fischer, MD
Duong Nguyen, MD
Evan L. Flatow, MD
Christopher S. Ahmad, MD

Louis U. Bigliani, MD
Center for Shoulder, Elbow and Sports Medicine,
Columbia University Medical Center, 622 West 168th Street,
PH-1117, New York, NY 10032.
E-mail address for W.N. Levine: wnl1@columbia.edu

References

1. Neer CS 2nd. Replacement arthroplasty for glenohumeral osteoarthritis. *J Bone Joint Surg Am.* 1974 Jan;56(1):1-13.
2. Neer CS 2nd, Watson KC, Stanton FJ. Recent experience in total shoulder replacement. *J Bone Joint Surg Am.* 1982 Mar;64(3):319-37.
3. Sperling JW, Cofield RH, Rowland CM. Minimum fifteen-year follow-up of Neer hemiarthroplasty and total shoulder arthroplasty in patients aged fifty years or younger. *J Shoulder Elbow Surg.* 2004 Nov-Dec;13(6):604-13.
4. Sperling JW, Cofield RH, Rowland CM. Neer hemiarthroplasty and Neer total shoulder arthroplasty in patients fifty years old or less. Long-term results. *J Bone Joint Surg Am.* 1998 Apr;80(4):464-73.
5. Bohsali KI, Wirth MA, Rockwood CA Jr. Complications of total shoulder arthroplasty. *J Bone Joint Surg Am.* 2006 Oct;88(10):2279-92.
6. Boyd AD Jr, Thomas WH, Scott RD, Sledge CB, Thornhill TS. Total shoulder arthroplasty versus hemiarthroplasty. Indications for glenoid resurfacing. *J Arthroplasty.* 1990 Dec;5(4):329-36.
7. Carroll RM, Izquierdo R, Vazquez M, Blaine TA, Levine WN, Bigliani LU. Conversion of painful hemiarthroplasty to total shoulder arthroplasty: long-term results. *J Shoulder Elbow Surg.* 2004 Nov-Dec;13(6):599-603.
8. Edwards TB, Kadakia NR, Boulahia A, Kempf JF, Boileau P, Némoz C, Walch G. A comparison of hemiarthroplasty and total shoulder arthroplasty in the treatment of primary glenohumeral osteoarthritis: results of a multicenter study. *J Shoulder Elbow Surg.* 2003 May-Jun;12(3):207-13.
9. Gartsman GM, Roddey TS, Hammerman SM. Shoulder arthroplasty with or without resurfacing of the glenoid in patients who have osteoarthritis. *J Bone Joint Surg Am.* 2000 Jan;82(1):26-34.
10. Orfaly RM, Rockwood CA Jr, Esenyel CZ, Wirth MA. A prospective functional outcome study of shoulder arthroplasty for osteoarthritis with an intact rotator cuff. *J Shoulder Elbow Surg.* 2003 May-Jun;12(3):214-21.
11. Pearl ML, Romeo AA, Wirth MA, Yamaguchi K, Nicholson GP, Creighton RA. Decision making in contemporary shoulder arthroplasty. *Instr Course Lect.* 2005; 54:69-85.
12. Rispoli DM, Sperling JW, Athwal GS, Schleck CD, Cofield RH. Humeral head replacement for the treatment of osteoarthritis. *J Bone Joint Surg Am.* 2006 Dec;88(12):2637-44.
13. Wirth MA, Tapscott RS, Southworth C, Rockwood CA Jr. Treatment of glenohumeral arthritis with a hemiarthroplasty: a minimum five-year follow-up outcome study. *J Bone Joint Surg Am.* 2006 May;88(5):964-73.
14. Baumgarten KM, Lashgari CJ, Yamaguchi K. Glenoid resurfacing in shoulder arthroplasty: indications and contraindications. *Instr Course Lect.* 2004;53:3-11.
15. Boyd AD Jr, Thornhill TS. Surgical treatment of osteoarthritis of the shoulder. *Rheum Dis Clin North Am.* 1988 Dec;14(3):591-611.
16. Hasan SS, Leith JM, Campbell B, Kapil R, Smith KL, Matsen FA 3rd. Characteristics of unsatisfactory shoulder arthroplasties. *J Shoulder Elbow Surg.* 2002 Sep-Oct;11(5):431-41.
17. Hettrich CM, Weldon E 3rd, Boorman RS, Parsons IM 4th, Matsen FA 3rd. Preoperative factors associated with improvements in shoulder function after humeral hemiarthroplasty. *J Bone Joint Surg Am.* 2004 Jul;86(7):1446-51.
18. Torchia ME, Cofield RH, Settergren CR. Total shoulder arthroplasty with the Neer prosthesis: long-term results. *J Shoulder Elbow Surg.* 1997 Nov-Dec;6(6):495-505.
19. Krishnan SG, Nowinski RJ, Harrison D, Burkhead WZ. Humeral hemiarthroplasty with biologic resurfacing of the glenoid for glenohumeral arthritis. Two to fifteen-year outcomes. *J Bone Joint Surg Am.* 2007 Apr;89(4):727-34.
20. O'Driscoll SW. Arthroscopic glenoidplasty and osteocapsular arthroplasty for advanced glenohumeral osteoarthritis. Read at the 67th Annual Meeting of the American Academy of Orthopaedic Surgeons; 2000 Mar 18; Orlando, FL.
21. Clinton J, Franta AK, Lenters TR, Mounce D, Matsen FA 3rd. Nonprosthetic glenoid arthroplasty with humeral hemiarthroplasty and total shoulder arthroplasty yield similar self-assessed outcomes in the management of comparable patients with glenohumeral arthritis. *J Shoulder Elbow Surg.* 2007 Sep-Oct;16(5):534-8. Epub 2007 May 16.
22. Levine WN, Djurasovic M, Glasson JM, Pollock RG, Flatow EL, Bigliani LU. Hemiarthroplasty for glenohumeral osteoarthritis: results correlated to degree of glenoid wear. *J Shoulder Elbow Surg.* 1997 Sep-Oct;6(5):449-54.
23. Iannotti JP, Norris TR. Influence of preoperative factors on outcome of shoulder arthroplasty for glenohumeral osteoarthritis. *J Bone Joint Surg Am.* 2003 Feb; 85-A(2):251-8.
24. Carter CW, Levine WN, Kleweno CP, Bigliani LU, Ahmad CS. Assessment of shoulder range of motion: introduction of a novel patient self-assessment tool. *Arthroscopy.* 2008 Jun;24(6):712-7. Epub 2008 Mar 21.
25. Verborgt O, El-Abiad R, Gazielly DF. Long-term results of uncemented humeral components in shoulder arthroplasty. *J Shoulder Elbow Surg.* 2007 May-Jun; 16(3 Suppl):S13-8. Epub 2006 Oct 25.
26. Sperling JW, Cofield RH. Revision total shoulder arthroplasty for the treatment of glenoid arthrosis. *J Bone Joint Surg Am.* 1998 Jun;80(6):860-7.