

Dobutamine Stress Echocardiography Identifies Hibernating Myocardium and Predicts Recovery of Left Ventricular Function After Coronary Revascularization

Carlos G. Cigarroa, MD; Christopher R. deFilippi, MD; M. Elizabeth Brickner, MD; Luis G. Alvarez, MD; Michael A. Wait, MD; and Paul A. Grayburn, MD

Background. The identification of hibernating myocardium is important in selecting patients who will benefit from coronary revascularization. This study was performed to determine whether dobutamine stress echocardiography (DSE) could identify hibernating myocardium and predict improvement in regional systolic wall thickening after revascularization.

Methods and Results. DSE was performed in 49 consecutive patients with multivessel coronary disease and depressed left ventricular function. Contractile reserve during DSE was defined by the presence of two criteria: (1) improved systolic wall thickening in at least two adjacent abnormal segments and (2) $\geq 20\%$ improvement in regional wall thickening score. Postoperative echocardiograms were evaluated for improved regional wall thickening in 25 patients at least 4 weeks after successful coronary revascularization. All studies were read in blinded fashion. Contractile reserve during DSE was present in 24 (49%) of 49 patients. The presence or absence of contractile reserve on preoperative DSE predicted recovery of ventricular function in the 25 patients who underwent successful revascularization. Thus, 9 of 11 patients with contractile reserve had improved systolic wall thickening after revascularization (hibernating myocardium), whereas 12 of 14 patients without contractile reserve did not improve ($P=.003$).

Conclusions. Dobutamine stress echocardiography provides a simple, cost-effective, and widely available method of identifying hibernating myocardium and predicting improvement in regional left ventricular wall thickening after coronary revascularization. This technique may be clinically valuable in the selection of patients for coronary revascularization. (*Circulation* 1993;88:430-436)

KEY WORDS • echocardiography • dobutamine • myocardium

The term hibernating myocardium was first used by Rahimtoola¹ to describe left ventricular dysfunction resulting from chronic myocardial ischemia and demonstrating recovery of function after coronary revascularization. Several lines of evidence support the concept that hibernating myocardium is clinically important. First, coronary revascularization may lead to improved regional and global left ventricular function,²⁻⁸ even in patients with symptoms of left ventricular dysfunction rather than angina.⁹⁻¹¹ Second, Nesto et al¹² have shown that patients with depressed left ventricular function who manifested significant improvement in preoperative ejection fraction with inotropic stimulation or a premature ventricular contraction have improved long-term survival compared with those lacking contractile reserve. Finally, several studies have shown that the ability to identify contractile reserve in

patients with depressed left ventricular function has important prognostic implications in patients being considered for coronary bypass surgery.¹³⁻¹⁷

Positron emission tomography and ²⁰¹Tl imaging have been used to identify myocardial viability.¹⁸⁻²³ These techniques, based on the cellular uptake of [¹⁸F]fluorodeoxyglucose or ²⁰¹Tl, reflect myocardial perfusion and metabolic activity but do not directly assess contractile function. Conversely, dobutamine has been shown to elicit a contractile response in ischemic myocardium with abnormal regional left ventricular function in an animal model.²⁴ Thus, dobutamine stress echocardiography may offer a simple, cost-effective, and widely available means of detecting contractile reserve in patients with chronic ischemic heart disease and abnormal left ventricular function. Accordingly, the purpose of this study was to determine whether dobutamine stress echocardiography could identify hibernating myocardium and predict improvement in regional left ventricular function after coronary revascularization.

Methods

Patient Population

We prospectively studied 58 consecutive patients with chronic multivessel coronary artery disease and abnor-

Received September 25, 1992; revision accepted March 9, 1993.
From the Department of Internal Medicine, Division of Cardiology, University of Texas Southwestern Medical School and VA Medical Center, Dallas, Tex.

Reprint requests to Paul A. Grayburn, MD, Director, Echocardiography Laboratories, University of Texas Southwestern Medical Center and VA Medical Center, 5323 Harry Hines Blvd, Dallas, TX 75235-9047.

mal resting left ventricular function (left ventricular ejection fraction $\leq 45\%$). Patients were selected if they had undergone cardiac catheterization and were found to have at least two major epicardial vessels with $\geq 70\%$ stenosis and wall motion abnormalities in at least two adjacent segments by ventriculography and/or two-dimensional echocardiography. Patients were specifically excluded if any of the following were present: (1) unstable angina, (2) recent acute myocardial infarction, (3) history of sustained ventricular tachycardia or atrial fibrillation, (4) significant valvular disease, (5) left main coronary artery obstruction $\geq 50\%$, (6) decompensated congestive heart failure, or (7) protruding thrombus in left ventricle. Two patients refused to participate and 7 (12%) had technically inadequate echocardiograms, leaving a total of 49 subjects who completed the study. There were 48 men and one woman, ranging in age from 38 to 73 years (mean, 59 ± 8 years). Mean left ventricular ejection fraction was 0.32 ± 0.08 .

Dobutamine Stress Echocardiography

Written informed consent was obtained in all subjects before they underwent dobutamine stress echocardiography. Patients underwent stress echocardiography after a 3-hour fasting state but were allowed to take all prescribed medications. These studies were performed before any planned revascularization procedure and did not influence clinical management. All subjects underwent two-dimensional echocardiography in the left lateral decubitus position with a Vingmed CFM750 instrument with a 3.25-MHz transducer (Vingmed Sound, Salt Lake City, Utah). Parasternal long-axis, midventricular parasternal short-axis, apical four-chamber, and apical two-chamber images were acquired and recorded on 1/2-in VHS tape for subsequent analysis. Next, a low-dose graded infusion of dobutamine was administered intravenously at increments of 5, 10, 15, and 20 $\mu\text{g} \cdot \text{kg}^{-1} \cdot \text{min}^{-1}$ at 3-minute intervals. Repeat (stress) images were obtained before each incremental increase in the infusion rate and were also recorded on 1/2-in VHS tape. Patients underwent continuous ECG monitoring and, blood pressure was recorded at 3-minute intervals with an automated cuff. Criteria for stopping the dobutamine infusion included (1) hypotension, (2) angina, (3) significant ventricular or supraventricular arrhythmias, (4) attainment of 85% maximal predicted heart rate, or (5) a new or worsened abnormality in systolic wall thickening in at least two segments.

Videotaped echocardiographic images were digitized into a Macintosh IICI computer using commercially available software (ECHOLOOPS 3.01, Vingmed Sound, Salt Lake City, Utah). R-wave triggering was used to capture a representative cardiac cycle in each view at 30 frames per second. The first 350 msec of the selected cycle was displayed in a continuous-loop format to evaluate systolic wall thickening without the potential confounding influence of diastolic septal motion.²⁵ A quad screen format was used to simultaneously compare resting with stress images in the same imaging planes. Regional systolic wall thickening was assessed according to the recommendations of the American Society of Echocardiography with a 16-segment model.²⁶ For each segment, systolic wall thickening is visually graded with a semiquantitative scoring system wherein 1 is normal or

hyperkinetic, 2 is hypokinetic, 3 is kinetic, and 4 is dyskinetic.²⁶ A regional systolic wall thickening score was quantified for each patient by summing the grades for each segment and dividing by the total number of segments analyzed. Since normal and hyperkinetic are both given scores of 1, dobutamine-induced hyperkinesis in normal segments cannot improve wall thickening score. Thus, a decreased wall thickening score reflects improved regional left ventricular function.

Regional wall thickening score was determined at rest and during each level of dobutamine infusion. It was determined before the study that significant improvement in regional systolic wall thickening during dobutamine infusion (contractile reserve) would be defined by the presence of the following two criteria: (1) improved systolic wall thickening grade in at least two adjacent abnormal segments and (2) a reduction in regional wall thickening score sufficient in magnitude to ascertain improved regional left ventricular function at a 95% confidence level. The former criterion was chosen to minimize the potential influence of tethering of an abnormal segment by adjacent normal or hyperkinetic segments. The latter criterion was determined by assessing interobserver and intraobserver differences in regional wall thickening score in the first 20 patients studied. Each of these studies was read in blinded fashion by two experienced observers. The primary observer reinterpreted the studies 4 weeks after his initial reading. Linear regression analysis was used to compare regional wall thickening score between observers. A correlation coefficient of ≥ 0.98 and a coefficient of variation of 10% was present for both interobserver and intraobserver variation. Thus, a 20% reduction in wall motion score represents the 95% confidence level for detecting a significant difference between resting and stress images in our laboratory. By these criteria, contractile reserve was considered to be present if the patient manifested improved regional systolic wall thickening at any dose of dobutamine, even if subsequent doses were associated with worsening of wall thickening caused by ischemia. Fig 1 shows an example of contractile reserve by dobutamine stress echocardiography.

Echocardiographic Follow-up

Follow-up echocardiograms were obtained in patients who underwent successful coronary revascularization to determine the utility of dobutamine stress echocardiography in predicting myocardial salvage. Coronary revascularization was attempted in 29 patients by either coronary artery bypass surgery ($n=25$) or percutaneous transluminal coronary angioplasty (PTCA, $n=4$). There were three perioperative deaths in the coronary bypass population. None of the surviving patients manifested clinical evidence of a perioperative myocardial infarction, and all were thought to have had successful revascularization. PTCA was successful in achieving complete revascularization in three patients, whereas one patient had an unsuccessful attempt to open an occluded artery and subsequently received medical therapy. The remaining patients in this study ($n=20$) received medical therapy (six of whom were considered too high risk for coronary bypass) and did not have a follow-up echocardiogram.

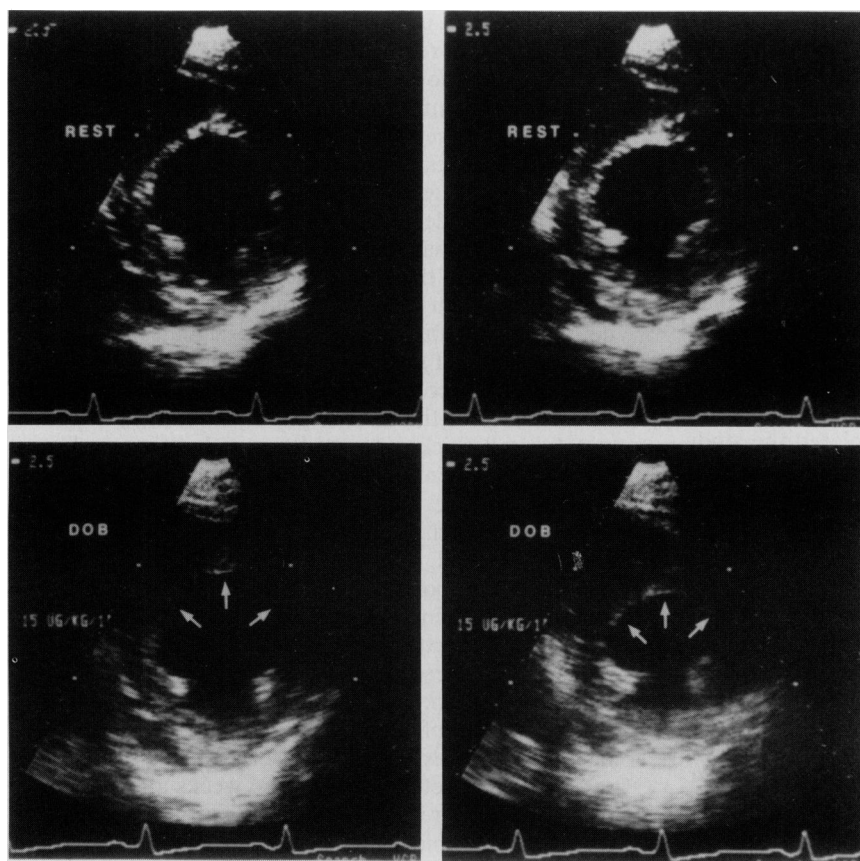


FIG 1. Representative example of contractile reserve as demonstrated by dobutamine stress echocardiography in a patient in this study. Top panels show resting midventricular short-axis frames at end diastole (left) and end systole (right). Marked hypokinesis is present in septal, anterior, and anterolateral segments. Bottom panels show the same views after dobutamine infusion ($15 \mu\text{g} \cdot \text{kg}^{-1} \cdot \text{min}^{-1}$) at end diastole (left) and end systole (right). As shown by the arrows, dobutamine resulted in a marked improvement in regional contractile function.

All patients who underwent successful coronary revascularization ($n=25$) had echocardiographic follow-up at least 4 weeks after their procedure. Postoperative resting wall motion score was determined as previously described by an experienced echocardiographer who was blinded as to patient identification, clinical history, and preoperative dobutamine stress echocardiogram. Postoperative improvement in left ventricular function was defined by the presence of both of the following criteria compared with the resting preoperative echocardiographic report: (1) improved systolic wall thickening grade in at least two adjacent segments and (2) $\geq 20\%$ reduction in wall thickening score.

Statistical Analysis

All data are reported as mean \pm SD. Contingency table analysis using χ^2 with continuity correction was used to determine whether improved regional systolic wall thickening during dobutamine stress echocardiography predicted improvement in regional systolic wall thickening after coronary revascularization. A value of $P \leq .05$ was considered statistically significant.

Results

Dobutamine stress echocardiography identified contractile reserve in 24 (49%) of the 49 patients in this study (Fig 2). The dobutamine dose at which regional wall thickening first showed improvement was variable. Thus, five subjects manifested improvement at $5 \mu\text{g} \cdot \text{kg}^{-1} \cdot \text{min}^{-1}$, eight at $10 \mu\text{g} \cdot \text{kg}^{-1} \cdot \text{min}^{-1}$, five at 15

$\mu\text{g} \cdot \text{kg}^{-1} \cdot \text{min}^{-1}$, and six at $20 \mu\text{g} \cdot \text{kg}^{-1} \cdot \text{min}^{-1}$. Analysis of all individual myocardial segments revealed that akinetic segments were capable of improved contractile function with dobutamine. Specifically, 73 of 184 akinetic segments (40%) showed improved systolic wall thickening during dobutamine infusion. In contrast,

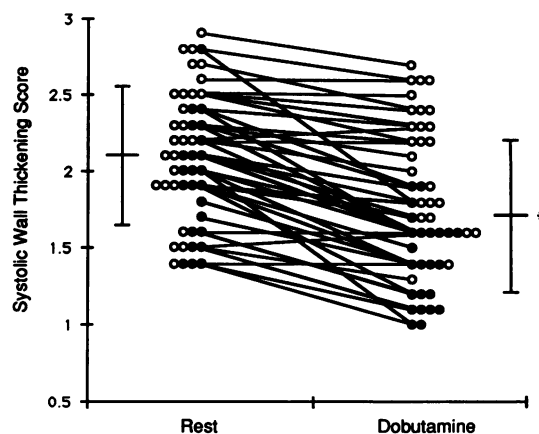


FIG 2. Plot of regional echocardiographic systolic wall thickening scores in all 49 patients at rest and during dobutamine infusion. Closed circles represent the 24 patients who manifested contractile reserve as defined by improved wall thickening in at least two adjacent segments and $\geq 20\%$ improvement in systolic wall thickening score. Mean values \pm SD are shown. * $P < .0001$ compared with resting values.

TABLE 1. Clinical Characteristics of Patients With and Without Contractile Reserve by Dobutamine Stress Echocardiography

	Contractile reserve by DSE		
	Present (n=24)	Absent (n=25)	P
Age (years)	60±9	58±8	.45
No. of diseased vessels	2.7±0.5	2.8±0.4	.19
LVEF	0.35±0.08	0.29±0.09	.016
Wall motion score (rest)	1.9±0.4	2.2±0.4	.012
Wall motion score (DSE)	1.4±0.3	2.1±0.4	.0001
Patients with total occlusion	17 (71%)	17 (68%)	.93
Patients with apical dyskinesia	2 (8.3%)	10 (40%)	.025

DSE, dobutamine stress echocardiography; LVEF, left ventricular ejection fraction.

improved systolic wall thickening was present in only 2 of 38 dyskinetic segments (5%).

Table 1 shows the clinical characteristics of patients with and without contractile reserve by dobutamine stress echocardiography. No significant differences existed in terms of age, number of diseased vessels, or number of patients with totally occluded vessels. However, patients lacking contractile reserve had lower resting ejection fractions and higher wall motion scores and were more likely to have apical dyskinesia.

Fig 3 depicts the results of preoperative dobutamine stress echocardiography and the postoperative echocardiographic follow-up in the 25 patients who underwent successful coronary revascularization. The finding of improved regional wall thickening during dobutamine infusion was predictive of postoperative improvement in wall thickening ($\chi^2=8.83$, $P=.003$). Specifically, 11 patients manifested contractile reserve during dobutamine infusion, 9 (82%) of whom subsequently showed improved regional wall thickening after coronary revascularization. In contrast, 12 of 14 patients (86%) who had no significant contractile improvement during preoperative dobutamine infusion failed to improve after revascularization. Thus, dobutamine stress echocardiography has a high positive and negative predictive value

in determining recovery of regional left ventricular function after revascularization.

The dobutamine stress echocardiography protocol was successfully completed in 45 of the 49 patients (93%). Three studies were discontinued at $20 \mu\text{g} \cdot \text{kg}^{-1} \cdot \text{min}^{-1}$ secondary to angina symptoms, whereas one other patient had asymptomatic hypotension at $15 \mu\text{g} \cdot \text{kg}^{-1} \cdot \text{min}^{-1}$. One subject experienced new-onset atrial fibrillation and chest pain shortly after the infusion ended. This patient underwent successful cardioversion and suffered no evidence of myocardial injury. Other side effects experienced by patients included palpitations (7%), nonsustained ventricular tachycardia (5%), and tingling or flushing sensation (9%). All symptoms of chest pain were relieved quickly with sublingual nitroglycerin.

Discussion

Dobutamine stress echocardiography has received considerable attention as a safe, noninvasive means of diagnosing coronary artery disease.²⁷⁻³¹ This technique uses progressively increasing doses of dobutamine, which may induce ischemic wall motion abnormalities by increasing myocardial oxygen demand in the setting of a coronary stenosis.³² However, low doses of dobutamine may elicit an improved contractile response from myocardial segments that are abnormal at rest, thus demonstrating contractile reserve.²⁴ Previous studies have shown that low-dose dobutamine stress echocardiography can identify contractile reserve in the setting of acute myocardial infarction (stunned myocardium).^{33,34} The present study extends these observations to patients with chronic ischemic heart disease by demonstrating that dobutamine stress echocardiography identifies hibernating myocardium and predicts recovery of segmental left ventricular function after coronary revascularization.

Previous studies have shown that reversal of wall motion abnormalities with inotropic stimulation or nitroglycerin predicts recovery of left ventricular function after revascularization.^{12,35-37} These data are particularly relevant in patients with severely depressed left

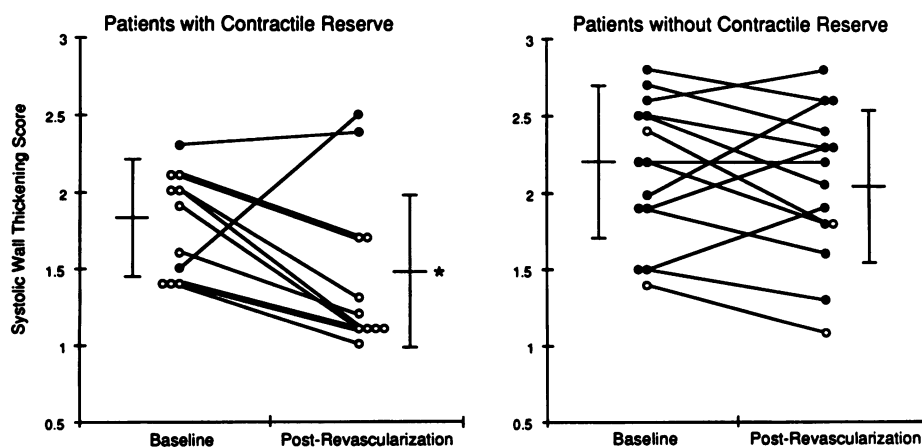


FIG 3. Plot of regional echocardiographic systolic wall thickening scores at rest and after revascularization in patients with (left panel) and without (right panel) contractile reserve by dobutamine stress echocardiography. Open circles represent patients with improved regional left ventricular function after revascularization. Closed circles represent patients without improved regional left ventricular function after revascularization. Error bars show the mean \pm SD. * $P < .0001$ compared with resting values.

ventricular function (ejection fraction ≤ 0.35) who are considered for coronary bypass surgery. Although such patients have significantly higher surgical morbidity and mortality, their long-term survival is improved with bypass surgery compared with medical therapy.³⁸ Nesto et al¹² have shown that patients with depressed left ventricular function who demonstrate significant improvement in ventriculographic ejection fraction ($>10\%$) during inotropic stimulation have improved left ventricular function and better long-term survival after coronary revascularization. In contrast, comparable patients lacking contractile reserve have a poor prognosis whether treated medically or surgically.¹²

The present study was not designed with mortality as an end point. However, eight patients in the study died over a follow-up period ranging from 3 to 6 months. All deaths were cardiac in origin, and all occurred in patients without contractile reserve by dobutamine stress echocardiography. Three deaths occurred in patients receiving medical therapy, all of whom had severely depressed left ventricular function and were considered inoperable. There were three perioperative deaths caused by pump failure, and two other patients underwent bypass surgery and later died of congestive heart failure. Although lack of contractile reserve on dobutamine stress echocardiography was significantly associated with increased cardiac mortality ($\chi^2=5.72$, $P=.017$), it cannot be determined whether this effect is independent of resting left ventricular function. Thus, although the apparent increase in mortality in patients without contractile reserve supports the prognostic findings of Nesto et al,¹² a large prospective clinical trial is needed to determine whether dobutamine stress echocardiography can predict mortality in patients undergoing revascularization.

The major finding of this study is that echocardiographic detection of contractile reserve during low-dose dobutamine infusion is a strong predictor of recovery of left ventricular function after coronary revascularization. Ventriculography has been used to detect contractile reserve^{12,35-37}; however, this is technically cumbersome and has not achieved widespread clinical application. Moreover, ventriculographic improvement in ejection fraction during inotropic stimulation may reflect hyperkinesis in normal segments even if abnormal segments do not improve. In contrast, dobutamine stress echocardiography directly assesses systolic wall thickening in abnormal segments, thus providing regional rather than global left ventricular function. Finally, dobutamine stress echocardiography is simple and noninvasive and avoids the potential adverse effects of additional iodinated contrast on renal function and hemodynamics.

Other methods of detecting viable myocardium, such as positron emission tomography and ²⁰¹Tl reinjection or delayed imaging, have also been shown to predict recovery of left ventricular function after revascularization.^{20,21} Positron emission tomography identifies myocardial viability in terms of metabolic activity by using [¹⁸F]fluorodeoxyglucose to detect the presence of normal or enhanced glucose metabolism in underperfused regions.¹⁸ ²⁰¹Tl imaging identifies viable myocardium on the basis of myocardial uptake and washout of ²⁰¹Tl, which is primarily dependent on myocardial perfusion

and integrity of the cell membrane.³⁹ It is possible that metabolic activity and myocardial perfusion may be present in the absence of contractile function. For example, small islands of viable myocytes may exist within a predominantly infarcted region that is incapable of contractile improvement after revascularization.⁴⁰ Thus, a particular strength of dobutamine stress echocardiography is that it identifies myocardial viability in terms of contractile reserve.

Few studies exist comparing dobutamine stress echocardiography with nuclear techniques in identifying viable myocardium. Pierard et al³⁴ reported a 79% concordance between dobutamine stress echocardiography and positron emission tomography in the identification of viable myocardial segments in 17 patients with acute myocardial infarction who were treated with thrombolytic therapy. Although positron emission tomography, ²⁰¹Tl imaging, and dobutamine stress echocardiography are all capable of identifying viable myocardium, the latter method is widely available, cost-effective, and time-efficient and identifies contractile reserve rather than metabolic activity or myocardial perfusion.

Our data indicate that nearly 50% of patients with coronary artery disease and depressed left ventricular function have significant improvement in regional left ventricular function with dobutamine. Furthermore, the ability to manifest improved segmental contractile function with dobutamine extended to akinetic and rarely to dyskinetic segments. The ability of an akinetic or dyskinetic segment to demonstrate contractile reserve is not surprising, given that pathological studies have shown that these segments may have nontransmural myocardial infarction or even normal myocardium histologically.^{40,41} Furthermore, histopathological analysis of segments lacking contractile reserve generally reveals significant myocardial fibrosis, whereas reversible wall motion abnormalities are associated with minimal muscle loss or even normal myocardium.⁴⁰

Limitations

The number of patients studied was small, precluding multivariate analysis or prediction of patient outcomes. Most of our patients were men; it is uncertain whether the results apply to women. Dobutamine stress echocardiography was not compared with ventriculographic or nuclear methods of assessing myocardial viability.

Dobutamine stress echocardiography is not feasible in approximately 10% of patients because of technically inadequate images. In addition, paradoxical septal motion may confound the interpretation of regional left ventricular function after bypass surgery. Accordingly, we emphasized systolic wall thickening, which minimizes the difficulties encountered by paradoxical septal motion associated with median sternotomy, pacing, or left bundle branch block.⁴² However, since these data were analyzed by a single, experienced observer in a high-volume echocardiography laboratory, the results may not apply to all hospital settings.

Quantitative regional wall motion analysis was not used for several reasons. First, quantitative techniques require stop-frame analysis of the videotaped echocardiograms, which results in loss of 50% of the image. Second, manual tracing of the endocardial and epicar-

dial contours is required, thus adding a subjective component to the "quantitative" methods. This is particularly troublesome if endocardial dropout is present over a portion of the image. Finally, quantitative techniques that analyze only end-diastolic and end-systolic frames lack the temporal resolution to examine early systolic thickening and therefore may be more subject to the effects of cardiac translation and/or tethering. Because of these considerations, we used the semiquantitative method of assessing regional wall thickening that has been recommended by the American Society of Echocardiography.²⁶ Given the reproducibility of this method⁴³ and the fact that the images were interpreted in blinded fashion, it is unlikely that the results would have been enhanced by application of quantitative methods.

Conclusions

Dobutamine stress echocardiography is a simple, cost-effective, and widely available method of identifying hibernating myocardium and predicting recovery of left ventricular function after coronary revascularization. This technique promises to be clinically valuable in the selection of patients for coronary revascularization.

Acknowledgments

The authors gratefully acknowledge Arvella Peters and Mannil Abraham for performing the echocardiograms and Drs. L. David Hillis, Eric J. Eichhorn, and Carlos E. Velasco for their thoughtful review of the manuscript.

References

- Rahimtoola SH. A perspective on the three large multicenter randomized clinical trials of coronary bypass surgery for chronic stable angina. *Circulation*. 1985;72(suppl V):V-123-V-135.
- Rees G, Bristow JD, Kremkau KLE, Green GS, Herr RH, Griswald HE, Starr A. Influence of aortocoronary bypass on left ventricular performance. *N Engl J Med*. 1971;284:1116-1120.
- Chatterjee K, Swan HJC, Parmley WW, Sustaita H, Marcus H, Matloff J. Depression of left ventricular function due to acute myocardial ischemia and its reversal after aortocoronary saphenous vein bypass. *N Engl J Med*. 1972;286:1117-1122.
- Bourassa M, Lesperance J, Campeau L, Saliel J. Fate of left ventricular contraction following aortocoronary venous grafts: early and late post-operative modifications. *Circulation*. 1972;46:724-730.
- Brundage BH, Massie BM, Botvinick EH. Improved regional ventricular function after successful surgical revascularization. *J Am Coll Cardiol*. 1984;3:902-908.
- Rankin JS, Newman GE, Muhlbaier LH, Behar VS, Fedor JM, Sabiston DC Jr. The effects of coronary revascularization on left ventricular function in ischemic heart disease. *J Thorac Cardiovasc Surg*. 1985;90:818-832.
- Topol EJ, Weiss JL, Guzman PA, Dorsey-Lima S, Blanck JJ, Humphrey LS, Baumgartner WA, Flaherty JT, Reitz BA. Immediate improvement of dysfunctional myocardial segments after coronary revascularization: detection by intraoperative transesophageal echocardiography. *J Am Coll Cardiol*. 1984;4:1123-1134.
- van den Berg EK Jr, Popma JJ, Dehmer GJ, Snow FR, Lewis SA, Vetrovec GW, Nixon JV. Reversible segmental left ventricular dysfunction after coronary angioplasty. *Circulation*. 1990;81:1210-1216.
- Akins CW, Pohost GM, DeSanctis RW, Block PC. Selection of angina-free patients with severe left ventricular dysfunction for myocardial revascularization. *Am J Cardiol*. 1980;46:695-700.
- Shanes JG, Kondos GT, Levitsky S, Pavel D, Subramanian R, Brundage BH. Coronary artery obstruction: a potentially reversible cause of dilated cardiomyopathy. *Am Heart J*. 1985;110:173-178.
- Pigott JD, Kouchoukos NT, Oberman A, Cutter GR. Late results of surgical and medical therapy for patients with coronary artery disease and depressed left ventricular function. *J Am Coll Cardiol*. 1985;5:1036-1045.
- Nesto RW, Cohn LH, Collins JJ, Wynne J, Holman L, Cohn PF. Inotropic contractile reserve: a useful predictor of increased 5-year survival and improved postoperative left ventricular function in patients with coronary artery disease and reduced ejection fraction. *Am J Cardiol*. 1982;50:39-44.
- Cohn LH, Collins JJ, Cohn PF. Use of the augmented ejection fraction to select patients with left ventricular dysfunction for coronary revascularization. *J Thorac Cardiovasc Surg*. 1976;72:835-839.
- Rutherford JD, Braunwald E. Chronic ischemic heart disease. In: Braunwald E, ed. *Heart Disease: A Textbook of Cardiovascular Medicine*. Philadelphia, Pa: WB Saunders; 1992:1329-1334.
- Braunwald E, Rutherford JD. Reversible ischemic left ventricular dysfunction: evidence for the "hibernating myocardium." *J Am Coll Cardiol*. 1986;8:1467-1470.
- Kloner RA, Przyklenk K, Patel B. Altered myocardial states: the stunned and hibernating myocardium. *Am J Med*. 1989;86(suppl 1A): 14-22.
- Rahimtoola SH. The hibernating myocardium. *Am Heart J*. 1989;117:211-221.
- Schelbert HR. Positron emission tomography for the assessment of myocardial viability. *Circulation*. 1991;84(suppl I):I-122-I-131.
- Marshall RC, Tillisch JH, Phelps ME, Huang SC, Carson R, Henze E, Schelbert HR. Identification and differentiation of resting myocardial ischemia and infarct in man with positron computed tomography, ¹⁸F-labeled fluorodeoxyglucose and N-13 ammonia. *Circulation*. 1983;67:766-778.
- Dilsizian V, Rocco TP, Freedman NMT, Leon MB, Bonow RO. Enhanced detection of ischemic but viable myocardium by the reinjection of thallium after stress-redistribution imaging. *N Engl J Med*. 1990;323:141-146.
- Tillisch J, Brunken R, Marshall R, Schwaiger M, Mandelkern M, Phelps M, Schelbert HR. Reversibility of cardiac wall-motion abnormalities predicted by positron tomography. *N Engl J Med*. 1986;314:884-888.
- Dilsizian V, Smeltzer WR, Freedman NMT, Dextras R, Bonow RO. Thallium reinjection after stress-redistribution imaging: does 24-hour delayed imaging after reinjection enhance detection of viable myocardium? *Circulation*. 1991;83:1247-1255.
- Bonow RO, Dilsizian V, Cuocolo A, Bacharach SL. Myocardial viability in patients with chronic coronary artery disease and left ventricular dysfunction: Thallium-201 reinjection versus ¹⁸F-fluorodeoxyglucose. *Circulation*. 1991;83:26-37.
- Schulz R, Guth BD, Pieper K, Martin C, Heusch G. Recruitment of an inotropic reserve in moderately ischemic myocardium at the expense of metabolic recovery: a model of short-term hibernation. *Circ Res*. 1992;70:1282-1295.
- Feigenbaum H. Digital recording, display, and storage of echocardiograms. *J Am Soc Echocardiogr*. 1988;1:378-383.
- Schiller NB, Shah PM, Crawford M, DeMaria A, Devereaux R, Feigenbaum H, Gutgesell H, Reichek N, Sahn D, Schnittger I, Silverman NH, Tajik AJ. Recommendations for quantitation of the left ventricle by two-dimensional echocardiography. *J Am Soc Echocardiogr*. 1989;2:358-367.
- Sawada SG, Segar DS, Ryan T, Brown SE, Dohan AM, Williams R, Fineberg NS, Armstrong WF, Feigenbaum H. Echocardiographic detection of coronary artery disease during dobutamine infusion. *Circulation*. 1991;83:1605-1614.
- Armstrong WF. Stress echocardiography for detection of coronary artery disease. *Circulation*. 1991;84(suppl I):I-43-I-49.
- Martin TW, Seaworth JF, Johns JP, Pupa LE, Condos WR. Comparison of adenosine, dipyridamole, and dobutamine in stress echocardiography. *Ann Intern Med*. 1992;116:190-196.
- Marcovitz PA, Armstrong WF. Dobutamine stress echocardiography: diagnostic utility. *Herz*. 1991;16:372-378.
- Cohen JL, Revor OG, Ottenweller J, Binenbaum SZ, Wilchfort SD, Kim CS. Dobutamine digital echocardiography for detecting coronary artery disease. *Am J Cardiol*. 1991;67:1311-1318.
- Fung AY, Gallagher KP, Buda AJ. The physiologic basis of dobutamine as compared with dipyridamole stress interventions in the assessment of critical coronary stenosis. *Circulation*. 1987;76:943-949.
- Barilla F, Gheorghide KP, Alam M, Khaja F, Goldstein S. Low dose dobutamine in patients with acute myocardial infarction identifies viable but not contractile myocardium and predicts the magnitude of improvement in wall motion abnormalities in response to coronary revascularization. *Am Heart J*. 1991;122:1522-1531.
- Pierard LA, de Landsheere CM, Berthe C, Rigo P, Kulbertus HE. Identification of viable myocardium by echocardiography during dobutamine infusion in patients with myocardial infarction after

- thrombolytic therapy: comparison with positron emission tomography. *J Am Coll Cardiol.* 1990;15:1021-1031.
35. Popio KA, Gorlin R, Bechtel D, Levine JA. Postextrasystolic potentiation as a predictor of potential myocardial viability: preoperative analyses compared with studies after coronary bypass surgery. *Am J Cardiol.* 1977;39:944-951.
 36. Helfant RH, Pine R, Meister SG, Feldman MS, Trout RG, Banka VS. Nitroglycerin to unmask reversible asynergy: correlation with post coronary bypass ventriculography. *Circulation.* 1974;50:108-113.
 37. Horn HR, Teicholz LE, Cohn PF, Herman MV, Gorlin R. Augmentation of left ventricular contraction pattern in coronary artery disease by an inotropic catecholamine: the epinephrine ventriculogram. *Circulation.* 1974;49:1063-1071.
 38. Alderman EL, Fisher LD, Litwin P, Kaiser GC, Myers WO, Maynard C, Levine F, Schloss M. Results of coronary artery surgery in patients with poor left ventricular function (CASS). *Circulation.* 1983;68:785-795.
 39. Gould KL. Myocardial viability: what does it mean and how do we measure it? *Circulation.* 1987;10:743-747.
 40. Bodenheimer MM, Banka VS, Hermann GA, Trout RG, Pasdar H, Helfant R: Reversible asynergy: histopathologic and electrocardiographic correlations in patients with coronary artery disease. *Circulation.* 1976;53:792-796.
 41. Cabin HS, Clubb KS, Vita N, Zaret BL. Regional dysfunction by equilibrium radionuclide angiocardiology: a clinicopathologic study evaluating the relation of degree of dysfunction to the presence and extent of myocardial infarction. *J Am Coll Cardiol.* 1987; 10:743-774.
 42. Feigenbaum H. Exercise echocardiography. *J Am Soc Echocardiogr.* 1988;1:161-166.
 43. Oberman A, Fan PH, Nanda NC, Lee JY, Huster WJ, Sulentic JA, Storey OF. Reproducibility of two-dimensional exercise echocardiography. *J Am Coll Cardiol.* 1989;14:923-928.