

The Birth, Early Years, and Future of Interventional Radiology

Josef Rösch, MD, Frederick S. Keller, MD, and John A. Kaufman, MD

J Vasc Interv Radiol 2003; 14:841–853

Abbreviations: AGIB = acute gastrointestinal bleeding, PTA = percutaneous transluminal angioplasty, SFA = superficial femoral artery, SIR = Society of Interventional Radiology, SK = streptokinase, TIPS = transjugular intrahepatic portosystemic shunt

THE Society of Interventional Radiology (SIR) celebrates its 30th anniversary this year. During these 30 years, SIR has grown from a closed club with fewer than 100 members to an open society with 4,000 members. The history of the Society and its exciting growth is detailed on the SIR web site, www.sirweb.org. This issue of *JVIR* also contains commemorative articles of some founding members on the formative years of SIR, its transition to an open society, perspectives for its future, and the history of nonvascular interventions. However, only a few SIR members remember the birth and early years of interventional radiology. It is our intention to bring these days back to you by recounting how interventional radiology was born and how it grew, particularly in the area of vascular interventions.

This article is a remembrance, a collection of the highlights of our memories of events that happened 25–40 years ago, documented by historic pictures. Fortunately, the human memory has the most generous and merciful nature; it encrypts in the mind exciting and memorable events while repressing unemotional or disturbing occasions or at least permitting us to look at them differently. Many of the mo-

mentous events associated with the birth and early years of interventional radiology are still as fresh in our memory as if they occurred yesterday. But, because the human memory is also quite subjective, our memories could be somewhat biased as we take you back into the exciting early years of interventional radiology.

THE BIRTH OF INTERVENTIONAL RADIOLOGY

Interventional radiology developed from diagnostic angiography and from the innovative minds and technical skills of many angiographers. Charles Dotter (Fig 1) (1) conceived interventional radiology in the early 1960s and first officially spoke about it on June 19, 1963, at the Czechoslovak Radiological Congress in Karlovy Vary. In his more than 1 hour presentation, “Cardiac catheterization and angiographic techniques of the future,” he discussed, among other topics, catheter biopsy, controlled exit catheterization, occlusion catheterization for various purposes, and the rationale of catheter endarterectomy (2). After his conclusion stating that “[t]he angiographic catheter can be more than a tool for passive means for diagnostic observation; used with imagination, it can become an important surgical instrument,” Charles received a standing ovation from more than 300 attendees, including many prominent European angiographers. For those of us in the audience, it was like a bomb had been dropped. At that time, all

angiographers had only one thing in mind, to deliver an exact diagnosis to our referring clinical colleagues, interventionalists and surgeons, thereby allowing them to select proper treatment. Until then, none of us had even thought that we might be able to treat patients ourselves percutaneously with use of catheters and guide wires. Also, none of us present at the congress realized or even dreamed that Dotter’s words would soon become reality.

Interventional radiology was born January 16, 1964, when Dotter percutaneously dilated a tight, localized stenosis of the superficial femoral artery (SFA) in an 82-year-old woman with painful leg ischemia and gangrene who refused leg amputation. After successful dilation of the stenosis with a guide wire and coaxial Teflon catheters, the circulation returned to her leg (Fig 2) (3). Charles told us that his skeptical surgical colleagues kept the patient in the hospital under observation for several weeks expecting the dilated artery to thrombose. Instead, her pain ceased, she started walking, and three irreversibly gangrenous toes spontaneously sloughed. She left the hospital on her feet—both of them. The dilated artery stayed open until her death from pneumonia 2.5 years later.

Encouraged by this success, Dotter not only continued to dilate SFA stenoses, but also began treatment of SFA occlusions. In his first paper on this subject published in the November 1964 issue of *Circulation* (3), Dotter—with Melvin Judkins, developer of transfemoral coronary catheterization

From the Dotter Interventional Institute, Oregon Health and Science University, 3181 SW Sam Jackson Park Road, L342, Portland, Oregon 97239. Address correspondence to J.R.; E-mail: roschj@ohsu.edu

© SIR, 2003

DOI: 10.1097/01.RVI.0000083840.97061.5b





Figure 1. Charles Dotter and his trademark (trademark drawing reprinted with permission from reference 1).

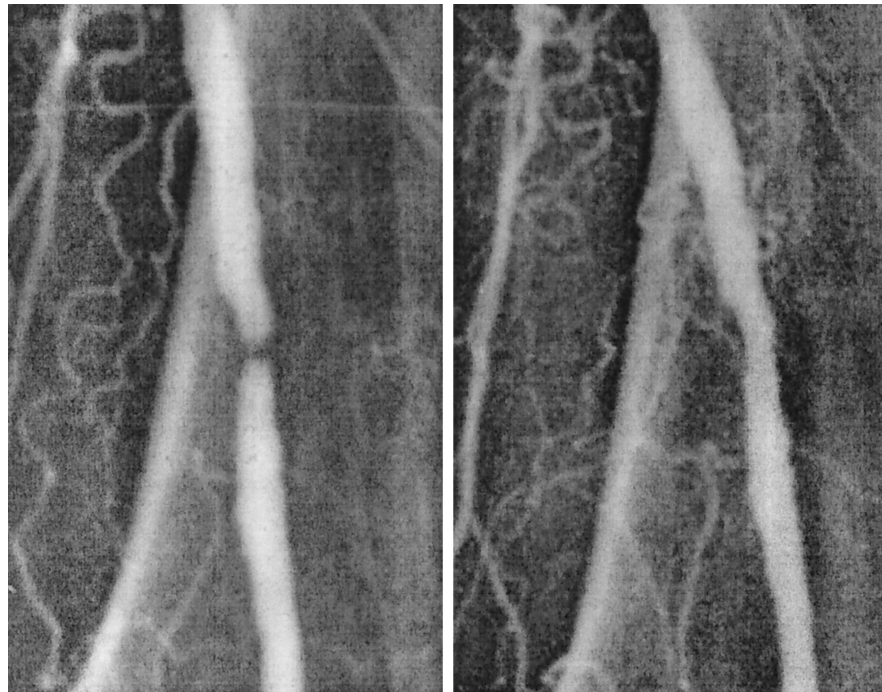


Figure 2. The first percutaneous transluminal angioplasty, performed January 16, 1964 (reprinted with permission from reference 3).

technique (**Fig 3**)—summarized their 5-month experience with angioplasty. They reported treatment of 11 extremities in nine patients, including four

with short SFA occlusions and four with long SFA occlusions. The treatment of occlusions was not always successful, but four of seven amputa-

tions were averted in these patients. In the description of the technique, Dotter recommended “passing guide wires through the lesions more by the application of judgment than of force, even when both are often needed for subsequent dilation.” Force was indeed often necessary when passing the 15-F outer diameter dilation catheter over the first 9-F catheter. Dotter’s experience rapidly grew, and in May 1966, he reported treatment of 82 lesions in 74 patients, including six iliac artery stenoses. This report also mentioned the first use of braided mesh reinforced latex balloon dilation catheters (3A).

Dotter refined his technique and decreased the size of coaxial dilation catheters to 8 F and 12 F and improved the taper of their tips. In 1968, 4 years after his first case, he reported on 217 dilations of 153 lesions in 127 patients (4). Dotter considered himself a “body plumber” and, to avoid reference to his technique as “reaming out,” he drew and published a picture of his concept of the basic mechanism of transluminal dilation in which nothing is removed except for the obstruction. Dotter, for a long time, called his technique “percutaneous transfemoral catheter dilatation,” but later changed it to the presently known “percutaneous transluminal angioplasty” (PTA).

The term “interventional radiology” was coined by Alexander Margulis in his editorial in the March 1967 issue of the *American Journal of Roentgenology* (5). In the mid 1960s, occasional reports were published on treatment with radiologic techniques other than PTA or on new manipulative diagnostic radiologic procedures. These included treatment of rigid shoulders by joint distention during arthrography, abscess drainages, intrauterine transfusion of the fetus under fluoroscopic guidance, removal of plugs from a T-tube by fluoroscopically controlled catheter manipulation, pulmonary and liver biopsy, catheter placements for intraarterial chemotherapy, and transjugular cholangiography. Margulis, a gastrointestinal radiologist and educator, realized that a new trend and new specialty was developing in radiology. In his editorial, he not only defined interventional radiology, but also set requirements for its performance that are still valid today. He defined interventional radiology as




Figure 3.
Melvin Judkins
with his coronary
catheters.

manipulative procedures controlled and followed under fluoroscopic guidance that may be predominantly therapeutic or primarily diagnostic. Margulis emphasized the need for special training, technical skills, clinical knowledge, ability to care for patients before, during, and after the procedure, and close cooperation with surgeons and internists as requirements for performance of interventional radiologic procedures. He also raised questions of obligatory training of interventional radiologists in surgical techniques. High-quality radiologic imaging equipment was another of his basic requirements for performance of interventional radiologic procedures (6).

Dotter was not enthusiastic about the term "interventional," calling it imperfect. His main reservation about the term "interventional" was its lack of definition of our work. He believed that this term leads to confusion about what we do among the lay public and many physicians. Dotter himself defined interventional radiology as a variety of percutaneous image-guided alternatives or aids to surgery. However, he realized that generalized use of the term "interventional radiology" allowed definition of a new subspecialty in radiology and separated it

from general radiology and its other subspecialties.

THE EARLY YEARS OF INTERVENTIONAL RADIOLOGY

The most exciting years of our professional lives were from the late 1960s to the mid 1980s. Dotter's papers, his lectures, and, later, daily work with him were constant inspirations to us that changed our orientation from diagnostic angiographers to interventionalists. We can still hear his voice telling us that, whenever examining the patient, we must not only concentrate on improving diagnoses, but we must also always think about potential ways to percutaneously treat whatever we find. We and many other interventional pioneers worked hard at it. In the earlier years, new techniques were often introduced as treatments in patients without experimental testing, particularly when no other options were available. Emergencies found us prepared to innovate. In our department, introduction of PTA and arterial embolization of upper gastrointestinal bleeding were introduced in this manner. Applications of our experience and techniques in one organ system to a completely new organ system or

structure led to new indications for interventional procedures. Examples include our introduction of selective arterial thrombolysis and fallopian tube recanalization. More recent devices and techniques such as stents, stent-grafts, transjugular intrahepatic portosystemic shunt (TIPS) creation, and direct intrahepatic portal systemic shunt creation underwent detailed experimental testing in animals and were introduced for clinical use with approval of the institutional review board.

Departments in other institutions were developing devices and techniques in a similar fashion. Interventional treatment that started with opening vascular obstructions expanded to creating therapeutic vascular occlusions and shunts and treating tumors. Its application also expanded from the vascular system to the pulmonary, biliary, gastrointestinal, genitourinary, and central nervous systems. There were many pioneers who introduced new methods of interventional treatment. We will highlight some of them and concentrate mainly on interventional treatment related to the vascular system, particularly PTA, local thrombolysis, stent development, treatment of acute gastrointestinal bleeding, and TIPS creation.

EARLY HIGHLIGHTS IN PERCUTANEOUS TRANSLUMINAL ANGIOPLASTY

After a few successful procedures, Dotter started an aggressive campaign to recruit patients and gain recognition for PTA. His referrals were mainly from general practitioners and occasionally from internists. Surgeons were not interested in nonsurgical treatment of atheromatous disease and were adamantly opposed to PTA. Dotter's articles in local newspapers and his radio and TV interviews were effective in attracting patients interested in this new procedure. These patients were admitted to the hospital on the radiology service under Dotter's name and radiology residents or fellows, with varying degrees of enthusiasm, worked them up and prepared for the procedure.

Patient recruitment was greatly enhanced on a national level with a *Life* magazine article on PTA and Dotter.




Figure 4. From left to right, Eberhardt Zeitler, Andreas Grüntzig, and Charles Dotter in 1975 discussing angioplasty techniques at the symposium in Cologne, Germany.

Reporters visiting Oregon Health and Science University to write about the Starr-Edward cardiac valve were told about a new procedure, PTA. They insisted on catching Dotter in action. Charles' emotions and reactions to various stages of the procedure were successfully captured in pictures. The article, when published, resulted in tremendous exposure for Charles and PTA and also earned him the nickname of "Crazy Charlie." This national publicity attracted a wealthy VIP patient, the wife of the owner of a large international company in New York City. Dotter flew to New York with his team and successfully treated this patient's SFA stenosis. Afterwards, the thankful patient donated \$500,000 to the Oregon Health and Science University radiology department. Dotter used this grant to purchase up-to-date angiographic equipment that allowed him to perform PTA and other angiographic procedures very efficiently. The remaining funds Dotter used for publicity for PTA, lectures abroad, and to support a 1-year research fellowship in Portland for Josef Rösch, whom he had met at the 1963 Czechoslovak Radiological Congress.

However, general recognition of PTA progressed slowly. In particular, acceptance in the United States stalled

for a long time. Even though Dotter published 17 papers on PTA in the first 4 years—seven in radiology journals, four in surgery journals, one in a cardiology journal, and five in general journals—PTA procedures in the United States were performed almost exclusively in Portland. Angiographers at other US institutions did not share Dotter's idea of "catheter therapy." They continued to concentrate only on diagnosis. However, European angiographers were more progressive at that time and demonstrated a desire to change and expand their work. Werner Porstmann, a good friend of Dotter from Berlin, started performing PTA in the mid 1960s and published his first experience in 1967 (6). Van AnDEL from The Netherlands modified the dilation catheters. However, the greatest credit for disseminating PTA throughout Europe belongs to Eberhardt Zeitler from Germany (Fig 4). Thanks to his work, many European angiographers accepted PTA and began "Dottering" diseased arteries (7,8).

The Europeans also made critical steps in PTA development by introduction of clinically applicable balloon catheters. The first "caged" or "corset" balloon catheter described by Portsmann in 1973 consisted of a latex bal-

loon inside a Teflon catheter with longitudinal slits (9). This device did not find wide application. However, a balloon catheter made of polyvinyl chloride introduced by German cardiologist Andreas Grüntzig in 1974 revolutionized PTA (Fig 4) (10). Realizing the potential of these balloons, medical device manufacturers rapidly placed them into production and balloon PTA took off. Favorable experience with Grüntzig balloon catheters in femoropopliteal and iliac arteries opened the way for balloon PTA of other vessels. Grüntzig performed the first successful balloon dilations of coronary arteries in 1976 (11).

Success of PTA in Europe ignited the interest of the new generation of angiographers in the United States. Some went to Europe to see Grüntzig at work at live case demonstrations he organized, and some even stayed with him for fellowships. Upon returning, they brought the improved PTA procedure back to the United States, where it originated approximately 15 years before. Enthusiastic work of these pioneers, including Barry Katzen, David Kumpe, Amir Motarjeme, Ernie Ring, Don Schwarten, Tom Sos, Charles Tegtmeier, and others, helped with the rapid dissemination of balloon PTA in the United States, where it soon became the most commonly performed interventional procedure (Fig 5).

LOCAL THROMBOLYSIS

Dotter introduced catheter-directed thrombolysis in 1972 at the annual meeting of the Radiological Society of North America in Chicago. The origins of the procedure were the treatment of complications of angiography and PTA. Thrombotic occlusions occasionally occurred at the catheter entrance or dilation sites because of the large size of diagnostic coronary catheters (8 F) and coaxial dilation catheters (12 F). Dotter wanted to treat these complications with interventional techniques rather than have the patient undergo surgery. In our department, we were familiar with thrombolysis because of randomized studies comparing systemic application of streptokinase (SK) and heparin for treatment of pulmonary embolism and acute deep venous thrombosis. We were working closely with Arthur Sea-



Figure 5. The pioneers of balloon PTA in the United States. From left to right, upper row: Barry Katzen, David Kumpe, Amir Motarjeme, Ernie Ring. Lower row: Donald Schwarten, Thomas Sos, Charles Tegtmeier.




Figure 7. Dotter's early followers in local thrombolysis. From left to right, upper row: Barry Katzen, Arina Van Breda. Lower row: Gary Becker, Thomas McNamara.

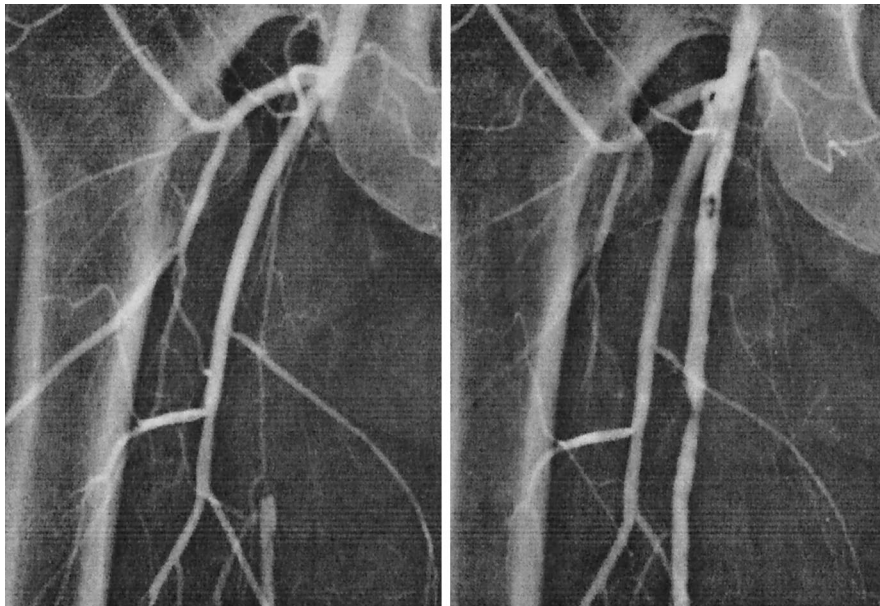


Figure 6. One of the first cases of local thrombolysis performed in June 1972 (reprinted with permission from reference 12).

man, an experienced hematologist in this area. In addition, we had extensive experience with local arterial infusion therapy, mainly with vasopressin infusions for control of arterial and variceal gastrointestinal bleeding and chemotherapy infusions for treatment of tumors.

It was a natural beginning. As soon

as the complication was recognized, an end-hole catheter was placed just above a short thrombus or a multiple-side hole catheter was thrust into a long thrombus in the angiography room. Continuous SK infusion was then performed in the intensive care unit. The dose of SK most often used was 5,000 U/h infused into the iliac or

femoral arteries, approximately 5% of the usual systemic dose. Portable angiograms at 12- or 24-hour intervals were used to monitor the progress of fibrinolysis. In the first six patients with acute thrombosis, 18–112-hour infusions (mean, 47 hours) were needed for complete clot lysis (**Fig 6**) (12). Encouraged by good results with acute thromboses, Dotter explored local SK infusions in chronic arterial occlusions, but found only minimal benefit for this indication. Therefore, we continued local thrombolysis for our occasional complications. Sometimes we used thrombolysis before PTA when there was clinical suspicion of acute or subacute thrombosis superimposed on chronic arterial obstruction.

Our publication on this technique in April 1974 did not generate enthusiasm for local thrombolysis among interventionalists. The need for hospitalization in the intensive care unit, the antigenic nature of SK, and some bleeding complications were probably the main factors for the limited acceptance of this technique. Barry Katzen and Arina Van Breda were the first followers in the United States and, in 1981, they published their experience and found local SK infusion beneficial

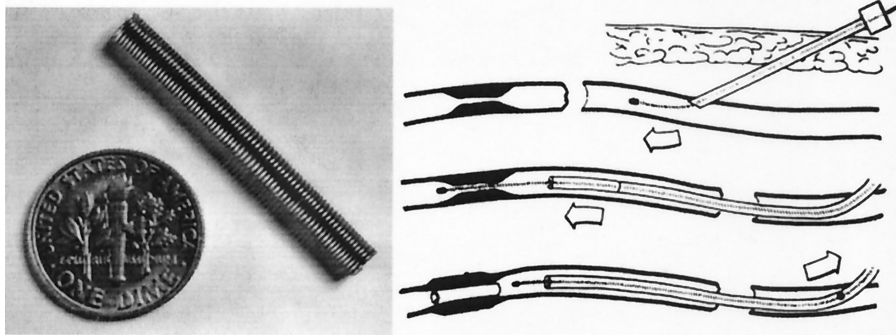


Figure 8. Coil spring endarterial tube graft and its percutaneous placement introduced by Charles Dotter in 1969 (reprinted with permission from reference 16).

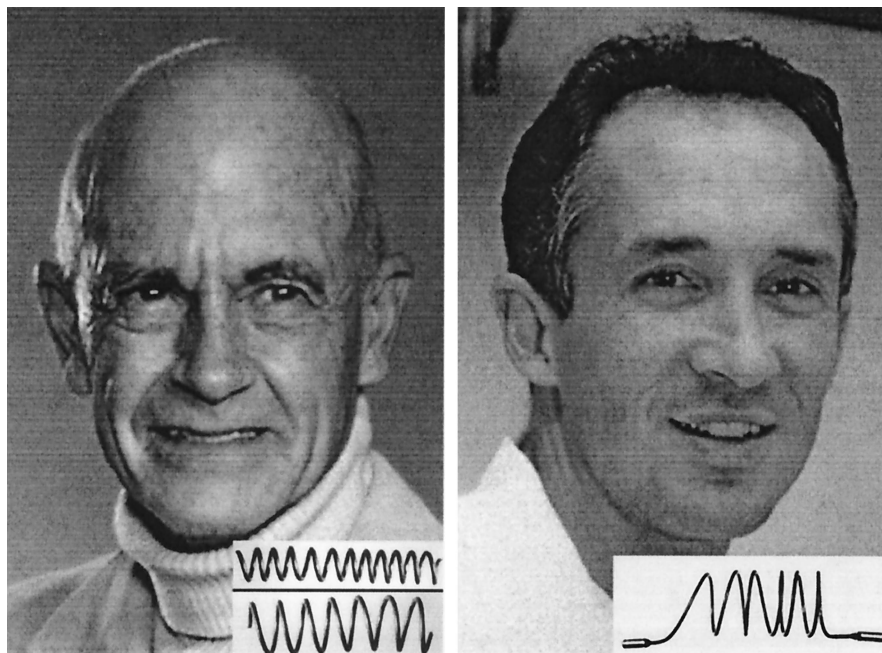


Figure 9. Charles Dotter (left) and Andrew Cragg (right) and their nitinol stents (stents reprinted with permission from references 19 and 20).

in acute thromboses and before balloon PTA (Fig 7) (13). Gary Becker and colleagues confirmed their results in a larger number of patients (14). However, local thrombolysis did not become widely accepted until SK was replaced by urokinase, a safer fibrinolytic agent that is relatively nonantigenic, with better probability of predicting therapeutic dose responses. Tom McNamara published the first large series of patients treated with local urokinase infusions and his dedicated efforts helped to spread local urokinase fibrinolysis into interventional practice (Fig 7) (15).

EXPANDABLE STENTS

Dotter started the era of intravascular stent placement in 1969 with the introduction of a transluminally placed *coil spring endarterial tube graft* (Fig 8) (16). Frustrated with the frequently occurring occlusions of a recanalized SFA, he tried to find a percutaneous method to keep the artery open. Of several different types of percutaneously introduced tubings, only the uncoated coil spring tubular prostheses stayed open in canine SFAs. Two of three 1-cm-long coil springs remained patent on follow-up angio-

grams more than 2 years after placement. The coil springs Dotter used were not expandable, but he suggested a mechanism for their expansion. "Coil springs, either stretched out or wound up and hooked to a controlling mandrel, can be reduced in diameter favoring their easy introduction and placement. Upon their externally effected release from the mandrel, they automatically expand to a bigger lumen and better anchoring at the site of placement." Only later did Dotter call these endarterial prostheses stents.

It took more than 10 years before Dotter's idea of endovascular stent placement became established in interventionalists' minds. But, when there, rapid progress followed. Several types of new expandable stents were introduced and tested in animals and most of them were eventually used in clinical practice. Early on, they were mostly handmade and used with local institutional review board approval. Later on, when companies obtained approval for their use in the biliary system, they were placed intravascularly on an off-label basis. More than 30 years after Dotter's original experiments, only a small number of stents have been approved by the Food and Drug Administration for intravascular use.

The Swiss surgeon Dierk Maass headed a line of creative inventors, mainly interventional radiologists including Dotter, Andrew Cragg, Cesare Gianturco, and Julio Palmaz, who, in the early and mid 1980s, introduced a variety of expandable metallic stents. These were either self- or balloon-expandable stents made primarily of stainless-steel alloys or thermal memory stents made of nitinol, an alloy of nickel and titanium. *Maass self-expandable spiral coils* and double-helix stents, introduced in 1982, were studied in animals and later used in clinical practice, mainly for relieving inferior vena cava obstructions and, occasionally, in aortic dissections (17,18). These devices never gained widespread acceptance mainly because their large introducing sheaths required arterial cutdown.

Nitinol stents were introduced in 1983 when Dotter and colleagues (19) and Cragg and colleagues (20) simultaneously published results of their experimental studies (Fig 9). With




Figure 10. Cesare Gianturco (left) and Hans Wallsten (right) and their self-expandable stents (Wallstent reprinted with permission from reference 28).

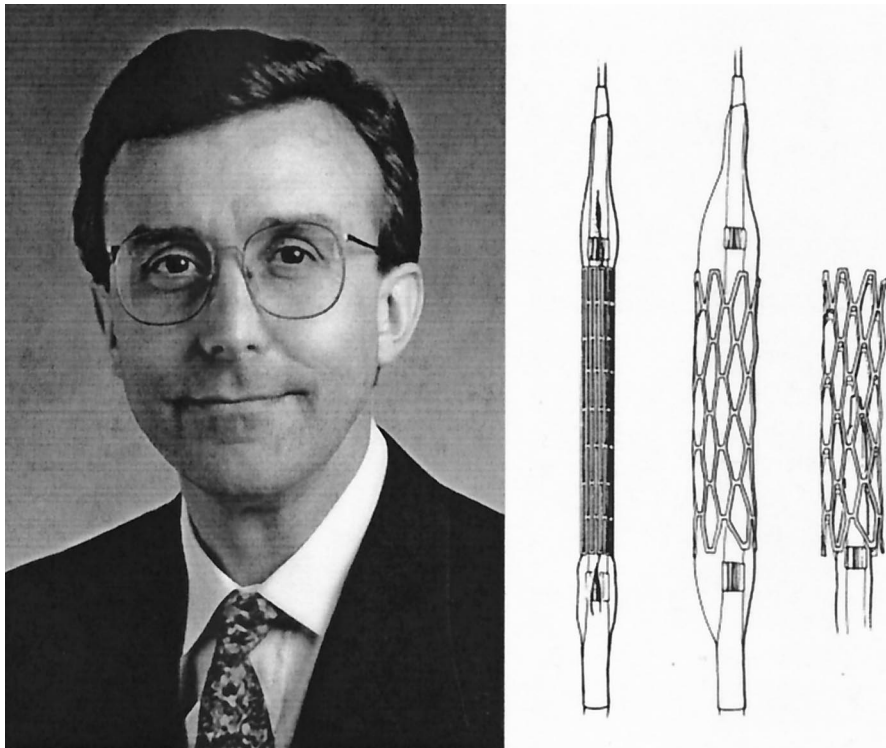


Figure 11. Julio Palmaz and his balloon-expandable stent (stent reprinted with permission from reference 26).

Dotter’s nitinol spiral stent, saline solution heated to 60°C was needed for rapid radial stent expansion after its

placement. Cragg’s body temperature-activated nitinol coil graft for expansion required flushing with cool

saline solution during introduction. These complex introduction systems, together with significant intimal proliferation of the stent-implanted canine iliac and femoral arteries, were drawbacks to the use of nitinol stents in the United States in the 1980s and early 1990s. In Russia, Josef Rabkin introduced a widely spaced nitinol spiral stent that was easy to introduce and that expanded at body temperature. After experimental animal testing, he used it in clinical practice beginning in 1985. In the early 1990s, he reported successful results in treatment of obstructions in vascular and nonvascular systems in 268 patients (21).

Three stents were introduced in 1985: the Gianturco Z stent, Palmaz stent, and Wallstent. *The self-expandable Gianturco Z stent (Fig 10)*, made from stainless-steel wire bent into a zigzag pattern with connected ends, had a strong expansile force (22). To prevent overexpansion of the stent-implanted structures and to maintain the desired diameter, we modified the original Z stent by suturing its bent “eyes” with monofilament (23). This also allowed us to form multisegmental stents and facilitate their placement. It was easy to make both the original and modified Z stents by hand. Many interventionalists in the United States and abroad made them at home before they became available from manufacturers. We often used modified Z stents for relief of obstructions of large veins, particularly the superior and inferior venae cavae (24). One of our patients with occlusion of the inferior vena cava and common iliac veins and enormous edema treated with stent placement in 1990 is still alive without edema recurrence. The simple zigzag pattern of the Z stent has been incorporated into frames of several types of aortic stent-grafts.

Palmaz made his original balloon-expandable stent under a low-power microscope by weaving stainless-steel wire into a crisscrossed tubular pattern and then electropolishing it. The crossover points were soldered to keep the stent expanded after balloon inflation (25). Soon, however, the process was modified for easier fabrication and his final stent design became a single stainless-steel tube with parallel staggered slots in the wall (Fig 11) (26). We had the opportunity to use homemade Palmaz stents for our ex-




Figure 12. Stanley Baum (left) and Moreye Nusbaum (right) in the mid 1960s reviewing an angiographic procedure.

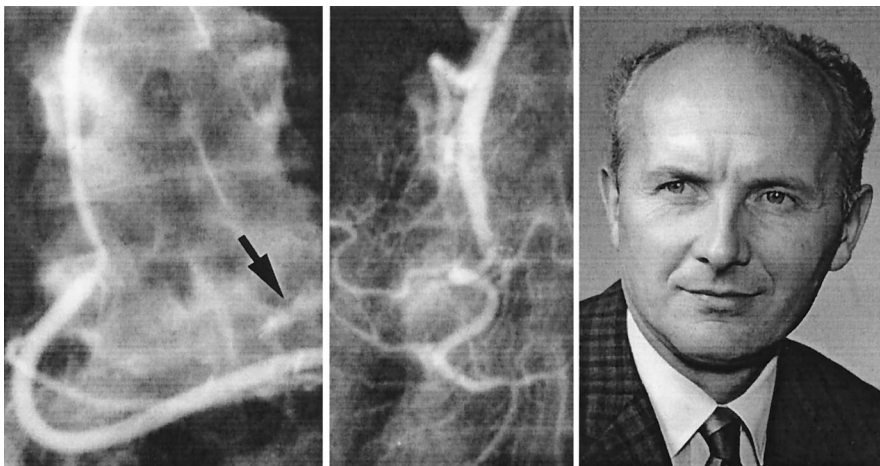


Figure 13. First case of selective arterial embolization of arterial treatment performed by Josef Rösch in November 1970. Selective angiograms before embolization and after embolization (angiograms reprinted with permission from reference 33).

perimental TIPS research in pigs, and they worked very well. Palmaz did excellent research work with his stents and their use in the arterial system including peripheral, renal, and coronary arteries, and in TIPS. His stent was the first and, for a long time, the only stent approved by the Food and Drug Administration for vascular use. Palmaz also studied biomechanical and hemodynamic effects of stents in various arteries and contributed significantly to our understanding of arterial stent placement.

The self-expanding spring-loaded meshwork stent known now as the *Wallstent* was developed by engineer Hans Wallsten at his Swiss company, Medinvent (Fig 10). With use of the technique known from other applications such as making braids in catheters or coaxial cable shielding, Wallsten spun 16–20 alloy spring filaments into a tubular, flexible, self-expanding braid configuration. The stent was then constrained on a small-diameter catheter by a rolling membrane for easy vascular introduction. For stent

placement, the membrane was withdrawn, freeing it and allowing stent expansion. After Schneider Europe started manufacturing the *Wallstent* with a simplified unsheathing delivery system and markers, the *Wallstent* became very popular in Europe and was used not only in vascular systems, including coronary arteries and TIPS, but also in nonvascular applications (27,28). Good results in Europe with the *Wallstent* brought it to the United States. Thanks to several clinical investigators including the interventional team at the University of California, San Francisco, *Wallstents* were soon approved for biliary use and later for other applications.

ACUTE GASTROINTESTINAL BLEEDING

Angiographic diagnosis and treatment of acute gastrointestinal bleeding (AGIB) was pioneered by Stanley Baum and Moreye Nusbaum in the 1960s. First, they showed in 1963 that selective visceral cut-film arteriography was capable of demonstrating extravasation at rates as low as 0.5 mL/sec (29). Then, in 1967, after they found in animal experiments that vasoconstrictive infusion of the superior mesenteric artery could reduce portal hypertension (30), they started to use continuous low-dose vasopressin infusion in clinical practice for control of variceal bleeding (Fig 12) (31). Since that time, diagnosis and treatment of AGIB has become an important part of an interventionalist's work. In the 1960s and early 1970s, when emergency endoscopy had not been widely adopted, selective and superselective visceral arteriography was the primary procedure in the diagnosis of AGIB. The role of interventionalists further increased when they became involved with AGIB treatment. We still remember the many night, weekend, and holiday emergency calls and seeming AGIB epidemics during Christmas and New Year's time. Nevertheless, it gave us great satisfaction when we were able to pinpoint the source of bleeding and stop the hemorrhage.

In 1968, we started with short *selective infusions* of epinephrine into the bleeding artery preceded by low-dose propranolol injection to block its β -adrenergic effect in the treatment of ar-

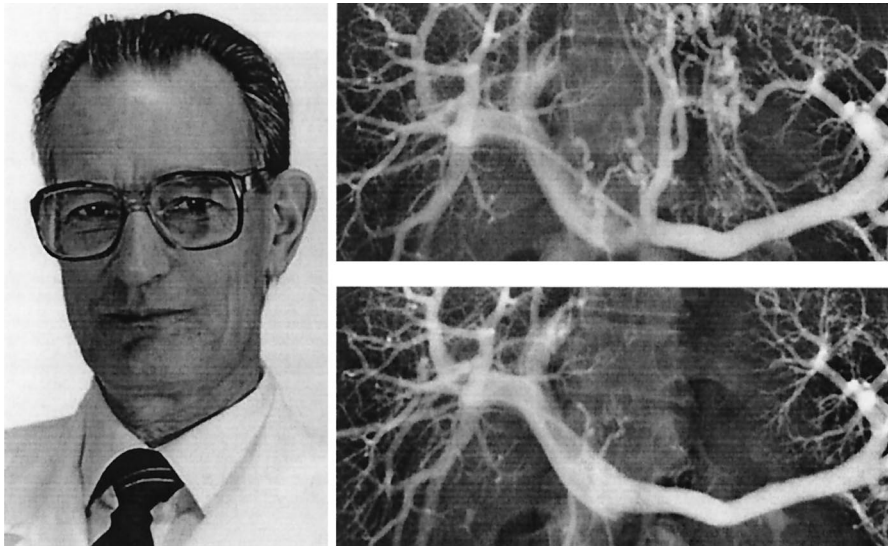


Figure 14. Anders Lunderquist and his transhepatic variceal embolization introduced in 1974. Transhepatic portograms before (top) and after (bottom) embolization.

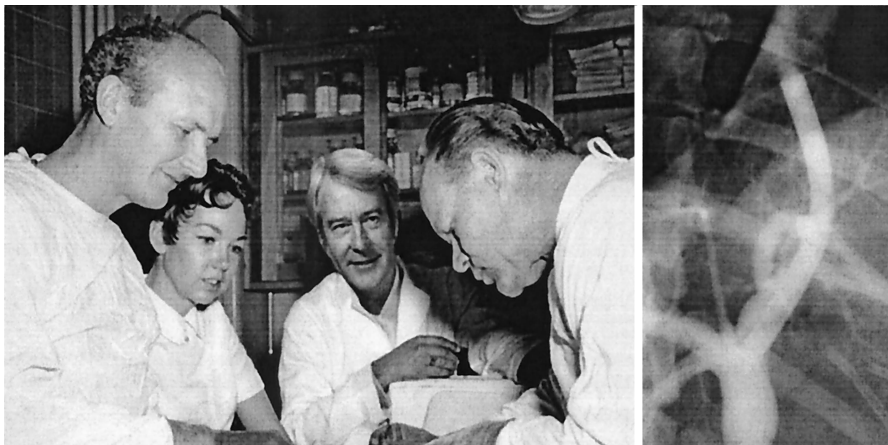


Figure 15. Experimental TIPS in canines performed by a University of California Los Angeles team in 1969. From left to right: Josef Rösch, Nancy Ross, William Hanafee, Harold Snow (portogram reprinted with permission from reference 39).

terial bleeding. When we reported successful control of bleeding in our first five patients in 1970 in *Gastroenterology* (32), a somewhat sarcastic editorial entitled "Turned Off Bleeders" warned about the use of this experimental technique. We were not discouraged. With epinephrine infusions as long as 1 hour, we were able to control bleeding in 12 of the next 16 patients. In four patients with coagulopathies, bleeding resumed after the infusions were over and three had to undergo surgery. The last of these patients with a bleeding prepyloric ulcer

and advanced cirrhosis, who was not a surgical candidate, was treated in November 1970 with a new technique, *selective arterial embolization* with use of autologous clots. We advanced the catheter deep into the gastroduodenal artery and preceded and followed the clot injection with epinephrine infusions to hold the clot at the bleeding site, at the origin of the gastroepiploic artery. The bleeding stopped and, 14 hours later, angiography showed an occluded gastroepiploic artery (Fig 13). To explore technique and safety of embolization before our case publica-

tion in 1972, we did a series of canine experiments and found that the combination of vasoconstrictive infusions and clot embolization was effective and did not cause infarction because of multiple visceral collaterals (33). After our case publication, selective arterial embolization became rapidly accepted to control acute arterial bleeding. After several attempts to use modified autologous clots (34), surgical gelatin (Gelfoam; Upjohn, Kalamazoo, MI) became the embolization material of choice (35). It was mostly used as pieces cut from surgical pads for more central embolization. We also occasionally used Gelfoam powder for peripheral embolization, particularly for diffuse small-vessel bleeding in erosive gastritis to prevent bleeding from multiple gastric collaterals (36).

For control of variceal bleeding, we started in 1970 with continuous low-dose *vasopressin* infusion into the superior mesenteric artery, as introduced by Baum and Nusbaum (31). After exclusion of an arterial bleeding source, a 20-minute vasopressin infusion was performed in the angiography laboratory to evaluate its effectiveness. Continuous 2–4-day infusion then followed in the intensive care unit. Vasoconstrictive infusions were reasonably successful and controlled bleeding in approximately 60%–70% of patients with only minor to moderate local and systemic complications. However, these selective infusions fell into disfavor after studies in our research laboratory showed that they have no better effect on portal and systemic hemodynamics than low-dose systemic infusions, which was later confirmed by randomized clinical studies.

Another factor in decreasing the use of selective vasoconstrictive therapy was the introduction of a new interventional method, *transhepatic variceal embolization*, by Anders Lunderquist in 1974 (Fig 14) (37). With a transhepatic portal approach, the veins supplying varices were selectively catheterized and embolized together with varices. We were very actively involved with this technique and preferred isobutyl 2-cyanoacrylate or Gelfoam mixed with sodium tetradecylsulfate, sometimes preceded with Gianturco coil placement to slow flow in large varices, as our embolic

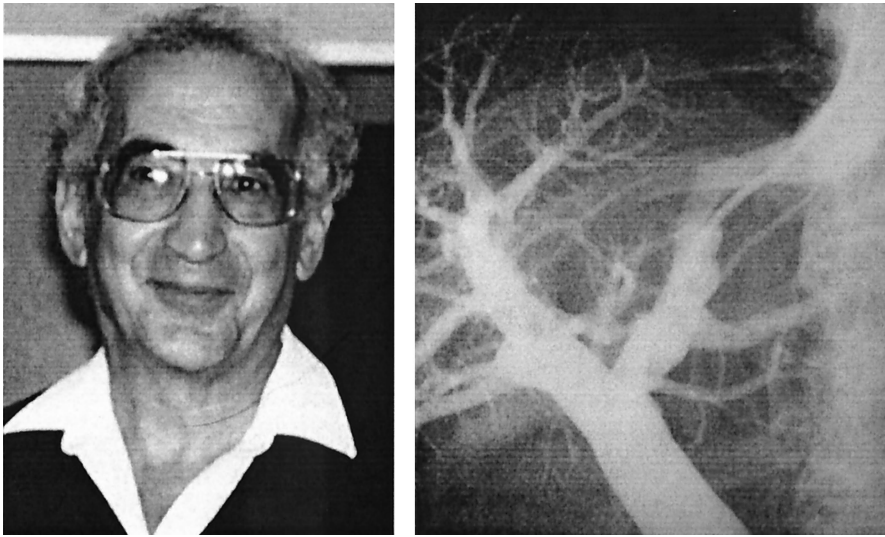


Figure 16. Ronald Colapinto with his first clinical TIPS procedure performed by balloon dilation of the created intrahepatic tract (portogram reprinted with permission from reference 41).

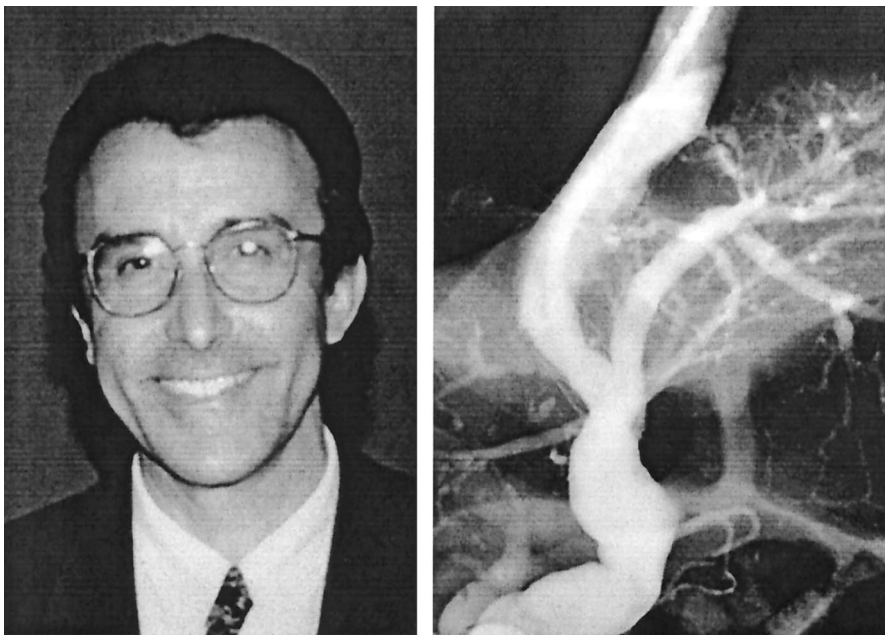


Figure 17. Julio Palmaz and 9-month follow-up of an experimental TIPS in a dog performed with placement of his balloon-expandable stents into the created intrahepatic tract.

materials. The procedure was quite effective, controlling acute bleeding in more than two thirds of patients. However, bleeding frequently recurred from recanalized or subsequently formed varices. These failures, combined with occasional thrombosis of the portal vein after the procedure, diminished the early enthusiasm for

this procedure. At approximately the same time, flexible endoscopy emerged and endoscopic sclerotherapy became the preferred method for treatment of variceal bleeding. In the late 1970s and 1980s, management of gastroesophageal varices was therefore almost completely under gastroenterologists' control, until the intro-

duction of TIPS into clinical practice in 1988.

TRANSJUGULAR INTRAHEPATIC PORTOSYSTEMIC SHUNTS

The TIPS technique was developed in canine experiments at the University of California Los Angeles in the late 1960s by Rösch (Fig 15) (38). A modified transeptal Ross needle was used for entrance of the portal vein from a hepatic vein and coaxial Teflon catheters as large as 18 F were used for dilation of the hepatic puncture tract. Rigid Teflon tubing was used in the first animals for the shunt connection. The idea to create TIPS in the early years of interventional radiology was enhanced by open, inquisitive minds. Specifically, it was a natural progression from inadvertent punctures of intrahepatic portal branches during transjugular cholangiography that we frequently used at that time to define causes of biliary obstruction. With more than 10 years of involvement with angiographic diagnosis of portal circulation, first with splenoportography, and, later, with arterial portography, this new technique of portal system visualization was the logical next step. It was easy to accomplish, to slip a 9-F catheter along the needle and wire into the portal vein and inject contrast medium. However, being influenced by Dotter's ideas that catheters should replace scalpels, enlarging the tract to create a portosystemic shunt was the next step. Various types of tubing to keep the created shunt open were explored in 40 dogs. Covered coils worked best. These shunts stayed patent for approximately 2 weeks and then thrombosed because of their small (4–6 mm) diameter and slow flow in dogs with normal portal pressure. In our final report, we concluded that TIPS creation was a feasible technique (39). Although we performed TIPS creation in cadavers and human liver specimens, technology at that time was not sufficiently advanced for clinical use because it would have required the use of large tubing that was not possible to introduce percutaneously.

An important advancement in TIPS was made by Gutierrez and Burgener (40), who, in the late 1970s, used repeated balloon dilation for shunt cre-

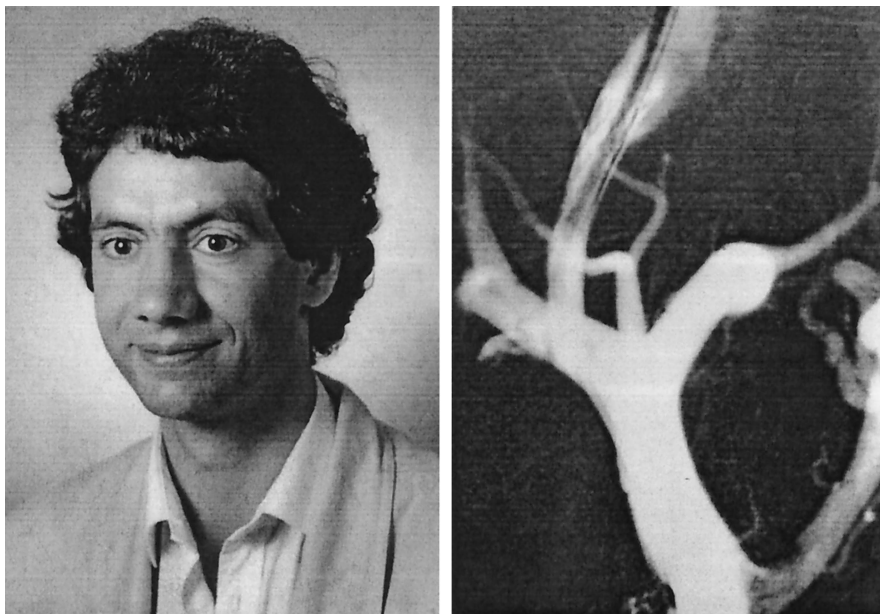


Figure 18. Goetz Richter and his clinical TIPS created with placement of Palmaz stents into the created intrahepatic tract (portogram reprinted with permission from reference 46).



Figure 19. The TIPS pioneers in the United States. Left to right, upper row: Ernie Ring, Jeanne LaBerge, Roy Gordon. Lower row: Gerald Zemel, Barry Katzen, James Benenati, Gary Becker.

ation in canines with portal hypertension. Their shunts stayed open for 1 year. In the early 1980s, Ronald Colap-

into and colleagues performed the first clinical TIPS creation by continuous 12-hour balloon dilation of the liver

puncture tract (Fig 16) (41). Initially, they achieved significant portal decompression and control of bleeding. However, recurrent bleeding in a majority of his 15 patients demonstrated that simple balloon dilation was not sufficient for prolonged portal decompression (42). In the mid 1980s, Palmaz made the final step in TIPS evolution with introduction of his balloon-expandable stents to keep the TIPS open. In most of his dogs with portal hypertension, TIPS exhibited long-term primary patency (Fig 17) (43). In our experiments, we also had good early results creating TIPS with use of modified Z stents in young swine without portal hypertension. Unfortunately, liver parenchyma growth through the stent prevented long-term patency (44).

The first clinical TIPS procedure with stents was performed in January 1988 at Freiburg, Germany, by Goetz Richter and associates with use of Palmaz stents (Fig 18) (45). To facilitate the portal vein puncture, tract dilation, and stent placement, they used a retrieval loop placed by transhepatic access. The procedure was technically successful, but the patient died later of acute respiratory distress syndrome with a patent shunt. They had much better results with their other patients, and their success inspired many interventionalists to introduce TIPS procedures (46). Interventional teams at the University of California, San Francisco, and Miami Vascular Institute were the TIPS pioneers in the United States (Fig 19). Presently, TIPS is widely disseminated throughout the world and is accepted as a minimally invasive treatment of complications of portal hypertension. More than 1,000 publications about TIPS listed in Medline attest to its clinical ability.

FUTURE OF INTERVENTIONAL RADIOLOGY

The three authors of this article have close to 100 years of collective angiographic and interventional radiology practice and experience. During that time, we have seen almost everything in interventional radiology. Some of us have witnessed and participated in the original introduction of basic procedures that define the specialty, what many would call the

“golden days.” Over time, the enthusiastic introduction of new devices and methods resulted in continuously increasing numbers of patients treated with our nonsurgical techniques. We have seen interventional radiology become an indispensable, essential part of medicine: it is literally surgery without a scalpel, the treatment of the future. On the other hand, we have witnessed and have been part of the not-so-golden days when devices and methods we developed were “taken away” from us by our clinical colleagues and the number of our patients started to diminish. Diagnostic and interventional procedures that were once performed only by us disappeared from our schedules as cardiologists, vascular surgeons, gastroenterologists, and other specialists started treating their own patients. Originally, these patients were referred to us for our techniques and expertise. However, our clinical colleagues are trying to learn these techniques and claim them as their own. We could blame our colleagues for this encroachment and intrusion into our field; however, looking back as objectively as possible at this invasion, the major fault was our own.

Many interventional radiologists, including us, have concentrated mainly on development of technical skills and performance and improvement of our procedures. We became superb “body plumbers” relying on referrals from clinicians. We neglected to develop clinical skills and did not get involved with management of patients. We did not listen to the warnings from our own leaders. In 1968, Dotter predicted our present predicament: “[i]f we don’t assume clinical responsibility for our patients, we will face forfeiture of our territorial rights based solely on imaging equipment others can obtain and skills others can learn.” In the 1980s, Ring, Bob White, and Tom Meaney and, in the 1990s, Gary Becker reminded us again that, to keep our specialty, we must have direct access to patients and provide total patient care (47–51). We have not done this in great enough numbers and now many interventional radiologists are experiencing decreases in or complete loss of certain types of procedures.

What do we need to do to survive

and blossom? We must adapt and change in several areas:

1. We need to assume clinical responsibilities and achieve competence to take care of patients. In addition to treating them with percutaneous techniques, we must admit, evaluate, and perform follow-up. This will completely change our role and will bring us direct referrals from primary care physicians.
2. Interventional training has to change to be in step with the new role of interventionalists. SIR has already taken action in this direction. Some institution training programs are already or will be soon offering focused training in interventional radiology during radiology residency. SIR is developing a proposal for an alternate pathway to subspecialty training.
3. We need to stand separate from diagnostic radiology. This affords us the ability to act and concentrate on interventional radiology as a patient care specialty. It further allows us to establish our own financial base. SIR has already taken important steps in this regard. Interventional radiology has been recognized by the American College of Radiology as distinct from diagnostic radiology.
4. We need to form partnerships with clinicians—teams based on equality, mutual respect, and the concept that each individual does what he or she does best with the goal of providing the best care to patients. These could be in the form of simple partnerships, centers, or more complex structures that reduce conflicts of interest, eliminate duplications, enhance patient care, and decrease treatment costs.
5. We need to become recognized by primary care providers and the public so they are informed as to who we are and what we do. A name change and selection of the proper name will go a long way toward achieving this.
6. With all these changes, we must also continue to concentrate on our innovative work,

develop new tools, devices, techniques, and methods, and expand the indications for interventional treatment.

7. As a specialty, we need to pursue basic and clinical research in the diseases we treat and the mechanisms of action of our therapies. Research is the foundation of clinical practice.

Does it seem impossible? Of course not. We need to follow the words of rocket scientist Bob Goddard, who learned from his own work, “[i]t is difficult to say what is impossible, for the dream of yesterday is the hope of today and reality of tomorrow” (From “The Speaker’s Electronic Reference Collection,” AAPex Software, 1994).

References

1. Friedman SG. Charles Dotter: interventional radiologist. *Radiology* 1989; 172:921–924.
2. Dotter CT. Cardiac catheterization and angiographic techniques of the future. *Cesk Radiol* 1965; 19:217–236.
3. Dotter CT, Judkins MP. Transluminal treatment of atherosclerotic obstructions: description of a new technique and preliminary report of its applications. *Circulation* 1964; 30:654–670.
- 3A. Dotter CT, Frische LH, Judkins MP, Mueller R. The nonsurgical treatment of iliofemoral arteriosclerotic obstructions. *Radiology* 1966; 86:871–875.
4. Dotter CT, Judkins MP, Rösch J. Nichtoperative, transluminale Behandlung der arteriosklerotischen Verschlussaffektionen. *Fortschr Röntgenstr* 1968; 109:125–133.
5. Margulis AR. Interventional diagnostic radiology—a new subspecialty (Editorial). *AJR Am J Roentgenol* 1967; 99: 761–762.
6. Porstmann W, Wierny L. Intravasale recanalisation inoperabler arterieller Obliterationen. *Zentralbl Chir* 1967; 92(suppl 26):1586–1591.
7. Zeitler E, Müller R. Erste Ergebnisse mit der Katheter-rekanalisation nach Dotter bei arterieller Verschlusskrankheit. *Fortschr Röntgenstr* 1969; 111: 345–352.
8. Zeitler E, Schoop W, Schmidtke I. Mechanische Behandlung von Beckenarterienstenosen mit der perkutanen Kathetertechnik. *Verh Dtsch Kreislaufforsch* 1971; 37:402–407.
9. Porstmann W. Ein neuer Korsett-Balloon-Katheter zur transluminalen Recanalisation nach Dotter unter besonderer Berücksichtigung von Obliterationen.

- tionen an den beckenarterien. *Radiol Diagn* 1973; 14:239–244.
10. Grüntzig A, Hopff H. Percutane Recanalization chronischer arterieller Verschlüsse mit einem neuen dilatationskatheter. *Dtsch Med Wochenschr* 1974; 99:2502–2505.
 11. Grüntzig A. Percutane dilatation von koronarstenosen. Beschreibung eines neuen kathetersystem. *Klin Wochenschr* 1976; 54:543–545.
 12. Dotter CT, Rösch J, Seaman AJ. Selective clot lysis with low-dose streptokinase. *Radiology* 1974; 111:31–37.
 13. Katzen BT, van Breda A. Low dose streptokinase in the treatment of arterial occlusions. *AJR Am J Roentgenol* 1981; 136:1171–1178.
 14. Becker GJ, Rabe FE, Richmond BD, et al. Low-dose fibrinolytic therapy: results and new concepts. *Radiology* 1983; 148:663–670.
 15. McNamara T, Fischer JR. Thrombolysis of peripheral arterial and graft occlusions: improved results using high-dose urokinase. *AJR Am J Roentgenol* 1985; 144:769–775.
 16. Dotter CT. Transluminally-placed coilspring endarterial tube grafts: long-term patency in canine popliteal artery. *Invest Radiol* 1969; 4:329–332.
 17. Maass D, Kropf L, Egloff L, Demierre D, Turina M, Senning A. Transluminal implantation of intravascular “double-helix” spiral prostheses: technical and biological considerations. *ESAO Proc* 1982; 9:252–257.
 18. Mass D, Zollikofer CL, Largiader, Senning A. Radiological follow-up of transluminally inserted vascular endoprostheses: an experimental study using expanding spirals. *Radiology* 1984; 152:659–663.
 19. Dotter CT, Bushmann RW, McKinney MK, Rösch J. Transluminal expandable nitinol coil stent grafting: preliminary report. *Radiology* 1983; 147:259–260.
 20. Cragg A, Lund G, Rysavy J, Castaneda F, Castaneda-Zuniga WR, Amplatz K. Nonsurgical placement of arterial endoprostheses: a new technique using nitinol wire. *Radiology* 1983; 147:261–263.
 21. Rabkin JE, Germashev V. The Rabkin nitinol coil stent: a five-year experience. In: Castaneda-Zuniga WR, Tadarthy SM, eds. *Interventional Radiology*, Second Edition. Baltimore: Williams & Wilkins, 1992;576–581.
 22. Wright KC, Wallace S, Charnsangavej C, Carrasco CH, Gianturco C. Percutaneous endovascular stents: an experimental evaluation. *Radiology* 1985; 156:69–72.
 23. Uchida BT, Putnam JS, Rösch J. Modifications of Gianturco expandable wire stents. *AJR Am J Roentgenol* 1988; 150:1185–1187.
 24. Rösch J, Uchida BT, Hall LD, et al. Gianturco-Rösch expandable Z-stents in the treatment of superior vena cava syndrome. *Cardiovasc Intervent Radiol* 1992; 15:319–327.
 25. Palmaz JC, Sibbitt RR, Reuter SR, Tio FO, Rice WJ. Expandable intraluminal graft: a preliminary study. *Radiology* 1985; 156:73–77.
 26. Palmaz JC, Kopp DJ, Hayashi H, et al. Normal and stenotic renal arteries: experimental balloon-expandable intraluminal stenting. *Radiology* 1987; 164:705–708.
 27. Rousseau H, Puel J, Joffre F, et al. Self-expanding endovascular prosthesis: an experimental study. *Radiology* 1987; 164:709–714.
 28. Sigwart V, Puel J, Mirkovitch V, Joffre F, Kappenberger L. Intravascular stents to prevent occlusions and restenosis after transluminal angioplasty. *N Engl J Med* 1987; 316:701–706.
 29. Nusbaum M, Baum S. Radiographic demonstration of unknown site of gastrointestinal bleeding. *S Forum* 1963; 14:374–375.
 30. Nusbaum M, Baum S, Sakiyalak P, Blakemore WS. Pharmacologic control of portal hypertension. *Surgery* 1967; 62:299–310.
 31. Baum S, Nusbaum M. The control of gastrointestinal hemorrhage by selective mesenteric arterial infusion of vasopressin. *Radiology* 1971; 98:497–505.
 32. Rösch J, Gray RK, Grollman JH Jr, Ross G, Stecker RJ, Weiner M. Selective arterial drug infusions in the treatment of acute gastrointestinal bleeding. *Gastroenterology* 1970; 59:341–349.
 33. Rösch J, Dotter CT, Brown MT. Selective arterial embolization. A new method for control of acute gastrointestinal bleeding. *Radiology* 1972; 102:303–306.
 34. Bookstein JJ, Closta EM, Foley D, Walter JF. Transcatheter hemostasis of gastrointestinal bleeding using modified autogenous clot. *Radiology* 1974; 113:277–285.
 35. Golf RE, Grace DM. Gelfoam embolization of the left gastric artery for bleeding ulcer: experimental considerations. *Radiology* 1975; 116:575–580.
 36. Rösch J, Keller FS, Kozak B, Niles N, Dotter CT. Gelform powder embolization of the left gastric artery in treatment of massive small-vessel gastric bleeding. *Radiology* 1984; 151:365–370.
 37. Lunderquist A, Vang J. Transhepatic catheterization and obliteration of the coronary vein in patients with portal hypertension and esophageal varices. *N Engl J Med* 1974; 291:646–649.
 38. Rösch J, Hanafee WN, Snow H. Transjugular portal venography and radiologic portacaval shunt: an experimental study. *Radiology* 1969; 92:1112–1114.
 39. Rösch J, Hanafee W, Snow H, Barenfus M, Gray R. Transjugular intrahepatic portacaval shunt: an experimental work. *Am J Surg* 1971; 121:588–592.
 40. Gutierrez OH, Burgener FA. Production of nonsurgical portosystemic venous shunts in dogs by transjugular approach. *Radiology* 1979; 130:507–509.
 41. Colapinto RF, Stronell RD, Gildiner M, et al. Formation of intrahepatic portosystemic shunts using a balloon dilation catheter: preliminary clinical experience. *AJR Am J Roentgenol* 1983; 140:709–714.
 42. Gordon JD, Colapinto RF, Abecassis M, et al. Transjugular intrahepatic portosystemic shunt: a nonoperative approach to life-threatening variceal bleeding. *Can J Surg* 1987; 30:45–49.
 43. Palmaz JC, Garcia F, Sibbitt RR, et al. Expandable intrahepatic portacaval shunt stents in dogs with chronic portal hypertension. *AJR Am J Roentgenol* 1986; 147:1251–1254.
 44. Rösch J, Uchida BT, Putnam JS, et al. Experimental intrahepatic portacaval anastomosis with use of expandable Gianturco stents. *Radiology* 1987; 162:481–485.
 45. Richter GM, Palmaz JC, Nöldge G, et al. Der transjuguläre intrahepatische portosystemische stent shunt (TIPSS). *Radiologie* 1989; 29:408–411.
 46. Richter GM, Noeldge G, Palmaz JC, et al. Transjugular intrahepatic portocaval stent shunt: Preliminary clinical results. *Radiology* 1990; 174:1027–1030.
 47. Ring EJ, Kerlan RK Jr. Clinical responsibility in interventional radiology. *Radiology* 1983; 147:285.
 48. Ring EJ, Kerlan RK Jr. Inpatient management: a new role for interventional radiologists. *Radiology* 1985; 154:543.
 49. Kinnison ML, White RI Jr, Auster M, et al. Inpatient admissions for interventional radiology: philosophy of patient management. *Radiology* 1985; 154:349–351.
 50. Meaney TF. The decline of diagnostic radiology: call to action. 1989 Dotter Lecture. *Radiology* 1989; 172:889–892.
 51. Becker GJ. Interventional radiology 2000 and beyond: back from the brink. The 1999 Charles T. Dotter Lecture. *J Vasc Interv Radiol* 1999; 10:681–687.