



www.figo.org

Contents lists available at ScienceDirect

## International Journal of Gynecology and Obstetrics

journal homepage: www.elsevier.com/locate/ijgo



## CLINICAL ARTICLE

## Uterine artery embolization versus laparoscopic occlusion of uterine vessels for management of symptomatic uterine fibroids

Sreekrishnakiran Ambat<sup>a</sup>, Suneeta Mittal<sup>a,\*</sup>, Deep N. Srivastava<sup>b</sup>, Renu Misra<sup>c</sup>, Vatsla Dadhwal<sup>a</sup>, Bhaswati Ghosh<sup>a</sup><sup>a</sup> Department of Obstetrics and Gynecology, All India Institute of Medical Sciences, New Delhi, India<sup>b</sup> Department of Radiodiagnosis, All India Institute of Medical Sciences, New Delhi, India<sup>c</sup> Department of Obstetrics and Gynecology, Sitaram Bharatiya Hospital, New Delhi, India

## ARTICLE INFO

## Article history:

Received 30 October 2008

Received in revised form 21 December 2008

Accepted 9 January 2009

## Keywords:

Fibroids

Laparoscopic occlusion of uterine vessels

Uterine artery embolization

## ABSTRACT

**Objective:** To evaluate the efficacy and complications of uterine artery embolization (UAE) versus laparoscopic occlusion of uterine vessels (LOUV) in the management of symptomatic fibroids. **Methods:** A pilot randomized clinical trial in which 20 patients with symptomatic fibroids were randomly allocated into two groups. Ten women underwent UAE, and 10 women underwent LOUV. Symptomatic improvement in menorrhagia and reduction in the volumes of the uterus and the fibroid were assessed at 3 and 6 months. **Results:** The patients were comparable with regard to age and parity. At 6 months, there was no significant difference in the mean reduction in menstrual blood loss, uterine volume, and volume of the dominant fibroid between the two groups ( $P=0.436$ ,  $P=0.796$ ,  $P=1.00$ , respectively). However, higher pain scores were recorded on day 1 in the UAE group compared with the LOUV group ( $P=0.0002$ ). **Conclusions:** The effects of UAE and LOUV in the management of symptomatic fibroids are comparable. The main advantage of LOUV is less postoperative pain compared with UAE.

© 2009 International Federation of Gynecology and Obstetrics. Published by Elsevier Ireland Ltd. All rights reserved.

## 1. Introduction

Leiomyoma of the uterus is the most common pelvic tumor among women of reproductive age. Although the number of hysterectomies performed per year is decreasing, fibroids still account for 26.9% of all hysterectomies performed each year in the United States [1]. Recently, conservative modalities, including uterine artery embolization (UAE), have been used to manage symptomatic fibroids in women who wish to retain their uterus. Liu et al. [2] used laparoscopic occlusion of uterine vessels (LOUV), a relatively new technique that uses the same principle of arterial occlusion, to manage fibroids. They achieved promising results.

The aim of the present study was to compare UAE and LOUV as methods to treat symptomatic fibroids by shrinking the uterus and the fibroids, and to provide symptomatic relief. We also evaluated any adverse effects and complications resulting from these procedures.

## 2. Materials and methods

This pilot randomized clinical trial was conducted at the Department of Obstetrics and Gynecology, All India Institute of Medical

Sciences (AIIMS) in collaboration with the Department of Radiodiagnosis. Approval for the study was obtained from the institutional review board, and all women gave informed written consent. Twenty consecutive patients who visited a single practitioner in the gynecological outpatient department for conservative treatment of symptomatic fibroids were randomly allocated by computer-generated random numbers to undergo LOUV or UAE; there were 10 patients in each group. We included symptomatic women with enlarged uteri that corresponded in size to 12–20 weeks of pregnancy. Women with a history of thromboembolic disorder, bleeding diathesis or breast cancer, and women who had taken hormones during the last 3 months were excluded. Pretreatment with hormones (gonadotropin receptor hormone agonists) reduces uterine and fibroid volume and this may bias the results. Pregnancy and pelvic inflammatory disease were ruled out in suspected cases. Women with suspected submucosal fibroids on the basis of ultrasound scan were also excluded from the study.

The primary aim of the study was to compare symptomatic improvement in menstrual blood loss (assessed by pictorial blood loss assessment charts [PBACs]) following LOUV compared with UAE. The secondary outcomes measured were postoperative pain, reduction in uterine and fibroid volumes, and adverse effects and complications following these procedures.

A thorough gynecological evaluation was done; in addition to a routine preoperative workup, all women underwent an endometrial aspiration and Pap smear. Blood hemoglobin levels were measured.

\* Corresponding author. Department of Obstetrics and Gynecology, All India Institute of Medical Sciences, Ansari Nagar, New Delhi-110029, India. Tel.: +91 11 26588547, +91 9818542111; fax: +91 11 26588449.

E-mail address: suneeta\_mittal@yahoo.com (S. Mittal).

Radiological evaluation included ultrasound (transabdominal or transvaginal) and magnetic resonance imaging (MRI) of the pelvis. PBACs were given to all women at recruitment for objective assessment of menorrhagia.

All patients were admitted 1 day before the procedure. UAE was performed under intravenous analgesia (pethidine and promethazine) by a single interventional radiologist. The procedure was performed through the right trans-femoral route using a 5-French uterine artery catheter and 500–700 µm polyvinyl alcohol particles (PVA, Contour; Boston Scientific, Natick, MA, USA). A pigtail catheter was introduced through the right femoral artery. When the tip was at the level of the renal arteries, a flush aortogram was taken to detect any aberrant blood vessels. The anterior division of the internal iliac artery and the uterine artery were identified on the left side, and the pigtail catheter was withdrawn after a guide wire was inserted. The uterine catheter was advanced over the guide wire until the tip of the catheter was lying at the origin of the uterine artery. Embolization was performed using a free flow technique with 500–700 µm PVA particles. The ipsilateral (right) uterine artery was catheterized using a loop technique and was embolized in a similar way. Complete occlusion was confirmed in all cases by stasis of contrast dye under fluoroscopy. The lower limb was immobilized for 24 hours following the procedure, and intravenous analgesia was administered on demand.

LOUV was performed under general anesthesia by either one of two experienced gynecologic laparoscopic surgeons. The patients were positioned in low lithotomy (modified Lloyd Davies position). After introducing the laparoscope through the umbilical port, 2 or 3 ancillary portals were made for better access. The angle between the infundibulopelvic ligament and round ligament over the external iliac vessels was identified, and the anterior leaf of the broad ligament was incised over this angle. Large vessels were traced up to the origin of the internal iliac artery, and the uterine artery was identified at its origin from the anterior division. The vessel was occluded using either polymer clips or completely desiccated with bipolar coagulation forceps under direct vision. Double clips were applied to ensure complete occlusion. The same procedure was carried out on the contralateral uterine artery. Afterwards, the utero-ovarian ligaments were also coagulated bilaterally. The uterus became soft and purple.

After surgery, patients in both groups were asked to record their pain on a visual analog scale (VAS) on day 1 of the procedure; analgesics were given on demand. For both procedures perioperative antibiotic prophylaxis (third-generation cephalosporin and metronidazole) was given intravenously for 24 hours followed by oral antibiotics for 5 days after discharge.

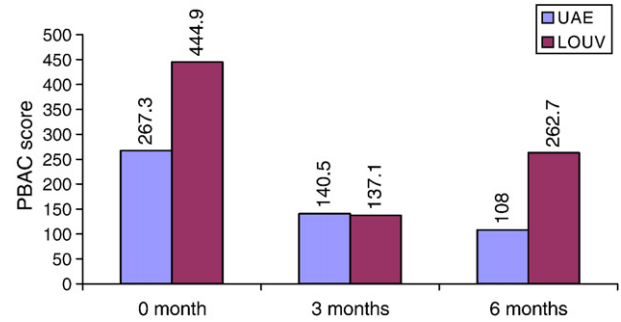
All patients were reviewed at 3 and 6 months after the procedures. The patients' perceived improvement in symptoms was noted. In addition, change in menstrual blood loss was objectively assessed by reviewing their PBAC charts at 3 and 6 months. Blood hemoglobin levels were measured at the 6-month visit. Clinical examination was also carried out during these follow-up visits. A single clinician was responsible for recruitment, clinical evaluations, and follow-up assessments to maintain uniformity.

**Table 1**

Baseline characteristics of women in the study.

Characteristic	UAE (n = 10)	LOUV (n = 10)	P value
Mean age, y	40.80	40.50	0.89
Parity, mean ± SD	2.40 ± 1.43	2.90 ± 0.994	0.64
Symptoms			
Menorrhagia	10	10	
Dysmenorrhea	2	7	
Bulk-related symptoms	1	1	

Abbreviations: UAE, uterine artery embolization; LOUV, laparoscopic occlusion of uterine vessels.



**Fig. 1.** Mean pictorial blood loss assessment chart (PBAC) score in the uterine artery embolization (UAE) and laparoscopic occlusion of uterine vessels (LOUV) groups.

Radiological follow-up included ultrasound at 3 and 6 months and MRI at 6 months. Where there were multiple fibroids, the volume of the dominant fibroid was taken as the reference. The volumes of the uterus and the dominant fibroid were calculated using the formula length multiplied by width multiplied by depth multiplied by 0.5233 [3].

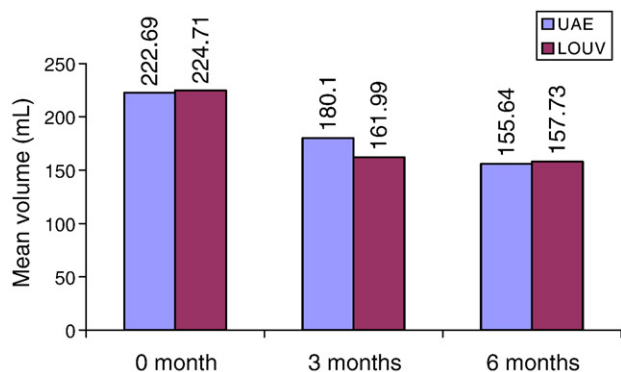
All values were reported as mean ± SD for normal distributed data and as median for skewed data. Chi-squared and Fisher exact test were used to compare categorical values. Unpaired *t* test was used to compare intergroup means when the variable being compared had a near normal distribution, whereas Wilcoxon-Mann-Whitney test was used to compare markedly skewed data. *P* < 0.05 was considered statistically significant.

**3. Results**

The patients in the two groups were comparable in age and parity. The dominant symptom in both groups was menorrhagia. Few women had dysmenorrhea or bulk-related symptoms (Table 1). Ultrasound and MRI showed that the dominant fibroid was intramural in all patients. In the UAE group, 1 patient had a subserosal fibroid in addition to the intramural fibroid; in the LOUV group, 2 women had associated subserosal fibroids. Nine women in the UAE group and 7 women in the LOUV group had multiple fibroids.

Baseline PBAC score before the procedure was significantly higher in the LOUV group compared the UAE group (444.9 vs 267.3; *P* = 0.04). However, the mean fibroid volume was slightly higher in the UAE group compared with the LOUV group (57.99 mL vs 38.4 mL), although the difference was not statistically significant (*P* = 0.07). The mean uterine volumes were similar in the UAE and LOUV groups (222.69 mL vs 224.71 mL, respectively; *P* = 0.83).

All of the women in both groups perceived an improvement in menorrhagia at 3 and 6 months. The mean reduction in PBAC score at



**Fig. 2.** Change in uterine volume after uterine artery embolization (UAE) and laparoscopic occlusion of uterine vessels (LOUV).

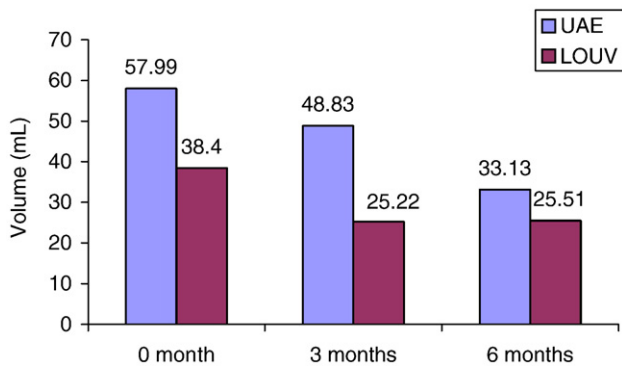


Fig. 3. Change in volume of fibroid (assessed by ultrasound) after uterine artery embolization (UAE) and laparoscopic occlusion of uterine vessels (LOUV).

3 months after the procedures was 47.3% in the UAE group and 69.2% in the LOUV group. The difference between the two groups was not statistically significant ( $P=0.165$ ). At 6 months after the procedures, the PBAC scores reduced further in the UAE group (by 59.6% from pretreatment values). Menorrhagia recurred in 4 patients in the LOUV group; however, the mean PBAC score was still 41% less than that at recruitment. Again, the difference between the 2 groups was not significantly different ( $P=0.436$ ) (Fig. 1). The mean baseline hemoglobin levels in the 2 groups were similar: 12.08 g/dL (range, 10.4–14.4 g/dL) in the UAE group compared with 11.5 g/dL (range, 9.9–14.1 g/dL) in the LOUV group ( $P=0.09$ ). Despite the reduction in PBAC scores, there was no significant improvement in hemoglobin levels in the two groups at 6 months (UAE group:  $P=0.77$ ; LOUV group:  $P=0.65$ ).

The reduction in uterine volume on ultrasound assessment was 19% and 30% following UAE and 28% and 29.8% following LOUV at 3 and 6 months, respectively. The differences between the two groups were not significant at 3 and 6 months ( $P=0.529$  and  $P=0.796$ , respectively). Fibroid volume was reduced by 15.8% at 3 months and by 43% at 6 months after UAE, and by 34.3% at 3 months and by 33.6% at 6 months after LOUV (Figs. 2 and 3). Again, the differences between the 2 groups were not statistically significant at 3 and 6 months ( $P=0.075$  and  $P=1.00$ , respectively).

The mean subjective pain score as assessed by VAS on day 1 of the procedures was 6.50 in the UAE group and 2.75 in the LOUV group; the pain score was significantly higher in the UAE group ( $P=0.0002$ ). Mean hospital stay was 3.5 days in both the UAE and LOUV groups (range, 2–7 days vs 2–10 days, respectively;  $P=1.0$ ). Mean operating time was also similar: 62 minutes (range, 60–80 minutes) in the UAE group, and 100 minutes (range, 60–195 minutes) in the LOUV group ( $P=0.085$ ). Three women in the LOUV group had additional procedures at the time of surgery (1 sterilization, 2 adhesiolysis).

#### 4. Discussion

UAE is a well-established technique for controlling various forms of pelvic hemorrhage, including control of postpartum hemorrhage,

uterine arteriovenous malformation, and placenta accreta [4]. Ravina et al. [5] were the first to describe the successful use of UAE in the treatment of uterine leiomyoma. They observed symptomatic relief in 78% of patients at 3 months after the procedure. Walker et al. [6] evaluated the efficacy and complication rate following UAE in 400 women. They reported symptomatic improvement in menorrhagia in 84% of patients and relief of menstrual pain in 79% of patients. Improvement in pressure symptoms was recorded in 73%–90% of women. The reduction of uterine volume after a mean of 9.7 months following the procedure was 55% in their series; and volume of the fibroid was reduced by 73%. In a subset of 114 women from this series, Watson et al. [7] reported a 58% reduction in fibroid volume 6 months after UAE. Ninety-one percent of women in their series perceived an improvement or resolution of symptoms. In the present study, although all women undergoing UAE reported some improvement in menorrhagia, the quantitative improvement was not as encouraging as in previous studies. The major limitation of the present study is the small number of patients.

LOUV was first performed by Liu et al. [2] in 2001. After the procedure, symptomatic improvement was seen in 89.4% of patients, and there was a significant reduction in the size of the fibroid and the uterus (mean reduction 76% and 46%, respectively). Similarly, Yen et al. [8] reported a reduction in fibroid size by 59.1% and uterine size by 38.3% at 6 months after the procedure. LOUV has also been used in an attempt to reduce the volume of the uterus before myomectomy [9].

In the present study, all of the women who underwent LOUV had some symptomatic improvement at 3 months. However, 4 patients had a slight recurrence in menorrhagia at 6 months, possibly secondary to the development of collaterals. Hence, all patients should be counseled about this possibility. The reduction in the volume of the uterus and the volume of the dominant fibroid was again less in our study than in previous studies; the reason for this is unknown.

Various complications such as postembolization syndrome, myoma expulsion, uterine necrosis, and sepsis have been reported after UAE [10,11]. LOUV is not associated with any significant specific complication except for transient obturator ischemia [12]. However, the risks of general anesthesia and of abdominal surgery, which are not encountered during UAE, should be considered for LOUV.

In the present study, 2 patients in the UAE group were diagnosed with postembolization syndrome with fever, myalgia, and abdominal pain. They were managed conservatively with antibiotics and analgesics. No procedure-related complications were seen after LOUV, except in 1 patient who developed transient paralytic ileus.

Hald et al. [12] compared the efficiency and complications of LOUV and UAE in the treatment of fibroids. They concluded that LOUV provides similar results to UAE for managing fibroid-related symptoms; with LOUV there was less postoperative pain and no risk of radiation exposure. These authors have recently reported the results of a similar randomized controlled clinical trial [13] in which they primarily looked at the effect of these procedures on PBAC scores. They also compared postoperative pain and nausea, treatment failures, secondary interventions, and complications among other outcome measures. The results of the present study are comparable with those of both of these studies (Table 2).

Table 2

Symptomatic relief and reduction in uterine and fibroid volume and subjective pain score after UAE compared with LOUV.

Parameter	Hald et al. [12]			Hald et al. [13]			Present study		
	LOUV (n=22)	UAE (n=24)	P value	LOUV (n=28)	UAE (n=28)	P value	LOUV (n=10)	UAE (n=10)	P value
Reduction in PBAC at 6 months (%)	50	66	0.38	56	50	0.57	41	59.6	0.436
Reduction in uterine volume at 6 months (%)	37	40	0.67	–	–	–	29.8	30	0.796
Reduction in fibroid volume at 6 months (%)	36	45	0.453	–	–	–	33.6	43	1.00
Subjective pain score at day 1 (VAS)	1.4	1.9	0.008	2.48	1.06	0.026	2.75	6.5	0.0002

Abbreviations: UAE, uterine artery embolization; LOUV, laparoscopic occlusion of uterine vessels; PBAC, pictorial blood loss assessment charts; VAS, visual analog scale.

In conclusion, our data suggest that the effects of LOUV and UAE in the management of symptomatic fibroids are comparable. The main advantage of LOUV is less postoperative pain compared with UAE. LOUV can be offered to patients who prefer conservative management, as an alternative to UAE. However, patients should be warned about the risks of general anesthesia and abdominal surgery that are associated with LOUV. These risks are not encountered with UAE. Larger well-powered trials, with longer follow-up, are needed to confirm the promising results of this study.

## References

- [1] Merrill RM. Hysterectomy surveillance in the United States, 1997 through 2005. *Med Sci Monit* 2008;14(1):CR24–31.
- [2] Liu WM, Ng HT, Wu YC, Yew YK, Yuan CC. Laparoscopic bipolar coagulation of uterine vessels: a new method for treating symptomatic fibroids. *Fertil Steril* 2001;75(2):417–22.
- [3] Orsini LF, Salardi S, Pilu G, Bovicelli L, Cacciari E. Pelvic organs in premenarcheal girls: real-time ultrasonography. *Radiology* 1984;153(1):113–6.
- [4] Yamashita Y, Harada M, Yamamoto H, Miyazaki T, Takahashi M, Miyazaki K, et al. Transcatheter arterial embolization of obstetric and gynaecological bleeding: efficacy and clinical outcome. *Br J Radiol* 1994;67(798):530–4.
- [5] Ravina JH, Herbreteau D, Ciraru-Vigneron N, Bouret JM, Houdart E, Aymard A, et al. Arterial embolization to treat uterine myomata. *Lancet* 1995;346(8976):671–2.
- [6] Walker WJ, Pelage JP. Uterine artery embolisation for symptomatic fibroids: clinical results in 400 women with imaging follow up. *BJOG* 2002;109(11):1262–72.
- [7] Watson GM, Walker WJ. Uterine artery embolization for the treatment of symptomatic fibroids in 114 women: reduction in size of the fibroids and women's view of the success of the treatment. *BJOG* 2002;109(2):129–35.
- [8] Yen YK, Liu WM, Yuan CC, Ng HT. Laparoscopic bipolar coagulation of uterine vessels to treat symptomatic myomas in women with elevated Ca 125. *J Am Assoc Gynecol Laparosc* 2001;8(2):241–6.
- [9] Liu WM, Tzeng CR, Yi-sen C, Wang RH. Combining the uterine depletion procedure and myomectomy may be useful for treating symptomatic fibroids. *Fertil Steril* 2004;82(1):205–10.
- [10] Gabriel H, Pinto CM, Kumar M, Nikolaidis P, Miller FH, Weinrach DM, et al. MRI detection of uterine necrosis after uterine artery embolization for fibroids. *Am J Roentgenol* 2004;183(3):733–6.
- [11] Spies JB, Spector A, Roth AR, Baker CM, Mauro L, Murphy-Skrynarz K. Complications after uterine artery embolization for leiomyomas. *Obstet Gynecol* 2002;100(5 Pt 1):873–80.
- [12] Hald K, Langebrenne A, Kløw NE, Noreng HJ, Berge AB, Istre O. Laparoscopic occlusion of uterine vessels for the treatment of symptomatic fibroids: Initial experience and comparison to uterine artery embolization. *Am J Obstet Gynecol* 2004;190(1):37–43.
- [13] Hald K, Kløw NE, Qvigstad E, Istre O. Laparoscopic occlusion compared with embolization of uterine vessels: a randomized controlled trial. *Obstet Gynecol* 2007;109(1):20–7.