

Colour Retinal Image Enhancement based on Domain Knowledge

by

Gopal Dutt Joshi, Jayanthi Sivaswamy

in

Proc. of the IEEE Sixth Indian Conference on Computer Vision, Graphics and Image Processing (ICVGIP 2008), pp. 591-598, Dec 16-19 2008, Bhubaneswar, India.

Report No: IIIT/TR/2009/9



Centre for Visual Information Technology
International Institute of Information Technology
Hyderabad - 500 032, INDIA
January 2009

Colour Retinal Image Enhancement based on Domain Knowledge

Gopal Datt Joshi, Jayanthi Sivaswamy
Centre for Visual Information Technology
IIIT-Hyderabad, India
gopal@research.iiit.ac.in, jsivaswamy@iiit.ac.in

Abstract

Retinal images are widely used to manually or automatically detect and diagnose many diseases. Due to the complex imaging setup, there is a large luminosity and contrast variability within and across images. Here, we use the knowledge of the imaging geometry and propose an enhancement method for colour retinal images, with a focus on contrast improvement with no introduction of artifacts. The method uses non-uniform sampling to estimate the degradation and derive a correction factor from a single plane. We also propose a scheme for applying the derived correction factor to enhance all the colour planes of a given image. The proposed enhancement method has been tested on a publicly available dataset [8]. Results show marked improvement over existing methods.

1. Introduction

Among the many uses of retinal images are in the early detection and diagnosis of many eye diseases such as diabetic retinopathy (DR) and age-related macular degeneration (AMD). Automated analysis techniques for retinal images has been an important area of research of late for developing screening programmes [8]. In retinal images, vascular topography, dark and bright pathology (subtle or otherwise) are mainly of interest. A good quality of image is essential for a reliable diagnosis performed either manually or automatically. Therefore, improvement of image quality is a fundamental problem in retinal image analysis.

Retinal images are acquired with a digital fundus camera, which captures the illumination reflected from the retinal surface. Despite the controlled conditions under which imaging takes place, there are many patient-dependent aspects which are difficult to control. Thus, most retinal images suffer from non-uniform illumination. Some of the contributing factors are: (a) The curved surface of the retina. Consequently, all retinal regions cannot be illuminated uniformly; (b) Imaging requires a dilated pupil. The degree of

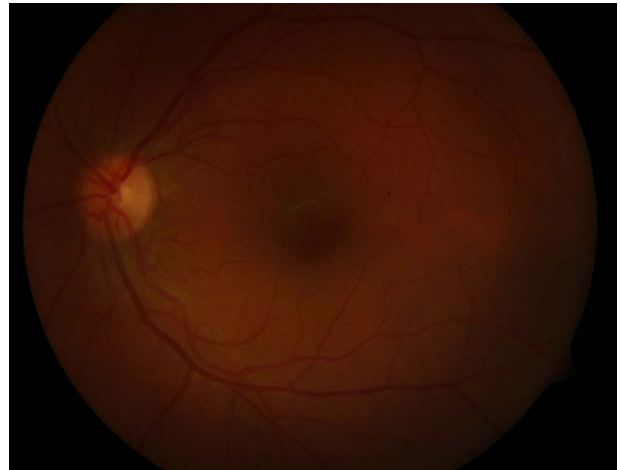

Figure 1. A retinal image with uneven illumination and contrast.

dilation is highly variable across patients; (c) Unexpected movements of the patient's eye. The bright flash-light makes the patient move his/her eye away from the view of the camera involuntarily; (d) Presence of other diseases such as cataract which can block the light reaching the retina. These factors result in images having a large luminosity and contrast variability within and across images. Hence, for a reliable diagnosis, whether manual or automated, an image normalization step is necessary.

A sample of typical retinal image is shown in figure 1 affected by non-uniform illumination. It can be observed that luminosity and contrast distribution is not uniform across the image. Such variations affect the detection, for instance, of important objects such as microaneurysms (MA) which are of interest in early diagnosis of DR. These appear as tiny red dots in a colour retinal image as highlighted in images shown in figure 2. The sample MA regions and the blood vessels (red lines/curves) also occur with varying local contrast across images. A normalisation step is hence

an important preprocessing step which has been shown to improve vessel segmentation [12].

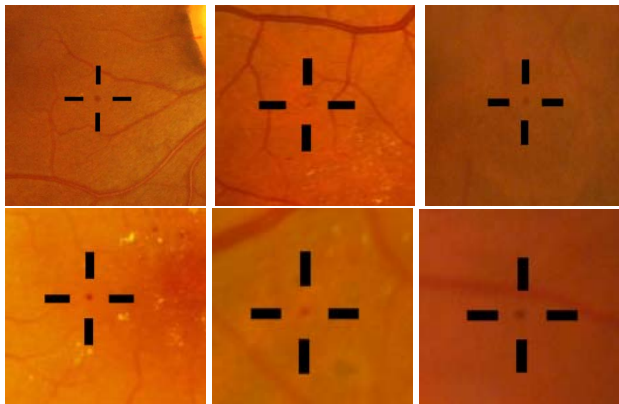


Figure 2. Image regions containing microaneurysms.

Based on the above observations, few desired characteristics of retinal image enhancement technique can be inferred.

- It is a low-level technique. The technique should not depend on high-level information such as knowledge of the location of the sub-parts of the retina. This is necessary because it is a preprocessing step which can influence the detection of the sub-parts of the retina.
- It should be performed without manual intervention.
- It should not change the basic characteristics of any anatomical structure or bright/dark lesions present in the retinal image.

Several techniques have been used to enhance retinal images. Histogram equalisation has been shown to be inappropriate for retinal images [10]. Unsharp masking-based enhancement is partly effective but is not capable of handling uneven illumination [10]. A local normalisation of each pixel to zero mean and unit variance aims to compensate lighting variation and enhancing local contrast but also introduces artifacts due to amplification of noise [10]. Enhancement using matched filters [1][6][9] improves local contrast and aids in vessel segmentation but does not preserve the fidelity of the image. It also affects other structures present in the image [10]. Histogram matching between the red and green planes has been used as a preprocessing step for vessel segmentation [12]. This improves the contrast of gross dark features like vessels but reduces the contrast of bright objects and tiny dark objects like MA. Slow variations of luminosity have been extracted via median (large) filtering and then subtracted from the observed

image [7] but it smooths brighter structure present in the image. Other methods estimate illumination function drift from segmented vessel pixels and use it for illumination correction [5][13]. These methods rely on vessel segmentation accuracy which is highly sensitive to the underlying luminosity and contrast of the image. A contourlet transform-based enhancement has also been proposed [10]. This does not produce satisfactory results in poor contrast regions of the retinal image.

Enhancement in all of the above mentioned methods has been motivated by automatic analysis where, to this day, only one colour (green) plane of the colour image is processed since it contains maximal information about structures of interest, compared to the red and blue planes [5][13]. Thus, enhancement performance is demonstrated by showing improvement in a *specific* task such as vessel/lesion segmentation from the green plane image. These methods have not been extended for colour retinal image enhancement which is essential to aid manual diagnosis which is currently used heavily in practice due to immaturity of automatic diagnosis methods. We argue that focus on colour image enhancement can also benefit automated analysis as vector processing techniques can then be employed.




Figure 3. (a) A region containing hemorrhage, (b) region after enhancement

There have been attempts to extend histogram equalisation designed for grayscale images to restore colour images [11]. In [11], a method is proposed to generate an almost uniform colour histogram, which however, would change the ratios of the RGB components and thus producing hue-shifting related artifacts [2] and introduces new colours to the objects in an image. This method was claimed to be more suitable for better visualisation of pseudo-colour scientific pictures than for ordinary image enhancement.

In order to avoid hue-shifting related artifacts, colour image enhancement methods were formulated in HSI colour space [11] [4]. In this, the hue plane is kept intact and image correction is independently applied to the intensity (I) and saturation (S) components of the retinal image. The enhanced intensity and saturation components are combined

with hue component and colour image is recovered in RGB colour space. This shows promising results and it has been compared with the proposed scheme in the later section.

A colour remapping scheme is suggested for colour retinal image enhancement[3]. It does luminosity and contrast enhancement on each colour plane of RGB colour space, independently. Later, they recover original chromatic distribution by identifying an overall image chromatic statistical distribution in the observed image. Figure 3 shows distortion introduced by this method [4] in a region containing large hemorrhage¹.

In this paper, we propose a solution for colour retinal image enhancement which is based on the knowledge of the retina geometry and imaging conditions. Specifically, we present (i) a novel enhancement method which uses a non-uniform sampling-based estimation of the degradation components and report on results of applying it to a single colour plane; (ii) a solution for colour image enhancement which combines (i) and a linear color remapping technique. In the following sections, we will present enhancement methods and performed experiments in detail.

2 Image Enhancement on a Given Colour Plane

Starting with a linear model of image formation, the relation between the true (ideal, uniform illumination) image $U(x, y)$ and observed image $I(x, y)$ can be written as:

$$I(x, y) = U(x, y) * S_M(x, y) + S_A(x, y) \quad (1)$$

where $S_M(x, y)$ is the multiplicative and $S_A(x, y)$ the additive component. Both S_A and S_M are generally assumed to be continuous and slowly varying functions. S_M and S_A represent the degradation components namely, the contrast and luminosity components of the image, respectively. This model does not incorporate blurring or additive noise.

The recovery of true image U is based on the estimation of S_A and S_M and the correction of the observed image I as:

$$U(x, y) = \frac{I(x, y) - S_A(x, y)}{S_M(x, y)} \quad (2)$$

In the retinal imaging scenario, the degradation functions have to be estimated from a given image. An understanding of the imaging mechanism is useful in the designing the estimation technique. The retina is a curved surface which is illuminated by a source of light located close to the pupil of the eye a few centimetres away. The camera, which is also locate close to the pupil, captures the reflected illumination from the retina. Due to this imaging geometry, the peripheral part of the retinal surface receives less illumination. Hence, the peripheral region appears darker than the central region of the retinal image.

¹The sample image regions are taken from [4].

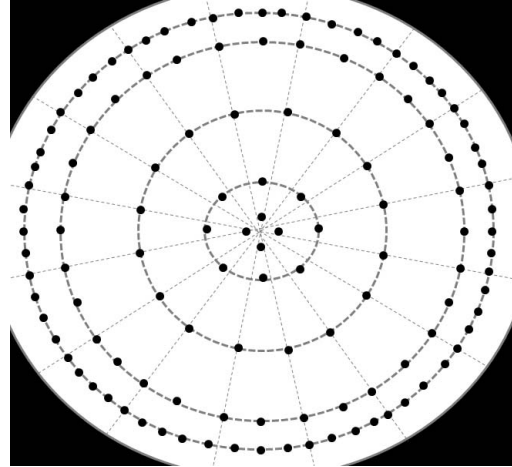


Figure 4. Non-uniform sampling used for estimation.

With the above in mind, we propose a *non-uniform* sampling scheme on a polar grid to estimate the degradation components for the acquired image. The sampling is coarse in the central region (well illuminated region) and dense in the periphery (poorly illuminated region). Thus, with the sampling points defined on a (r, θ) space, the sampling is non-uniform in both r and θ dimensions, as illustrated in fig. 4.

2.1 Estimation of S_A and S_M functions

In order to have an effective estimation, we follow the strategy of [3]. Here, the image (green channel) is separated into a set of background and foreground (made up of retinal structures of interest) pixels first. Next, the degradation components are estimated from the background image. This strategy is motivated by the fact that the retinal structures can bias the luminosity component. For instance, the optic disk (bright circular region on left in fig. 1) is a naturally high luminosity zone and the vessels (dark) are a low luminosity zone.

The background pixels are extracted from I using the local mean and standard deviation as follows:

1. For every point on the sampling grid compute the local mean μ and σ within a window of size $w \times w$.
2. Interpolate between the sampling points to obtain $\mu(x, y)$ and $\sigma(x, y)$ for all (x, y) .
3. Compute the Mahalanobis distance $D(x, y)$ as follows.

$$D(x, y) = \left| \frac{I(x, y) - \mu(x, y)}{\sigma(x, y)} \right| \quad (3)$$

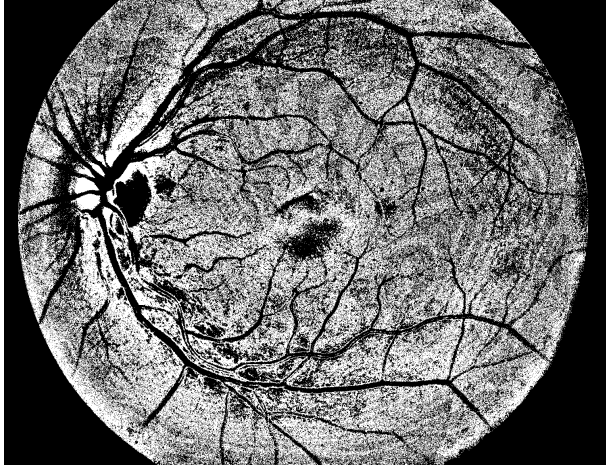

Figure 5. A background image for the image in fig 1. Black pixels belong to foreground and white pixels to background.

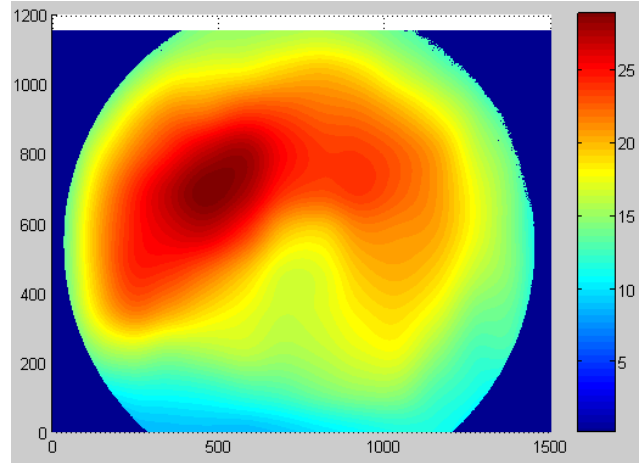
Given an image, a pixel is taken to belong to the background if $D(x, y) \leq t$ where t is a fixed threshold. Figure 5 shows a computed background image on the green plane of the image in fig. 1. The degradation components are estimated from the background image by computing the local mean and the standard deviation values at every point (x, y) , within a window of size $(w_0 \times w_0)$. The desired contrast component S_M is nothing but the standard deviation and the luminosity component is S_A .

In our experiments, bilinear interpolation was used in step 2 and w_0 was set to 50, $t = 1$ and a large enough window size ($w = 125$) was chosen to include retinal structures as well as the background. A sample estimated S_A and S_M functions are shown in fig. 6.

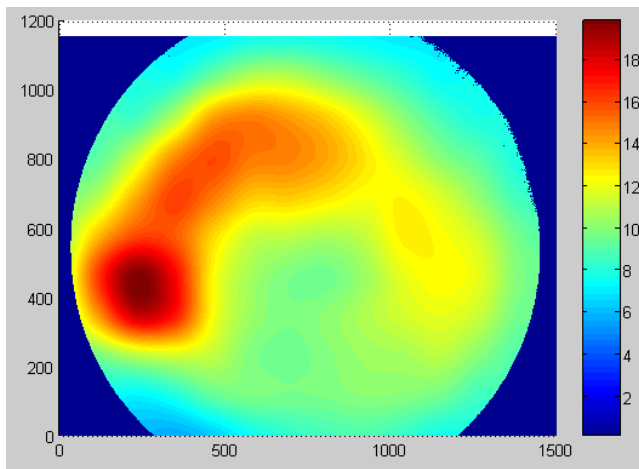
Finally, the true image $U(x, y)$ is obtained by applying the point transformation (equation 2) to each pixel of the image. A sample result of applying the proposed method is shown in fig. 7(f). The enhanced image has good luminosity and different retinal structures are contrasted well against the background.

2.2 Strengths of the proposed method

The proposed technique differs from the method in [3] which results in some advantages. The approach in [3] uses a square sampling grid and determines local (over a $w \times w$ neighbourhood) mean and variance. Since w is taken to be the sampling interval, the computation of background thus uses contiguous windows on the given image. The value of w impacts on the success of the background/foreground separation. A small w will lead to inability to discriminate between retinal structures and background, thus result in a



(a)



(b)

Figure 6. Estimated functions (a) S_A and (b) S_M for the image in fig 1.

poor background image. A large w leads to fewer samples and hence an imprecise background determination.

Our proposed non-uniform sampling technique addresses this problem very effectively. Firstly, it permits taking differential number of samples in different regions of the retina which is desirable, given the imaging geometry. Secondly, once a non-uniform sampling pattern is fixed, a window size w can also be fixed to result in computation in overlapping windows over the peripheral region and contiguous windows in the centre, which is not possible in a uniform grid.

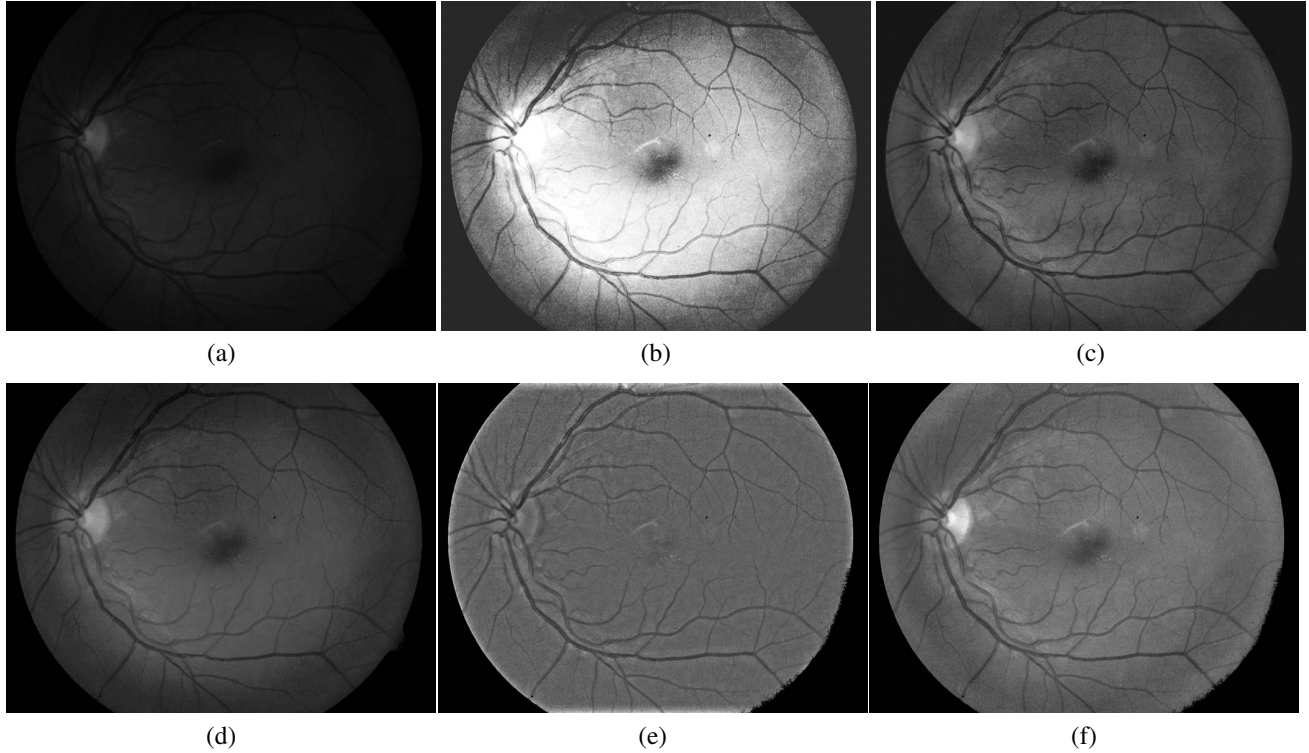


Figure 7. (a) Input image; Image enhancement results obtained from (b) global histogram equalisation, (c) local histogram equalisation, (d) adaptive correction using red colour channel [12], (e) low-pass subtraction: standard correction method used for retinal image [7] and (f) proposed method

3 Colour Retinal Image Enhancement

We propose a colour remapping process for retinal colour enhancement images which is based on the chromatic information of the original image. Given a colour image with colour components (r, g, b) or (h, s, v) , the single plane correction described in section 2 is applied to the g plane and g_{corr} is obtained. Next the enhanced colour image $(\hat{r}, \hat{g}, \hat{b})$ is computed as :

$$\hat{r} = \frac{g_{corr}}{v} * r, \quad \hat{g} = \frac{g_{corr}}{v} * g, \quad \hat{b} = \frac{g_{corr}}{v} * b, \quad (4)$$

Since, $v = \max[r, g, b]$, it plays a normalisation role in the enhancement. Thus, the ratio of the original r, g and b is maintained in the above linear color remapping and the chromatic content in the original image is preserved in the enhanced color image. Figure 8(d) shows the enhanced colour retinal image by the proposed remapping technique. It can be seen that a good contrast and uniform illumination is obtained and colour distribution is also well preserved.

4 Experimentation Results

For all our experiments, we have used a public retinal image database aimed for benchmarking diabetic retinopathy detection from digital images [8]. Images were captured using the 50 degree field-of-view digital fundus camera with varying imaging settings. This dataset corresponds to a good practical situation and consists of total 89 digital retinal images.

The single plane enhancement method presented in section 2 was applied to green plane images and compared against existing retinal image enhancement techniques. Figure 7 shows results obtained from the different techniques. It can be seen that proposed method gives better visual quality of the enhanced image while keeping good contrast of retinal structures. Other methods including local (adaptive) and global ones either fail in the enhancement or affect contrast of retinal structures. For instance, optic disk (bright circular region in left) is smoothed by method [7] (shown in fig. 7(e)) and by local histogram equalisation (shown in fig. 7(c)).

Next, we present results of evaluating the proposed

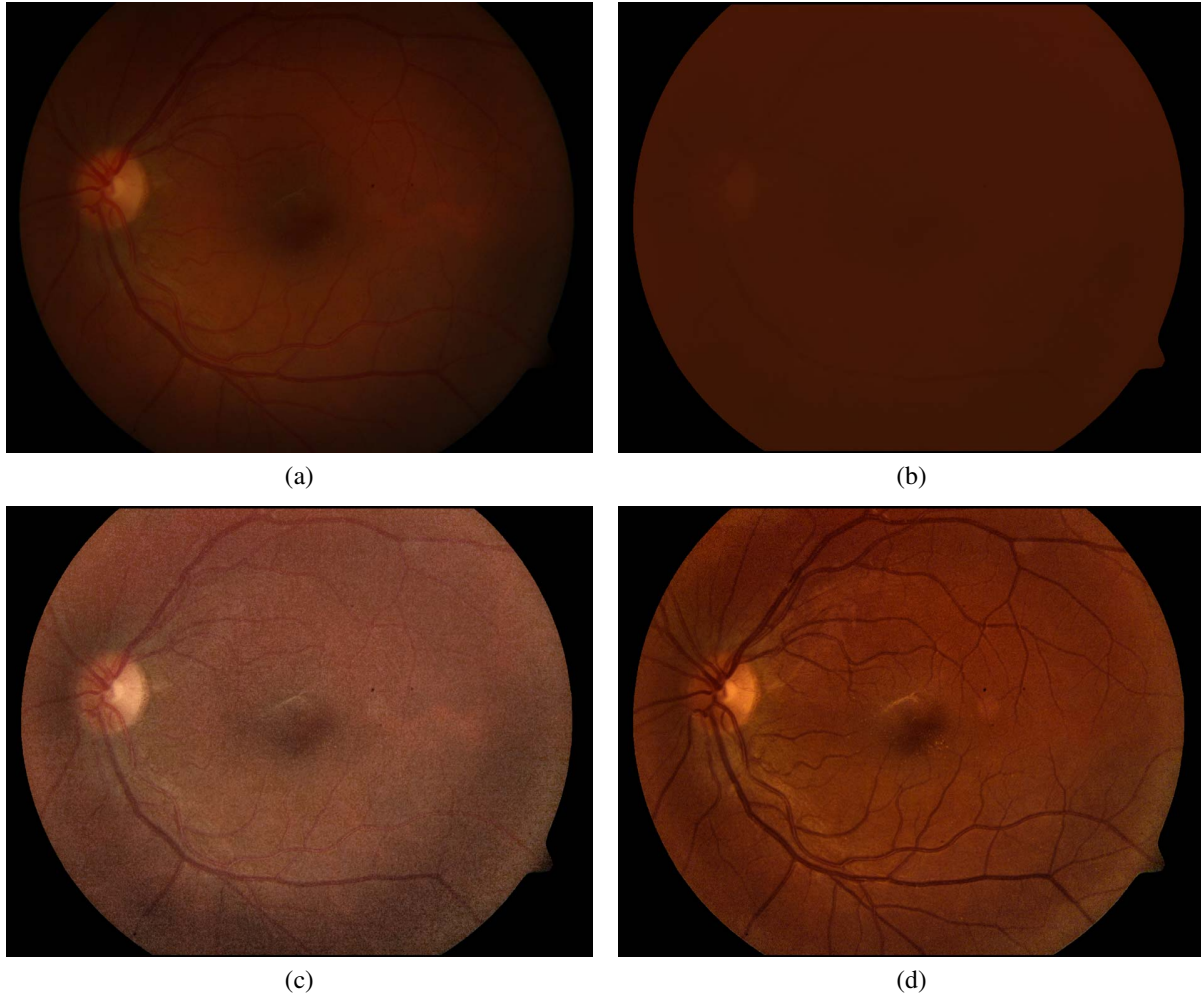


Figure 8. Comparison of colour enhancement methods on (a) test input image. Results obtained from (b) method proposed in [3], (c) method performing enhancement on saturation and intensity of HSI colour space, and (d) proposed method.

colour enhancement scheme (section3) against some existing schemes. Sample results are in Figure 8. In the method presented in [4] and [11], the hue plane is kept intact and image enhancement is performed independently on the intensity (I) and saturation (S) components of the HSI space. The enhanced intensity and saturation components are later combined with original hue component and colour image is recovered in RGB colour space. The obtained results are shown in fig.8(c). It can be seen that the resulting colour image maintains the visual appearance of retinal structures but compromised contrast of the retinal structures. This is mainly due to the inclusion of the I component in the correction process. Furthermore, the output image does not preserve the original colour distribution.

Next, we have tested the colour enhancement method

suggested in [3]. In our implementation, an identical enhancement technique is applied to all the three (r, g, b) channels separately. Given an image plane I_x of image I , enhanced image I_x^{corr} is obtained using method presented in section 2. To preserve the original chromatic distribution, a normalisation step is performed on I_x^{corr} suggested in [3] as follows: $\hat{I}_x^{corr} = I_x^{corr} * \sigma_x + \mu_x$. Where, μ_x and σ_x are the mean and standard deviation of the observed image I_x , respectively. The colour output shown in fig. 8(b), is obtained by applying above procedure on each r, g, b plane. Though, the original colour distribution appears to be preserved, the overall contrast in the colour image gets reduced due to colour normalisation.

Our proposed colour enhancement scheme on the other hand, preserves the colour distribution and improves the

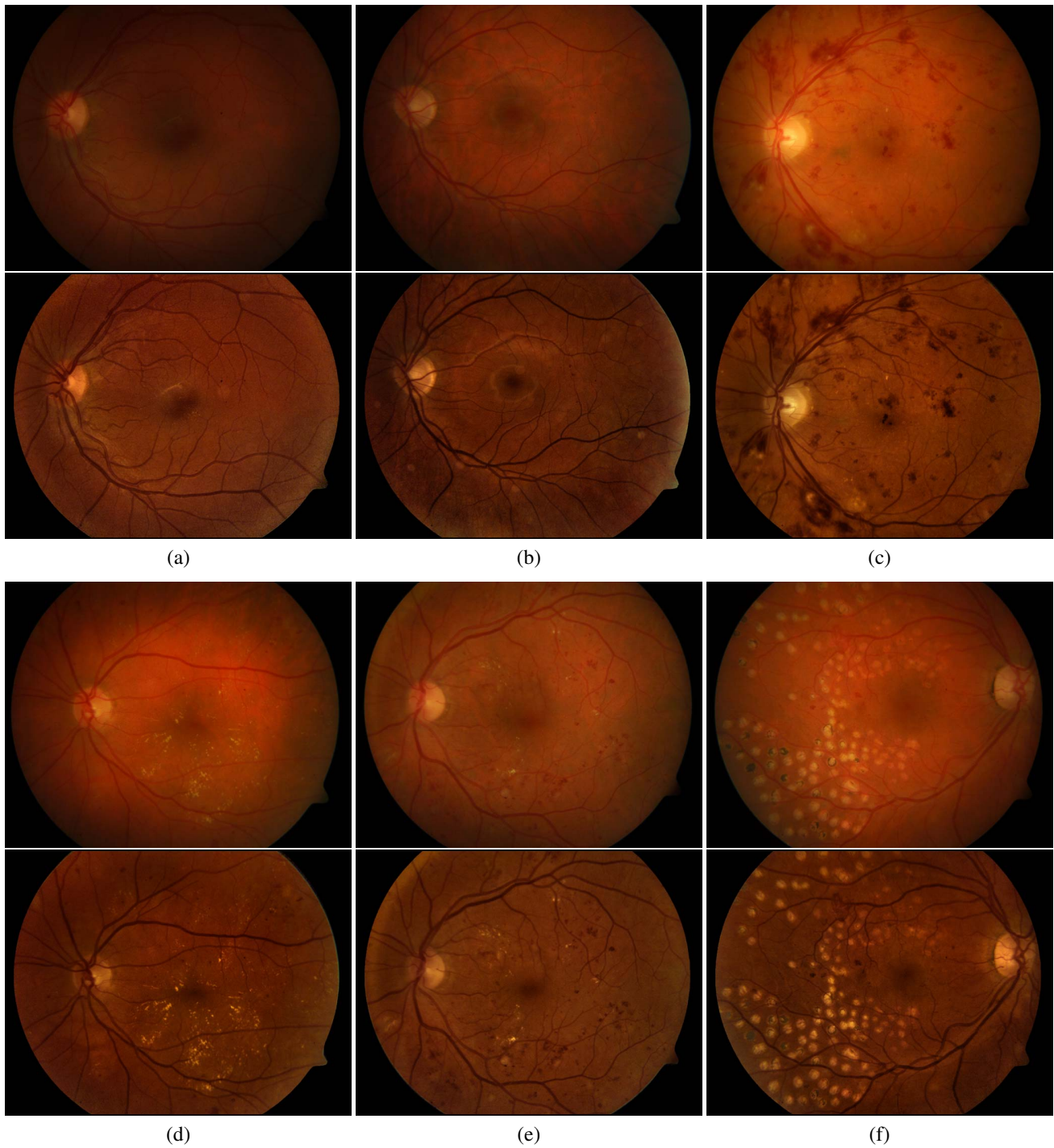


Figure 9. Results on a set of test images using proposed method. The odd rows show the test image and even rows show their corresponding enhanced colour image.

overall contrast in the output image shown in Figure 8(d). Additional results are shown in fig. 9.

Next, we have evaluated the effect of enhancement on the dark and bright lesions present in a retinal image. Figure 10 shows the subimages containing the lesions and the processed results. It can be seen that proposed method is able to retain large dark lesion (fig. 10(a)) which was getting smoothed in [3]. No artifacts have also been introduced. In fact, the proposed method significantly enhances the contrast of the lesion against the background. For instance, the tiny MA and small yellowish regions (fig. 10(b)) are visible due to the improved contrast as compared to the original image. It can however be noted that the colour has shifted on this image. This effect was noted to occur only when the red content in the input image was dominant.

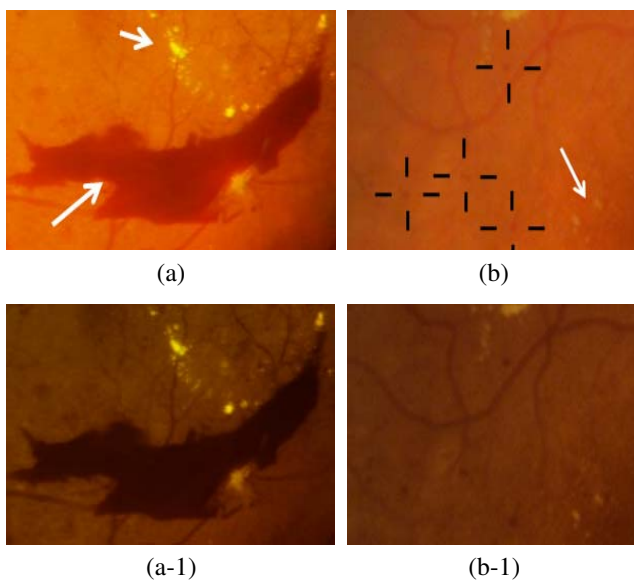


Figure 10. First row shows sample region image regions and second row shows corresponding results obtained from the proposed method.

5 Conclusion

In retinal images, vascular topography, dark and bright pathology (subtle or otherwise) are mainly of interest. In this paper, we presented a method for colour retinal image enhancement which is based on the knowledge of the retina geometry and imaging conditions. The method determines a correction factor using a single plane and then applies a normalised correction to all three (r, g, b) planes. The correction factor is found using a non-uniform sampling-based estimation of the degradation components. The re-

sults of testing the proposed colour enhancement method on 89 colour images show that it is able to improve the overall contrast and correct for non-uniform illumination successfully. There is a minimal shift in the colour content and no new artifacts are introduced. All of these features are attractive in applications which require manual as well as automatic examination of colour retinal images.

References

- [1] S. Chaudhuri, S. Chatterjee, and N. Katz. Detection of blood vessels in retinal images using two-dimensional matched filters. *IEEE Trans. Med. Imaging*, 3(8):263–269, 1989.
- [2] J. Duan and G. Qiu. Novel histogram processing for colour image enhancement. *Proc. Int. Conf. Image and Graphics*, pages 55–58, 2004.
- [3] M. Foracchia, E. Grisan, and A. Ruggeri. Luminosity and contrast normalization in retinal images. *Medical Image Analysis*, 3(9):179–190, 2005.
- [4] E. Grisan, A. Giani, E. Ceseracciu, and A. Ruggeri. Model-based illumination correction in retinal images. *IEEE Int. Symp. Biomedical Imaging: Nano to Macro*, pages 984–987, 2006.
- [5] A. Hoover. Equalizing illumination in a retinal image using blood vessels as a reference. *Technical Report:URL <http://www.parl.clemson.edu/stare/eq/>*.
- [6] A. Hoover, V. Kouznetsova, and M. Goldbaum. Locating blood vessels in retinal images by piecewise threshold probing of a matched filter response. *IEEE Trans. Med. Imaging*, 3(19):203–210, 2000.
- [7] G. ien and P. Osnes. Diabetic retinopathy: automatic detection of early symptoms from retinal images. *Proc. Norwegian Signal Processing Society Symposium(NORSIG)*, 1995.
- [8] T. Kauppi, V. Kalesnykiene, J. Kmrinen, L. Lensu, I. Sorri, A. Raninen, R. Voutilainen, H. Uusitalo, H. Klvinen, and J. Pietil. Diaretdb1 diabetic retinopathy database and evaluation protocol. *Proc. Medical Image Understanding and Analysis (MIUA)*, pages 61–65, 2007.
- [9] T. S. Lin, M. H. Du, and J. T. Xu. The preprocessing of subtraction and the enhancement for biomedical image of retinal blood vessels. *Journal of Biomedical Engg.*, 1(20):56–59, 2003.
- [10] P.Feng, Y. Pan, B. Wei, W. Jin, and D. Mi. Enhancing retinal image by the contourlet transform. *Pattern Recognition Letters*, 4(28):516–522, 2007.
- [11] E. Pichon, M. Niethammer, and G. Sapiro. Color histogram equalization through mesh deformation. *Proc. Int. Conf. Image Processing*, (2):117–120, 2003.
- [12] N. M. Salem and A. K. Nandi. Novel and adaptive contribution of the red channel in pre-processing of colour fundus images. *Journal of the Franklin Institute*, (344):243–256, 2007.
- [13] Y. Wang, W. Tsu, and S. Lee. Illumination normalization of retinal images using sampling and interpolation. *Proc. SPIE, Medical Imaging*, pages 500–507, 2001.