

Linköping University Medical Dissertations

No. 1262

Treatment of Epicondylalgia and Nerve Entrapments around the Elbow

Birgitta Svernlöv



Linköping University
FACULTY OF HEALTH SCIENCES

Linköping University, Faculty of Health Sciences
Department of Clinical and Experimental Medicine
Division of Surgery and Clinical Oncology
SE-581 85 Linköping, Sweden

Linköping 2012

© Birgitta Svernlöv, 2012

Cover: Detail from a painting by Nicolas Poussin (1594-1665) called “Et in Arcadia ego”, the Louvre Museum (Paris, France).

Previously published articles have been reprinted with the permission of the copyright holders.

Printed in Sweden by LiU-Tryck, Linköping, Sweden 2011

ISBN: 978-91-7393-065-9

ISSN: 0345-0082

*To unpathed waters, undreamed shores; A
Winter's Tale (W. Shakespeare 1564-1616)*

*Our doubts are traitors, and make us lose the
good we oft might win, by fearing to attempt;
Measure for Measure (W. Shakespeare 1564-
1616)*

CONTENTS

ABSTRACT

ABBREVIATIONS

LIST OF PAPERS

INTRODUCTION	1
HISTORY	1
BACKGROUND	4
ANATOMY	6
The lateral epicondyle.....	6
The medial epicondyle.....	7
EPICONDYLALGIA	9
Epidemiology and pathomechanics	9
Diagnosis	12
TREATMENT METHODS	15
Natural course	15
Conservative management	16
Eccentric (strengthening) exercise	16
<i>Eccentric exercises and stretching</i>	18
<i>Stretching</i>	19
Surgery	19
COMPRESSIVE OR ENTRAPMENT NEUROPATHIES AROUND THE ELBOW ..	21
Epidemiology and pathomechanics	21
<i>Radial tunnel syndrome (RTS)</i>	21
<i>Pronator syndrome (PS)</i>	22
<i>Cubital tunnel syndrome (CuTS)</i>	22
Diagnosis	23
<i>Radial tunnel syndrome</i>	23
<i>Pronator syndrome</i>	24
<i>Cubital tunnel syndrome</i>	26
TREATMENT METHODS	27
Conservative management	27
<i>Radial tunnel syndrome</i>	27
<i>Pronator syndrome</i>	27
<i>Cubital tunnel syndrome</i>	27
Surgery	28
<i>Radial tunnel syndrome</i>	28
<i>Pronator syndrome</i>	29
<i>Cubital tunnel syndrome</i>	29
METHODS FOR ASSESSMENTS OF OUTCOME	30
Neurophysiological investigations.....	30
Visual analogue scale (VAS)	30

CONTENTS

Jamar dynamometer	32
Manual muscle testing (MMT) and digital dynamometer	33
Ordinal scales.....	34
The Verhaar score.....	35
The Disability of Arm, Shoulder and Hand Questionnaire (DASH)	35
The patient-rated elbow evaluation questionnaire (PREE).....	36
The American Shoulder and Elbow Surgeons-Elbow (ASES-E)	36
The Mayo elbow performance index (MEPI)	36
The Canadian Occupational Performance Measure (COPM).....	37
The Mos 36-Item Short-Form Health Survey (SF-36)	37
Measurement of health-related quality of life (EUROQUAL)	37
AIMS OF THE THESIS.....	39
GENERAL AIM.....	39
SPECIFIC AIMS:	39
SUMMARY OF STUDIES I - V	40
Ethics	40
PATIENTS	40
Paper I	40
Paper II.....	42
Paper III.....	43
Paper IV	44
Paper V	45
METHODS OF TREATMENT	45
Paper I	45
Paper II.....	48
Paper III.....	48
Paper IV	49
Paper V	49
METHODS FOR ASSESSMENTS OF OUTCOME.....	51
Evaluation of pain.....	51
Evaluation of grip and finger adduction strength.....	51
Evaluation of treatment for tennis elbow.....	52
Self-assessed evaluation of the arm, shoulder and hand function.....	52
Motor and sensory nerve conduction velocities and electromyography.....	52
Self-perceived occupational performance and satisfaction	52
Self-perceived evaluation- change of symptoms.....	52
Self-perceived evaluation - satisfaction	53
Self-perceived evaluation - repeat surgery.....	53
STATISTICAL METHODS IN PAPERS	53
RESULTS	54
Paper I	54
Paper II.....	55
Paper III.....	55
Paper IV	56
Paper V	57

GENERAL DISCUSSION	61
OUTCOME MEASUREMENTS AND INTERPRETATION OF RESULTS	61
CAN ECCENTRIC EXERCISES REDUCE PAIN AND INCREASE GRIP STRENGTH (IN PATIENTS WITH EPICONDYLALGIA)?	63
CAN SURGERY HELP PATIENTS WITH CHRONIC LATERAL EPICONDYLALGIA?	64
CAN CONSERVATIVE TREATMENT IMPROVE CUBITAL TUNNEL SYNDROME?	65
IS SURGERY FOR NERVE ENTRAPMENT IN THE FOREARM AN OPTION WHEN CONSERVATIVE TREATMENT FAILS?	67
TREATMENT STRATEGIES FOR EPICONDYLALGIA	68
TREATMENT STRATEGIES FOR NERVE ENTRAPMENTS	69
CONCLUSIONS	70
FUTURE RESEARCH	71
SAMMANSTÄLLNING PÅ SVENSKA	72
ACKNOWLEDGEMENTS	73
REFERENCES	75

ABSTRACT

Disorders causing pain in the elbow region is a common problem and is one of the most frequent forms of work-related health problems. These conditions are thus of major importance from the public health point of view, as well as from that of the suffering individual. Both sensory and motor function may be impaired, particularly in cases where a nerve is involved, resulting in severely impaired hand function.

"Tennis elbow" (lateral epicondylalgia) has been found to be the second most frequently diagnosed musculoskeletal disorder of the upper extremity in the primary health-care setting. "Golfer's elbow" (medial epicondylalgia) is not that commonly encountered. It has been stated that tennis or golfer's elbow syndromes are self-limiting. Even so, clinical experience has shown that there are a few cases where symptoms have a painful and long-lasting course, resistant to many forms of therapy. The outcomes of frequently adopted management regimes for treatment of epicondylalgia or nerve entrapments around the elbow were examined in the following five studies:

I: A randomised, prospective study of 38 patients with tennis elbow (lateral epicondylalgia). Groups were assigned to eccentric exercises or stretching. Eccentric exercise gave somewhat better results.

In a second part of the study, a 4-year follow-up of 127 patients who used eccentric exercises for tennis elbow was performed. Patients showed decreased pain and increased grip-strength after 3 months treatment. At the time of publication this study was the first to examine eccentric exercises for this condition.

II: A retrospective analysis of long-term results from 51 patients treated with surgical release of the common extensor origin because of "chronic tennis elbow". Eighty-seven per cent of the patients rated themselves as completely recovered or improved.

III: A randomised, prospective study of 70 patients with ulnar neuropathy in the forearm (cubital tunnel syndrome). Groups assigned the commonly recommended elbow brace at night or nerve gliding exercises were compared with a control group (information only). The majority of patients improved considerably, both subjectively and objectively, after a 3 months period, regardless of group. The study thus showed the effectiveness of information and expectance, and that orthosis or nerve gliding exercises added nothing further to the result.

IV: A retrospective study of 205 patients treated with surgery for suspected nerve entrapment in the forearm. Follow-up, almost 4 years later, demonstrated a subjective improvement in two of three patients, but only 3% experienced complete relief of all symptoms.

V: A prospective long-term study on 20 patients with golfer's elbow (medial epicondylalgia) treated with eccentric exercises over 3 months. The results showed decreased pain and increased grip-strength. This is the first study published on the management of this disorder with eccentric exercises.

ABBREVIATIONS

ASES-E	The American Shoulder and Elbow Surgeons -Elbow
CEO	Common extensor origin
COPM	The Canadian Occupational Performance Measure
CuTS	Cubital tunnel syndrome
DASH	The Disability of Arm, Shoulder and Hand Questionnaire
ECRB	Extensor carpi radialis brevis
ECRL	Extensor carpi radialis longus
ECU	Extensor carpi ulnaris
EDC	Extensor digitorum communis
EDM	Extensor digiti minimi
EMG	Electromyography
ES	Eccentric strengthening
EUROQUAL	Health-related quality of life measurement
FCR	Flexor carpi radialis
FCU	Flexor carpi ulnaris
FDP	Flexor digitorum profundus
FDS	Flexor digitorum superficialis
GE	Golfers' elbow
LE	Lateral epicondylalgia
ME	Medial epicondylalgia
MEPI	The Mayo elbow performance index
MMT	Manual muscle testing
NCV	Nerve conduction velocities
NSAID	Non-steroidal anti-inflammatory drugs
PL	Palmaris longus
PREE	Patient-rated elbow evaluation
PS	Pronator syndrome
PT	Pronator teres
RCT	Randomised controlled trial
RTS	Radial tunnel syndrome
SF-36	The MOS 36-Item Short-Form Health Survey
TE	Tennis elbow
VAS	Visual analogue scale

LIST OF PAPERS

This thesis is based on the following papers. They will be referred to by their roman numerals.

- I. *Non-operative treatment regime including eccentric training for lateral humeral epicondylalgia.*
B. Svernlöv, L. Adolfsson. *Scand J Med Sci Sports*. 2001. Dec: 11(6): 328-334
- II. *Outcome of release of the lateral extensor muscle origin for epicondylitis.*
B. Svernlöv, L. Adolfsson . *Scand J Plast Reconstr Surg Hand Surg*. 2006. 40 (3): 161- 5
- III. *Conservative treatment of the cubital tunnel syndrome.*
B. Svernlöv, M. Larsson, K. Rehn and L. Adolfsson. *J Hand Surg Eur Vol*. 2009. 34 (2): 201-7
- IV. *Patient-reported outcome of surgical treatment of nerve entrapments in the proximal forearm*
B. Svernlöv, G. Nylander and L.Adolfsson. *Adv Orthop* 2011;

Epub 2011 Sep 11
- V. *Medial epicondylalgia (golfer's elbow) treated with eccentric exercises.*

Birgitta Svernlöv, Eva Hultgren, Lars Adolfsson. *Shoulder & Elbow*.
Article first published online: 7 OCT 2011

INTRODUCTION

"What's in a name?" Romeo and Juliet
(W. Shakespeare 1564-1616)

HISTORY

In 1830 Renton reported on a patient that suffered from pain along the outer forearm, which increased on using the hand. This is probably the first description of a condition that might have been what later became referred to as "tennis elbow" (TE). A more detailed description of pain around the lateral humeral epicondyle was later published by the German physician Runge in 1873, who called the condition "writers cramp", which he attributed to a periostitis on the lateral humeral epicondyle. Lateral elbow pain has since been given many different names such as "tennis arm", the name derived from "lawn-tennis arm" described by Morris in 1882, an activity that precipitated his own painful elbow condition. Major (1883), in his paper "Lawn-tennis Elbow", considered the pathology to be located in the 'annular ligament around the head of the radius and the triceps'. Winkworth (1883) disagreed with Morris and Major, arguing that a sprain could not account for all symptoms. He proposed, instead, that it was a nerve entrapment that caused the pain of "lawn-tennis elbow". In particular he named the posterior interosseous nerve as it passes "through the substance of the supinator brevis muscle" and the median nerve as it passes between the two heads of the pronator radii teres muscle (Thurston, 1998a).

Remak (1894) and Bernhardt (1896) were of the opinion that the problem was a periosteal tear due to occupational overuse of the extensor muscles arising from the lateral condyle. Couderc (1896) called the condition "ruptured epicondylar tendon", Fe're' (1897) "epicondylalgia", and Franke (1910) "epicondylitis" (Cyriax, 1936). The name 'tennis elbow' was subsequently replaced by the idiom "epicondylitis" after a proposition by Cyriax in 1936, implying an inflammatory cause. In 2005 the term

epicondylalgia (suffix *algia* means *pain*) was revived by Waugh (2005), since this does not imply any underlying pathology. Advocates of the term *epicondylalgia* embrace the theory that this is a complex condition with presumably several pathophysiologic mechanisms and underlying causes of pain (Waugh, 2005).

“Golfer’s elbow” (GE) is another umbrella term coined to describe medial or ulnar elbow pain when flexing the wrist and hand, which is acquired from such activities as grasping, clutching, and typing. The name GE emerged from the supposition that the muscles and tendons required to hit a golf ball are the same as the ones used in the above-mentioned activities. Medial epicondylitis, another incorrect denomination, was first described in 1883 by Morris. He put forward the idea that medial epicondylitis was elicited by the backstroke in lawn- tennis, causing a sprain of the musculus pronator radii teres and the fascia and intermuscular septum on the inner side of the humerus (Thurston, 1998a). Later research has greatly expanded our understanding of both the location and the aetiology of this condition (Jobe and Ciccotti, 1994).

The term GE was not included in the discussion of medial and lateral epicondylitis in 1925, but Cyriax mentioned this condition without describing its origin. In many orthopaedic standard texts epicondylitis humeri ulnaris is mentioned only very briefly or in a subordinate paragraph as a variant of epicondylitis humeri radialis (Cyriax, 1982; O’Dwyer and Howie, 1995; Kritschek et al., 1999).

Radial tunnel syndrome (RTS) was first described by Winkworth (1883) who called the disorder “radial neuritis” (Thurston, 1998a). Roles and Maudsley suggested, in 1972, that entrapment of the posterior interosseous nerve (PIN) in a musculo-aponeurotic space extending from the lateral epicondyle of the humerus to the distal edge of the supinator muscle produced aching discomfort or pain around the elbow and proximal lateral forearm without motor findings. This disorder is often diagnosed as refractory tennis elbow (Dawson et al., 1983; Lee et al., 2008).

Struther, in 1848, was the first person to describe median nerve entrapment by a structure, a fibrous band, connecting a supracondylar process with the medial

epicondyle (the ligament of Struther) but the pronator syndrome (PS) was first described by Seyffarth in 1951 (Dang et al., 2009).

Until the late 1800s, few reports were published with regard to ulnar neuritis and especially its surgical treatment. For many authors, the history of ulnar nerve compression at the elbow began in 1878 when Fèvre reported a remarkable treatment for ulnar palsy, decompression of the nerve referred to as “liberation of the nerve”. Poncet (1888) published the first description of the surgical treatment of ulnar nerve dislocation from the sulcus nervus ulnaris. He created a deeper sulcus at the original location, placed the ulnar nerve in it, and sutured the periosteum over the nerve to create a roof over the tunnel. In 1898 Curtis reported for the first time a technique that today is called anterior subcutaneous transposition. This description is important in modern surgery for ulnar neuropathy (Bartels, 2001). The first time the cubital tunnel syndrome is mentioned is in 1958, when Feindel and Stratford, as a result of surgical findings, reassessed the anatomical factors involved in ulnar palsy.

BACKGROUND

*"Our bodies are our gardens to which our wills are gardeners";
Othello, The Moore of Venice (W. Shakespeare 1564-1616)*

Pain around the humeral epicondyles is a common clinical problem. According to some, pain is more than twice as common on the lateral as on the medial side of the elbow (Kamien, 1988; Hume et al., 2006). Others have found lateral epicondylalgia to be seven to ten times more frequent than medial epicondylalgia (Leach and Miller, 1987; Ciccotti et al., 2004; Rineer and Ruch, 2009). Lateral epicondylalgia (LE) is the most common diagnosis made in patients with elbow lesions and overuse injuries of the elbow (Vicenzino et al., 1996; Thurston, 1998a; Boyer and Hastings, 1999; Hong et al., 2004; Radpasand, 2009) and has been found to be the second most frequently diagnosed musculoskeletal disorder of the upper extremity in the primary health-care setting (Ekberg et al., 1994).

Epicondylalgia refers to elbow pain at either the medial or lateral humeral epicondyle of the elbow related to the common flexor-pronator or extensor tendon origins, respectively, at these points. There are several terms used interchangeably, and sometimes incorrectly, in the literature to describe epicondylar inflections such as: epicondylitis (implying an inflammatory cause); epicondylosis (involving a degenerative source); and epicondylalgia (explained above). Most authors, however, have used the terms epicondylitis or tennis elbow (TE) (Thurston, 1998a; DeSmedt et al., 1998). Kraushaar and Nirschl (1999) proposed the aetiology of TE to be a cellular response to internal micro-tears leading to tendinosis, and suggested four stages of repetitive micro-trauma:

Stage 1: distinct injury with a probable normal inflammatory response and likely resolution – this stage corresponds to epicondylitis.

Stage 2: tendon injury from repetitive micro-trauma, corresponding to epicondylosis.

Stage 3: a partial tear of the tendon plus fibrosis, tendinosis and calcification, corresponding to epicondylalgia.

Stage 4 is a continuation of Stage 3 but with complete tear of the tendon.

Most patients in published articles have been diagnosed with epicondylalgia in the chronic stage, i.e. duration of pain and discomfort longer than 3 months (Zeisig, 2008) possibly corresponding to Stage 2 in the description above. In the text that follows, the term 'epicondylalgia' is used whenever applicable, regardless of the term used by the original author.

The symptoms are usually associated with grasping, resisted wrist extension and certain activities such as in tennis and golf, hence the common terms "tennis elbow" corresponding to LE, and "golfer's elbow" corresponding to ME. Despite the label TE, tennis is the probable cause in only 5% of people with LE (Murtagh, 1988; Buchbinder et al., 2008). Kohn (1996) found that elbow problems in golfers occurred in 24% of amateurs and approximately 4% of professionals. Although the term GE has historically described ME, the more frequent problem in golfers is actually LE. McCarroll and colleagues (1990) found that lateral elbow pain was five times more common than medial pain in amateur golfers. Lateral epicondylalgia most often occurs in the left elbow of a right-handed golfer (Stockard, 2001). Chronic lateral epicondylalgia is usually accompanied with more pain and muscle function impairment of the arm, than the chronic medial counterpart (Pienimäki et al., 2002; Hume et al., 2006).

Pain around the humeral epicondyles of the elbow may also be caused by nerve entrapment, which is clinically difficult to distinguish from the more common musculoskeletal disorders. These may also co-exist, which makes diagnosis even more difficult (Spinner and Amadio, 2003; Andreisek et al., 2006). Compression neuropathy of the radial, median, and ulnar nerves in the region of the elbow is a frequent cause of pain and weakness as well as sensory complaints (Hume et al., 2006; Posner, 1990). These nerves are intimately associated with the elbow and innervate the muscles responsible for wrist and finger function. Lateral elbow pain or

“refractory tennis elbow” may be due to radial nerve entrapment which may give rise to symptoms similar to LE, and median as well as ulnar nerve compression may mimic ME, making diagnosis difficult (Spinner and Amadio, 2003; Stanley, 2006; Tsai and Steinberg, 2008).

An array of assessment and diagnostic tools has been suggested to assist clinicians in their complete evaluation of the patient to ensure correct diagnosis and the appropriate conservative or surgical management strategy (Hume et al., 2006).

ANATOMY

The lateral epicondyle

The extensor carpi radialis brevis (ECRB), extensor digitorum communis (EDC), and extensor carpi ulnaris (ECU) form a strong, conjoined tendon inserting at the anterior aspect of the lateral humeral epicondyle and lateral supracondylar ridge, adjacent to the origin of extensor carpi radialis longus (ECRL). The lateral epicondyle is also the site of origin for parts of the supinator and extensor digiti minimi (EDM), which merge with ECRB, EDC, and ECU to form the common extensor origin (CEO). The ECRB inserts at the base of the third metacarpal bone, and the ECRL inserts at the base of the second metacarpal bone (Walz et al., 2010).

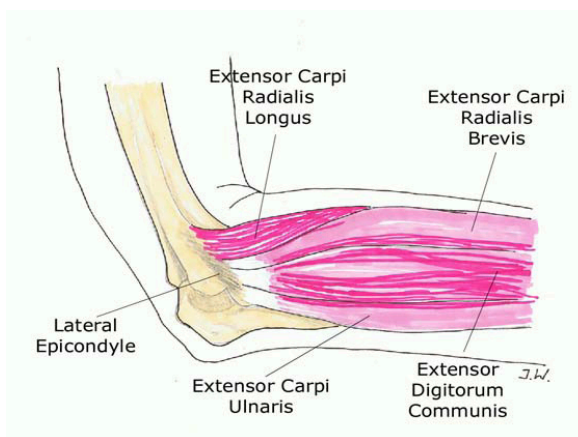


Figure1. The lateral epicondyle with the ECRL and part of the common extensor origin

Innervations

The radial nerve is comprised of fibres from C5, C7, C8 and T 1. In the upper arm, the nerve supplies the triceps and the anconeus muscles and in the forearm, the supinator muscle, and the extensors to the wrist, fingers and thumb. Small nerve branches innervate parts of the elbow joint capsule. The superficial branch of the nerve exits from under the brachioradialis tendon and supplies a cutaneous area on the dorsum of the hand on the radial side, overlying the area between the thumb, index, and middle fingers. The terminal branch of the posterior interosseous nerve supplies pain and proprioceptive fibers to the dorsum of the wrist joint (Andreisek et al., 2006; Stanley, 2006).

The sensory innervations at the origin of the ECRB muscle is not fully known, but sympathetic innervations have been observed in the muscle origin at the lateral epicondyle, specifically associated with some of the arteries, while no evidence for parasympathetic innervations has been found (Ljung et al., 1999b).

The medial epicondyle

The superficial forearm flexor muscles originate from a common tendon at the medial epicondyle of the humerus. The muscles of the flexor-pronator group include the pronator teres (PT), flexor carpi radialis (FCR), palmaris longus (PL), flexor digitorum superficialis (FDS), and flexor carpi ulnaris (FCU). Flexor carpi radialis (FCR), PL, and FCU form the common flexor tendon (Pilgian et al., 2000).

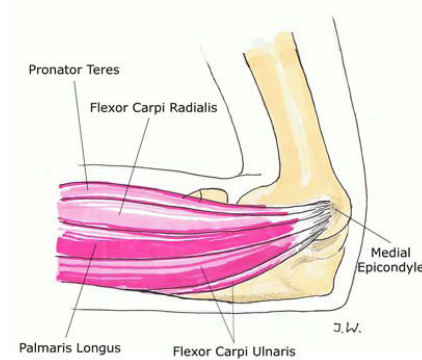


Figure 2. The medial epicondyle with PT and the common flexor origin.

Innervations

The median nerve is comprised of fibres from C6 through C8, and T1 and is distributed to the medial epicondylar muscles by two branches for PT, a common trunk for FCR and PL, and one branch for the FDS. When traversing the elbow joint the nerve gives off small branches that, together with twigs from the musculocutaneous nerve, innervate the ventral aspect of the joint capsule.

The ulnar nerve originates from the inferior roots of the brachial plexus (C8-T1). The nerve passes posterior to the medial epicondyle in the cubital tunnel and is distributed to the medial epicondylar muscles FCU, and the ulnar half of flexor digitorum profundus (FDP). The nerve then passes between the 2 heads of the FCU muscle to enter the anterior compartment. It descends the forearm on the anterior surface of the FDP to the volar aspect of the wrist. The ulnar nerve gives off branches for skin sensation in the area around the medial epicondyle and a few small branches innervating the medial portion of the joint capsule (Andreisek et al., 2006).

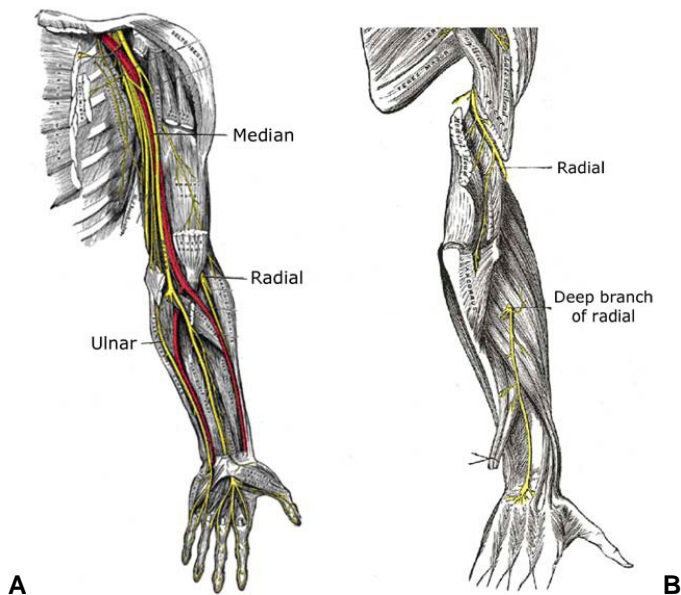


Figure 3. A. The median, radial and ulnar nerves in the arm and hand. B. The deep branch of the radial nerve (from Gray's Anatomy).

EPICONDYLALGIA

"The aim of the wise is not to secure pleasure, but to avoid pain".
(Aristotle (384 B.C. - 322 B.C.))

Epidemiology and pathomechanics

The prevalence of LE in the general population is reported to be 0.7 - 4% (Buchbinder et al., 2008; Shiri and Viikari-Juntura, 2011) and 0.3 -12.2 % amongst manual workers. In a survey of residents of Stockholm, Sweden, the prevalence was found to be 1 - 10 % (Allander, 1974). Epicondylalgia occurs most frequently in middle age between 40 and 60 years-of-age, men and women being afflicted to the same extent (Solheim et al., 2011; Shiri and Viikari-Juntura, 2011). The incidence of LE has been shown to be 0.3 - 1.1 % per year in general practice (Kivi, 1983; Hamilton, 1986; Verhaar, 1994;

Buchbinder et al., 2008; Shiri and Viikari-Juntura, 2011) and the rate for LE in the working population is 2 - 4% (Descatha et al., 2003; Gold et al., 2009; Shiri and Viikari-Juntura, 2011), and Allander (1974) reported an annual incidence of 0.1 - 1 %, in Stockholm.

Ciccotti and co-authors (2004) stated that there is a scarcity of literature regarding ME, which likely depends on its low incidence, being only 9.8 - 20% of all patients diagnosed with epicondylalgia. The prevalence rate is thought to be 0.3 -1% in the general population, and 0.2 - 3.8% in the working population (Descatha et al., 2003; Gold et al., 2009; Shiri and Viikari-Juntura, 2011). Medial epicondylalgia frequently coexists with LE (Field and Savoie, 1998; Gold et al., 2009; Shiri and Viikari-Juntura, 2011).

The true incidence of LE and ME in the general population is not, however, fully known according to Allander (1974) and Shiri and Viikari-Juntura (2011).

In classic epicondylalgia or epicondylitis (a misnomer since there is insufficient evidence to support the inflammation component) (Nirschl, 1992; Boyer and Hastings, 1999; Khan et al., 1999; Alfredson et al., 2000; Ljung et al., 2004; Dunn et al., 2008), the pathomechanism is believed to be chronic overuse with micro-trauma, circulatory disorder and varying degrees of degeneration, on the forearm extensor or flexor aponeurosis at their attachment to the epicondyles (Walz et al., 2010). Goldie (1964) described the pathology as a microscopic rupture of the attachment fibres of ECRB. Nirschl and Pettrone (1979) identified the primary pathologic alteration in the ECRB, termed histologically as angiofibroblastic hyperplasia, subsequently modified to angiofibroblastic tendinosis (Dunn et al., 2008). Kraushaar and Nirschl (1999) considered the condition to be a connective tissue disease involving the production of collagen that does not remodel into normal tendon. Ljung and associates in a study (2004) on ME observed findings in the muscle origin at the medial aspect that were similar to those at the lateral aspect as found in previous studies. Their conclusion was that the results gave further evidence for the hypothesis that the pathophysiology of various disorders with painful tendon insertions, such as LE and

ME, includes a neurogenic component which could explain the pain (Ljung et al., 1999; Zeisig et al., 2006). With time, scar tissue forms that may be vulnerable to repetitive trauma, leading to further tearing. Continuation of this cycle of injury and immature repair results in more substantial tears, with consequent alteration and failure of musculo-tendinous biomechanics and worsening of symptoms (Levin et al., 2005; Walz et al., 2010). The lack of vascular support at the undersurface of the tendon further contributes to degeneration and tendinosis (Bunata et al., 2007; Walz et al., 2010).

Some authors are in agreement about the existence of confounding factors in the assessment of musculoskeletal pain patients, such as signs of somatosensory dysfunction in a subgroup of this population (Travell and Simons, 1983; Leffler et al., 2000). There is recent evidence that LE also involves sensitisation of the nociceptive system. Lower pressure-pain threshold and wider referred pain patterns suggest that both peripheral and central sensitisation exists in chronic LE (Leffler et al., 2000; Ferna' ndez-Carnero et al., 2009). Combes and co-workers proposed, in 2009, that LE could be looked upon as comprising three interrelated components: the local tendon pathology; changes in the nociceptive system; and impairment of the motor system.

The muscle mostly involved in LE is the common extensor tendon (Coonrad and Hooper, 1973; Friden and Lieber, 1994; Lieber et al., 1997; Ljung et al., 1999a; Piligian et al., 2000; Shiri and Viikari-Juntura, 2011). Shiri and co-authors (2006) showed that LE was strongly associated with work tasks demanding a combination of repetitive and forceful activities and with long exposure to these activities. The wrist extensors play a central role in stabilising the wrist during grasping (Chard and Hazleman, 1989; Shiri et al., 2006).

According to some authors the cause of ME seems to be overload due to poor mechanics, poor physique, limited flexibility, and fatigue leading to increased transmission of both concentric and eccentric contractile loading forces (Ciccotti et al., 2004; Walz et al., 2010). Shiri and co-workers (2006) found that work tasks requiring forceful or repetitive movements were risk factors for ME.

Pronator teres and FCR (together termed the flexor-pronator mass) are the muscles most commonly involved in ME (Helliwell, 1999; Ciccotti et al., 2004; Walz et al., 2010).

Diagnosis

*"Who shall decide, when doctors disagree,
and soundest casuists doubt, like you and me?"
(Alexander Pope, 1688-1744)*

Epicondylalgia, both lateral and medial, is primarily a clinical diagnosis based on history, including pain around the humeral epicondyles, and clinical examination.

The criteria for epicondylalgia are: 1. pain distinctly located over the lateral or medial humeral epicondyles on palpation; 2. during resisted wrist extension in LE or wrist flexion in ME with the elbow extended and the forearm pronated or supinated, respectively; and 3. in ME, during resisted pronation of the forearm, and in LE, during resisted extension of the third finger, i.e. a positive middle finger test ("Maudsley test") (Roles and Maudsley, 1972; Morrison, 1981; Chop, 1989; Haker, 1991; Söderberg et al., 2011).

Active and passive extension of the wrist and elbow are mostly unaffected according to some authors (Zeisig, 2008) but according to Gellman (1992) active extension of the wrist is usually limited because of pain.

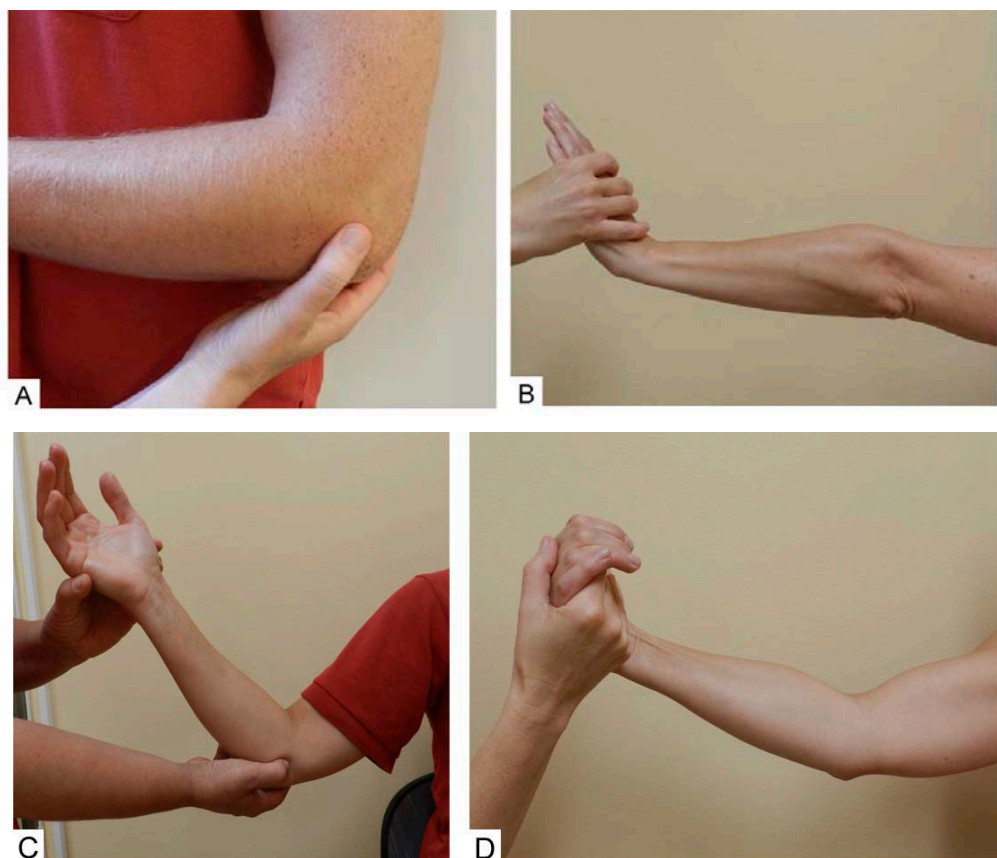


Figure 4. Diagnosis of lateral and medial epicondylalgia. **A.** Palpation of the lateral epicondyle. **B.** Isometric resistance of the wrist extensor muscles. **C.** Palpation of the medial epicondyle. **D.** Isometric resistance of the wrist flexor muscles.

In apparently straightforward cases of epicondylalgia, many clinicians feel that the diagnosis may confidently be made clinically, thus obviating the need for sophisticated investigation. Imaging has an important, but secondary role to rule out other causes of pain (Khan and Cook, 2003; Wilson and Best, 2005). This includes plain-film radiography, which may reveal bony abnormalities, e.g. loose bodies or osteoarthritis. More advanced imaging examinations are not necessary unless the diagnosis remains unclear after a thorough history and physical examination, as in

the case of recalcitrant pain despite adequate conservative management, or for preoperative assessment. Ultrasonography and magnetic resonance imaging (MRI) are options that can show changes of tendinosis (Miller, 1999; Wilson and Best, 2005). There is currently no evidence to suggest that findings on imaging should dictate management of the condition or be used as an outcome measure (Cook and Vicenzino, 2009).

Differential diagnosis of lateral epicondylalgia

Over 25 conditions have been suggested in the literature as being causes of lateral elbow pain, including periostitis, infection, bursitis, fibrillation of the radial head, radio-ulnar joint disease, synovitis and arthritis of the radio-humeral joint, annular ligament lesion, nipped synovial fringe, osteochondritis dissecans, neurogenic origins, RTS, referred pain from myofascial trigger points in the shoulder (Travell and Simons, 1983), fibromyalgia, and cervical radiculopathy. Many use the diagnosis as a non-specific term for lateral elbow pain, according to Thurston (1998b).

Differential diagnosis of medial epicondylalgia

Differential diagnosis of pain on the medial aspect of the elbow include PS, referred pain from myofascial trigger points in the shoulder (Travell and Simons, 1983), and cervical radiculopathy (Sellards and Kuebrich, 2005), any of which may mimic or coexist with ME (Walz et al., 2010). Medial epicondylalgia and ulnar nerve neuropraxia are commonly associated. Furthermore, ME and ulnar nerve neuropraxia are very commonly present when chronic medial ulnar collateral insufficiency exists. Nirschl (1980) found that 60% of patients undergoing surgery for ME exhibited some signs and symptoms of ulnar nerve neuropraxia (Field and Savoie, 1998).

TREATMENT METHODS

"Our remedies oft in ourselves do lie";

All's Well that Ends Well (W. Shakespeare 1564 - 1616)

Natural course

There is very little scientific data available on the natural history of epicondylalgia (Labelle et al., 1992), but the common opinion is that the disorder is usually self-limiting with a good prognosis (Chard and Hazleman, 1989; Shiri and Viikari-Juntura, 2011), and recovers spontaneously within six months to two years (Cyriax, 1936; Murtagh, 1988; Hudak et al., 1996a) in 80 - 90% of patients (Haahr and , Andersen, 2003; Rineer and Ruch, 2009; Shiri and Viikari-Juntura, 2011). Blanchette and Normand (2011) believe that the main mechanism of healing is a self-limiting pathology; pain restricts function and thus protects the insertion of the extensor muscles from mechanical stress during the healing process. However, a considerable proportion of individuals with epicondylalgia encounter recurrence of the condition (Hamilton, 1986; Chard and Hazleman, 1989; Smidt and van der Windt, 2006; Shiri and Viikari-Juntura, 2011). Results from a study by Almekinders and Almekinders (1994) indicate that chronic overuse injuries are not always self-limiting but can result in prolonged symptoms. Moreover, results from two studies on conservative treatment for epicondylalgia showed a recurrence rate of 26% and that 40% had prolonged minor discomfort at a follow-up on average 39 months later (Binder and Hazelman, 1983). Clinical experience has shown that there is a small number of persons who have a painful and long-lasting (for a few years) ailment, resistant to all forms of therapy (Chard and Hazleman, 1989; Hudak et al., 1996a; Helliwell, 1999; Shiri and Viikari-Juntura, 2011).

Between five and ten per cent of patients will need surgery after several months of unsatisfactory conservative management (Blanchette and Normand, 2011).

However, the present lack of scientific data on the natural history of LE may leave the physician in an ethical dilemma. On the one hand, active treatment may seem superfluous in a condition likely to resolve itself, on the other, if a patient asks for pain-relieving therapy this must be respected.

If one is to be more certain whether or not active treatment is in order, long-term studies of the natural history of the disease must be performed, paying special attention to the characteristics of patients who recover fully and of those who experience recurrence (Hong et al., 2004).

Conservative management

Conservative management is the mainstay of epicondylalgia therapy. The objective of conservative care is to relieve pain and allowing sufficient rehabilitation for the patient to be able to return to work and normal activity (Ciccotti et al., 2004). There are more than 40 treatment modes (Ernst, 1992; Blanchette and Normand, 2011) for the condition including acupuncture, corticosteroid injections, non-steroidal anti-inflammatory drugs (NSAIDs), topical drugs, extracorporeal shockwave therapy, orthoses/braces, exercises, electrotherapy, and ultrasound. There are systematic reviews from Cochrane and other databases investigating the scientific evidence in support of these treatments. Most reviews conclude that there is little evidence for existing treatments due to insufficient methodological quality of studies; small sample sizes, differences in study design, patient selection, follow-up time, in outcome measurements, and furthermore, lack of a control group in some cases (Assendelft et al., 2002; Bisset et al., 2005; Buchbinder et al., 2008).

Eccentric (strengthening) exercise

Eccentric strengthening (ES) exercises have been advocated as treatment for tendon overuse conditions since the early 1980's (Curwin and Stanish, 1984; Stanish et al., 1986). There are many theories supporting ES exercises. According to some authors,

ES loads the musculo-tendinous unit to induce hypertrophy and increased tensile strength, while reducing the strain on the tendon during movement (Stanish et al., 1986; Alfredson et al., 1998; Öhberg et al., 2004a; Martinez-Silvestrini et al., 2005). A number of authors suggest that an eccentric contraction might provide greater stimulus for the tenocytes to produce collagen, and trains the tendon to withstand a greater force than encountered in the inciting activity (Stanish et al., 1986; el Hawary et al., 1997; Martinez-Silvestrini et al., 2005). The most recent theory is that, ES decreases the neo-vascularisation believed to be a causative factor in painful tendinopathy (Alfredson, 2003; Öhberg et al., 2004b; Martinez-Silvestrini et al., 2005). In a study on ES exercises in Achilles tendinopathy, Öhberg and colleagues (2004a) reported a significant decrease in and normalisation of the size of the tendon after 12 weeks training (Martinez-Silvestrini et al., 2005). Pensini and co-workers (2002) showed that ES may provide neuromuscular benefits via central adaptation of both agonist and antagonist muscles. Consequently, ES might provide both structural and functional benefits during tendinopathy rehabilitation (Page, 2010).

In an eccentric contraction, the muscle–tendon unit lengthens as load is applied. This is in contrast to concentric loading where the muscle–tendon unit shortens and isometric contraction where the muscle–tendon unit remains constant in length. The optimum exercise “dose” is not known as regards number of repetitions, training frequency, speed of movement and load, nor is the optimum duration of treatment known (Langberg and Kongsgaard, 2008). However, as far as duration of treatment is concerned, some studies have shown that 12 weeks of ES exercise for Achilles tendinopathy leads to significantly increased collagen synthesis (Langberg et al., 2007), reduced degree of neo-vascularisation (Öhberg et al., 2004b) and a significant reduction in the pathologically increased capillary blood flow at the point of pain in both insertional and mid-portion tendinopathy, with decreased pain as a result (Knobloch et al., 2007a; Knobloch, 2007b; Knobloch, 2009).

As regards training frequency, Miller and associates (2005) demonstrated that collagen synthesis following exercises peaked at 24h to 72h after exercise. This would

imply that a training frequency somewhat less than twice a day is the most effective alternative (Langberg and Kongsgaard, 2008). Another issue concerns the often advocated principle of 'no pain, no gain', i.e. training with pain (Alfredson et al., 1998; Stasinopoulos et al., 2005) whilst others maintain that pain must be interpreted as a warning signal telling the patient to stop exercising (Stanish et al., 1986; Martinez-Silvestrini et al., 2005; Croisier et al., 2007).

However, since the basic pathophysiology of tendinopathy remains poorly understood, it is difficult to determine the mechanisms by which ES exercises help (Langberg and Kongsgaard, 2008).

Eccentric exercises and stretching

In a review of studies on ES exercises for epicondylalgia (Buchbinder et al., 2008) the only randomised controlled trial (RCT) found was a trial comparing six weeks treatment with ES with stretching, concentric strengthening with stretching, and stretching alone for LE (Martinez-Silvestrini et al. 2005). The authors concluded that all of the above treatment modes seemed equally effective in improving pain-free grip strength or spontaneous pain at follow-up (Buchbinder et al., 2008). In 2007, Croisier and co-workers carried out a study comparing isokinetic ES to non-strengthening classical rehabilitation. Their results demonstrated short-term effectiveness (9 wk) of the isokinetic ES programme. Manias and Stasinopoulos (2006) found no significant difference in pain reduction at the end of treatment (4 wk) or at the 3-month follow up, between the intervention group, who carried out an exercise programme combined with ice, and a control group with the exercise programme only. The exercise programme consisted of slow progressive ES exercises of the wrist extensors and static stretching exercises of the ECRB tendon. In a recent study by Söderberg and associates (2011), 42 patients suffering from LE were allocated to ES and forearm band, or control (forearm band only), for six weeks. The

intervention group had significantly higher pain-free hand grip and wrist extensor strength at the end of six weeks treatment.

Stretching

In a study by Sölveborn (1997), in which he compared stretching with upper forearm band, the outcome was statistically significant in favour of stretching at all follow-up times.

Woodley and co-authors (2007) who reviewed existing databases to determine the effectiveness of ES exercise programmes in the treatment of common tendinopathies, noted a lack of high-quality studies comparing the effectiveness of ES exercise to standard management of tendinopathy.

Surgery

“There is probably nothing which brings the surgical profession into greater discredit at the present time than the inability to cure a ‘tennis elbow’. The condition is extremely common, and so helpless have we been in treatment that most sufferers now never consider consulting a medical man at all” (G. Percival Mills, 1928)

Surgical techniques for treating LE can be grouped into three main categories; open, percutaneous, and arthroscopic. Dunkow and associates demonstrated in 2004 that treatment with percutaneous surgical release had reduced the time to return to work and improved function at 1-year follow-up in patients who had previously not shown improvement after 12 months of conservative management. Furthermore, lateral release of the tendinous origin of the extensors of the wrist and fingers, as described by Hohmann (1933) and some other surgeons, is considered to be a relatively simple technique (Goldie, 1964; Verhaar et al., 1993; Bankes and Jessop, 1998; Boyer and Hastings, 1999).

In 2007 a Cochrane Collaboration database review was published by Lo and Safran showing that no conclusions may be drawn regarding the effectiveness of surgical treatment. The authors found that there were advantages and disadvantages for each procedure; no technique appeared superior by any measure. The authors therefore concluded that until more randomised, controlled trials are undertaken, it is reasonable to leave decisions to the individual surgeon based on experience and ease of procedure.

Buchbinder and colleagues (2008) found nothing to support surgery being better than conservative management in their Cochrane database analysis.

Various surgical procedures have been employed for ME ranging from percutaneous epicondylar release to epicondylectomy, but there is no generally accepted technique (Ciccotti et al., 2004; Walz et al., 2010). Nowadays, standard surgical treatment includes: excision of the pathologic portion of the tendon; enhancement of local blood circulation to stimulate a healing response; firm reattachment of any elevated tendon origin back to the epicondyle; repair of the resultant defect; and management of any concurrent ulnar nerve or ulnar collateral ligament pathology. Arthroscopic debridement has been proposed for the surgical management of LE, but the close proximity of both the ulnar nerve and the ulnar collateral ligament excludes this procedure for ME. Although reports on surgical treatment for ME are limited in the literature, there have been good to excellent results reported, with 85% of patients returning to pre-injury activity levels and reporting overall satisfaction. Some residual strength deficit in the involved extremity may occur, but this does not seem to interfere with functional activities (Ciccotti et al., 2004; Walz et al., 2010).

COMPRESSIVE OR ENTRAPMENT NEUROPATHIES AROUND THE ELBOW

*“Pain and death are part of life. To reject them is to reject life itself”
(Ellis Havelock 1859-1939)*

Epidemiology and pathomechanics

Radial tunnel syndrome (RTS)

Compared with other entrapment neuropathies of the upper extremity, RTS is less common and more controversial (Lee et al., 2008). The quoted incidence of RTS, or supinator syndrome, is according to Stanley (2006) approximately 2% of all peripheral nerve entrapments in the upper limb, and in approximately 5% to 10% of cases of LE (Roles and Maudsley, 1987; Sellards and Kuebrich, 2005; Stanley, 2006; Lee et al., 2008; Tsai and Steinberg, 2008). Most affected are manual labourers performing work that requires forceful and repetitive movements involving elbow extension and forearm supination (Roquelaure et al., 2002; Sarris et al., 2002). In general, the incidence increases up to middle age before declining again. Radial neuropathies are more frequent in men than women (Latinovic et al., 2006). According to Lee and co-authors (2008) the incidence appears to be increasing, perhaps due to repetitive or prolonged isometric use of the index and middle fingers using a computer mouse.

Radial tunnel syndrome is caused by compression of the radial nerve. There are various sites at which compression of the radial nerve may occur. The most common site is believed to be at the proximal edge of the supinator muscle, hence the name supinator syndrome. At this level, the arcade of Frohse may be found, which is a congenital variant that can be found in 30-50% of the general population, and is defined as a fibrous adhesion between the brachialis and brachioradialis muscles (Rinker et al., 2004; Sellards and Kuebrich, 2005). In addition the medial tendinous

edge of the ECRB has been suggested as a structure which could cause mechanical compression (Lister et al., 1979; Rinker et al., 2004).

Pronator syndrome (PS)

Compression neuropathy of the median nerve in the arm and forearm can be a difficult diagnostic and therapeutic challenge (Hartz et al., 1981). Median nerve entrapment at the level of the PT, the so-called pronator syndrome (PS), is generally considered a rather rare condition (Stål et al., 2004). It is four times more common in women than men, and typically presents in the fifth decade (Tetro and Pichora, 1996; Stål et al., 2004). Medial elbow pain or resistant GE may be due to median nerve entrapment and may masquerade as ME, leading to an incorrect diagnosis (Nirschl, 1980; Field and Savoie, 1998).

It was originally thought that in PS the median nerve was compressed between the two heads of the PT or by the FDS. Since Seyffarth's original description, PS has been expanded to include compression of the median nerve at the lacertus fibrosus (bicipital aponeurosis) (Tetro and Pichora, 1996; Lee and LaStayo, 2004). It can follow acute trauma to the proximal forearm or be due to muscular hypertrophy in the same area associated with activities that can cause hypertrophy in these muscle groups (Halpern and Nagel, 1979).

Cubital tunnel syndrome (CuTS)

An additional nerve entrapment on the medial side of the elbow, which may be confused with epicondylalgia, is ulnar nerve entrapment in the cubital tunnel. It is the second most common entrapment neuropathy of the upper extremity, after carpal tunnel syndrome (Dawson, 1993; Idler, 1996; Spinner and Amadio, 2003; Bartels et al., 2005).

The annual incidence is estimated to be 0.8% per person-year, on the basis of 15 new cases during a three-year period in a population of 598 workers whose jobs involved repetitive work, according to Descatha and co-authors (2004), but its exact incidence and prevalence is still unknown. In a recent report, the standardised yearly incidence was estimated at 20.9 per 100,000 (Mondelli et al., 2005; Bartels and

Verbeek, 2007). It occurs most frequently at the end of the fifth decade and is more common in men than women (Bartels et al., 1998; Bartels and Verbeek, 2007). In general, the incidence of the condition increases up to middle age before declining again. In men, this compression neuropathy is most common between 55 and 64 years. This is also true, though less consistently, in women according to Latinovic and co-authors (2006).

Specific work-related risk factors commonly associated with the CuTS include repetitive and sudden elbow flexion, repeated trauma, and/or pressure to the elbow at the ulnar groove (Pilgian et al., 2000). Moderate compression of the nerve within the cubital tunnel, which occurs due to physiologic decrease in cubital tunnel volume during elbow flexion, is normal and may not result in neuropathy (Andreisek et al., 2006). Cubital tunnel syndrome arises from pathologic compression or a lesion of the ulnar nerve within the cubital tunnel, where the nerve passes beneath the fascia between the two heads of the FCU (Dawson et al., 1993) or beneath the cubital tunnel retinaculum (also known as the epicondylo-olecranon ligament or the Osborne band) (Spinner and Amadio, 2003; Andreisek et al., 2006), but may also be caused by traction or friction. Previous injury to the elbow is assumed to be a frequent cause of ulnar neuropathy, but in the majority of patients the aetiology is unknown (Dawson et al., 1993; Bartels et al., 1998; Mondelli et al., 2005).

Diagnosis

Radial tunnel syndrome

Radial tunnel syndrome is clinically difficult to distinguish from LE. The diagnosis depends heavily on physical findings. The hallmark of RTS is pain over the proximal forearm with little or no motor weakness; if present it may be a result of the pain. The pain is usually located over the extensor musculature, four to five cm distal to the lateral epicondyle and may radiate distally or proximally over the forearm. Tenderness on palpation over the radial tunnel (supinator muscle) is an important

criterion. Resisted extension of the third finger, the “middle finger test”, with the elbow extended causes a sharp pain in the region of the radial nerve, because of tightening of the fascial origin of ECRB. Supination against resistance might elicit pain over the radial tunnel, which can be explained by increased compression of the nerve by the arcade of Frohse in concert with muscular contraction (Dawson et al., 1983; Andreisek et al., 2006). Rest and nocturnal pain are also features of the radial tunnel syndrome (Roles and Maudsley, 1972; Lister et al., 1979; Dawson et al., 1983; Barnum et al., 1996; Soteranos et al., 1999). No sensory disturbance or numbness is present (Andreisek et al., 2006).

Electrophysiological evaluation

The results of electrodiagnostic testing may be normal or ambiguous in many patients, and well-established electrophysiological criteria for diagnosis do not exist (Rinker and Effron, 2004; Andreisek et al., 2006; Stanley, 2006).

Differential diagnosis

Differential diagnosis commonly includes LE, proximal root affection, polyneuropathy, as well as other chronic pain syndromes of the forearm (fibromyalgia) (Dawson et al., 1983; Andreisek et al., 2006).

The major differential diagnostic sign is the location of maximum tenderness. In LE the tenderness lies over the epicondyle itself, whereas in RTS maximum tenderness may be found several centimetres distal to the epicondyle, in the muscle mass.

Pronator syndrome

The diagnosis of PS is usually based on clinical findings. Since compression is often minimal and sometimes intermittent; symptoms may be ill-defined and difficult for the patient to describe accurately (Dawson et al., 1983). Patients with PS experience pain and numbness in the volar and medial aspects of the elbow and forearm as well as in the hand. Muscle weakness is usually not present. Physical examination produces pain on palpation over the PT muscle, which may feel firm or have the

appearance of a hard mass. Furthermore, the pressure may produce radiating pain and digital numbness. A positive Tinel sign (dysaesthesia in the digits involved produced by tapping over the nerve) may be present (Dawson et al., 1983). In an attempt to establish the level of compression, Spinner (1978) suggested several tests. In one, the examiner attempts to supinate the forearm and extend the wrist against resistance. Increased pain in the forearm would signify compression at the level of the PT. Resisted pronation of the forearm may reproduce or exacerbate the pain associated with the problem, because the test causes contraction of the biceps muscle and tightening of the lacertus fibrosus, thus indicating that the compression is at this level. The last test is flexion of the long digit's proximal interphalangeal joint against resistance. This contracts the FDS to the third finger, and the forearm pain caused by this test signals compression at the level of the superficialis arch. Deep palpation over the ulnar head of the PT may also reproduce symptoms (Spinner, 1978). Nocturnal pain is rare, but there may be reduced sensation in the radial three and a half digits of the hand which might lead to the wrong diagnosis (Dawson et al., 1983; Rehak, 2001; Sellards and Kuebrich, 2005; Andreisek et al., 2006). Sensory findings are usually poorly defined (Dawson et al., 1983).

Electrophysiological evaluation

Electrodiagnostic tests are often normal. Occasionally signs of denervation are observed in the PT, FCR, and FDS muscles by EMG. Conduction velocity in the median nerve may be delayed at the antecubital fossa (Andreisek et al., 2006). These tests may be useful in excluding other conditions in the differential diagnosis (Dawson et al., 1983).

Differential diagnosis

Differential diagnosis should include cervical radiculopathy, polyneuropathy, carpal tunnel syndrome and ME (Rehak, 2001; Hartz et al., 1981; Andreisek et al., 2006).

Cubital tunnel syndrome

Depending on the severity of the entrapment, typical symptoms in CuTS include: activity- related numbness or paraesthesiae involving the fourth and fifth fingers; pain in the medial aspect of the elbow and proximal forearm; difficulty in adducting the fifth digit while in extension (Wartenberg's sign); progressive inability to abduct the fingers; loss of grip strength (in severe cases, claw position of the ring and little fingers); and hand weakness and atrophy of the hypothenar and interossei muscles (Idler, 1996). Furthermore, the symptoms of CuTS are often associated with nocturnal pain and there is usually a positive Tinel sign (Novak et al., 1994; Idler, 1996). Motor examination includes pinch and grip strength, strength of the FDP of digits four and five, and the adduction strength of the second and fifth finger. Sensory tests reveal abnormalities of tactile and thermal sensations. Two-point discrimination and light touch are the most revealing tests (Dawson et al., 1983).

Electrophysiological evaluation

Electrodiagnostic studies are sometimes useful in confirming the diagnosis, but, when negative, the condition cannot be ruled out (Rinker and Effron, 2004; Greenwald et al., 2006; Goldfarb, 2007).

Differential diagnosis

The following differential diagnosis should be considered: ulnar collateral ligament injury of the elbow joint; polyneuropathy; and cervical radiculopathy (Dawson et al., 1983; Sellards and Kuebrich, 2005). Ulnar nerve neuropathy and ME are commonly associated as mentioned earlier.

TREATMENT METHODS

*"Cur'd yesterday of my disease
I died last night of my physician";
The Remedy Worse than the disease
(Mathew Prior, 1664-1721)*

Conservative management

Radial tunnel syndrome

Spinner and Amadio (2003) suggest prolonged conservative management, including a several-month period of NSAIDs, splinting, avoidance of forearm rotatory movements, and a physiotherapy programme establishing a balance between extensor and flexor forces. Huisstede and co-workers (2008), however, found no randomised controlled trials or controlled clinical trials. They therefore concluded that there was no available evidence for the effectiveness of conservative management.

Pronator syndrome

Treatment consists of activity modification, NSAIDs, splinting, and physiotherapy. There are no published data supporting these regimens (Tetro and Pichora, 1996; Rehak, 2001; Sellards and Kuebrich, 2005)

Cubital tunnel syndrome

There is no general agreement as to the time from the onset of symptoms for which adequate conservative measures should be tried before surgery is considered in patients with mild to moderate affection, but recommendations range from six months (Idler, 1996) to one year (Tetro and Pichora, 1996). There is little agreement in the literature on the best method of conservative treatment for moderate CuTS,

compared to mild neuropathy, based on reports of less successful outcomes compared to mild neuropathy (Piligian et al., 2000). It has been recommended that conservative management should include modification of provocative exposure such as extreme or repetitive elbow flexion. Patients frequently benefit from the use of an elbow splint at night. The elbow should not be placed in flexion greater than 45° and no direct pressure should be applied to the nerve (Sailer, 1996).

Dellon and associates (1993) found that a high percentage (89%) of patients with mild, intermittent syndrome were successfully treated without surgery, whereas only 38% of those with moderate problem such as persistent paraesthesiae, muscle weakness, and abnormal two-point discrimination (less than 10 mm) were effectively managed conservatively.

Surgery

Radial tunnel syndrome

If there is no response to conservative management after approximately three to six months, if there is evidence of denervation, or progressive or persistent paralysis, surgical decompression should be considered (Sellards and Kuebrich, 2005; Stanley, 2006; Tsai and Steinberg, 2008;). There are at least four approaches to surgical treatment for RTS that have been described in the literature; the brachioradialis-splitting approach (Lister, 1979), a posterior approach (Thompson, 1918), an anterior approach (Henry, 1957; Eversman, 1993), and an approach through the brachioradialis-extensor carpi radialis longus interval (Hall et al., 1984). Which approach is used depends on the experience of the surgeon (Tsai and Steinberg, 2008). Huisstede and associates (2008) conducted a systematic review reporting that the effectiveness of surgical treatment (decompression of the radial tunnel) ranged from 67 - 95%, depending on the different outcome measures used and patient satisfaction ranged from 40 - 83%. They concluded that surgical decompression of the radial tunnel may be effective in patients with RTS.

Pronator syndrome

Surgery is not indicated until after 8 -12 weeks of conservative management with no significant improvement in symptoms (Lee and LaStayo, 2004) and, according to Sellards and Kuebrich (2005), if symptoms persist for longer than six months, EMG indicates axonal loss, or a significant decrease in function can be seen. Surgical decompression of the median nerve involves decompression of all possible sites of nerve compression since differentiation is difficult (Rehak, 2001; Lee and LaStayo, 2004). In general, most studies report 85 - 90% good to excellent results following surgical decompression (Tetro and Pichora, 1996; Lee and LaStayo, 2004).

Cubital tunnel syndrome

Surgical intervention is generally recommended in relieving severe sensory or motor impairment (Idler, 1996; Tetro and Pichora, 1996). Many procedures are employed for the surgical treatment of CuTS including simple decompression, anterior transposition (subcutaneous, sub-muscular, and intramuscular) and medial epicondylectomy (Eaton et al., 1980; Kleinman and Bishop, 1989; Kuschner, 1996; Tsai et al., 1999; Caliandro et al., 2011). There is no consensus in the literature about the best technique (Spinner and Amadio, 2003) but simple decompression is recommended as being the least invasive surgical procedure which offers the patients the opportunity to quickly return to work and recreational activities (Nabhan et al., 2005; Nathan et al., 2005). Nathan and collaborators (1995) found that 79% of patients treated with simple decompression showed good to excellent results at four-year follow-up. Other success rates reported in the literature for the same procedure range between 80% and 90% (Elhassan and Steinmann, 2007; Watts and Bain, 2009). Furthermore, sub-muscular transposition was associated with a higher incidence of complications in a study by Biggs and Curtis (2006). The authors therefore suggested that the simpler procedure of neurolysis *in situ* is the treatment

of choice, but pointed out that, sub-muscular transposition still had a place in some circumstances. Caliendo and co-workers (2011) carried out a meta-analysis of treatments for ulnar neuropathy at the elbow, and the results suggested that simple decompression and decompression with transposition are equally effective in idiopathic CuTS, including cases of severe nerve impairment.

METHODS FOR ASSESSMENTS OF OUTCOME

*".....if they have measured many
The measure then of one is easily told";
Love's Labour's Lost (W. Shakespeare 1564-1616)*

Neurophysiological investigations

Neurophysiological investigations comprise nerve conduction studies and electromyography (EMG) (Kamen, 2004). EMG is performed using an electromyograph that records electric activity in skeletal muscles recorded on an electromyogram. The signals generated by the muscle cells can be analysed to detect medical abnormalities, activation level, or recruitment order. There are two kinds of EMG: surface, which is used for recordings from superficial muscles; and intramuscular, investigating deep muscles.

Nerve conduction studies are used to evaluate the function, especially electrical conduction, of the motor and sensory nerves (Chémali and Tsao, 2005). Nerve conduction velocity (NCV) is one such measurement in this test. The term is often used to signify the actual test, but velocity is only one measurement in the test suite. The test is usually performed with surface patch electrodes similar to those used for an EMG.

Visual analogue scale (VAS)

The VAS is frequently used to assess pain. This tool is usually presented as a horizontal line, 100 mm in length, where the left extreme end indicates "no pain" and

the right end “worst imaginable pain”. There are two ways of presenting the scale. One is that patients are asked to mark on the line, with a pen, a vertical stroke over the point they feel represents the pain they perceive. The other is by using a rigid white plastic ruler on which the subjects are asked to move a vertical marker along the line to a position that best represents their current perception of pain between the labelled extremes (Choinière and Amsel, 1996). The VAS is a valid and reliable measure of chronic pain intensity (Downie et al., 1978; Scott and Huskisson, 1979; McCormack et al., 1988; Gaston-Johansson, 1996; Bijur et al., 2001) and to measure differences in pain over time (Bijur et al., 2001; Williamson and Hoggart, 2005). It has been described as providing a convenient, easy, and rapidly administered instrument that is useful in a wide variety of clinical and research settings to measure a number of subjective phenomena. There are however some major issues including the ability of the patient to imagine the unit of the line as representing a personal perception of an abstract concept. It is essential that the assessor presents a clear and careful definition of the phenomenon to be measured. Another concern is that elderly patients or children, who have less abstract thinking ability, could find this numerical scale hard to use. Finally, “no pain” is easily understood by patients whereas “worst imaginable pain” has no absolute value and could be argued to be immeasurable. Therefore, any mark along the line between these two extremes is entirely dependent on the patient’s personal understanding of “worst pain” and based on the patient’s experience to date (Wewers and Lowe, 1990). This is an interesting point when comparing pain at different points in time, sometimes with a long interval.



Figure 5. The VAS ruler. The aspect shown uppermost is presented to the patient

Jamar dynamometer

Grip strength is by some considered to be the best objective outcome measure to evaluate the effects of treatment for LE and ME (De Smet et al., 1998) and sometimes neuropathy, especially CuTS (Dellon et al., 1993). The Jamar hand-held hydraulic digital dynamometer is the instrument often used. The unit of measurement is kilogrammes. Grip strength measurements are usually made according to the methods described by Mathiowetz and co-workers (1984). The dynamometer handle is set in the second position, the patient seated in a standard position with shoulder adducted in a neutral position, elbow in 90° of flexion, the forearm in neutral rotation, and the wrist in a neutral position. There are two ways to perform the procedure; a pain-free or a maximum grip approach. In the pain-free method the subjects are asked to slowly squeeze the handle until they begin to experience pain and the mean value of three consecutive pain-free attempts is recorded (Mathiowetz et al., 1984; Radpasand, 2009). In the maximum grip strength method, the subjects are requested to squeeze the handle as hard as they can. The procedure is repeated three times in both arms starting with the unaffected side, giving each arm/hand a resting period of about one minute. Either the mean or the maximum value of the three attempts is calculated and used for analysis (Mathiowetz et al., 1984). The use of maximum effort

in strength testing in patients with epicondylalgia is a measure reflecting the amount of force required to reproduce pain and is therefore an indirect measure of pain rather than a measure of strength (Combes et al., 2009). Unpublished data from a study on LE by Bisset and co-authors (2006), showed that maximal grip strength testing reproduced an average pain intensity on a VAS of 53 mm, indicating that this test is strongly pain-provocative in this population, further emphasising that pain-free grip testing, rather than maximum grip strength could be preferred as an outcome measure (Smidt et al., 2002; Bisset et al., 2006; Combes et al., 2009). Moreover, pain-free grip is more sensitive to change than maximum grip strength, and is recommended by Stratford and Levy (1994) as the preferred clinical outcome measure in LE. The results from reliability studies by Peolsson and associates (2001) showed that handgrip strength measured with the Jamar dynamometer is a reliable method (ICC values 0.85–0.98) and can be recommended for use in clinical practice. The reliability of the Jamar dynamometer has also been demonstrated by Mathiowetz and colleagues (1984).

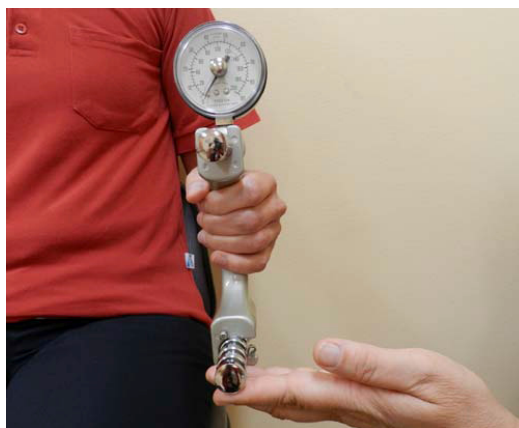

Figure 6. Testing with the Jamar dynamometer

Manual muscle testing (MMT) and digital dynamometer

There are several grading systems to classify muscle strength, including the British Medical Research Council (MRC) grading system, first published in 1943 (Medical

Research Council, 1981; Janda, 1977). This assesses muscle strength on a scale from 0 to 5, where 0 = no contraction; 1 = flicker or trace of contraction; 2 = active movement, with gravity eliminated; 3 = active movement, against gravity; 4 = active movement, against gravity and resistance; 5 = normal power (Novak, 2003).

Adduction strength of the fifth finger can also be measured with a digital dynamometer in kilogrammes (Department of Clinical Neurophysiology, University Hospital, Linköping).



Figure 7. Test of 5th finger adduction power using the digital dynamometer.

Ordinal scales

Change in symptoms after treatment may be assessed by an ordinal scale containing the alternatives 'completely recovered', 'improved', 'unchanged' and 'worse' (Binzer and Kullgren, 1998).

Satisfaction with the result of treatment may be evaluated with the help of an ordinal scale using the alternatives 'very satisfied', 'satisfied', 'dissatisfied' and 'very dissatisfied', or with a VAS rating (DeSmets et al., 1998; Martinez-Silvestrini et al., 2005; Gong et al., 2010).

Willingness to undergo surgery again, may be estimated by an ordinal scale with the alternatives 'yes', 'maybe', and 'no' (Sotereanos et al., 1999; Tomaino et al., 2001; Novak et al., 2002; Nathan et al., 2005; Townshend et al., 2005; Bolster and Bakker, 2009).

The Verhaar score

The Verhaar elbow scale (1993) is a TE-specific scoring system that rates the success of outcome after conservative or surgical treatment. Using this scale, the result is rated as 'excellent' if the pain at the lateral epicondyle is relieved completely, the patient is satisfied, there is no subjective loss of grip strength, and there is no pain on resisted wrist dorsiflexion. A 'good' result means that there is slight or occasional pain at the lateral epicondyle on strenuous activity, the patient is satisfied, there is no or slight subjective loss of grip strength, and there is no pain on resisted wrist dorsiflexion. The result is considered 'fair' if there is discomfort at the lateral epicondyle after strenuous activity but more tolerable than before the operation, the patient is satisfied or moderately satisfied, there is slight or moderate subjective loss of grip strength, and there is slight or moderate pain on resisted wrist dorsiflexion. The 'poor' rating is given if the pain has not decreased, the patient is dissatisfied, there is severe subjective loss of grip strength, and resisted dorsiflexion of the wrist causes severe pain (Verhaar et al., 1993).

Many scoring systems have been used for elbow disorders, so called domain- or organ-specific. However, only a few of these have been validated, and many assess only a few aspects of elbow function. Below are some of the most well-known.

The Disability of Arm, Shoulder and Hand Questionnaire (DASH)

The DASH questionnaire is a self-administered outcome instrument developed to measure upper-extremity disability and symptoms (Hudak et al., 1996b). It mainly consists of a 30-item disability/symptom scale concerning the patient's health status during the preceding week. The items ask about the degree of difficulty in

performing various physical activities due to an arm, shoulder or hand problem (21 items), the severity of each of the symptoms of pain, activity-related pain, tingling, weakness and stiffness (5 items), as well as the problem's effect on social activities, work, and sleep and its psychological impact (4 items). Each item has 5 response alternatives, ranging from 'no difficulty' or 'no symptom' to 'unable to perform activity' or 'very severe symptom', and is scored on a 1 to 5-point scale. The scores for all items are then used to calculate a scale score ranging from 0 (no disability) to 100 (most severe disability). The DASH is a valid and reliable instrument (Hudak et al., 1996). The Swedish version of the DASH was validated by Atroshi and associates in 2000.

The patient-rated elbow evaluation questionnaire (PREE)

(MacDermid, 2001) is an organ-specific score in which both pain and function are investigated. The evaluation of elbow function is performed by a series of questions (Longo et al., 2008). This is a validated instrument that was translated into Swedish in 2008 (Nilsson et al., 2008).

The American Shoulder and Elbow Surgeons-Elbow (ASES-E)

is a standardised elbow evaluation score developed in 1999 (King et al., 1999). It consists of patient self-evaluation, which allows the assessment of pain and functional deficits, and a physician's assessment section. This score contains objective criteria, represented by measurements of motion, stability and strength (Longo et al., 2008). It is not validated and not available in a Swedish version.

The Mayo elbow performance index (MEPI)

is a physician-based elbow rating systems from 1993 (Morrey et al., 1993). This tool is not validated and is unavailable in a Swedish version.

Generic index measures are designed for use across a wide range of health interventions rather than being aimed at one particular disease or treatment. The following are some of the most well-known:

The Canadian Occupational Performance Measure (COPM)

COPM is an individualised, client-centred outcome measure for identification and evaluation of self-perceived occupational performance and satisfaction with performance in the areas of self-care, productivity and leisure. It is standardised in so far as there are specific instructions and methods for administering and scoring the test (Law et al., 1998; Dedding et al., 2004).

The COPM is administered using a semi-structured interview, which measures the patients' opinion of their ability to perform self-selected activities and how they prioritise them. For scoring the self-perceived performance, and satisfaction with this performance, 10-point scales are used ranging from 1, meaning 'not able to do it' or 'not satisfied at all', to 10, which is 'able to do it extremely well' or 'extremely satisfied'. The difference between initial evaluation and re-evaluation is the clinically important score (Wressle et al., 2003). An improvement of two points or more is considered to have clinical relevance (Law et al., 1990, 1994, 1998). The COPM test is considered to be valid (Law et al., 1998), and the Swedish version of the instrument indicates that it has high a responsiveness to change with time, and could therefore serve as an outcome measure in occupational therapy (Wressle et al., 1999).

The Mos 36-Item Short-Form Health Survey (SF-36)

was constructed by Ware and Sherbourne in 1992. Its aim is to detect medically and socially relevant differences in health status and changes in health status with time. It was translated into Swedish in 1995 (Sullivan et al., 1995).

Measurement of health-related quality of life (EUROQUAL),

developed by the EuroQol Group (1990), is multi-country, multi-centre and multi-disciplinary. The questionnaire was simultaneously completed in many European languages, including Swedish, in 1992 (Brooks, 1996).

AIMS OF THE THESIS

GENERAL AIM

This thesis evaluates the efficacy of procedures used to treat epicondylalgia and nerve entrapment around the elbow.

The following were investigated: conservative management of lateral and medial epicondylalgia; conservative management of ulnar nerve entrapment; and surgical treatment of lateral epicondylalgia and nerve entrapment in the forearm.

SPECIFIC AIMS:

- I To investigate the efficacy of eccentric training in the conservative management of lateral humeral epicondylalgia.
- II To explore the outcome of surgical extensor release for chronic lateral humeral epicondylalgia.
- III To investigate the efficacy of treatment with a brace or nerve gliding exercises in the conservative management of cubital tunnel syndrome.
- IV To examine the outcome of decompression surgery of the median, radial and ulnar nerves for neuropathic pain in the forearm.
- V To investigate the effectiveness of eccentric training in the conservative management of medial humeral epicondylalgia.

SUMMARY OF STUDIES I - V

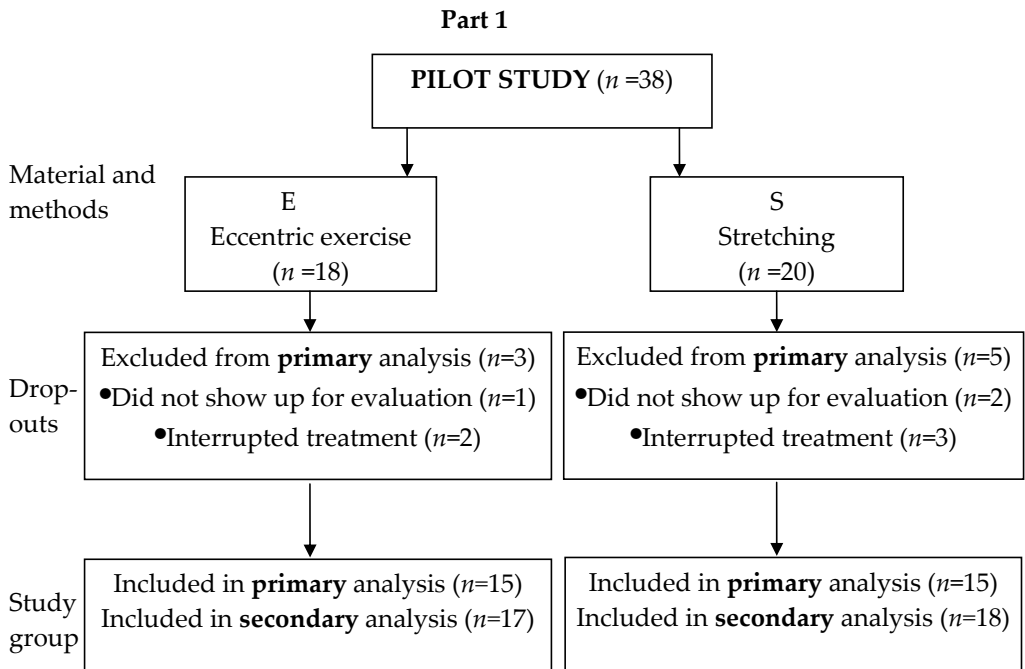
Ethics

The regional ethics review board of Linköping University approved Studies III (Dnr97143), IV (DnrM152-8) and V (Dnr2010/318-31). All participants in the five studies were informed in both verbal and written form before consent was given.

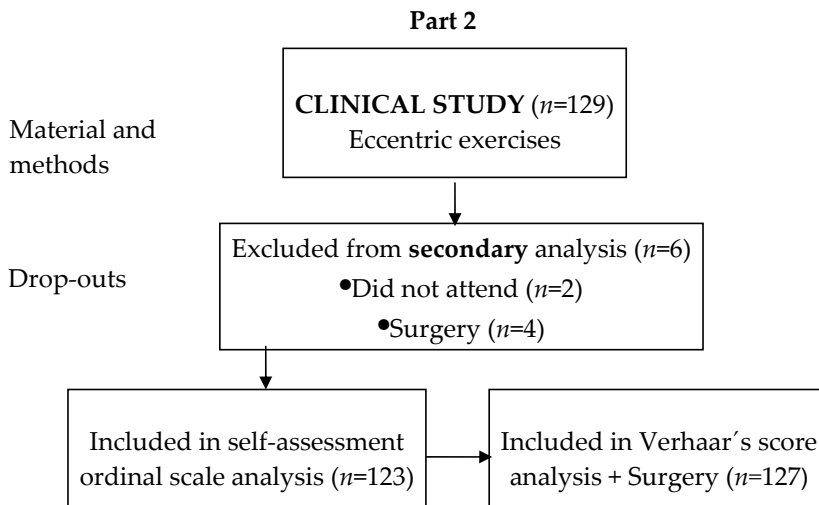
PATIENTS

Paper I

Non-operative treatment regime including eccentric training for lateral humeral epicondylalgia



Thirty-eight patients with clinically diagnosed LE were referred to the physiotherapy unit of the Department of Plastic Surgery, Hand surgery and Burns, Linköping University Hospital. The patients were randomly allocated, by the use of sequentially numbered, sealed envelopes, to one of two groups; eccentric exercises (interventional E) or stretching (control S). There were two women and 16 men in group E and 12 women and 8 men in group S. The mean age of the patients was 43 years (range 23-54) in group E and 42 years (range 29-57) in group S. Duration of symptoms was, on average, 11 months (range 3-24) for group E, and 8 months (range 3-20) for group S.



A consecutive series of 129 adult patients underwent the eccentric exercise programme for LE at the same unit. There were 72 women and 57 men with a mean age of 46 years (range 24-70) and average duration of symptoms of 19 months (range 1-180).

Inclusion criteria for both Parts 1 and 2 were: pain distinctly located over the lateral humeral epicondyle on palpation; pain over the lateral epicondyle during resisted wrist extension with the elbow extended and the forearm pronated; and positive middle finger test, i.e. pain over the lateral epicondyle during resisted

extension of the third finger (Roles & Maudsley, 1972; Morrison, 1981; Chop, 1989; Haker & Lundeberg, 1990).

Exclusion criteria for both Parts 1 and 2 were: rheumatoid arthritis; fibromyalgia; previous surgery in the region; pain that could be provoked from the elbow joint; neck problems suggesting possible cervical rhizopathy; or signs of radial nerve entrapment.

After a mean of 41 months (range 12-90), 127 of the 129 patients were retrospectively reviewed (71 women and 56 men).

Paper II

Outcome of release of the lateral extensor muscle origin for epicondylitis

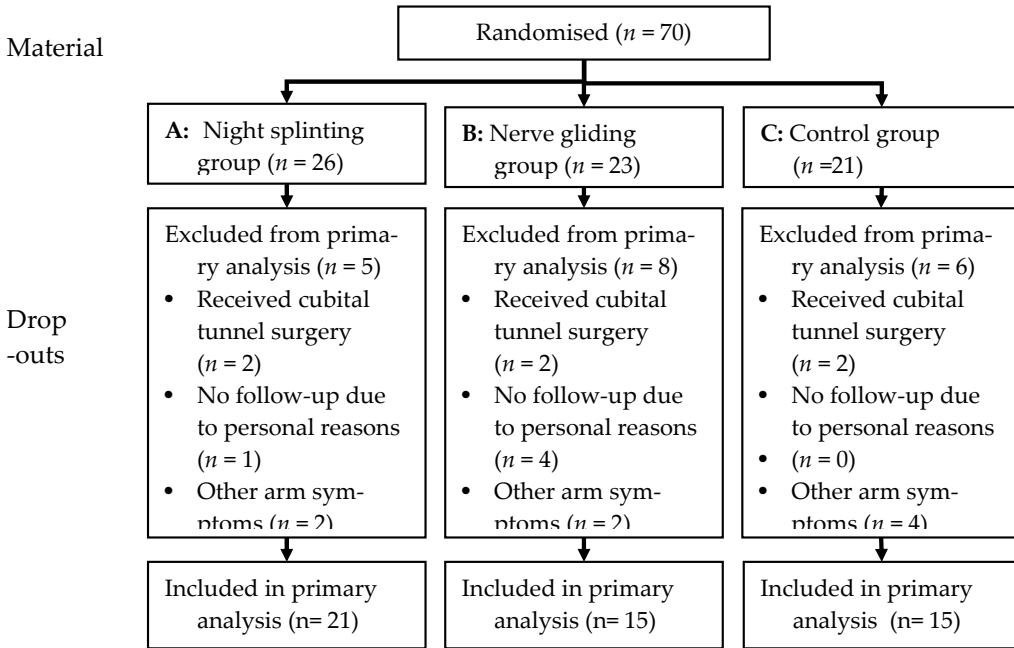
Over a thirteen-year period a consecutive series of 53 adult patients with LE underwent release of the common extensor origin at the Department of Plastic Surgery, Hand Surgery and Burns, Linköping University Hospital. After an average of 90 months a follow-up was conducted. Fifty-one patients (53 elbows), 27 women and 24 men, were available. The mean age was 46 years (range 25-64). Prior to surgery, conservative management over at least six months had failed.

Inclusion criteria: pain over the lateral humeral epicondyle on palpation; on resisted wrist extension; and on resisted middle finger extension.

Exclusion criteria: clinical signs of posterior interosseous nerve entrapment; cervical radiculopathy; and/or arthrogenic origin. They were all operated with the same surgical technique.

Paper III

Conservative treatment of the cubital tunnel syndrome



Seventy patients with clinical symptoms of mild or moderate CuTS were referred to the Department of Plastic Surgery, Hand Surgery and Burns, Linköping University Hospital for participation in a study on conservative management. There were 39 women and 31 men, with a mean age of 43 years (range 17-72). Duration of symptoms was at least 3 months (range 3-72). They were randomly allocated, by the use of sequentially numbered, sealed envelopes, to one of three groups: Group A, elbow brace at night; Group B, nerve gliding exercises; and Group C, control.

Inclusion criteria were: numbness and paraesthesiae of the ulnar aspect of the forearm and the hand; pain over the ulnar aspect of the elbow; tenderness and a

positive Tinel sign over the cubital tunnel; and a subjective feeling of intermittent weakness of intrinsic muscles in the hand.

Exclusion criteria were: symptoms of neck problems; clinical signs of another nerve problem; previous trauma or surgery to the same arm; arthritis or palpable swelling at the elbow; and subluxation of the ulnar nerve.

Nineteen patients dropped out of the study, leaving 51 for the final assessment. There were 27 women and 24 men, with an average age of 44 years (range 17-72).

Paper IV

Patient-reported outcome of surgical treatment of nerve entrapments in the proximal forearm

Two-hundred and seventeen consecutive adults with clinical signs of entrapment neuropathy in the proximal forearm were operated on with simple decompression at the Department of Plastic Surgery, Hand Surgery and Burns, Linköping University Hospital. After an average of 45 months post- procedure, 205 patients were available for follow-up. There were 108 women and 97 men, and the mean age was 46 years (range 18-77). The diagnoses were distributed as follows: 76 patients with PS; 33 patients with RTS; 72 patients with CuTS; 20 patients with unilateral involvement of both the median and ulnar nerves; three patients with unilateral median and radial nerve symptoms; and one patient with unilateral ulnar and radial nerve involvement.

Inclusion criteria were: longstanding pain over the alleged compression sites, both at rest and during activity; paraesthesiae and/or numbness along the nerve distribution; tenderness on palpation over the suspected compression sites; and occasionally weakness in the muscles innervated by the affected nerve.

Exclusion criteria were clinical signs of cervical radiculopathy and joint pathology. Two hundred and five patients (94%), 97 men and 108 women, were available for follow-up at a mean of 45 months (range 9-87) after operation.

Paper V

Medial epicondylalgia (golfer's elbow) treated by eccentric exercise

Twenty consecutive adult patients with clinically diagnosed ME were referred to the unit of physiotherapy at the Department of Plastic Surgery, Hand Surgery and Burns, Linköping University Hospital for conservative management. There were 11 women and 9 men, with a mean age of 47 years (range 31-62) and symptom duration of 19 months (range 2-60).

Inclusion criteria were: pain over the humeral medial epicondyle on palpation; on resisted wrist flexion; and on resisted pronation of the forearm.

Exclusion criteria were: clinical signs of cervical radiculopathy; rheumatoid arthritis; ulnar neuropathy; previous surgery in the region; and pain from the elbow joint.

At a mean of 133 months, a follow-up was carried out. Eighteen patients were assessed. There were 11 women and 7 men.

METHODS OF TREATMENT

Paper I

Part 1

The treatment method used for the intervention group E was eccentric exercise combined with static stretch as a home training programme. At the primary visit the patients were instructed by a physiotherapist, and also provided with a detailed instruction sheet to enable them to safely follow the protocol at home (Fig 2).

Figure 8 . Description of the eccentric exercise training programme

Freely after Curwin & Stanish (1984)

1. Warm-up of the forearm extensor and flexor muscles by wrist movements without load (2–3 min).
2. Static stretch (15–30 s). Repeat 3–5 times
3. Eccentric exercises of the forearm extensor muscles. Patient sits next to a table on which the forearm is resting in full pronation and the elbow flexed at about 90°, the wrist in neutral position with the palm over the edge of the table facing the floor and holding a refillable dumb-bell., The weight is slowly lowered over 10 s by flexion of the wrist. The hand holding the weight is brought back to the starting position with the help of the other hand. Three sets of 5 repetitions are performed.
4. Static stretch of the wrist flexor muscles (3 times at 15-30 s each).

To be performed once a day.

Starting weight: 1.0 kg (men), 0.5 kg (women) with 10% weight increase each week for 3 months.

No pain should be experienced during the exercise.

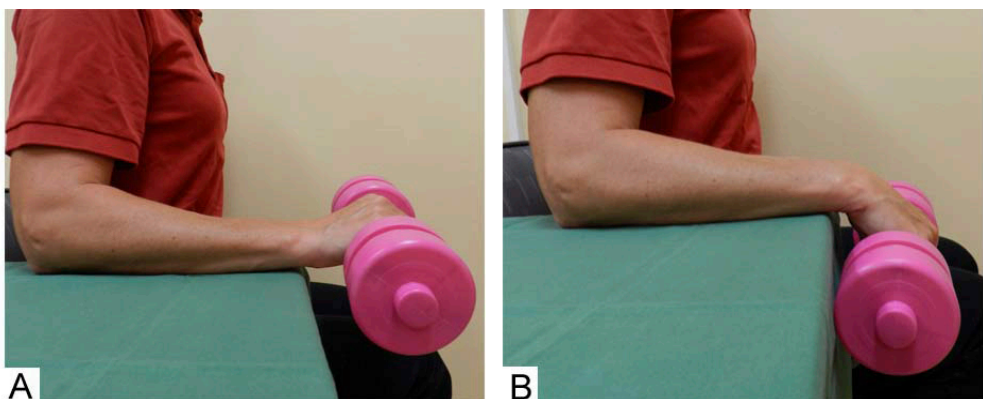


Figure 8. A. Starting position B. End position

The control group S performed a stretching programme, already in use, developed and tested by Sölveborn (1997), at home. They too received an illustrated description of the programme (Fig 3).

Figure 9 . Description of the stretching training programme

1. *Contraction of the forearm extensors (10 s)*
2. *Relaxation (2 s)*
3. *Stretching (15–20 s)*
4. *Repeat 3–5 times.*

To be performed twice daily

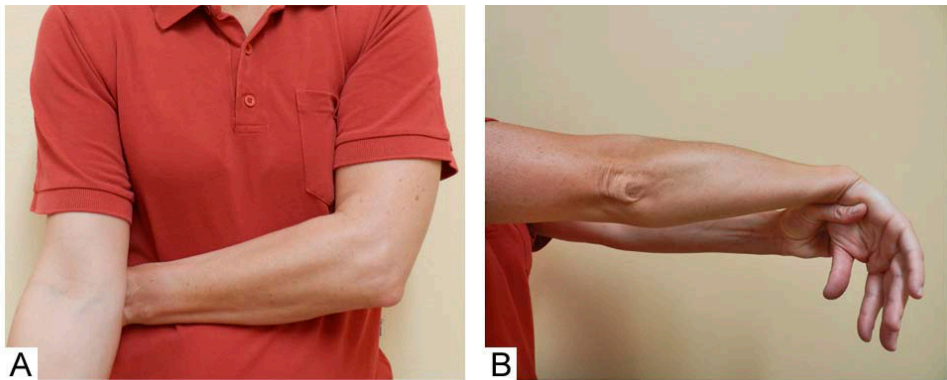


Figure 9. A. Contraction of the left wrist extensor muscles. **B.** Passive stretch

Both groups were asked to complete a daily diary commenting on their daily performance and status, and both groups were seen by the instructor after one week and then once a month during the three-month treatment period. They were all

informed about ergonomics, especially in connection with work, and instructed to use the affected arm, but to avoid painful movement.

Part 2

All patients were treated with the eccentric exercise programme tested in Part 1.

Paper II

The patients were treated with lateral release of the tendinous origin of the extensors of the wrist and fingers. The operations were done as day-case surgery under local anaesthesia. Postoperatively, a light compression bandage was applied and kept on until removal of the sutures after two weeks. During this period, all patients were instructed to preserve full range of motion. After two weeks, light stretching exercises of the elbow joint and forearm extensor muscles were allowed, and six weeks postoperatively physiotherapy was started.

Paper III

Two groups, A and B, were treated actively with either a night splint or a nerve gliding programme, while Group C had no intervention (control). The night splint, set to about 45° of flexion, was to be worn every night, and the nerve gliding exercises were to be performed at home twice daily in accordance with a programme used at the Philadelphia Hand Centre, Philadelphia (Byron, 1995). The nerve gliding group was also provided with a detailed instruction sheet to enable them to safely follow the protocol at home. Furthermore, all groups were given verbal and written information by an occupational therapist about the probable cause of symptoms, basic ergonomics, and the anatomy around the elbow. The intervention period lasted three months.

Paper IV

The patients were treated with simple decompression of the relevant nerve. All operations were performed as day-case surgery under general anaesthesia. The patients were instructed to use the operated extremity in normal every-day activities immediately following surgery, but heavy work or lifting was not allowed for six weeks. In the postoperative rehabilitation programme, all patients were followed according to our structured care plan, i.e. that a surgeon saw them at least once after the operation and, if necessary, prior to going back to work or back to normal activity. All patients were seen by a physiotherapist and instructed in nerve gliding exercises, scar management, and possible pain and mobility monitoring, as well as by an occupational therapist, whenever necessary, for oedema reduction and/or treatment of scar hyperaesthesia if present.

Paper V

The patients were treated with eccentric exercises of the finger and wrist flexor muscles using a modification of the programme used for LE in Paper I (Fig 4).

Figure 10. Description of the eccentric exercise training programme

1. Warm-up of the forearm flexor and extensor muscles by wrist movements without load (1-2 min) followed by static stretch of the wrist flexor muscles (3 times 30-45 sec each).
2. Eccentric exercises of the forearm flexor muscles. Patient sits next to a table on which the forearm is resting in full supination and the elbow flexed at about 90°, the wrist slightly flexed with the palm over the edge of the table facing the ceiling and holding a refillable dumb-bell. Over 5-7 s, the weight is slowly lowered by dorsiflexion of the wrist. The hand with the weight is brought back to the starting position with the help of the other hand. Three sets of 5 repetitions are performed.
3. Static stretch of the wrist flexor muscles (3 times 30-45 sec each).

To be performed once a day.

Starting weight: 1.0 kg (men), 0.5 kg (women) with 10% weight increase each week for 3 months.

No pain should be experienced during the exercise.

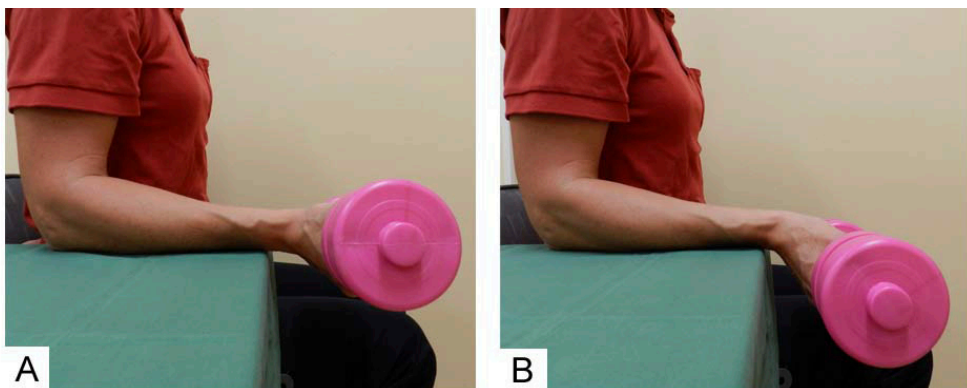


Figure 10. A. Starting position B. End position

METHODS FOR ASSESSMENTS OF OUTCOME

Evaluation of pain

Pain assessed on a visual analogue scale (VAS) was used as the primary outcome measure in Papers I, IV and V, and as a secondary one in Paper III. In Papers I and V pain over the epicondyles of the elbow was asked about at inclusion, while at rest in Papers I, III and IV, and during activity in Papers III and IV. Pain was also rated in connection with grip strength measurements in Paper I. VAS was used at baseline in Papers I, III and V, at the end of treatment in Papers I and V, and at follow-up visits in Papers I, III, IV and V.

Evaluation of grip and finger adduction strength

Grip strength was used as a secondary outcome measure of the effect of treatment in Papers I, III, and V. In Paper I, part 1 the grip strength was measured with a special strain-gauge device constructed at the Department of Neurophysiology, University Hospital, Linköping.

In Paper I, part 2, and in Papers III and V, grip strength was assessed with the Jamar dynamometer. Maximum voluntary grip strength was used in Papers I and III, but in Paper V, pain-free gripping was applied. In Papers I and III, the highest of three values was used for analysis, but in Paper V, the mean of three pain-free attempts was calculated.

In Paper III the adduction strength of the fifth finger was employed as a secondary outcome measure in some of the patients (the 42 patients treated at the University Hospital, Linköping) using a digital dynamometer. The mean of three trials was recorded at baseline and at the follow-up visit (six months).

Evaluation of treatment for tennis elbow

The result of surgery in Paper II, and of conservative treatment in Paper I, part 2, was evaluated by Verhaar's tennis elbow-specific scoring system, which was employed as the primary outcome measure.

Self-assessed evaluation of the arm, shoulder and hand function

Patient-perceived disability of the upper extremity in Papers IV and V was assessed using the Swedish version of the DASH questionnaire. It was used at the follow-up visit as a secondary outcome measure.

Motor and sensory nerve conduction velocities and electromyography

Motor and sensory NCV and EMG were used as a supplement to neurophysiological examination as a primary outcome measure in Paper III and a secondary in Paper IV. These were performed on all patients prior to treatment in Paper III, on two thirds in Paper IV, and on 88% of the material at follow-up in Paper III.

Self-perceived occupational performance and satisfaction

Activity impairment was evaluated with COPM, as secondary outcome measurement in Paper III. All patients assessed their symptoms according to the COPM, before beginning treatment and at the follow-up visit at six months.

Self-perceived evaluation- change of symptoms

Subjective perception of change in symptoms was used as a secondary outcome measure and assessed using a four-point ordinal scale with the alternatives: 'completely recovered', 'improved', 'unchanged', and 'worse' at the end of treatment in Papers I and V, and in Papers I, II and IV at follow-up.

Self-perceived evaluation - satisfaction

Overall satisfaction was established using a four-point ordinal scale, with the alternatives: 'very satisfied', 'satisfied', 'dissatisfied' and 'very dissatisfied', in Paper IV. In Paper V a VAS scale (100 mm; from 0 'Very dissatisfied' to 100 'Very satisfied') was employed as a secondary outcome measure.

Self-perceived evaluation - repeat surgery

'Would the patient consider undergoing surgery again, based on what they knew today', was evaluated on a three-point ordinal scale in Paper IV, with the alternatives: 'yes', 'maybe' and 'no'. It was used as a secondary outcome measure.

STATISTICAL METHODS IN PAPERS**Table 1. Statistical methods in Papers I-V**

Statistical methods in paper	I	II	III	IV	V
Descriptive statistics	x	x	x	x	x
Fisher's exact test	x	x	x		x
Student's <i>t</i> -test	x		x		x
Mann - Whitney U-test.	x				x
Chi-square test		x		x	
Spearman Rank Order Correlation		x		x	
One-way ANOVA			x	x	
Paired <i>t</i> -test				x	x
Pearson's product-moment correlation				x	x
Logistic regression				x	

P values < 0.05 were considered significant.

RESULTS

The major findings are presented below. For more detailed results please see the respective papers.

Paper I

Part 1

There were eight drop-outs from the study, three patients (one in group E and two in group S) did not complete the training period and were excluded from the study. Five other patients (two in group E and three in group S) interrupted their respective training programmes because of increase in symptoms and were regarded as failures.

The self-rated treatment outcome showed no difference between the groups at three or six months. After 12 months all patients rated themselves as improved or completely recovered. In group E, 12 patients considered themselves as completely recovered as compared to 7 patients in group S ($p=0.09$).

In group E all but one patient, and in group S all but two patients reported complete relief of pain at rest at the 6-month follow-up. No significant differences between the groups were seen in the five pain VAS recordings.

Grip strength increased significantly in both groups after three months ($p=0.001$). At the 6-month follow-up the increase was significantly larger in group E ($p=0.05$).

Part 2

Evaluation of pain

At the end of the treatment period (three months) statistically significant improvements were seen in all of the five pain VAS recordings ($p<0.0002$).

Evaluation of grip strength

Significantly increased grip strength, compared to baseline, was observed ($p<0.0001$).

At follow-up, on average 41 months, two patients were not available and four had been surgically treated and were not further evaluated. Eight had received additional conservative treatment during the follow-up period.

Evaluation of treatment

According to Verhaar's score, 48 patients were excellent, 35 good, 32 fair and 12 poor.

Self-perceived evaluation – change of symptoms

A total of 66 patients considered themselves as completely recovered, 53 improved, two unchanged and two worse.

Duration <12 months and > 12 months

Among patients with short duration of symptoms, 72% had excellent or good results. Among patients with long duration, 70% had excellent or good results. Both according to Verhaar's score.

Paper II

Evaluation of treatment

According to Verhaar's score, nine elbows were considered excellent, 17 good, 20 fair, and seven poor.

Self-perceived evaluation – change of symptoms

According to the self-assessment score 21 elbows were completely recovered, 25 improved, seven unchanged, and none worse.

Paper III

Fifty- one patients were available for assessment at six months. Thirteen patients were drop-outs and another six patients, two from each group, underwent surgical decompression because of persistent symptoms after completing the programme. They were therefore not clinically assessed.

NCV and EMG

Overall nine of the 12 patients with abnormal neurophysiological findings improved with conservative treatment (75%). The neurophysiological changes were equally distributed between the groups.

Self-perceived occupational performance and satisfaction

All groups showed an improvement of on average two points in activity performance and three to four points in satisfaction. There were no significant differences between the groups.

Evaluation of pain

An improvement in day-time pain was seen in all three groups at 6-month follow-up, which was significant in Groups B and C ($p<0.05$) and nocturnal pain, which was significant in all three groups ($p<0.05$). There were no significant differences in improvement between groups.

Evaluation of grip strength

Grip strength was improved in all three groups. There were no significant differences between the groups.

Evaluation of adduction strength

There were no significant changes in the fifth digit adduction power between the groups or within the groups.

Paper IV

At follow-up 205 patients were available, but in the analysis three patients were excluded, accordingly, 201 patients comprised the cohort.

Evaluation of pain

Pain decreased significantly ($p=0.001$). There were no significant differences between the groups.

There was a significant correlation between preoperative duration of symptoms and patient perceived postoperative pain.

NCV and EMG

There was a significant difference between the groups. Pathological readings prior to surgery were more common in the ulnar nerve group ($p<0.001$).

Self-perceived evaluation - satisfaction

Altogether 59% of the patients were very satisfied or satisfied. There were no significant differences between the nerve groups.

Self-perceived evaluation - change in symptoms

Fifty-eight per cent considered themselves completely recovered or improved, and 3% as being entirely relieved of all symptoms. There were no significant differences between the different nerve groups.

Self-assessed evaluation of the arm, shoulder and hand function

The mean postoperative DASH score was 35.29 points for the whole patient population.

Self-perceived evaluation - repeat surgery

The result showed that 134 patients (67%) would consider undergoing the operation again. There were no differences between the nerve groups.

Paper V

At long-term follow-up two patients had received additional treatment and were not further evaluated.

Evaluation of pain

At three months, the end of treatment, as well as at 11 years, on average, all VAS recordings of pain were significantly decreased compared to before treatment ($p=0.0001$).

Patients with symptom duration of 12 or more months had a significantly higher total pain score before treatment ($p=0.028$), and at three months ($p=0.004$) but not at follow-up.

Evaluation of grip strength

Grip strength in the involved arm/hand had increased significantly at the end of treatment ($p < 0.009$), but the increase at follow-up was not significant.

Self-perceived evaluation – change of symptoms

At three months, one patient considered himself completely recovered, 16 patients improved and two unchanged. There were no patients in the worse category and no gender difference. The rating from one patient was missing.

Self-perceived evaluation - satisfaction

At follow-up the mean satisfaction VAS score was 83.18 mm. There was no difference between women and men, nor was there any difference between patients with long or short duration of symptoms.

Self-assessed evaluation of the arm, shoulder and hand function

The mean disability score was 18.71 points. There was no difference between women or men nor was there any difference between patients with long or short duration of symptoms.

Table 2. Overview of the papers included in the thesis. The numbers are mean or frequency.

	Paper I	Paper II	Paper III	Paper IV	Paper V
Design	Part 1: Randomised, prospective	Retrospective case series	Randomised prospective	Retrospective case series	Prospective case series
	Part 2: Prospective case series				
Material	Part 1: 38 Part 2: 127	51 (53 elbows)	70	205	20
Age (years)	Part 1: 43 Part 2: 46	46	43	46	47
Treatment modes	Part 1: <i>Group E:</i> Eccentric exercises of the finger-and wrist extensor muscles <i>Group S:</i> Stretching Part 2: Eccentric exercises of the finger-and wrist extensor muscles	Lateral release of the tendinous origin of the wrist extensor muscles	<i>Group A:</i> Night splint <i>Group B:</i> Nerve gliding exercises <i>Group C:</i> Control	Simple decompression of the median, radial and ulnar nerves in the forearm	Eccentric exercises of the finger- and wrist flexor muscles
Outcome measures	Part 1: VAS Strain-gauge grip-strength device Self-assessment ordinal scale Part 2: VAS Jamar dynamometer Verhaar's score Self-assessment ordinal scale	Verhaar's score Self-assessment ordinal scale	Neurophysiologic examination COPM VAS Jamar dynamometer Digital adduction dynamometer	VAS Self-assessment ordinal scales Neurophysiologic examination DASH	VAS Self-assessment ordinal scale Jamar dynamometer DASH

Table 2. Continued.

	Paper I	Paper II	Paper III	Paper IV	Paper V
Results	<p>Part 1:</p> <p>Reduced pain and increased grip strength were seen in both treatment groups but 12 out of 17 patients (71%) in group E rated themselves as completely recovered as compared to 7 out of 18 (39%) in group S.</p> <p>In group E the increase in grip strength after 6 months was statistically significantly larger.</p> <p>Part 2:</p> <p>Statistically significant improvements in all VAS recordings and grip strength.</p> <p>After 3 years 38% had excellent, 28% good, 25% fair and 9% poor results.</p> <p>In the Self-assessment ordinal scale 54% regarded themselves as completely recovered, 43% improved, 2% unchanged and 2% worse.</p>	<p>49% were excellent or good, and 51% fair or poor.</p> <p>40% were completely recovered, 47% improved, 13% unchanged, and zero worse.</p>	<p>Nine of the 12 patients with abnormal neurophysiological findings improved with conservative treatment (75%).</p> <p>Neurophysiological changes were equally distributed between the groups</p> <p>Fifty-one patients (89.5%) were improved at the follow-up.</p> <p>There were no significant differences between the groups in any of the recorded variables.</p>	<p>Pain decreased significantly in all groups 59% of the patients were satisfied, 58% considered themselves improved, and 3% as being entirely relieved of all symptoms.</p>	<p>Pain decreased significantly in all the measured variables on both assessment occasions.</p> <p>Grip strength in the affected arm/hand increased significantly after 3 months.</p>

GENERAL DISCUSSION

"Health shall live free and sickness freely die"; All's Well that Ends Well
(W. Shakespeare 1564-1616)

OUTCOME MEASUREMENTS AND INTERPRETATION OF RESULTS

The subject of the present thesis is the treatment of conditions that are mainly manifested as pain, discomfort and subjective dysfunction. The patients' expectations on the outcome of a treatment vary depending on factors such as previous experience, personality, society and desired level of activity. It may thus be difficult or sometimes improper to make inter-individual comparisons or even to find a common instrument applicable for all subjects.

Instead there are several indirect ways of describing the individual impact of the disorder such as visual analogue scales or scoring systems. Strength measurements and neurophysiological recordings might occasionally add valuable information but cannot be used to objectively describe the cause of symptoms. Since the causative pathomechanisms remain enigmatic, treatment in most cases aims at reducing symptoms rather than curing an underlying disease. The literature is replete with assessment systems, many of which are debatable, and effectiveness of treatment is difficult to assess. According to some, pain, being a subjective experience, should probably be evaluated separately from objective measures of elbow function in physician-based elbow ratings (Doornberg et al., 2005; Longo et al., 2008). Others, however, have stated that an ideal tool for the assessment of the elbow would measure pain, function, and disability simultaneously and accurately (Turchin et al., 1998).

In Papers I and II the score by Verhaar and associates was used. The categorical results of excellent, good, fair, and poor are based on the patient's condition at final follow-up regardless of their previous levels of pain and function (Verhaar et al., 1993;

Bankes and Jessop, 1998; Krischek et al., 1999; Dunn et al., 2008). The shortage of validated instruments for evaluating treatment for LE made us choose this tool, since previous studies of interest had applied this instrument, making comparison possible. One self-assessment score exists to-day, the PRTEE, validated and translated into Swedish (2008), which could be used in connection with outcome of treatment in patients suffering from LE in both prospective and retrospective studies (MacDermid, 2005; Nilsson et al., 2008). DASH has also been available in a Swedish version since 2001, but is considered to be of limited value due to a lengthy general questionnaire, and furthermore it is not designed to address a specific diagnosis such as LE (Sathyamoorthy et al., 2004; Longo et al., 2008).

In epicondylalgia, as well as in nerve entrapment, pain is the main reason for seeking medical attention. Pain and other symptoms such as paraesthesiae and numbness are subjective experiences which led us to assess the outcome of treatment with the help of self-assessment scales. The use of ordinal rating scales for evaluating change in symptoms, to assess satisfaction, and willingness to repeat surgery was inspired by previously published studies (Binzer and Kullgren, 1998; Sotereanos et al., 1999; Tomaino et al., 2001; Novak et al., 2002; Nathan et al., 2005; Townshend et al., 2005; Bolster and Bakker, 2009).

Strength measurements are frequently used in an attempt to quantify the severity of a painful condition or nerve affection. Although strength cannot be used to grade the causative condition itself, it may be used to reflect the ensuing dysfunction.

Grip strength is considered to be the best objective outcome measure to evaluate the effects of treatment for LE and ME (De Smet et al., 1998) and sometimes in neuropathies, especially CuTS (Dellon et al., 1993). In Paper III a special *strength gauge device* was built to address the question of assessing adduction power in the little finger of patients with CuTS, since no instrument measuring this function was commercially available.

Apart from the problems associated with assessment of effectiveness of treatment, the present thesis is partially based on retrospective studies. Assessment

of outcome in such studies, several years after treatment, may be affected by such factors as: natural course of the disease; adaptation; placebo effect; and lack of recollection. All conclusions have been drawn with this borne in mind. On the other hand these studies are based on relatively large numbers of patients with a long duration of symptoms, and the results presented represent outcome of commonly used treatments. At the time of publication the studies reported in Papers I and V were the first studies reporting clinical results from their respective treatment modes.

CAN ECCENTRIC EXERCISES REDUCE PAIN AND INCREASE GRIP STRENGTH (IN PATIENTS WITH EPICONDYLALGIA)?

Chronic epicondylalgia (tendinopathy) is considered to be a degenerative condition, essentially absent of inflammatory infiltrate. It has therefore become increasingly recognised that anti-inflammatory treatment is largely ineffective in the treatment of this condition (Rees et al., 2006). This has led to an increased interest in other therapeutic modalities, and many authors underline the incomplete effectiveness of conventional treatment due to absence of strengthening exercises believed to promote tendon healing and reorganisation (Almekinders and Temple, 1998; Paavola et al., 2000; Croisier et al., 2007).

In recent years eccentric exercise programmes have been emphasised in the literature as a key part of tendinopathy rehabilitation. However the mechanisms behind the positive effect of eccentric treatment are still to be determined.

Several hypotheses have been mentioned in the literature. It has been proposed that in an established tendinosis, the tendon often does not progress to an active healing cycle and that eccentric exercises may act by mechanically stimulating the tenocytes (Rees et al., 2009). Furthermore, it has been shown that in patients with Achilles tendinopathy treated with eccentric exercises, an increased paratendinous capillary blood flow was reduced and pain decreased (Öhberg and Alfredson, 2004b; Knobloch et al., 2007a). It has been hypothesised that eccentric training may lead to

tendon hypertrophy and increased tensile strength, and that the effect of the stretching component of the exercise may have a significant influence on the elastic characteristics of the tendon (Alfredson et al., 2000). It has also been suggested that eccentric training for Achilles tendinopathy may have a sclerosing effect on neovascularisation (Öhberg and Alfredson, 2004b; Mahieu et al., 2008). Regardless of the mechanisms involved, one could speculate that eccentric exercises have a similar effect in both LE and ME since they have comparable histopathological features (Khan et al., 1999; Ashe et al., 2004).

In Paper I, patients suffering from LE treated with the programme where ES was the main ingredient had better results than the control group, and in the clinical series, decreased pain and significantly increased grip strength was observed following ES treatment. Good long-term results were also found following the use of a similar programme for patients with ME (Paper V). We chose to perform the exercises pain-free according to the recommendations of Stanish and co-workers (1986) where the idea for this model originated. We believe that pain caused by carrying out of the programme could potentially cause patients to abandon their eccentric exercises. No patients were worse at the end of treatment and no adverse effect was seen.

More recent studies, using eccentric exercises for LE, appear to corroborate our findings but due to methodological differences direct comparisons are difficult (Martinez-Silvestrini et al., 2005; Croisier et al., 2007; Söderberg et al., 2011). We believe that a programme containing eccentric exercises can help patients suffering from epicondylalgia by decreasing pain and increasing grip power.

CAN SURGERY HELP PATIENTS WITH CHRONIC LATERAL EPICONDYLALGIA?

There are still a number of patients that do not benefit from conservative treatment. In those patients surgery can be the final option. Several surgical procedures have

been proposed for the treatment of LE including tenotomy or release of the CEO, selective release of the ERCB, excision of an allegedly degenerative portion of the ERCB, annular ligament resection, complete denervation of the lateral epicondyle, and lengthening of the distal ECRB tendon. These procedures are more or less complicated and although assessment methods do not allow for reliable comparison, most publications report surprisingly similar outcomes. Since the pathology of LE is unclear it is impossible to advocate a specific procedure, and the potential effect of surgery on the underlying cause of pain cannot be established. It appears that all procedures have potential denervation of the common extensor origin in common, which may be part of the positive effect that has been reported. The technique of lateral release of the CEO was used due to its relative simplicity (Goldie, 1964; Verhaar et al. 1993; Bankes and Jessop, 1998; Boyer and Hastings, 1999).

In Paper II we found self-perceived relief of pain and disability in 87% of patients, which is an acceptable success rate. The patients whose symptoms were unchanged after surgery were clinically re-examined and an additional diagnosis was found in all but one, emphasising the importance of careful exclusion of differential diagnoses.

As mentioned previously, current literature does not allow any conclusions on the effectiveness of surgical treatment, but with the present knowledge it appears justifiable to recommend lateral extensor release for patients with chronic LE refractory to conservative management.

CAN CONSERVATIVE TREATMENT IMPROVE CUBITAL TUNNEL SYNDROME?

Entrapment neuropathies are often overlooked because localised neural pain may be attributed to musculoskeletal injury. If nerve symptoms are caused by a local affliction this may be due to compression by surrounding anatomical structures, but may also be caused by traction or friction. Nerves will most likely react similarly

regardless of the underlying problem, which makes diagnosis difficult. Prompt recognition of the problem and the specific site of affliction are important in order to institute effective treatment and limit, if not totally eliminate, permanent sequelae (Posner, 1990; Hume et al., 2006). In the rare instance of a mechanical compression causing constant and severe nerve dysfunction, immediate surgery is usually recommended. In the majority of cases, however, the nerve dysfunction is mild or intermittent and initial conservative treatment is advocated.

Conservative management may include avoidance of aggravating activities, rest, splinting, corticosteroid injections, and anti-inflammatory medication.

Most cases of CuTS improve if the nerve is relieved of its irritation. In non-traumatic cases, this can easily be achieved by simply teaching patients to avoid external pressure on the medial side of the elbow, and to avoid keeping the elbow flexed for a prolonged period of time (Posner, 2000). It has been shown that flexion of the elbow reduces the volume of the cubital tunnel, thereby increasing pressure on the nerve (Apfelberg and Larson, 1973; Dellon et al., 1993; Eisen and Danon, 1974). Eisen and Danon (1974) described the cross-sectional diameter of the ulnar nerve as being larger at the entrance to the cubital tunnel than anywhere else, and that the tunnel is considerably narrowed during elbow flexion and widened upon extension. This appears to explain the relief of symptoms frequently experienced by patients when extending the elbow.

To avoid involuntary flexion of the elbow during sleep a splint is frequently advocated (Eisen and Danon, 1974; Hong et al., 1996; Idler, 1996; Sailer, 1996; Posner, 2000; Rich and McKay, 2002; Coppieters et al., 2004; Robertson and Saratsiotis, 2005). In Paper III we demonstrated successful pain and symptom reduction in patients with CuTS treated conservatively with information about the syndrome and the avoidance of aggravating activities. There were no adverse effects of this management but a minority of patients experienced insufficient symptom relief and underwent surgery with acceptable results. One can thus conclude that conservative management for mild to moderate cases of CuTS may be recommended.

IS SURGERY FOR NERVE ENTRAPMENT IN THE FOREARM AN OPTION WHEN CONSERVATIVE TREATMENT FAILS?

In instances where conservative management has failed, surgical decompression may be warranted. The rationale of such a procedure is to reduce external pressure from anatomical structures that could be the cause of the compression. As mentioned above, mechanisms other than simple external pressure may be the cause of symptoms, but discrimination between these cannot always be made on clinical or neurophysiological grounds.

In Paper IV the success rate of 58% subjectively improved patients after simple decompression for nerve entrapment in the forearm is lower than reported elsewhere in the literature. Twelve per cent rated themselves as worse after surgery. The rate of satisfaction in the present study was 59%. Previous studies using patient satisfaction as the primary outcome measurement are few and based on small study samples. One example is a study by Bolster and Bakker (2009) where 92% of the 12 patients reported, at an average 10-month follow-up, satisfaction with the result of decompression of the radial nerve. Tomaino and co-worker (2001) reported a 100% satisfied result 38 months after surgery in their study of 16 patients who underwent *in situ* ulnar nerve release with medial epicondylectomy.

We found only one other study that used subjective improvement as an outcome measurement after surgery for ulnar neuropathy (Novak et al., 2002). They used a telephone interview to assess subjective improvement after transposition, and reported that 75% of the patients considered themselves to be improved at follow-up after 37 months.

The results presented in those papers are better than the findings in our study, and this may possibly be explained by differences in group size, variation in surgical techniques, follow-up times and patient selection. Another explanation might be that in the present study, Paper V, surgeons were not involved in the assessments.

Surgical nerve decompression in the forearm can be looked upon as a treatment that provides help to a majority of patients where other options have failed. In this study, on the other hand, surgery may be regarded as unnecessary for a large proportion of the patients. This underlines the need for improved diagnostic accuracy and algorithms for patient selection. The lack of high quality prospective studies is obvious.

In the light of these findings it may be argued that since most patients benefitted from treatment and few reported aggravation of symptoms, surgery may be justifiable when conservative treatment has been found insufficient.

TREATMENT STRATEGIES FOR EPICONDYLALGIA

Most patients in published papers suffer from chronic epicondylalgia (Tennis elbow), i.e. duration of pain and discomfort longer than 3 months (Zeisig, 2008) (BS). In this thesis we have discussed treatment of more or less chronic stages of epicondylalgia. The natural course of epicondylalgia is not fully understood and the results of all interventions performed within a time frame of at least one year must be looked upon with some reservation. Most publications discussing a natural course refer to studies in which some form of conservative management is included.

In the acute phase some of the treatment methods used by physiotherapists and occupational therapists in primary health-care are ranked according to effectiveness: patient education - ergonomic modification and risk factors; rest and activity modification; stretch exercise wrist orthosis and counter force brace; iontophoresis and ice; (MacDermid et al., 2010). At the same time the general practitioner might try injection with corticosteroids, since some studies have shown very vague evidence for a short-term effect. Oral medication with NSAIDs, whose beneficial effect in the chronic phase is unknown, may also be tried at this stage.

If, after approximately three months of management, the disorder is not in remission, eccentric exercises are introduced. Eccentric training will usually be

implemented beyond the initial acute phase. The remodelling phase, characterised by increased collagen cross-linkage, appears a more favourable time to begin training (Croisier et al., 2007). This programme continues for 12 weeks, and is followed up at 3, 6 and 12 months.

If by then the result is unsatisfactory, surgery might be the only option. Lateral release of the common muscle origin is then recommended (Goldie, 1964; Verhaar et al., 1993; Boyer and Hastings, 1999).

TREATMENT STRATEGIES FOR NERVE ENTRAPMENTS

Conservative management is the main-stay for compression neuropathies of the forearm. The generally recommended management period in the literature, is approximately three months (Langberg et al., 2007).

During this time the following options are available: patient education- rest and activity modification; orthosis/splints; pain management; nerve gliding exercises; and NSAIDs (Tetro and Pichora, 1996; Spinner and Amadio, 2003, Tsai and Steinberg, 2008).

If symptoms remain despite exhaustive non-operative measures, surgery is indicated (Tetro and Pichora, 1996; Spinner and Amadio, 2003; Tsai and Steinberg, 2008). Simple decompression is preferable (Filippi et al., 2002; Bartels et al., 2005).

CONCLUSIONS

The aim of this thesis was to investigate the effectiveness of conservative management in LE and ME, conservative treatment of ulnar nerve entrapment, surgical treatment of LE, and surgical treatment of nerve entrapments in the forearm. The following conclusions were drawn:

1. Conservative management including a programme of eccentric exercises and static stretch can decrease pain and increase grip strength in patients with LE or/and ME (Papers I and V).
2. Conservative management including a programme consisting of patient information alone or combined with nerve gliding exercises or a night splint can improve nerve dysfunction and reduce activity impairment in patients suffering from mild to moderate CuTS (Paper III).
3. Surgery with lateral release of the CEO will reduce symptoms in most patients with refractory LE (Paper II).
4. Surgery with simple decompression of the radial, median or/and ulnar nerves may reduce pain in the majority of patients with RTS, PS or/and CuTS (Paper IV).
5. There were no adverse effects in the conservatively managed patients, but among the surgically treated patients 12% rated themselves as worse after nerve decompression in the forearm (Paper IV).

FUTURE RESEARCH

In order to be able to improve the management of epicondylalgia and nerve entrapment we need a better understanding of the pathomechanics and natural course of these disorders, as well as detailed knowledge of the mechanisms behind the effects of eccentric exercises on tendinopathy. We also need:

1. General agreement on which assessment systems should be used for a specific condition. These instruments must be validated and translated into the respective language.
2. Larger RCT studies comparing different methods for treating nerve compression.
3. Larger RCT studies comparing eccentric exercises directly with other treatment modes.
4. Studies comparing treatment intervention with no treatment – the natural course.

SAMMANSTÄLLNING PÅ SVENSKA

(Popular scientific abstract in Swedish)

Smärttillstånd kring armbågen är vanligt förekommande och en av de mest frekventa orsakerna till arbetsrelaterade hälsoproblem. Även vardagsliv och fritidsaktiviteter kan i uttalade fall vara påverkade, vilket gör dessa åkommor betydelsefulla ur ett folkhälsoperspektiv. I de fall där en nerv är påverkad, kan känsel och motorik i handen vara försämrade.

"Tennisarmbåge" har rapporterats vara den, i primärvården, oftast diagnosticerade muskuloskelettala åkomsten i armen, ca 1 procent av befolkningen drabbas varje år. "Golfarmbåge" är inte lika frekvent förekommande. Tennisarmbåge och golfarmbåge anses av många vara självutläkande. Trots det har klinisk erfarenhet visat att en del personer har ett mycket långvarigt smärttillstånd, som står emot många behandlingar. I denna avhandlings följande fem delarbeten undersöktes resultaten av vanligen rekommenderade behandlingar för smärttillstånd kring armbågen belägna i muskel- och senfästen eller orsakade av nervinklämning:

I. Omfattar en pilotstudie, där excentrisk träning jämfördes med stretching för behandling av "tennisarmbåge". Den förra behandlingen befanns ge något bättre resultat och huvuddelen av arbetet utgörs av 4-års uppföljning av drygt 120 patienter som genomgått denna. Resultatet visade på minskad smärta och ökad greppstyrka. Vid tiden för publikation var detta den första studie som redovisat resultat av denna behandling för "tennisarmbåge".

II. Beskriver långtidsresultat hos 51 patienter som genomgått operation på grund av "kronisk tennisarmbåge", där konservativ behandling inte gett tillräcklig lindring. Resultatet visade en subjektiv förbättring, 87 procent av patienterna bedömde sig som helt bra eller bättre vid uppföljningen.

III. Är en studie av patienter med symptom från ulnarisnerven i armbågsnivå. Rekommenderade behandlingar som stödskena nattetid eller nervglidningsövningar jämfördes med en kontrollgrupp (endast information). Majoriteten av alla patienter förbättrades avsevärt både subjektivt och objektivt oavsett behandlingsgrupp.

IV. Är en långtidsuppföljning av 205 patienter, som genomgått kirurgisk behandling för misstänkta nervinklämningar kring armbågen. Uppföljning, nära 4 år efter operation, påvisade en subjektiv förbättring hos två tredjedelar av patienterna.

V. Omfattar en långtidsuppföljning av 20 patienter med "golfarmbåge", som behandlats med excentrisk (se ovan) muskelträning. Resultatet visade på minskad smärta och ökad greppstyrka. Inga tidigare studier finns publicerade med denna behandling för "golfarmbåge".

ACKNOWLEDGEMENTS

"We are advertis'd by our loving friends"; King Henry VI

(W. Shakespeare 1564-1616)

I wish to express my appreciation and gratitude to all of you who, in different ways, supported and helped me while working on this thesis

Lars Adolfsson, main supervisor and co-author for his dedication and persistence and razor-sharp intellectual guidance during this long and sometimes intense journey, for never giving up on me and always finding time for me despite himself having a very tight schedule

Göran Nylander, co-supervisor, co-author and inspirer for his support and outstanding knowledge as a senior researcher in the field of hand surgery

Gunnar Kratz, co-supervisor and subject coordinator always ready with advice or a helping hand whenever needed

Birgitta Öberg, head of the Dept of Medical and Health Sciences, Faculty of Health Sciences, Linköping University, for starting me up on this long endeavour

Mona Larsson, *Eva Hultgren* and *Karin Rhen*, co-authors, for various and valuable contributions in their respective areas of study

My *colleagues* at the Unit of Occupational and Physiotherapy at the Dept of Plastic Surgery, Hand Surgery and Burns, Linköping University hospital, for invaluable help with photos and picture editing

Olle Eriksson and *Karl Wahlin*, statisticians, for greatly appreciated help in the statistical analysis of the fourth and fifth manuscripts

ACKNOWLEDGEMENTS

Peter Cox, 'Jolly English anaesthetist', for his exceptional linguistic revision of this thesis

Ingegerd Wranne, a dear and long-time friend, for excellent skills in illustrating the muscles around the epicondyles

Johan Scheer, within the same research group, for taking the time to read the thesis, giving me valuable and constructive criticism

The *librarians* at the Faculty of Health Sciences, for their exceptional services and support

Ingrid Steinvall, a dear friend and former colleague, for relentlessly giving me so much time as well as valuable and practical “hands on” support

Eva Granfeldt, a close friend and former head of the Division of Occupational and Physical Therapy, Dept of Plastic Surgery, Hand surgery and Burns, Linköping University hospital, for always supporting, cheering and comforting me whatever stage I have been in

Dag, wonderful husband and life-time best friend, for always believing in me and endlessly supporting me

REFERENCES

- Alfredson H, Pietilä T, Jonsson P, Lorentzon R. Heavy-load eccentric calf muscle training for the treatment of chronic Achilles tendinosis. *Am J Sports Med*. 1998. May-Jun; 26(3):360-6.
- Alfredson H, Ljung B-O, Thorsen K, Lorentzon R. In vivo investigation of ECRB tendons with microdialysis technique: No signs of inflammation but high amounts of glutamate in tennis elbow. *Acta Orthop Scand*. 2000 Oct; 71(5):475-9.
- Alfredson H. Chronic midportion Achilles tendinopathy: an update on research and treatment. *Clin Sports Med*. 2003; 22:727–41.
- Allander E. Prevalence, incidence and remission rates of some common rheumatic diseases and syndromes. *Scand J Rheumatol*. 1974; 3:145–153.
- Almekinders LC, Almekinders SV. Outcome in the treatment of chronic overuse sports injuries: a retrospective study. *J Orthop Sports Phys Ther*. 1994 Mar; 19(3):157-61.
- Almekinders LC, Temple JD. Etiology, diagnosis, and treatment of tendinitis: an analysis of the literature. *Med Sci Sports Exerc*. 1998; 30:1183–90.
- Andreisek G, Crook DW, Burg D, Marincek B, Weishaupt D. Peripheral neuropathies of the median, radial, and ulnar nerves: MR imaging features. *Radiographics*. 2006 Sep-Oct; 26 (5):1267-87. Review
- Apfelberg DB, Larson SJ. Dynamic anatomy of the ulnar nerve at the elbow. *Plast Reconstr Surg*. 1973 Jan; 51(1):79-81.
- Ashe MC, McCauley T, Khan KM. Tendinopathies in the upper extremity: a paradigm shift. *J Hand Ther*. 2004; 17:329–34.
- Assendelft W, Green S, Buchbinder R, Struijs P, Smidt N. Tennis elbow (lateral epicondylitis). *Clin Evid*. 2002 Dec; (8):1290-300. Review.
- Atroshi I, Gummesson C, Andersson B, Dahlgren E, Johansson A. The disabilities of the arm, shoulder and hand (DASH) outcome questionnaire: reliability and validity of the Swedish version evaluated in 176 patients. *Acta Orthop Scand*. 2000 Dec; 71 (6):613-8.

- Bankes MJ, Jessop JH. Day-case simple extensor origin release for tennis elbow. *Arch Orthop Trauma Surg.* 1998; 117 (4-5):250-1.
- Barnum M, Mastey RD, Weiss AP, Akelman E. Radial tunnel syndrome. *Hand Clin.* 1996 Nov; 12(4):679-89.
- Bartels RH, Menovsky T, van Overbeeke JJ, Verhagen W. Surgical management of ulnar nerve compression at the elbow: an analysis of the literature. *J Neurosurg.* 1998 Nov;89 (5):722-7. Review.
- Bartels RH. History of the Surgical Treatment of Ulnar Nerve Compression at the Elbow. *Neurosurgery.* 2001 Aug; 49(2):391-9; discussion 399-400. Review.
- Bartels RH, Termeer EH, van der Wilt GJ, van Rossum LG, Meulstee J, Verhagen WI, Grotenhuis JA. Simple decompression or anterior subcutaneous transposition for ulnar neuropathy at the elbow: a cost-minimization analysis--Part 2. *Neurosurgery.* 2005 Mar; 56 (3):531-6; discussion 531-6.
- Bartels RH, Verbeek AL. Risk factors for ulnar nerve compression at the elbow: a case control study. *Acta Neurochir (Wien).* 2007; 149 (7):669-74; discussion 674.
- Biggs M, Curtis JA. Randomized, prospective study comparing ulnar neurolysis in situ with submuscular transposition. *Neurosurgery.* 2006 Feb; 58 (2):296-304; discussion 296-304.
- Bijur PE, Silver W, Gallagher EJ. Reliability of the visual analog scale for measurement of acute pain. *Acad Emerg Med.* 2001 Dec; 8(12):1153-7.
- Binder AI, Hazleman BL. Lateral humeral epicondylitis--a study of natural history and the effect of conservative therapy. *Br J Rheumatol.* 1983 May; 22(2):73-6.
- Binzer M, Kullgren G. Motor conversion disorder. A prospective 2- to 5-year follow-up study. *Psychosomatics.* 1998 Nov-Dec; 39(6):519-27.
- Bisset L, Paungmali A, Vicenzino B, Beller E. A systematic review and meta-analysis of clinical trials on physical interventions for lateral epicondylalgia. *Br J Sports Med.* 2005 Jul; 39(7):411-22; discussion 411-22. Review.
- Bisset LM, Russell T, Bradley S, et al. Bilateral sensorimotor abnormalities in unilateral lateral epicondylalgia. *Arch Phys Med Rehabil* 2006; 87:490-5.

- Blanchette MA, Normand MC. Augmented soft tissue mobilization vs natural history in the treatment of lateral epicondylitis: a pilot study. *J Manipulative Physiol Ther.* 2011 Feb; 34(2):123-30.
- Bolster MA, Bakker XR. Radial tunnel syndrome: emphasis on the superficial branch of the radial nerve. *J Hand Surg Eur Vol.* 2009 Jun; 34(3):343-7.
- Boyer MI, Hastings H. Lateral tennis elbow: "Is there any science out there?" *J Shoulder Elbow Surg.* 1999 Sep-Oct; 8(5):481-91.
- Brooks, R. (1996). EuroQual: The current state of play. *Health Policy*, 37, 53–72.
- Buchbinder R, Green SE, Struijs P. Tennis elbow. *Clin Evid (Online).* 2008 May 28.
- Bunata RE, Brown DS, Capelo R. Anatomic factors related to the cause of tennis elbow. *J Bone Joint Surg Am* 2007; 89:1955–1963.
- Caliandro P, La Torre G, Padua R, Giannini F, Padua L. Treatment for ulnar neuropathy at the elbow. *Cochrane Database Syst Rev.* 2011 Feb 16;(2). Review.
- Chard MD, Hazleman BL. Tennis elbow--a reappraisal. *Br J Rheumatol.* 1989 Jun; 28(3):186-90. Review.
- Chémali KR, Tsao B. Electrodiagnostic testing of nerves and muscles: when, why, and how to order. *Cleve Clin J Med.* 2005 Jan; 72(1):37-48.
- Choinière M, Amsel R. A visual analogue thermometer for measuring pain intensity. *J Pain Symptom Manage.* 1996 May;11 (5):299-311.
- Chop WM Jr. Tennis elbow. *Postgrad Med.* 1989 Oct; 86(5):301-4, 307-8. Review
- Ciccotti MC, Schwartz MA, Ciccotti MG. Diagnosis and treatment of medial epicondylitis of the elbow. *Clin Sports Med* 2004; 23:693–705.
- Cook J, Vicenzino B. Exercise for the treatment of Tendinopathy. Kibler W, ed. *OKU Sports Medicine 4. American Academy of Orthopaedic Surgeons.* Rosemont, Illinois, USA. 2009:313–18.39, 49
- Coombes BK, Bisset L, Vicenzino B. A new integrative model of lateral epicondylalgia. *Br J Sports Med* 2009;43(4):252–8
- Coonrad RW, Hooper WR. Tennis elbow: its course, natural history, conservative and surgical management. *J Bone Joint Surg.* 1973; 55A:1177-1182.

- Coppieters MW, Bartholomeeusen KE, Stappaerts KH. Incorporating nerve-gliding techniques in the conservative treatment of cubital tunnel syndrome. *J Manipulative Physiol Ther.* 2004 Nov-Dec; 27(9):560-8.
- Croisier JL, Foidart-Dessalle M, Tinant F, Crielaard JM, Forthomme B. An isokinetic eccentric programme for the management of chronic lateral epicondylar tendinopathy. *Br J Sports Med.* 2007 Apr; 41(4):269-75.
- Curwin S, Stanish WD. *Tendinitis: Its etiology and treatment.* Lexington, MA: Collamore Press, 1984: 115–132.
- Cyriax JH. The pathology and treatment of tennis elbow. *J. Bone Joint Surg.* 1936;18:921-40
- Cyriax J. *Textbook of Orthopaedic Medicine Volume One: Diagnosis of Soft Tissue Lesions.* 8th ed. London, England: Bailliere Tindall; 1982.
- Dang AC, Rodner CM. Unusual compression neuropathies of the forearm, part II: median nerve. *J Hand Surg Am.* 2009 Dec; 34(10):1915-20.
- Dawson DM, Hallett M, Millender LH. Radial nerve entrapment. In: *Entrapment neuropathies.* 1st ed. Boston, Little, Brown and Co, 1983 pp141-168.
- Dawson DM. Entrapment neuropathies of the upper extremities. *N Engl J Med.* 1993 Dec 30; 329(27):2013-8.
- Dedding C, Cardol M, Eyssen IC, Dekker J, Beelen A. Validity of the Canadian Occupational Performance Measure: a client-centred outcome measurement. *Clin Rehabil.* 2004 Sep;18 (6):660-7.
- Dellon AL, Hament W, Gittelshon A. Nonoperative management of cubital tunnel syndrome: an 8-year prospective study. *Neurology.* 1993 Sep; 43(9):1673-7.
- Descatha A, Leclerc A, Chastang JF, Roquelaure Y. Medial epicondylitis in occupational settings: prevalence, incidence and associated risk factors. *J Occup Environ Med/American College of Occupational and Environmental Medicine* 2003 Sep; 45(9):993–1001.

- De Smet L, Van Ransbeeck H, Fabry G. Grip strength in tennis elbow: long-term results of operative treatment. *Acta Orthop Belg.* 1998 Jun; 64(2):167-9.
- Doornberg JN, Ring D, Fabian LM, Malhotra L, Zurakowski D, Jupiter JB. Pain dominates measurements of elbow function and health status. *J Bone Joint Surg Am.* 2005 Aug; 87(8):1725-31
- Downie WW, Leatham PA, Rhind VW, Wright V, Branco JA, Anderson JA. Studies with pain rating scales. *Ann Rheum Dis.* 1978; 37:378–81.
- Dunkow PD, Jatti M, Muddu BN. A comparison of open and percutaneous techniques in the surgical treatment of tennis elbow. *J Bone Joint Surg Br* 2004; 86-B: 701–704.
- Dunn JH, Kim JJ, Davis L, Nirschl RP. Ten- to 14-year follow-up of the Nirschl surgical technique for lateral epicondylitis. *Am J Sports Med.* 2008 Feb; 36(2):261-6.
- Eaton RG, Crowe JF, Parkes JC 3rd. Anterior transposition of the ulnar nerve using a non-compressing fasci dermal sling. *J Bone Joint Surg Am.* 1980 Jul; 62(5):820-5.
- Eisen A, Danon J. The mild cubital tunnel syndrome. Its natural history and indications for surgical intervention. *Neurology.* 1974 Jul; 24(7):608-13.
- Ekberg K, Bjorkqvist B, Malm P, Bjerre-Kiely B, Karlsson M, Axelson O. Case-control study of risk factors for disease in the neck and shoulder area. *Occup Environ Med.* 1994. 51(4): 262-6.
- Elhassan B, Steinmann SP. Entrapment neuropathy of the ulnar nerve. *J Am Acad Orthop Surg.* 2007;15 :672– 681.
- el Hawary R, Stanish WD, Curwin SL. Rehabilitation of tendon injuries in sport. *Sports Med.* 1997;24:347–58.
- Ernst E. Conservative therapy for tennis elbow. *Br J Clin Pract.* 1992 Spring; 46(1):55-7.
- Eversmann WW Jr. Entrapment and compression neuropathies. In: Green DP, ed. *Operative hand surgery.* 3rd ed. New York: Churchill Livingstone; 1993. p 1341-85.
- Feindel W, Stratford J. The role of the cubital tunnel in tardy ulnar palsy. *Can J Surg.* 1958 Jul; 1(4):287-300.

- Fernández-Carnero J, Fernández-de-las-Peñas C, Sterling M, Souvliis T, Arendt-Nielsen L, Vicenzino B. Exploration of the extent of somato-sensory impairment in patients with unilateral lateral epicondylalgia. *J Pain*. 2009 Nov;10 (11):1179-85.
- Field, LD, Savoie, FH. Common Elbow Injuries in Sport. *Sports Med*. 1998 Sep; 26 (3): 193-205.
- Filippi, R., Farag, S., Reisch, R., et al. Cubital tunnel syndrome. Treatment by decompression without transposition of ulnar nerve. *Minim Invasive Neurosurg*. 45: 164-168, 2002.
- Fridén J, Lieber RL. Physiologic consequences of surgical lengthening of extensor carpi radialis brevis muscle-tendon junction for tennis elbow. *J Hand Surg Am*. 1994 Mar;19 (2):269-74
- Gaston-Johansson F. Measurement of pain: the psychometric properties of the Pain-O-Meter, a simple, inexpensive pain assessment tool that could change health care practices. *J Pain Symptom Manage*. 1996;12:172–81.
- Gellman H. Tennis elbow (lateral epicondylitis). *Orthop Clin North Am*. 1992; 23:75–82.
- Gold JE, d’Errico A, Katz JN, Gore R, Punnett L. Specific and non-specific upper extremity musculoskeletal disorder syndromes in automobile manufacturing workers. *American Journal of Industrial Medicine* 2009 Feb; 52(2):124–32.
- Goldie I. Epicondylitis lateralis humeri (epicondylalgia or tennis elbow). *Acta Chir. Scand*. 1964; Suppl 339.
- Gong HS, Chung MS, Kang ES, et al. Musculofascial lengthening for the treatment of patients with medial epicondylitis and coexistent ulnar neuropathy. *J Bone Joint Surg Br*. 2010;92:823-7.
- Greenwald D, Blum LC 3rd, Adams D, Mercantonio C, Moffit M, Cooper B. Effective surgical treatment of cubital tunnel syndrome based on provocative clinical testing without electrodiagnostics. *Plast Reconstr Surg*. 2006 Apr 15;117 (5):87-91.
- Goldfarb C. “Cubital tunnel syndrome and radial tunnel syndrome,” in *Hand surgery Update IV*. Rosemont American Society for Surgery of the Hand, T. E. Trumble and J. E. Budoff, Eds., p. 409, 2007.

- Haahr JP, Andersen JH. Prognostic factors in lateral epicondylitis: a randomized trial with one-year follow-up in 266 new cases treated with minimal occupational intervention or the usual approach in general practice. *Rheumatology (Oxford)*. 2003 Oct; 42(10):1216–25.
- Haker E. Lateral epicondylalgia (tennis elbow). A diagnostic and therapeutic challenge. Doctoral Thesis, KarolinskaInstitutet, Stockholm, 1991.
- Hall HC, MacKinnon SE, Gilbert RW. An approach to the posterior interosseous nerve. *Plast Reconstr Surg*. 1984 Sep; 74(3):435-7.
- Halpern AA, Nagel DA. Compartment syndromes of the forearm: early recognition using tissue pressure measurements. *J Hand Surg Am*. 1979 May; 4(3):258-63.
- Hamilton P. The prevalence of humeral epicondylitis: a survey in general practice. *J R Coll Gen Pract* 1986; 36:464–465.
- Hartz CR, Linscheid RL, Gramse RR, Daube JR. The pronator teres syndrome: compressive neuropathy of the median nerve. *J Bone Joint Surg Am*. 1981 Jul; 63(6):885-90.
- Helliwell PS. Regional musculoskeletal pain. The elbow, forearm, wrist and hand. *Baillieres Best Pract Res Clin Rheumatol*. 1999 Jun;13 (2):311-28. Review.
- Henry AK. Extensile exposure applied to limb surgery. 2nd ed. Baltimore, MD: Williams and Wilkins; 1957.
- Hong CZ, Long HA, Kanakamedala RV, Chang YM, Yates L. Splinting and local steroid injection for the treatment of ulnar neuropathy at the elbow: clinical and electrophysiological evaluation. *Arch Phys Med Rehab*. 1996, 77: 573–7.
- Hong QN, Durand MJ, Loisel P. Treatment of lateral epicondylitis: where is the evidence? *Joint Bone Spine*. 2004 Sep; 71(5):369-73.
- Hudak P, Cole D, Haines T. Understanding prognosis to improve rehabilitation: the example of lateral elbow pain. *Arch Phys Rehabil* 1996a;77:568–593.
- Hudak PL, Amadio PC, Bombardier C. Development of an upper extremity outcome measure: the DASH (disabilities of the arm, shoulder and hand) [corrected]. *The*

- Upper Extremity Collaborative Group (UECG) Am J Ind Med. 1996b Jun; 29(6):602-8.
- Huisstede B, Miedema HS, van Opstal T, de Ronde MT, Verhaar JA, Koes BW. Interventions for treating the radial tunnel syndrome: a systematic review of observational studies. J Hand Surg Am. 2008 Jan; 33(1):72-8. Review.
- Hume PA, Reid D, Edwards T. Epicondylar injury in sport: epidemiology, type, mechanisms, assessment, management and prevention. Sports Med. 2006; 36(2):151-70.
- Idler RS. General principles of patient evaluation and nonoperative management of cubital tunnel syndrome. Hand Clin. 1996 May; 12 (2):397-403.
- Janda V. Muskelfunktionsdiagnostik. Studentlitteratur, Lund, 1977.
- Jobe FW, Ciccotti MG. Lateral and medial epicondylitis of the elbow. J Am Acad Orthop Surg. 1994; 2:1- 8.
- Kamen, Gary. Electromyographic Kinesiology. In Robertson, DGE et al. Research Methods in Biomechanics. Champaign, IL: Human Kinetics Publ., 2004.
- Kamien M. Tennis elbow in long-time tennis players. Aust J Sci Med Sport. 1988; 20 (2): 19-27
- Khan KM, Cook JL, Bonar F, Harcourt P, Astrom M. Histopathology of common tendinopathies: update and implications for clinical management. Sports Med. 1999; 27:393-408.
- Khan K, Cook J. The painful nonruptured tendon: clinical aspects. Clin Sports Med. 2003; 22:711-25.
- King GJ, Richards RR, Zuckerman JD, Blasier R, Dillman C, Friedman RJ, Gartsman GM, Iannotti JP, Murnahan JP, Mow VC, Woo SL. A standardized method for assessment of elbow function. Research Committee, American Shoulder and Elbow Surgeons. J Shoulder Elbow Surg. 1999 Jul-Aug; 8(4):351-4.
- Kleinman WB, Bishop AT. Anterior intramuscular transposition of the ulnar nerve. J Hand Surg Am. 1989 Nov; 14 (6):972-9.

- Kohn HS. Prevention and treatment of elbow injuries in golf. *Clin Sports Med.* 1996;15: 65-83.
- Kivi P. The etiology and conservative treatment of lateral epicondylitis. *Scand J Rehabil Med.* 1983;15: 37-41.
- Knobloch K, Kraemer R, Jagodzinski M, Zeichen J, Meller R, Vogt PM. Eccentric training decreases paratendon capillary blood flow and preserves paratendon oxygen saturation in chronic achilles tendinopathy. *J Orthop Sports Phys Ther.* 2007a May;37 (5):269-76.
- Knobloch K. Eccentric rehabilitation exercise increases peritendinous type I collagen synthesis in humans with Achilles tendinosis. *Scand J Med Sci Sports.* 2007b Jun;17 (3):298-9.
- Knobloch K. Eccentric training and the science behind. *Med Sci Sports Exerc.* 2009a Jan; 41(1):251; author reply 252.
- Knobloch K. Comment on: "The mechanism for efficacy of eccentric loading in Achilles tendon injury: an in vivo study in humans". *Rheumatology (Oxford).* 2009b Feb;48 (2):202-3; author reply 203.
- Kraushaar BS, Nirschl RP. Tendinosis of the elbow (tennis elbow): clinical features and findings of histological, immunohistochemical, and electron microscopy studies. *J Bone Joint Surg Am.* 1999;81:259-78.
- Krischek O, Hopf C, Nafe B, Rompe JD. Shock-wave therapy for tennis and golfer's elbow--1 year follow-up. *Arch Orthop Trauma Surg.* 1999;119(1-2):62-6.
- Kuschner SH. Cubital tunnel syndrome. Treatment by medial epicondylectomy. *Hand Clin.* 1996 May;12 (2):411-9.
- Labelle H, Guibert R, Joncas J, Newman N, Fallaha M, Rivard CH. Lack of scientific evidence for the treatment of lateral epicondylitis of the elbow: an attempted meta-analysis. *J Bone Joint Surg Br.* 1992; 74: 646-51.
- Langberg H, Ellingsgaard H, Madsen T, Jansson J, Magnusson SP, Aagaard P, Kjaer M. Eccentric rehabilitation exercise increases peritendinous type I collagen

- synthesis in humans with Achilles tendinosis. *Scand J Med Sci Sports*. 2007 Feb;17 (1):61-6.
- Langberg H, Kongsgaard M. Eccentric training in tendinopathy--more questions than answers. *Scand J Med Sci Sports*. 2008 Oct;18 (5):541-2.
- Latinovic R, Gulliford MC, Hughes RA. Incidence of common compressive neuropathies in primary care. *J Neurol Neurosurg Psychiatry*. 2006 Feb; 77 (2):263-5.
- Law M, Baptiste S, McColl MA, Opzoomer A, Polatajko H, Pollock N. The Canadian Occupational Performance Measure: an outcome measure for occupational therapy. *Can J Occup Ther*. 1990, 57: 82-7.
- Law M, Polatajko H, Pollock N, McColl MA, Carswell A, Baptiste S. Pilot testing of the Canadian Occupational Performance Measure: clinical and measurement issues. *Can J Occup Ther*. 1994, 61: 191-7.
- Law M, Baptiste S, Carswell A, McColl MA, Polatajko H, Pollock N. Canadian Occupational Performance Measure, third edition. Ottawa: CAOT Publications ACE, 1998.
- Leach RE, Miller JK. Lateral and medial epicondylitis of the elbow. *Clin Sports Med*. 1987 Apr; 6 (2):259-72.
- Lee MJ, LaStayo PC. Pronator syndrome and other nerve compressions that mimic carpal tunnel syndrome. *J Orthop Sports Phys Ther*. 2004 Oct; 34 (10):601-9.
- Lee JT, Azari K, Jones NF. Long term results of radial tunnel release--the effect of co-existing tennis elbow, multiple compression syndromes and workers' compensation. *J Plast Reconstr Aesthet Surg*. 2008 Sep; 61(9):1095-9.
- Leffler AS, Kosek E, Hansson P. The influence of pain intensity on somatosensory perception in patients suffering from subacute/chronic lateral epicondylalgia. *Eur J Pain*. 2000;4(1): 57-71.
- Levin D, Nazarian LN, Miller TT, et al. Lateral epicondylitis of the elbow: US findings. *Radiology* 2005; 237:230-234.

- Lieber RL, Ljung BO, Fridén J. Sarcomere length in wrist extensor muscles. Changes may provide insights into the etiology of chronic lateral epicondylitis. *Acta Orthop Scand*. 1997 Jun; 68(3):249-54.
- Lister GD, Belsole RB, Kleinert HE. The radial tunnel syndrome. *J Hand Surg Am*. 1979 Jan; 4(1):52-9
- Ljung BO, Forsgren S, Fridén J. Substance P and calcitonin gene-related peptide expression at the extensor carpi radialis brevis muscle origin: implications for the etiology of tennis elbow. *J Orthop Res*. 1999a Jul; 17 (4):554-9.
- Ljung BO, Forsgren S, Fridén J. Sympathetic and sensory innervations are heterogeneously distributed in relation to the blood vessels at the extensor carpi radialis brevis muscle origin of man. *Cells Tissues Organs*. 1999b; 165(1):45-54.
- Ljung BO, Alfredson H, Forsgren S. Neurokinin 1-receptors and sensory neuropeptides in tendon insertions at the medial and lateral epicondyles of the humerus. Studies on tennis elbow and medial epicondylalgia. *J Orthop Res*. 2004 Mar; 22(2):321-7.
- Lo MY, Safran MR. Surgical treatment of lateral epicondylitis: a systematic review. *Clin Orthop Relat Res*. 2007 Oct; 463:98-106.
- Longo UG, Franceschi F, Loppini M, Maffulli N, Denaro V. Rating systems for evaluation of the elbow. *Br Med Bull*. 2008; 87:131-61.
- McCarroll JR, Rettig AC, Shelbourne KD. Injuries in the amateur golfer. *The Physician and Sports Medicine* 1990; 18: 122-126.
- McCormack HM, Horne DJ, Sheather S. Clinical applications of visual analogue scales: a critical review. *Psychol Med*. 1988; 18:1007-19.
- MacDermid JC . Outcome evaluation in patients with elbow pathology: issues in instrument development and evaluation. *J Hand Ther*. 2001 Apr-Jun; 14 (2):105-14. Review.
- Mahieu NN, McNair P, Cools A, D'Haen C, Vandermeulen K, Witvrouw E. Effect of eccentric training on the plantar flexor muscle-tendon tissue properties. *Med Sci Sports Exerc*. 2008 Jan; 40 (1):117-23.

- Manias P, Stasinopoulos D. A controlled clinical pilot trial to study the effectiveness of ice as a supplement to the exercise programme for the management of lateral elbow tendinopathy. *Br J Sports Med*. 2006 Jan;40 (1):81-5.
- Mathiowetz V, Weber K, Volland G, Kashman N. Reliability and validity of grip and pinch strength evaluations. *J Hand Surg Am*. 1984 Mar;9 (2):222-6.
- Martinez-Silvestrini JA, Newcomer KL, Gay RE, et al. Chronic lateral epicondylitis: Comparative effectiveness of a home exercise program including stretching alone versus stretching supplemented with eccentric or concentric strengthening. *J Hand Therapy* 2005;18: 411–420.
- Medical Research Council. Aids to the examination of the peripheral nervous system, Memorandum no. 45, Her Majesty's Stationery Office, London, 1981.
- Miller TT. Imaging of elbow disorders. *Orthop Clin North Am*. 1999; 30:21-36.
- Miller BF, Olesen JL, Hansen M, Døssing S, Crameri RM, Welling RJ, Langberg H, Flyvbjerg A, Kjaer M, Babraj JA, Smith K, Rennie MJ. Coordinated collagen and muscle protein synthesis in human patella tendon and quadriceps muscle after exercise. *J Physiol*. 2005 Sep 15; 567(Pt 3):1021-33.
- Mondelli M, Giannini F, Ballerini M, Ginanneschi F, Martorelli E. Incidence of ulnar neuropathy at the elbow in the province of Siena (Italy). *J Neurol Sci*. 2005 Jul 15; 234(1-2):5-10.
- Morrey BF, An KN, Chao EY. The elbow and its disorders. Functional evaluation of the elbow, 1993, Philadelphia, PA:USA: W.B.Saunders. 86-97.
- Morrison DL. Tennis elbow and radial tunnel syndrome: differential diagnosis and treatment. *J Am Osteopath Assoc*. 1981 Aug; 80(12):823-6.
- Murtagh J. Tennis elbow. *Aust Fam Physician*. 1988; 17:90–91,94–95.
- Nabhan A, Ahlhelm F, Kelm J, Reith W, Schwerdtfeger K, Steudel WI. Simple decompression or subcutaneous anterior transposition of the ulnar nerve for cubital tunnel syndrome. *J Hand Surg Br*. 2005 Oct; 30(5):521-4.

- Nathan PA, Keniston RC, Meadows KD. Outcome study of ulnar nerve compression at the elbow treated with simple decompression and an early programme of physical therapy. *J Hand Surg Br.* 1995 Oct;20 (5):628-37.
- Nathan PA, Istvan JA, Meadows KD. Intermediate and long-term outcomes following simple decompression of the ulnar nerve at the elbow. *Chir Main.* 2005 Feb; 24(1):29-34.
- Nilsson P, Baigi A, Marklund B, Månsson J. Cross-cultural adaptation and determination of the reliability and validity of PRTEE-S (Patientskattad Utvärdering av Tennisarmbåge), a questionnaire for patients with lateral epicondylalgia, in a Swedish population. *BMC Musculoskelet Disord.* 2008 Jun 5;9: 79.
- Nirschl RP, Pettrone FA. Tennis elbow. The surgical treatment of lateral epicondylitis. *J Bone Joint Surg Am.* 1979 Sep; 61(6A):832-9.
- Nirschl RP. Medial tennis elbow, surgical treatment. *Orthop Trans Am Acad Orthop Surg.* 1980; 7: 298-302.
- Nirschl RP. Elbow tendinosis/tennis elbow. *Clin Sports Med.* 1992 Oct;11 (4):851-70. Review.
- Novak CB, Lee GW, Mackinnon SE, Lay L. Provocative testing for cubital tunnel syndrome. *J Hand Surg Am.* 1994 Sep;19 (5):817-20.
- Novak CB, Mackinnon SE, Stuebe AM. Patient self-reported outcome after ulnar nerve transposition. *Ann Plast Surg.* 2002 Mar;48 (3):274-80.
- Novak CB. Evaluation of the nerve-injured patient. *Clin Plast Surg.* 2003 Apr; 30(2):127-38.
- O'Dwyer K, Howie C. Medial epicondylitis of the elbow. *Int Orthop.* 1995; 19:69-71.
- Paavola M, Kannus P, Paakkala T, et al. Long-term prognosis of patients with Achilles tendonitis. *Am J Sports Med.* 2000;28 :634-42.
- Page N. A new exercise for tennis elbow that works! *Am J Sports Phys Ther.* 2010 Sep; 5(3):189-93.
- Pensini M, Martin A, Maffiuletti NA. Central versus peripheral adaptations following eccentric resistance training. *Int J Sports Med.* 2002 Nov; 23(8):567-74.

- Peolsson A, Hedlund R, Oberg B. Intra- and inter-tester reliability and reference values for hand strength. *J Rehabil Med*. 2001 Jan; 33(1):36-41.
- Pienimäki TT, Siira PT, Vanharanta H. Chronic medial and lateral epicondylitis: a comparison of pain, disability, and function. *Arch Phys Med Rehabil*. 2002 Mar;83(3):317-21.
- Piligian G, Herbert R, Hearn M, Dropkin J, Landsbergis P, Cherniack M. Evaluation and management of chronic work-related musculoskeletal disorders of the distal upper extremity. *Am J Ind Med*. 2000 Jan; 37(1):75-93.
- Posner MA. Compressive neuropathies of the median and radial nerves at the elbow. *Clin Sports Med*. 1990 Apr; 9(2):343-63. Review.
- Posner MA. Compressive neuropathies of the ulnar nerve at the elbow and wrist. *Instr Course Lect* 2000;49:305-317.
- Radpasand M. Combination of manipulation, exercise, and physical therapy for the treatment of a 57-year-old woman with lateral epicondylitis. *J Manipulative Physiol Ther*. 2009 Feb; 32(2):166-72.
- Rees JD, Wilson AM, Wolman RL. Current concepts in the management of tendon disorders. *Rheumatology (Oxford)*. 2006 May; 45(5):508-21. Review.
- Rees JD, Wolman RL, Wilson A. Eccentric exercises; why do they work, what are the problems and how can we improve them? *Br J Sports Med*. 2009 Apr; 43(4):242-6. Review.
- Rehak DC. Pronator syndrome. *Clin Sports Med*. 2001; 20:531-540.
- Rich BC, McKay MP. The Cubital Tunnel syndrome: a case report and discussion. *J Emerg Med*. 2002 Nov;23 (4):347-50.
- Rinker B, Effron CR, Beasley RW. Proximal radial compression neuropathy. *Ann Plast Surg*. 2004; 52:174-183.
- Rineer CA, Ruch DS. Elbow tendinopathy and tendon ruptures: epicondylitis, biceps and triceps ruptures. *J Hand Surg Am*. 2009 Mar; 34 (3):566-76. Review.
- Robertson C, Saratsiotis J. A review of compressive ulnar neuropathy at the elbow. *J Manipulative Physiol Ther*. 2005 Jun;28 (5):345.

- Roles NC, Maudsley RH. Radial tunnel syndrome: resistant tennis elbow as a nerve entrapment. *J Bone Joint Surg.* 1972; 4B:499–508.
- Roquelaure Y, Mariel J, Fanello S, Boissiere JC, Chiron H, Dano C, et al. Active epidemiological surveillance of musculoskeletal disorders in a shoe factory. *Occupational and Environmental Medicine* 2002 Jul; 59(7):452–8.
- Sailer SM. The role of splinting and rehabilitation in the treatment of carpal and cubital tunnel syndromes. *Hand Clin.* 1996 May;12 (2):223-41.
- Sarris IK, Papadimitriou NG, Sotereanos DG. Radial tunnel syndrome. *Tech Hand Up Extrem Surg.* 2002 Dec; 6(4):209-12.
- Sathyamoorthy P, Kemp GJ, Rawal A, Rayner V, Frostick SP (2004) Development and validation of an elbow score. *Rheumatology (Oxford).* 2004 Nov; 43(11):1434-40.
- Scott J, Huskisson EC. Vertical or horizontal visual analogue scales. *Ann Rheum Dis.* 1979; 38:560.
- Sellards R, Kuebrich C. The elbow: diagnosis and treatment of common injuries. *Prim Care.* 2005 Mar;32 (1):1-16. Review.
- Seyffarth H. Primary myositis in the M. pronator teres as cause of lesion of the N. medianus (the pronator syndrome). *Acta Psychiatr Neurol Scand Suppl.* 1951;74: 251-4.
- Shiri R, Viikari-Juntura E, Varonen H, Heliövaara M. Prevalence and determinants of lateral and medial epicondylitis: a population study. *Am J Epidemiol.* 2006 Dec 1;164 (11):1065-74.
- Shiri R, Viikari-Juntura E. Lateral and medial epicondylitis: role of occupational factors. *Best Pract Res Clin Rheumatol.* 2011 Feb;25(1):43-57. Review
- Smidt N, van der Windt DAWM, Assendelft WJJ, et al. Corticosteroid injections for lateral epicondylitis are superior to physiotherapy and a wait and see policy at short-term follow-up, but inferior at long-term follow-up: results from a randomised controlled trial. *Lancet* 2002; 359:657–662.
- Smidt N, van der Windt DA. Tennis elbow in primary care. *BMJ.* 2006 Nov 4; 333(7575):927-8.

- Solheim E, Hegna J, Øyen J. Extensor tendon release in tennis elbow: results and prognostic factors in 80 elbows. *Knee Surg Sports Traumatol Arthrosc.* 2011 Jun; 19(6):1023-7.
- Sotereanos DG, Varitimidis SE, Giannakopoulos PN, Westkaemper JG. Results of surgical treatment for radial tunnel syndrome. *J Hand Surg Am.* 1999 May;24 (3):566-70.
- Spinner RJ, Amadio PC. Compressive neuropathies of the upper extremity. *Clin Plast Surg* 2003; 30:155–173.
- Spinner, M. *Injury to the Major Branches of Peripheral Nerves of the Forearm* (2nd ed.) Philadelphia: Saunders, 1978.
- Stål M, Hagert CG, Englund JE. Pronator syndrome: a retrospective study of median nerve entrapment at the elbow in female machine milkers. *J Agric Saf Health.* 2004 Nov;10 (4):247-56.
- Stanish W.D., Rubinovich R.M., Curwin S. Eccentric exercise in chronic tendinitis. *Clin Orthop Relat Res.* 1986; 208:65-68.
- Stanley J. Radial tunnel syndrome: a surgeon's perspective. *J Hand Ther.* 2006 Apr-Jun;19(2):180-4. Review.
- Stasinopoulos D, Stasinopoulous K, Johnson MI. An exercise programme for the management of lateral elbow tendinopathy. *Br J Sports Med.* 2005 Dec; 39(12):944-7. Review.
- Stockard, AR. "Elbow injuries in golf." *The Journal of the American Osteopathic Association* 101.9 (2001): 509-16.
- Stratford PW, Levy DR. Assessing Valid Change over Time in Patients with Lateral Epicondylitis at the Elbow. *Clin J Sports Med.* 1994; 4:88–91.
- Sullivan M, Karlsson J, Ware JE Jr. The Swedish SF-36 Health Survey--I. Evaluation of data quality, scaling assumptions, reliability and construct validity across general populations in Sweden. *Soc Sci Med.* 1995 Nov; 41(10):1349-58.

- Söderberg J, Grooten WJ, Ang BO. Effects of eccentric training on hand strength in subjects with lateral epicondylalgia: a randomized-controlled trial. *Scand J Med Sci Sports*. 2011 Apr 18.
- Sölveborn SA. Radial epicondylalgia ('tennis elbow'): treatment with stretching or forearm band. A prospective study with long-term follow-up including range-of motion measurements. *Scand J Med Sci Sports*. 1997. 7(4): 229-37.
- Tetro AM, Pichora DR. High median nerve entrapments. An obscure cause of upper-extremity pain. *Hand Clin*. 1996 Nov; 12 (4):691-703.
- Thompson JE. Anatomical methods of approach in operations on the long bones of the extremities. *Ann Surg*. 1918; 68:309-29.
- Thurstun AJ. THE EARLY HISTORY OF TENNIS ELBOW: 1873 TO THE 1950s. *Aust. N.Z. J. Surg*. 1998a 68; 219-224.
- Thurstun AJ. Conservative and surgical treatment of tennis elbow: a study of outcome. *Aust N Z J Surg*. 1998b Aug; 68(8):568-72.
- Tomaino MM, Brach PJ, Vansickle DP. The rationale for and efficacy of surgical intervention for electrodiagnostic-negative cubital tunnel syndrome. *J Hand Surg Am*. 2001 Nov; 26 (6):1077-81
- Townshend DN, Taylor PK, Gwynne-Jones DP. The outcome of carpal tunnel decompression in elderly patients. *J Hand Surg Am*. 2005 May; 30(3):500-5.
- Travell JG, Simons DG. Myofascial pain and dysfunction. In: *The trigger point Manual*. Baltimore, USA: Williams and Wilkins, 1983.
- Tsai TM, Chen IC, Majd ME, Lim BH. Cubital tunnel release with endoscopic assistance: results of a new technique. *Journal of Hand Surgery Am*. 1999; 24(1):21-9.
- Tsai P, Steinberg DR. Median and radial nerve compression about the elbow. *J Bone Joint Surg Am*. 2008 Feb; 90 (2):420-8.
- Turchin DC, Beaton DE, Richards RR. Validity of observer-based aggregate scoring systems as descriptors of elbow pain, function, and disability. *J Bone Joint Surg Am*. 1998 Feb; 80(2):154-62.

- Verhaar J, Walenkamp G, Kester A, van Mameren H, van der Linden T. Lateral extensor release for tennis elbow: a prospective long-term follow-up study. *J Bone Joint Surg Am*. 1993; 75 (7):1034–1043.
- Verhaar J. Tennis elbow: anatomical, epidemiological and therapeutic aspects. *Int Orthop*. 1994;18:263–267.
- Vicenzino B, Collins D, Wright A. The initial effects of a cervical spine manipulative physiotherapy treatment on the pain and dysfunction of lateral epicondylalgia. *Pain*. 1996 Nov; 68(1):69-74.
- Walz DM, Newman JS, Konin GP, Ross G. Epicondylitis: pathogenesis, imaging, and treatment. *Radiographics*. 2010 Jan;30(1):167-84
- Ware JE Jr, Sherbourne CD. The MOS 36-item short-form health survey (SF-36). I. Conceptual framework and item selection. *Med Care*. 1992 Jun; 30 (6):473-83.
- Watts AC, Bain GI. Patient-rated outcome of ulnar nerve decompression: a comparison of endoscopic and open in situ decompression. *J Hand Surg Am*. 2009 Oct; 34 (8):1492-8.
- Waugh EJ. Lateral epicondylalgia or epicondylitis: what's in a name? *J Orthop Sports Phys Ther*. 2005 Apr; 35(4):200-2.
- Wewers ME, Lowe NK. A critical review of visual analogue scales in the measurement of clinical phenomena. *Res Nurs Health*. 1990 Aug;13 (4):227-36.
- Williamson A, Hoggart B. Pain: a review of three commonly used pain rating scales. *J Clin Nurs*. 2005 Aug;14 (7):798-804.
- Wilson JJ, Best TM. Common overuse tendon problems: A review and recommendations for treatment. *Am Fam Physician*. 2005 Sep 1;72 (5):811-8. Review.
- Woodley BL, Newsham-West RJ, Baxter GD. Chronic tendinopathy: effectiveness of eccentric exercise. *Br J Sports Med*. 2007 Apr; 41(4):188-98; discussion 199.
- Wressle E, Samuelsson K, Henriksson C. Responsiveness Swedish version of the Canadian Occupational Performance Measure. *Scand J Occup Ther* 1999; 6: 84-89.

- Wressle E, Lindstrand J, Neher M, Marcusson J, Henriksson C. The Canadian Occupational Performance Measure as an outcome measure and team tool in a day treatment programme. *Disabil Rehabil.* 2003 May 20;25 (10):497-506.
- Zeisig E, Ohberg L, Alfredson H. Extensor origin vascularity related to pain in patients with tennis elbow. *Knee Surg Sports Traumatol Arthrosc.* 2006;14: 659–63.
- Zeisig E. TENNIS ELBOW. Sonographic findings and intratendinous injection treatment. Doctoral Thesis, Umeå University, Umeå, Sweden, 2008.
- Öhberg L, Lorentzon R, Alfredson H. Eccentric training in patients with chronic Achilles tendinosis: normalised tendon structure and decreased thickness at follow up. *Br J Sports Med.* 2004a Feb;38(1):8-11;
- Öhberg L, Alfredson H. Effects on neovascularisation behind the good results with eccentric training in chronic mid-portion Achilles tendinosis? *Knee Surg Sports Traumatol Arthrosc.* 2004b Sep;12(5):465-70.