

Spinal Curves and Scoliosis

SUSAN M. ANDERSON, M.A.ED., R.T.(R)

Scoliosis, an abnormal side-to-side curve of the spine with associated vertebral rotation, affects as many as 4% of all adolescents. Several different categories of scoliosis exist, and treatment can range from observation and follow-up to bracing and surgical correction. This article discusses special imaging series for scoliosis and emphasizes the need for proper radiation protection techniques for patients with scoliosis, most of whom are girls in their early to mid-teens.

This article is a Directed Reading. Your access to Directed Reading quizzes for continuing education credit is determined by your area of interest. For access to other quizzes, go to www.asrt.org/store.

Note: Lateral images are displayed according to institutional preference, which may vary by institution.

After completing this article, the reader should be able to:

- Identify and label the parts of a vertebra and describe the differences between the vertebrae in each section of the spine.
- Distinguish between and describe the appearance of normal vs abnormal spinal curves.
- Explain the 3 treatment options for scoliosis and describe how a treatment is chosen.
- Discuss the role of medical imaging in the diagnosis and treatment of scoliosis.
- Summarize basic procedural differences for radiographing the spine in patients with scoliosis.
- Identify radiation safety methods necessary for imaging young scoliosis patients.

The spine, or vertebral column, is located centrally and posteriorly in the body. It is an important part of the body and has many functions. The spine is necessary for providing structure, flexibility, support and movement for our bodies. It acts as an attachment site for the muscles of the back, as well as the posterior ribs.¹ The spine also encloses and helps to protect the spinal cord.¹

According to *Merrill's Atlas*, the adult spine is composed of 24 true vertebrae that are separated into 3 segments based on body location. The cervical segment in the neck consists of 7 vertebrae. The thoracic segment in the upper back and thorax consists of 12 vertebrae, and the lumbar segment in the lower back consists of 5 vertebrae. The vertebral column is supported and held together by ligaments and joints.¹ Also considered part of the vertebral column are the sacrum and coccyx, which together are referred to as the pelvic section of the spine.¹

During prenatal development and in early childhood, the vertebral column consists of approximately 33 individual segments that include the pelvic segments

of the spine.² Figure 1A shows the lateral lumbar spine and lateral sacrum in a toddler. The lateral sacral image, Figure 1B, shows the individual sacral bodies before fusion. When the pelvic segments fuse, they are called false or fixed vertebrae.¹ The fusion of these vertebrae results in the appearance of 2 separate bones: the sacrum and the coccyx.

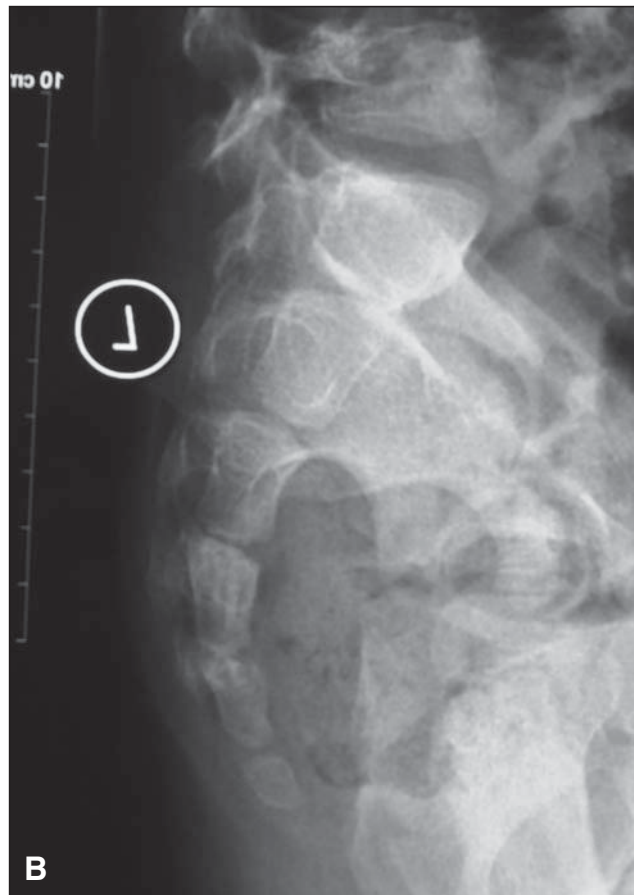
As medical imaging professionals we know that our vertebral column is not perfectly straight, even though it may appear so in the posterior and anterior views. When seen from the side, 4 slight curves are visible, arching anteriorly and posteriorly from the coronal plane and forming an elongated "S" shape.¹ These curves are normal and help us in our daily activities by keeping us balanced and flexible. The curves also help to absorb stresses placed on our bodies through impact activities such as running and jumping.² Normal curves of the spine develop as we grow and learn motor skills.^{1,2}

According to the National Scoliosis Foundation, 2% to 3% of the population has an abnormal curve to their spine called scoliosis.³ A common lay definition

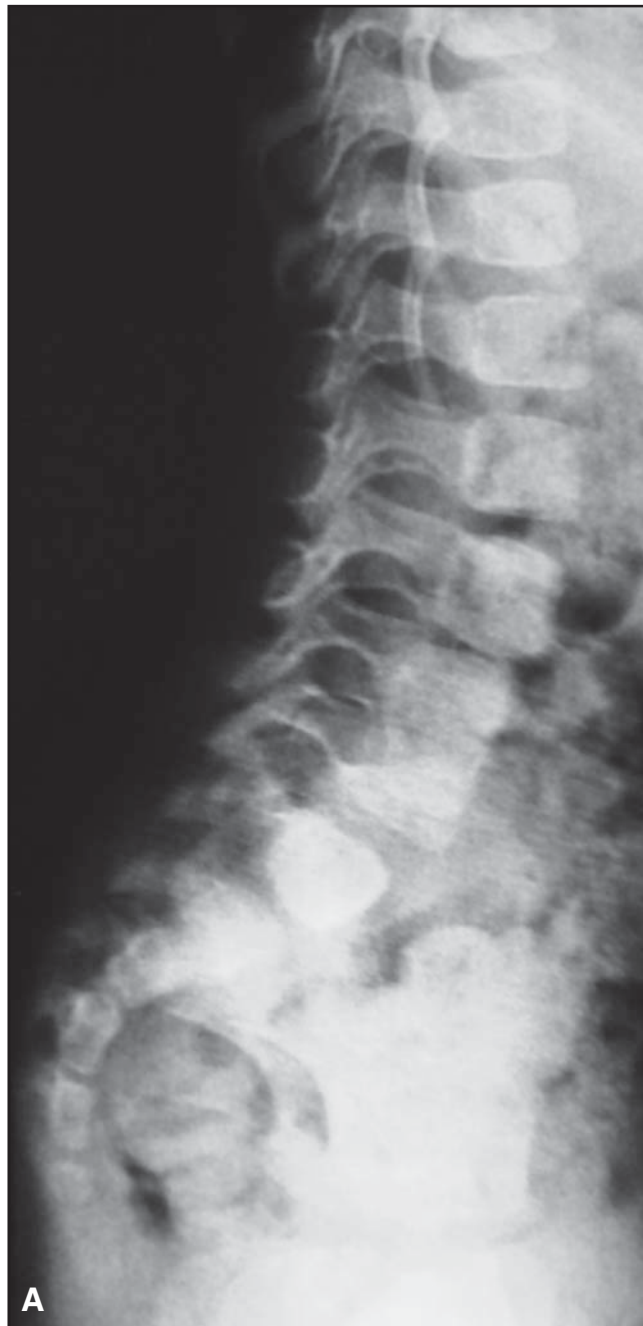

Figure 1. Lateral images of the lumbar spine and sacrum in a toddler, demonstrating the separation of pelvic vertebrae before fusion into the sacrum and coccyx occurs.

of scoliosis is an abnormal side-to-side curvature of the spine. As imaging technologists, we frequently see evidence of scoliosis on lumbar and thoracic spine exams



but may know little about this condition beyond its definition.

This article is meant to enlighten imaging technologists about the curves of the spine, including information on scoliosis and imaging considerations for patients with scoliosis. Although there are several categories of scoliosis that affect people of different ages, this Directed Reading will focus on the most common form, which affects adolescents.

Normal Spinal Anatomy

Anatomy of the Vertebrae

Adult vertebrae vary slightly in size and shape according to their location in the spine. With the exception of the first and second cervical vertebrae, the spinal vertebrae have similar structural components that can be divided into 2 distinct sections: the body and the vertebral arch.^{1,2}

The body is the thick, rounded anterior part of the vertebra. It is the weight-bearing part.² The superior and inferior surfaces of the vertebral body are referred to as endplates and are the attachment sites for the intervertebral disks.²

Intervertebral disks separate the bodies of the vertebrae in the vertebral column. The disks are composed of 2 sections and act as shock absorbers for the body during activities such as running, jumping and other activities that increase the axial load on the spine. The outer section of the disk is composed of fibrocartilaginous material and is termed the annulus fibrosus.^{1,2} The inner section of the disk is called the nucleus pulposus and is filled with a semigelatinous material.^{1,2} The intervertebral disks are best demonstrated through magnetic resonance (MR) and computed tomography (CT) imaging. The disks are not radiopaque and, therefore, are not visible on radiographs.

The posterior portion of a vertebra, the vertebral arch, is composed of the pedicles and the laminae.^{1,2} The pedicles are short columns of bone that protrude posteriorly from the vertebral body.¹ The superior and inferior concave portions of the pedicle (called the superior and inferior vertebral notches) form the intervertebral foramen in the articulated spine.¹ The foramen allows for passage of spinal nerves and blood vessels.¹

The laminae are flat sections of bone that project from the pedicles in a posterior and medial direction. Together, the pedicles and laminae create the opening between the body of the vertebrae and the vertebral arch. This opening is called the vertebral foramen.

The series of articulated vertebrae and vertebral foramen form the vertebral canal, through which the spinal cord and nerve roots pass.^{1,2} The canal houses and protects the spinal cord beginning at the foramen magnum, where the spinal cord exits the skull.

The pedicles and the laminae support 7 processes of bone that have specific functions.¹ Posteriorly and somewhat inferiorly from the center of the laminae projects the spinous process.¹ The spinous process is the most posterior aspect of the vertebrae and is felt as a bony knob or protrusion at the center of the back. Projecting laterally from the pedicles are the transverse processes. The transverse processes act as attachment sites for various muscles and ligaments of the back.⁴

The final 4 processes include the 2 superior and 2 inferior articular processes. Each superior and

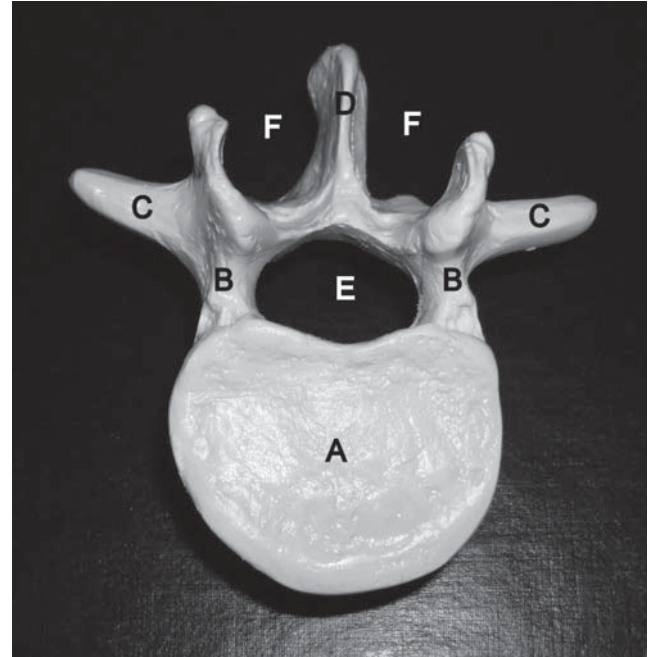


Figure 2A. Superior aspect of a typical vertebra. A. Vertebral body. B. Pedicles. C. Transverse processes. D. Spinous process. E. Vertebral foramen. F. Inferior to the letter F is the area of the laminae.

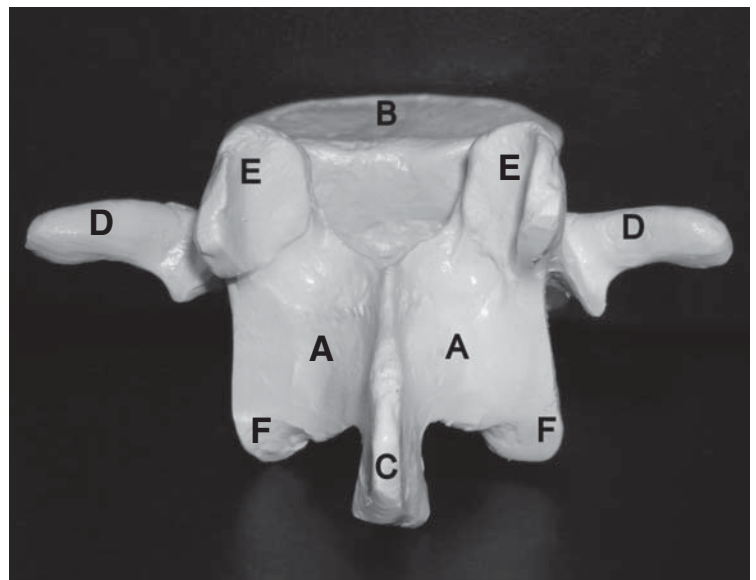


Figure 2B. Posterior aspect of a lumbar vertebra. A. Pars interarticularis. B. Vertebral body. C. Spinous process. D. Transverse process. E. Superior articular process (facet). F. Posterior aspect of the inferior articular process.

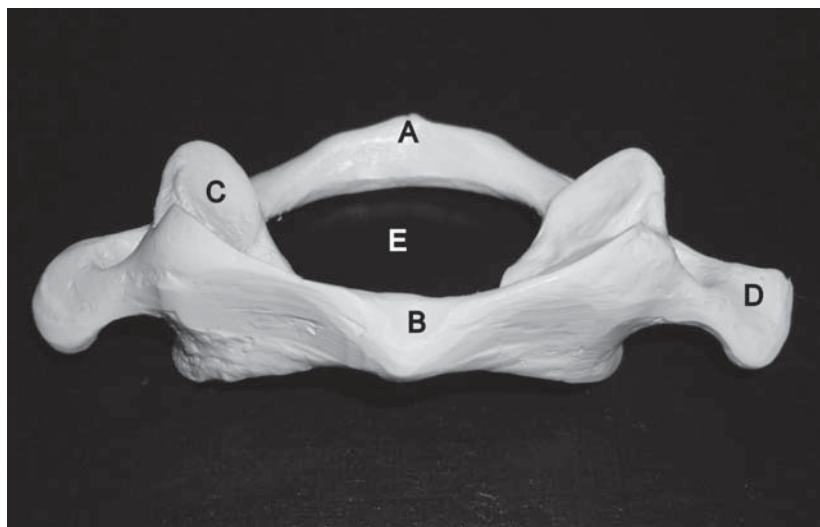


Figure 3A. Image of the atlas (C-1). A. Posterior vertebral arch. B. Anterior vertebral arch. C. Facet for articulation with the occipital bone (forms the atlanto-occipital joint). D. Transverse process (each cervical transverse process contains a transverse foramen, which is not visible here). E. Vertebral foramen.

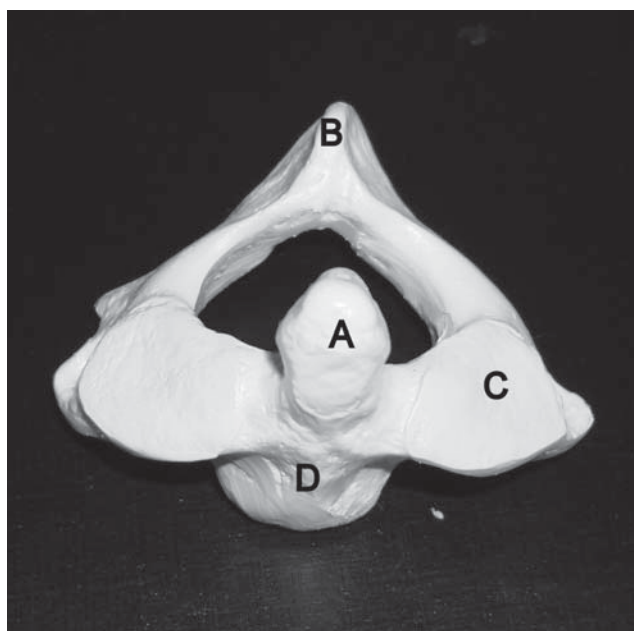


Figure 3B. Image of the axis (C-2). A. Dens or odontoid process. B. Spinous process. C. Superior articular process (facet) for articulation with C1. D. Body of C2.

inferior articular process connects to form a column of bone called the articular pillar.¹ The articular pillars are found behind each transverse process at the junction of the pedicle and lamina.¹ The articulations between vertebrae occur at the inferior articular processes of the superior vertebra with the superior articular processes of the inferior vertebra. Fibrocartilage covers each of the articulating surfaces of the articular processes. These articular surfaces often are called facets.^{1,2} The joints formed between the vertebrae at these facets are called zygapophyseal joints or facet joints.^{1,2}

Figure 2A demonstrates the superior aspect of a vertebra, and Figure 2B shows the posterior aspect of a lumbar vertebra. Note that when the posterior aspect of the lamina, which is located between the superior and inferior articular processes, appears in the lumbar vertebra it is called the pars interarticularis.

Basic Sectional Differences

The individual vertebrae get progressively larger the more distally located they are in the spine. The first section of the spine, the cervical section, has the smallest vertebrae. These vertebrae are adapted especially to support the weight and movement of the head.^{2,5}

The first and second cervical vertebrae, respectively called the atlas and axis, are adapted especially for rotational movements.⁵ The atlas (C-1) has no vertebral body and is composed of a ring of bone specially adapted to articulate with the head.^{1,2,5,6} The axis (C-2) contains the upward-pointing odontoid process. This adaptation is useful in allowing extreme rotational movements of the head and neck.^{1,5,6} It also is important to note that there is no intervertebral disk between the first and second cervical vertebrae due to the unique structure of each.^{1,2} Figure 3A shows the atlas (C-1) and Figure 3B shows the axis (C-2).

All 7 cervical vertebrae have transverse foramen.^{1,2} These openings are located in the transverse processes and are important passageways for the vertebral artery, nerves and veins.^{1,2} Other sectional differences found in the cervical vertebrae include the bifid spinous tips on C-2 through C-6 and the overlapping vertebral bodies of C-3 through C-6.^{1,2}

The thoracic vertebrae are larger than the cervical vertebrae but provide much less movement capability.^{5,6}

The thoracic vertebrae, along with the ribs, are adapted for organ protection and stability and form the posterior portion of the bony thorax.^{2,6}

The thoracic vertebrae are unique in that they have facets on all 12 vertebral bodies and on the transverse processes of T-1 through T-10.² These facets form the costovertebral and costotransverse joints with the ribs.^{1,2,5}

Moving distally from T-1 through T-12, the thoracic vertebral bodies gradually increase in size.¹ The upper thoracic vertebrae more closely resemble the cervical vertebrae, while the distal thoracic vertebrae resemble those of the lumbar spine.^{1,2} The middle section of thoracic vertebrae, referred to as typical thoracic vertebrae, have a spinous process that angles sharply downward.^{1,2}

The vertebrae of the lumbar spine are the largest and strongest in the body.² This is necessary to help support the weight of the body's torso.^{2,5,6} The bodies of the lumbar vertebrae also progress in size from L-1 to L-5.^{1,2} The lumbar section of the spine has more movement capability than the thoracic section and is more likely to be injured.^{1,5,6}

Normal Vertebral Curves

Each of the 4 sections of the vertebral column — the cervical, thoracic, lumbar and pelvic regions — has its own subtle curve when viewed laterally. These normal curves are referred to as primary and compensatory curves.¹ Primary curves are the natural curves in the spine that we are born with. These curves include the thoracic and pelvic curves.¹ These curves are necessary and functional. The curves of the spine help to increase the overall strength of the vertebral column and help to maintain balance in the upright position.²

Figure 4 shows a spine in the lateral position and demonstrates the normal primary and compensatory spinal curves. Letter A represents the cervical region of the spine and demonstrates the slight lordotic curve present in the normal spine. Letter B represents the thoracic curve, showing the normal kyphotic curve. Letter C represents the lumbar region, and letter D represents the sacral or pelvic region of the spine, each showing its respective normal curve.

The primary curves of the spine are called kyphotic curves and are described as being convex posterior (concave anterior).¹ Curves are described as convex or concave to illustrate the direction of the arch of the curve in relation to the hollow or depressed side of the curve. When viewed from the side, the kyphotic curve arches posteriorly (as in the thoracic and sacral regions).

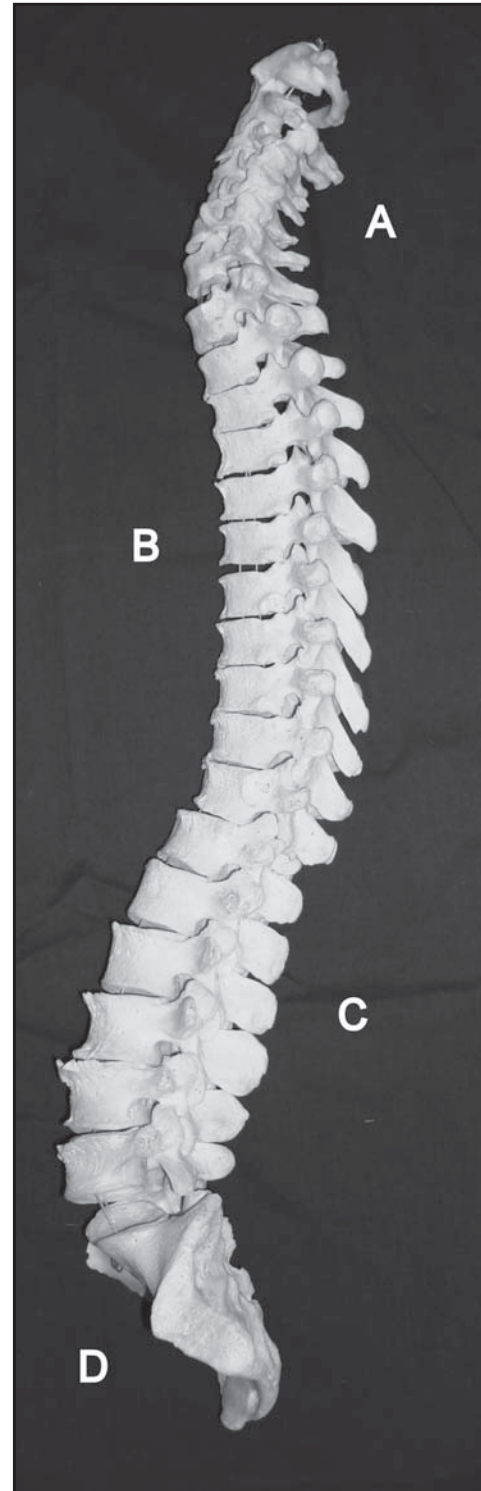


Figure 4. Lateral image of the entire spine showing the cervical (A), thoracic (B), lumbar (C) and pelvic regions (D).

Compensatory curves, also called secondary curves, develop after birth in response to learned motor skills.^{1,2} The compensatory curves develop as the body's way of keeping the head centered over the trunk and feet.¹ Compensatory curves are lordotic and are described as being convex anterior (concave posterior). The compensatory curves are found in the cervical and lumbar sections of the spine.

The cervical curve is the first of the 2 compensatory curves to develop and is the least pronounced of all the spinal curves.¹ This curve develops in response to an infant learning to hold his or her head upright and learning to sit unsupported.¹ The cervical curve begins to develop at 3 to 4 months of age.¹ The lumbar curve is last to develop.^{1,2} This curve begins to develop as a child learns to walk.²

Compensatory and primary curves, usually the lumbar and thoracic curves, can become exaggerated. This exaggeration can occur through aging, disease, poor posture or as a birth defect.⁷ An exaggerated kyphotic curve in the thoracic spine is called kyphosis.^{1,2,7} Kyphosis is an abnormal and exaggerated rounding of the upper back and shoulders that is sometimes called hunchback in severe cases.⁷ An exaggerated lordotic curve in the lower back or lumbar region is called lordosis.^{1,2} Lordosis leads to a swayback appearance with an exaggerated protrusion of the buttocks.^{1,2} Figure 5 shows exaggerated lordosis in a lateral lumbar spine radiograph.

Occasionally, a slight lateral or side-to-side curvature of less than 10° will develop in the upper thoracic region of an adult.^{1,2} This lateral curve is usually convex to the side of the dominant extremity (ie, convex to the right in a right-handed person and convex to the left in the left-handed person) and has no rotational element.^{1,2} This slight lateral curve is thought to be muscular in nature and may be occupationally related.^{1,2}

Scoliosis: An Overview

Definitions

Definitions of scoliosis vary slightly depending upon the source. Basically, scoliosis can be defined as an abnormal, side-to-side curvature of the spine that radiographically measures greater than 10° and usually is associated with rotation of individual vertebrae.^{1,2,8,11} Scoliosis that produces rotation of the vertebrae (usually rotation is toward the convex or pointed side of the curve) is called rotoscoliosis.⁸ Other terms associated with scoliosis include dextroscoliosis, which describes a scoliotic curve that is convex to the right and usually

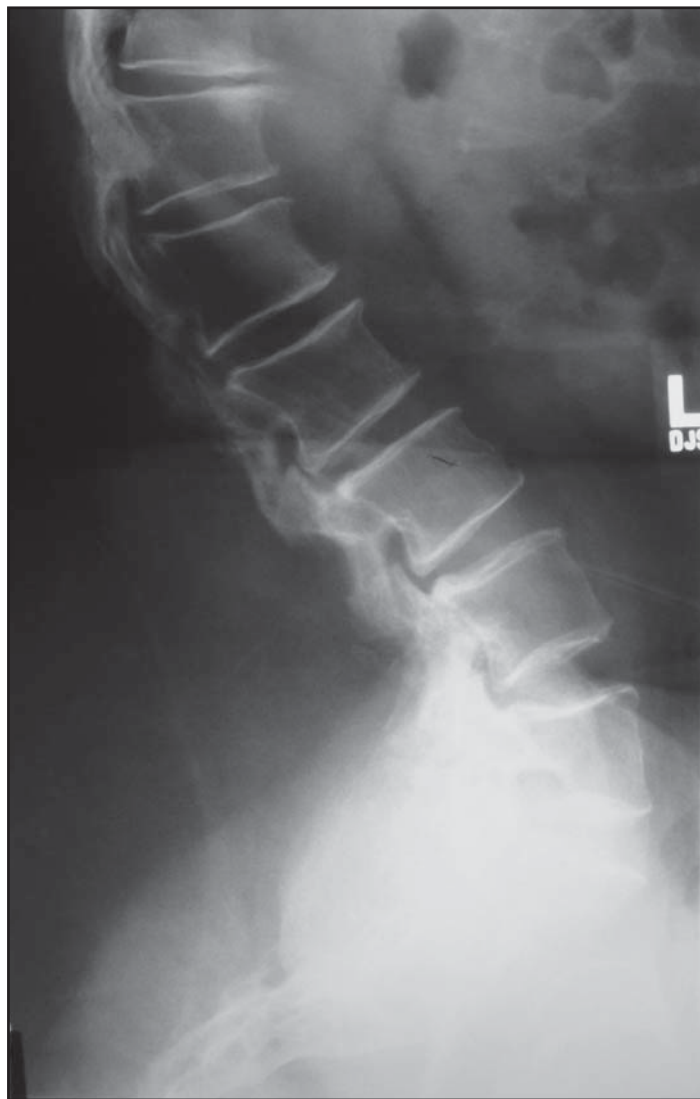

Figure 5. Lateral lumbar spine image showing exaggerated lumbar lordosis in an adult patient.

occurs in the thoracic spine, and levoscoliosis, which describes a scoliotic curve that is convex to the left and usually occurs in the lumbar region of the spine.^{8,9} Figure 6 shows a routine abdominal radiograph of an adult patient that demonstrates a scoliotic curve in the thoracolumbar region.

Anyone can have scoliosis. It occurs in all types of people and in all countries.¹⁰⁻¹² It can be present at birth, develop during childhood or occur in adulthood as a result of degenerative changes in the spine. One form of scoliosis occurs as a result of posture or

other developmental disorders.¹⁰⁻¹² Scoliosis and other abnormal spinal curves also can develop as a direct result of disease.¹³ General signs of scoliosis are listed in Table 1.

History

Knowledge of scoliosis and abnormal spinal curves has been around for centuries and still the condition remains incompletely understood.¹¹ The term *scoliosis* comes from the Greek word *skolios*, which means crooked. According to Charles Mehlman, D.O., M.P.H., a description of scoliosis and its treatment is mentioned in ancient Hindu materials dating back to 3500 to 1800 BC.¹¹ Mehlman's article "Idiopathic Scoliosis" also stated that around 400 BC Hippocrates mentioned various types of curvatures in the spine and described the lateral curves as being postural and muscular in nature, even indicating that they might be due to the way people slept.¹¹ Spinal manipulations and traction were the methods of choice for scoliosis treatment at the time.¹¹

In the 19th and early 20th centuries, speculations regarding the causes of scoliosis were abundant.¹⁴ Some physicians believed scoliosis in girls was due to the fact that girls participated in less physical exercise than boys, causing their spines to be weak and grow crooked.¹⁴ Other early speculations regarding the causes of scoliosis included school room furniture that many felt caused students to sit at awkward angles, the wearing of corsets by women, unequal leg lengths and muscle weakness on 1 side of the body.¹⁴

Treatments for scoliosis in the 19th and early 20th centuries primarily involved the use of braces and other devices that stabilized the spine and reduced or prevented further disfigurement.^{11,15,16} Early treatments included exercises prescribed for strengthening back muscles, popularized by French surgeon Jacques Delpech in the early 1800s; use of the full-body cast, popularized by American orthopedic surgeon Lewis Sayre in the mid 1800s; and the use of various combinations of treatments that included traction, suspension, bracing and postural corrections to try to correct scoliosis curves.¹¹

The earliest and most often prescribed stabilizing devices were plaster jackets that were worn continuously

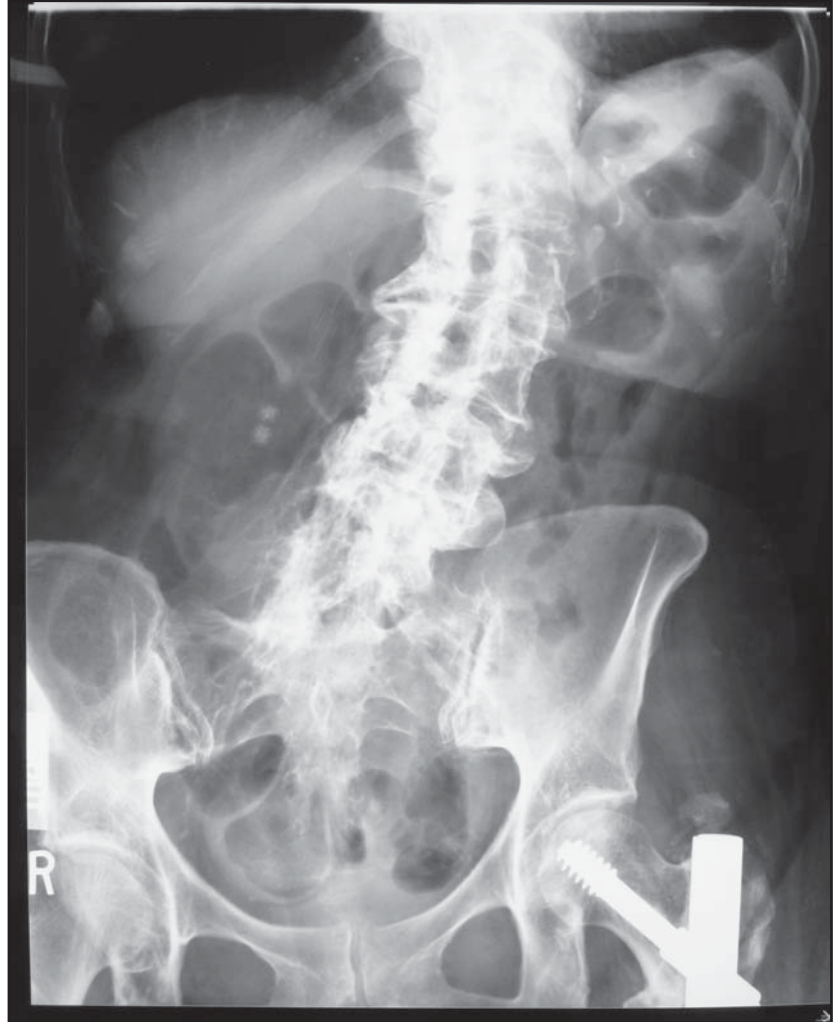

Figure 6. Convex left thoracolumbar scoliosis in an adult patient.

and were not removed even for bathing.¹⁶ Metal pressure pads sewn into clothes were introduced in 1904 in an attempt to correct the asymmetry of the body caused by scoliosis curves and prevent development of more severe curves.¹⁶ Other methods of spine straightening and bracing during this time included traction devices and corsets for women, along with suspenders and brasieres that were sold as corrective measures and claimed to straighten crooked backs.¹⁶ Most corsets and commercial braces were sold through women's magazines and catalogues and were mass produced rather than custom made to fit the individual.¹⁶

Failure of the early devices and scoliosis treatments was due in part to the lack of understanding of the condition

Table 1
General Signs and Indicators of Probable Scoliosis in Adolescents^{10,21}

| When standing erect, there is: |
|---|
| ■ Asymmetry in the way the arms hang. |
| ■ Shoulder height asymmetry. |
| ■ Asymmetry in hip height or position (asymmetric appearing waist). |
| ■ Asymmetry in scapula height or position. |
| ■ Thoracic or lumbar spine prominence. |
| When bending forward, there is: |
| ■ Asymmetry in the heights of each side of the back (rib hump). |

and its causes. Scoliosis was thought to be only a lateral growth of the spine, and many times it was attributed to poor posture, weak muscles or bad habits.¹¹ The corrective measures of the times were meant to push the spine back to the center of the body and correct poor posture.¹⁶ It was not known during this period that scoliosis also involved vertebral rotation and was more complex than simple lateral displacement or deviation of the spine due to sup- posed muscle weakness or poor posture.^{11,16}

In the early 1900s, surgical fusion of the spine was the newest method used to try to halt and correct the progression of scoliosis.^{11,16} American surgeon Russell Hibbs used a combination of bracing followed by posterior spinal fusion surgery to first stabilize then halt progression of the scoliosis curvature.^{11,17} Hibbs is credited with performing the first spinal fusion to halt the progression of a spinal curve in a spinal tuberculosis patient, subsequently changing the course of treatment for future scoliosis patients.¹⁷

Types

Scoliosis can be classified in several ways. First, scoliosis can be classified into 2 groups: functional (nonstructural) and structural.^{8,9,12,13,18} Functional scoliosis means that the spine is structurally normal, but a lateral curve has developed as a secondary response to a problem occurring elsewhere in the body.¹³

Nonstructural scoliosis also is known as compensatory or postural scoliosis and can occur due to differing leg lengths or a tilt to the pelvis, as well as flexion deformities at the hip or knee.^{9,13,18} In nonstructural scoliosis, the lateral curve to the spine resolves when the patient is seated or recumbent.^{13,18}

Several other types of nonstructural scoliosis have been identified, including sciatic scoliosis, hysterical scoliosis and inflammatory scoliosis.¹⁸ Sometimes these types are classified as transient structural scoliosis.⁹ Sciatic scoliosis results when patients experience a painful sciatic nerve and try to position themselves to lessen the pain, creating a compensatory spinal curve.¹⁸ Inflammatory scoliosis results from an infective process such as appendicitis, while hysterical scoliosis develops from an underlying psychological disorder.¹⁸ In non- structural scoliosis, the abnormal curve of the spine is usually temporary and disappears when the underlying cause has been addressed.³

Structural scoliosis is the type of scoliosis most people are familiar with. The spine not only has a lateral curve, but also has a rotational element to the vertebrae.¹⁸ Structural scoliosis directly involves the structural aspect of the spine and does not go away when the patient lies down or sits upright.^{9,13,18}

Structural scoliosis also can be categorized into various types. The categories may vary slightly depending upon the source, but are all ways of identifying the underlying cause (etiology) of scoliosis. Some structural categories include congenital, neurological, myopathic, traumatic and idiopathic.^{9,10,18}

Congenital scoliosis is a fixed spinal curvature that is present at birth and usually is due to a deformity in the bony structure of 1 or more vertebrae.^{10,18-20} Absence of a vertebra, lack of vertebral separation and partially formed vertebrae are considered to be common causes of congenital scoliosis.¹⁹ According to Dr. Robert Winter of the Minnesota Spine Center, a founder of the Scoliosis Research Society, congenital scoliosis affects girls more often than boys (60% to 40%) and affects approximately 1 in 10 000 Americans.²⁰

The neurological and myopathic scoliosis categories often are combined into a single category called neuromuscular scoliosis. In neuromuscular forms of scoliosis, the spinal curvature is due to underlying neurological or muscular disease.¹⁸ These diseases include cystic fibrosis, various types of muscular dystrophy, spina bifida, cerebral palsy, Marfan syndrome, rheumatic disease such as rheumatoid arthritis, myelomeningocele and tumors.^{9,18,19} Deformity of the spine is often severe in patients with neuromuscular scoliosis.¹⁹

The final 2 types of scoliosis are traumatic and idiopathic. Traumatic scoliosis, which is mentioned infrequently, is a spinal curvature due to trauma of the spine or its components. Traumatic scoliosis can be caused by fractures, surgery or irradiation.⁹ Idiopathic scoliosis,

which is the most common form, is a structural curve whose cause is unknown.^{9,18,19,21}

Idiopathic scoliosis is divided into classifications based upon the child's age at the time of diagnosis.^{9,13,19,21} The 3 classifications of idiopathic scoliosis are infantile (aged 3 years and younger), juvenile (discovered between ages 3 and 10), and adolescent idiopathic scoliosis (discovered between age 10 and skeletal maturity).^{9,10,15,19,21} Idiopathic scoliosis will be the main focus of the remainder of this Directed Reading.

Prevalence

Because scoliosis is not a medical condition that must be reported, the prevalence of the condition is only estimated.¹³ According to the National Scoliosis Foundation, in the United States alone, an estimated 6 million people have scoliosis.³ Estimates are that idiopathic scoliosis affects 2% to 4% of all adolescents.^{21,23}

Adolescent idiopathic scoliosis (AIS) accounts for an estimated 80% of idiopathic scoliosis cases and is detected most commonly in children between the ages of 10 and 16 years.^{9,12,13,21,22} Most idiopathic scoliosis patients are girls, but incidence rates vary, depending on the degree of the curve and type of scoliosis.^{11,13,19,21} The classic profile of a scoliosis patient is a tall, adolescent girl in her teens with a convex right thoracic curve.²³

AIS occurs in both boys and girls, but not at the same rates.^{11,13,23} The spinal curve is usually in the thoracic or thoracolumbar region and is convex to the right in most cases.^{11,13} The difference in incidence between boys and girls is related to the degree of the curve.^{11,19,21,23} In patients with minor spinal curves (those of approximately 10°) the ratio of boys to girls is equal.^{11,19,21,23} However, in patients with spinal curves of 25° or more, almost 90% are girls.^{10,13,21}

Infantile idiopathic scoliosis, usually detected by 6 months of age, is more common in boys and people of European descent. Infantile idiopathic scoliosis curves usually occur in the thoracic spine and are convex to the left.^{11,13,22,23} In many cases these curves resolve on their own by the time the child reaches 3 years of age.^{11,13,22} It has been estimated that infantile idiopathic scoliosis accounts for only 0.5% of all idiopathic scoliosis cases in the United States and as many as 4% to 5% in European countries.¹¹

Juvenile idiopathic scoliosis is very similar to the adolescent type.¹¹ Girls are most often affected by this type.^{11,22} Juvenile idiopathic scoliosis curvatures occur in the thoracic region and are usually convex to the right.^{11,22} Due to its high rate of curve progression and the need for surgical treatment, this form of scoliosis

sometimes is called a malignant subtype of adolescent idiopathic scoliosis.¹¹

Treatment and Prognosis

Treatments and prognoses vary greatly from person to person. Treatments are very individualized and depend on factors such as the type of scoliosis; the degree, direction and pattern of the spinal curve; the patient's age; and how much more the patient may grow.^{12,19}

Skeletal maturity is measured in several different ways. One of the most commonly used methods is the Risser grading system.²¹ The Risser scale estimates remaining skeletal growth by measuring the ossification of the iliac apophysis and assigning a numeric value from 0 to 5.²¹ Figure 7 shows a hip radiograph to illustrate the area of the iliac apophysis in a 16-year-old girl. Table 2 shows the Risser grading system used to measure skeletal maturity. Using Figure 7 and the Risser scale, the estimated Risser grade for this patient is 4.

Progression of the curve is a common concern for patients, their families and physicians. Typically, scoliosis curves located in the thoracic spine are more likely to progress than curves located in the lumbar or thoracolumbar regions.¹¹ In addition, smaller curves in older adolescents are much less likely to progress than larger curves in skeletally immature patients.^{10,11,13,19} Curves are more likely to progress in female patients, but most curves that develop in childhood will not progress beyond skeletal maturation.²³ Although many adolescents have scoliosis, it is estimated that only 10% of patients have a curve that progresses to the point of requiring medical treatment.²¹

Unless a child has the infantile idiopathic form of scoliosis, which can spontaneously disappear, there is no chance of the idiopathic curve simply disappearing.^{11,13,23} The majority of curves either progress or stay the same.¹³ Juvenile idiopathic scoliosis has the greatest rate of progression and need for medical or surgical intervention.¹¹ Prognosis for progression in AIS depends primarily on the size of the curve and how much the child has left to grow.^{10,13,23} Growth depends on chronological age and skeletal maturity.^{10,13,21,23}

In AIS it is suggested that curves less than 30° will not progress once skeletal maturity has been reached.^{21,23} Curves that measure between 30° and 50° are likely to progress an additional 10° to 15° over the patient's lifetime.^{10,21,22} Curves of 50° or more at skeletal maturity have been shown to progress as much as 1° per year into adulthood.^{10,21,23} Curves that reach 100° or more can affect the patient's cardiopulmonary functions.^{15,21,22}

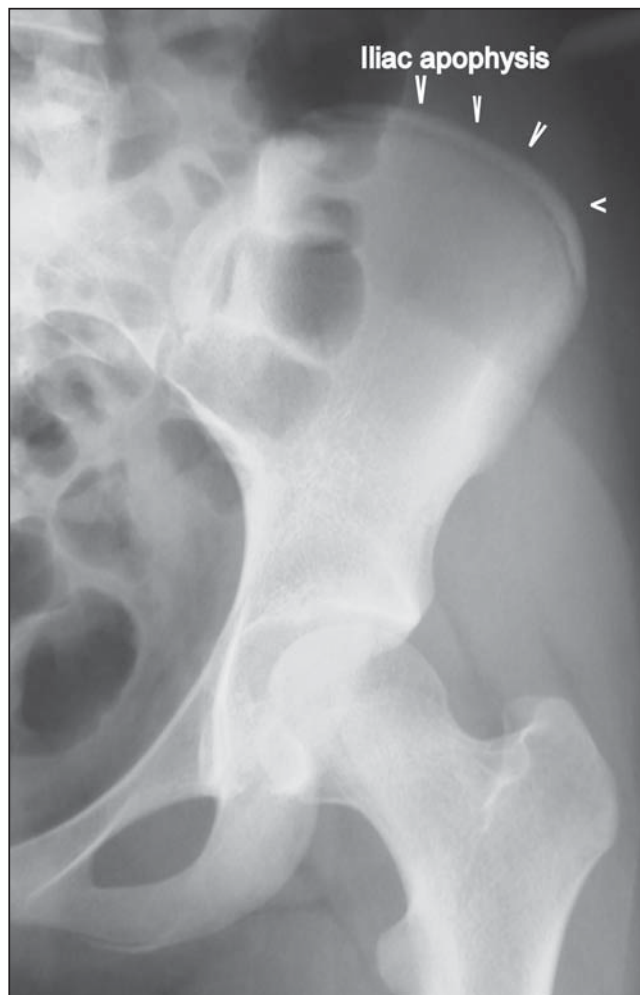

Figure 7. Radiograph of the hip of a 16-year-old patient demonstrating the area of the iliac apophysis (marked).

Because no cure for scoliosis exists, treatment options are used to monitor the progression of the curve and to intervene to slow or halt progression, if necessary. Treatment for idiopathic scoliosis involves 3 options: observation, bracing and surgical intervention.^{10,12,13,21,22} Physical therapy has been tried and found to have no measurable effect on the magnitude of spinal curves associated with AIS.²⁴ Treatment options must be tailored to the individual patient. Basic guidelines, which will not work for every patient, are based on the degree of curvature.

Many sources list treatment options for scoliosis, and they all differ slightly in their approach and timing of treatment. Generally, observation usually is recommended for curves less than 25° in patients who are still

Table 2
Risser Grades for Skeletal Growth Estimates²¹

| | |
|--|------------------------------------|
| Grade 0 | No ossification |
| Grade 1 | 25% ossification (of lateral ¼) |
| Grade 2 | 26-50% ossification (of lateral ½) |
| Grade 3 | 51-75% ossification (of lateral ¾) |
| Grade 4 | 76-100% ossification (no fusion) |
| Grade 5 | complete bony fusion |
| <i>Ossification measured using the iliac wing apophysis.</i> | |

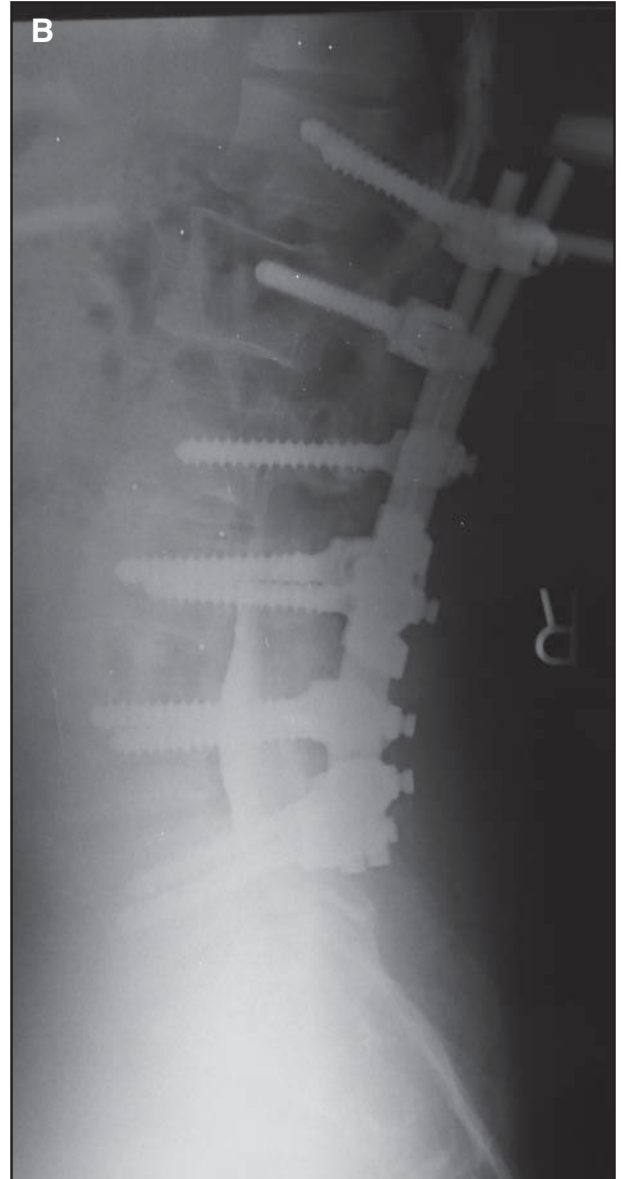
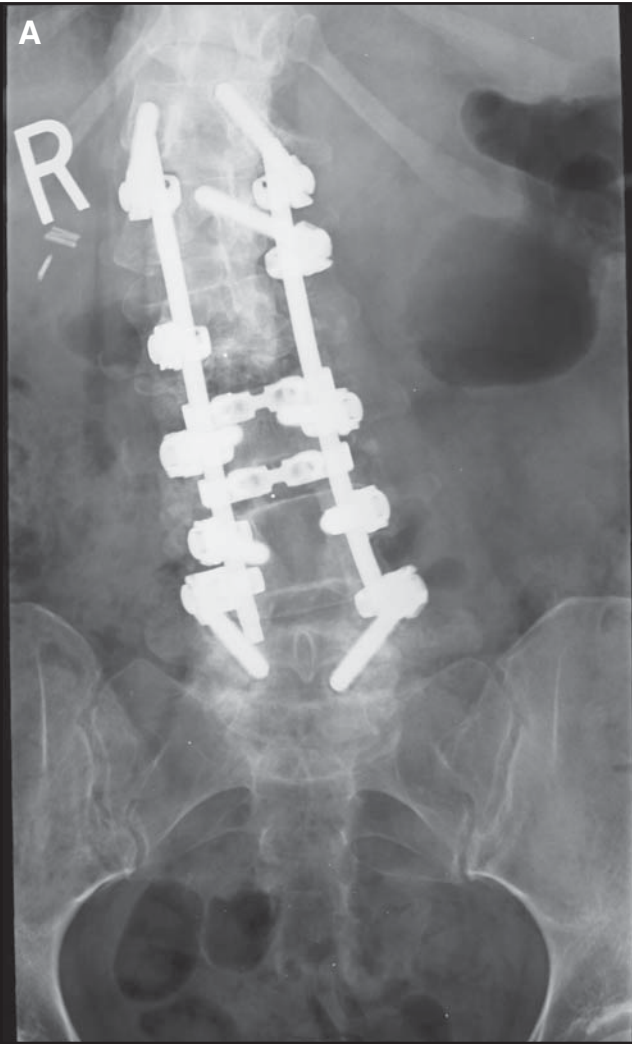
Table 3
Warning Signs Prompting Extensive Evaluation^{21,23}

| |
|--|
| ■ Convex left thoracic curve |
| ■ Severe, large curves in very young children |
| ■ Scoliosis in boys |
| ■ Scoliosis that is painful |
| ■ Stiffness |
| ■ Sudden rapid curve progression in a previously stable curve |
| ■ Extensive curve progression after skeletal maturity is reached |
| ■ Abnormal neurological findings |
| ■ Small, hairy patch on the lower back |

growing.^{10,12} During the observation period, the patient usually is seen and radiographed every 4 to 6 months to monitor possible progression of the curve.^{12,21} Patients may be monitored more frequently and treatment options may change if the patient presents with any of the warning signs listed in Table 3.

Bracing is the second option used for scoliosis patients. Currently, bracing is used to slow and prevent progression of the curve and is the only acceptable nonsurgical treatment for scoliosis.^{10,24} Bracing usually is recommended when the curve measures between 25° and 40° and the child has not yet reached skeletal maturity (Risser scale 0-3).^{10,12,19,24} Bracing also may be used in adolescents who present with a rapidly progressing curve.¹¹ Bracing has not been proven to be effective for older adolescents (Risser scale 4-5).²⁴

Bracing today is much more effective than it was in the 19th and early 20th centuries.^{11,24} Braces are not only better constructed and lightweight, but they also are



Figures 8A and 8B. Postsurgical images of an adult patient with surgical correction of scoliosis using screws and plates.

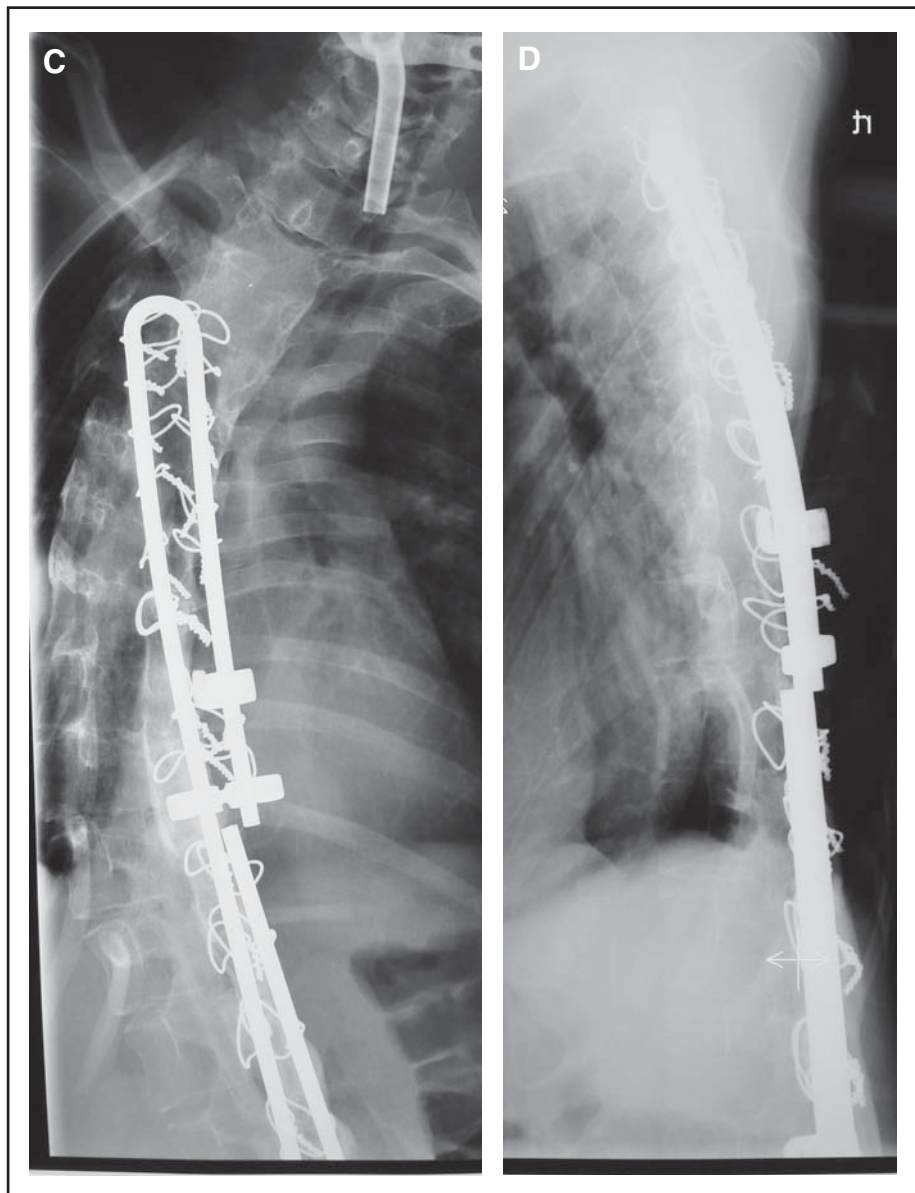
tailored for individual patients and often can be worn under clothing.^{10,21,24,26} The fit of the brace and curve measurements are checked every 6 months in patients who are still growing.¹⁰ Although more studies need to be performed, recent research suggests bracing is effective at stopping curve progression 70% to 74% of the time in patients who comply with prescribed bracing recommendations.^{10,21}

The final treatment option for some scoliosis

patients is surgery. Surgical intervention often involves fusion of vertebrae and may include rods or plates and screws inserted for stability and curve correction.^{12,24}

Figures 8A through 8D demonstrate surgical fixation of scoliotic curves. Figures 8A and 8B show screw fixation; Figures 8C and 8D demonstrate the use of rod devices such as Harrington rods.

Surgical intervention may become an option for patients with AIS curvatures of more than 40° to 45° who



Figures 8C and 8D. Postsurgical images of a young adult with surgical correction of neuromuscular scoliosis using rod fixation devices.

have not yet reached skeletal maturity.^{10,12,24} Surgery also may be indicated in patients who have thoracolumbar curves of 50° to 60° at skeletal maturity.^{22,25}

There are times when surgery will be indicated in adult patients. Surgery in adults is indicated when the patient complains of pain or is concerned about appearance.²² Surgery also may be indicated for adult patients who are experiencing shortness of breath or

other cardiopulmonary problems due to large thoracic curves.²²

Surgery in patients who have the more severe form of idiopathic scoliosis, the juvenile form, is more common than in patients with AIS.¹¹ This is due to the fact that the curves are found in more skeletally immature patients (ages 3 to 10) and have a tendency to progress rapidly, especially in children older than 5 years.^{11,19}

According to an article by Asher and Burton from the University of Kansas Medical Center, research shows that treatment options such as bracing and surgery for patients with AIS often are not needed. Estimates suggest that only 1 in 10 AIS curves will progress to the point of needing bracing and only 1 in 25 progresses to the point of requiring surgical intervention.²²

Diagnosing Scoliosis

Idiopathic scoliosis usually is noticed first at school screenings or at the pediatrician's office during routine physical examinations.¹⁰ It might even be recognized by something as simple as an uneven pant leg or uneven hemline on a skirt or dress.²⁵ In children wearing clothes with stripes, the uneven appearance of the stripes can be an indicator of scoliosis and is due to the lack of symmetry between the 2 sides of the body.

Screening Guidelines

Screenings are based on the theory that identifying curves early and treating them appropriately will slow or halt curve progression.²⁴ Many schools have scoliosis screening programs, but the accuracy of school screenings is considered to be very low.^{21,24} An estimated two-thirds of school-screened patients who were referred to physicians were found to have no abnormal spinal curves or no curve warranting treatment.^{21,24} Due to the over-referral of patients, some schools have stopped their screening programs,

even though the American Academy of Orthopaedic Surgeons and the Scoliosis Research Society still support school screenings.^{21,24,26}

Furthermore, there is no clear consensus about the best ages for screening. The American Academy of Orthopaedic Surgeons and the Scoliosis Research Society recommend screening girls at ages 10 and 12 and screening boys 1 time only at either age 13 or 14.^{21,25} The American Academy of Pediatrics recommends that scoliosis screenings become a regular part of a child's physical examinations at ages 10, 12, 14 and 16 years.^{21,25}

Although some studies support screenings, others, such as a 2006 report published by the U.S. Preventative Task Force, recommend against screening for idiopathic scoliosis because of screening's ineffectiveness and potential harmful effects on those with a false-positive screening result.²⁷ Harmful effects listed include the stress of unnecessary follow-up physician visits and evaluations and the psychological stress that accompanies the possibility of having scoliosis.²⁷ This new recommendation represents a change from the 1996 version, which stated that no recommendation could be made for or against scoliosis screening due to insufficient evidence.²¹

The Adam's Forward Bend Test

The most common and simplest-to-perform test for the initial assessment of structural scoliosis (and the one used by most school screening programs) is the Adam's forward bend test.^{10,13,21,23,26} With back bared, the patient bends forward at the hips while keeping his or her knees straight to position the back parallel with the floor.^{10,19,21,26} The patient should extend both arms overhead and parallel to the floor with the palms touching or allow the arms to hang down perpendicular to the floor (see Figure 9).^{10,19,21,26} The evaluator then should examine the patient from the front or back, as well as from the side, looking at the contour of the back for possible asymmetry.^{10,19,21}

The forward bend test is useful in determining asymmetry of the trunk, but asymmetry does not mean a spinal curve is present.¹⁹ The trunk or thorax can develop asymmetrically due to overdevelopment on the patient's dominant hand side.¹⁹ This asymmetrical trunk development may have led many school screeners to misinterpret findings and refer patients to a physician unnecessarily.^{19,26} (In the past, many screeners were not medical personnel.)

If the characteristic rib hump is visible during the test, this should prompt a follow-up radiographic examination.²¹ The rib hump is an indicator of a rib cage deformity that appears when the patient has thoracic

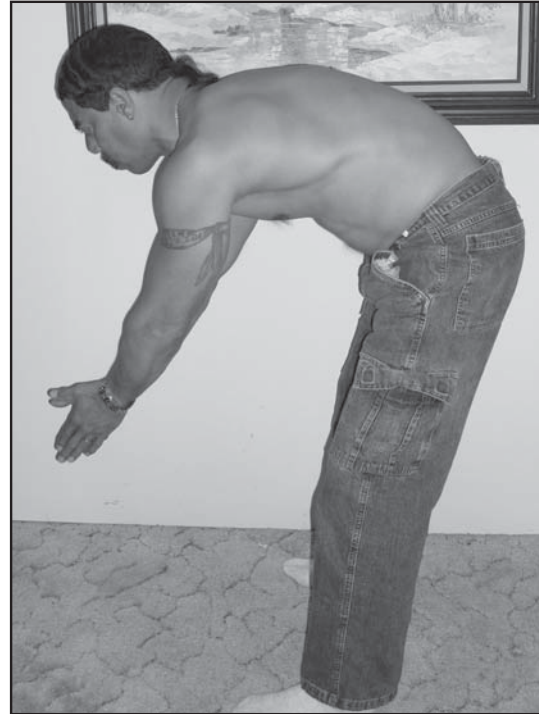

Figure 9. The Adam's forward bend test position, used in the initial screening of patients with scoliosis.

scoliosis with a rotational element.^{21,23} The rib hump usually is indicative of a scoliotic curve greater than 10°.²¹

Once a possible curve has been discovered, a complete medical examination and patient history should be obtained by a physician.^{10,21} Musculoskeletal and neuromuscular functions should be assessed, including reflexes, gait and flexibility.¹⁰ The patient should be questioned about any instances of pain, as well as bowel or bladder abnormalities, because these findings would be atypical and might indicate a spinal cord pathology.^{10,21} If abnormalities are present during the physical examination, radiographic evaluation for confirmation of the diagnosis is needed, with possible MR imaging to evaluate for underlying spinal pathology.^{10,21}

Imaging the Scoliosis Patient

Radiographic imaging of the spine is not uncommon. Any trauma or pathologic process that affects the spinal column, particularly those that affect mobility, or the integrity of the spinal column and relationships between the vertebrae can affect the quality of the patient's life adversely.²⁸ The spine can be affected by degenerative and traumatic conditions, infectious and

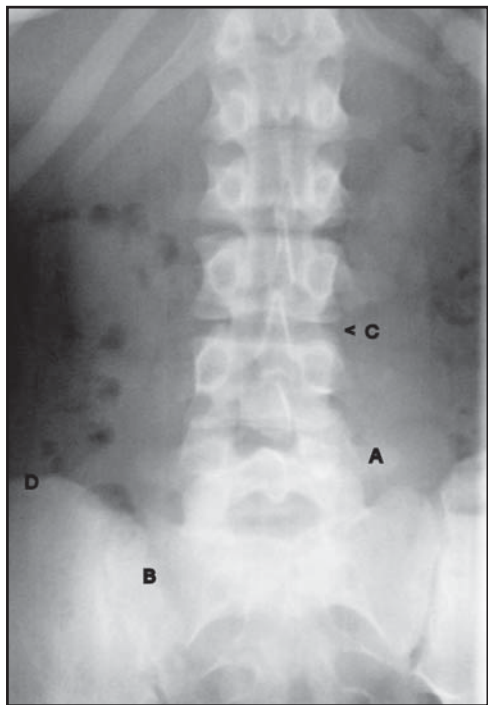


Figure 10A. AP projection of the lumbar spine demonstrating normal curves in the lumbar region. Common vertebral anatomy shown: transverse processes at L5 (A), sacral wing (B) and intervertebral disk space (C).

inflammatory conditions, and metabolic and congenital processes.²⁸ Tumors, metastatic cancer and developmental abnormalities also can affect the spine.²⁸ Diagnostic radiography is usually the first modality used to detect spinal abnormalities.²⁸

Scoliosis patients are imaged for several reasons. Initial imaging is done to confirm a spinal curvature and determine the degree, direction and curve magnitude. Patients with scoliosis often are monitored for curve progression and may be radiographed 2 to 3 times a year until skeletal growth is complete.^{10,12,21} Imaging also is used as part of pre- and postsurgical assessments.

Routine Spinal Imaging

When imaging the spine for nonscoliotic assessment, routine examinations of the thoracic and lumbar spine usually are taken with the patient recumbent; however, flexion and extension images, if ordered, should be performed with the patient erect when possible.^{1,2,28} Each section of the spine is imaged separately during routine spinal imaging using the smallest image receptor (IR) necessary to include the entire spinal section. For the

anteroposterior (AP) and lateral projections of the thoracic and lumbar spines, this usually involves the use of 14 x 17-inch IR, although individual department policies should be followed.^{1,2,28}

It is important to image the spine in more than 1 position to effectively evaluate the size, shape and relationship of the individual vertebrae to each other. For nonscoliosis imaging, routine lumbar spine radiographs generally include an AP or posteroanterior (PA), both obliques (either posterior or anterior), and a lateral with or without a spot lateral of the L5-S1 area.^{1,2,28} The AP (or PA) and lateral lumbar images show the lumbar vertebral bodies and the intervertebral disk spaces, as well as the relationships between the individual vertebrae.^{1,2} The AP also allows for visualization of the transverse processes, the sacroiliac joints and the sacrum. The lateral lumbar spine includes the intervertebral foramina, lateral view of the vertebral bodies and their alignment, the spinous processes and partial lateral view of the sacrum.^{1,2} Routine AP and lateral projections of the lumbar spine are shown in Figures 10A and 10B.

Oblique radiographs of the lumbar spine show the relationship between the vertebrae at the area of the zygapophyseal joints. A popular radiographic sign, the Scotty dog, is visible on properly positioned oblique lumbar spine images.^{1,2} The Scotty dog represents the various parts of a lumbar vertebra and is shown in Figure 11.

A routine thoracic spine examination usually consists of an AP and a lateral projection using a breathing technique (3 to 4 second exposure time with the patient continually breathing gently throughout the exposure).^{1,2,28} AP and lateral thoracic spine images show the thoracic vertebral bodies and intervertebral disk spaces, as well as the relationship between the individual vertebrae.^{1,2} The AP projection also allows for visualization of the transverse processes, posterior ribs and the costovertebral joints.^{1,2} The lateral projection includes visualization of the intervertebral foramina, the vertebral bodies and their alignment, and the intervertebral disk spaces.^{1,2} Routine AP and lateral images of the thoracic spine are shown in Figures 12A and 12B.

Scoliosis Imaging

The main reasons for initial imaging of patients with scoliosis are to confirm the initial diagnosis, evaluate the structural component of the curve, determine the curve's magnitude and estimate skeletal maturity.^{10,21} Because the majority of patients will be pediatric and the radiographs will be taken to confirm a suspected diagnosis, a limited number of images is all that is necessary. Evaluating the

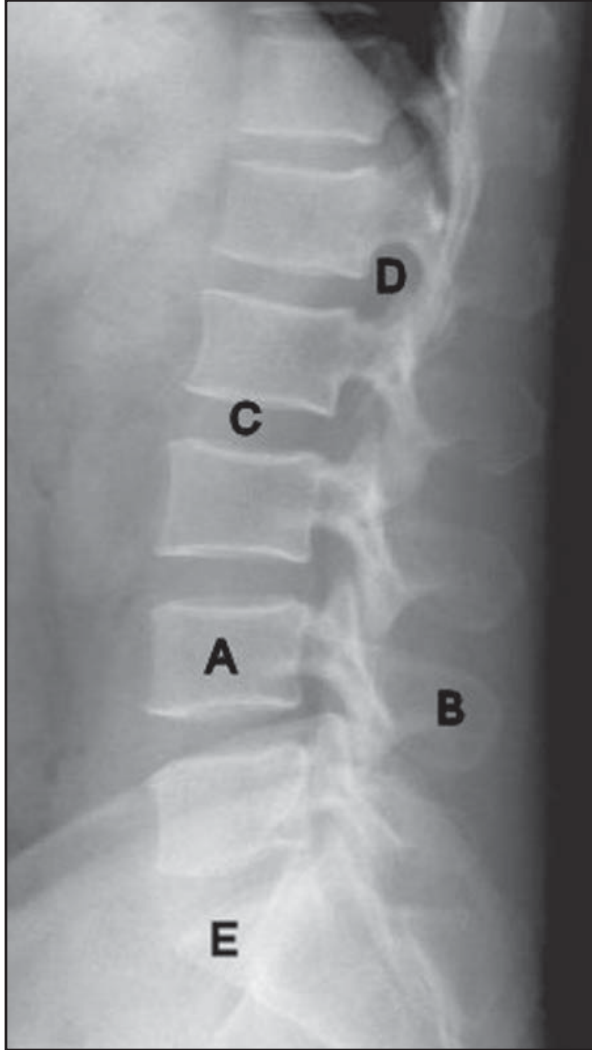


Figure 10B. Lateral projection of the lumbar spine demonstrating normal curves in the lumbar region. Common vertebral anatomy shown: L4 vertebral body (A), spinous process (B), intervertebral disk space (C), intervertebral foramina (D) and sacral promontory (E).

size, shape and relationship of the individual vertebrae in different body positions is not necessary in initial scoliosis diagnosis or monitoring of curve progression.

The scoliotic curve should be imaged in a way that shows the effect of gravity on the curve's magnitude.^{1,2} To assess the effects of gravity on the spine and the curve, patients with suspected scoliosis should be imaged erect.¹ When possible, a large image receptor (14 x 36 inches) should be used to include the entire spine on one projection, which can help minimize radiation dose.^{1,2,28} The

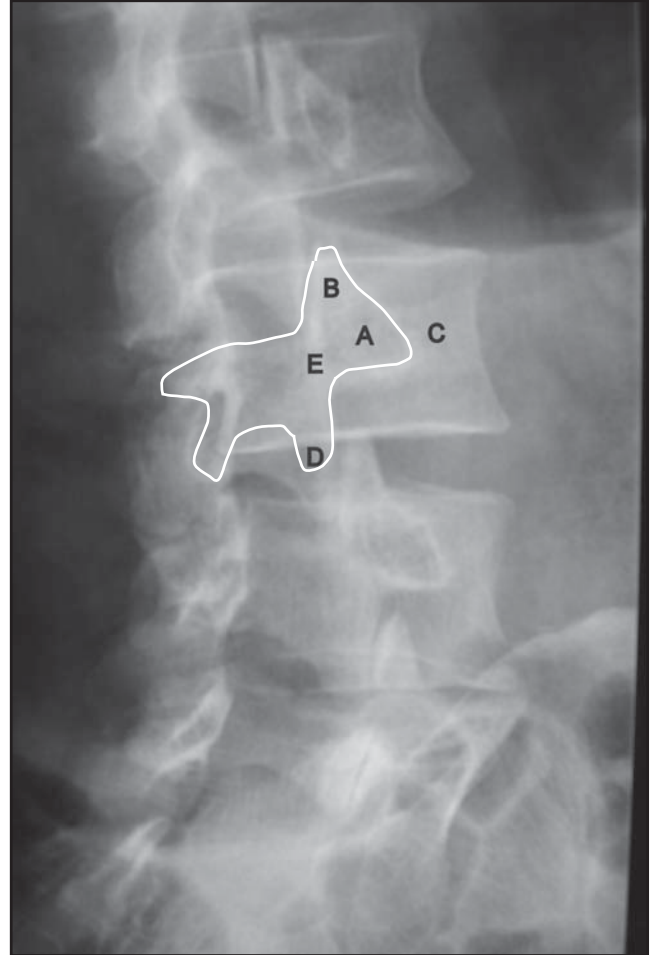

Figure 11. Oblique projection of the lumbar spine showing the vertebral anatomy that makes up the Scotty dog. A. The pedicle represents the eye. B. The superior articular process represents the ear. C. The transverse process represents the nose. D. The inferior articular process represents the leg. E. The area of the pars intertarsalis represents the neck.

source-to-image-receptor distance should be a minimum of 60 inches to allow exposure of the entire length of the larger IR.^{1,2}

Specific images that might be taken as part of a routine scoliosis examination include a PA/AP erect, erect lateral, PA/AP side-to-side bending and the Ferguson method.^{1,2,28} The most widely mentioned preferred initial images are the PA erect and lateral erect.^{9,10,21,28}

The PA erect and lateral erect images should include the entire thoracic and lumbar spines, the tops of the iliac bones and, in some instances, the cervical spine.^{1,2,28} In patients who have surgically treated scoliosis, these

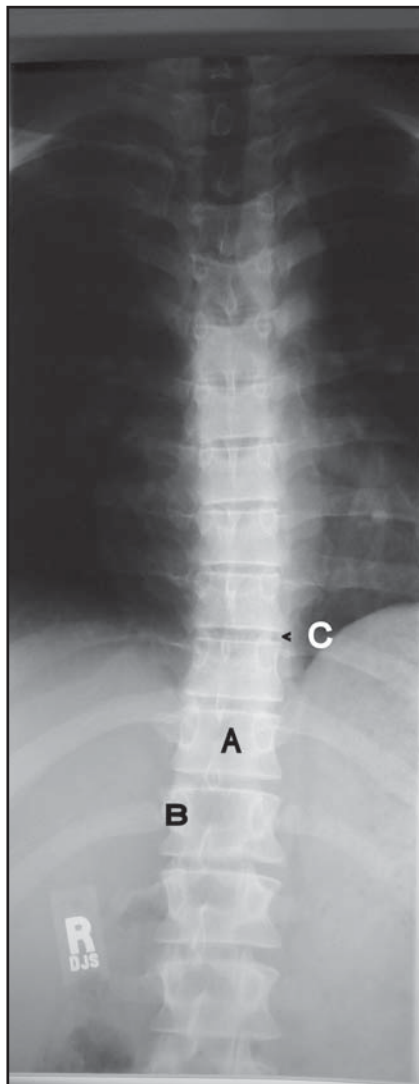


Figure 12A. AP projection of the thoracic spine demonstrating no abnormal curves in the thoracic region. A. Thoracic vertebral body (T-11). B. Area of the costovertebral joints. C. Intervertebral disk space.

images might be used to assess the internal fixation devices.¹ The erect PA and lateral projections are used most often to show the degree of curvature that occurs while the patient is standing.¹ Skeletal maturity plays a role in determining treatment options for the patient. Because the iliac regions are shown on the initial standing PA and lateral images, these images can be used to assess the patient's skeletal maturity using the previously mentioned Risser scale, thus minimizing the need for additional images of young patients.

The erect lateral image can be used to assess the patient for any exaggeration of the normal lumbar lordosis or thoracic kyphosis, which sometimes accompanies scoliosis.^{1,9} The erect lateral projection also can assist with determining the presence of spondylolysis or spondylolisthesis.^{1,9} Spondylolysis is a breakdown of the vertebral structure; spondylolisthesis is a slippage or forward subluxation of the lower lumbar vertebrae on the sacrum.³¹ These conditions are present in approximately 5% of the population.⁹

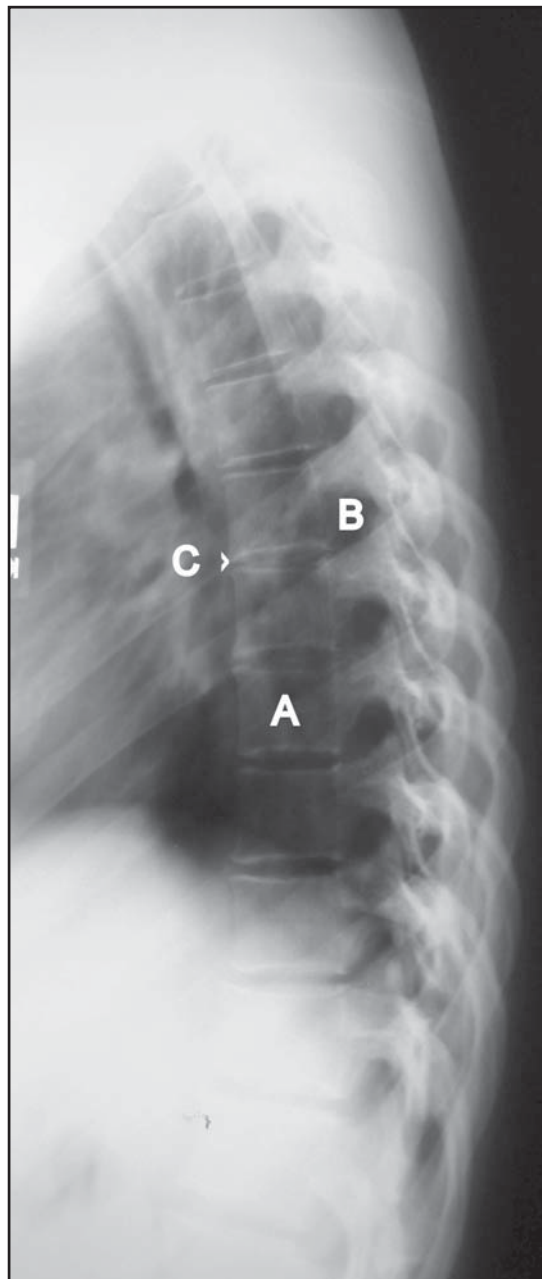


Figure 12B. Lateral projection of the thoracic spine demonstrating no abnormal curves in the thoracic region. A. Thoracic vertebral body. B. Intervertebral foramen. C. Intervertebral disk space.

Cobb Method

The Cobb method has been used since 1948 to measure the magnitude of the angle on the PA erect image.^{9,10,21,24,29} The Cobb angle is found by first locating

the endplates of the most angulated inferior and superior vertebrae of the curve.^{9,29} The angle then is determined from the intersection of a line perpendicular to each of the predetermined endplates.^{9,29} Figure 13 demonstrates how the Cobb angle is calculated.

The Cobb angle is useful in distinguishing between scoliosis and simple asymmetry.^{9,29} Curves less than 10° to 15° as measured by the Cobb angle are considered to be due to asymmetry rather than scoliosis.^{11,29} Figure 14 shows a 15-year-old male patient with a curve of 16°. Figure 15 shows a female patient, aged 14 years, with AIS. In this patient, the magnitude of the curve is 25°.

The Cobb angle also is useful as a monitoring tool to measure progression or correction of the curve during bracing or observation.²⁹ However, it is important to note that the Cobb angle does not measure the amount of vertebral rotation or alignment of the spine, nor does it account for the degree of tilt on the endpoint vertebrae.²⁹

Additional Images Used

Also useful in assessing scoliosis patients are PA/AP side-to-side bending images. In some patients with scoliosis, a secondary or compensatory curve may develop.^{1,9} The secondary curve is usually nonstructural and develops in response to the body trying to balance itself and keep the head in alignment with the feet.^{1,2,30} Figure 16 shows a 27-year-old female patient with a primary curve of 42° and a compensatory curve of 16° that developed superiorly to the original curve.

Bending images not only assist with measuring range of motion, they also can be useful in distinguishing between a primary scoliotic curve and a compensatory curve.^{1,2,9} Lateral bending images also can be used to assess the flexibility of the scoliotic curve to assist with determining what degree of straightening would be possible with surgical intervention.²⁸

Bending images should be performed with the patient erect and facing the IR; however, acceptable supine bending images also are possible. Using the pelvis as a fulcrum (a stationary point at which the body will pivot), the patient should be positioned in a lateral flexion position.² This involves the patient bending laterally, first to one side for an image, then to the other side for the second image. Patients should bend as far as they are able to without moving the pelvic area.

Bending images should include the thoracic and lumbar spines, or at least include as much of the thoracolumbar region as possible, and the tops of the iliac spines.^{2,28} Compensatory curves have a tendency to correct themselves or change when the patient bends.^{1,9}

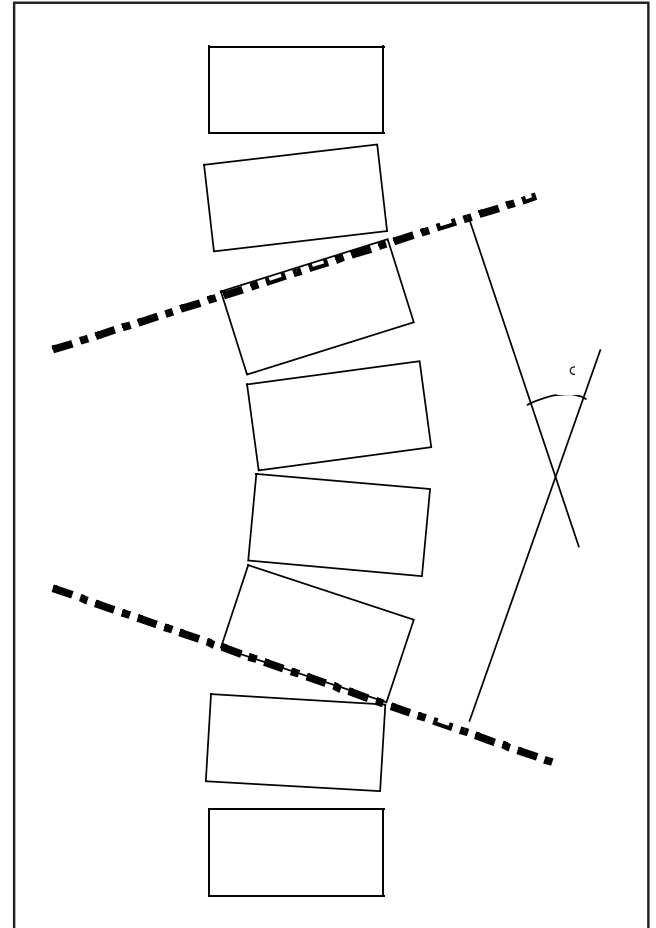


Figure 13. The Cobb method for finding the magnitude of a scoliotic curve. Redrawn and used with permission from the University of Washington School of Medicine Web site. www.rad.washington.edu/mskbook/scoliosis.html.

Primary curves do not change in appearance when the patient changes position.^{1,9}

The Ferguson method is another series of images that can be taken to help determine which curves are primary and which might be compensatory.^{1,2} The Ferguson method does not involve bending, but instead uses a standing block. The patient must be able to stand or sit unsupported.^{1,2} Two images are taken: a standard erect PA image that includes the entire spine (or at least the thoracic and lumbar regions) and an image using a block.^{1,2}

For the second image, the patient is asked to stand with 1 foot elevated 3 to 4 inches on the block.¹ The elevated foot should correspond to the convex side of the patient's curve.^{1,2} A full-spine image, preferably PA, should be

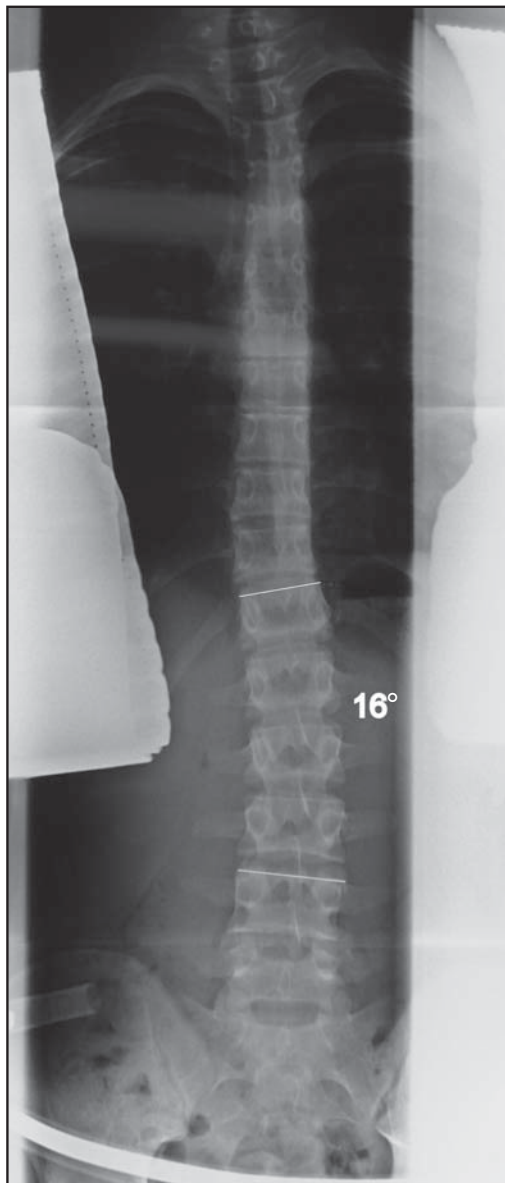


Figure 14. PA erect projection for determining the degree of spinal curvature. This is a 15-year-old male patient with a 16° curvature.

obtained with the patient in this position. Comparison of the 2 images will show any curve correction associated with elevation of the foot. Because curve correction does not occur in structural curves, any correction seen indicates an element of compensatory or secondary curve development.

A benefit of the Ferguson method is that it can be used to detect a secondary curve in a patient who cannot stand but can sit erect.² With the patient sitting, a block 3 to 4

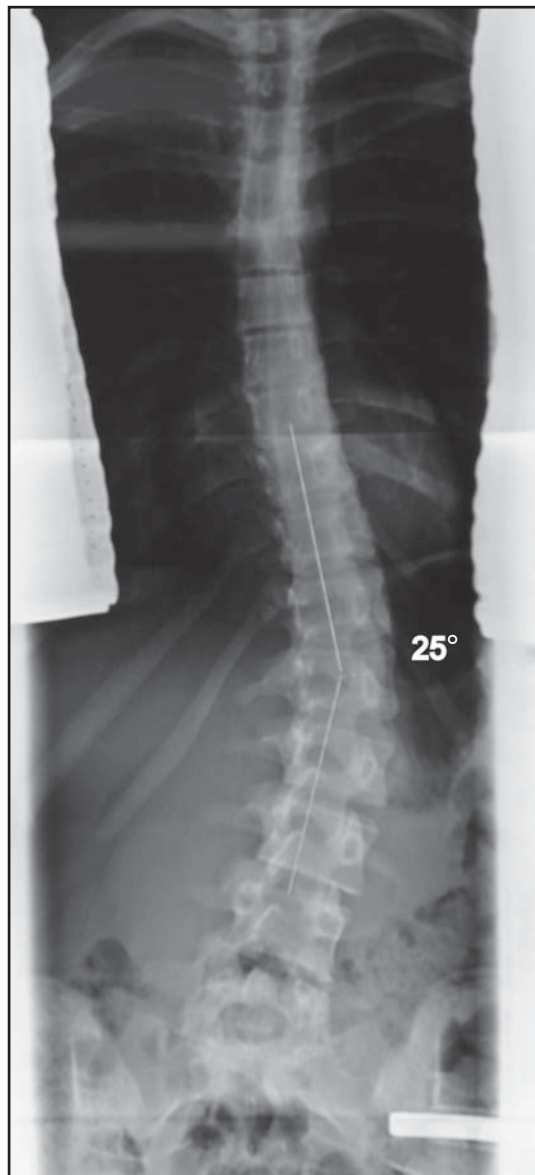


Figure 15. PA erect projection showing a 25° thoracolumbar curve.

inches in height is placed under the hip and buttock corresponding to the convex side of the curve.² This will elevate the patient enough to demonstrate a curve correction by comparing this image with the PA projection.

Other Imaging Techniques

Although other imaging modalities usually are not used in the diagnosis and follow-up of patients with scoliosis, these techniques can be useful when the patient

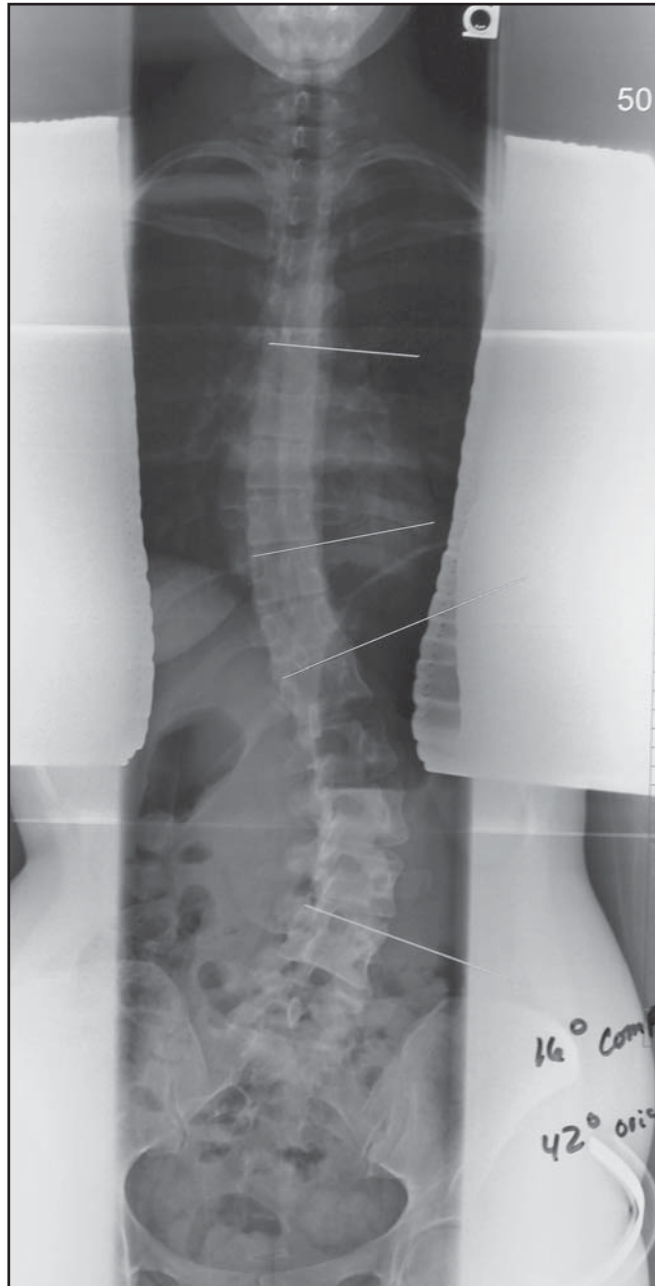

Figure 16. PA erect projection showing 2 spinal curves: a primary lumbar curve of 42° and a developing compensatory curve of 16° located superior to the primary curve.

is symptomatic.^{21,24} MR imaging has been used to image scoliosis patients. MR examinations usually are warranted when a patient has a left thoracic curve, when the patient has neurological signs on examination or when

there is pain, stiffness or other atypical signs or symptoms associated with the spinal curve.^{21,24} Nuclear medicine bone scans also are useful in patients who present with pain.²⁴ Bone scans can reveal an underlying tumor, infection or discitis.²⁴

Radiation Protection

Proper radiation protection practices are critically important in imaging patients with scoliosis. Reducing patient exposure is essential because most patients who are examined for scoliosis are girls younger than 18 years. These patients may have radiographic images taken often as part of the observation process, some every 4 to 6 months during skeletal growth.^{12,21}

Although radiation safety practices are specific to each radiology department, several general recommendations can be made to reduce exposure to adolescents during scoliosis imaging. Radiation protection for scoliosis imaging should include the use of preferred projections, minimized exposures, good collimation and proper shielding techniques. As imaging professionals, radiographers have a responsibility to protect their patients from excessive radiation exposure whenever possible.^{1,2}

Spinal images can be taken in either the PA or the AP projection. In many instances, routine spinal images are taken in the AP projection to place the spine closer to the IR and also to make the patient more comfortable if imaged on the table. However, when performing scoliosis imaging studies, the preferred projection for radiation protection purposes is the PA projection.^{1,2,28}

It is estimated that imaging the patient in the PA projection rather than the AP projection for spinal images can reduce the radiation dose to the ovaries by 25% to 30%.² Performing the study using the PA projection also can help reduce the radiation dose to breast tissue.^{1,2,23,25} Simply exposing the patient in the PA projection rather than the AP can reduce dose to the breast by an estimated 90%.²

Reducing the number of images also is a good radiation safety measure. Because the entire spine must be imaged, 1 way to reduce the number of exposures is to use the recommended 14 x 36 inch (35 x 90 cm) image receptor.^{1,2} This allows taking 1 image that shows the entire spine, rather than a series of images requiring multiple exposures. When using the larger IR, compensating filters can be used to improve image quality by allowing for a more even density between the thorax and abdomen.^{1,2} Figure 17 shows a dedicated Kodak DirectView CR unit specifically designed for scoliosis imaging.




Figure 17. A. Open, dedicated Kodak LLI DirectView CR unit showing cassette placement options. B. Kodak DirectView CR unit ready for imaging. Images courtesy of Radiology Consultants/Central Virginia Imaging of Lynchburg.

Because scoliosis images typically include the entire spinal column, both breast and gonadal shielding are warranted.^{1,2} Several types of shields are available. There are shields that the patient wears, called contact shields, and there are shadow shields that attach to the collimator housing. Both types of shielding are effective and 1 or the other should be used to reduce radiation exposure to the breast and gonadal areas. Figure 18 shows 1 type of contact lung/breast shield as well as a contact gonadal shield. Figure 19 shows the use of scoliosis shielding devices when the patient is imaged in the preferred PA projection. The lung/breast shields are adjustable to fit different size patients and are shown partially shortened. The lung/breast shields should be adjusted carefully so as not to overlie the spine during exposure. The gonadal shield is worn low on the hips or waist. Shielding preferences differ from

department to department, but many gonadal shields are worn so that the top of the shield corresponds to the anterior superior iliac spine region.

Collimation also is essential when radiographing patients to reduce exposure to areas of the body that are not of clinical interest. Collimation reduces the patient's exposure by reducing the volume of tissue that is irradiated, and in doing so it also reduces the amount of scatter radiation.² When scatter radiation is reduced, image quality increases — another reason to employ accurate collimation.²

Conclusion

Scoliosis affects between 2% and 4% of all adolescents.^{21,23} These patients may appear frequently in the radiology department for spinal imaging, not only to

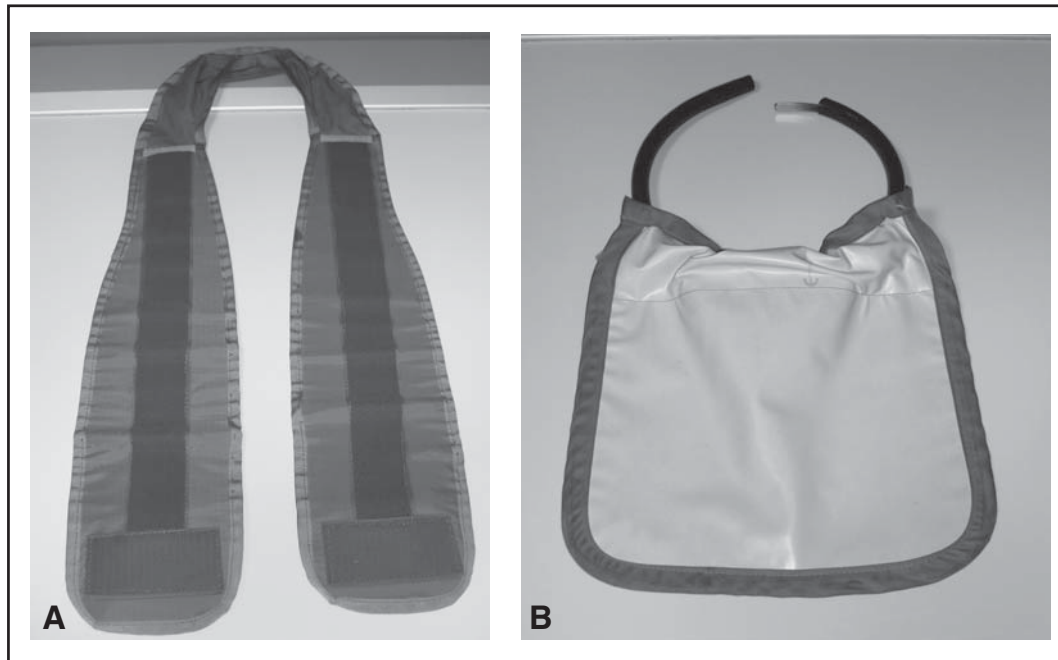


Figure 18. A. Breast/lung shield used for scoliosis imaging (shown in long length). B. Gonadal shield worn at waist or anterior superior iliac spine during scoliosis imaging. Images courtesy of Radiology Consultants/Central Virginia Imaging of Lynchburg.

confirm a diagnosis of scoliosis but also to evaluate the curve for structural components, determine the magnitude of the curve and estimate skeletal maturity. Once a patient has been diagnosed, follow-up images may be needed to monitor spine curves for progression.

Because radiology departments play a role in diagnosing and monitoring these patients, technologists should be familiar with scoliosis and how it affects the spine. Technologists also should have a basic understanding of the role that imaging plays in the treatment and observation process. By understanding scoliosis and the importance of radiology in monitoring and diagnosing spinal curves, technologists will be better prepared to provide the best possible images in the safest manner for these patients.

References

- Ballinger P, Frank E. *Merrill's Atlas of Radiographic Positions and Radiographic Procedures*. 10th ed. St. Louis, MO: Mosby Inc; 2003.
- Bontrager K, Lampignano J. *Textbook of Radiographic Positioning and Related Anatomy*. 6th ed. St. Louis, MO: Mosby Inc; 2005.
- Information. National Scoliosis Foundation Web site. www.scoliosis.org/index.php. Accessed November 10, 2006.
- Adolescent idiopathic scoliosis. North American Spine Society Web site. www.spine.org/fsp/prob_action-injury-scoliosis.cfm. Accessed November 15, 2006.
- Anatomy of the spine. All About Back & Neck Pain Web site. www.allaboutbackand-neckpain.com/html/spinesub.asp?id=45. Accessed November 18, 2006.
- Spinal Anatomy and Back Pain. Spine-health.com Web site. www.spine-health.com/topics/anat/a01.html. Accessed November 20, 2006.
- Mayo Clinic staff. Kyphosis. MayoClinic.com Web site. www.mayoclinic.com/health/kyphosis/ds00681/dsection=1. Published March 3, 2006. Accessed November 20, 2006.
- Laudicina P. *Applied Pathology for Radiographers*. Philadelphia, PA: WB Saunders Co; 1989.
- Scoliosis. University of Washington School of Medicine Web site. www.rad.washington.edu/mskbook/scoliosis.html. Accessed November 20, 2006.
- Hart E, Grottkau B. Your important role in managing scoliosis. *Clinical Advisor*. 2003;9(2):43-48.
- Mehlman CT. Idiopathic scoliosis. eMedicine Web site. www.emedicine.com/orthoped/topic504.htm. Updated June 30, 2004. Accessed November 20, 2006.
- What is scoliosis? Fast facts: an easy-to-read series of publications for the public. National Institute of Arthritis and Musculoskeletal and Skin Diseases Web site. www.niams.nih.gov/hi/topics/scoliosis/ffscoliosis.htm. Accessed November 23, 2006.
- Clinical review: scoliosis and spinal conditions in children. *General Practitioner*. January 6, 2006:19.
- The twentieth century's explanations for scoliosis. University of Iowa Hospitals & Clinics Web site. www.uihealthcare.com/depts/medmuseum/wallexhibits/scoliosis/history/20explanations.html. Updated October 16, 2006. Accessed December 5, 2006.
- The core curriculum: spines. Pediatric Orthopaedic Society of North America Web site. www.posna.org/index?service=page/corecurriculum. Accessed December

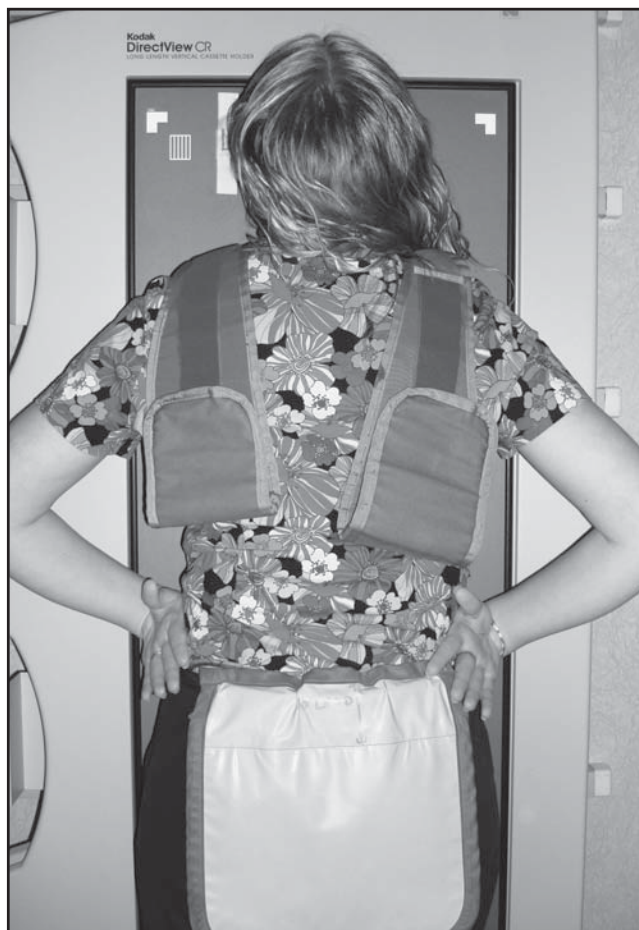

Figure 19. Patient position and shielding devices used during scoliosis imaging. The breast shields are folded to show adjustability.

- 5, 2006.
16. Treatments of the nineteenth and early twentieth centuries. University of Iowa Hospitals & Clinics Web site. www.uihealthcare.com/depts/medmuseum/wallexhibits/scoliosis/history/treat1920.html. Updated October 16, 2006. Accessed December 5, 2006.
 17. Falcone D. The Hibbs Society. Scoliosis Research Society Web site. www.srs.org/hibbs/about. Accessed November 12, 2006.
 18. Taft E, Francis R. Evaluation and management of scoliosis. *J Pediatr Health Care*. 2003;17(1):42-44. www.medscape.com/viewarticle/449233. Accessed December 10, 2006.
 19. In depth review of scoliosis. Scoliosis Research Society Web site. www.srs.org/patients/review. Updated September 2000. Accessed December 10, 2006.
 20. What is congenital scoliosis? National Scoliosis Foundation Web site. www.scoliosis.org/resources/medicalupdates

- /congenital.php. Accessed November 12, 2006.
21. Reamy BV, Slakey JB. Adolescent idiopathic scoliosis: review and current concepts. *Am Fam Physician*. 2001;64(1):111-116.
 22. Asher MA, Burton DC. Adolescent idiopathic scoliosis: natural history and long term treatment effects. *Scoliosis*. 2006;1(1):2. www.scoliosisjournal.com/content/1/1/2. Published March 31, 2006. Accessed November 21, 2006.
 23. Cutts S. Managing scoliosis in adolescents. *Practitioner*. 2006;250(1685):40-44.
 24. Skaggs DL, Bassett GS. Adolescent idiopathic scoliosis: an update. *Am Fam Physician*. 1996;53(7):2327-2335.
 25. Farley D. Correcting the curved spine of scoliosis. *FDA Consumer*. 1994;28(6):26-29.
 26. Skaggs DL. Referrals from scoliosis screenings. *Am Fam Physician*. 2001;64(1):32-35. www.aafp.org/afp/20010701/editorials.html. Accessed November 30, 2006.
 27. Agency for Healthcare Research and Quality. The guide to clinical preventative services 2006: recommendations of the U.S. Preventive Services Task Force. www.ahrq.gov/clinic/pocketgd.pdf. Published June 2006. Accessed January 1, 2007.
 28. Long B, Rafert J. *Orthopaedic Radiography*. 1st ed. Philadelphia, PA: WB Saunders Co; 1995.
 29. Foster JB. Experts debate role of Cobb angle in scoliosis bracing — 3D orthosis design must factor in many variables, including spinal alignment, for optimal outcomes. *BioMechanics*. 2006;13(5):41-46. www.biomech.com/showArticle.jhtml?articleID=187203210. Accessed July 25, 2007.
 30. Glossary of terms. National Scoliosis Foundation Web site. www.scoliosis.org/glossary.php. Accessed January 5, 2007.
 31. *Tabor's Cyclopedic Medical Dictionary*. 16th ed. Philadelphia, PA: FA Davis Co; 1989:1731.

Susan Anderson, M.A.Ed., R.T.(R), is an assistant professor of radiography at Central Virginia Community College in Lynchburg. She has a B.A. in chemistry from Lynchburg College and a master's degree in adult education from the University of Phoenix. Ms Anderson has been a registered radiographer since 1989, working in diagnostic radiography, mammography, administration and education. Currently, she is a clinical and didactic instructor who teaches radiographic procedures, positioning and pathology.

The author would like to give special thanks to the technologists of Centra Health and Radiology Consultants/Central Virginia Imaging in Lynchburg for their assistance in finding images for this article.