

See discussions, stats, and author profiles for this publication at: <https://www.researchgate.net/publication/255987767>

# Laser refractive surgery in glaucoma patients

Article in Saudi Journal of Ophthalmology · April 2011

DOI: 10.1016/j.sjopt.2010.04.003 · Source: PubMed

---

CITATION

1

---

READS

23

1 author:



[Essam A Osman](#)

King Saud University

50 PUBLICATIONS 322 CITATIONS

SEE PROFILE



King Saud University  
Saudi Journal of Ophthalmology

www.saudiophthaljournal.com  
www.ksu.edu.sa  
www.sciencedirect.com



REVIEW ARTICLE

# Laser refractive surgery in glaucoma patients

Essam Osman, MD, FRCS \*

Department of Ophthalmology, King Abdulaziz University Hospital (KAUH), Riyadh, Saudi Arabia

Received 11 March 2010; revised 10 April 2010; accepted 18 April 2010  
Available online 21 April 2010

## KEYWORDS

Glaucoma;  
Laser refractive surgery;  
Corneal thickness;  
LASIK

**Abstract** Glaucoma may not be an absolute contraindication to Laser-Assisted *in situ* Keratomileusis (LASIK), but so far it is a relative one. People who are glaucoma suspects or who have glaucoma are just as likely as any other to seek laser refractive surgery. LASIK is a popular ocular procedure, relatively pain free and it is carried out with an extremely precise computer-controlled excimer laser emission. On the other hand, glaucoma is a group of diseases manifested by optic nerve damage with visual field changes. Patients that undergo a transient but significant rise in intraocular pressure during LASIK procedure have risk of further optic nerve damage. Furthermore, steroids which are typically used after refractive surgery can increase intraocular pressure (IOP) especially in steroid responders, who are more prevalent among glaucoma patient. Glaucoma patients interested in LASIK surgery may visit a glaucoma specialist or another LASIK surgeon who has had experience with performing LASIK in glaucoma patients. PRK (photorefractive keratectomy), LASEK (laser epithelial keratomileusis) are good alternatives for glaucoma patients. Refractive surgeons might want to consider giving patients a photo of their optic nerve, or a drawing, or an objective record of their preoperative examination.

© 2010 King Saud University. Production and hosting by Elsevier B.V. All rights reserved.

\* Address: Department of Ophthalmology, King Abdulaziz University Hospital, P.O. Box 245, Riyadh 11411, KSA. Tel.: +966 1 4775731; fax: +966 1 4775741.

E-mail address: [essam.osman065@gmail.com](mailto:essam.osman065@gmail.com)



## Contents

1. Introduction . . . . .	170
2. Glaucoma. . . . .	170
3. LASIK. . . . .	170
4. Corneal thickness . . . . .	171
5. Steroid . . . . .	171
6. Acute angle closure glaucoma. . . . .	171
7. Retinal nerve fiber layer (RNFL) . . . . .	171
8. Can patients with glaucoma undergo laser refractive surgery? . . . . .	172
9. Conclusion . . . . .	172
References . . . . .	172

## 1. Introduction

Glaucoma is a broad spectrum of diseases that under which a considerable number of sub-groups of optic nerve related diseases lies, it involves loss of retinal ganglion cells in a characteristic pattern of optic neuropathy (Rokicki et al., 2007; Vrabec and Levin, 2007; Flammer and Mozaffarieh, 2007). LASIK stands for Laser-Assisted *in situ* Keratomileusis and is a procedure that permanently changes the shape of the cornea using an excimer laser. A mechanical knife, called a *microkeratome*, is used to cut a flap in the cornea (Fig. 1). A hinge is left at one end of this flap. The flap is folded back revealing the stroma, the middle section of the cornea. Pulses from a computer-controlled laser vaporize a portion of the stroma and the flap is replaced. LASIK for glaucoma patients is controversial; it may be recommended for some patients and not for others because of the use of a suction ring that may damage the optic disc by increasing the IOP in glaucoma patients. LASEK and PRK, in which a suction ring is not used, are more suitable as there is no rise of IOP during the procedure.

## 2. Glaucoma

Glaucoma is a major cause of blindness in the world and Saudi Arabia (Quigley, 1996). It is the second leading cause of blindness globally (World Health Organization, 2004; Potter et al., 2008). In spite of raised IOP being a significant risk factor for developing glaucoma, there is no definite threshold for intraocular pressure that causes glaucoma. One person may develop

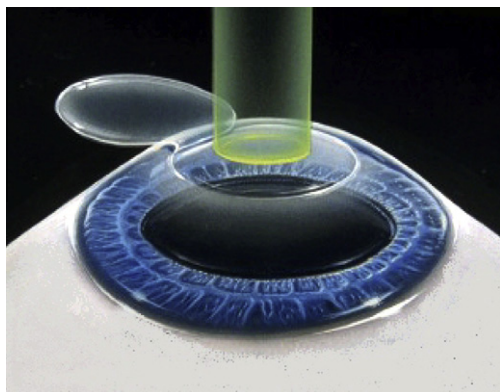


Figure 1 LASIK flap.

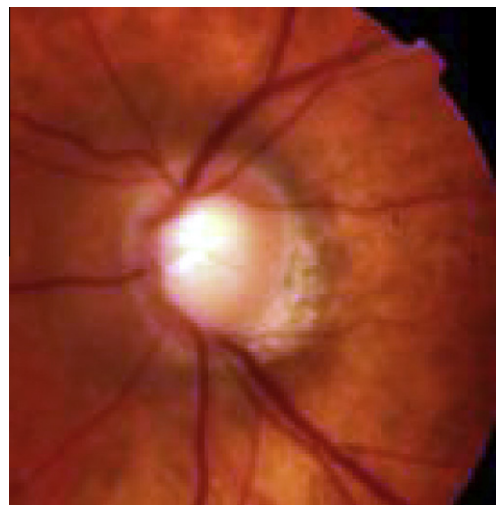


Figure 2 Glaucoma disc.

nerve damage at a relatively low-pressure, while another person may have high IOP for years and never develop nerve damages (Shields, 2008) (Fig. 2). Uncontrolled glaucoma progression leads to permanent damage of the optic nerve and visual field loss, which can lead to blindness. Glaucoma has been nicknamed “sneak thief of sight” because the loss of visual field often occurs gradually over a long time with resistance of papillomacular bundle that is responsible for maintaining good central vision and hence good visual acuity till the end of the disease, so damage may only be recognized when it is already quite advanced.

## 3. LASIK

LASIK stands for Laser-Assisted *In situ* Keratomileusis. LASIK surgery is the most popular form of laser eye surgery, in which an ophthalmic surgeon reshapes the cornea of the eye using an excimer laser, thereby corrects or enhances eyesight (Maldonado et al., 2008; Ghadhfan et al., 2007). LASIK is currently the dominant procedure in refractive surgery otherwise photorefractive keratectomy (PRK) has become currently used in correction of refractive errors to avoid post-LASIK ectasia (Randleman et al., 2008). The main advantage of LASIK over PRK is related to maintaining the central corneal epithelium, this increases comfort during the early post-operative period, allows for rapid visual recovery, and reduces the wound heal-

ing response (Slade et al., 2009; Ambrósio and Wilson, 2003). During LASIK, a microkeratome is affixed to the eye with suction, this suction greatly increases the IOP of the eye for a short time that may negatively affect a patient with glaucoma or someone predisposed to glaucoma (Bashford et al., 2005). Recently femtosecond laser technology provides a more precise, predictable method for creating the corneal flap than the conventional mechanical microkeratome (Kurtz et al., 1998; Lubastschowsky et al., 2000; Ratkay-Traub et al., 2001). This technology includes a solid-state laser used to create flaps during LASIK. The laser uses an infrared wavelength (1053 nm) to deliver closely spaced 3- $\mu$ m spots that can be focused to a preset depth to photo disrupt tissue within the corneal stroma. The resultant plasma produces cavitations bubbles, consisting primarily of water and carbon dioxide. Femtosecond laser system (example: IntraLase) relies on a low-pressure (35 mm Hg) suction ring to align and stabilize the globe. In a study by Hernández-Verdejo et al. (2007) on freshly enucleated porcine eyes, changes in IOP from the application of the suction ring through the end of the passage of the mechanical microkeratome (M2; Moria, Antony, France) or creation of the non-mechanical flap with the femtosecond laser, the IOP increased in both groups, although it followed a different pattern. In the Moria group, the mean IOP increase during suctioning was  $122.53 \pm 30.40$  mm Hg and reached a mean  $160.52 \pm 22.73$  mm Hg during the creation of the lamellar corneal flap, a great deal of fluctuation in the IOP levels is observed. However, in the IntraLase group, the mean IOP during suctioning was  $89.24 \pm 24.57$  and  $119.0 \pm 17.01$  mm Hg during the flap creation.

#### 4. Corneal thickness

The measurement of intraocular pressure (IOP) after LASIK may not be accurate because of changes in central corneal thickness. Goldman applanation tonometry, the “gold standard” for IOP assessment, is based on the Imbert-Fick principle, it overestimates IOP for thick corneas, and underestimates IOP for thin corneas. The Ocular Hypertension Treatment Study (OHTS) showed central corneal thickness (CCT) to be

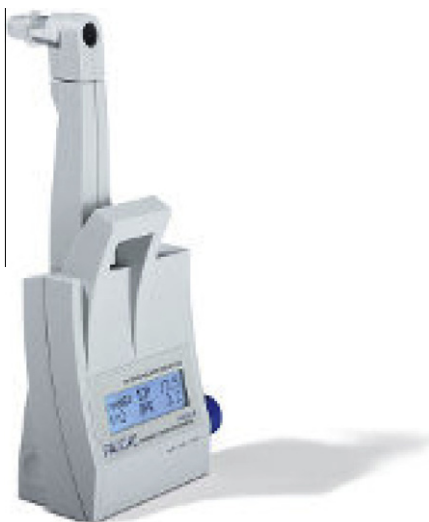

Figure 3 Pascal tonometry.

a powerful predictor of developing glaucoma, eyes with corneal thickness of 555 microns or less had a threefold greater risk of developing glaucoma (Brandt et al., 2008).

Overestimating IOP in patients with OHT and underestimating IOP in patients with NTG may be due to differences in corneal thickness (Lee et al., 2002). Nowadays, a new available tonometer, Pascal, whose results are not affected by corneal thickness are suited for monitoring IOP in unoperated eyes and in eyes that have had LASIK (Kniestedt et al., 2005; Siganos et al., 2004) (Fig. 3). There is a fear that, as the LASIK population ages, glaucoma will go undetected in large numbers of people. The physician should check for more than IOP, comprehensive eye examination should be done, which should include a dilated magnified and stereoscopic look at the optic nerve.

#### 5. Steroid

Steroid induced glaucoma is a secondary open angle glaucoma that is due to topical or systemic corticosteroid use. It is seen mainly with topical, high dose inhaled or oral steroids. Approximately 30% of the patients on topical therapy may be affected. Those who respond with increase in IOP have defective set of particular genes, are said to be responders. The general population of 25% will develop steroid-induced elevations in IOP after 4 times per day for 4 weeks with topical steroid drugs. 5% of population is “super-responders” – these patients develop pressure—elevations greater than 10–15 mm Hg with topical steroid use and may develop an IOP rise within 2 weeks.

Steroids are thought to change the Trabecular meshwork ability to process aqueous humor, Glycosaminoglycan accumulation is thought to be the underlying difficulty and Trabecular meshwork endothelium decreases phagocytotic ability. Steroid-induced rise in intraocular pressure after LASIK can cause transudation of aqueous fluid across the endothelium that collects in the flap; interface Elevated Intraocular Pressure Induced Interlamellar Stromal Keratitis (PISK) worsened by frequent topical steroids that indicated for post-LASIK diffuse lamellar keratitis (DLK) (Belin et al., 2002). The interface fluid leads to inaccurately low central applanation tonometry measurements that obscure the diagnosis of steroid-induced glaucoma, serious visual loss may result (Hamilton et al., 2002).

#### 6. Acute angle closure glaucoma

Acute angle closure glaucoma may take place after LASIK, especially in hyperopic patients, and it should be prevented through meticulous examinations including gonioscopy. Many postulations were suggested to elucidate the reason behind pupillary dilatation which explain the occurrence of angle closure attack, these include, the use of local anesthetic drops, the suction ring, steroid drops, emotional stress, dark room and mechanical deformity of anterior segment structure.

Prophylactic laser iridotomy should be performed for patients with narrow angle before LASIK correction. In terms of that, a case of unilateral angle closure glaucoma after hyperopic LASIK correction was reported as successfully managed by laser iridotomy (Paciuc et al., 2000). We presented a case report of bilateral acute angle closure glaucoma immediately after LASIK correction for Hyperopia that was managed well

with laser iridotomy in both eyes and IOP was controlled without medication for more than 6 months (Osman et al., 2009).

## 7. Retinal nerve fiber layer (RNFL)

RNF is formed by the expansion of the fibers of the optic nerve; it is thickest near the porous optics, gradually diminishing toward the ora serrata. As the nerve fibers pass through the lamina cribrosa, they lose their medullary sheaths and are continued onward through the choroid and retina as simple axis-cylinders. When they reach the internal surface of the retina they radiate from their point of entrance over this surface grouped in bundles, and in many places arranged in plexuses. Most of the fibers are centripetal, and are the direct continuations of the axis-cylinder processes of the cells of the ganglionic layer, but a few of them are centrifugal and ramify in the inner plexiform and inner nuclear layers, where they end in enlarged extremities. Optical Coherence Tomography (OCT) Imaging can be used to measure the thickness of the nerve fiber layer to give an indication on the status of the optic nerve as well (Gyatsho et al., 2008). Some case studies have reported that this increase in IOP damages the retinal ganglion cells, causing visual field defects (Piette et al., 2003). Other studies have reported that the retinal nerve fiber layer thickness decreases after uncomplicated LASIK (Nevyas et al., 2002; Roberts et al., 2002). Acute damage to the optic nerve after LASIK has also been reported (Lee et al., 2000). Other Studies have showed that transient extreme elevation of intraocular pressure during LASIK does not affect the optic disc morphology or retinal nerve fiber layer thickness in normal myopic eyes (Hamada et al., 2006; Whitson et al., 2003).

## 8. Can patients with glaucoma undergo laser refractive surgery?

Many questions are always raised from patients in the glaucoma clinic; can I do LASIK? And definitely we do not have a single answer as each case differ from other.

LASIK can still be an option for a patient with glaucoma, particularly if the pressure within the eye is considered to be under control. The surgeon might pick between PRK and LASIK but both are similar forms of laser vision correction. PRK generally causes less of a pressure increase during the surgery so is sometimes the favored method of laser vision correction. Following LASIK or PRK, a glaucoma patient must be aware that future measurements of IOP must be adjusted to determine a true reading. While this is not difficult, it is simply one extra consideration to ensure that the glaucoma treatment is still effective. If a patient is turned down for LASIK surgery because he has glaucoma, it might be advisable to visit a glaucoma specialist or another LASIK surgeon who has had experience with performing LASIK on glaucoma patients. Physicians should be aware of patients with glaucoma risk factors who seek LASIK surgery including myopia, hyperopia, Family history of glaucoma, high IOP, Diabetes, suspicious optic nerve appearance.

## 9. Conclusion

LASIK in glaucoma patients presents a challenge to physicians; the importance of this review comes from the fact that

Glaucoma can be a complication for someone who is willing to undergo laser refractive surgery. Individuals with high IOP or predisposed to glaucoma may not be appropriate for LASIK, or may be at a great risk of developing permanent Glaucoma. Pre-existing glaucoma should not be an absolute contraindication for LASIK surgery, but it should be a relative contraindication, because every patient has to be evaluated individually, and further studies are still needed to determine whether the procedure presents any added risk. If the glaucoma is under good control, there might be a good chance to undertake refractive surgery which is still an option however (Lin and Yu, 2006), PRK or LASEK, do not require a microkeratome and do not dramatically raise the patient's IOP and are good options for glaucoma patients, Also Patients who did filtering surgery with bleb formation are also recommended to avoid suction ring. Pascal tonometry is advisable tool for measuring post-LASIK IOP.

## References

- Ambrósio Jr., R., Wilson, S., 2003. SLASIK vs. LASEK vs PRK: advantages and indications. *Seminars in Ophthalmology* 18 (1), 2–10.
- Bashford, K.P., Shafranov, G., Tauber, S., Shields, M.B., 2005. Considerations of glaucoma in patients undergoing corneal refractive surgery. *Survey of Ophthalmology* 50 (3), 245–251.
- Belin, M.W., Hannush, S.B., Yau, C.W., Schultze, R.L., 2002. Elevated intraocular pressure-induced interlamellar stromal keratitis. *Ophthalmology* 109 (10), 1929–1933.
- Brandt, J.D., Gordon, M.O., Beiser, J.A., et al., 2008. Changes in central corneal thickness over time: the ocular hypertension treatment study. *Ophthalmology* 115, 1550–1556.
- Flammer, J., Mozaffarieh, M., 2007. What is the present pathogenetic concept of glaucomatous optic neuropathy? *Survey of Ophthalmology* 52 (Suppl. 2), S162–S173.
- Ghadhfan, F., Al-Rajhi, A., Wagoner, M.D., 2007. Laser in situ keratomileusis versus surface ablation: visual outcomes and complications. *Journal of Cataract and Refractive Surgery* 33 (12), 2041–2048.
- Gyatsho, J., Kaushik, S., Gupta, A., Pandav, S.S., Ram, J., 2008. Retinal nerve fiber layer thickness in normal, ocular hypertensive, and glaucomatous Indian eyes: an optical coherence tomography study. *Journal of Glaucoma* 17 (2), 122–127.
- Hamada, N., Kaiya, T., Oshika, T., et al., 2006. Optic disc and retinal nerve fiber layer analysis with scanning laser tomography after LASIK. *Journal of Refractive Surgery* 22 (4), 372–375.
- Hamilton, David Rex, Manche, Edward E., Rich, Larry F., Maloney, Robert K., 2002. Steroid-induced glaucoma after laser in situ keratomileusis associated with interface fluid. *Ophthalmology* 109 (4), 659–665.
- Hernández-Verdejo, José L., Teus, Miguel A., et al., 2007. Porcine model to compare real-time intraocular pressure during LASIK with a mechanical microkeratome and femtosecond laser. *Investigative Ophthalmology and Visual Science* 48, 68–72.
- Kniestedt, Christoph, Kanngiesser, Hartmut, Stamper, Robert L., 2005. Assessment of Pascal dynamic contour tonometer in monitoring IOP after LASIK. *Journal of Cataract and Refractive Surgery* 31 (3), 458–459.
- Kurtz, R.M., Horvach, C., Liu, H.-H., et al., 1998. Lamellar refractive surgery with scanned intrastromal picosecond and femtosecond laser pulses in animal eyes. *Journal of Refractive Surgery* 14, 541–548.
- Lee, A.G., Kohnen, T., Ebner, R., 2000. Optic neuropathy associated with laser in situ keratomileusis. *Journal of Cataract and Refractive Surgery* 26, 1581–1584.

- Lee, G.A., Khaw, P.T., Ficker, L.A., et al., 2002. The corneal thickness and intraocular pressure story: where are we now? *Clinical and Experimental Ophthalmology* 30, 334–337.
- Lin, X., Yu, M., 2006. Application of laser-assisted in situ keratomileusis in glaucoma patients. *Yan Ke Xue Bao* 22, 80–84.
- Lubastowsky, H., Maatz, G., Heisterkamp, A., et al., 2000. Application of ultrashort laser pulses for intrastromal refractive surgery. *Graefe's Archive for Clinical and Experimental Ophthalmology* 238, 33–39.
- Maldonado, M.J., Nieto, J.C., Piñero, D.P., 2008. Advances in technologies for laser-assisted in situ keratomileusis (LASIK) surgery. *Expert Review of Medical Devices* 5 (2), 209–229.
- Nevyas, J.Y., Nevyas, H.J., Nevyas-Wallace, A., 2002. Change in retinal nerve fiber layer thickness after laser in situ keratomileusis. *Journal of Cataract and Refractive Surgery* 28, 2123–2128 ([CrossRef][Web of Science][Medline][Order article via Infotrieve]).
- Osman, Essam A., Alturki, T., AlSaleh, A., et al., 2009. Bilateral acute angle closure glaucoma after hyperopic LASIK correction. *Saudi Journal of Ophthalmology* (3–4), 215–217.
- Paciuc, M., Velasco, C.F., Naranjo, R., 2000. Acute angle-closure glaucoma after hyperopic laser in situ keratomileusis. *Journal of Cataract and Refractive Surgery* 26 (4), 620–623.
- Piette, S., Liebman, J.M., Ishihara, H., Gurses-Ozden, R., Buxton, D., Rich, R., 2003. Acute conformational changes in the optic nerve head with rapid intraocular pressure elevation: implications for LASIK surgery. *Ophthalmic Surgery, Lasers and Imaging* 34, 334–341.
- Potter, B.K., Avard, D., Graham, I.D., Entwistle, V.A., et al., 2008. Guidance for considering ethical, legal, and social issues in health technology assessment: application to genetic screening. *International Journal of Technology Assessment in Health Care* 24, 412–422.
- Quigley, H.A., 1996. Number of people with glaucoma worldwide. *British Journal of Ophthalmology* 80 (5), 93–389.
- Randleman, J.B., Woodward, M., Lynn, M.J., Stulting, R.D., 2008. Risk assessment for ectasia after corneal refractive surgery. *Ophthalmology* 115 (1), 37–50.
- Ratkay-Traub, I., Juhasz, T., Horvath, D., et al., 2001. Ultra-short pulse femtosecond laser surgery, initial use in LASIK flap creation. *Ophthalmology Clinics of North America* 14, 347–355.
- Roberts, T.V., Lawless, M.A., Rogers, C.M., et al., 2002. The effect of laser-assisted in situ keratomileusis on retinal nerve fiber layer measurements obtained with scanning laser polarimetry. *Journal of Glaucoma* 11, 173–176.
- Rokicki, W., Dorecka, M., Romaniuk, W., 2007. Retinal ganglion cells death in glaucoma—mechanism and potential treatment. *Klinka Oczna* 109 (7–9), 353–355.
- Shields, M.B., 2008. Normal-tension glaucoma: is it different from primary open-angle glaucoma? *Current Opinion in Ophthalmology* 19 (2), 85–88.
- Siganos, D.S., Papastergiou, G.I., Moedas, C., 2004. Assessment of the Pascal dynamic contour tonometer in monitoring intraocular pressure in unoperated eyes and eyes after LASIK. *Journal of Cataract and Refractive Surgery* 30 (4), 746–751.
- Slade, S.G., Durrie, D.S., Binder, P.S., 2009. A prospective, contra lateral eye study comparing thin-flap LASIK (sub-Bowman keratomileusis) with photorefractive keratectomy. *Ophthalmology* 116 (6), 1075–1082.
- Vrabec, J.P., Levin, L.A., 2007. The neurobiology of cell death in glaucoma. *Eye* 21 (Suppl. 1), S11–S14.
- Whitson, J.T., McCulley, J.P., Cavanagh, H.D., Song, J., Bowman, R.W., Hertzog, L.E., 2003. Effect of laser in situ keratomileusis on optic nerve head topography and retinal nerve fiber layer thickness. *Journal of Cataract and Refractive Surgery* 29 (12), 2302–2305.
- World Health Organization, 2004. Global data on visual impairment in the year 2002. *Bulletin of the World Health Organization*, vol. 82, Number 11, November 2004, pp. 811–890.