


This article was downloaded by:[ANKOS 2007 ORDER Consortium]
On: 28 November 2007
Access Details: [subscription number 772814176]
Publisher: Informa Healthcare
Informa Ltd Registered in England and Wales Registered Number: 1072954
Registered office: Mortimer House, 37-41 Mortimer Street, London W1T 3JH, UK



International Journal of Neuroscience

Publication details, including instructions for authors and subscription information:

<http://www.informaworld.com/smpp/title~content=t713644851>

UNERTAN SYNDROME: A CASE SERIES DEMONSTRATING HUMAN DEVOLUTION

Üner Tan ^a; Sibel Karaca ^b; Meliha Tan ^b; Bekir Yilmaz ^c; Namik Kemal Bagci ^c;
Ayhan Ozkur ^d; Sadrettin Pence ^d

^a Cukurova University, Faculty of Sciences, Adana, Turkey

^b BaŞkent University, Department of Neurology, Adana, Turkey

^c Sevgican Polikliniği, Islahiye, Gaziantep,, Turkey

^d Gazi Antep University, Medical School, Department of Radiology, Gazi Antep,
Turkey

Online Publication Date: 01 January 2008

To cite this Article: Tan, Üner, Karaca, Sibel, Tan, Meliha, Yilmaz, Bekir, Bagci,

Namik Kemal, Ozkur, Ayhan and Pence, Sadrettin (2008) 'UNERTAN SYNDROME: A CASE SERIES
DEMONSTRATING HUMAN DEVOLUTION', International Journal of Neuroscience, 118:1, 1 - 25

To link to this article: DOI: 10.1080/00207450701667857

URL: <http://dx.doi.org/10.1080/00207450701667857>

PLEASE SCROLL DOWN FOR ARTICLE

Full terms and conditions of use: <http://www.informaworld.com/terms-and-conditions-of-access.pdf>

This article maybe used for research, teaching and private study purposes. Any substantial or systematic reproduction, re-distribution, re-selling, loan or sub-licensing, systematic supply or distribution in any form to anyone is expressly forbidden.

The publisher does not give any warranty express or implied or make any representation that the contents will be complete or accurate or up to date. The accuracy of any instructions, formulae and drug doses should be independently verified with primary sources. The publisher shall not be liable for any loss, actions, claims, proceedings, demand or costs or damages whatsoever or howsoever caused arising directly or indirectly in connection with or arising out of the use of this material.

UNERTAN SYNDROME: A CASE SERIES DEMONSTRATING HUMAN DEVOLUTION

ÜNER TAN

Cukurova University
Faculty of Sciences
Adana, Turkey

SIBEL KARACA MELIHA TAN

Başkent University
Department of Neurology
Adana, Turkey

BEKİR YILMAZ NAMIK KEMAL BAGCI

Sevgican Polikliniği
İslihiye, Gaziantep, Turkey

AYHAN OZKUR

Gazi Antep University
Medical School, Department of Radiology
Gazi Antep, Turkey

SADRETTİN PENCE

Gazi Antep University
Medical School, Department of Physiology
Gazi Antep, Turkey

Received 22 January 2007.

This work was supported by the Research Funds of the Gaziantep University. Also this study was partly supported by the Turkish Academy of Sciences, Ankara, Turkey.

Address correspondence to Prof. Dr. Uner Tan, Cukurova University, Faculty of Sciences, Department of Physics, Balcalı Adana 01330, Turkey. E-mail: unertan37@yahoo.com

A large family with six individuals exhibiting the Unertan syndrome (UTS) was identified residing in southern Turkey. All of the individuals had mental impairments and walked on all four extremities. The practice of intra-familial marriages suggested that the UTS may be an autosomal recessive disorder, similar to previously described cases. The inferior portions of the cerebellum and vermis were absent as evidenced by MRI and CT scans. The height and head circumference of those affected were within normal ranges. Barany's test suggested normal vestibular system function. The subjects could not name objects or their close relatives. The males ($n = 4$) could understand simple questions and commands, but answered questions with only one or two sounds. The females ($n = 2$) were superior to the males with respect to language skills and walking, suggesting an association between walking and speaking abilities. One male exhibited three walking patterns at the same time: quadrupedal, tiptoe, and scissor walking. Another male used two walking styles: quadrupedal and toe-walking. It is emphasized that there are important differences between the UTS and the disequilibrium syndrome. It is suggested that the inability to walk upright in those affected with the UTS may be best explained by a disturbance in lateral-balance mechanisms, without being related to the cerebello-vestibular system. An interruption of locomotor development during the transition from quadrupedality to bipedality may result in habitual walking on all four extremities and is normal in some children. Because quadrupedal gait is an ancestral trait, individuals with the UTS, exhibiting a manifestation of reverse evolution in humans, may be considered an experiment of nature, useful in understanding the mechanisms underlying the transition from quadrupedality to bipedality during human evolution. The proposed mutant gene or gene pool playing a role in human quadrupedality may also be responsible for human bipedality at the same time. Herein there is no intent to insult or injure; rather, this report is an endeavor to better understand human beings. Supplementary materials are available for this article. Go to the publisher's online edition of *International Journal of Neuroscience* for the following free supplemental resource(s): video clips.

Keywords ataxia, cerebellar hypoplasia, language impairment, quadrupedality, scissoring gait, toe-gait, Unertan syndrome, vermial hypoplasia

INTRODUCTION

The Unertan syndrome, recently described in two consanguineous families, one family residing near Iskenderun and the other family in Adana, is characterized by three ancestral features: quadrupedal gait, primitive intelligence with a primitive conscious experience, and primitive language (Tan, 2005a, b, 2006a, b, c). Although the affected individuals in two different families are known to exhibit similar features, the underlying neural mechanisms differ and involve a central vestibular disorder in the first family and a peripheral vestibular disorder in the second family (Tan et al., 2007 [in press]). Accordingly, there is a cerebellar hypoplasia, especially involving the vermis, as evidenced by MRI

and PET scans of the affected individuals in the first family, whereas these structures appear to be normal in the second family.

Following a worldwide interest in the UTS, a physician (NKB) working in a private clinic near Gaziantep reported a large family that exhibited features consistent with the UTS that were relatives of his colleague (BY). NKB thus invited the author (UT) to the village for verification. Indeed, there was a very large consanguineous family consisting of five sub-families, replete with intra-familial marriages. Interestingly, this family lives in a small village near Syria, as does the first family described.

The present study was aimed at reporting the results of the physical and radiologic examinations of the affected individuals from the new family, considering the possible relations to ancestral traits, such as a quadrupedal walking pattern and primitive cognitive abilities, specifically intelligence, speech, and a conscious experience.

METHODS

Participants

As illustrated in Figure 1, this is a very large family with intra-familial marriages, living in a small village in southern Turkey near the Syrian border. Although the affected individuals, that is, those habitually walking quadrupedally with cognitive impairment, including language, are now between 12 and 46 years of age, they have not attracted the interest from any physician or scientist until now. One of the authors, BY, a relative of this family, contacted UT, who first described the UTS, and invited him to evaluate some of his relatives in the hope of establishing a diagnosis. The current report is an abbreviated account of the identification of the third family exhibiting the UTS.

There were five sub-families, with at least one individual in each exhibiting the UTS, most likely resulting from intra-familial marriages (Figure 1). One quadrupedal male (V-12) died during childhood. The gender, age, and height of the affected individuals are presented in Table 1. Six affected participants underwent physical and radiologic examinations. The parents of the affected individuals provided written consent prior to examinations. The affected individuals could neither read nor write.

Neurologic Examination

All neurologic examinations were performed by two neurologists (SK and MT). Clinical tests were used to examine nystagmus, truncal stability during sitting

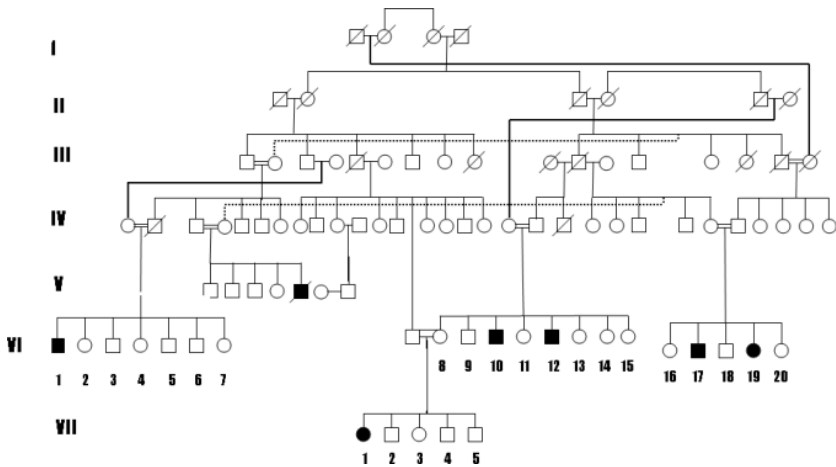


Figure 1. Gynology of the family living in a small village in the Southern Turkey.

and standing, ataxia, cranial nerve integrity, muscle tone, muscle strength, coordination (rapid alternating movements and point-to-point movements), the Romberg sign, deep tendon reflexes, clonus, plantar responses (Babinsky reflex), and vibration and position sense.

To assess the function of the peripheral and/or central vestibular system, Barany's caloric nystagmus test was performed. During this test, the participant was placed in a reclining position with the head inclined 30 degrees from the horizontal. Water, at 7°C below body temperature, was introduced through a plastic tube into the ear canal for 30 s, and nystagmus was recorded as movement in a direction opposite to the stimulated side. The duration of nystagmus was measured by a stop watch; it normally decayed within 2 min. This procedure was separately performed for the right and left ears. During caloric vestibular stimulation, the vestibular cortex within the posterior insula and retroinsular regions are activated; the visual cortex is also bilaterally activated (Bense et al., 2004).

Magnetic Resonance Imaging

Patients were scanned with a Siemens 1.5 T magnetic resonance scanner (Erlangen, Germany) using a standard head coil and a titled T-1 weighted coronal and sagittal sequence and a T-2 weighted axial spin-echo sequence. Prior to performing the MRI, the participants were asked to remove anything

Table 1. Physical and neurological measurements in affected individuals

Traits	(VI-1)	(VI-10)	(VI-12)	(VI-17)	(VI-19)	(VII-1)
	İBRAHİM SAHAN	ADNAN YILMAZ	HALEF YILMAZ	HASAN YILMAZ	SEMA YILMAZ	ESER SAHAN
Gender	Male	Male	Male	Male	Female	Female
Age	35	46	37	17	12	17
Height (cm)	158	152	145	150	135	142
Trunc.ataxia	(+)	(+)	(+)	(+)	(+)	(+)
Romberg	(-)	(-)	(-)	(-)	(-)	(-)
Epilepsy	(-)	(-)	(-)	(-)	(-)	(+)
Arm-reflexes	Hyper	Vivid	Normal	Normal	Normal	Vivid
Leg-reflexes	Hyper	Vivid	Hyper	Hyper	Hyper	Hyper
Hoffman (R)	(-)	(+)	(+)	(-)	(-)	(-)
Hoffman (L)	(-)	(+)	(+)	(-)	(-)	(-)
Trommer (R)	(-)	(-)	(+)	(-)	(-)	(+)
Trommer (L)	(-)	(-)	(+)	(-)	(-)	(+)
Babinsky (R)	(+)	(-)	(-)	(-)	(+)	(+)
Babinsky (L)	(+)	(-)	(-)	(-)	(+)	(-)
Clonus (R)	(-)	(-)	(-)	(+)	(-)	(-)
Clonus (L)	(-)	(-)	(-)	(+)	(-)	(-)
Spasticity	(-)	(-)	(-)	(-)	(-)	(-)
Force (arms)	Normal	Normal	Normal	Normal	Normal	Normal
Force (legs)	Normal	Normal	Normal	Normal	Normal	Normal
Int.tremor(R)	(-)	(-)	(-)	(+)	(-)	(+)
Int/tremor(L)	(-)	(-)	(-)	(+)	(-)	(-)
Dysmetria(R)	(+)	(+)	(-)	(+)	(?)	(-)
Dysmetria(L)	(+)	(+)	(-)	(+)	(?)	(+)
Dysdia. (R)	(?)	(+)	(+)	(?)	(+)	(+)
Dysdia. (L)	(?)	(+)	(+)	(?)	(+)	(+)
Vibration	(?)	(?)	(?)	(?)	(?)	(?)
Arm (cm)	73	67	67	71	58	61
Leg (cm)	90	84	81	81	79	79
Head (cm)	53	55	52.5	53	51	54
Cal. Nys. (R)	<2 min	<2 min	<2 min	<2 min	<2 min	<2 min
Cal. Nys. (L)	<2 min	<2 min	<2 min	<2 min	<2 min	<2 min

Dysdia.: Dysdiadochokinesis; R: right; L: left; Cal. Nys.: caloric nystagmus.

that might degrade the MRI images of the head, such as hairpins, jewelry, eyeglasses, and hearing aids. The individuals were then placed on a sliding table so that the surface coil was positioned around the head. After positioning the individuals with the head inside the MRI gantry, the radiologist and technologists left the room, and the MRI sequences were performed. The

individuals were asked not to move during the imaging process. They were, however, able to communicate with the radiologist at any time using an intercom.

The regions of interest on the MRI scans were traced manually by a single investigator, blinded to the clinical data and diagnostic category, using a workstation (Sun Microsystems Inc., Mountain View, CA, USA) and commercially available software for image analysis (Magic View 1000, Siemens). Total areas (mm^2) of the vermis, cerebellar hemispheres, cingulate gyrus, lentiform nucleus, and thalamus were obtained by outlining these structures on coronal and sagittal slices. The cerebellar vermis and corpus callosum were traced on the mid-sagittal section. The cerebellar hemispheres were traced on the coronal sections, excluding the vermis, cerebellar peduncles, and the fourth ventricle. The lentiform nucleus and thalamus were traced on the axial section. The measured areas on the MRI slices have been shown elsewhere (Tan et al., 2007).

RESULTS

There were five sub-families within the main family that practiced intra-familial marriages. The genealogy of the family is presented in Figure 1. The filled squares (males) and circles (females) depict the individuals exhibiting the UTS. The affected individual in family V (12), known to have a quadripedal gait (expected probability, 25%; observed frequency, 20%), died at age four after falling from a balcony. Of seven children, one man was affected within family V (1–7) (expected probability, 25%; observed frequency 14%). Of eight children, two men (14, 18) were affected within family V, 13–20 (expected probability, 25%; observed frequency, 25%). Within family VI, there was one male (20%) and one female (20%) affected individuals.

İBRAHİM SAHAN, V-1, MALE, 35 YEARS OF AGE

Walking Pattern

İbrahim's gait is illustrated in Figure 2. He habitually walks on all four extremities using a diagonal pattern, with the feet at diagonal ends of the body striking the ground together to simultaneously maintain balance and support; for example, as the left foot and right hand are grounded, the left hand and right foot are suspended, and then the opposite diagonal combination occurs so as to effect progressive forward movement.



Figure 2. İbrahim Sahan's palmigrade pig-toe walking.

As also seen in Video clip 1, he does not use a wide-based gait. However, he crosses his legs during quadrupedal walking, exhibiting a scissoring gait, characterized by slightly flexed legs hitting and even crossing in a scissor-like movement. Furthermore, he usually walks on his tiptoes (i.e., a tiptoe gait).

He is able to stand upright and remain in the upright position with flexed hips and knees, as long as he desires. However, he falls down if he tries to lift one of his feet, not being able to initialize a step from the upright position. Although İbrahim also uses crutches to walk around the village, he prefers walking on all four extremities as part of his everyday routine because of its ease.

Speech

İbrahim cannot speak. If he has to speak, he usually answers questions with an understandable simple sound after a delay, such as “pa-pa.” He seems to understand simple questions and needs, such as eating, walking, returning, not engaging in a specific act, coming toward someone, and stopping. The mini-mental-state examination test could not be applied because he could not understand the questions. There was a severe problem in communication. His cognitive faculties were not accessible because of his severe mental retardation. Apparently, he has no conscious experience; he is not aware of time, place, year, or day.

CT Scan

MRI scans could not be performed on İbrahim Sahin because it was not possible to maintain his equanimity during the scanning procedure. Therefore, a CT scan was performed. Figure 3 depicts the coronal (above, left) and mid-sagittal (below, left) CT scans of İbrahim Sahan and an unaffected control person (right). There was cerebellar hypoplasia (arrow) with absence of the inferior portion (above, left). There was also vermial hypoplasia (arrow), again with absence of the inferior portion (below, left). The black region outside the cerebellum and vermis has no tissue and is filled with cerebrospinal fluid.

ADNAN YILMAZ, V-14, MALE, 46 YEARS OF AGE

Walking Pattern

Adnan habitually walks on all four extremities and does not use crutches. His walking pattern is illustrated in Figure 4. Similar to İbrahim, Adnan also walks in a quadripedal fashion. That is, he habitually prefers palmigrade walking, exhibiting a diagonal gait-pattern.

He can get upright position from a sitting position, but he cannot step during standing. If he is asked to step during standing, he needs assistance from others. In this case, he can step only with great difficulty. Video clip 2 shows Adnan standing and walking.

Handedness

Adnan usually uses his right hand in everyday activities, such as reaching for and holding food. Video clip 3 shows Adnan reaching for a glass of tea

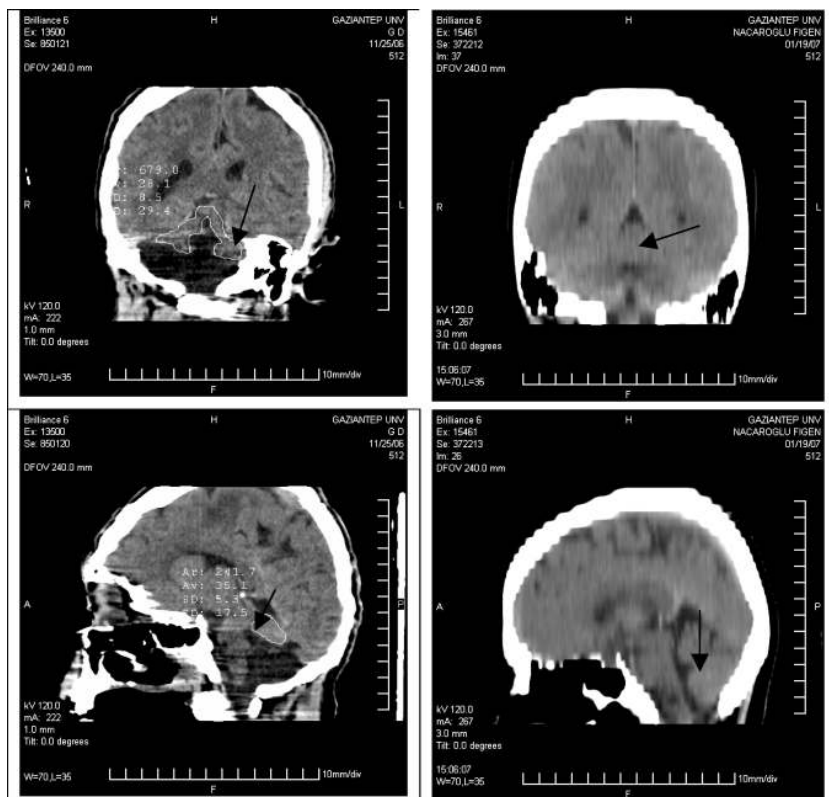


Figure 3. Ibrahim Sahan's CT scans. Above, left: cerebellum (arrow) in coronal section; below, left: cerebellar vermis (arrow). Above, right: cerebellum in a normal individual (arrow); below, right: vermis in a normal individual (arrow).

and drinking with his right hand. Apparently, his hand movements were not encumbered by imbalances and/or an intention tremor and his hands were fairly good in targeting objects with a fairly good dexterity.

Cognitive Ability

He seemed to understand simple sentences. However, he did not know any words to use. He only mutters using a few unintelligible sounds, although with great difficulty. Any cognitive test was not applicable because his mental faculties were not accessible. He was unaware of time, place, names of objects,




Figure 4. Adnan (above) and Halef (below) walking on all fours.

and names of relatives, including his mother and father. He could not count from one to two. He appeared to have no conscious experience.

MRI Scan

Figure 5 depicts the MRI scans from Adnan's father (above) and Adnan (bottom). In the father's MRI scans, the cerebellar vermis (above, left) and the cerebellum (above, middle, and right) were normal in appearance. In Adnan's MRI scans, however, the inferior portions of the cerebellar vermis (below, left) and cerebellum (below, middle and right) were absent.

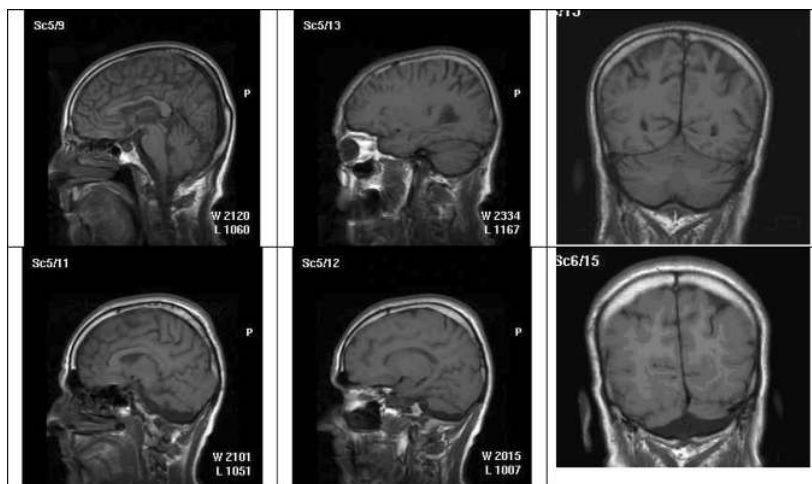


Figure 5. MRI scans from Adnan Yılmaz (below) and his father (above). Left: cerebellar vermis in midsagittal sections; middle: cerebellum in sagittal sections; right: cerebellum in coronal sections.

HALEF YILMAZ, V-18, MALE, 37 YEARS OF AGE

Walking Pattern

Halef habitually walks in a quadrupedal fashion with a diagonal pattern, not using crutches (Figure 4). He can stand up from a sitting position, and maintains the upright position with flexed hips and knees as long as he desires, but he cannot raise his foot to take a step during standing. In like manner to Adnan, he always uses shoes for his hands during walking. He can walk bipedally, although with great difficulty, and only with help from others, in contrast to the ease with which he can ambulate in a quadrupedal fashion. Video clip 4 shows Halef's walking style and Adnan standing up.

Cognition

Halef appears to understand simple questions and commands. However, he could not speak; he responded to questions only with a simple sound. Any IQ test was not applicable because of difficulties in communication. He was unaware of time, place, year, month, and day, and had no conscious experience.

Handedness

Halef usually uses his left hand in everyday activities, such as holding a glass of tea and eating. Video clip 5 shows Halef filling the glass with tea and drinking

from the Turkish tea-glass. Apparently there was no intention tremor or any other disabilities with respect to his hand skills.

MRI Scanning

Figure 6 depicts Halef's mid-sagittal (above) and coronal (below) MRI sections, which demonstrated the vermis and cerebellum, respectively. There was a tiny portion of the superior vermis remaining due to vermial hypoplasia, the inferior vermial portion being completely absent (Figure 6). There was a moderate simplification of the cerebral cortical gyri, the brain stem, and the pons were particularly small. The corpus callosum was normal. The superior portion of the cerebellum was normal, whereas the inferior cerebellar portion was absent (Figure 6).

HASAN YILMAZ, V-22, MALE, 17 YEARS OF AGE

Walking

Hasan essentially walks on all four extremities, while he also uses crutches while walking around the village. Interestingly, Hasan's circumducted leg crosses the midline during the swing phase, producing a scissoring gait (Figure 7). He could stand up and remain in the upright position as long as he desired. However, he could not step during the upright position. If he was forced to step, he immediately fell down. Video clip 6 shows Hasan using crutches to walk upright. Video clip 7 shows his scissoring gait during walking on all four extremities. He could stand up from a sitting position, while he could not step from the upright position. If he tried to step, he fell down immediately (Video clip 8).

Cognition

It was very difficult to communicate with him. He seemed to understand simple commands, although he could not use the language to express himself, using only a few unintelligible sounds. In addition to his primitive verbal ability, his spatial ability was also at a primitive level. He was unaware of time, place, year, and day, and had no conscious experience whatsoever.

Brain Scan

It was not possible to hold him quiet for a sufficient length of time. Therefore, this study utilized a CT scan instead of the MRI scan. The mid-sagittal (left)

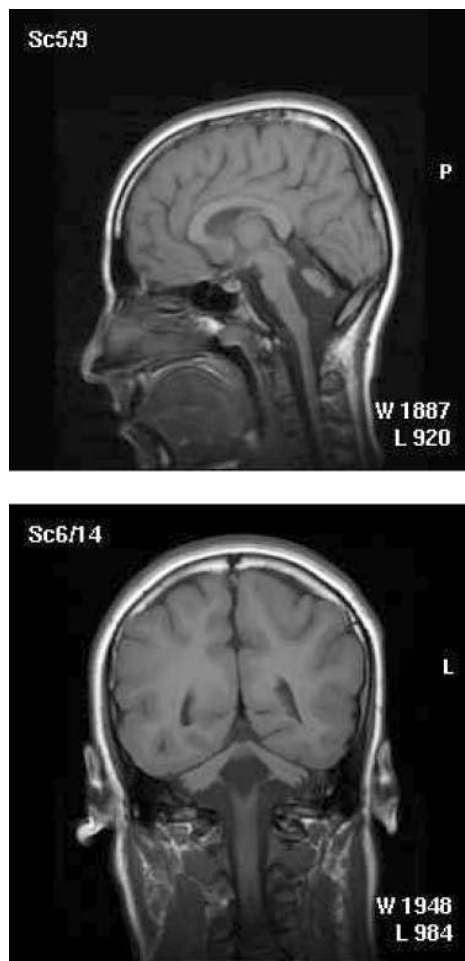


Figure 6. MRI scans from Halef Yılmaz. Above: cerebellar vermis in midsagittal section; below: cerebellum in coronal section.

and coronal (right) CT scans are illustrated in Figure 8. The vermis showed a high degree of hypoplasia, especially in the inferior portion, which seemed to be completely absent (Figure 8, left). There was also hypoplasia in the inferior portion of the cerebellum, its superior portion being quasi-normal (Figure 8, right).



Figure 7. Hasan Yılmaz, palmigrade crossed walking.

SEMA YILMAZ, V-24, FEMALE, 12 YEARS OF AGE

Walking

Sema was a palmigrade wrist-walker until she was 6 years old. At that time, her mother forbade her to walk in a quadrupedal fashion and forced her to walk

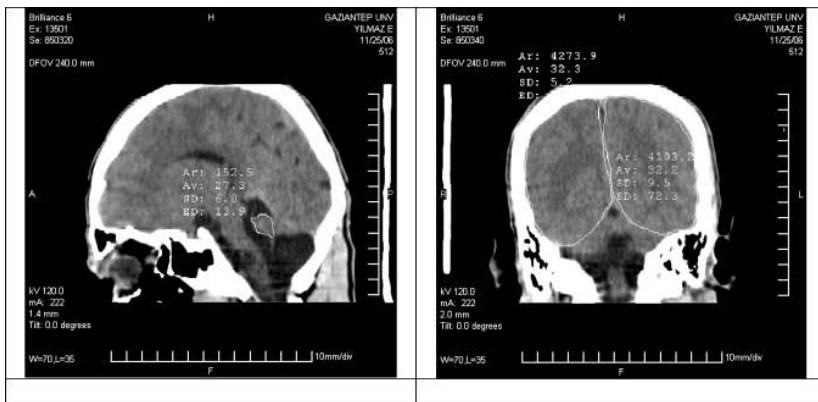


Figure 8. CT scans from Hasan Yılmaz. Left: vermis in midsagittal section; right cerebellum in coronal section.



Figure 9. Sema's unsteady bipedal walking despite exercise for six years.

bipedally in the upright position with stones fastened to her feet. This primitive physical therapy lasted for six years. Despite that, her ability to ambulate in a quadrupedal fashion was not extinguished, although she is still not permitted to walk on all four extremities. Sema's upright walking is currently unsteady (Figure 9), despite the long-lasting exercises. Her upright walking can be seen in Video clip 9.

Cognition

Sema could understand simple questions and commands; she could speak and answer all the questions with a limited vocabulary; her speech was dysarthric. She was a little better than the other quadrupeds in her language skills. She was mentally retarded as the other wrist-walkers (*vide supra*). She was also unaware of time, place, year, and season, and had no conscious experience.

Brain Scan

It was not possible to keep Sema Yılmaz sufficiently quiet to perform an MRI scan. Therefore, a CT scan was obtained. Figure 10 illustrates her coronal (left) and mid-sagittal (right) CT scans. The inferior portion of the cerebellum

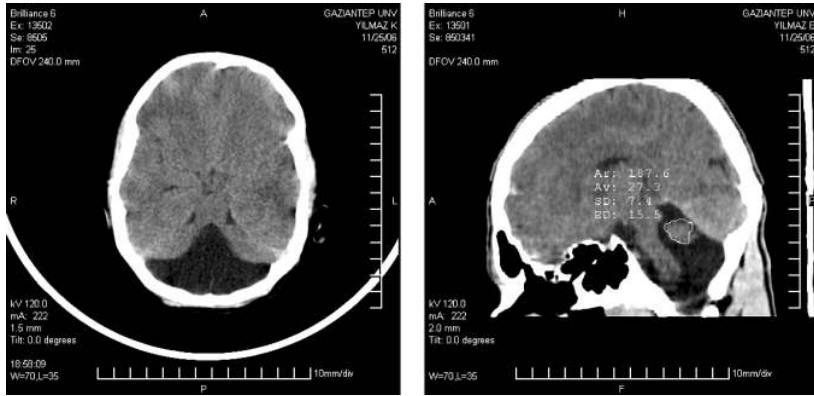


Figure 10. CT scans from Sema Yılmaz. Left: cerebellum in coronal section; right: Cerebellar vermis in midsagittal section.

was absent, whereas the superior portion was quasi-normal (Figure 10, left). Similarly, the inferior portion of the cerebellar vermis was absent, whereas the superior portion of the cerebellar vermis appeared normal (Figure 10, right).

ESER SAHAN, V-1, FEMALE, 17 YEARS OF AGE

Walking

Eser usually walks on all four extremities, which is forbidden by her family, at least in the presence of non-family members. She can walk bipedally in the upright position, although unsteadily and with great difficulty (Figure 11 and Video clip 10 was obtained). Actually, she has never been forced to walk bipedally in an upright position. She spontaneously stood up and tried walking bipedally at 4 years of age.

Cognition

Although she was not aware of time, place, season, and year, she could understand nearly 100 words and followed the physician's instructions during neurologic examinations and answered the questions with a few words, despite her dysarthria.

MRI Scan

Eser's MRI scan (mid-sagittal section) is depicted in Figure 12. The mid-sagittal MRI section from her normal sister is depicted as a control. As seen, the



Figure 11. Eser's unbalanced-upright walking using the arms for balance with flexed knees.

inferior vermis was absent, whereas the superior vermis was still visible; the gyri of the cerebral hemisphere were mildly simplified. The corpus callosum appeared to be normal, whereas the brain stem appeared to be small. Similar to the vermis, the inferior cerebellum was also absent, whereas the superior portion of the cerebellum was still visible in the coronal MRI section (not shown).

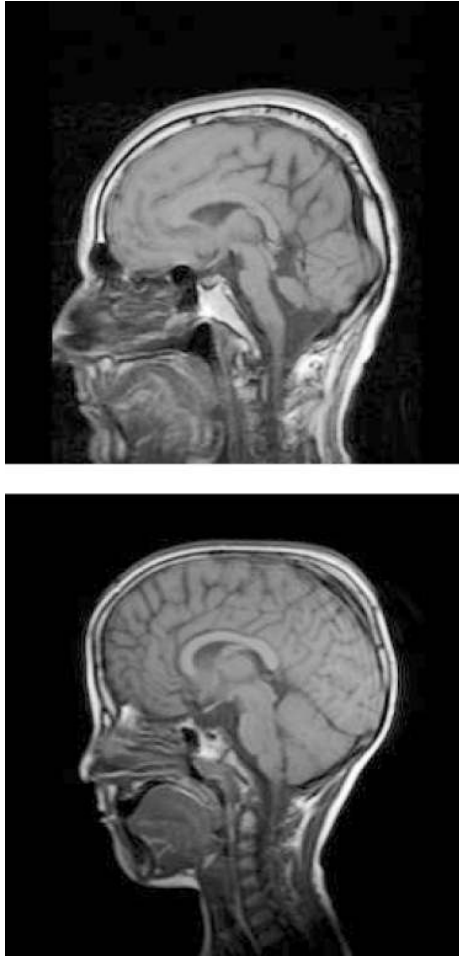


Figure 12. Midsagittal MRI scans from Eser Sahan (above) and her sister (below). Notice the hypoplastic vermis and smoothed cerebral cortex in Eser Sahan compared to the normal brain in the control subject.

DISCUSSION

In addition to the two families previously described (Tan, 2005a, b, 2006a, b, c), four additional families with the UTS are described in the present work. Interestingly, all of these families were consanguineous, suggesting that the UTS may be an autosomal recessive disease. A variant of this syndrome has also been recently published (Tan, 2007), which involved a single case without

intra-familial marriages, and only expressed the main feature of the UTS, that is, walking on all four extremities.

UTS and DES

Although the UTS is proven to be a unique syndrome not described before in the scientific literature, there is a syndrome that should be discussed with regard to the UTS. This is the disequilibrium (DES), which was first introduced into the scientific literature by Hagberg et al. (1972). Later, Sanner (1973) re-studied this syndrome and provided evidence for an autosomal recessive pattern of inheritance since many patients in one region of Sweden originated from parental consanguinity. The DES is also found among the Hutterites of Montana (Schurig et al., 1981; Palister & Opitz, 1986). Similar cases were later reported by Glass, Boycott, Adams et al. (2005) in 12 Hutterites, similar to the former clan, except that the latter study included MRI scans.

There are significant differences between the DES and the UTS. Those affected with the UTS habitually walk in a quadrupedal fashion without any sign of dysequilibrium, whereas those with the DES habitually walk bipedally with a broad-based ataxic gait due to cerebellar hypoplasia. This is the most important difference between the UTS and the DES. Although both syndromes result from autosomal recessive inheritance due to intra-familial marriages, the genetic defect differs. That is, the gene responsible for the DES is localized to chromosome region 9p24 (Boycott et al., 2007), while the gene responsible for the UTS is localized to chromosome 17p, at least in the affected individuals of the first family described (Turkmen et al., 2006), which has been confirmed by the authors' collaborative work with Tayfun Ozcelik at Bilkent University in Ankara, Turkey (unpublished studies). However, the authors were unable to confirm this result in the affected individuals of the second and third families, suggesting that the UTS may be a multigenic disorder. Speech is at the very primitive level in the affected members of the first family. They cannot name objects in everyday use, generally understanding only themselves; their neighbors cannot understand them. The affected individuals of the second and third families do not use a language. To communicate, they use only one or two sounds, whereas those affected with the DES use their mother language, which is, however, dysarthric and unintelligible. There is mild-to-moderate mental retardation in the DES, but there is severe mental retardation with no conscious experience at all in patients with the UTS. Furthermore, there was no short stature in subjects with the UTS, whereas most of the subjects with the DES exhibit short stature. There was no intention tremor in most of those affected

with the UTS, whereas there was intention tremors in most affected with the DES. The common features between the UTS and the DES include: autosomal recessive inheritance, exaggerated deep tendon reflexes (primarily in the lower extremities), and rarely, epilepsy.

Thus, the UTS and the DES are different pathologic conditions, exhibiting different clinical signs and symptoms. The MRI scans seems to be similar in the DES and in some affected individuals of the first and third families with the UTS, that is, the inferior cerebellum and the inferior vermis being absent with a mild gyral simplification in both the DES and the UTS. However, these structures were nearly normal in the affected individuals of the second family (Tan, 2006b). Moreover, the cerebro-cerebellar structures were completely normal in the MRI scans of an individual exhibiting only the main symptom of the UTS, that is, habitual walking on all four extremities without any mental disturbances (Tan, 2007). The integrity of the vestibular system has not been studied thus far in those affected with the DES. In contrast, the vestibular system was tested using Barany's caloric nystagmus test in the affected individuals of the first family (Tan et al., 2007), which indicated a defect in the central vestibular system, comprising the neural nuclei in the brain stem responsible for postural reflexes, gravity-dependent reflexes, and spatial orientation. There was a defect in the peripheral vestibular system in the affected individuals of the second family (Tan et al., 2007), that is, damage to the nerve of the inner ear, which controls balance. Interestingly, the peripheral and central vestibular systems were normal in the affected individuals of the third family presented in the present work. These results exclude the possibility that a defective vestibular system would be responsible for the UTS. In sum, the aforementioned differences between the UTS and the DES suggest that these two disorders may be entirely different with respect to clinical and central neural mechanisms.

Lateral Balance with Upright Posture

From the physiologic point of view, human bipedal walking is associated with a complex balance-control mechanism that is not thoroughly studied yet. As Hof et al. (2007) argued on page 250, "in walking the human body is never in balance." To initialize a step, for instance with the left foot, the trunk must be supported by the right foot and leg against gravitational forces. This is the first stage in walking, which is performed by the extensor motor system controlling the extensor muscles of the right leg. Then, the opposite foot, the left foot, has to be lifted, to make a step. This is a flexor motor system activity, bending the knee and hip, as the trunk is supported by the right leg's extensor motor system.

As can be seen in video clips, the individuals with the UTS can stand up, except the affected members of the second family, and remain in an upright position, but they cannot asymmetrically support the trunk, using the extensor motor system, to make the necessary flexor actions on the contralateral side. That is, they cannot hold the trunk upright using only one leg. An erect (extensor) posture of one leg against the gravitational forces is required to be able to initialize a flexor response from the opposite leg. Careful examination of the video clips demonstrates this difficulty.

If those affected with the UTS are supported by someone else, they can make a step and walk, as seen in the video clips. The inability to support the trunk unilaterally, before making a step with the opposite leg, suggests a high-degree disturbance in the lateral-balance mechanisms during upright position of individuals exhibiting the UTS. This is entirely different from the cerebellar ataxic gait in DES, because those affected with the DES can in fact walk in an upright position, but with some coordination problems originating from the cerebellar and vermial hypoplasia, which has nothing to do with walking in the UTS.

The importance of the stepping strategy for lateral balance is recently accentuated by Hof et al. (2007). Consistent with the unimportant role of the vestibular system in the UTS (*vide supra*), Dieterich et al. (2003) reported that motion is controlled through an asymmetrical motor cortical system (see also Tan, 1985a, b, 1990), rather than the vestibular system alone. Accordingly, it may be concluded that there is a disturbance in the cortical lateral-balance control mechanisms in UTS independent from the vestibular system.

Walking on All Four Extremities

Human quadrupedal gait, as a transient stage during the locomotor development of children, was first reported by Hrdlicka (1928). However, individuals with the UTS do not ever progress beyond this stage of locomotor development. The habitual quadrupedality, that is, always walking on all four extremities, is not unique to the few individuals discovered in southern Turkey. It has also been observed in several regions of the world, such as Chile, Argentina, and India, hitherto reported to one of the authors (UT). Thus, the quadrupedal walking pattern may be a normal walking style for some otherwise normal individuals, as a variant of the UTS. An individual with normal mental capacity and a quadrupedal gait and no intra-familial marriage between parents has recently been reported by Tan (2007).

As mentioned earlier, there is a disturbance in the lateral-balance mechanisms during upright posture in these individuals, because they cannot

support the trunk during the stance phase of walking. Further, this condition may not be related to the functional integrity of the vestibular system. It may rather be a dysfunction of the cortical balance mechanisms, including the asymmetrical multi-sensory motor cortical system (Dieterich et al., 2003). Accordingly, Guillou et al. (2007) have recently suggested on page 317 that “this asymmetrical control would induce a functional postural dominance during a dynamic unipedal equilibrium task.” This asymmetrical cortico-motor control of lateral balance during upright stepping may not be fully developed in those affected by the UTS, who actually can make stepping movements during quadrupedal walking, suggesting that there is nothing defective with stepping, the main failure being located within the cortical motor control of the lateral balance. Apparently, the asymmetrical cortical motor system controlling the lateral balance cannot complete its development in some children, resulting in a failure in transition from quadrupedality to bipedality. This may be genetic and/or environmental in origin (see Tan, 2007). The simplification of the cortical gyri observed in the MRI scans of individuals with the UTS supports the cerebral, not cerebellar, origin of quadrupedality.

Tiptoe Walking

Interestingly, one of the subjects described herein (İbrahim Sahan) exhibited tiptoe gait during walking on all four extremities. Tiptoe walking is essentially a common finding in otherwise normal children, between 10 and 18 months of age, when children are learning to walk. Only a small percentage of children persist in walking on their toes (Tidwell, 1999). Idiopathic toe-walking was first described by Hall and colleagues (1967), as a congenital short tendo calcaneus in children. Adults with habitual tiptoe gait can walk with a normal well-coordinated, efficient gait pattern without any sign of imbalance (Caselli et al., 1988). İbrahim Sahan was also a habitual toe-walker with no signs of imbalance during walking on all four extremities at the same time. The habitual tiptoe walking may be associated with upper motor neuron pathology, as in cerebral palsy (Riley & Kerrigan, 2001), due to an overactive ankle plantar flexor (physiological extensor) activity leading to a shortened Achilles tendon. İbrahim’s tiptoe walking may be associated with lesions within the corticospinal pathways, because the Babinski sign was positive bilaterally.

Scissoring Gait

İbrahim Sahan also exhibited scissor gait in addition to his tiptoe walking during walking on all four extremities. Thus, he exerted all of three walking

patterns at the same time, that is, quadrupedal, tiptoe, and scissor walking. The last two gaits usually occur in cerebral palsy. Accordingly, the Babinski signs were positive bilaterally. Hasan Yılmaz also used scissoring gait during walking on all four extremities. Clonus was positive bilaterally. The overall results strongly suggest cerebral involvement in the UTS.

UTS in Relation to Evolution

UTS may tentatively be regarded as an experiment of nature to elucidate the neural mechanisms of transition from quadrupedality to bipedality during human evolution. In this regard, fossils are not suitable to illuminate function. The genetic character of the UTS suggests that there may be a genetic factor playing a role in the development of the cortical circuits responsible for the control of the lateral balance during upright standing posture to walk bipedally.

Including the family presented in the present report, there are now 13 examples for human reverse evolution, or devolution, at least with respect to walking on all four extremities. The reverse evolution in humans is consistent with reverse evolution in animals, frequently reported during the last several years (Porter & Crandall, 2003; Teotonio & Rose, 2000, 2001, 2002; Tvrdik & Capecchi, 2006). Accordingly, Tvrdik and Capecchi (2006) have recently succeeded in creating a reverse evolution in mice, reconstructing a gene that may have existed more than 500 million years ago. Similarly, studying humans with the UTS, exhibiting the most important ancestral trait, such as the habitual quadrupedal gait, one can understand the neural mechanisms for the transition from the habitual quadrupedality to the habitual bipedality, which most probably occurred by a punctuated evolution (see Elena et al., 1996) resulting from a genetic mutation, provided that one can determine the location of the gene or gene pool responsible for the quadrupedal gait in the UTS. This would be a groundbreaking development in human history. Therefore, there is no reason to be insulted or suggest injury by the UTS.

REFERENCES

- Bense, S., Deuschlaender, A., Stephan, Th., Bartenstein, P., Schwaiger, M., Brandt, Th., & Dieterich, M. (2004). Preserved visual-vestibular interaction in patients with Bilateral Vestibular failure. *Neurology*, *63*, 122–128.
- Boycott, K. M., Flavelle, S., Bureau, A., Glass, H. C., Fujiwara, T. I., Wirrell, E., Davey, K., Chudley, A. E., Scott, J. N., McLeod, D. R., & Parboosingh, J. S. (2007). Homozygous deletion of the very low density lipoprotein receptor gene causes

- autosomal recessive cerebellar hypoplasia with cerebellar gyral simplification. *The American Journal of Human Genetics*, 77, 477–483.
- Caselli, M. A., Rzonca, E. C., & Lue, B. Y. (1988). Habitual toe-walking: Evaluation and approach to treatment. *Clinics in Pediatric Medicine and Surgery*, 5, 547–549.
- Dieterich, M., Bense, S., Lutz, S., Drzezga, A., Stephan, T., Bartenstein, P., & Brandt, T. (2003). Dominance for vestibular cortical function in the non-dominant hemisphere. *Cerebral Cortex*, 13, 994–1007.
- Elena, S. F., Cooper, V. S., & Lenski, R. E. (1996). Punctuated evolution caused by selection of rare beneficial mutations. *Science*, 272, 1802–1804.
- Glass, H. C., Boycott, K. M., Adams, C., Barlow, K., Scott, J. N., Chudley, A. E., Mary, T., Morgan, K., Wirrell, E., & McLeod, D. R. (2005). Autosomal recessive cerebellar Hypoplasia in the Hutterite population. *Developmental Medicine & Child Neurology*, 47, 691–695.
- Guillou, E., Dupui, P., & Golomer, E. (2007). Dynamic balance sensory motor control and symmetrical or asymmetrical equilibrium training. *Clinical Neurophysiology*, 118, 317–324.
- Hagberg, B., Sanner, G., & Steen, M. (1972). The dysequilibrium syndrome in cerebral palsy, Clinical aspects and treatment. *Acta Paediatrica Scandinavica*, 61(suppl. 226), 1–63.
- Hall, J. E., Salter, R. B., & Bhalla, S. K. (1967). Congenital short tendo calcaneus. *Journal of Bone and Joint Surgery*, 49B, 695–697.
- Hof, At., van Bockel, R. M., Schoppen, T., & Postema, K. (2007). Control of lateral balance in walking, experimental findings in normal subjects and above-knee amputees. *Gait & Posture*, 25, 250–258.
- Hrdlicka, A. (1928). Children running on all fours. *American Journal of Physical Anthropology*, 11, 149–185.
- Pallister, P., & Opitz, J. (1986). Brief clinical report: Disequilibrium syndrome in Montana Hutterites. *American Journal of Medical Genetics*, 22, 567–569.
- Porter, M. L., & Crandall, K. A. (2003). Lost along the way: The significance of evolution in reverse. *Trends in Ecology and Evolution*, 18, 541–547.
- Riley, P. O., & Kerrigan, D. C. (2001). The effect of voluntary toe-walking on body propulsion. *Clinical Biomechanics*, 16, 681–687.
- Sanner, G. (1973). The disequilibrium syndrome: A genetic study. *Neuropediatric*, 4, 403–413.
- Schurig, V., Oram, A. V., & Bowen, P. (1981). Nonprogressive cerebellar disorder with mental retardation and autosomal recessive inheritance in Hutterites. *American Journal of Medical Genetics*, 9, 43–53.
- Tan, Ü. (1985a). Relationship between hand skill and the excitability of motoneurons innervating the postural soleus muscle in human subjects. *International Journal of Neuroscience*, 26, 289–300.

- Tan, Ü. (1985b). Left-right differences in the Hoffmann reflex recovery curve associated with handedness in normal subjects. *International Journal of Psychophysiology*, 3, 75–78.
- Tan, Ü. (1990). There is a close relationships between hand skill and the excitability of motor neurons innervating the postural soleus muscle in left-handed subjects. *International Journal of Neuroscience*, 51, 25–34.
- Tan, Ü. (2005a). Ünertan Senromu ve insane ruhunun evri,mine ilişkin yeni bir teori. *Biyobank*, 3. sayı, 15 November 2005.
- Tan, Ü. (2005b). Ünertan Syndrome; quadrupedality, primitive language, and severe mental retardation; a new theory on the evolution of human mind. *NeuroQuantology*, 4, 250–255.
- Tan, Ü. (2006a). A new syndrome with quadrupedal gait, primitive speech, and severe mental retardation as a live model for human evolution. *International Journal of Neuroscience*, 116, 361–369.
- Tan, Ü. (2006b). Evidence for “Unertan Syndrome” and the evolution of the human mind. *International Journal of Neuroscience*, 116, 763–774.
- Tan, Ü. (2006c). Evidence for “Uner Tan Syndrome” as a human model for reverse evolution. *International Journal of Neuroscience*, 116, 1433–1441.
- Tan, Ü. (2007). A wrist-walker exhibiting no “Üner Tan Syndrome”: A theory for possible mechanisms of human devolution toward the atavistic walking patterns. *International Journal of Neuroscience*, 117, 147–156.
- Tan, Ü., Pençe, S., Yılmaz, M., Özkur, A., Karaca, S., Tan, M., & Karataş, M. (2007). “Üner Tan Syndrome” in two Turkish families in relation to devolution and emergence of homo erectus: Neurological examination, MRI and PET scans. *International Journal of Neuroscience*, in press
- Teotonio, H., & Rose, M. R. (2000). Variation in the reversibility of evolution. *Nature*, 276(408), 463–466.
- Teotonio, H., & Rose, M. R. (2001). Perspective: Reverse evolution. *Evolution*, 55(278), 653–660.
- Teotonio, H., & Rose, M. R. (2002). Reverse evolution of fitness in *Drosophila melanogaster*. *Journal of Evolutionary Biology*, 15, 608–617.
- Tidwell, M. (1999). The child with tip-toe gait. *International Pediatrics*, 14, 235–238.
- Turkmen, S., Demirhan, O., Hoffmann, K., Diers, A., Zimmer, C., Sperling, K., & Mundlos, S. (2006). Cerebellar hypoplasia and quadrupedal locomotion in humans as a recessive trait mapping to chromosome 17p. *Journal of Medical Genetics*, 43, 461–464.
- Tvrđik, P., & Capecchi, M. R. (2006). Reversal of Hox1 gene subfunctionalization in the mouse. *Developmental Cell*, 11, 239–250.