

REVIEW ARTICLE

Pathophysiology of REM sleep behaviour disorder and relevance to neurodegenerative disease

B. F. Boeve,^{1,4,6} M. H. Silber,^{1,4,6} C. B. Saper,⁹ T. J. Ferman,^{2,7} D. W. Dickson,^{5,7} J. E. Parisi,^{1,3,6} E. E. Benarroch,^{1,6} J. E. Ahlskog,^{1,6} G. E. Smith,^{2,6} R. C. Caselli,^{1,8} M. Tippman-Peikert,^{1,4,6} E. J. Olson,^{4,6} S.-C. Lin,^{4,7} T. Young,^{1,4,6} Z. Wszolek,^{1,7} C. H. Schenck,¹⁰ M. W. Mahowald,¹⁰ P. R. Castillo,¹⁰ K. Del Tredici¹¹ and H. Braak¹¹

¹Department of Neurology, ²Department of Psychology and Psychiatry, ³Laboratory Medicine and Pathology, ⁴Sleep Disorders Center and ⁵Neuropathology Laboratory, ⁶Mayo Clinic College of Medicine, Rochester, MN, ⁷Mayo Clinic College of Medicine, Jacksonville, FL, ⁸Mayo Clinic College of Medicine, Scottsdale, AZ, ⁹Department of Neurology, Beth Israel Deaconess Medical Center, Harvard Medical School, Boston, MA, ¹⁰Minnesota Regional Sleep Disorders Center, University of Minnesota, Minneapolis, MN, USA and ¹¹Institute for Clinical Neuroanatomy, J.W. Goethe University, Frankfurt/Main, Germany

Correspondence to: Bradley F. Boeve, MD, Mayo Clinic, 200 First Street SW, Rochester, MN 55905, USA
E-mail: bboeve@mayo.edu

REM sleep behaviour disorder (RBD) is a parasomnia characterized by the loss of normal skeletal muscle atonia during REM sleep with prominent motor activity accompanying dreaming. The terminology relating to RBD, and mechanisms underlying REM sleep without atonia and RBD based on data in cat and rat are presented. Neuroimaging data from the few published human cases with RBD associated with structural lesions in the brainstem are presented, in which the dorsal midbrain and pons are implicated. Pharmacological manipulations which alter RBD frequency and severity are reviewed, and the data from human neuropathological studies are presented. An anatomic framework and new schema for the pathophysiology of RBD are proposed based on recent data in rat regarding the putative flip-flop switch for REM sleep control. The structure in man analogous to the subcoeruleus region in cat and sublateralodorsal nucleus in rat is proposed as the nucleus (and its associated efferent and afferent pathways) crucial to RBD pathophysiology. The association of RBD with neurological disease ('secondary RBD') is presented, with emphasis on RBD associated with neurodegenerative disease, particularly the synucleinopathies. The hypothesized pathophysiology of RBD is presented in relation to the Braak staging system for Parkinson's disease, in which the topography and temporal sequence of synuclein pathology in the brain could explain the evolution of parkinsonism and/or dementia well after the onset of RBD. These data suggest that many patients with 'idiopathic' RBD are actually exhibiting an early clinical manifestation of an evolving neurodegenerative disorder. Such patients may be appropriate for future drug therapies that affect synuclein pathophysiology, in which the development of parkinsonism and/or dementia could be delayed or prevented. We suggest that additional clinicopathological studies be performed in patients with dementia or parkinsonism, with and without RBD, as well as in patients with idiopathic RBD, to further elucidate the pathophysiology and also characterize the clinical and pathophysiological relevance of RBD in neurodegenerative disease. Furthermore, longitudinal studies in patients with idiopathic RBD are warranted to characterize the natural history of such patients and prepare for future therapeutic trials.

Keywords: REM sleep behaviour disorder; parasomnia; dementia with Lewy bodies; Parkinson's disease; multiple system atrophy; synuclein; synucleinopathy

Abbreviations: AD = Alzheimer's disease; DLB = dementia with Lewy bodies; EEG = electroencephalographic; EMG = electromyographic; LC = locus coeruleus; LDTN = laterodorsal tegmental nucleus; LPT = lateral pontine tegmentum; MAPT = gene encoding *microtubule associated protein tau*; MCI = mild cognitive impairment; MCRF = magnocellular reticular formation; MSA = multiple system atrophy; PAF = pure autonomic failure; PD = Parkinson's disease; PGRN = gene encoding *progranulin*; PPN = pedunculopontine nucleus; PPND = pallido-ponto-nigral degeneration; PSG = polysomnography;

PSP = progressive supranuclear palsy; RBD = rapid eye movement sleep behaviour disorder; REM = rapid eye movement; RN = raphe nucleus; RSWA = REM sleep without atonia; SCA-3 = Spinocerebellar atrophy—type 3; SLD = sublateralodorsal nucleus; vlPAG = ventrolateral periaqueductal grey matter; VLST = ventrolateral reticulospinal tract

Received September 19, 2006. Revised February 22, 2007. Accepted February 26, 2007. Advance Access publication April 5, 2007

Introduction

REM sleep behaviour disorder (RBD) is characterized by loss of normal skeletal muscle atonia during REM sleep with prominent motor activity and dreaming (Olson *et al.*, 2000; Schenck and Mahowald, 2002). Herein, we discuss the terminology relating to RBD, and review the known and presumed neural networks involved in REM sleep and RBD pathophysiology based on animal models. We then turn to human RBD and review the pathophysiology of the parasomnia, focusing on pharmacological studies, lesion studies, and neuropathological studies. We propose an anatomic framework for studying the pathophysiology of human RBD. We conclude by discussing the association of RBD and neurodegenerative disease, and elaborate on the overlap of brainstem nuclei degeneration in RBD and Parkinson's disease. Our goals are to heighten awareness of the RBD-neurodegenerative disease association, stimulate further interest in understanding normal REM sleep, and better clarify the clinical and pathophysiological significance of RBD associated with neurodegenerative disease.

Terminology relating to REM sleep behaviour disorder

Some of the terms relating to RBD are confusing, and this terminology warrants clarification. In the absence of any associated neurological disorder, it is termed 'idiopathic' RBD. 'Secondary' or 'symptomatic' RBD refers to the combination of RBD plus another neurological disorder, such as narcolepsy or a neurodegenerative disease.

There are important similarities and differences between REM sleep without atonia, dream enactment behaviour and RBD. REM sleep without atonia (RSWA) refers to the electrophysiologic finding of loss of EMG atonia during REM sleep, which can be measured in animals and humans. Dream enactment behaviour refers to behaviour exhibited during sleep that is interpreted by an observer as 'acting out dreams'. Dream enactment behaviour is certainly a core feature of RBD, but similar behaviour can also occur in untreated obstructive sleep apnea (Iranzo and Santamaria, 2005), as well as in sleepwalking and sleep terrors in adults, post-traumatic stress disorder, or as an effect of alcohol or drug administration or withdrawal (Schenck *et al.*, 1989; Schenck and Mahowald, 2002). Hence, a history of recurrent dream enactment behaviour could be viewed as representing 'clinically probable RBD', and PSG confirmation of RSWA +/- complex motor behaviour during REM sleep in a patient with a history of recurrent dream enactment behaviour could be termed 'definite RBD' or 'PSG-confirmed RBD'.

The recently published 2nd edition of the International Classification of Sleep Disorders requires the following for the clinical diagnosis of RBD (ICSD, 2005):

- (i) Presence of RSWA on PSG.
- (ii) At least one of the following:
 - (1) sleep-related, injurious, potentially injurious or disruptive behaviours by history (i.e. dream enactment behaviour) and/or
 - (2) abnormal REM sleep behaviour documented during polysomnographic monitoring.
- (iii) Absence of EEG epileptiform activity during REM sleep unless RBD can be clearly distinguished from any concurrent REM sleep-related seizure disorder.
- (iv) The sleep disorder is not better explained by another sleep disorder, medical or neurological disorder, mental disorder, medication use or substance use disorder.

RSWA is, therefore, an electrophysiologic finding, and is one of the features sought on PSG when evaluating a patient for suspected RBD. Some have applied the term 'subclinical' or 'preclinical' RBD to patients with RSWA but without associated dream enactment behaviour (Pareja *et al.*, 1996; Kimura *et al.*, 1997). However, RSWA is not synonymous with RBD. While RSWA may represent 'subclinical' or 'preclinical' RBD in some individuals, there are insufficient longitudinal data in patients with RSWA to prove progression to the clinical syndrome. Thus we will reserve the term RBD for those with both abnormal REM sleep electrophysiology and abnormal REM sleep behaviour. The typical clinical features of RBD are shown in Table 1.

Current concepts on REM sleep, RSWA and RBD based on animal studies

The states of being in the existence of most animals occur in three states: wakefulness, non-REM (NREM) sleep and REM sleep. Essentially all animal species have some or all elements of REM sleep, which very likely represents some constitutive survival-based need since animals deprived of REM sleep die (Kushida *et al.*, 1989); however, the precise benefit of sleep and particularly REM sleep is unknown. The loss of skeletal muscle tone, which is one of the hallmarks of REM sleep, can be measured electrophysiologically via surface electromyographic (EMG) leads over skeletal muscles.

Much of our knowledge of the neural substrates of REM sleep is based on animal studies over the past 40 years,

Table 1 Typical clinical features of REM sleep behaviour disorder

Male gender predilection
Mean onset age 50–65 years (range childhood–80 years)
Vocalizations, swearing, screaming
Motor activity varies from simple limb jerks to complex motor behaviour, with injuries to patient or bedpartner
Dreams often involve chases or attacks by animals or humans
Exhibited behaviours mirror dream content
Behaviors tend to occur in latter half of the sleep period
When associated with neurodegenerative disease, RBD often precedes dementia and/or parkinsonism by years or decades

Reprinted with permission from Boeve et al. (2003b).

primarily involving the cat and rat. Paradoxical sleep in animals is the state analogous to REM sleep in humans.

Studies in cat

Studies in cat suggested that there are two motor systems involved in normal REM sleep: one for generating muscle atonia and one for suppressing locomotor activity. Figure 1 incorporates data and concepts derived from multiple groups of investigators (Jouvet and Delorme, 1965; Hendricks *et al.*, 1982; Lai and Siegel, 1988, 1990; Shouse and Siegel, 1992; Lai and Siegel, 1997*a, b*; Morrison, 1998; Rye, 1998).

In this schema, the absence of motor activity in normal REM sleep occurs via active inhibition of spinal motoneurons (shown in the network on the right in Fig. 1) plus reduced drive within locomotor generators (shown on the left in Fig. 1). While phasic oculomotor and locomotor activity such as REM and brief and low amplitude muscle twitches occur as

normal phenomena in REM sleep, more elaborate motoric activity is directly or indirectly suppressed (Mahowald and Schenck, 2000).

The final common pathway of spinal motor neuron inhibition was inferred to be via the medullary magnocellular reticular formation (MCRF); this inhibitory nucleus is known to suppress anterior horn cell activity via projections of the ventrolateral reticulospinal tract (VLST). Several pontine nuclei are known to influence the REM and non-REM sleep circuits, including the noradrenergic locus coeruleus (LC) and the cholinergic nuclei, pedunculopontine nucleus (PPN) and laterodorsal tegmental nucleus (LDTN). In addition, forebrain structures have been tied into these circuits: substantia nigra, hypothalamus, thalamus, basal forebrain and frontal cortex. However, the precise interactions of these nuclei, and their roles in normal REM sleep have been unclear.

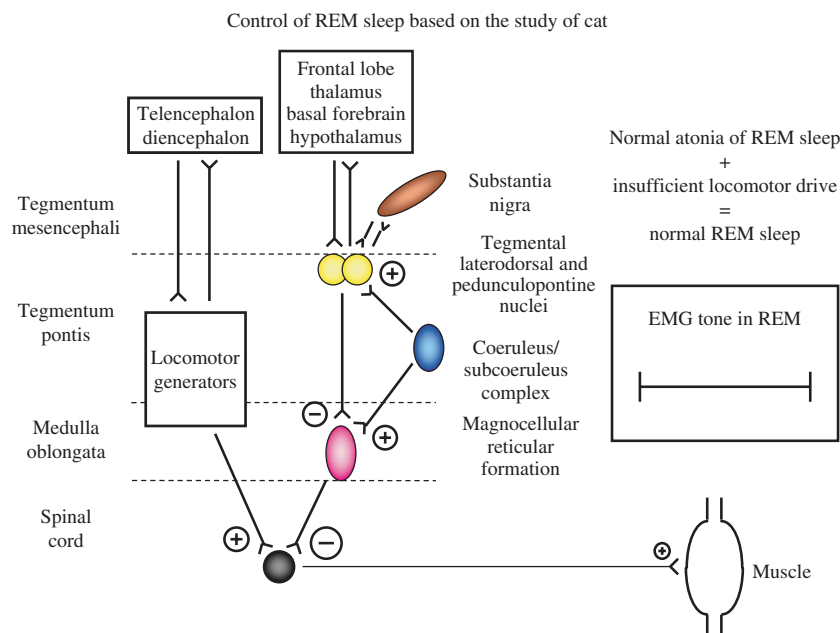


Fig. 1 Control of REM sleep based on studies in cat. See text for details. Excitatory projections represented by encircled plus sign, inhibitory projections represented by encircled minus sign, with the size of these symbols representing the relative effect of each projection on the synapsing nuclei. Normally populated nuclei are represented by coloured circles or ovals. EMG = electromyographic, REM = rapid eye movement. Adapted from Boeve et al. (2003b). Reprinted with permission from Human Press, Inc.

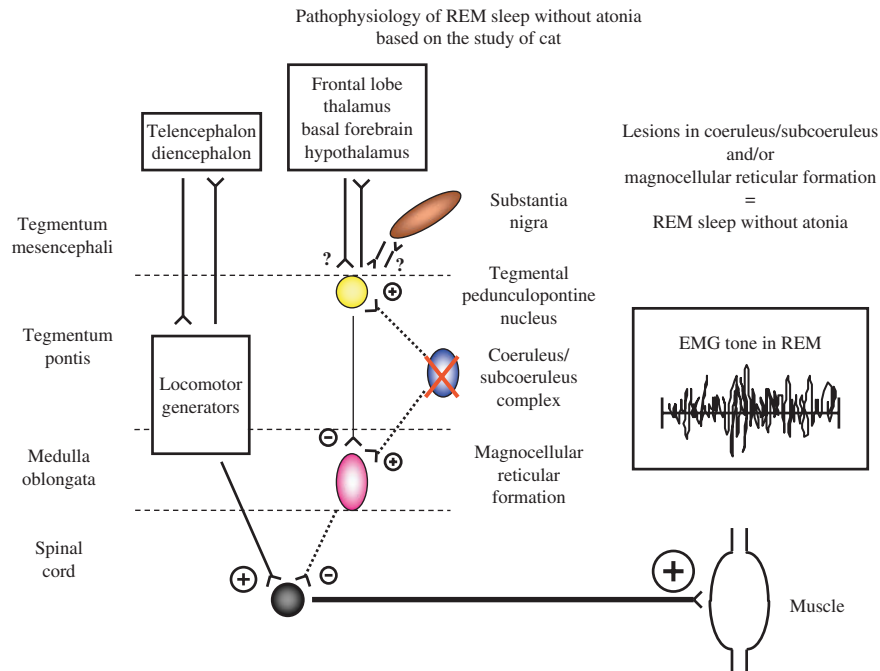


Fig. 2 Pathophysiology of REM sleep without atonia based on studies in cat. See text for details. Excitatory projections represented by encircled plus sign, inhibitory projections represented by encircled minus sign, with the size of these symbols representing the relative effect of each projection on the synapsing nuclei. Nuclei are represented by circles or ovals, with solid coloured circles and ovals reflecting those with normal populations of neurons, and speckled circles and ovals reflecting those with significantly reduced populations of neurons. A cross sign reflects ablation of a nucleus. The relative tonic influences of each projection are represented by line thickness, with thicker lines depicting stronger influences, thinner lines depicting weaker influences and dashed lines depicting weak influences due to damage to neurons in the respective nuclei. Questionable or unproven effects of lesions represented by '?'. EMG = electromyographic, REM = rapid eye movement. Adapted from Boeve *et al.* (2003b). Reprinted with permission from Human Press, Inc.

The brainstem regions that have classically been considered in RBD pathophysiology based on lesion studies in cat include the MCRF, locus coeruleus/subcoeruleus complex, PPN, LDTN and possibly substantia nigra (SN) (Fig. 2) (Jouvet and Delorme, 1965; Hendricks *et al.*, 1982; Lai and Siegel, 1988, 1990; Shouse and Siegel, 1992; Lai and Siegel, 1997a, b; Morrison, 1998; Rye, 1998). Although these studies have identified components of REM sleep circuits, the primary sites and interactions have been debated. Lesions in the MCRF release the tonic inhibition on spinal motoneurons, leading to RSWA, but these lesions also destroyed fibres of passage. Lesions in the coeruleus/subcoeruleus complex cause RSWA, and the site and size of the lesion determines whether simple or complex behaviours are exhibited (Hendricks *et al.*, 1982). There is also debate whether lesions in the PPN cause REM sleep without atonia (Rye, 1997, 1998; Morrison, 1998). The substantia nigra has been proposed as a component of this REM sleep system, but there is a paucity of direct evidence to implicate this nucleus. Similarly, no convincing examples of RSWA nor RBD that have resulted from diencephalic or telencephalic lesions have been reported to date. Most evidence now suggests populations of neurons that are considered 'REM-on' cells in the subcoeruleus region are central to REM sleep and the associated EMG atonia (Siegel, 2006).

Studies in rat

The principle nuclei mediating REM sleep and the interactions with other brainstem and forebrain nuclei has recently been clarified via elegant work in rat (Fig. 3). The sublateralodorsal (SLD) nucleus identified by Boissard *et al.*, which is equivalent to the subcoeruleus or peri-locus coeruleus in the cat, is the major structure responsible for REM sleep (Boissard *et al.*, 2002, 2003). More recent work has led to the concept of a putative on/off switch for control of REM sleep (Lu *et al.*, 2006). The proposed nuclei and pathways involved in REM sleep control are based on lesioning, anterograde tracing, and c-Fos protein expression in the rat. While homologous structures in humans have yet to be precisely defined, this new and more complex schema allows many hypotheses to be tested.

In this model, the ventrolateral part of the periaqueductal grey matter (vPAG) and the lateral pontine tegmentum (LPT) represent the REM-off region; i.e. these nuclei turn off REM sleep. Lesions of these nuclei increase the amount of REM sleep. This region is regulated by multiple afferents. It is *inhibited* by GABAergic and galanin-ergic projections from the forebrain ventrolateral preoptic nucleus (eVLPO) plus the cholinergic projections from the PPN/LDTN. The vPAG and LPT REM-off neurons are *activated* by

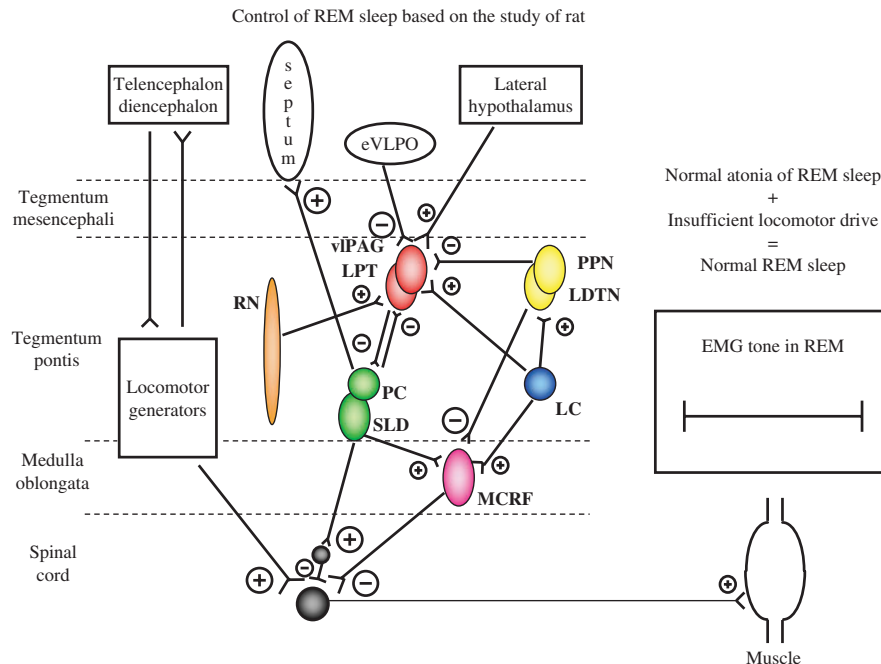


Fig. 3 Control of REM sleep based on studies in rat. See text for details. Excitatory projections represented by encircled plus sign, inhibitory projections represented by encircled minus sign, with the size of these symbols representing the relative effect of each projection on the synapsing nuclei. Normally populated nuclei are represented by coloured circles or ovals. The REM-off region is represented by the vIPAG and LPT in red, and the REM-on region is represented by the PC and SLD in green. EMG = electromyographic, eVLPO = extended part of the ventrolateral preoptic nucleus, LC = locus coeruleus, LDTN = laterodorsal tegmental nucleus, LPT = lateral pontine tegmentum, MCRF = magnocellular reticular formation, PC = pre-coeruleus, PPN = pedunculopontine nucleus, REM = rapid eye movement, RN = raphe nucleus, SLD = sublaterodorsal nucleus, vIPAG = ventrolateral part of the periaqueductal grey matter.

projections from the noradrenergic LC, serotonergic raphe nucleus (RN) and importantly, by hypocretinergic pathways from the lateral hypothalamus. Of clinical relevance, narcolepsy is characterized by inappropriate intrusions of REM sleep and severe reductions of brain hypocretin; this could be explained by loss of this hypocretin projection, thereby tipping the balance in favor of REM-on firing.

The REM-on region has reciprocal interactions with the REM-off area and these structures are mutually inhibitory. The REM-on region is represented by the sublaterodorsal nucleus and the pre-coeruleus (PC) region. Studies in rat indicate that the SLD contains glutamatergic neurons that project to the medulla and the spinal cord, where they contact inhibitory interneurons that hyperpolarize anterior horn motor neurons during REM sleep. This occurs via glutamatergic projections from the SLD to ventral horn glycinergic and GABAergic interneurons; these inhibit the spinal cord motor neurons, resulting in atonia during REM sleep. There are projections from the SLD to MCRF which may be active during REM sleep, but they are not required for the generation of EMG atonia during REM sleep. It also appears that the theta electroencephalographic (EEG) activity characteristic of REM sleep occur via pre-coeruleus glutamatergic projections to the medial septum, which activates the hippocampi and other structures.

Considering the recently reported lesioning studies in the rat, in which the REM sleep-on region, REM sleep-off region, REM sleep muscle atonia region and REM sleep theta EEG activity promoter region were identified (Lu *et al.*, 2006), the following model is proposed for REM sleep without atonia in rat (Fig. 4). Lesions to the SLD nucleus leads to disinhibition of spinal motoneurons, resulting in increased EMG tone during REM sleep (Lu *et al.*, 2006). Lesions of MCRF neurons, sparing fibres of passage, failed to alter EMG atonia in REM sleep (Lu *et al.*, 2006); thus, prior lesioning studies implicating the MCRF in REM sleep atonia may have inadvertently disrupted the descending SLD projections, which accounted for the findings.

Current concepts on RSWA and RBD based on human studies

Insights into the pathophysiology of RSWA and RBD in humans can be appreciated by considering drug effects, radiographic lesion studies and neuropathological studies.

Insights from pharmacotherapy in humans

No randomized, double-blind, placebo-controlled study has ever been reported for any drug treatment for RBD. Yet, numerous medications have been tried over the past

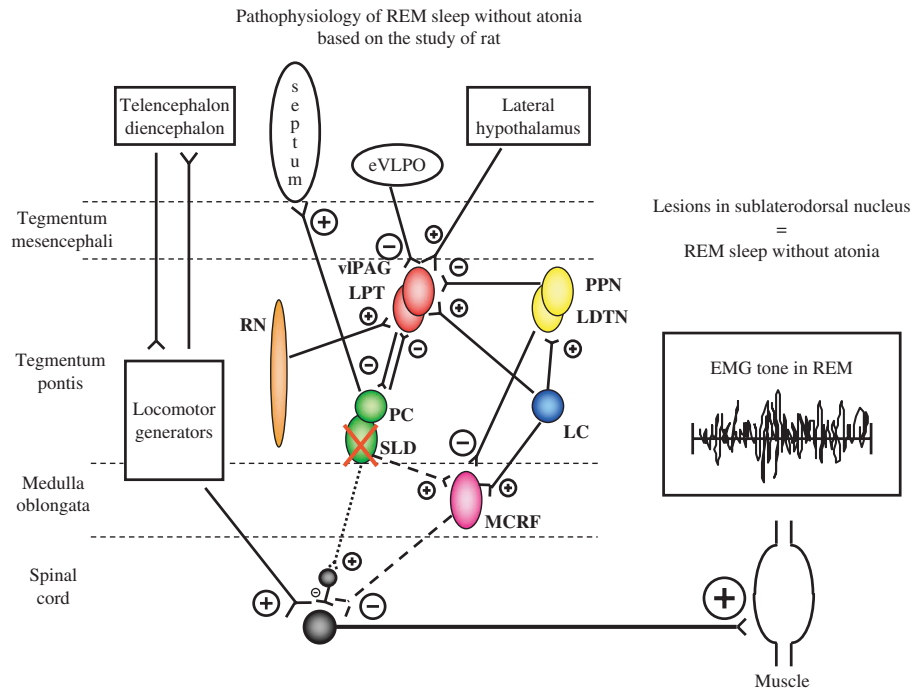


Fig. 4 Pathophysiology of REM sleep without atonia based on studies in rat. See text for details. Excitatory projections represented by encircled plus sign, inhibitory projections represented by encircled minus sign, with the size of these symbols representing the relative effect of each projection on the synapsing nuclei. Nuclei are represented by circles or ovals, with solid coloured circles and ovals reflecting those with normal populations of neurons, and speckled circles and ovals reflecting those with significantly reduced populations of neurons. A cross sign reflects ablation of a nucleus. The relative tonic influences of each projection are represented by line thickness, with thicker lines depicting stronger influences, thinner lines depicting weaker influences, and dashed and dotted lines depicting weak influences due to damage to neurons in the respective nuclei. The REM-off region is represented by the VIPAG and LPT in red, and the REM-on region is represented by the PC and SLD in green. The SLD projects to spinal interneurons ('direct route', denoted by the dotted line from SLD to spinal interneurons) and represents the final common pathway that causes active inhibition of skeletal muscle activity in REM sleep. The 'indirect route', denoted by the dashed line from SLD to the MCRF to the spinal interneurons, may also contribute to EMG atonia. However, lesions in structures which project to and from the MCRF, and lesioning the MCRF itself, are not considered critical in altering EMG atonia during REM sleep in animal models.

Table 2 Drugs that significantly alter the frequency and/or severity of REM sleep behaviour disorder (RBD)

Agents that tend to *decrease* the frequency and/or severity of RBD

Clonazepam
Melatonin
Levodopa
Pramipexole
Carbamazepine

Donepezil
Galantamine
Triazolam
Clozapine
Quetiapine

Agents that tend to *increase* the frequency and/or severity of RBD

Tricyclic antidepressants (particularly amitriptyline)
Chocolate
Selective serotonin and norepinephrine reuptake inhibitors (particularly venlafaxine and mirtazepine)

20 years to reduce the frequency and severity of RBD, with clonazepam being the most successful agent (Schenck and Mahowald, 1990, 2002; Olson *et al.*, 2000), and melatonin also showing efficacy alone or in combination with clonazepam (Kunz and Bes, 1999; Boeve *et al.*, 2003a) (Table 2). Interestingly, clonazepam has little effect on EMG tone in REM sleep on PSG despite near complete suppression of clinical RBD; whereas partial restoration of normal EMG

atonia during REM sleep has been observed in RBD patients treated with melatonin (Takeuchi *et al.*, 2001). Thus, these two agents may affect different aspects of the pathophysiological circuitry of RBD. Levodopa (Tan *et al.*, 1996; Rye, 1998; Yamouchi *et al.*, 2003) and pramipexole (Fantini *et al.*, 2003a) reduce the clinical manifestations of RBD, but may do this via suppression of REM sleep. Other drugs with inconsistent effects include carbamazepine (Bamford, 1993),

donepezil (Ringman and Simmons, 2000) and quetiapine (Boeve *et al.*, 2001a, 2004). Many other drugs, such as benzodiazepines (other than clonazepam), tricyclic antidepressants and antiepileptic agents, have been tried with generally poor response.

There is growing evidence implicating the newer generation antidepressant agents, particularly venlafaxine and mirtazapine (Husain *et al.*, 2001; Schenck and Mahowald, 2002; Onofrij *et al.*, 2003b; Winkelman and James, 2004), are frequent precipitators or aggravators of RBD. Chocolate (Vorona and Ware, 2002) and caffeine (Stolz and Aldrich, 1991) consumed in excess have also been implicated with RBD.

Any theory on RBD pathophysiology must explain these positive and negative responses to various therapies, but no adequate hypothesis has been suggested as yet that adequately takes these factors into account. It appears that a complex interplay of noradrenergic, serotonergic, cholinergic and other neurochemical systems are involved in RBD pathogenesis.

Insights from lesion studies

To our knowledge, there are five cases of RBD associated with lesions in the brainstem. Kimura *et al.* reported on a 75-year-old woman who had PSG-verified RBD associated with a presumably ischaemic lesion in the left upper pons (Fig. 5, Kimura *et al.* case) (Kimura *et al.*, 2000). A 25-year-old patient with relapsing–remitting multiple sclerosis (MS) had several hyperintensities in cerebral and pontine white matter (imaging studies not shown in this report)

(Plazzi and Montagna, 2002). We also recently evaluated a 51-year-old female patient with MS who developed RBD, verified by PSG, suddenly after experiencing an MS exacerbation which was associated with a new demyelinating lesion in the dorsal pontine tegmentum (Fig. 5, Tippmann-Peikert *et al.* case) (Tippmann-Peikert *et al.*, 2006a). A 32-year-old patient who underwent a second surgical procedure for a tegmental ponto-mesencephalic cavernoma developed RBD (Fig. 5, Provini *et al.* case) (Provini *et al.*, 2004). Additionally, a 59-year-old male with a 6-year history of essentially nightly RBD was found to have a brainstem neurinoma, and dream enactment behaviour disappeared after resection of the tumor (not shown in Fig. 5) (Zambelis *et al.*, 2002). Based on the imaging findings in these reports, these cases indicate that lesions within or near the mesencephalic and pontine tegmentum can be associated with human RBD. Nevertheless, the specific nuclei, projections and neurochemical systems involved in human RBD pathophysiology are not adequately characterized. Clearly, neuroimaging of patients with acute onset RBD may further enhance our understanding of the neuroanatomic systems involved in RBD.

Insights from neuropathological studies

Additional insights have been gained by the neuropathological study of patients with idiopathic or secondary RBD. Only one case of PSG-proven idiopathic RBD that has undergone neuropathological examination has been reported, and ‘incidental Lewy body disease (LBD)’ was identified in this patient (Uchiyama *et al.*, 1995). The distribution of

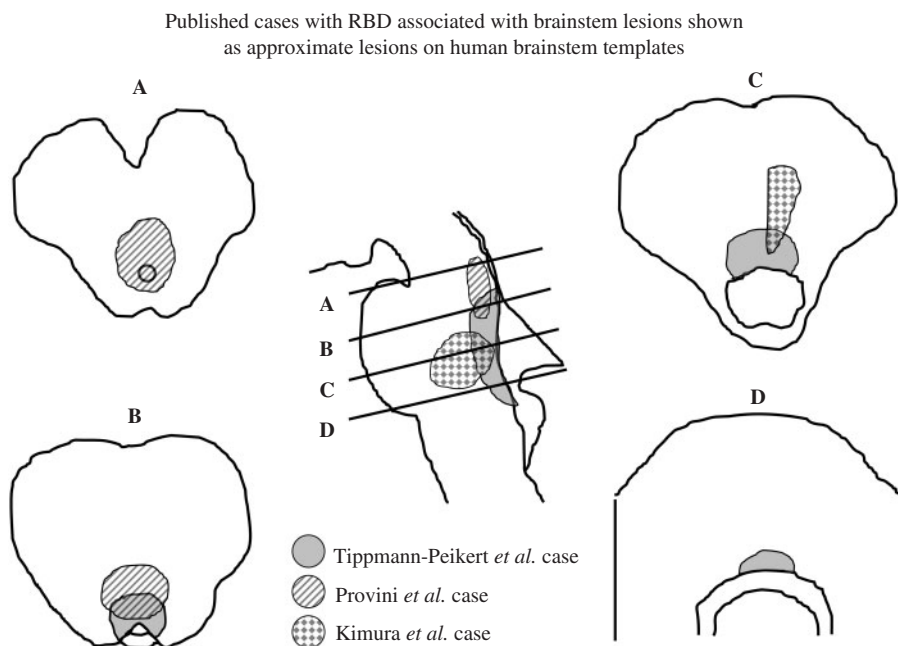


Fig. 5 Published cases with RBD associated with brainstem lesions shown as approximate lesions on human brainstem templates. Letters represent cross-sectional views through the brainstem, with **A** corresponding to the pontomesencephalic junction, **B** to the upper/mid pons, **C** to lower/mid pons and **D** just rostral to the pontomedullary junction. The approximate locations of the lesions based on the magnetic resonance imaging (MRI) data associated with the three published cases are shown.

Lewy bodies in this case would now be classified as brainstem-predominant Lewy body disease (LBD) or PD stage 3 (McKeith *et al.*, 1996, 2005; Braak *et al.*, 2003). Due to the severe neuronal loss and gliosis in the substantia nigra (SN) and coeruleus/subcoeruleus complex in their case, the authors postulated that degeneration of brainstem monoaminergic neurons explained RBD (Uchiyama *et al.*, 1995). However, the focus was on monoaminergic nuclei in this case and it is unclear whether other brainstem nuclei were carefully examined.

We have recently encountered another patient with a 15-year history of idiopathic RBD and no associated neurological symptoms, who died (at age 72 years); neuropathological examination revealed brainstem-predominant Lewy body disease, yet only mild degeneration of the SN, LC and raphe nuclei was present (Boeve *et al.*, 2007). These findings therefore argue against degeneration of the monoaminergic SN and LC being the primary cause of idiopathic RBD.

We have also performed PSG in six affected and five genealogically at risk family members of the pallido-pontine nigral degeneration (PPND) kindred, who have the N279K mutation in the microtubule associated protein tau (*MAPT*) (Boeve *et al.*, 2006). None of the subjects had any history of dream enactment behaviour. Nine of the eleven members attained sufficient REM sleep on PSG, and the electrophysiologic features of RSWA and behavioural manifestations of RBD were absent in all subjects. Neuropathological examination in four affected individuals revealed marked nigral degeneration in three along with mild degenerative changes in the locus coeruleus, pontine gray and pontine tegmentum. These findings also argue against nigral degeneration being sufficient to cause RBD.

Two other studies have reported neuronal quantification in RBD patients. In one case of RBD associated with combined Lewy body with Alzheimer's disease pathology, marked neuronal loss within the locus coeruleus but higher density of cholinergic mesopontine neurons were found (Schenck *et al.*, 1996b, 1997). One interpretation of these data is that the increase in cholinergic neurons and possible disinhibition of these neurons by the reduced number of locus coeruleus neurons led to increased REM sleep drive and RBD (Schenck *et al.*, 1996b). In the other analysis, four patients with multiple system atrophy (MSA) were studied—these four cases had depletion of the cholinergic neurons in the pedunculopontine nucleus/laterodorsal tegmental nucleus as well as neuromelanin-containing locus coeruleus neurons (Benarroch and Schmeichel, 2002). Depletion of cholinergic neurons in the pedunculopontine nucleus/laterodorsal tegmental nucleus neurons was thought to possibly underlie RBD in these patients (Benarroch and Schmeichel, 2002) and could conceivably explain the occasional benefit of cholinesterase inhibitors, such as donepezil, in RBD (Ringman and Simmons, 2000) and the presence of RBD in some patients with PSP (Arnulf *et al.*, 2005). However, the recent experimental evidence discussed above (Lu *et al.*, 2006) indicates

that cholinergic mechanisms may have a modulatory role in REM-related phenomena rather than a primary role in RSWA. The disparate findings in the pedunculopontine nucleus/laterodorsal tegmental nucleus in the two studies noted above suggest alterations in the pedunculopontine nucleus/laterodorsal tegmental nucleus nuclei do not fully account for RBD pathogenesis. It should be noted that the LC is silent during REM sleep (Gervasoni *et al.*, 2000; Lu *et al.*, 2002) and hence this nucleus, per se, should not be directly responsible for RBD.

Proposed anatomic substrate for REM sleep control in humans

If we extrapolate the findings on REM sleep control in the rat model to humans, one could propose a similar network of nuclei and projections as depicted in Fig. 4, with the locations of specific nuclei in the human brainstem as shown in Fig. 6. There may be species-specific differences in REM sleep control (Siegel, 2006), and thus further analyses in humans will be necessary to determine how similar REM sleep control and dyscontrol is between humans and animal models, particularly with respect to the structure(s) in humans analogous to the subcoeruleus in cat and sublaterodorsal nucleus in rat.

Proposed pathophysiology of human RBD

Based on the available animal and human lesion and pathological data as well as the known brainstem structures in humans, a schematic representation underlying RBD in humans is proposed in Fig. 7. This schema is clearly a work in progress, with other pertinent structures and neurochemical systems perhaps not yet identified, or not yet known to contribute to REM sleep physiology. We hypothesize that the structures and networks are similar to the animal models, with the SLD or analogous nucleus with projections to spinal interneurons ('direct route', denoted by the dotted line from SLD to spinal interneurons in Fig. 7) being the final common pathway that causes active inhibition of skeletal muscle activity in REM sleep. The 'indirect route' (denoted by the dashed line from SLD to spinal interneurons in Fig. 7) can also contribute, with SLD lesioning causing reduced excitation of the MCRF, thereby causing a net reduced inhibition of spinal motoneurons (either directly or via spinal interneurons). It remains to be seen if lesioning or degeneration of the MCRF is sufficient to cause RBD in humans.

The locomotor generators, which are presumed to project to the spinal motoneurons either directly or indirectly via other brainstem nuclei, have yet to be identified and characterized. The neuronal circuitry for this process is poorly understood, and supratentorial influences on both the locomotor generators and the muscle atonia system are likely. One might expect a variety of stimuli could alter locomotor drive and/or muscle atonia, such as other primary sleep disorders (e.g. obstructive sleep apnea), neurodegeneration,

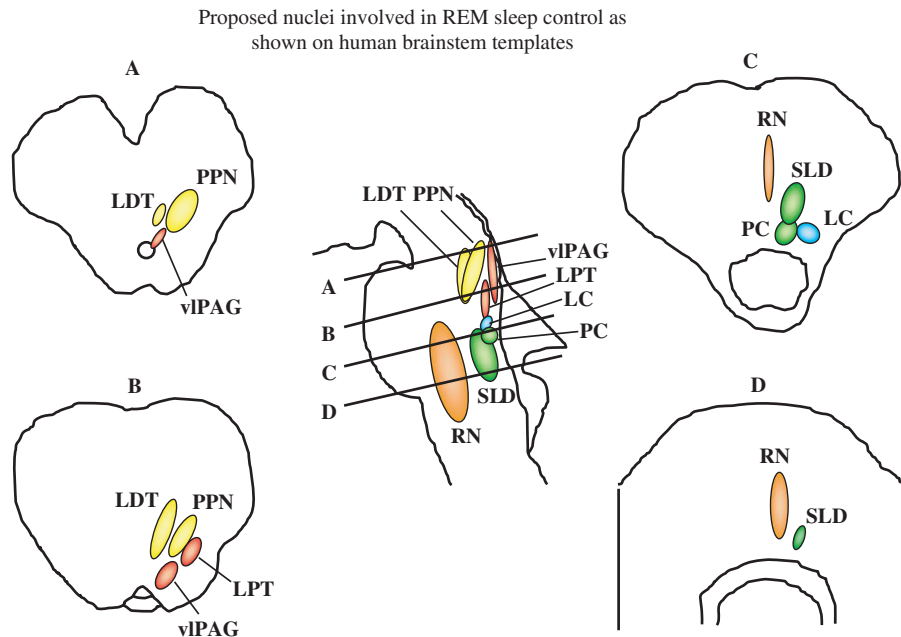


Fig. 6 Proposed nuclei involved in REM sleep control as shown on human brainstem templates. Letters represent cross-sectional views through the brainstem, with **A** corresponding to the pontomesencephalic junction, **B** to the upper/mid pons, **C** to lower/mid pons and **D** just rostral to the pontomedullary junction. The REM-off region is represented by the vIPAG and LPT in red, and the REM-on region is represented by the PC and SLD in green. eVLPO = extended part of the ventrolateral preoptic nucleus, LC = locus coeruleus, LDTN = laterodorsal tegmental nucleus, LPT = lateral pontine tegmentum, PC = pre-coeruleus, PPN = pedunculopontine nucleus, REM = rapid eye movement, RN = raphe nucleus, SLD = sublateralodorsal nucleus, vIPAG = ventrolateral part of the periaqueductal grey matter.

structural lesions in the brainstem, medications, illicit drugs, head trauma, etc.

If the brainstem lesions associated with RBD as shown in Fig. 5 are superimposed on the proposed nuclei involved in REM sleep control as shown on Fig. 6, one can see that two of the lesions involve the region expected to represent the SLD (Fig. 8). Since the caudal extent of the lesion in the instructive case reported by Provini *et al.* (2004) cannot be surmised based on the reported MRI, it is not known if the proposed SLD region is necessarily involved in every instance of RBD associated with a brainstem lesion. It also remains to be seen if lesions that either affect the REM-off region or projections to and from the REM-on region are sufficient to cause RBD in humans.

Increased phasic locomotor drive and/or loss of REM sleep atonia has been suggested as the likely mechanism for the clinical expression of human RBD (Mahowald and Schenck, 2000). As noted earlier, some patients have PSG evidence of RSWA but have never exhibited dream enactment behaviour. One could propose that lesions to, degeneration of, or pharmacological manipulations of the SLD or MCRF would be sufficient to cause RSWA but insufficient to cause dream enactment behaviour. One could also posit that processes that activate the locomotor generators may overcome the tonic inhibition of the SLD or MCRF on spinal motoneurons, potentially leading to occasional dream enactment behaviour. This could explain why patients

with moderate to severe obstructive sleep apnea, who have increased REM sleep drive due to the sleep fragmentation inherent to untreated obstructive sleep apnea, exhibit features indistinguishable from RBD, except that EMG atonia in REM sleep is typically normal on PSG (Iranzo and Santamaria, 2005). Administration or discontinuation of drugs could cause similar effects.

RBD is a dream disorder almost as much as a REM motor disorder (Fantini *et al.*, 2005), and the tendency for the dream content to involve an aggressive, attacking or chasing theme is well-known but poorly understood (Olson *et al.*, 2000; Schenck and Mahowald, 2002; Fantini *et al.*, 2005). RBD is often considered to reflect an individual 'acting out one's dream', implying that the dream content dictates the vocalizations and motor behaviours that are exhibited. Yet another explanation involves the concept of 'dreaming around one's actions'. In other words, the loss of EMG atonia and increased locomotor drive could lead to limb movements, and the dream content could evolve secondarily around what is exhibited. We have heard many patients describe dreams that seemed to emanate from physical stimuli occurring at the time. Examples include patients who describe dreams about being in an earthquake if they are sleeping in a car while traveling on a bumpy road, and the potentially dangerous experience of dreaming that a person is grabbing and attacking them when in fact their spouse is grabbing the patients' arms in an attempt to

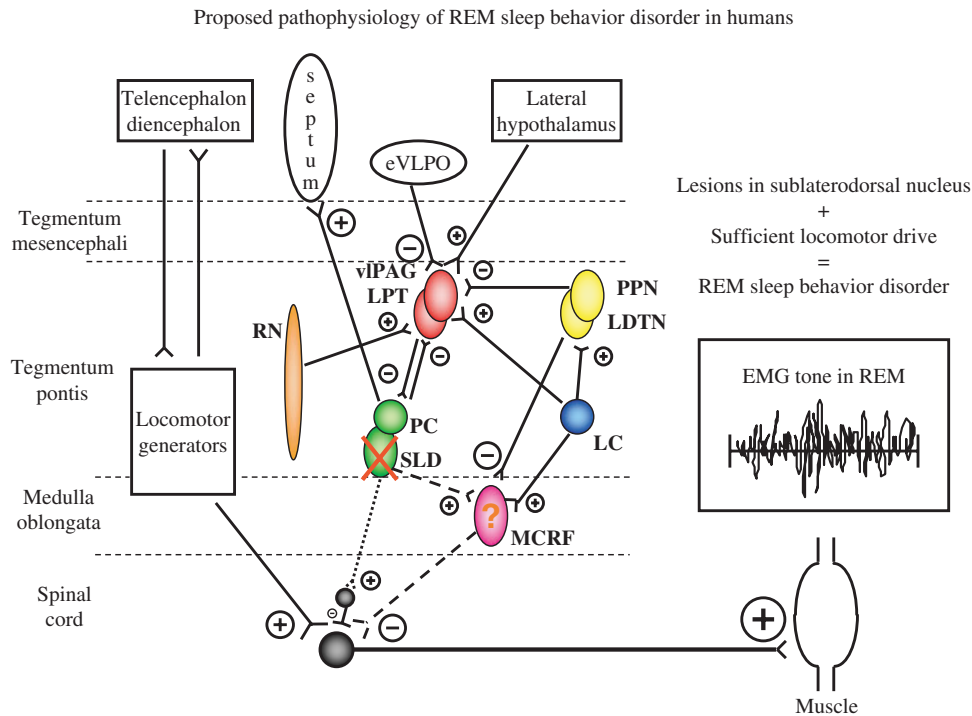


Fig. 7 Proposed pathophysiology of REM sleep behaviour disorder in humans. See text for details. Excitatory projections represented by encircled plus sign, inhibitory projections represented by encircled minus sign, with the size of these symbols representing the relative effect of each projection on the synapsing nuclei. Nuclei are represented by circles or ovals, with solid coloured circles and ovals reflecting those with normal populations of neurons, and speckled circles and ovals reflecting those with significantly reduced populations of neurons. A cross sign reflects ablation of a nucleus. The relative tonic influences of each projection are represented by line thickness, with thicker lines depicting stronger influences, thinner lines depicting weaker influences, and dashed and dotted lines depicting weak influences due to damage to neurons in the respective nuclei. The REM-off region is represented by the vIPAG and LPT in red, and the REM-on region is represented by the PC and SLD in green. The SLD (or analogous nucleus in humans) projects to spinal interneurons ('direct route', denoted by the dotted line from SLD to spinal interneurons) and likely represents the final common pathway that causes active inhibition of skeletal muscle activity in REM sleep. The 'indirect route', denoted by the dashed line from SLD to the MCRF to the spinal interneurons, may also contribute to EMG atonia. However, in humans, it is not yet known whether lesions in structures which project to and from the MCRF, and lesioning the MCRF itself, are critical in affecting EMG atonia during REM sleep. EMG = electromyographic, eVLPO = extended part of the ventrolateral preoptic nucleus, LC = locus coeruleus, LDTN = laterodorsal tegmental nucleus, LPT = lateral pontine tegmentum, MCRF = magnocellular reticular formation, PC = pre-coeruleus, PPN = pedunclopontine nucleus, REM = rapid eye movement, RN = raphe nucleus, SLD = sublaterodorsal nucleus, vIPAG = ventrolateral part of the periaqueductal grey matter.

suppress the fighting behaviour during a dream; the latter can lead to injuries to the bedpartner. These two phenomena of 'acting out one's dreams' and 'dreaming around one's actions' are not mutually exclusive, and could be working in concert.

In those with pervasive RBD, it is likely that sufficient locomotor drive is necessary in the setting of RSWA to result in clinical RBD on a nightly basis. Yet, we have observed many patients with RBD, whether 'idiopathic' or associated with a neurological disorder, who report that their nightmares and dream enactment behaviour tend to cluster. That is, such patients may experience RBD features many times over several nights or weeks, alternating with periods of weeks or months when no nightmares or episodes of dream enactment behaviour occur. Few are ever able to describe any consistent pattern of food or beverage ingestion, change in sleeping, change in exercise, emotional stressors or drugs that adequately explains this clustering effect. We do not have

a clear explanation for this phenomenon, but clustering is well-known in other neurological disorders, such as cluster and migraine headaches as well as seizures, and perhaps a similar mechanism could result in RBD clustering.

Clinical and pathophysiological relevance of RSWA and RBD associated with human neurodegenerative disease

The REM sleep behaviour disorder—neurological disorder association

RBD has been reported in association with many aetiological categories of neurological disorders (i.e. secondary RBD), including vascular lesions, tumours, demyelinating disease (examples of these are described earlier), autoimmune/inflammatory disorders and neurodegenerative disorders (described later). Within the autoimmune/inflammatory

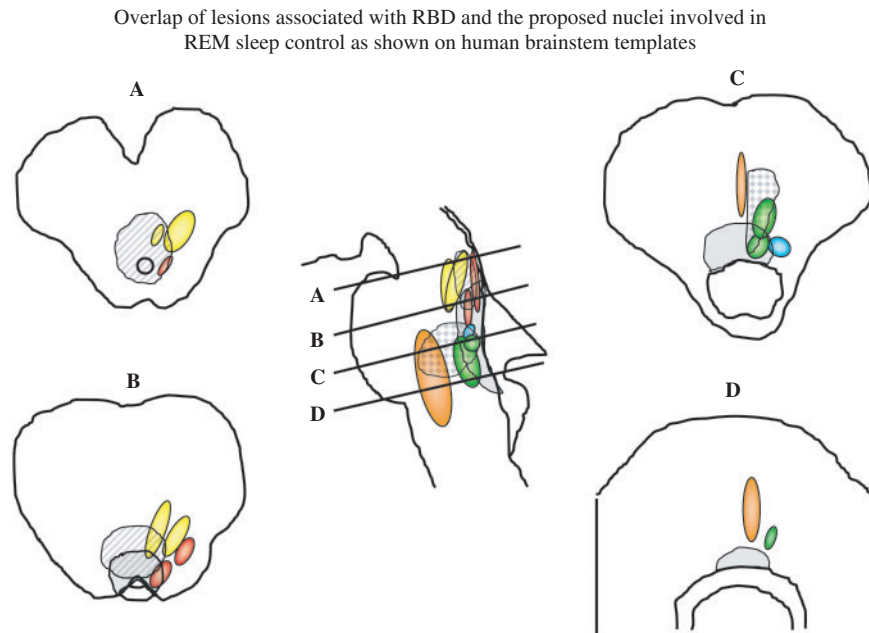


Fig. 8 Overlap of lesions associated with RBD and the proposed nuclei involved in REM sleep control as shown on human brainstem templates. See text for details. Letters represent cross-sectional views through the brainstem, with **A** corresponding to the pontomesencephalic junction, **B** to the upper/mid pons, **C** to lower/mid pons and **D** just rostral to the pontomedullary junction. The REM-off region is represented by the vlPAG and LPT in red, and the REM-on region is represented by the PC and SLD in green. The approximate lesions are superimposed on the proposed anatomic brainstem nuclei involved in REM sleep control.

disorder spectrum, RBD is often associated with narcolepsy (Schenck and Mahowald, 1992; Nightingale *et al.*, 2005) and more recently has been reported with limbic encephalitis associated with voltage-gated potassium channel antibodies (Iranzo *et al.*, 2006a). These disorders may reflect autoimmune/inflammatory processes affecting the structures and pathways involved in RBD pathophysiology as shown in Fig. 7. Quantitative neuropathological studies in brainstem nuclei of autopsied patients with narcolepsy and limbic encephalitis associated with voltage-gated potassium channel antibodies, with and without RBD, could help delineate the key nuclei involved in human RBD.

The REM sleep behaviour disorder—neurodegenerative disease association

Numerous cases of RBD have been reported in association with clinically diagnosed Parkinson's disease (Schenck *et al.*, 1986; Silber and Ahlskog, 1992; Silber *et al.*, 1993; Tan *et al.*, 1996; Sforza *et al.*, 1997; Comella *et al.*, 1998; Kunz and Bes, 1999; Rye *et al.*, 1999; Arnulf *et al.*, 2000; Olson *et al.*, 2000; Gagnon *et al.*, 2002; Onofrij *et al.*, 2002, 2003a, b; Eiseensehr *et al.*, 2003; Fantini *et al.*, 2003a; Iranzo *et al.*, 2005; Ozekmekci *et al.*, 2005; Pacchetti *et al.*, 2005; Scaglione *et al.*, 2005; Hanoglu *et al.*, 2006; Iranzo *et al.*, 2006b; Sinfioriani *et al.*, 2006), dementia with Lewy bodies (Boeve *et al.*, 1998, 2001b, 2003a, b, c; Ferman *et al.*, 1999; Ferman *et al.*, 2002; Massironi *et al.*, 2003; Ferman *et al.*, 2004, 2006; Iranzo *et al.*, 2006b), multiple system atrophy

(Cocagna *et al.*, 1985; Quera Salva and Guilleminault, 1986; Schenck *et al.*, 1986, 1987; Wright *et al.*, 1990; Manni *et al.*, 1993; Tison *et al.*, 1995; Plazzi *et al.*, 1997; Sforza *et al.*, 1997; Tachibana *et al.*, 1997; Olson *et al.*, 2000; Tachibana and Oka, 2004; Iranzo *et al.*, 2005, 2006b). Pure autonomic failure has also been reported (Sforza *et al.*, 1997; Weyer *et al.*, 2006). RBD was identified in several members of a kindred with a parkin mutation (Kumru *et al.*, 2004), and Lewy body disease pathology has been reported in a different large kindred with parkin mutations (Pramstaller *et al.*, 2005). The association of RBD with PD, DLB, MSA, PAF and other disorders with Lewy body pathology is therefore clearly established. In fact, RBD is now considered a suggestive feature in the clinical diagnostic criteria for DLB (McKeith *et al.*, 2005).

RBD has been reported in two cases of clinically suspected sporadic PSP (Sforza *et al.*, 1997; Olson *et al.*, 2000) and in 2/15 (13%) of a group of PSP subjects (Arnulf *et al.*, 2005). Spinocerebellar atrophy—type 3 (SCA-3) has also been reported associated with dream enactment behaviour (although few have had PSG confirmation) (Friedman, 2002; Fukutake *et al.*, 2002). One case of RBD with amyotrophic lateral sclerosis has also been identified (Sforza *et al.*, 1997). RSWA has been reported in a single case of sporadic CBD (Kimura *et al.*, 1997), but this patient did not have clinical RBD features. There are no published reports of RBD associated with Pick's disease, frontotemporal dementia, progressive nonfluent aphasia syndrome, semantic dementia, progressive subcortical gliosis, argyrophilic grain disease or dementia lacking distinctive histopathology

(Boeve *et al.*, 2001b), and no evidence of RSWA or RBD was found in a recent study of 11 members of the pallido-pontonigral degeneration kindred (Boeve *et al.*, 2006). One case of clinically diagnosed Alzheimer's disease was associated with RBD (Schenck *et al.*, 1996b), but neuropathological analysis identified both Alzheimer's disease and Lewy body disease (Schenck *et al.*, 1997). We (Boeve *et al.*, unpublished data) and others (Gagnon *et al.*, 2006a, b) have observed sparse cases of RBD associated with clinically probable AD, but until neuropathological examinations are completed on such cases, it remains to be seen if RBD occurs in pure AD.

The REM sleep behaviour disorder—synucleinopathy association

Recent immunocytochemical analyses have revealed that Parkinson's disease (PD), dementia with Lewy bodies (DLB), multiple system atrophy (MSA) and pure autonomic failure (PAF) share the similarity of α -synuclein positive intracellular inclusions (Spillantini *et al.*, 1998; Dickson *et al.*, 1999; Arai *et al.*, 2000), and these disorders are now considered collectively as the 'synucleinopathies'. Most other neurodegenerative and prion disorders can be classified as 'tauopathies', 'prionopathies' and 'polyglutamine triplet repeat disorders' (Hardy, 1999; Hardy and Gwinn-Hardy, 1999), with the very recent addition of 'hypoprogranulinopathies' representing frontotemporal dementia and/or parkinsonism associated with mutations in progranulin (*PGRN*) and frontotemporal degeneration with ubiquitin-positive inclusions pathology (Baker *et al.*, 2006). Several reports over the past few years have led to the appreciation that RBD is frequently associated with the synucleinopathies and less frequently with the non-synucleinopathy neurodegenerative disorders (Boeve *et al.*, 2001b, 2003a, b, c; Ozekmekci *et al.*, 2005; Stiasny-Kolster *et al.*, 2005; Gagnon *et al.*, 2006b; Iranzo *et al.*, 2006b).

Our clinicopathological experience at Mayo Clinic of RBD associated with dementia and/or parkinsonism, updated from our prior report (Boeve *et al.*, 2003c), is shown in Table 3. These cases represent patients who satisfy all of these criteria: (i) have been diagnosed with probable or definite

RBD based on a history of recurrent dream enactment behaviour +/- PSG confirmation; (ii) have experienced parkinsonism and/or dementia and have been clinically diagnosed with Alzheimer's disease, vascular dementia, dementia with Lewy bodies, Parkinson's disease (with or without dementia), multiple system atrophy, frontotemporal dementia, primary progressive aphasia/progressive non-fluent aphasia syndrome/semantic dementia, corticobasal syndrome, posterior cortical atrophy or progressive supranuclear palsy based on established criteria; and (iii) have undergone autopsy and been neuropathologically diagnosed with Alzheimer's disease, Lewy body disease, vascular dementia, multiple system atrophy, Pick's disease, frontotemporal lobar degeneration with or without ubiquitin-positive inclusions, frontotemporal dementia and parkinsonism due to a mutation in microtubule associated protein tau, corticobasal degeneration, argyrophilic grain disease or progressive supranuclear palsy based on established criteria. As can be seen, 35/36 (97%) of such cases have had an underlying synucleinopathy. Over this same time period, well over 300 cases with a non-synucleinopathy disorder verified neuropathologically had no history of dream enactment behaviour. Therefore, the clinical and pathological literature suggests that when associated with a neurodegenerative disorder, RBD often (but not always) reflects an underlying synucleinopathy (Boeve *et al.*, 2001b, 2003b, c, 2004; Stiasny-Kolster *et al.*, 2005; Boeve and Saper, 2006; Gagnon *et al.*, 2006b; Iranzo *et al.*, 2006b; Postuma *et al.*, 2006).

The frequency of RBD is ~33–60% in PD patients (Comella *et al.*, 1998; Gagnon *et al.*, 2002), 50–80% in DLB patients (Boeve *et al.*, 2004) and 80–95% of MSA patients (Plazzi *et al.*, 1997; Tachibana *et al.*, 1997), but these frequencies are based on convenience samples of patients with these disorders evaluated at specialized centres. The true frequency of RSWA and RBD in the various neurodegenerative disorders will require PSGs to be performed in a population-based manner in all subjects with a neurodegenerative disease (or at least by a random sampling method) regardless of a history of dream enactment behaviour or not, and then all study participants will then require neuropathological examination. Due to the rarity of some neurodegenerative disorders, problem of identifying or sampling appropriate subjects, expense required to examine subjects and perform PSGs, infrastructure needed to secure autopsies and surely other issues, determining the true frequency of RSWA and RBD in the various neurodegenerative disorders will indeed be challenging.

Among the non-synucleinopathy disorders associated with RBD (e.g. PSP, SCA-3 and AD), patients have tended to have RBD evolve in concert with or after the onset of parkinsonism, whereas RBD typically begins years before the onset of cognitive and motor features of PD, DLB, MSA and PAF. Hence, RBD preceding the motor and cognitive features of a neurodegenerative disorder may be particularly specific for synucleinopathies.

Table 3 Updated clinicopathological experience at Mayo Clinic from January 1990 to December 2006 of REM sleep behaviour disorder associated with dementia and/or parkinsonism

Pathological diagnoses	N
Lewy body disease ^a	31
Multiple system atrophy	4
Progressive supranuclear palsy ^b	1
Total	36

^aTwelve of the LBD cases also met criteria for intermediate or high likelihood of Alzheimer's disease.

^bCoexisting vascular and Alzheimer pathology was present.

The one patient we followed longitudinally with the corticobasal syndrome who had a long history of dream enactment behaviour was ultimately found to have mixed Lewy body disease/Alzheimer's disease pathology, again exemplifying the need to perform neuropathological examination in patients with probable or definite RBD. This is the only patient with the corticobasal syndrome among over 50 patients evaluated at our institution with this clinical diagnosis over the past 10 years who had a history suggesting RBD. Despite evaluating over 200 patients with clinically diagnosed progressive supranuclear palsy also over the past 10 years, and pathologically characterizing well over 400 PSP brains as part of the Society for Progressive Supranuclear Palsy Brain Bank (D.W. Dickson *et al.*, unpublished data), a history of recurrent dream enactment behaviour in clinically and/or pathologically diagnosed PSP is extremely uncommon in our experience. Our experience and the literature published to date clearly indicates that RBD is more frequent in the synucleinopathies than in the non-synucleinopathies, which suggests that despite the presence of parkinsonism as well as pathologically verified nigral degeneration in most synucleinopathies, tauopathies and other neurodegenerative disorders, there are likely other abnormalities in the brainstem that are different between the synucleinopathy and non-synucleinopathy disorders that explain the differential expression of RBD.

The tendency of RBD to occur frequently in the synucleinopathies and rarely in the tauopathies and other neurodegenerative disorders supports the concept of selective vulnerability occurring in key brainstem neuronal networks in the synucleinopathies, and such neuronal networks are likely to be less dysfunctional or normal in the tauopathies and other neurodegenerative disorders (Boeve *et al.*, 2001*b*, 2003*b*, *c*, 2004; Boeve and Saper, 2006; Gagnon *et al.*, 2006*b*; Iranzo *et al.*, 2006*b*). PD, DLB, MSA, the other few non-synucleinopathy disorders associated with RBD and the rare RBD cases with structural brainstem lesions may provide particular insights into RBD pathophysiology by demonstrating which neuronal networks are dysfunctional compared to the multitude of disorders and cases that are not associated with RBD. Comparing the neuropathological findings (especially if neuronal quantification of key brainstem structures can be performed) in the rare cases of RBD associated with non-synucleinopathy disorders to the more common cases of non-synucleinopathy disorders not associated with RBD may be particularly enlightening.

Overlap of brainstem nuclei degeneration in Parkinson's disease and REM sleep behaviour disorder

Any theory on RBD pathogenesis must be consistent with the high frequency of the disorder in the synucleinopathies and the tendency for RBD to precede parkinsonism and/or dementia. A recently proposed staging system for the

neuropathological characterization of PD may be particularly pertinent to these issues (Boeve *et al.*, 2003*c*, 2004; Braak *et al.*, 2003, 2004; Stiasny-Kolster *et al.*, 2005; Gagnon *et al.*, 2006*b*; Iranzo *et al.*, 2006*b*; Postuma *et al.*, 2006). This staging system posits a temporal sequence of synuclein pathology in the brain beginning in the medulla and eventually ascending to more rostral structures (Braak *et al.*, 2003, 2004). Dysfunction in the SLD (Stage 2) could lead to RSWA and RBD, and more specifically, prominent degeneration in the SLD could be the critical nucleus involved. This temporal sequence of pathology could explain why RBD precedes parkinsonism (Stages 3 and 4) and dementia (Stages 4–6) in many patients with Lewy body pathology. Recent studies provide further support for this staging system as it relates to RBD (Stiasny-Kolster *et al.*, 2005; Postuma *et al.*, 2006). Yet, if this staging scheme is accurate, why do a significant minority of patients with PD +/- dementia and DLB never exhibit dream enactment behaviour, and why do some DLB patients never exhibit parkinsonism? One explanation is that RBD may not be expressed until sufficient degeneration in the relevant nuclei has occurred, and parkinsonism may not be expressed until sufficient degeneration (typically thought to be at least 80% neuronal loss) in the substantia nigra has taken place. Yet, most cases that come to autopsy have had parkinsonism and/or dementia for many years, in which severe and end-stage pathology is found at autopsy. Hence, further characterization of the temporal and topographical course of degenerative changes in patients with early neurodegenerative disease in the synucleinopathies and non-synucleinopathies, with and without RBD, is needed. Analyses in patients with idiopathic RBD (Boeve *et al.*, 2007), and/or only mild cognitive and motor features, may be most enlightening as the degenerative changes may be more mild and selective, and thus more revealing.

With the recent appreciation of secondary RBD associated with neurodegenerative disease, particularly the synucleinopathies, there is increasing interest in better understanding RBD pathogenesis (Abbott, 2005). One reflection of the growing interest in the RBD-neurodegenerative disease association can be found in the National Sleep Disorders Research Plan from the National Center on Sleep Disorders Research from the United States, in which it was recommended that investigators 'better define the pathophysiology and neuroanatomic substrates of primary parasomnias in human and animal studies' and 'establish a brain bank for RBD and other parasomnias' (2003).

The structures of interest in the human brain are shown in Figs 9–11. Some testable hypotheses to confirm or refute that the subcoeruleus/sublaterodorsal nucleus and/or magnocellular reticular formation are central to RBD pathophysiology in humans include (i) in patients with idiopathic RBD and in those with RBD associated with neurodegenerative disease, significant neuronal loss will be

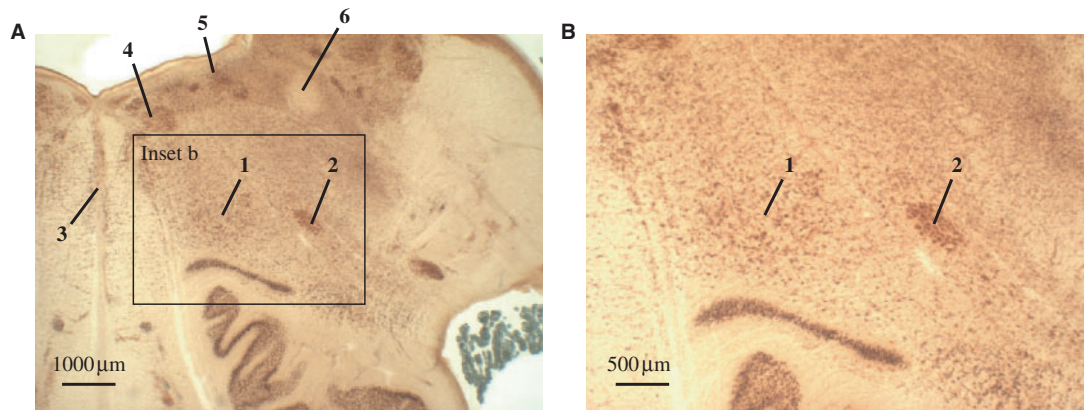


Fig. 9 Photograph of the human brainstem at the medullary level. Photograph of brainstem cut at the medullary level from a 53-year-old control male subject stained with lipofuscin pigment (with adehydefuchsin) and Nissl substance (with Darrow red) (**A** and **B**). 1 = magnocellular reticular formation, 2 = ambiguous nucleus, 3 = nucleus raphes obscurus, 4 = motor nucleus of the hypoglossal nerve, 5 = dorsal motor nucleus of the vagal nerve, 6 = solitary tract.

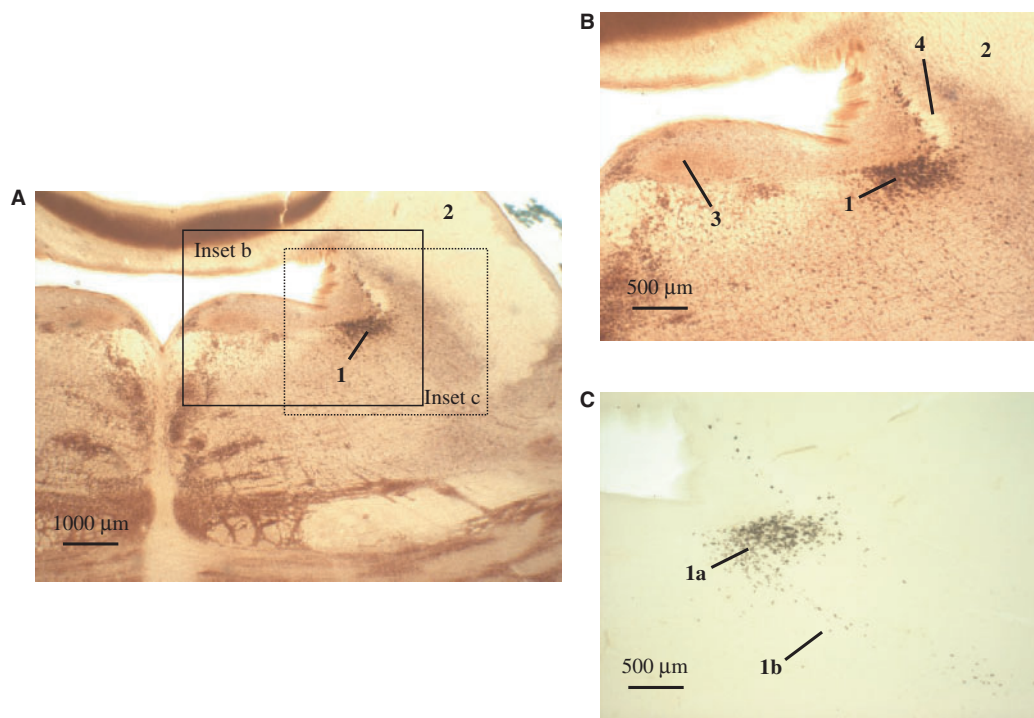


Fig. 10 Photograph of the human brainstem at the lower pontine level. Photograph of brainstem cut at the lower pontine level from a 53-year-old control male subject stained with lipofuscin pigment (with adehydefuchsin) and Nissl substance (with Darrow red) (**A** and **B**; **C** is unstained). 1 = coeruleus/subcoeruleus complex (melanoneurons), 1a = locus coeruleus, 1b = subcoeruleus, 2 = inferior cerebellar peduncle, 3 = dorsal tegmental nucleus of Gudden, 4 = tractus mesencephali n. trigemini.

present in the subcoeruleus/sublaterodorsal nucleus and/or magnocellular reticular formation and (ii) in subjects with normal EMG atonia during REM sleep as documented by PSG, normal populations of neurons will exist in the subcoeruleus/sublaterodorsal nucleus and magnocellular reticular formation.

'Idiopathic' REM sleep behaviour disorder—a harbinger of neurodegenerative disease

As noted earlier, RBD tends to precede the onset of parkinsonism or dementia in patients with MSA, PD and DLB by years or decades (Wright *et al.*, 1990; Silber and Ahlskog, 1992; Tison *et al.*, 1995; Tan *et al.*, 1996;

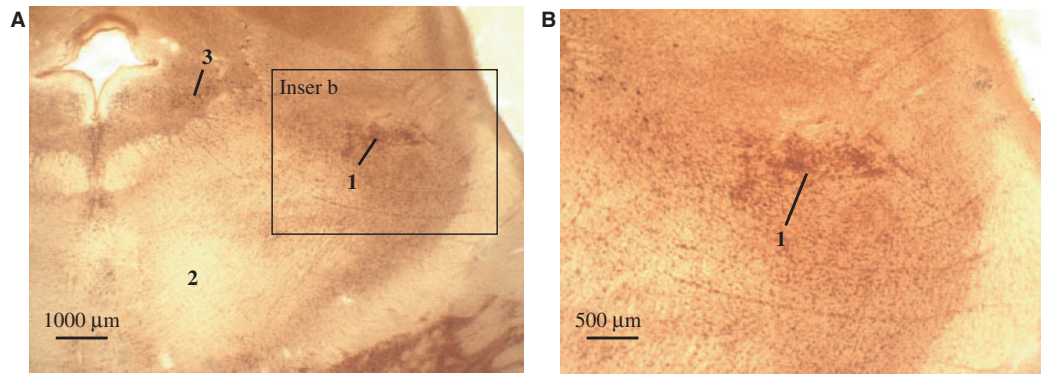


Fig. II Photograph of the human brainstem at the upper pontine level. Photograph of brainstem cut at the upper pontine level from a 53-year-old control male subject stained with lipofuscin pigment (with adehydefuchsin) and Nissl substance (with Darrow red) (**A** and **B**). 1 = pedunculopontine nucleus, 2 = decussation of superior cerebellar peduncles, 3 = anterior pole of locus coeruleus.

Schenck *et al.*, 1996a, 2003, 1997; Turner *et al.*, 1997; Boeve *et al.*, 1998, 2001b, 2003c; Ferman *et al.*, 1999; Olson *et al.*, 2000; Turner *et al.*, 2000; Schenck and Mahowald, 2002, 2004. Almost 40% of patients with idiopathic RBD in one series were subsequently found to have developed a parkinsonian disorder (Schenck *et al.*, 1996a), and with continued longitudinal follow-up, over 65% of the original cohort has developed parkinsonism and/or dementia (Schenck *et al.*, 2003). In another series of idiopathic RBD followed over a mean period of 11 years, 23 subjects have been re-contacted, with three being diagnosed with DLB, one with PD, one with dementia (not otherwise specified) and another 10 subjects have developed neurological symptoms highly suggestive of parkinsonism and/or dementia (total 15/23 = 65%) (Tippmann-Peikert *et al.*, 2006b). Symptoms of RBD preceded dementia and/or parkinsonism in 67% of another series (Boeve *et al.*, 2003c). Recent studies have demonstrated changes on electroencephalography (Fantini *et al.*, 2003b; Massicotte-Marquez *et al.*, 2005), single photon emission computed tomography (Eisensehr *et al.*, 2000, 2003; Mazza *et al.*, 2006), neuropsychological testing (Ferini-Strambi *et al.*, 2004), smell testing (Stiasny-Kolster *et al.*, 2005), colour discrimination (Postuma *et al.*, 2006), cardiac autonomic activity (Ferini-Strambi *et al.*, 1996) and more subtle abnormalities on measures of autonomic, motor and gait functioning (Postuma *et al.*, 2006), also suggesting that a more widespread multisystem neurological disorder is present. In a recent study comparing 17 cognitively normal patients with histories of dream enactment behaviour to 17 controls, the patients with dream enactment behaviour had reduced cerebral metabolic rate for glucose in regions preferentially affected in patients with dementia with Lewy bodies, suggesting that dream enactment behaviour may be a possible risk factor for the development of DLB (Caselli *et al.*, 2006). Therefore, several lines of evidence suggest that many cases of 'idiopathic' RBD may not be truly idiopathic, leading some to suggest the term 'cryptogenic' rather than 'idiopathic'

(Ferini-Strambi *et al.*, 2004). Rather, such cases may represent an early clinical manifestation of an evolving neurodegenerative disease, which in many cases may be a synucleinopathy. The presence of RBD may therefore be particularly relevant early in the course of a neurodegenerative disease when intervention may be most critical.

Future directions

As we have noted previously (Boeve *et al.*, 2003c, 2004; Boeve, 2004; Boeve and Saper, 2006), RBD is analogous to the syndrome of mild cognitive impairment (MCI). MCI is considered by many to represent the earliest clinical manifestation of an evolving dementing illness, which is usually Alzheimer's disease (Petersen *et al.*, 1999, 2001a, 2006; Petersen, 2000; Jicha *et al.*, 2006). MCI has gained significant attention of late, and clinicians are now encouraged to identify and monitor patients with MCI (Petersen *et al.*, 2001b). Approximately 80% of those who meet the criteria for amnesic MCI will have Alzheimer's disease within 6 years (Petersen *et al.*, 1995, 1999). Several treatment trials are either just completed or currently in progress to potentially delay the progression of patients from MCI to Alzheimer's disease, with one recent trial demonstrating delayed conversion from MCI to Alzheimer's disease with donepezil (Petersen *et al.*, 2005). A similar line of reasoning could apply to those with 'idiopathic' RBD, particularly once agents that may positively affect synuclein-based pathophysiology are developed—these therapies could potentially delay or prevent the development of cognitive impairment or parkinsonism. The lengthy time period between the onset of RBD and onset of parkinsonism and/or dementia, in which most studies have shown the duration can range from 5 to 40 years, suggests that the early window of opportunity for intervention may be even more potentially beneficial in delaying or preventing the motor and cognitive features (Boeve and Saper, 2006). In the absence of such treatments at present, longitudinal investigations into the

natural history of ‘idiopathic’ RBD are critical to prepare for future treatment trials (Boeve and Saper, 2006).

Decades of work on dopamine physiology, substantia nigra degeneration and the oxidative stress hypothesis have led to symptomatic therapies for PD, but complications of such therapies clearly occur. The cholinesterase inhibitors can improve cognition and neuropsychiatric features in patients with DLB and PD with dementia, but the cognitive decline ultimately progresses. No truly promising treatments for synucleinopathies have been developed to date, due in part to the prolonged focus on the motor aspects of PD (Ahlskog, 2005), and on the cognitive and neuropsychiatric aspects of DLB, in the waking state. It is to be hoped that this review will stimulate further work between sleep and neurodegenerative disease investigators to understand normal and abnormal sleep—particularly REM sleep behaviour disorder—which may provide insights into preventative or disease-altering approaches for therapy of synucleinopathies.

Acknowledgements

We are indebted to our colleagues with whom we work on the RBD/neurodegenerative disease association, namely Ann M. Schmeichel, Robert J. Ivnik, PhD, Ronald C. Petersen, PhD, MD, Keith A. Josephs, MD, Daniel A. Drubach, MD, Josephs Y. Matsumoto, MD, David S. Knopman, MD and Neill R. Graff-Radford, MBChB. We thank our staff at the Mayo Sleep Disorders Center and Mayo Alzheimer’s Disease Research Center for their evaluation and education/counselling for many of the patients and families included in this report. We particularly extend our gratitude to the patients and their families for participating in research on neurodegenerative disease, ageing, and REM sleep behaviour disorder. Supported by grants P50 AG16574, P50 NS40256, U01 AG06786, RO1 AG15866, RO1 AG23195, and the Robert H. and Clarice Smith and Abigail Van Buren Alzheimer’s Disease Research Program of the Mayo Foundation and by a grant from the German Research Council (DFG BR 317/17-2).

References

- Abbott A. Neuroscience: while you were sleeping. *Nature* 2005; 437: 1220–2.
- Ahlskog JE. Challenging conventional wisdom: the etiologic role of dopamine oxidative stress in Parkinson’s disease. *Mov Disord* 2005; 20: 271–82.
- Arai K, Kato N, Kashiwado K, Hattori T. Pure autonomic failure in association with human alpha-synucleinopathy. *Neurosci Lett* 2000; 296: 171–3.
- Arnulf I, Bonnet AM, Damier P, Bejjani BP, Seilhean D, Derenne JP, et al. Hallucinations, REM sleep, and Parkinson’s disease: a medical hypothesis. *Neurology* 2000; 55: 281–8.
- Arnulf I, Merino-Andreu M, Bloch F, Konofal E, Vidailhet M, Cohen V, et al. REM sleep behavior disorder and REM sleep without atonia in patients with progressive supranuclear palsy. *Sleep* 2005; 28: 349–54.
- Baker M, Mackenzie I, Pickering-Brown S, Gass J, Rademakers R, Lindholm C, et al. Mutations in progranulin cause tau-negative frontotemporal dementia linked to chromosome 17. *Nature* 2006; 442: 916–9.
- Bamford C. Carbamazepine in REM sleep behavior disorder. *Sleep* 1993; 16: 33–4.
- Benarroch EE, Schmeichel AM. Depletion of cholinergic mesopontine neurons in multiple system atrophy: a substrate for REM behavior disorder? *Neurology* 2002; 58 (Suppl 3): A345.
- Boeve BF, Silber MH, Ferman TJ, Kokmen E, Smith GE, Ivnik RJ, et al. REM sleep behavior disorder and degenerative dementia: an association likely reflecting Lewy body disease. *Neurology* 1998; 51: 363–70.
- Boeve B, Silber M, Ferman T. Current management of sleep disturbances in dementia. *Cur Neurol Neurosci Reports* 2001a; 2: 169–77.
- Boeve B, Silber M, Ferman T, Lucas J, Parisi J. Association of REM sleep behavior disorder and neurodegenerative disease may reflect an underlying synucleinopathy. *Mov Disord* 2001b; 16: 622–30.
- Boeve B, Silber M, Ferman T. Melatonin for treatment of REM sleep behavior disorder in neurologic disorders: results in 14 patients. *Sleep Med* 2003a; 4: 281–4.
- Boeve B, Silber M, Ferman T, Parisi J, Dickson D, Smith G, et al. REM sleep behavior disorder in Parkinson’s disease, dementia with Lewy bodies, and multiple system atrophy. In: Bedard M, Agid Y, Chouinard S, Fahn S, Korczyn A, Lesperance P, editors *Mental and behavioral dysfunction in movement disorders*. Totowa: Humana Press; 2003b. p. 383–97.
- Boeve B, Silber M, Parisi J, Dickson D, Ferman T, Benarroch E, et al. Synucleinopathy pathology and REM sleep behavior disorder plus dementia or parkinsonism. *Neurology* 2003c; 61: 40–5.
- Boeve B. Dementia with Lewy bodies. In: Peterson R, editor. *Continuum*. Vol. 10. Minneapolis: American Academy of Neurology; 2004. p. 81–112.
- Boeve B, Silber M, Ferman T. REM sleep behavior disorder in Parkinson’s disease and dementia with Lewy bodies. *J Ger Psychiatry Neurol* 2004; 17: 146–57.
- Boeve B, Lin S-C, Strongosky A, Dickson D, Wszolek Z. Absence of REM sleep behavior disorder in eleven members of the PPNd kindred. *Arch Neurol* 2006; 63: 268–72.
- Boeve B, Saper C. REM sleep behavior disorder: a possible early marker for synucleinopathies. *Neurology* 2006; 66: 796–7.
- Boeve B, Dickson D, Olson E, Shepard J, Silber M, Ferman T, et al. Insights into REM sleep behavior disorder pathophysiology in brainstem-predominant Lewy body disease. *Sleep Med* 2007; 8: 60–64.
- Boissard E, Fort P, Gervasoni D, Barbagli B, Luppi P. Localization of the GABAergic and non-GABAergic neurons projecting to the sublaterodorsal nucleus and potentially gating paradoxical sleep onset. *Eur J Neurosci* 2003; 18: 1627–39.
- Boissard R, Gervasoni D, Schmidt M, Barbagli B, Fort P, Luppi P. The rat ponto-medullary network responsible for paradoxical sleep onset and maintenance: a combined microinjection and functional neuroanatomical study. *Eur J Neurosci* 2002; 16: 1959–73.
- Braak H, Del Tredici K, Rub U, de Vos R, Jansen Steur E, Braak E. Staging of brain pathology related to sporadic Parkinson’s disease. *Neurobiol Aging* 2003; 24: 197–211.
- Braak H, Ghebremedhin E, Rub U, Bratzke H, Del Tredici K. Stages in the development of Parkinson’s disease-related pathology. *Cell Tissue Res* 2004; 318: 121–34.
- Caselli R, Chen K, Bandy D, Smilovici O, Boeve B, Osborne D, et al. A preliminary fluorodeoxyglucose positron emission tomography study in healthy adults reporting dream-enactment behavior. *Sleep* 2006; 29: 927–33.
- Coccagna G, Martinelli P, Zucconi M, Cirignotta F, Ambrosetto G. Sleep-related respiratory and haemodynamic changes in Shy-Drager syndrome: a case report. *J Neurol* 1985; 232: 310–13.
- Comella C, Nardine T, Diederich N, Stebbins G. Sleep-related violence, injury, and REM sleep behavior disorder in Parkinson’s disease. *Neurology* 1998; 51: 526–9.

- Dickson DW, Liu W, Hardy J, Farrer M, Mehta N, Uitti R, et al. Widespread alterations of alpha-synuclein in multiple system atrophy. *Am J Pathol* 1999; 155: 1241–51.
- Eisensehr I, Linke R, Noachtar S, Schwarz J, Gildehaus F, Tatsch K. Reduced striatal dopamine transporters in idiopathic rapid eye movement sleep behaviour disorder: comparison with Parkinson's disease and controls. *Brain* 2000; 123: 1155–60.
- Eisensehr I, Linke R, Tatsch K, Kharraz B, Gildehaus JF, Wetter CT, et al. Increased muscle activity during rapid eye movement sleep correlates with decrease of striatal presynaptic dopamine transporters. IPT and IBZM SPECT imaging in subclinical and clinically manifest idiopathic REM sleep behavior disorder, Parkinson's disease, and controls. *Sleep* 2003; 26: 507–12.
- Fantini M, Gagnon J-F, Filipini D, Montplaisir J. The effects of pramipexole in REM sleep behavior disorder. *Neurology* 2003a; 61: 1418–20.
- Fantini ML, Gagnon JF, Petit D, Rompre S, Decary A, Carrier J, et al. Slowing of electroencephalogram in rapid eye movement sleep behavior disorder. *Ann Neurol* 2003b; 53: 774–80.
- Fantini ML, Corona A, Clerici S, Ferini-Strambi L. Aggressive dream content without daytime aggressiveness in REM sleep behavior disorder. *Neurology* 2005; 65: 1010–5.
- Ferini-Strambi L, Di Gioia M, Castronovo V, Oldani A, Zucconi M, Cappa S. Neuropsychological assessment in idiopathic REM sleep behavior disorder (RBD): does the idiopathic form of RBD really exist? *Neurology* 2004; 62: 41–5.
- Ferini-Strambi L, Oldani A, Zucconi M, Smirne S. Cardiac autonomic activity during wakefulness and sleep in REM sleep behavior disorder. *Sleep* 1996; 19: 367–9.
- Ferman TJ, Boeve BF, Smith GE, Silber MH, Kokmen E, Petersen RC, et al. REM sleep behavior disorder and dementia: cognitive differences when compared with AD. *Neurology* 1999; 52: 951–7.
- Ferman T, Boeve B, Smith G, Silber M, Lucas J, Graff-Radford N, et al. Dementia with Lewy bodies may present as dementia with REM sleep behavior disorder without parkinsonism or hallucinations. *J Internat Neuropsychol Soc* 2002; 8: 907–14.
- Ferman T, Smith G, Boeve B, Ivnik R, Petersen R, Knopman D, et al. DLB fluctuations: specific features that reliably differentiate DLB from AD and normal aging. *Neurology* 2004; 62: 181–7.
- Ferman T, Smith G, Boeve B, Graff-Radford N, Lucas J, Knopman D, et al. Neuropsychological differentiation of dementia with Lewy bodies from normal aging and Alzheimer's disease. *Clin Neuropsychol* 2006; 20: 623–36.
- Friedman J. Presumed rapid eye movement behavior disorder in Machado-Joseph disease (spinocerebellar ataxia type 3). *Mov Disord* 2002; 17: 1350–3.
- Fukutake T, Shinotoh H, Nishino H, Ichikawa Y, Goto J, Kanazawa I, et al. Homozygous Machado-Joseph disease presenting as REM sleep behavior disorder and prominent psychiatric symptoms. *Eur J Neurol* 2002; 9: 97–100.
- Gagnon J-F, Medard M-A, Fantini M, Petit D, Panisset M, Rompre S, et al. REM sleep behavior disorder and REM sleep without atonia in Parkinson's disease. *Neurology* 2002; 59: 585–9.
- Gagnon JF, Petit D, Fantini M, Rompre S, Gauthier S, Panisset M, et al. REM sleep behavior disorder and REM sleep without atonia in probable Alzheimer disease. *Sleep* 2006a; 29: 1321–5.
- Gagnon J-F, Postuma R, Mazza S, Doyon J, Montplaisir J. Rapid-eye-movement sleep behaviour disorder and neurodegenerative diseases. *Lancet Neurol* 2006b; 5: 424–32.
- García-Borreguero D, Caminero A, de la Llave Y, Larrosa O, Barrio S, Granizo J, et al. Decreased phasic EMG activity during rapid eye movement sleep in treatment-naive Parkinson's disease: effects of treatment with levodopa and progression of illness. *Mov Disord* 2002; 17: 934–41.
- Gervasoni D, Peyron C, Rampon C, Barbagli B, Chouvet G, Urbain N, et al. Role and origin of the GABAergic innervation of dorsal raphe serotonergic neurons. *J Neurosci* 2000; 20: 4217–25.
- Hanoglu L, Ozer F, Meral H, Dincer A. Brainstem 1H-MR spectroscopy in patients with Parkinson's disease with REM sleep behavior disorder and IPD patients without dream enactment behavior. *Clin Neurol Neurosurg* 2006; 108: 129–34.
- Hardy J. Pathways to primary neurodegenerative disease. *Mayo Clin Proc* 1999; 74: 835–7.
- Hardy J, Gwinn-Hardy K. Neurodegenerative disease: a different view of diagnosis. *Molecular Med Today* 1999; 5: 514–7.
- Hendricks J, Morrison A, Mann G. Different behaviors during paradoxical sleep without atonia depend on pontine lesion site. *Brain Res* 1982; 239: 81–105.
- Husain AM, Miller PP, Carwile ST. REM sleep behavior disorder: potential relationship to post-traumatic stress disorder. *J Clin Neurophysiol* 2001; 18: 148–57.
- International classification of sleep disorders: diagnostic and coding manual, 2nd edn. Westchester, IL: American Academy of Sleep Medicine; 2005.
- Iranzo A, Santamaria J. Severe obstructive sleep apnea/hypopnea mimicking REM sleep behavior disorder. *Sleep* 2005; 28: 203–6.
- Iranzo A, Santamaria J, Rye DB, Valdeoriola F, Marti MJ, Munoz E, et al. Characteristics of idiopathic REM sleep behavior disorder and that associated with MSA and PD. *Neurology* 2005; 65: 247–52.
- Iranzo A, Graus F, Clover L, Morera J, Bruna J, Vilar C, et al. Rapid eye movement sleep behavior disorder and potassium channel antibody-associated limbic encephalitis. *Ann Neurol* 2006a; 59: 178–81.
- Iranzo A, Molinuevo J, Santamaria J, Serradell M, Marti M, Valdeoriola F, et al. Rapid-eye-movement sleep behaviour disorder as an early marker for a neurodegenerative disorder: a descriptive study. *Lancet Neurol* 2006b; 5: 572–7.
- Jicha G, Parisi J, Dickson D, Johnson K, Cha R, Ivnik R, et al. Neuropathologic outcome of mild cognitive impairment following progression to clinical dementia. *Arch Neurol* 2006; 63: 674–81.
- Jouvet M, Delorme F. Locus coeruleus et sommeil paradoxal. *C R Soc Biol* 1965; 159: 895–9.
- Kimura K, Tachibana N, Toshihiko A, Kimura J, Shibasaki H. Subclinical REM sleep behavior disorder in a patient with corticobasal degeneration. *Sleep* 1997; 20: 891–4.
- Kimura K, Tachibana N, Kohyama J, Otsuka Y, Fukazawa S, Waki R. A discrete pontine ischemic lesion could cause REM sleep behavior disorder. *Neurology* 2000; 55: 894–5.
- Kumru H, Santamaria J, Tolosa E, Valdeoriola F, Munoz E, Marti M, et al. Rapid eye movement sleep behavior disorder in parkinsonism with parkin mutations. *Ann Neurol* 2004; 56: 599–603.
- Kunz D, Bes F. Melatonin as a therapy in REM sleep behavior disorder patients: an open-labeled pilot study on the possible influence of melatonin on REM-sleep regulation. *Mov Disord* 1999; 14: 507–11.
- Kushida C, Bergmann BM, Rechtschaffen A. Sleep deprivation in the rat: IV. Paradoxical sleep deprivation. *Sleep* 1989; 12: 22–30.
- Lai Y, Siegel J. Medullary regions mediating atonia. *J Neurosci* 1988; 8: 4790–6.
- Lai Y, Siegel J. Muscle tone suppression and stepping produced by stimulation of midbrain and rostral pontine reticular formation. *J Neurosci* 1990; 10: 2727–34.
- Lai Y, Siegel J. Brainstem-mediated locomotion and myoclonic jerks. I. Neural substrates. *Brain Res* 1997a; 745: 257–64.
- Lai Y, Siegel J. Brainstem-mediated locomotion and myoclonic jerks. II. Pharmacological effects. *Brain Res* 1997b; 745: 265–70.
- Lu J, Bjorkum A, Xu M, Gaus S, Shiromani P, Saper C. Selective activation of the extended ventrolateral preoptic nucleus during rapid eye movement sleep. *J Neurosci* 2002; 22: 4568–76.
- Lu J, Sherman D, Devor M, Saper C. A putative flip-flop switch for control of REM sleep. *Nature* 2006; 441: 589–94.
- Mahowald M, Schenck C. REM sleep behavior disorder. In: Kryger M, Roth T, Dement W, editors. Principles and practice of sleep medicine. Philadelphia: WB Saunders; 2000. p. 724–41.

- Manni R, Morini R, Martignoni E, Pacchetti C, Micieli G, Tartara A. Nocturnal sleep in multisystem atrophy with autonomic failure: polygraphic findings in ten patients. *J Neurol* 1993; 240: 247–50.
- Massicotte-Marquez J, Carrier J, Decary A, Mathieu A, Vendette M, Petit D, et al. Slow-wave sleep and delta power in rapid eye movement sleep behavior disorder. *Ann Neurol* 2005; 57: 277–82.
- Massironi G, Galluzzi S, Frisoni G. Drug treatment of REM sleep behavior disorders in dementia with Lewy bodies. *Int Psychogeriatr* 2003; 15: 377–83.
- Mazza S, Soucy J, Gravel P, Michaud M, Postuma R, Massicotte J, et al. Assessing whole brain perfusion changes in REM sleep behavior disorder. *Neurology* 2006; 67: 1618–22.
- McKeith IG, Galasko D, Kosaka K, Perry EK, Dickson DW, Hansen LA, et al. Consensus guidelines for the clinical and pathologic diagnosis of dementia with Lewy bodies (DLB): report of the consortium on DLB international workshop. *Neurology* 1996; 47: 1113–24.
- McKeith I, Dickson D, Lowe J, Emre M, O'Brien J, Feldman H, et al. Dementia with Lewy bodies: diagnosis and management: third report of the DLB Consortium. *Neurology* 2005; 65: 1863–72.
- Morrison A. The pathophysiology of REM-sleep behavior disorder. *Sleep* 1998; 21: 446.
- National Sleep Disorders Research Plan: National Center on Sleep Disorders Research, 2003.
- Nightingale S, Orgill JC, Ebrahim IO, de Lacy SF, Agrawal S, Williams AJ. The association between narcolepsy and REM behavior disorder (RBD). *Sleep Med* 2005; 6: 253–8.
- Olson E, Boeve B, Silber M. Rapid eye movement sleep behavior disorder: demographic, clinical, and laboratory findings in 93 cases. *Brain* 2000; 123: 331–9.
- Onofrij M, Thomas A, D'Andreamatteo G, Iacono D, Luciano AL, Di Rollo A, et al. Incidence of RBD and hallucination in patients affected by Parkinson's disease: 8-year follow-up. *Neurol Sci* 2002; 23: S91–4.
- Onofrij M, Luciano AL, Iacono D, Thomas A, Stocchi F, Papola F, et al. HLA typing does not predict REM sleep behaviour disorder and hallucinations in Parkinson's disease. *Mov Disord* 2003a; 18: 337–40.
- Onofrij M, Luciano AL, Thomas A, Iacono D, D'Andreamatteo G. Mirtazapine induces REM sleep behavior disorder (RBD) in parkinsonism. *Neurology* 2003b; 60: 113–5.
- Ozekmekci S, Apaydin H, Kilic E. Clinical features of 35 patients with Parkinson's disease displaying REM behavior disorder. *Clin Neurol Neurosurg* 2005; 107: 306–9.
- Pacchetti C, Manni R, Zangaglia R, Mancini F, Marchioni E, Tassorelli C, et al. Relationship between hallucinations, delusions, and rapid eye movement sleep behavior disorder in Parkinson's disease. *Mov Disord* 2005; 20: 1439–48.
- Paraja J, Caminero A, Masa J, Dobato J. A first case of progressive supranuclear palsy and pre-clinical REM sleep behavior disorder presenting as inhibition of speech during wakefulness and somnoliquy with phasic muscle twitching during REM sleep. *Neurologia* 1996; 11: 304–6.
- Petersen RC, Smith GE, Ivnik RJ, Tangalos EG, Schaid DJ, Thibodeau SN, et al. Apolipoprotein E status as a predictor of the development of Alzheimer's disease in memory-impaired individuals. *JAMA* 1995; 273: 1274–8.
- Petersen R, Smith G, Waring S, Ivnik R, Tangalos E, Kokmen E. Mild cognitive impairment: Clinical characterization and outcome. *Arch Neurol* 1999; 56: 303–8.
- Petersen RC. Mild cognitive impairment: transition between aging and Alzheimer's disease. *Neurologia* 2000; 15: 93–101.
- Petersen R, Doody R, Kurz A, Mohs R, Morris J, Rabins P, et al. Current concepts in mild cognitive impairment. *Arch Neurol* 2001a; 58: 1985–92.
- Petersen R, Stevens J, Ganguli M, Tangalos E, Cummings J, DeKosky S. Practice parameter: early detection of dementia: mild cognitive impairment (an evidence-based review). *Neurology* 2001b; 56: 1133–42.
- Petersen R, Thomas R, Grundman M, Bennett D, Doody R, Ferris S, et al. Vitamin E and donepezil for the treatment of mild cognitive impairment. *N Engl J Med* 2005; 352: 2379–88.
- Petersen R, Parisi J, Dickson D, Johnson K, Knopman D, Boeve B, et al. Neuropathologic features of amnesic mild cognitive impairment. *Arch Neurol* 2006; 63: 665–72.
- Plazzi G, Corsini R, Provini F, Pierangeli G, Martinelli P, Montagna P, et al. REM sleep behavior disorder in multiple system atrophy. *Neurology* 1997; 48: 1094–7.
- Plazzi G, Montagna P. Remitting REM sleep behavior disorder as the initial sign of multiple sclerosis. *Sleep Med* 2002; 3: 437–9.
- Postuma R, Lang A, Massicotte-Marquez J, Montplaisir J. Potential early markers of Parkinson disease in idiopathic REM sleep behavior disorder. *Neurology* 2006; 66: 845–51.
- Pramstaller P, Schlossmacher M, Jacques T, Scaravilli F, Eskelson C, Pepivani I, et al. Lewy body Parkinson's disease in a large pedigree with 77 Parkin mutation carriers. *Ann Neurol* 2005; 58: 411–22.
- Provini F, Vetruigno R, Pastorelli F, Lombardi C, Plazzi G, Marliani A, et al. Status dissociatus after surgery for tegmental ponto-mesencephalic cavernoma: a state-dependent disorder of motor control during sleep. *Mov Disord* 2004; 19: 719–23.
- Quera Salva M, Guilleminault C. Olivopontocerebellar degeneration, abnormal sleep, and REM sleep without atonia. *Neurology* 1986; 36: 576–7.
- Ringman J, Simmons J. Treatment of REM sleep behavior disorder with donepezil: a report of three cases. *Neurology* 2000; 55: 870–1.
- Rye D. Contributions of the pedunculopontine region to normal and altered REM sleep. *Sleep* 1997; 20: 757–88.
- Rye D. The pathophysiology of REM-sleep behavior disorder. *Sleep* 1998; 21: 446–9.
- Rye D, Johnston L, Watts R, Bliwise D. Juvenile Parkinson's disease with REM sleep behavior disorder, sleepiness, and daytime REM onset. *Neurology* 1999; 53: 1868–72.
- Scaglione C, Vignatelli L, Plazzi G, Marchese R, Negrotti A, Rizzo G, et al. REM sleep behaviour disorder in Parkinson's disease: a questionnaire-based study. *Neurol Sci* 2005; 25: 316–21.
- Schenck CH, Bundlie SR, Ettinger MG, Mahowald MW. Chronic behavioral disorders of human REM sleep: a new category of parasomnia. *Sleep* 1986; 9: 293–308.
- Schenck CH, Bundlie SR, Patterson AL, Mahowald MW. Rapid eye movement sleep behavior disorder. A treatable parasomnia affecting older adults. *JAMA* 1987; 257: 1786–9.
- Schenck C, Milner D, Hurwitz T, Bundlie S, Mahowald M. A polysomnographic and clinical report on sleep-related injury in 100 adult patients. *Amer J Psychiatr* 1989; 146: 1166–73.
- Schenck C, Mahowald M. A polysomnographic, neurologic, psychiatric and clinical outcome report on 70 consecutive cases with REM sleep behavior disorder (RBD): sustained clonazepam efficacy in 89.5% of 57 treated patients. *Clev Clin J Med* 1990; 57 (Suppl): 10–24.
- Schenck C, Mahowald M. Motor dyscontrol in narcolepsy: rapid-eye-movement (REM) sleep without atonia and REM sleep behavior disorder. *Ann Neurol* 1992; 32: 3–10.
- Schenck CH, Bundlie SR, Mahowald MW. Delayed emergence of a parkinsonian disorder in 38% of 29 older men initially diagnosed with idiopathic rapid eye movement sleep behaviour disorder. *Neurology* 1996a; 46: 388–93.
- Schenck CH, Garcia-Rill E, Skinner RD, Anderson ML, Mahowald MW. A case of REM sleep behavior disorder with autopsy-confirmed Alzheimer's disease: postmortem brain stem histochemical analyses. *Biol Psychiatry* 1996b; 40: 422–5.
- Schenck CH, Mahowald MW, Anderson ML, Silber MH, Boeve BF, Parisi JE. Lewy body variant of Alzheimer's disease (AD) identified by postmortem ubiquitin staining in a previously reported case of AD associated with REM sleep behavior disorder [letter]. *Biol Psychiatry* 1997; 42: 527–8.

- Schenck C, Mahowald M. REM sleep behavior disorder: clinical, developmental, and neuroscience perspectives 16 years after its formal identification in SLEEP. *Sleep* 2002; 25: 120–38.
- Schenck C, Bundlie S, Mahowald M. REM behavior disorder (RBD): delayed emergence of parkinsonism and/or dementia in 65% of older men initially diagnosed with idiopathic RBD, and an analysis of the minimum & maximum tonic and/or phasic electromyographic abnormalities found during REM sleep. *Sleep* 2003; 26: A316.
- Sforza E, Krieger J, Petiau C. REM sleep behavior disorder: clinical and physiopathological findings. *Sleep Med Rev* 1997; 1: 57–69.
- Shouse M, Siegel J. Pontine regulation of REM sleep components in cats: integrity of the pedunculopontine tegmentum (PPT) is important for phasic events but unnecessary for atonia during REM sleep. *Brain Res* 1992; 571: 50–63.
- Siegel J. The stuff dreams are made of: anatomical substrates of REM sleep. *Nature Neurosci* 2006; 9: 721–2.
- Silber M, Ahlsgog J. REM sleep behavior disorder in parkinsonian syndromes. *Sleep Res* 1992; 21: 313.
- Silber M, Dexter D, Ahlsgog J, Hauri P, Shepard J. Abnormal REM sleep motor activity in untreated Parkinson's disease. *Sleep Res* 1993; 22: 274.
- Sinforiani E, Zangaglia R, Manni R, Cristina S, Marchioni E, Nappi G, et al. REM sleep behavior disorder, hallucinations, and cognitive impairment in Parkinson's disease. *Mov Disord* 2006; 21: 462–6.
- Spillantini M, Crowther R, Jakes R, Cairns N, Lantos P, Goedert M. Filamentous alpha-synuclein inclusions link multiple system atrophy with Parkinson's disease and dementia with Lewy bodies. *Neurosci Lett* 1998; 251: 205–8.
- Stiasny-Kolster K, Doerr Y, Möller J, Höffken H, Behr T, Oertel W, et al. Combination of 'idiopathic' REM sleep behaviour disorder and olfactory dysfunction as possible indicator for -synucleinopathy demonstrated by dopamine transporter FP-CIT-SPECT. *Brain* 2005; 128: 126–37.
- Stolz S, Aldrich M. REM sleep behavior disorder associated with caffeine abuse. *Sleep Res Online* 1991; 20: 341.
- Tachibana N, Kimura K, Kitajima K, Shinde A, Kimura J, Shibasaki H. REM sleep motor dysfunction in multiple system atrophy: with special emphasis on sleep talk as its early clinical manifestation. *J Neurol Neurosurg Psychiatry* 1997; 63: 678–81.
- Tachibana N, Oka Y. Longitudinal change in REM sleep components in a patient with multiple system atrophy associated with REM sleep behavior disorder: paradoxical improvement of nocturnal behaviors in a progressive neurodegenerative disease. *Sleep Med* 2004; 5: 155–8.
- Takeuchi N, Uchimura N, Hashizume Y, Mukai M, Etoh Y, Yamamoto K, et al. Melatonin therapy for REM sleep behavior disorder. *Psychiat Clin Neurosci* 2001; 55: 267–9.
- Tan A, Salgado M, Fahn S. Rapid eye movement sleep behavior disorder preceding Parkinson's disease with therapeutic response to levodopa. *Mov Disord* 1996; 11: 214–6.
- Tippmann-Peikert M, Boeve B, Keegan B. REM sleep behavior disorder initiated by acute brainstem multiple sclerosis. *Neurology* 2006a; 66: 1277–9.
- Tippmann-Peikert M, Olson E, Boeve B, Silber M. Idiopathic REM sleep behavior disorder - a follow-up of 39 patients. *Sleep* 2006b; 29: A272.
- Tison F, Wenning G, Quinn N, Smith S. REM sleep behavior disorder as the presenting symptom of multiple system atrophy. *J Neurol Neurosurg Psychiatry* 1995; 58: 379–80.
- Turner R, D'Amato C, Chervin R, Blaivas M. The pathology of REM sleep behavior disorder with comorbid Lewy body dementia. *Neurology* 2000; 55: 1730–2.
- Turner RS, Chervin RD, Frey KA, Minoshima S, Kuhl DE. Probable diffuse Lewy body disease presenting as REM sleep behavior disorder. *Neurology* 1997; 49: 523–7.
- Uchiyama M, Isse K, Tanaka K, Yokota N, Hamamoto H, Aida S, et al. Incidental Lewy body disease in a patient with REM sleep behavior disorder. *Neurology* 1995; 45: 709–12.
- Vorona R, Ware J. Exacerbation of REM sleep behavior disorder by chocolate ingestion: a case report. *Sleep Med* 2002; 3: 365–7.
- Weyer A, Minnerop M, Abele M, Klockgether T. REM sleep behavioral disorder in pure autonomic failure (PAF). *Neurology* 2006; 66: 608–9.
- Winkelman J, James L. Serotonergic antidepressants are associated with REM sleep without atonia. *Sleep* 2004; 15: 317–21.
- Wright B, Rosen J, Buysse D, Reynolds C, Zubenko G. Shy-Drager syndrome presenting as a REM behavioral disorder. *J Geriatr Psychiatry Neurol* 1990; 3: 110–3.
- Yamouchi K, Takehisa M, Tsuno M, Kaneda Y, Taniguchi T, Ohno H, et al. Levodopa improved rapid eye movement sleep behavior disorder with diffuse Lewy body disease. *Gen Hosp Psychiatry* 2003; 25: 136–44.
- Zambelis T, Paparrigopoulos T, Soldatos CR. REM sleep behaviour disorder associated with a neurinoma of the left pontocerebellar angle. *J Neurol Neurosurg Psychiatry* 2002; 72: 821–22.