

Diagnostic Value of 64-Slice Dual-Source CT Coronary Angiography in Patients with Atrial Fibrillation: Comparison with Invasive Coronary Angiography

Jian-Jun Zhang, MD, Tie Liu, MD, Yue Feng, MD, Wei-Feng Wu, MS, Cai-Yun Mou, MS, Li-Hao Zhai, MS

All authors: Department of Radiology, Zhejiang Hospital, Zhejiang Province, 310013, China

Objective: We wanted to evaluate the image quality and diagnostic value of 64-slice dual-source computed tomography (DSCT) coronary angiography in patients with atrial fibrillation (Afib).

Materials and Methods: The coronary arteries of 22 Afib patients seen on DSCT were classified into 15 segments and the imaging quality (excellent, good, moderate and poor) and significant stenoses ($\geq 50\%$) were evaluated by two radiologists who were blinded to the conventional coronary angiography (CAG) results. The sensitivity, specificity, positive predictive value (PPV) and negative predictive value (NPV) for detecting important coronary artery stenosis were calculated. McNemar test was used to determine any significant difference between DSCT and CAG, and Cohen's Kappa statistics were calculated for the intermodality and interobserver agreement.

Results: The mean heart rate was 89 ± 8.3 bpm (range: 80-118 bpm). A range from 250 msec to 300 msec within the RR interval was the optimal reconstruction interval for the patients with Afib. The respective overall sensitivity, specificity, PPV and NPV values were 74%, 97%, 81% and 96% for reader 1 and 72%, 98%, 85% and 96% for reader 2. No significant difference between DSCT and CAG was found for detecting a significant stenosis (reader 1, $p = 1.0$; reader 2, $p = 0.727$). Cohen's Kappa statistics demonstrated good intermodality and interobserver agreement.

Conclusion: 64-slice DSCT coronary angiography provides good image quality in patients with atrial fibrillation without the need for controlling the heart rate. DSCT can be used for ruling out significant stenosis in patients with atrial fibrillation with its high NPV for detecting in important stenosis.

Index terms: CT; Coronary angiography; Atrial fibrillation; Coronary artery

INTRODUCTION

The main challenge of noninvasive imaging of the coronary arteries is the motion-free depiction of the coronary arteries and the vessel wall. With the recent

developments of CT coronary angiography (CTCA), improved sensitivity and a higher negative predictive value have been achieved for the detection of coronary artery stenosis (1-3).

One of the major drawbacks regarding the use of multidetector computed tomography (MDCT) in cardiac imaging has been the limited temporal resolution (1, 2). In most standard protocols of CT angiography, including those with using 64-section multidetector CT scanners, β -blocker administration is routinely used to reduce the heart rate and this minimizes the residual heart motion (3-7).

Atrial fibrillation (Afib) remains a contraindication for CTCA owing to the high heart rate and between-beat variation, which leads to inappropriate data sampling that results in significant motion artifact (3-6). With the newly introduced dual-source CT (DSCT), the main improvement

Received December 24, 2010; accepted after revision March 14, 2011.

Corresponding author: Jian-Jun Zhang, MD, Department of Radiology, Zhejiang Hospital, Linying Road 12th of Hangzhou, Zhejiang Province, 311113, China.

• Tel: (86) 0571 87987373 • Fax: (86) 13735882084

• E-mail: zhangyp31113@163.com

This is an Open Access article distributed under the terms of the Creative Commons Attribution Non-Commercial License (<http://creativecommons.org/licenses/by-nc/3.0>) which permits unrestricted non-commercial use, distribution, and reproduction in any medium, provided the original work is properly cited.

has been an increase in temporal resolution. The system combines two arrays, each consisting of an X-ray tube and a 64-section detector. With a rotation speed of 330 msec, a temporal resolution of 83 msec (one-fourth rotation) can be achieved, which is independent of heart rate (8). This higher temporal resolution is expected to decrease motion artifacts in patients with Afib (9, 10). The aim of this study was to assess the diagnostic accuracy of DSCT in patients with Afib as compared to the diagnostic accuracy of invasive angiography in a cohort of symptomatic Afib patients.

MATERIALS AND METHODS

Patients

From October 2007 to September 2009, we prospectively enrolled 22 consecutive Afib patients who were undergoing CTCA (M:F = 14:8; mean age \pm standard deviation, 72.1 \pm 8.3 years; age range, 53-89 years) and their mean heart rate (HR) was > 80 bpm. The patients' mean body mass index (BMI) was 22.5 \pm 3.7 (range, 12.6-27.2). Most of the patients were suspected of having coexistent coronary artery disease (CAD). The characteristics of the patient are listed in Table 1. All patients gave their written informed consent prior to participation in the study and the study was approved by our institutional review board.

The indications for CTCA were suspected CAD (n = 18) and the exclusion of CAD before radiofrequency catheter ablation (n = 4). The exclusion criteria for CT were as follows: an

unstable clinical condition, previous allergy to iodinated contrast agents, elevated serum creatinine levels > 1.5 mg/dL or > 132.6 μ mol/L, and failure to follow breath-hold commands. The mean time interval between CTCA and CAG was 1 \pm 9 days.

CT Coronary Angiography: Scan Protocol, Echocardiography-Editing and Reconstruction

All CT examinations were performed using a DSCT scanner (Somatom Definition, Siemens Healthcare, Forchheim, Germany). The CT scans were obtained with collimation in 64 sections of 0.6-mm thickness, a rotation time of 0.33 sec, the tube voltage was 120 kV, the effective charge was 450 mAs and the pitch was 0.25-0.5 (depending on the heart rate). The scan time was between 5 and 9 seconds for a single breath hold and the scan was performed in the craniocaudal direction. The patients did not receive any additional drugs for regulating the heart rate prior to the CT examination.

Coronary angiography scans were started by continuously injecting a bolus of Ultravist (370 mgI/mL; Bayer Schering Pharma, Berlin, Germany) and the volume of contrast material was adapted to the patient's body weight, and then this was followed by injecting 50 mL of saline solution into an antecubital vein via an 18-gauge catheter (injection rate, 5 mL/s). Contrast agent application was controlled by a bolus tracking technique. A region of interest was placed in the aortic root, and image acquisition was started 5s after the attenuation reached the predefined threshold of 100 Hounsfield units.

During the scan, the electrocardiography was recorded simultaneously. A monosegment reconstruction algorithm that used the data from a quarter rotation of both detectors was employed for image reconstruction (8). The raw data of the 22 patients was reconstructed in RR intervals by echocardiography (ECG) editing: step 1) the multiphases were reconstructed first and most of patients obtain a satisfactory phase, and if there was no satisfactory phase to be chosen, then step 2) the relatively good phase was edited (delete, insert, disable and R-shift).

The retrospective reconstructions were done during all cardiac phases at 50-msec intervals. For the reconstruction of transverse images, we used a section thickness of 0.75 mm and a section width of 0.5 mm; medium soft-tissue reconstruction kernels (B26f) were used. The reconstruction interval with the fewest motion artifacts was chosen and used for further analysis.

Table 1. Patient Characteristics

Parameter	Datum
Male/Female, n	14/8
Mean age, years	72.1 \pm 8.3
Body-mass index, kg/m ²	22.5 \pm 3.7
Mean heart rate, bpm	89 \pm 13
Clinical data	
Smoking, n	12
Hypertension, n	19
Diabetes, n	12
Atypical chest pain, n	15
Inconclusive stress test results, n	10
DLP (mGy \times cm)	618.81 \pm 230
CTDI _{vol}	43.57 \pm 17.3
Effective radiation dose, mSv	8.7 \pm 4.6

Note.— CTDI_{vol} = volume CT dose index, DLP = dose length product, n = number

Conventional X-Ray Coronary Angiography

All coronary angiography examinations were performed using a Philips H5000 machine (Philips Medical Systems, The Netherlands) and the eRad PACS software system (Philips Medical Systems). The invasive coronary angiography was evaluated by performing quantitative coronary angiography (QCA), and this was done by a cardiologist with 10 years coronary angiography experience and who was unaware of any of the previous CTCA findings. All stenoses were graded in two projections according to the densitometrical analysis of the QCA software and their locations were recorded according to the 15-segment coronary artery model of the American Heart Association (AHA) (11).

CT Coronary Angiography: Image Analysis

Using a double blind method, two senior radiologists who were experienced in cardiovascular CT analyzed the image quality independently. The AHA 15-segment classification was applied equally the same as in conventional coronary angiography (CAG) (12). Image quality was evaluated qualitatively for each coronary artery segment by using a four-point grading system: grade 1 = excellent, no motion artifacts, clear delineation of the segment, grade 2 = good with minor artifacts, mild blurring of the segment, grade 3 = adequate with moderate artifacts, moderate blurring without structure discontinuity and allowing the exclusion of significant stenosis, but limited for assessing nonstenotic noncalcified plaques, and grade 4 = nondiagnostic with doubling or discontinuity in the course of the segment that prevented diagnostic evaluation. Grades 1-3 were considered diagnostic. Disagreements between the readers were resolved by means of a final consensus reading. The images were evaluated for the presence of significant stenosis. The same as the diagnostic standard of CAG, a significant stenosis was defined as a narrowing of the coronary lumen exceeding 50% of the cross-sectional area, and the segments proximal and distal to the stenosis were used as a reference. All vessel segments with a diameter more than 2 mm were included in the analysis. Diseased segments with less than 50% narrowing were not considered as positive results.

Effective Dose Calculation

For each patient, the volume CT dose index ($CTDI_{vol}$) and the dose length product (DLP) were obtained from the patient protocol of the scanner. The effective dose of CTCA was derived from the product of DLP ($mGy \times cm$) and a

conversion factor of 0.014 for chest CT. The CARE Dose4D (Siemens Medical Solutions, Forchheim, Germany) was used for reducing the radiation dose. This technique allows a dose reduction, and it uses tube current modulation during the scan according to the patient's topogram and the diameter of the scan area (13).

Statistical Analysis

Statistical analysis was performed using statistical software (SPSS, version 12.0 for Windows). The sensitivity, specificity, positive predictive value (PPV) and negative predictive value (NPV) were calculated. These diagnostic parameters were expressed with a 95% confidence interval (CI). CAG was regarded as the standard of reference.

The McNemar test was used to search for significant differences between CTCA and CAG to help detect significant stenosis. A *p* value of less than 0.05 was considered statistically significant. Cohen's Kappa was calculated to quantify the inter-rater agreement. Kappa values less than 0.20 were interpreted as poor agreement, 0.21-0.40 as fair agreement, 0.41-0.60 as moderate, 0.61-0.80 as good and 0.81-1.00 as very good agreement.

RESULTS

Conventional Coronary Angiography

A total of 302 vessel segments were analyzed. In 39 (13%) of 302 segments, a diameter reduction of 50% or greater was found on CAG (Fig. 1). One total occlusion was observed in the middle segment of the right coronary artery (RCA) in one patient. The other 263 (87%) segments were found to be normal.

Dual-Source CT Angiography

The mean HR was 89 ± 8.3 bpm (range: 80-118 bpm). For all CT angiography images, the reconstructions were done in the RR intervals with the absolute intervals in milliseconds. In our study, most of images of the segments were of good image quality during systole (Figs. 1, 2). In 12 patients of the study group, 250 msec was the time interval with the fewest artifacts. In addition, a 200 msec interval was reconstructed in one patient, a 220 msec interval was reconstructed in one patient, a 240 msec interval was reconstructed in two patients, a 280 msec interval was reconstructed in two patients and a 300 msec interval was reconstructed in four patients (Fig. 3). Both readers used the same data sets for their evaluations.

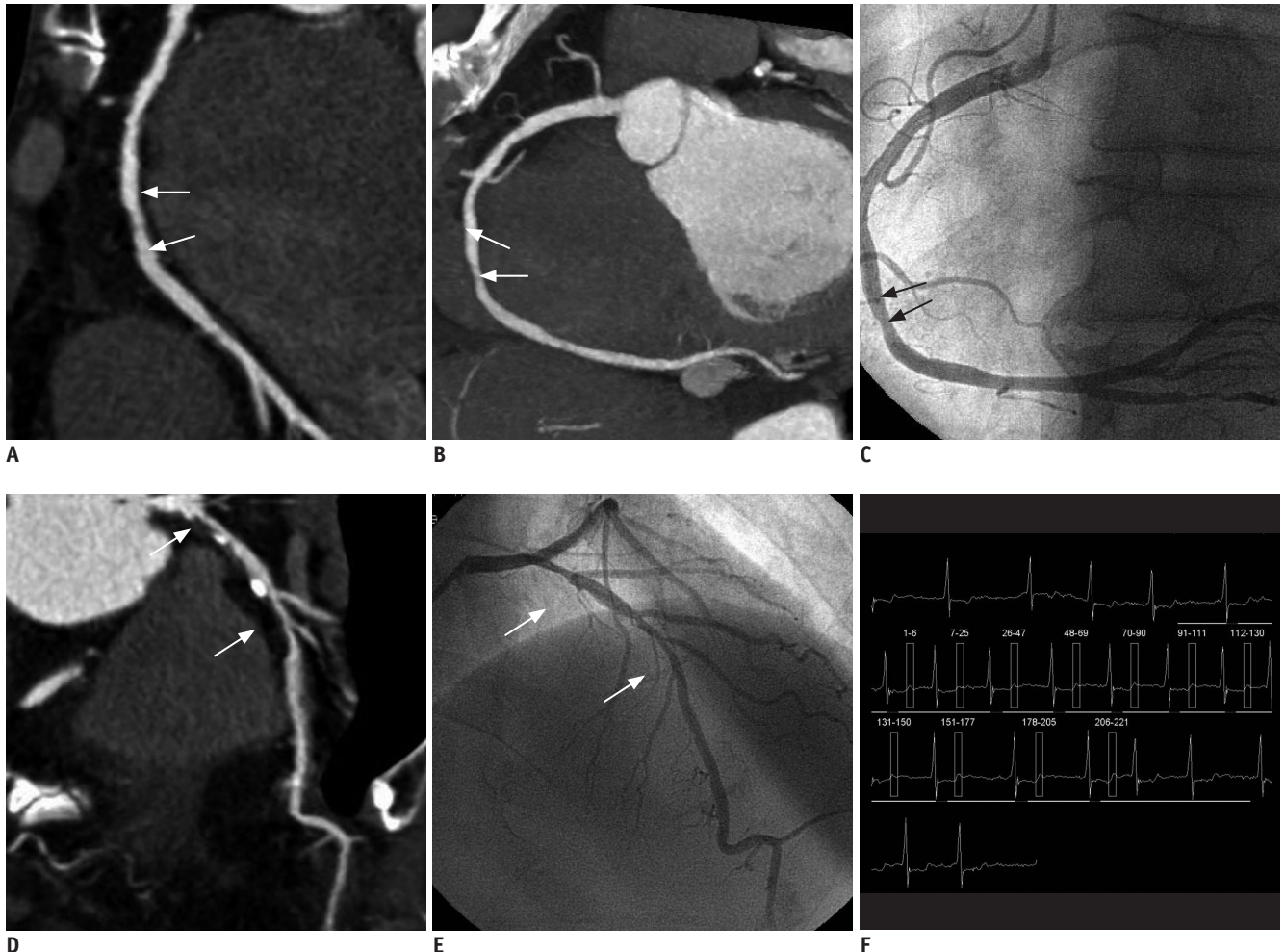


Fig. 1. CT angiography of 86-year-old man with atrial fibrillation (mean heart rate: 93 bpm, range: 66-143 bpm).

A, B. Curved multiplanar image (A) and maximum intensity projection image (B) showing two slight stenoses in right coronary artery segments 1 and 2 (arrows). **C.** Invasive angiography confirms these two lesions (arrows). **D.** Curved multiplanar image showing moderate stenosis and accompanying atherosclerotic lesions in left anterior descending artery segments 6 and 7 (arrows). **E.** Invasive angiography of left anterior descending artery confirms lesions (arrows). **F.** Echocardiography is shown (reconstruction at 250 ms of cardiac cycle).

The mean scan time was 7.45 ± 3.87 seconds (range: 6.4-10.3 seconds). The mean scan pitch was 0.4 ± 0.08 (range: 0.25-0.45). The effective radiation dose was 8.7 ± 4.6 mSv (range: 6.25-13.5 mSv) (Table 1). In 22 patients, a total of 302 segments were evaluated for image quality with respect to visible vessels and existing artifacts. Reader 1 evaluated 91 (30%) segments as excellent, 120 (40%) as good, 81 (27%) as moderate and 10 (3%) as nondiagnostic; reader 2 evaluated 69 (23%) segments as excellent, 134 (44%) as good, 91 (30%) as moderate and eight (3%) as nondiagnostic (Table 2). The nondiagnostic segments were not considered for further analysis.

Motion artifacts resulted in blurred or doubled vessel contours. Most motion artifacts affected the middle section of the RCA and the left circumflex coronary artery (LCx).

The left main coronary artery and proximal left anterior descending artery (LAD) were the least affected segments and they had the best image quality. Reader 1 evaluated 10 segments as nondiagnostic, including three of the RCA, five of the LCx and two of the LAD, and reader 2 evaluated eight segments as nondiagnostic, including five of the RCA, two of the LCx and one of the LAD.

The overall sensitivity, specificity, PPV and NPV for each reader were, respectively, for reader 1: 74% (29 of 39, 95% CI: 60%, 88%), 97% (246 of 253, 95% CI: 95%, 99%), 81% (29 of 36, 95% CI: 75%, 87%) and 96% (246 of 256, 95% CI: 94%, 98%) and for reader 2: 72% (28 of 39, 95% CI: 58%, 86%); 98% (249 of 255, 95% CI: 96%, 100%); 85% (28 of 34, 95% CI: 73%, 97%) and 96% (249 of 260, 95% CI: 94%, 98%) (Table 3).

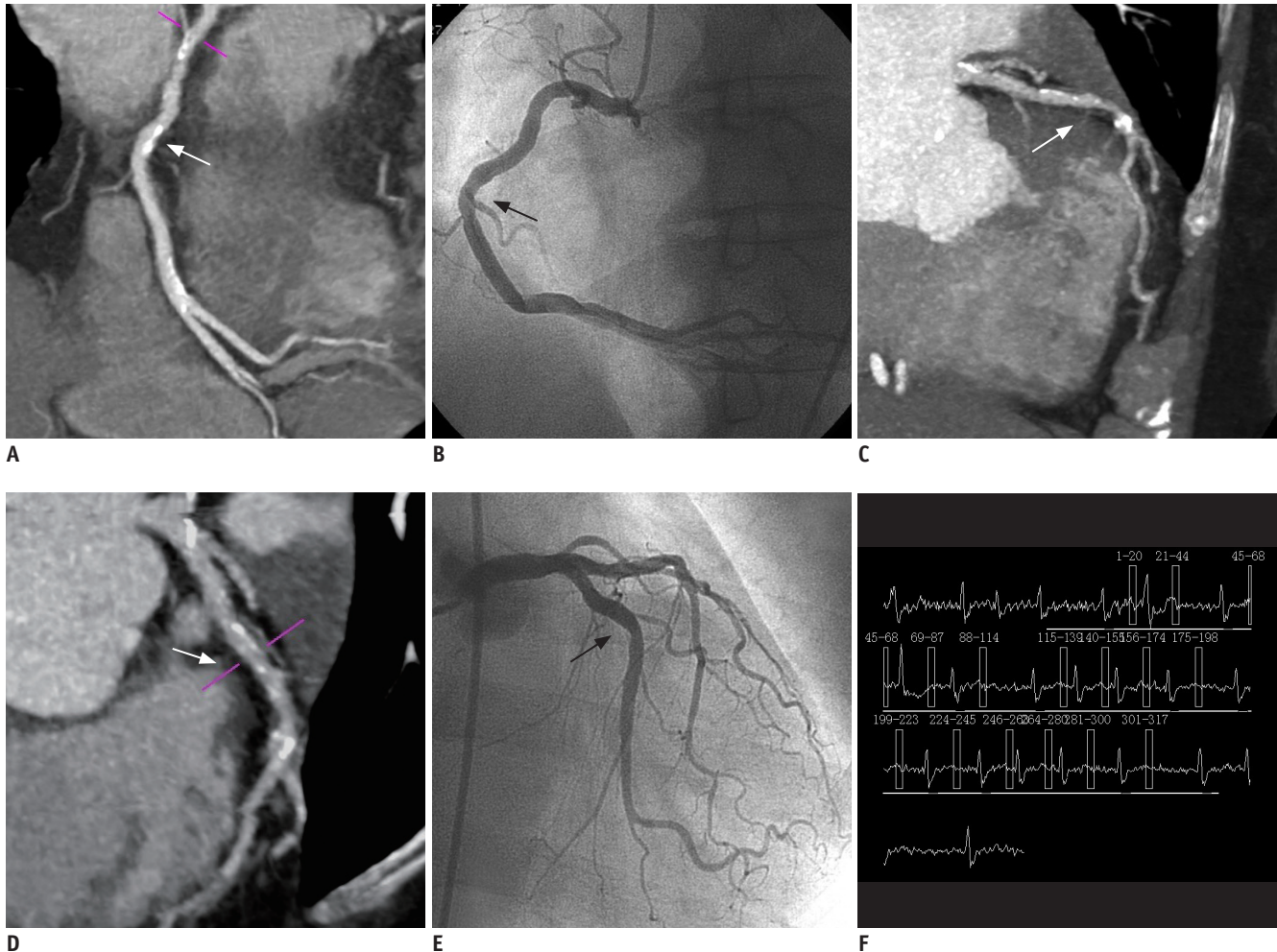


Fig. 2. CT angiography of 70-year-old woman with atrial fibrillation (mean heart rate: 87 bpm, range: 60-125 bpm). **A.** Curved multiplanar image showing slight stenosis in right coronary artery segment 1 (arrow). **B.** Invasive angiography of right coronary artery confirms presence (arrow) of mild lesion. **C, D.** Maximum intensity projection image (**C**) and curved multiplanar image (**D**) showing slight stenosis and accompanying atherosclerotic lesions in left anterior descending artery segment 7 (arrows). **E.** Invasive angiography confirms presence of lesion (arrow). **F.** Echocardiography is shown (reconstruction at 300 ms of cardiac cycle).

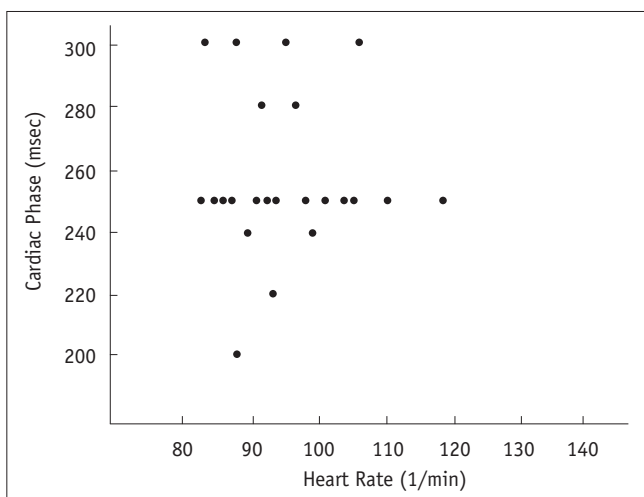


Fig. 3. Relationship between heart rate and cardiac phase that provided for optimal image quality.

With the McNemar test, no significant difference between DSCT angiography and conventional coronary angiography was found for detecting significant stenosis (reader 1, $p = 1.0$ and reader 2, $p = 0.727$).

Additionally, the k statistics demonstrated good intermodality agreement between the readers (reader 1, $k = 0.78$ and reader 2, $k = 0.687$).

The interobserver agreement for detecting significant stenoses was calculated as $k = 0.755$, which corresponds to good agreement.

DISCUSSION

The retrospective electrocardiographically gated technique and ECG-editing software were applied in our study. We

obtained good quality images for our reconstructions after ECG-editing. Reader 1 evaluated 10 (4%) segments as nondiagnostic, including three segments of the RCA, five segments of the LCX and two segments of the LAD, and reader 2 evaluated eight (3%) segments as nondiagnostic, including five segments of the RCA, two segments of the LCX and one segment of the LAD. We found that the middle sections of the RCA and the distal segments of the LCX were the most affected segments. Pasricha et al. (14) reported that the distal circumflex artery (segment 15) was the segment that most frequently had a significant variation in the quality score that required consensus analysis, and their evaluation was conducted on the single-source 320-MDCT. The left main coronary artery and proximal LAD were the least affected segments with the highest image quality due to their horizontal course and least amount of movement

at end-systole of each cardiac cycle. Variations in the duration of the individual R-R cycle, which cause severe motion artifacts, are the main reasons for impaired image quality in patients with Afib. The variation in the R-R cycle of Afib patients affects the duration of the diastolic phase more severely than the duration of the systolic phase. This resulted in superior reconstructed image quality at end-systole rather than those reconstructed at mid diastole in the R-R interval. This was also the reason that absolute intervals were preferred for reconstructions instead of relative intervals (15, 16). We found that the 250 msec-300 msec interval was the optimal reconstruction interval for the assessment of Afib patients with a rapid ventricular rate (17).

With faster heart rates, the optimal window for image reconstruction becomes more difficult to predict and this frequently occurs during the end-systolic phase of total myocardial contraction (18-21). For Afib with a rapid ventricular rate, the heart rate-adaptive table feed settings help decrease the patient's radiation dose to some extent by shortening the acquisition time. This property not only helped obtain better motion-free images, but it also decreases the radiation dose at high heart rates (9, 10, 22). The effective radiation dose in our patient cohort was 8.7 ± 4.6 mSv, which is lower than the mean effective radiation dose reported by Pasricha et al. (14) (19.28 mSv), Oncel et al. (15) (13.8 mSv) and Rist et al. (16) (13.28 mSv). This

Table 2. Grading of Image Quality of Dual Source CT Coronary Angiography

Image Quality	Reader 1	Reader 2
Excellent (grade 1)	91 (30)	69 (23)
Good (grade 2)	120 (40)	134 (44)
Adequate (grade 3)	81 (27)	91 (30)
Nondiagnostic (grade 4)	10 (3)	8 (3)
Total	302	302

Note.— Numbers represent graded coronary segments. Numbers in parentheses are percentages.

Table 3. Effectiveness of Dual Source CT for Demonstrating Coronary Artery Stenosis in Patients with Atrial Fibrillation

Analysis and Reader No.	Sensitivity (%)	Specificity (%)	PPV (%)	NPV (%)
Per segment (n = 292)				
Reader 1	74 (29/39) [60, 88]	97 (246/253) [95, 99]	81 (29/36) [75, 87]	96 (246/256) [94, 98]
Reader 2	72 (28/39) [58, 86]	98 (249/255) [96, 100]	85 (28/34) [73, 97]	96 (249/260) [94, 98]
Per vessel (n = 88)				
Reader 1	85 (17/20) [69, 100]	96 (65/68) [91, 100]	85 (17/20) [69, 100]	96 (65/68) [91, 100]
Reader 2	75 (15/20) [56, 94]	96 (65/68) [91, 100]	83 (15/18) [66, 100]	93 (65/70) [87, 99]
Per patient (n = 22)				
Reader 1	100 (13/13)	89 (8/9) [61, 100]	93 (13/14) [61, 100]	100 (8/8)
Reader 2	92 (11/12) [77, 100]	80 (8/10) [55, 100]	85 (11/13) [66, 100]	89 (8/9) [69, 100]

Note.— Numbers in parentheses are evaluated segments. Numbers in square brackets are 95% confidence intervals. NPV = negative predictive value, PPV = positive predictive value

can be explained by the lower BMI of Asians and the higher mean HR, resulting in a lower radiation dose.

In our study, the sensitivity was relatively lower (74% for reader 1, 72% for reader 2, on a per-segment basis) for the detection of significant stenosis than the other recently reported sensitivities. Rist et al. (16) reported a sensitivity of 90%/89% on a per-patient/per-segment basis, and Marwan et al. (17) reported a sensitivity of 100%/95% on a per-patient/per-artery basis (16, 17). The main cause for the lower sensitivity in our study was the mean HR (89 ± 8.3 bpm) in our study was higher than that of other reports. Although most of the reconstructed images were considered diagnostic, some distal segments of the RCA and LCX could be evaluated as false negatives. When the mean heart rate was more than 110 bpm, the image quality was decreased due to motion artifact in our study. We suggest β -blockers should be given before DSCT if the mean heart rate remains > 100 bpm at the time of scanning. Wang et al. (23) reported that the number of assessable segments for DSCT in Afib patients is still somewhat less than that in non-Afib patients. Rixe et al. (24) suggested that multi-segment reconstruction techniques should be taken into account when using retrospective ECG gating in patients with higher heart rates. Although the sensitivity was relatively low in our study, the major strength of the technique is its very high NPV that allows for the accurate exclusion of coronary significant stenosis.

Our study had several limitations. On one hand, the amount of radiation exposure is an important issue in CTCA. Although the heart rate-adaptive table feed settings helped decrease the patient dose, to some extent, by shortening the acquisition time, the radiation dose is still higher compared to other techniques such as prospective ECG triggering. In addition, multi-segment reconstruction was not used in our study to optimize image quality at even higher heart rates. Finally, a larger study sample and a multicenter study will be needed to determine if our results are reproducible.

In conclusion, DSCT provides better temporal resolution and it minimizes motion artifacts, which allows for coronary angiography at higher heart rates such as in Afib patients who have a rapid ventricular rate. DSCT has the potential to make noninvasive coronary angiography effective in a larger number of patients with a wider spectrum of clinical conditions, as compared with the older scanners. Further studies with larger patient samples are needed to confirm our results.

REFERENCES

- Schoepf UJ, Becker CR, Ohnesorge BM, Yucel EK. CT of coronary artery disease. *Radiology* 2004;232:18-37
- Schoenhagen P, Halliburton SS, Stillman AE, Kuzmiak SA, Nissen SE, Tuzcu EM, et al. Noninvasive imaging of coronary arteries: current and future role of multi-detector row CT. *Radiology* 2004;232:7-17
- Raff GL, Gallagher MJ, O'Neill WW, Goldstein JA. Diagnostic accuracy of noninvasive coronary angiography using 64-slice spiral computed tomography. *J Am Coll Cardiol* 2005;46:552-557
- Sun Z, Jiang W. Diagnostic value of multislice computed tomography angiography in coronary artery disease: a meta-analysis. *Eur J Radiol* 2006;60:279-286
- Heuschmid M, Kuettner A, Schroeder S, Trabold T, Feyer A, Seemann MD, et al. ECG-gated 16-MDCT of the coronary arteries: assessment of image quality and accuracy in detecting stenoses. *AJR Am J Roentgenol* 2005;184:1413-1419
- Pugliese F, Mollet NR, Runza G, van Mieghem C, Meijboom WB, Malagutti P, et al. Diagnostic accuracy of non-invasive 64-slice CT coronary angiography in patients with stable angina pectoris. *Eur Radiol* 2006;16:575-582
- Ha EJ, Kim Y, Cheung JY, Shim SS. Coronary artery disease in asymptomatic young adults: its prevalence according to coronary artery disease risk stratification and the CT characteristics. *Korean J Radiol* 2010;11:425-432
- Flohr TG, McCollough CH, Bruder H, Petersilka M, Gruber K, Suss C, et al. First performance evaluation of a dual-source CT (DSCT) system. *Eur Radiol* 2006;16:256-268
- Achenbach S, Ropers D, Kuettner A, Flohr T, Ohnesorge B, Bruder H, et al. Contrast-enhanced coronary artery visualization by dual-source computed tomography--initial experience. *Eur J Radiol* 2006;57:331-335
- Johnson TR, Nikolaou K, Wintersperger BJ, Leber AW, von Ziegler F, Rist C, et al. Dual-source CT cardiac imaging: initial experience. *Eur Radiol* 2006;16:1409-1415
- Austen WG, Edwards JE, Frye RL, Gensini GG, Gott VL, Griffith LS, et al. A reporting system on patients evaluated for coronary artery disease. Report of the Ad Hoc Committee for Grading of Coronary Artery Disease, Council on Cardiovascular Surgery, American Heart Association. *Circulation* 1975;51:5-40
- Johnson TR, Nikolaou K, Busch S, Leber AW, Becker A, Wintersperger BJ, et al. Diagnostic accuracy of dual-source computed tomography in the diagnosis of coronary artery disease. *Invest Radiol* 2007;42:684-691
- Althen JN. Automatic tube-current modulation in CT--a comparison between different solutions. *Radiat Prot Dosimetry* 2005;114:308-312
- Pasricha SS, Nandurkar D, Seneviratne SK, Cameron JD, Crossett M, Schneider-Kolsky ME, et al. Image quality of coronary 320-MDCT in patients with atrial fibrillation: initial experience. *AJR Am J Roentgenol* 2009;193:1514-1521
- Oncel D, Oncel G, Tastan A. Effectiveness of dual-source CT

- coronary angiography for the evaluation of coronary artery disease in patients with atrial fibrillation: initial experience. *Radiology* 2007;245:703-711
16. Rist C, Johnson TR, Muller-Starck J, Arnoldi E, Saam T, Becker A, et al. Noninvasive coronary angiography using dual-source computed tomography in patients with atrial fibrillation. *Invest Radiol* 2009;44:159-167
 17. Marwan M, Pflederer T, Schepis T, Lang A, Muschiol G, Ropers D, et al. Accuracy of dual-source computed tomography to identify significant coronary artery disease in patients with atrial fibrillation: comparison with coronary angiography. *Eur Heart J* 2010;31:2230-2237
 18. Leschka S, Scheffel H, Desbiolles L, Plass A, Gaemperli O, Valenta I, et al. Image quality and reconstruction intervals of dual-source CT coronary angiography: recommendations for ECG-pulsing windowing. *Invest Radiol* 2007;42:543-549
 19. Stein PD, Beemath A, Kayali F, Skaf E, Sanchez J, Olson RE. Multidetector computed tomography for the diagnosis of coronary artery disease: a systematic review. *Am J Med* 2006;119:203-216
 20. Herzog C, Arning-Erb M, Zangos S, Eichler K, Hammerstingl R, Dogan S, et al. Multi-detector row CT coronary angiography: influence of reconstruction technique and heart rate on image quality. *Radiology* 2006;238:75-86
 21. Leschka S, Wildermuth S, Boehm T, Desbiolles L, Husmann L, Plass A, et al. Noninvasive coronary angiography with 64-section CT: effect of average heart rate and heart rate variability on image quality. *Radiology* 2006;241:378-385
 22. Scheffel H, Alkadhi H, Plass A, Vachenaue R, Desbiolles L, Gaemperli O, et al. Accuracy of dual-source CT coronary angiography: First experience in a high pre-test probability population without heart rate control. *Eur Radiol* 2006;16:2739-2747
 23. Wang Y, Zhang Z, Kong L, Song L, Merges RD, Chen J, et al. Dual-source CT coronary angiography in patients with atrial fibrillation: comparison with single-source CT. *Eur J Radiol* 2008;68:434-441
 24. Rixe J, Rolf A, Conradi G, Elsaesser A, Moellmann H, Nef HM, et al. Image quality on dual-source computed-tomographic coronary angiography. *Eur Radiol* 2008;18:1857-1862