

Internationally Indexed Journal

Indexed in Chemical Abstract Services(USA), Index Copernicus, Ulrichs Directory of Periodicals, Google scholar, Cabi, DOAJ, PSOAR, EBSCO, SCOPUS, EMBASE etc.



Rapid Publishing

The International Journal of Pharma and Bio Sciences (IJPBS) is an international journal published quarterly. The Aim of IJPBS is to publish peer reviewed research and review articles in less time without much delay in the developing field of Pharmaceutical and Biological sciences. One week from the date of manuscript submission author gets the decision of acceptance and if accepted the manuscript will be processed within 3 weeks (approx.) for publication.

Pharmaceutical Sciences

Branches

- | | |
|---------------------------|------------------------|
| → Pharmaceutics | → Polymer sciences |
| → Novel drug delivery sys | → Biomaterial sciences |
| → Nanotechnology | → Medicinal chemistry |
| → Pharmacology | → Natural chemistry |
| → Pharmacognosy | → Biotechnology |
| → Analytical chemistry | → Pharmacoinformatics |
| → Pharmacy practice | → Biopharmaceutics |
| → Pharmacogenomics | |

Biological Sciences

Branches

- | | |
|-------------------|---------------------|
| → Biochemistry | → Molecular biology |
| → Biotechnology | → Neurobiology |
| → Bioinformatics | → Cytology |
| → Cell biology | → Pathology |
| → Microbiology | → Immunobiology |
| → Allied Sciences | |



Impact Factor 0.47*

*Refer Instruction to authors available at
www.ijpbs.net



Indexed In Elsevier Bibliographic Database
(SCOPUS, EMBASE and Sciverse)

Journal Home page
www.ijpbs.net

FOR INSTRUCTION TO AUTHORS VISIT
www.ijpbs.net

FOR ANY QUERIES EMAIL TO

- editorofijpbs@yahoo.com
- editorijpbs@rediffmail.com
- prasmol@rediffmail.com



**PROTECTIVE EFFECT OF *EMBLICA OFFICINALIS* ON CHLORPYRIFOS
(AN ORGANOPHOSPHATE INSECTICIDE) INDUCED MALE
REPRODUCTIVE SYSTEM IN RATS.**

ABIR LAL DUTTA^{1*} AND CHITTA RANJAN SAHU²


^{1*} - Research Scholar, Cell and developmental biology laboratory, Department of Zoology,
University of Kalyani, Kalyani, Nadia, West Bengal, India .pin- 741235.

² – Professor, Cell and developmental biology laboratory, Department of Zoology,
University of Kalyani, Kalyani, Nadia, West Bengal, India .pin- 741235.

ABSTRACT

Chlorpyrifos is one of the mostly used organophosphates insecticides, has a major toxic effect in mammalian rat's reproductive system. The ancient Indian herbal formulation, *Embllica officinalis* plays a major role to subvert many diseases in human body. Through a preliminary study, we have tried to establish the ameliorative properties of *Embllica officinalis* with respect to reproductive rejuvenation in case of *Rattus norvegicus*, (Wistar Strain). Adult male albino rats were exposed in 7mg/kg/day chlorpyrifos, 20mg/kg/d amla, 7mg chlorpyrifos with 20mg amla/kg/d body weight for 30 days. The Present study indicates that chlorpyrifos provoked an alteration of body weight, male reproductive organs weight and sperm related parameters. These changes are potentially detrimental and lead to infertility in rats. However, when the subjects were treated with amla and chlorpyrifos, these parameters tend to be normalized, thus highlighting the debilitating effect of chlorpyrifos and remedial effect of *Embllica officinalis*.

KEY WORDS: Organophosphate compounds (OP), Chlorpyrifos (CPF), *Embllica officinalis* (EO), traditional use, ameliorative, fertility, male reproduction.



ABIR LAL DUTTA

Research Scholar, Cell and developmental biology laboratory, Department of Zoology,
University of Kalyani, Kalyani, Nadia, West Bengal, India .pin- 741235.

*Corresponding author

INTRODUCTION

Pesticides enhanced the economic potentiality in agriculture to controlling the pest, on the debit side are the serious health implication for animals and as well as man¹. The population of non –agricultural countries also may be exposed to pesticides residues in food stuffs, especially fruits and vegetables, imported from other countries² or as a result of bioaccumulation in the food chain, including marine products³. Pesticides have a dual action- one is controlling the injurious pests and another is they also present a hazard to species not considered to be pest in the environment⁴. Organophosphates pesticides show their biological effect mainly through the electrophilic attack of cellular constituents with simultaneous generation of reactive oxygen species (ROS)⁵. Chlorpyrifos (CPF) [o,o-diethyl-o (3,5,6 – trichloro-2-pyridyl)- is an organophosphates insecticide with a broad range of activity against arthropods, pest of plants, animals including humans⁶. CPF is also known as a residential pesticide for killing fire ants, cockroach and other household pests. Particularly this pesticide has an effect on behavioral and neurological aspect *Emblica officinalis* (E.O), commonly known as amla is one of the fruits which contain a bioactive component showing antioxidative property. It is a traditional medicine, widely used in India (Asia)⁷⁻⁸. *Emblica officinalis* (EO) enjoys a vital position in pharmacology. In Unani medicine, the dried E.O fruits are used to treat hemorrhage, diarrhea, dysentery⁹ vomiting, cough, jaundice, fever, scurvy, diabetes etc¹⁰⁻¹². It is a very rich source of ascorbic acid¹³. *Emblica* is found to be a good herbal protector and at the same time non-toxic, reasonable and easily available botanical material. The aim of this study is to measure the male reproductive toxicity through the low dose chlorpyrifos (CPF) administration. Administration of *Emblica officinalis* was found to have ameliorative properties on the adverse effect caused by consumption of chlorpyrifos

on the reproductive system of male rats. In reproductive pharmacology, for our knowledge, there exists no previous scientific literature on *Emblica* as remedial representative for reproductive toxicity related disorder in male reproductive system.

MATERIALS AND METHODS

Animals

Healthy adult male albion rats (*Rattus norvegicus*, Wistar Strain) (weight approx. 170-220g) were used in the present study. The animals were housed individually in plastic cages, maintaining at a room temperature (21-24°C ± 3°C) in uniform light dark cycle (14:10:L:D). The animals were provided with diet (W.B.Dairy & Poultry Dev. Corp. Ltd.) and water *ad libitum* throughout the course of study. Animals were quarantined for 10 days before beginning of the experiments. The work related to rat experimentation was conducted with the permission from ethical committee (Vide ref no 892/ac/05/CPCSEA).

Chemicals

Chlorpyrifos was obtained from Nagarjuna Agrichem Limited (Hyderabad, Andhra Pradesh, India) for this experiment. All other chemicals were of analytical grade and were obtained from local commercial sources. EO was procured from local market. The fruits were washed, dried and crushed. The 20mg crushed material was extracted with 1 ml of water, and this extracted juice was given to the rat.

Animals' treatment schedule

Rat were divided into two groups, control (n=5) and experimental groups (n=15). The experimental groups were divided into three groups. Group1 (G1) received 20mg EO/ kg bw/d (n=5), group 2(G2) received 7mg CPF/ kg bw/d (n=5) and group3 (G3) received 7mg CPF /kg bw/d with 20mg EO/kg bw /d (n=5), through

oral intubations. The control groups however received the same amount of water. After taking the body weight, both control and experimental rats were sacrificed after 30 days of treatment and samples were taken for organ weight measurement, Sperm motility analysis, sperm density, testicular sperm count and epididymal sperm morphology,

Body and organ weights

The body weight has been measured on the day of starting of experiment and also on the day of sacrifice (31st day), both the control and experimental group, by automatic balance. The increment of body weight is showed in percentage. Similarly weight of different reproductive organs (Testis, Seminal vesicle, Epididymis) was also recorded.

Testicular Sperm count

Testicular sperm count was determined by the following Uzunhisarcikli et al., 2007 ¹⁴

Sperm motility analysis

Sperm motility was determined by the following Uzunhisarcikli et al., 2007 ¹⁴

Epididymal sperm morphology

Sperm morphology was assessed by the method of Filler, 1993 ¹⁵.

Sperm density

The reproductive organ epididymis was removed and fixed in Bouins fixative for 12-14 hrs. It was processed in a series of graded ethanol and embedded in paraffin. Section were cut at 5µm thickness and stained with hematoxylin (Leblond & Clermont, 1952) and eosin for light microscopic examination. The qualitative changes were recorded. In the

lumen of the epididymis sperm density was observed and was graded as normal (+++), moderately decreased (++) , or severely decreased (+), depending on the concentration of spermatozoa in the tubular cross-sections through the microscope.

Statistical analysis

Data were statistically analyzed using *t*-test. The maximum significant level chosen was $P<0.05$.

RESULTS

Evaluation of Body and organ weights

Death was not observed in any of the experimental groups during experimental periods. It is observed from the table-1, that the body weight increased with the advancement of age, both in control and in the treated groups. The body weight decreased significantly, $P<0.001$ and $P<0.05$, after 30 days treatment for G2 group and G3 group respectively, However in case of G1 group it increased significantly ($P<0.001$) than the control one. But the recovery group G3, Rats fed with Chlorpyrifos with Amla, gained body weight significantly ($P<0.001$) than the treated group G2. The weight of testis, epididymis and seminal vesicle and relative weight of seminal vesicle of G2 group significantly decreased ($P<0.001$) and ($P<0.01$) respectively, than the control value Table-2. When amla was singly fed, experimental organs showed no significant changes than the control groups. Due to recovery aspects, in group G3, the organ weight significantly increased than the G2 group, especially in testis ($P<0.001$). However they showed no significance changes than the control group.

Table-1
Body weight

Day & Dose	No of animal exposed	Initial body weight (gm)	Final body weight (gm)	Body weight increased (%)
Control	5	180.4	212.49	17.78
		± 4.54	± 5.40	± 0.09
G1	5	188.42	224	19.51 ***
		± 2.94	± 2.91	± 0.20
G2	5	190.8	208.4	9.16 ***
		± 3.42	± 3.90	± 0.28
G3	5	188.70	219.85	16.56* aaa
		± 3.33	± 3.71	± 0.24

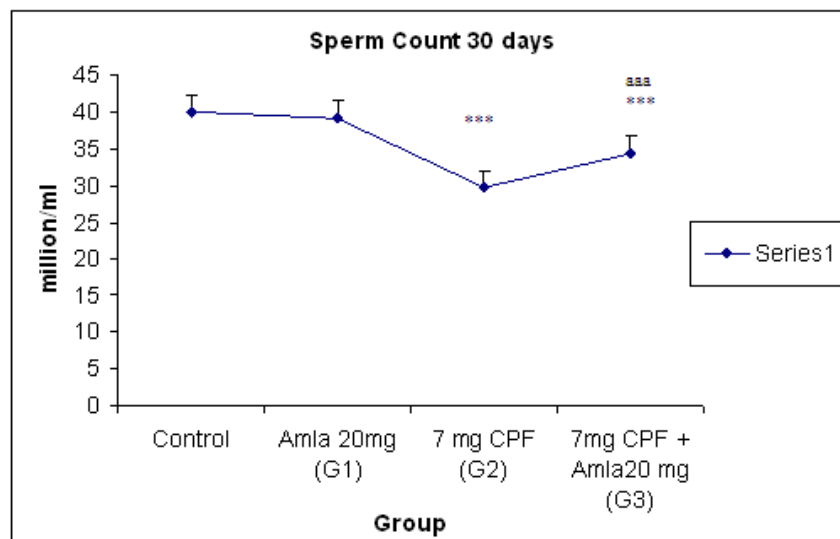
Table-2
Organs weight.

Day & Dose	No of animal exposed	Testis (gm)		Seminal vesicle (gm)		Epididymis (gm)	
		Absolute weight of body weight	Relative weight of body weight	Absolute weight of body weight	Relative weight of body weight	Absolute weight of body weight	Relative weight of body weight
Control	5	1.88	0.89	0.75	0.35	0.8	0.38
		± 0.06	± 0.03	± 0.04	± 0.01	± 0.03	± 0.01
G1	5	2.03	0.9	0.81	0.36	0.85	0.38
		0.05	0.01	0.04	0.02	0.03	0.01
G2	5	1.23	0.59	0.47	0.23	0.55	0.26
		***	***	***	**	***	***
G3	5	0.07	0.03	0.04	0.02	0.03	0.01
		1.82	0.83	0.69	0.31	0.72	0.33
		aaa	aaa	a	a	a	
		±0.02	±0.01	±0.04	±0.02	±0.03	±0.01

Evaluation of Testicular Sperm count

Figure 1 shows that the sperm count of G2 and G3 group significantly decreased ($P<0.001$) than the control group. Besides, the sperm count significantly increased ($P<0.001$) in G3 group than the G2 group. However, when amla was singly fed, there were no significant changes in testicular sperm count as compared to the control group.

Figure-1
Sperm count

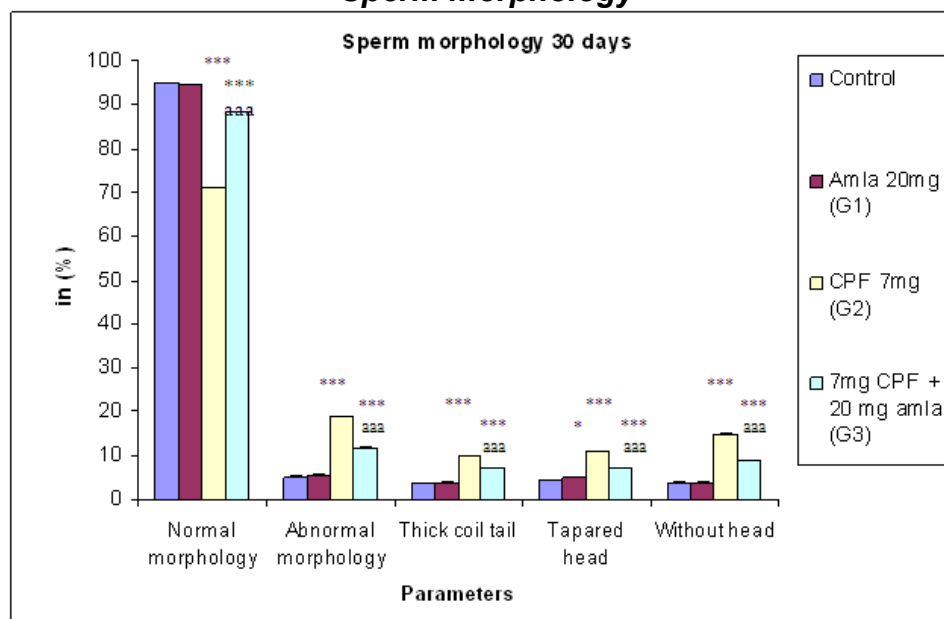


Evaluation of Epididymal sperm morphology

A significant decline ($P<0.001$) was found in normal sperm morphology in G2 and G3 group than the control group. Simultaneously, a significant increment ($P<0.001$) was showed in abnormal sperm morphological structure in both the group G2 and G3 after 30 days of exposure (fig 2). Thick coil tail, tapered head

and without head are the criteria of abnormal sperm morphology. In recovery aspect, the normal sperm morphology significantly increased ($P<0.001$) and abnormal sperm morphology significantly decreased than the group G2. No statistically significant changes were detected in normal and abnormal sperm morphology when only amla was singly administered.

Figure-2
Sperm morphology



Evaluation of Sperm motility analysis

A significant decline, $P<0.001$ and $P<0.01$, was observed in total epididymal sperm motility at the end of 30th day in G2 and G3 group respectively than the control (fig 3). But the data shows a significant increment ($P<0.001$) in group G3 than the treated group G2. Single amla fed group had no significant difference than the control group.

Figure 3
Sperm motility

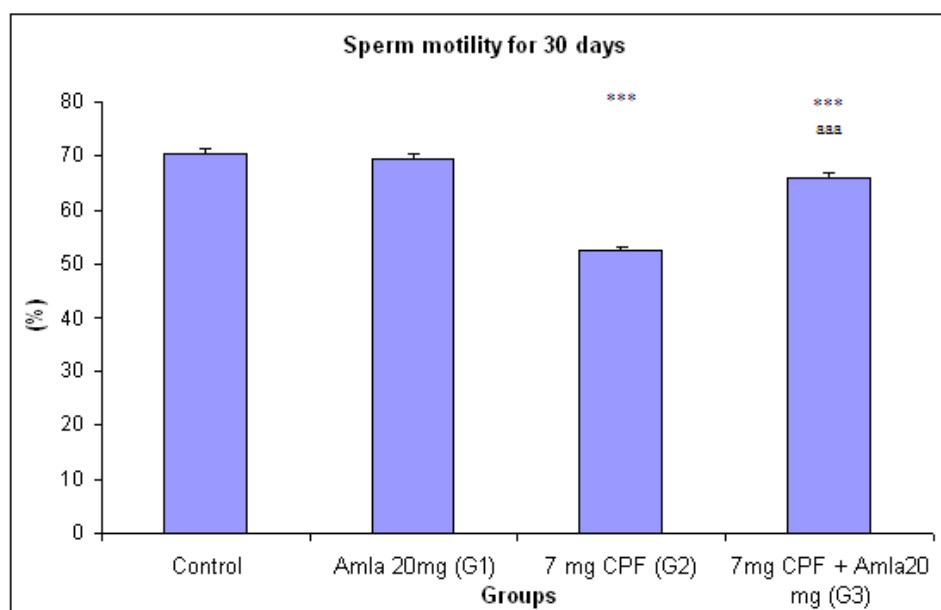


Fig-1,2,3 and Table-1,2-All data are presented as mean \pm S.E.M from five similar experiments. Data are significant at the level * $P<0.001$, ** $P<0.01$, and * $P<0.05$ for G1 G2 and G3 than the control animals. G2, aaa $P<0.001$, aa $P<0.01$ and a $P<0.05$ for G3 than the G2**

Sperm density

In case of CPF treated group, (G2), sperm density is reduced in the lumen of epididymal tubule as compared to the control rats (Table3). In epididymis, the control animals showed normal sperm density (+++). However, the sperm density is decreased (++) in 7mg/ kg d CPF treated group. But when CPF was fed with amla, the sperms showed a normal density (+++).Single amla fed group showed normal sperm density (+++).

Table-3
Sperm density (microscopically observed) for 30 days treatment.

Group	Sperm density
Control	+++
G1	+++
G2	++
G3	+++

+++ showing normal sperm density, ++ showing moderately decreased sperm density

DISCUSSION

The exponential increase in production, use and disposition of pesticides has a fundamental impact on the environment and creates unanticipated hazards to many organisms, including humans¹⁶⁻¹⁸. Organophosphates (OP) are the most widely used synthetic pesticides and it has a causable effect in fertility¹⁹. Herbal materials like amla, used in ancient medicines, are capable to subvert those toxic effects. The present study demonstrated that 30 day's exposure of male rats to chlorpyrifos at the dose of 7mg/kg b.w/day resulted in decreased body weight, reproductive organ weight (testis, epididymis and seminal vesicle), testicular sperm count, normal sperm morphology, sperm motility and sperm density in tested tissues. Our results showed that the body weight and reproductive organ weight significantly decreased upon chlorpyrifos treatment²⁰. According to Joshi *et al.*, 2007; the reproductive organs weight decreased significantly at various dose levels (7.5, 12.5 and 17.5 mg/kg b.w./day) for 30 days chlorpyrifos treatment. Similar results were found in Chitra *et al.*, 2004²¹, in endosulfan treated rats, indicating injury at testicular, pituitary or hypothalamic level. The epididymis and seminal vesicles are androgen-dependent organs and a reduction in their weights may reflect a decline of androgen production. The decrease in testicular weight in treated rats may be due to reduction of tubule size, spermatogenic arrest and inhibition of steroid biosynthesis of leydig cells²²⁻²³. In the present study, it is found that when amla was fed with CPF, there was a significant recovery in body and organ weight. Similar findings were observed when amla was fed singly, as compared to the control group. It may be due to recovery of organ or tissue injury or due to revitalized androgen secretion. According to Mode *et al.*, 2009²⁴, broiler birds gain their body weight due to amla treatment for 28 to 42 days. This body weight gain might be due to the hepatoprotecting activity resulting in the

improvement in the liver function²⁵⁻²⁷. The similar view was present in a master document of Natural Remedies Pvt.Ltd²⁸.

The observed decline in testis weight could be an indicator of sperm toxicity due to CPF treatment²⁹. Parallely, sperm cell degeneration is an essential indicator of sperm toxicity. The sperm count is one of the most sensitive tests for spermatogenesis and it is highly correlated with fertility. The decrease in sperm motility and density in chlorpyrifos treated group may be due to inadequacy of androgen³⁰ which caused anorgasmia in testicular functions by altering the activities of the enzymes which is contributing for spermatogenesis³¹⁻³². According to Zidan, 2009²⁰, percentage of sperm motility and sperm count significantly decreased in both the three pesticides (chlorpyrifos methyl, dizinon and profenofos,) and highest effect was noticed in case of diazinon exposure. The sperm morphology is considered as a better discriminator between fertility and infertility³³. Sperm morphology and motility is a useful marker of toxic damage³⁴. Similar result was showed by Abd El-Aziz *et al.*, 1994³⁵, who revealed that diazinon treated rats exhibited a decrease in sperm motility, associated with an increment of dead sperm percentage. According to Aikten *et al.*, 1984³⁶, sperm motility is an important functional measurement to anticipate their fertilizing capacity. Any negative impact on motility would gravely affect fertilizing ability of the organism³⁷. Sperm motility is seriously affected by the low level of ATP content and it may be affected by alteration of the enzymatic activities of oxidative phosphorytic process. Similarly oxidative phosphorytic process is required for ATP production, a source of energy for the alleviated movement of spermatozoa¹⁹. Full ATP pool is crucial for normal spermatozoal movement and a slight deprivation of ATP leads to reduction in motility, which is one of the major causes of infertility³⁸. According to

Chakraborty and Verma, 2009³⁹, oral administration of aqueous extract of *Emblica officinalis* along with ochratoxin for 45 days, significantly mitigated ochratoxin-induced alterations in reproductive parameters of mice. The recovery aspect of the herbal product, *Emblica officinalis*, find similar light in our study where there was a significant increase in sperm count, normal sperm morphology and sperm motility in case of amla treated group when compared to the CPF treated group. This shows the ameliorative effect of *Emblica officinalis*. Here amla works as an adjuvant. This might be due to the presence of bioactive compounds, namely: emblicanin A, emblicanin B, punigluconin and pedunculagin which are known to provide protection against oxygen radicals in various *in vitro* studies⁸.

CONCLUSION

Under the light of this study, it is concluded that chlorpyrifos is responsible for alteration of body weight, male reproductive organs weight, sperm morphology, sperm count, sperm motility and sperm density. These changes are potentially detrimental and lead to infertility in rats. Our results reveal that due to chlorpyrifos exposure; male fertility diminishes, thus being harmful to any animal, mammals as well as

human being. Based on our results obtained, it can be concluded that herbal formulation of *Emblica officinalis* boosts the male reproductive response. EO contains antioxidants which reduces oxidative stress and alleviates the toxicological changes. Amla fruit juice neutralizes the oxidizing potentials of reactive oxygen species generated and through these activities they maintain cell membrane integrity and viability. The present study highlights that amla plays an essential role to contain the chlorpyrifos toxicity in male reproductive system. The scavenging of oxygen radicals' property possessed by amla can achieve a healthy protection against chlorpyrifos induced male reproductive toxicity; the recovery might hasten with increased amla intake.

ACNOWLEDGMENT

This work was supported by University of Kalyani, Department of Zoology, Kalyani, Nadia, West Bengal, India and funding agency is University Grant Commission, India (U.G.C). I have taken the help from Debargha Chakraborty and Pradipta Dubey Research Scholar of the Department of Environmental Science and Rural Development and Management respectively, University of Kalyani.

REFERENCES

1. Bhatnagar V K, Pesticides pollution: Trends and perspective. ICMR Bulletin, 31: 1-9, (2001).
2. IPCS (International Programme on Chemical Safety), Environmental health criteria 145, Methyl parathion. WHO, 11-236, (1993).
3. Makita Y, Omura M, Tanaka A, and Kiyohara C, Effects of concurrent exposure to tributyltin and 1,1-dichloro-2,2 bis (p-chlorophenyl) ethylene (p,p'-DDE) on immature male Wistar rats. Basic clin pharmacol Toxicol, 97:364-368, (2005).
4. Tripathi S, Srivastav A K, Alterations in the profile of blood cells of wistar rats induced by long-term ingestion of chlorpyrifos. International J pharma and bio science, 1(4):315-322, (2010).
5. Dwivedi P D, Das M, and Khanna S K, Role of cytochrome P₄₅₀ in quinalphos toxicity: effect on hepatic and brain antioxidant enzymes in rats. Food Chem Toxicology, 36: 437-444, (1998).
6. Breslin W J, Liberacki A B, Dittenber D A, and Quast J F, Evaluation of the developmental and reproductive toxicity of

- chlorpyrifos in rat. Fundamental and applied toxicology, 29:119-130, (1996).
7. Ghosal S, Tripathi V K, and Chauhan S, Active constituents of *Embllica officinalis* Part I, the Chemistry and antioxidative effects of two hydrolysable tannins, emblicanin A and B. Indian J Chem 35 (B), 941-948 (1996).
8. Bhattacharya A, Chaterjee A, Ghosal S, and Bhattacharya S K, Antioxidant activity of active tannoid principles of *Embllica officinalis* (amla). Indian Journal of Experimental Biology, 37: 676, (1999).
9. Parroatta A J, Healing plants of peninsular India. CABI publishing New York, (2001).
10. Roy A K, Dhir H, Sharma A, and Talukder G, Comparative efficacy of Phyllanthus emblica fruit extract and ascorbic acid in modifying hepatotoxic and renotoxic effects induced by metals in vivo. International Journal of Pharmacology, 29: 117-126, (1991).
11. Sivarajan V V, Ayurvedic drugs and their plant sources. Labanon New Hampshire. International science publishers, (1994).
12. Mathur R, Sharma A, Dixit V P, and Varma M, Hypolipidaemic effect of fruit juice of *Embllica officinalis* in cholesterol-fed rabbits. Journal of ethnopharmacol, 50; 61, (1996).
13. Twarei S, Seshadri M, and Poduval T B, Migration inhibition of normal rat thymocytes as an in vitro method of detecting cell mediated rat and mouse. Journal of Immunological Methods, 51: 231-239, (1982).
14. Uzunhisarcikli M, Kalender Y, Dirican K, Kalender S, Ogutcu A, and Buyukkomurcu F, Acute, subacute and subchronic administration of Methyl parathion-induced testicular damage in male rats and protective role of vitamins C and E, Pesticides Biochem and physio, 87: 115-122, (2007).
15. Filler R, Methods for evaluation of the rat epididymal sperm morphology, in: R.E. Chapin, J. J. Heindel (eds.), *Male reproductive Toxicology, Methods in Toxicology Vol 3A*, New York: Academic Press 1993, 3: 334-343.
16. Chia S E, Endocrine disruptors and male reproductive function, A short review. Indian Journal of Andrology, 23: 45-46, (2000).
17. Karallieda L D, Edwards P, and Marrs T, C, Variables influencing the toxic response to organophosphates in humans. Food and Chemical Toxicology, 41: 11-13, (2003).
18. Karanthi S, Olivier K, and Pope J C, Interactive toxicity of organophosphorus insecticides chlorpyrifos and methyl parathion in adult rats. Toxicology and Applied Pharmacol 196: 183-190, (2004).
19. Joshi S C, Mathur R, and Gulati N, Testicular toxicity of chlorpyrifos (an organophosphate pesticide) in albino rat. Toxicology and Industrial Health, 23: 439-444, (2007).
20. Zidan N A, Evaluation of the reproductive toxicity of chlorpyrifos methyl, diazinon and profenofos pesticides in male rats. International journal of pharmacology, 5 (1): 51-57, (2009).
21. Chitra K C, Latchoumycandane C, and Mathur P P, Chronic effect of endosulfan on the testicular functions of rat. Asian Journal of Andrology, 1: 203-206, (1999).
22. Sujatatha R, Chitra K C, Latchoumycandane C, and Mathur P P, Effect of lindane on testicular antioxidant system and steroidogenic enzymes in adult rats. Asian Journal of Andrology, 3: 135-138, (2001).
23. Kaur C, and Mangat H K, Effects of estradiol dipropionate on the biochemical composition of testes and accessory sex organs of adult rats. Andrologia, 12 (4): 373-378, (1980).
24. Mode S G, Funde S T, Waghmarc S P, and Kolta A Y, Effect of herbal immunodulator on body weight gain in immunosuppressed broiler birds. Veterinary world, Vol 2 (7): 269-270, (2009).
25. Pande C B, Zeestress-A promising adptogenic antistress and

- immunomodulator-a review. Pashudhan, 15 (12): 4, (2000).
26. Babu B J, Kalkumar B, Reddy K S, Roa A S, Effect of Zeestress in cypermethrin induced suppression of growth and immunity in broiler. Review of aromatic and medicinal plants, 9 (2): 221, (2002).
27. Ratankumar M, Kalukumar M B, Arunkumar H S, and Reddy K S, Effect of Zestress on alfatoxin depressed growth and immunity in broilers. Indian vet J, 81: 903-904(2004).
28. This master document is exclusive intellectual property of natural remedies Pvt.Ltd, *Emblica officinalis*, thaiherbinfo.com/herb/phyllanthus emblica_phytochemistry/emblica officinalis. Natural remedies Plot 5B, Veerasandra Indl. Area, 19th K.M. Stone, Hosur road, Bangalore-561229.
29. Ohtani K, Yamazaki S, Kubota H, Miyagawa M. and Saegusa J, Comparative investigation of several sperm analysis methods for evaluation of spermatotoxicity of industrial chemical : 2- Bromopropane as an example. Industrial health, 42: 219-225, (2004).
30. Chadhuary N, and Joshi SC, Reproductive toxicity of endosulfan in male albino rats. Bull Environ Contam Toxicology, 70: 185-289, (2003).
31. Siha N, Narayan R, Shanker R, and Saxena, D.K, Endosulfan-induced biochemical changes in the testis of rats. Veterinary and Human Toxicology, 37 (6): 547-549, (1995).
32. Reuber M D, The role of toxicity in the carcinogenicity of endosulfan. Sci Total Environ, 20: 23-47, (1981).
33. Guzik D , Overstreet J, Factor-Litvak P, Brazil C K, and Nakajima S T, Sperm morphology, motility and concentration in fertile and infertile men. N Engl J Med. 345: 1388-1393, (2001).
34. Holdcraft R W, and Braun R E, Hormonal regulation of spermatogenesis. Int J Androl, 27:335-342, (2004).
35. Abd El-Aziz M I, Sahlab A M, and Abd El-Khalik M, Influence of diazinon and deltamethrin on reproductive organs and fertility of male rats. Dtsch Tierarzyl Wochenschr, 101: 230-232, (1994).
36. Aikten R I, Best F S M, Warner P, and Templeton A, prospective study of the relationship between semen quality and fertility in cases of unexplained infertility. International J andrology, 5: 297-303, (1984).
37. Murugavel T, Ruknu din A, Thangavelu S, and Akbarsha M A, Antifertility effect of *Vinca rosea* (Linn) leaf extract on male albino mice A sperm parametric study. Current Science, 58 (19):1102-1103, (1989).
38. Tso W W, and Lee C S, Effect of gossypol on boar spermatozoa *in vitro*. Archives of Andrology, 7: 85-88, (1981).
39. Chakraborty D, and Verma R, Spermatotoxic effect of ochratoxin and its amelioration by *Emblica officinalis* aqueous extract. Acta poloniac pharmacutica- Drug research, 66 (6): 689-695, (2009).